

The Male Breast: Masses, Malignancies and More

*Monique Marie Tyminski, DO, R Hultman, DO, J Watkins, MD,
T Stockl, MD, E T Ghosh, MD, S A MacMaster, MD*

Teaching Points:

- **Understand male breast anatomy and correlate with examples of male breast pathology seen on breast imaging**
- **Demonstrate the common imaging presentations of multiple benign and malignant diseases of the male breast**
- **Help narrow the differential diagnosis and understanding of both common and uncommon male breast lesions**
- **Examples of benign breast disease and breast cancer as well as extramammary breast cancer will be presented with clinical history, imaging findings on mammography, ultrasound, CT and MRI with pathology correlation images**

Anatomy of a Normal Male Breast

Pectoralis muscle

Skin

Nipple

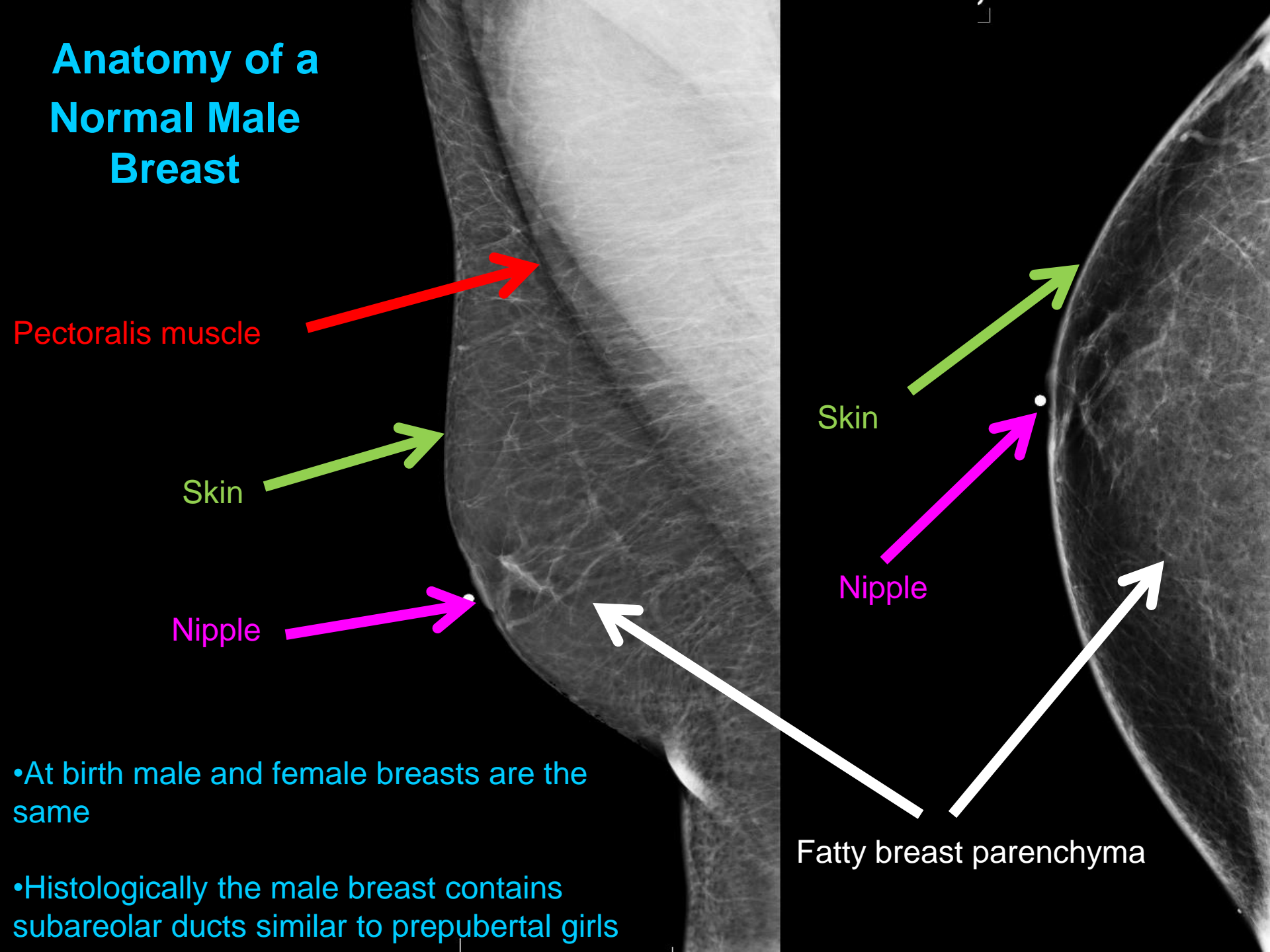
Skin

Nipple

Fatty breast parenchyma

•At birth male and female breasts are the same

•Histologically the male breast contains subareolar ducts similar to prepubertal girls



Normal Male Breast

Male breasts do not have Coopers ligaments

Lobule formation is **extremely** rare

Lobular absence explains the rarity of

Cyst formation

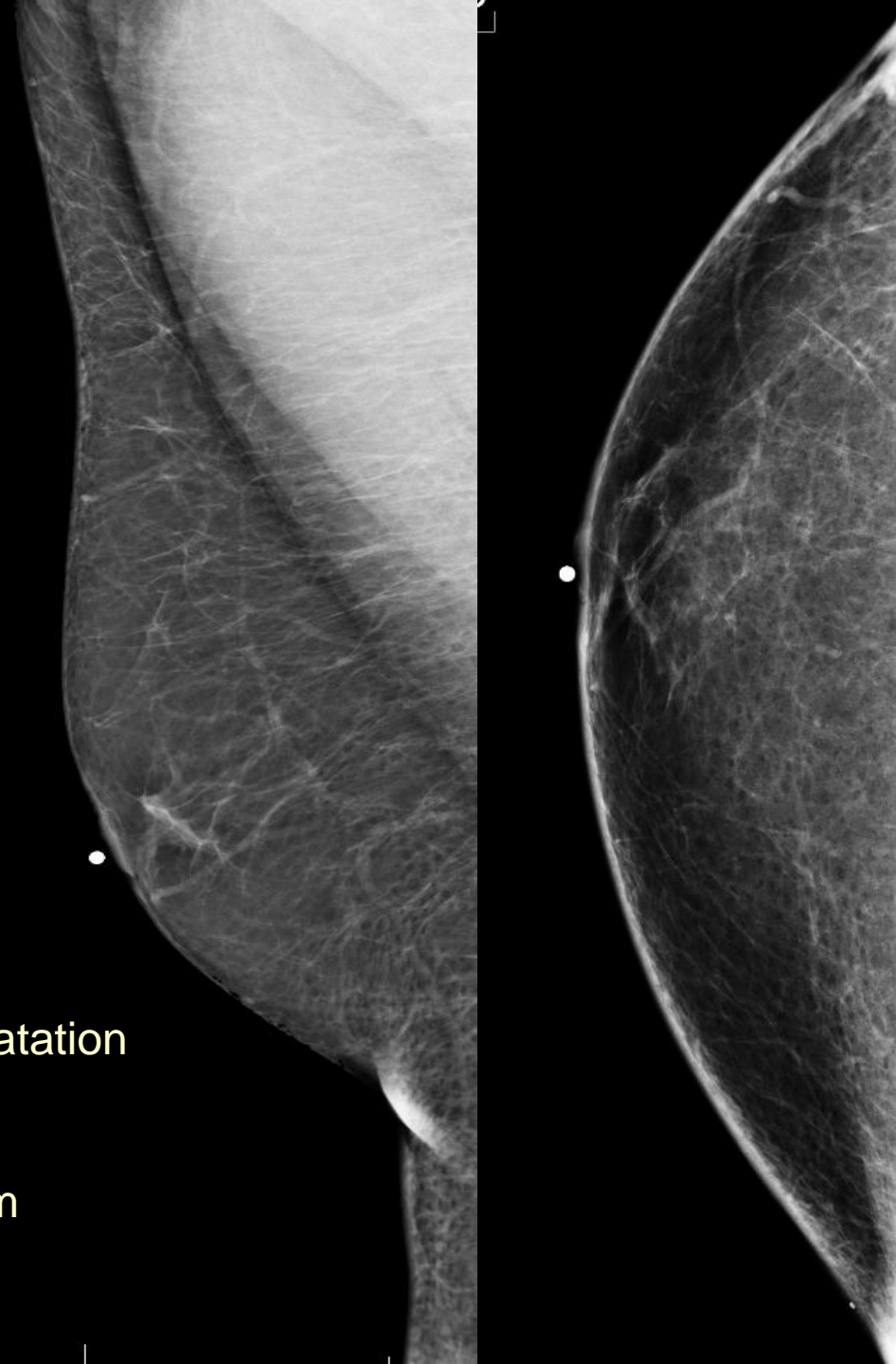Fibroadenomas

Lobular cancer

Phyllodes tumors

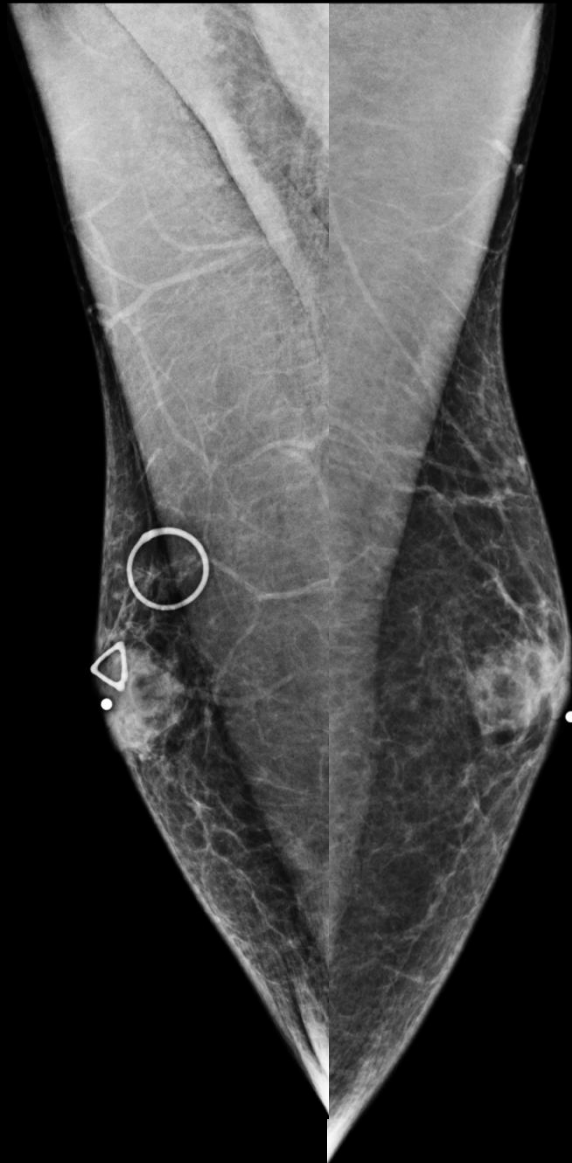Cysts in men are most likely due to ductal dilatation or cystic neoplasms

Cancers in males develop in ductal epithelium



Gynecomastia: Mammogram

- Usually presents as a soft, mobile, tender, subareolar mass
- Typically forms a fan/deltoid shape radiating from nipple usually to UOQ
- Lateral margins are usually straight or concave and can be indistinct or blend into surrounding fat
- Deep margin slightly irregular with interspersed fat

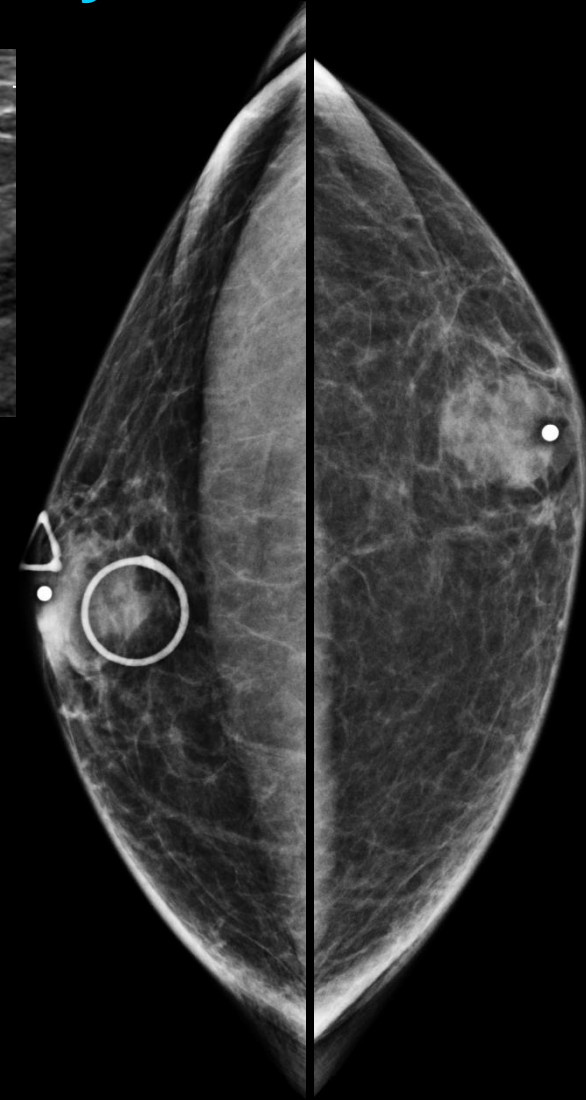
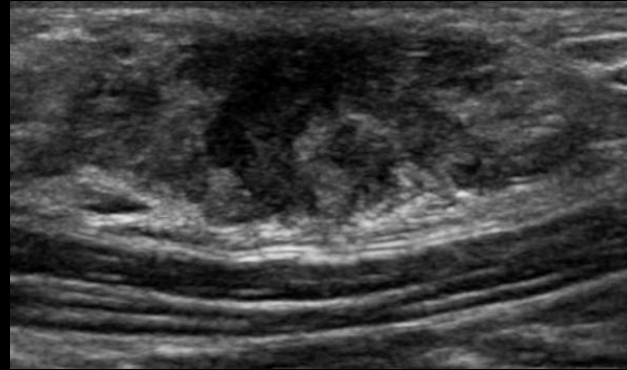
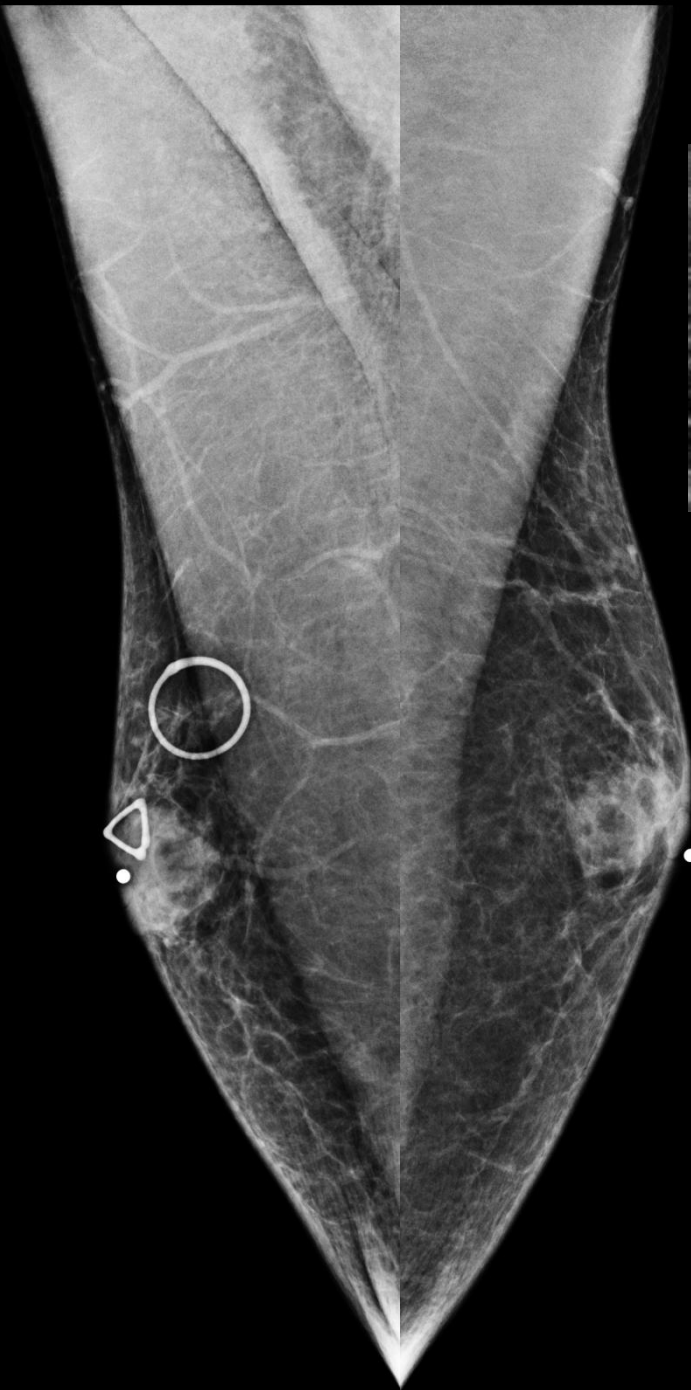

- Benign proliferation of subareolar ductal and periductal stromal tissues
- Many causes but underlying mechanism is an imbalance of estrogenic and testosterone effects at breast tissue level
- Degree of ductal proliferation and periductal fibrosis depends on length and degree of stimulation

Gynecomastia

- Three phases
- Nodular:
 - Correlates to pathologic stage of florid gynecomastia
 - Early phase
 - Increased number of ducts and epithelial proliferation with loose cellular stroma and edema- reversible
- Dendritic:
 - Correlates to pathologic fibrotic phase
 - Dilated ducts, moderate epithelial proliferation and fibrosis
- Diffuse:
 - Has appearance similar to a heterogeneously dense female breast with both nodular and dendritic components
 - Corresponds histopathologically to proliferative changes in some cases with lobule formation

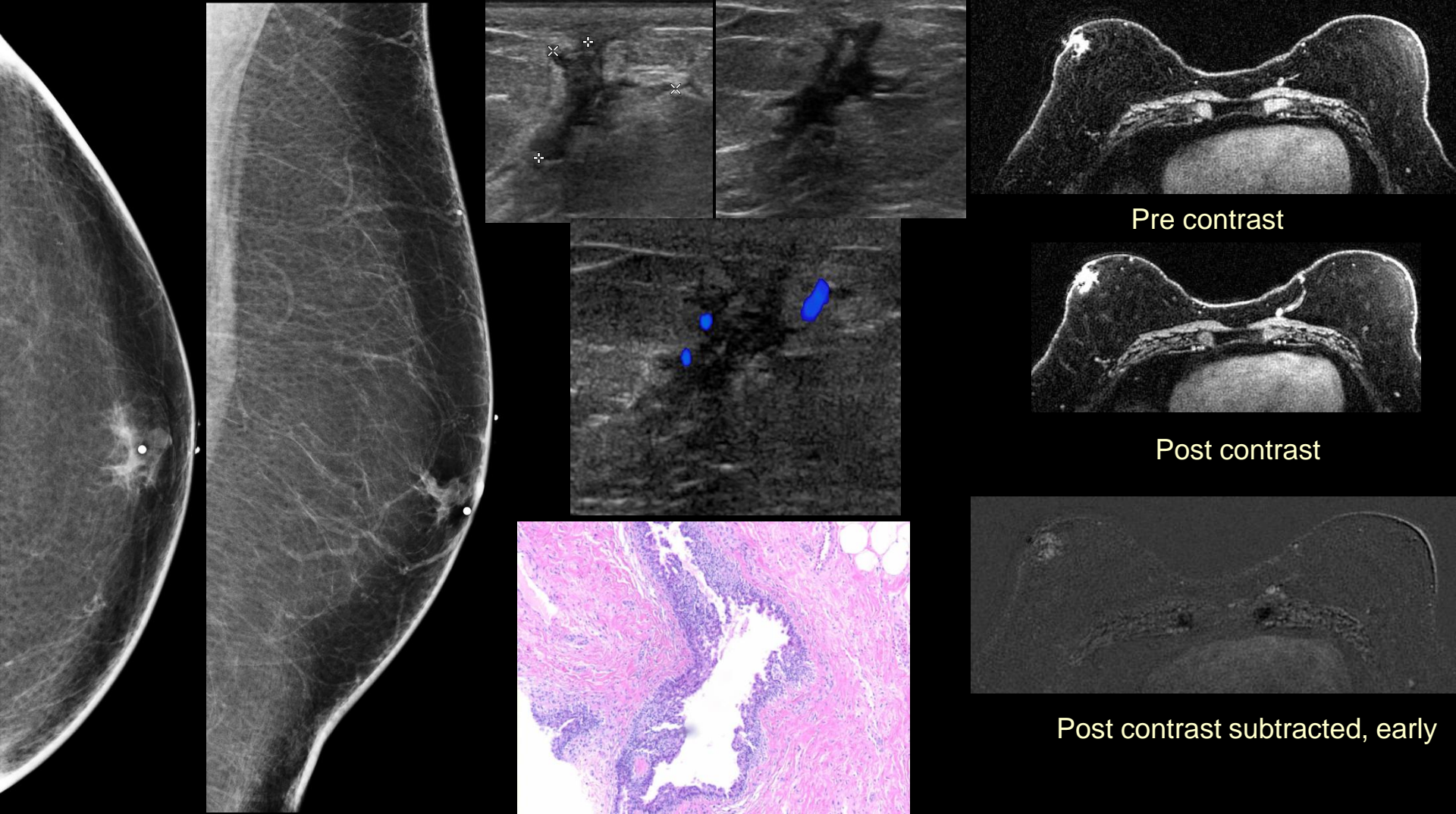
Nodular (Florid) Gynecomastia



25 M bilateral palpable breast lumps:

Mammogram: Scattered fan shaped retroareolar fibroglandular tissue bilaterally.

Ultrasound: Hypoechoic retroareolar fibroglandular tissue.



Pre contrast

Post contrast

Post contrast subtracted, early

Nodular (Florid) Gynecomastia

56 M palpable right breast mass and history of father with breast cancer:

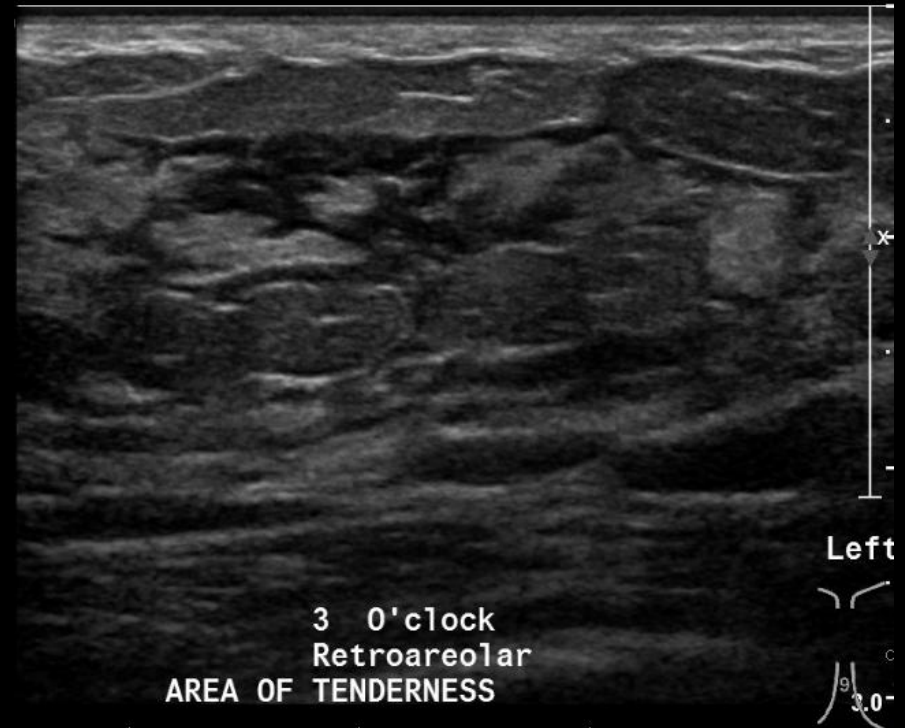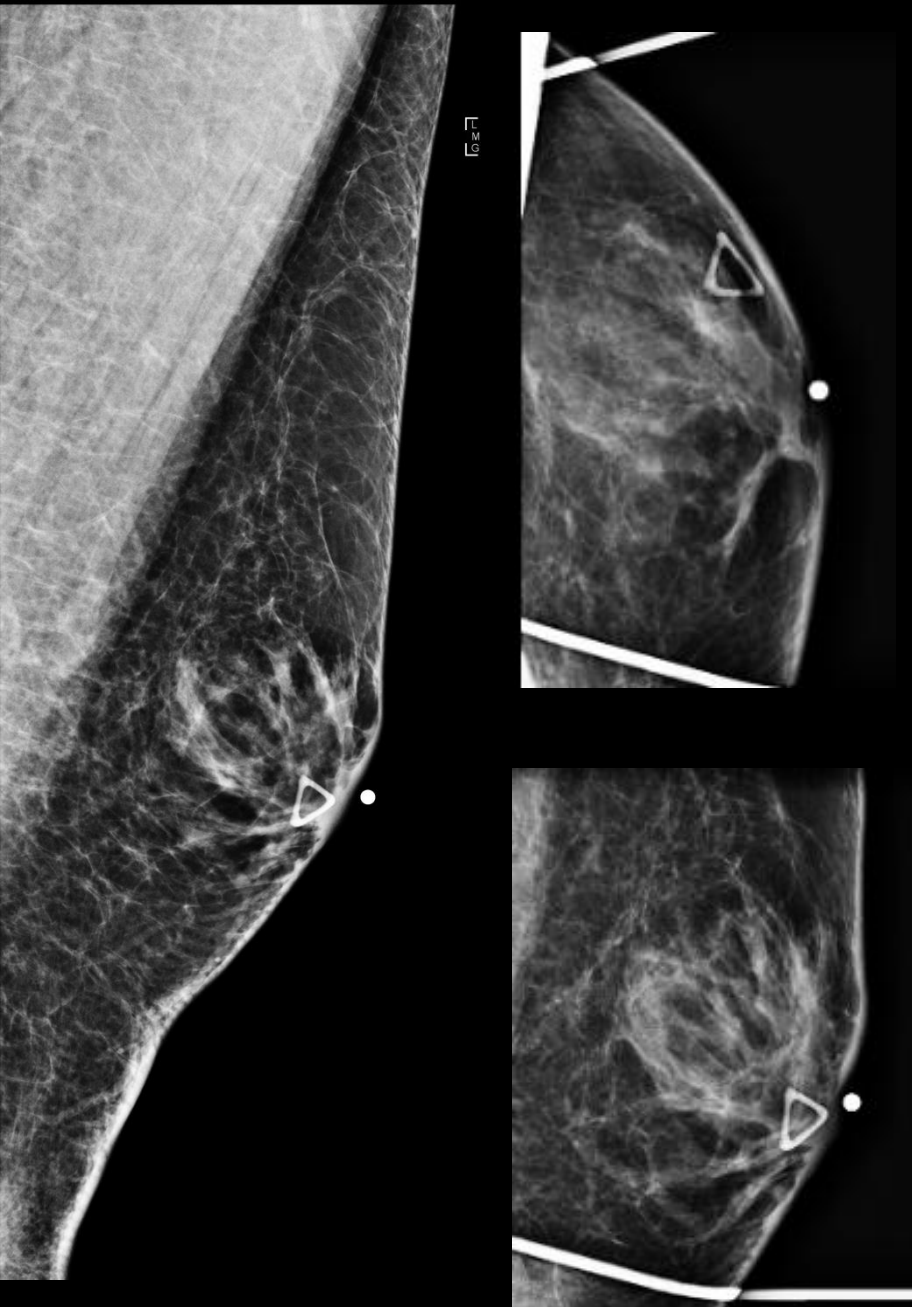
Mammogram: Irregular retroareolar nodular tissue.

Ultrasound: 8 x 8 mm irregular hypoechoic subareolar mass with angular margins, internal vascularity, no posterior features

MRI: Asymmetric regional non-mass like enhancement retroareolar breast with mixed kinetics and areas of washout, high in T1 signal pre-contrast images.

Pathology: Micropapillary hyperplasia of the ductal epithelium with fibrotic surrounding stroma.

Dendritic Fibrotic Gynecomastia

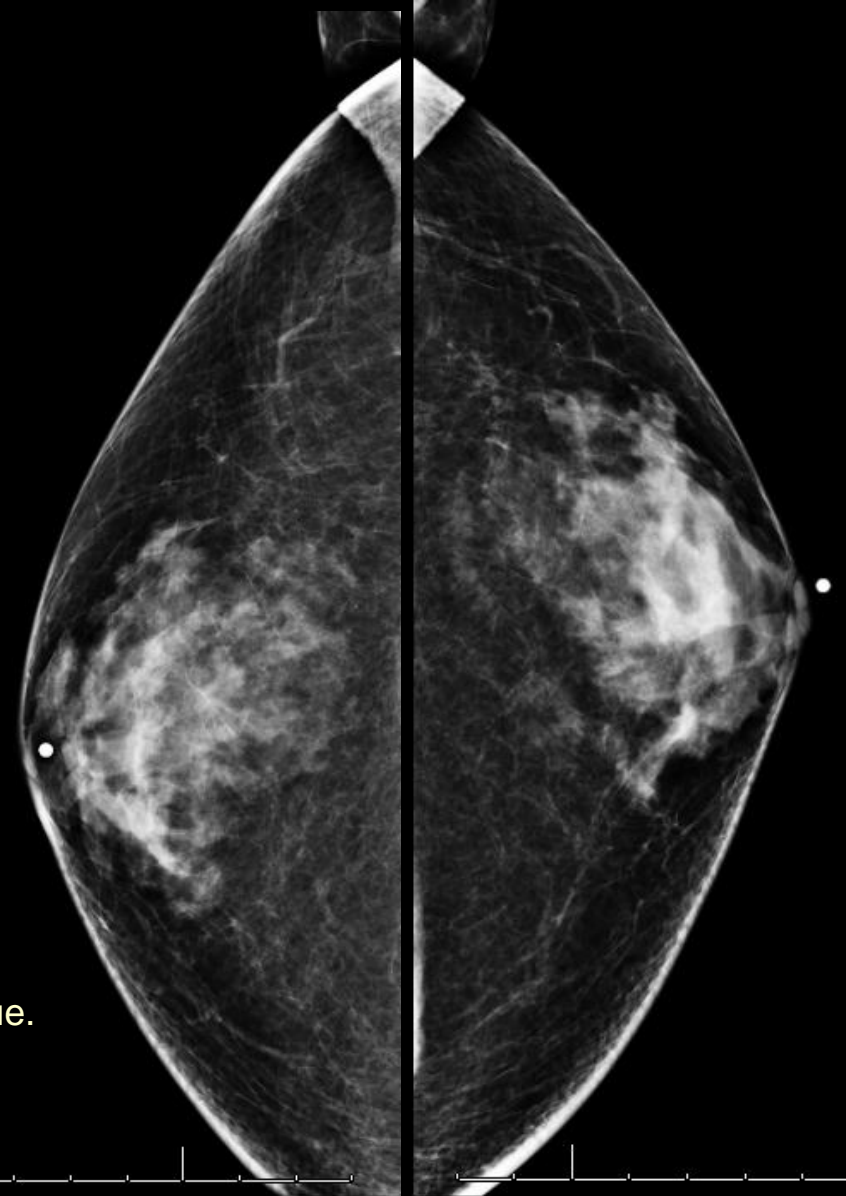
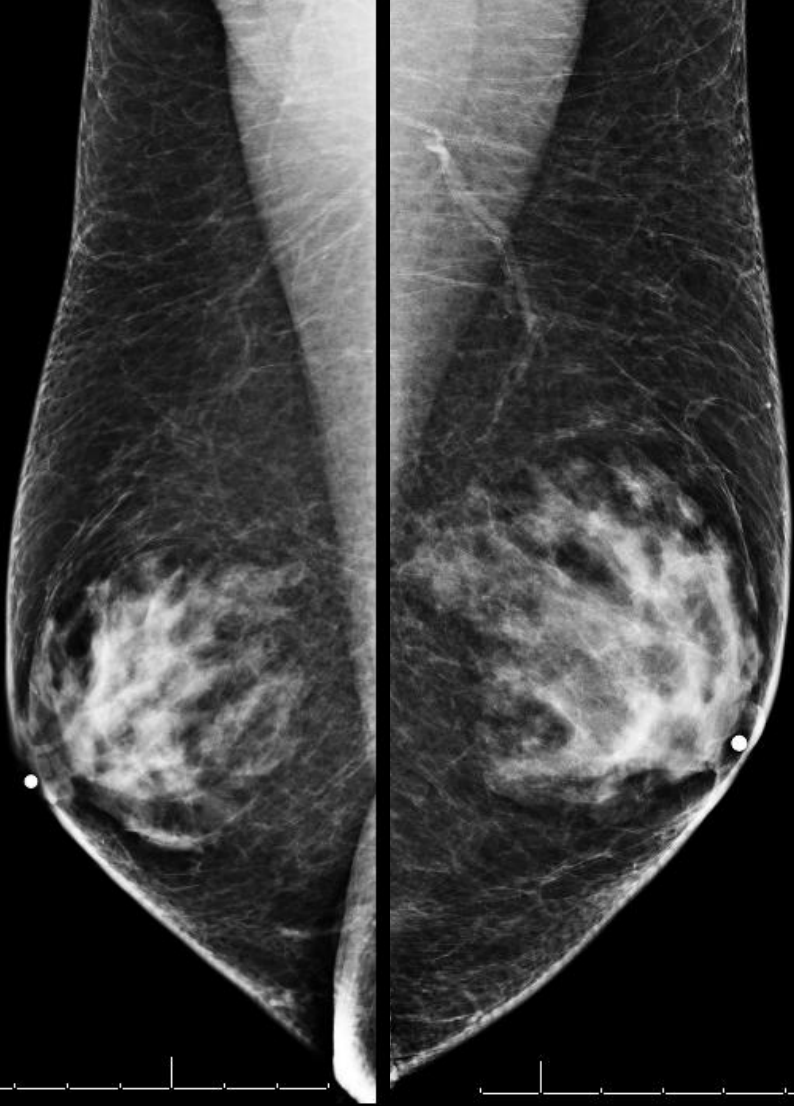


40 M left palpable breast lump:

Mammogram: Scattered retroareolar fibroglandular tissue.

Ultrasound: Hypoechoic scattered retroareolar fibroglandular tissue.

Diffuse Gynecomastia

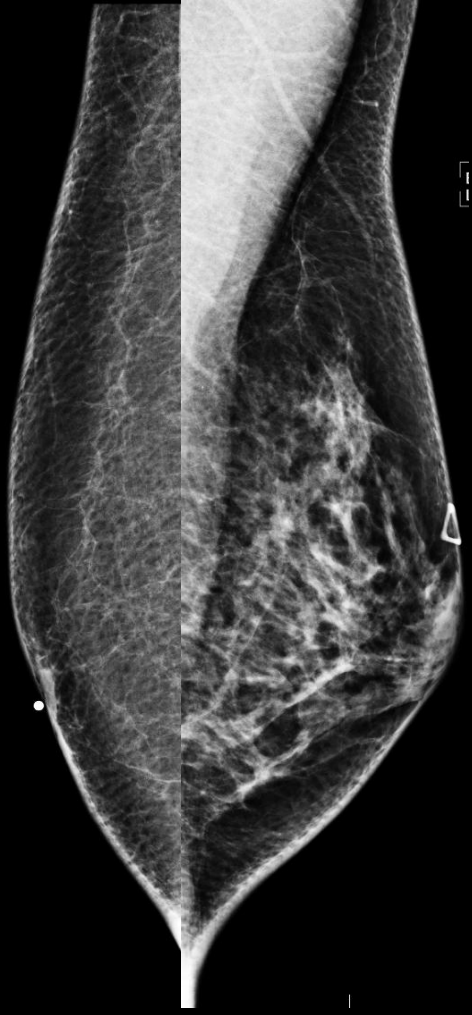

71 M bilateral palpable breast lumps and pain:
Mammogram: Bilateral dense retroareolar fibroglandular tissue.

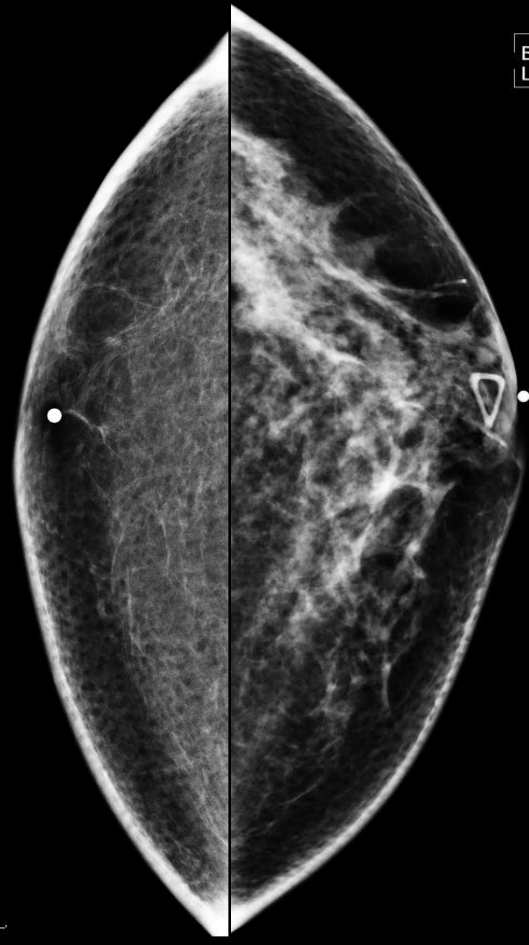Diffuse

Gynecomastia

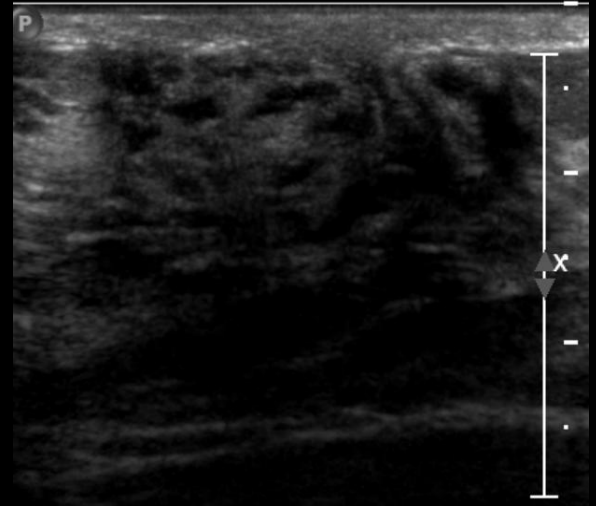
R



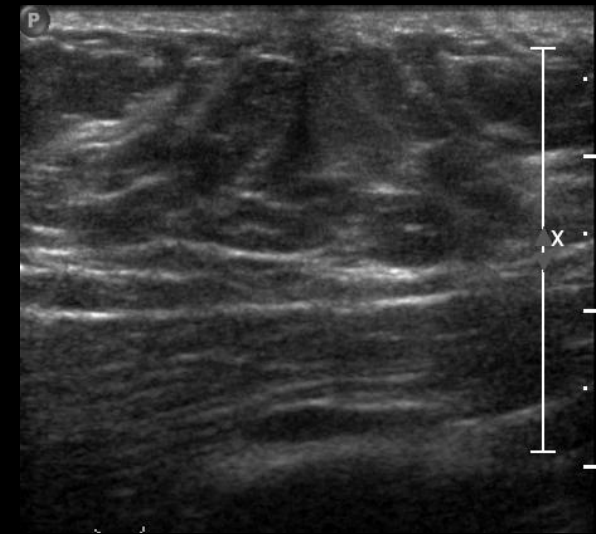
L



E
L



Sagittal left retroareolar



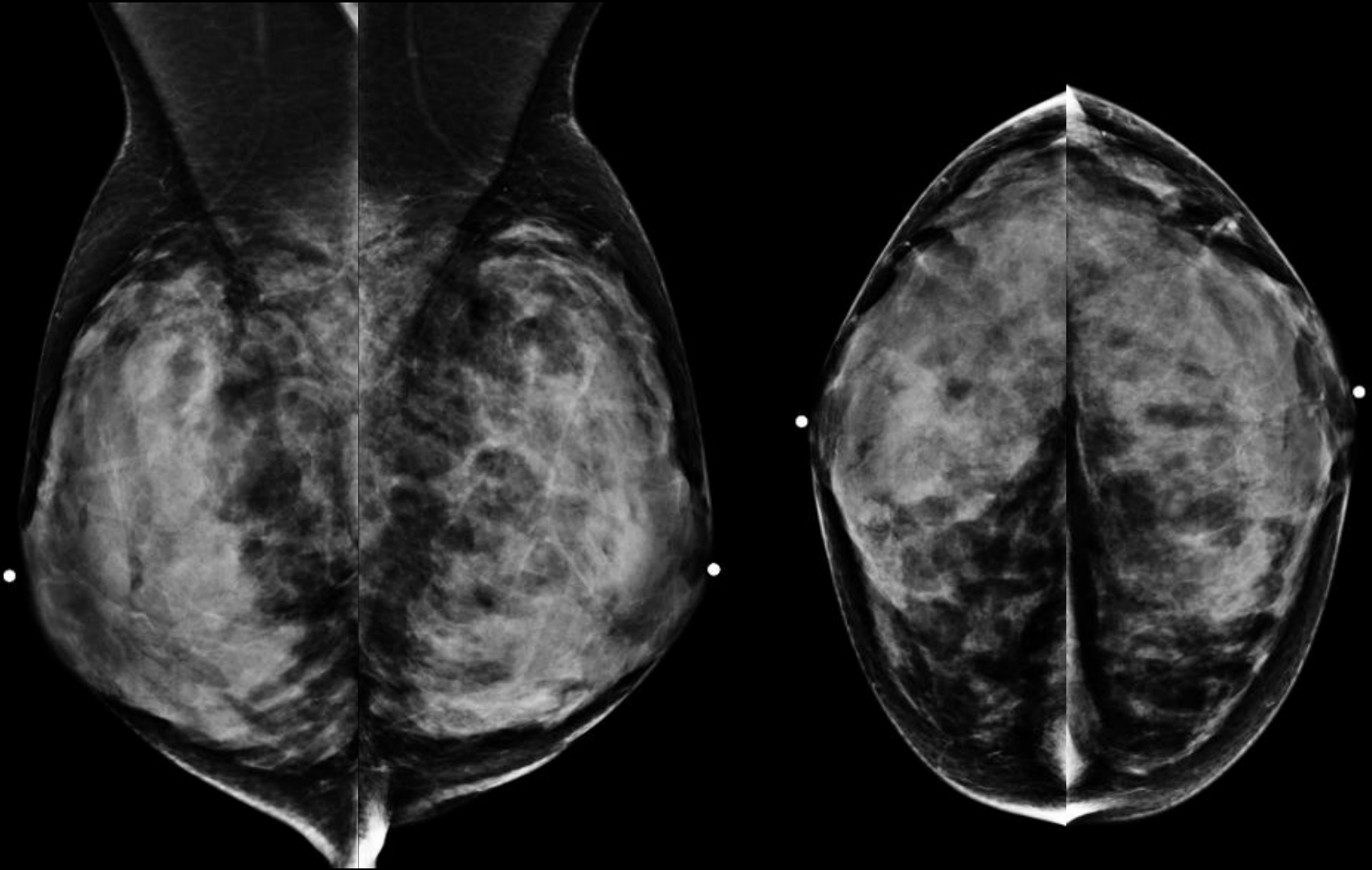
Sagittal right retroareolar

24 M left palpable breast lump:

Mammogram: Asymmetric dense fibroglandular tissue in the left breast.

Ultrasound: hypoechoic area of retroareolar tissue in the left breast.

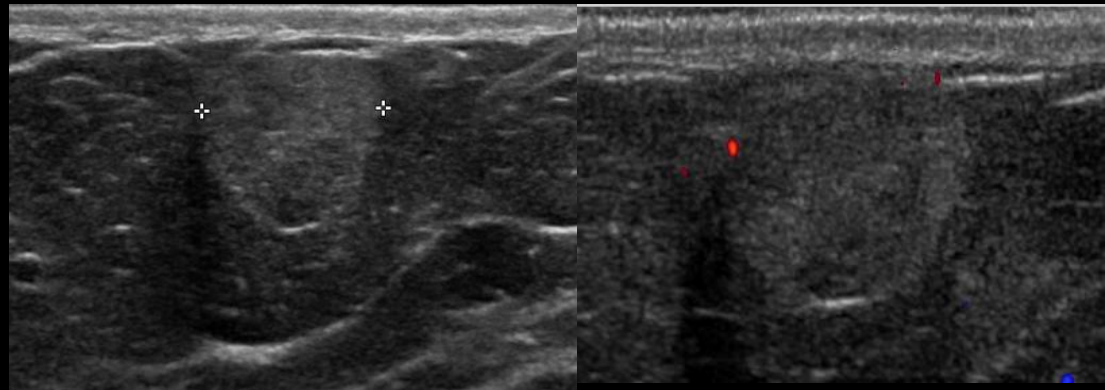
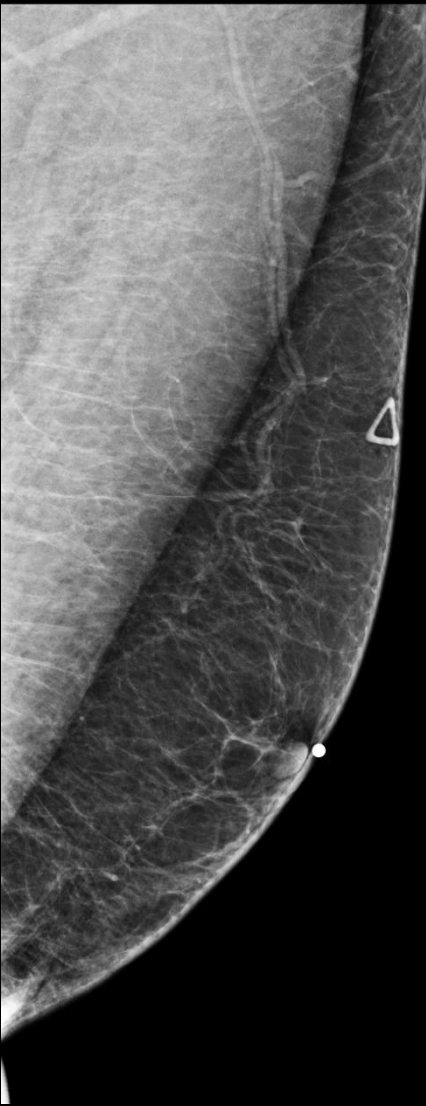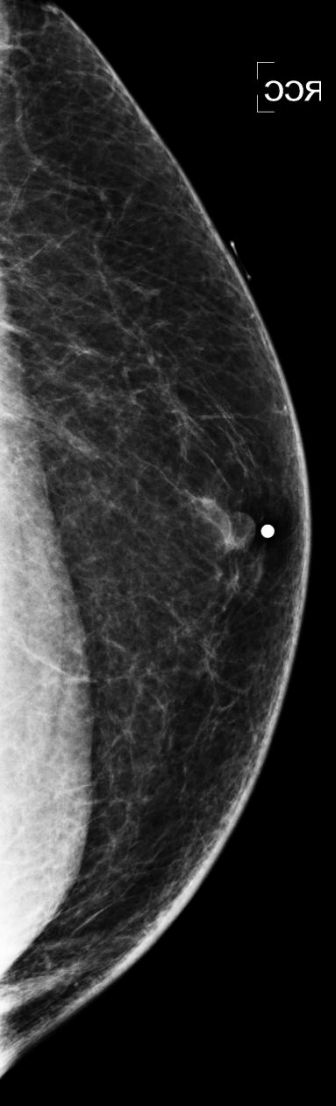EXOGENOUS ESTROGEN IN TRANSGENDER PATIENT



53 M transgender on exogenous estrogen presents with breast tenderness:
Mammogram: Extremely dense breasts with extensive diffuse bilateral gynecomastia.

Lipoma

- Second most common male lesion after gynecomastia
- More commonly hyperechoic in men than in women
- Less compressible in men than women due to high fibrous content



54 M with bilateral palpable lumps:

Mammogram Right Breast: No significant masses, calcifications, or abnormalities.

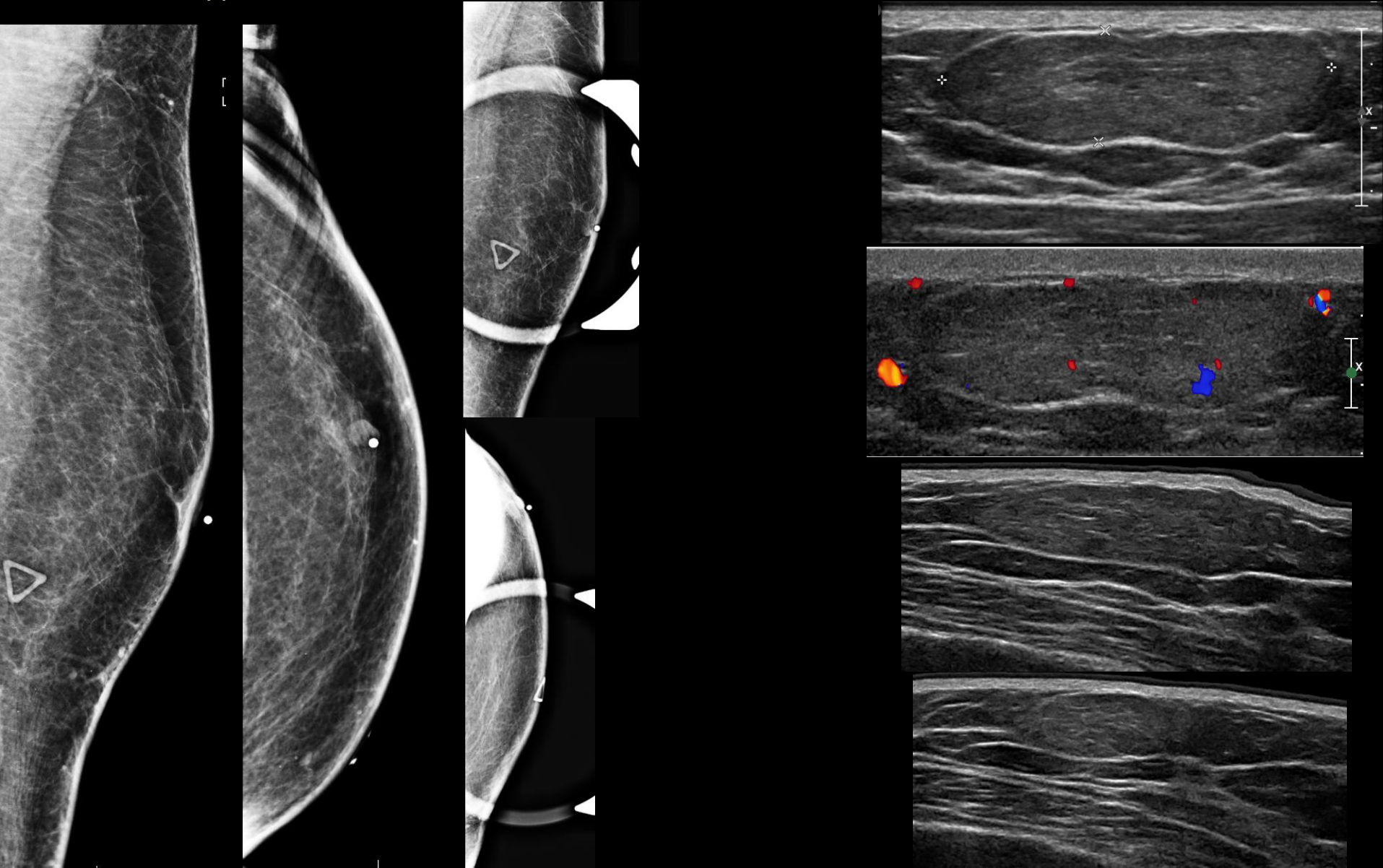
US Right Breast: 9 x 11 x 8 mm circumscribed echogenic mass at the site of palpable abnormality 10 o'clock 8cm from nipple, no internal flow.

66 M with palpable left breast lump:

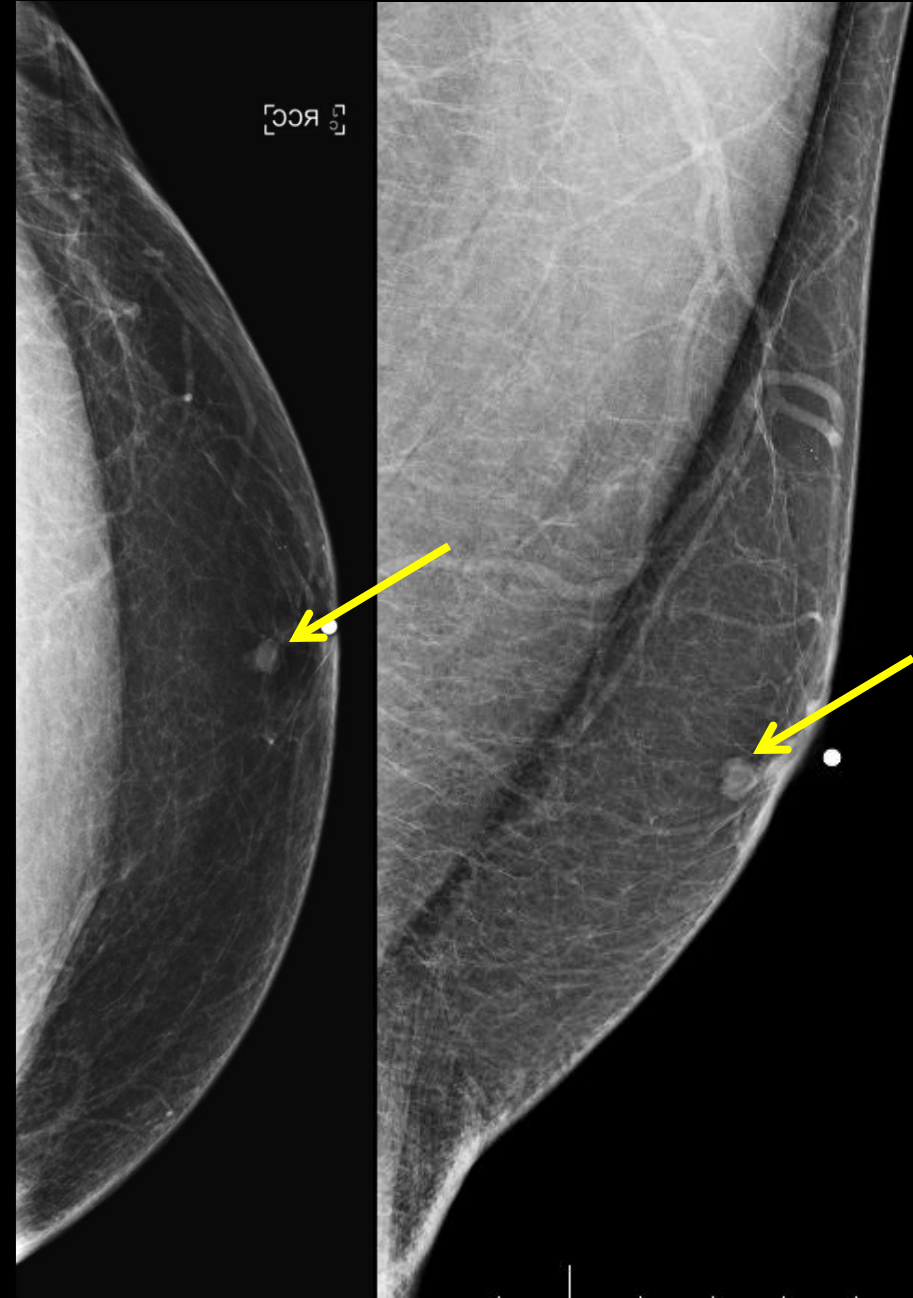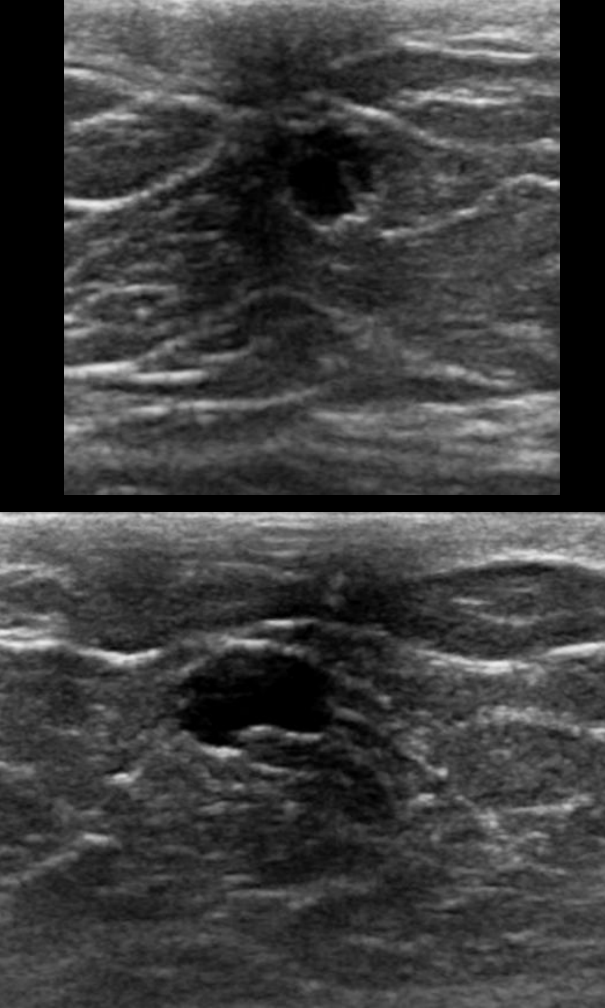
Mammogram: No significant masses, calcifications or other abnormalities.

Ultrasound: Ovoid echogenic solid mass measuring 36 x 30 x 9mm at 9 o'clock 7 cm from the nipple.

Lipoma



Cyst

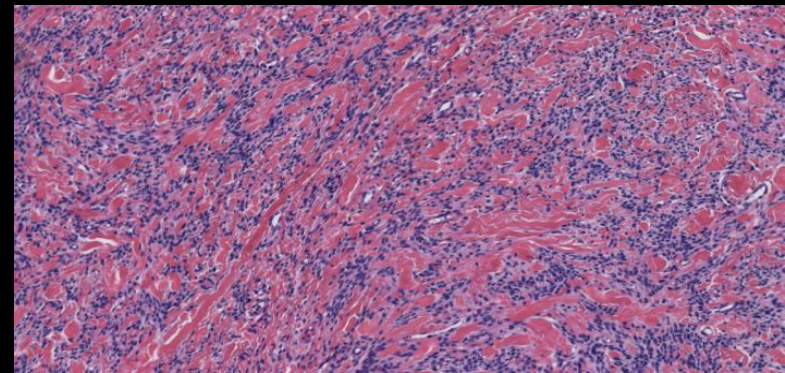
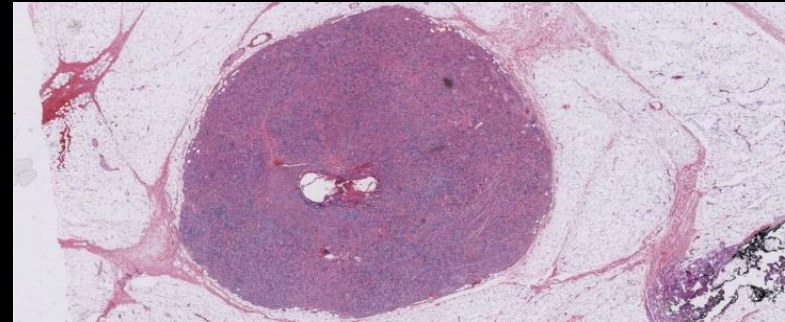
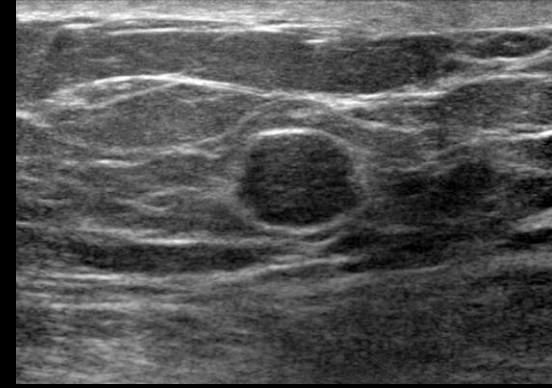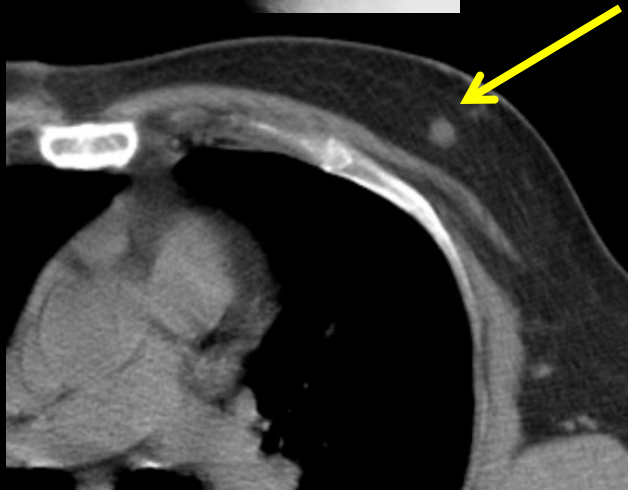
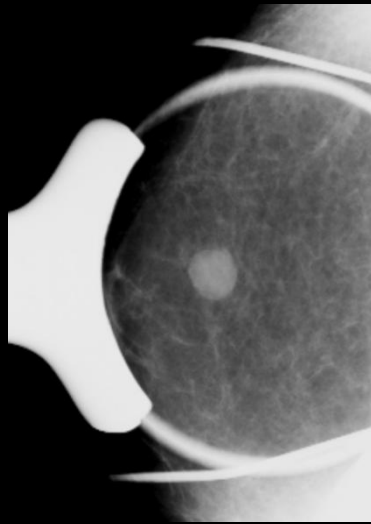
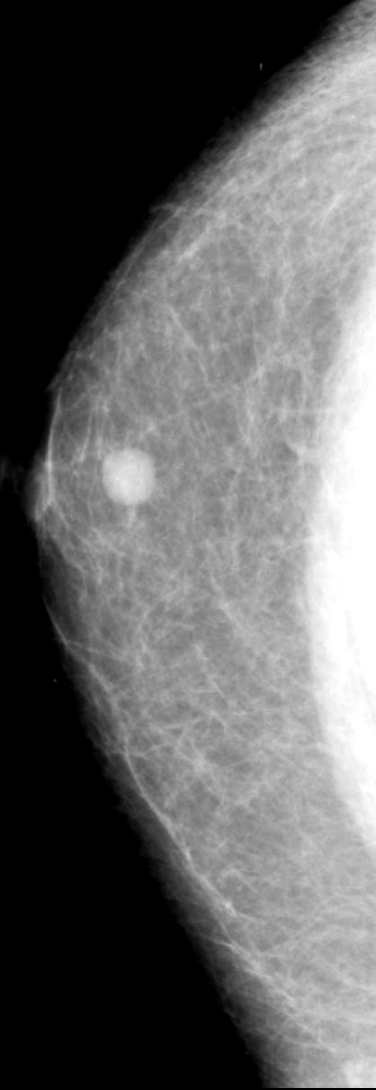


49 M with palpable left breast mass, with incidental right subareolar lesion:

Mammogram: 5 mm well circumscribed mass in the subareolar region.

Ultrasound: Hypoechoic 6 x 3 x 5 mm cyst at the site of mammographic mass, with thin internal septation, without internal flow.

Myofibroblastoma



64 M with incidental left breast mass on chest CT:

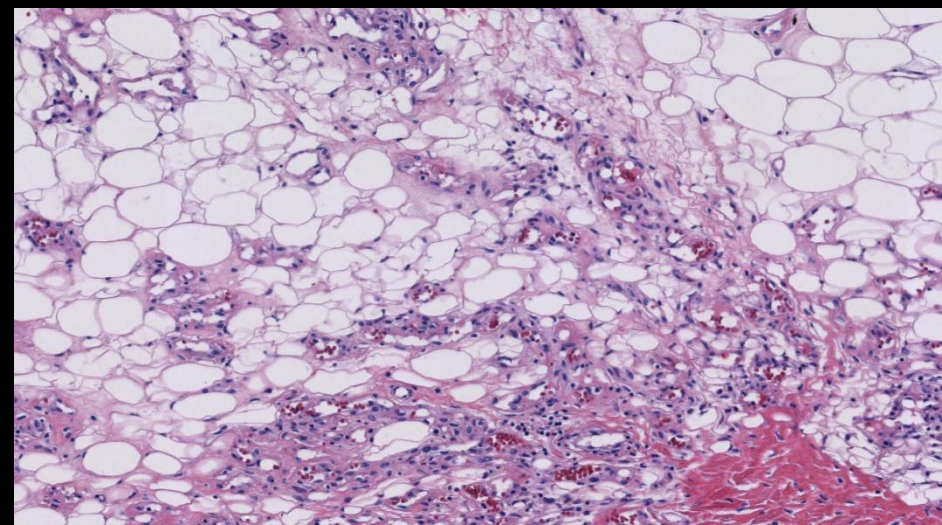
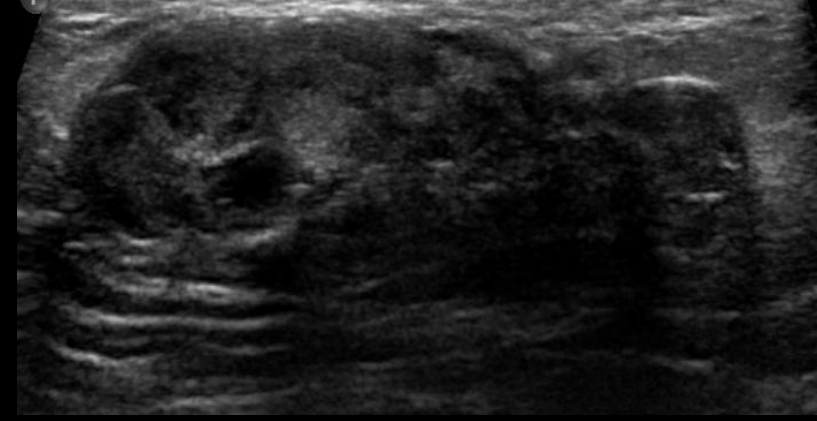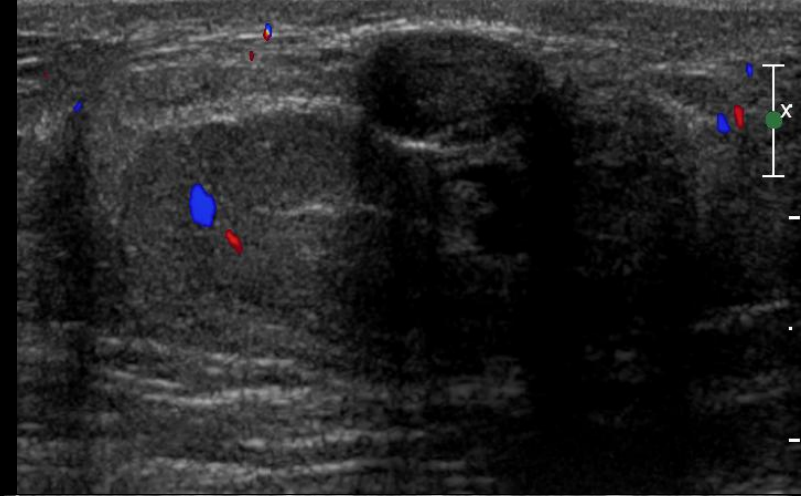
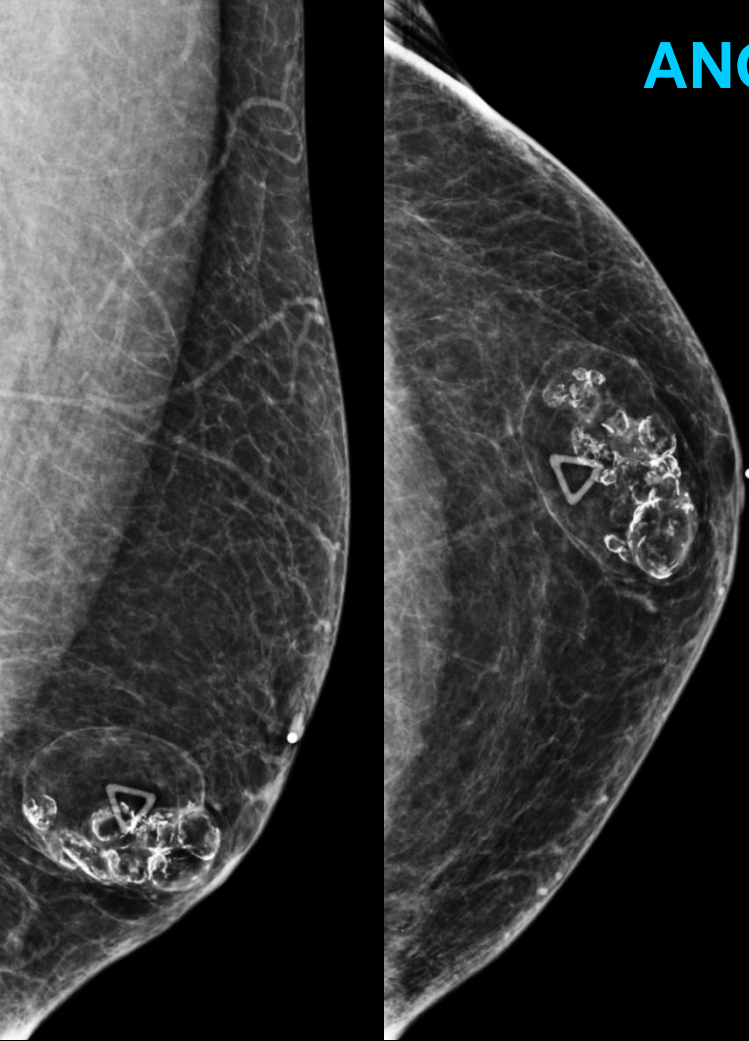
Mammogram: Circumscribed mass retroareolar left breast.

Ultrasound: Round hypoechoic circumscribed retroareolar mass.

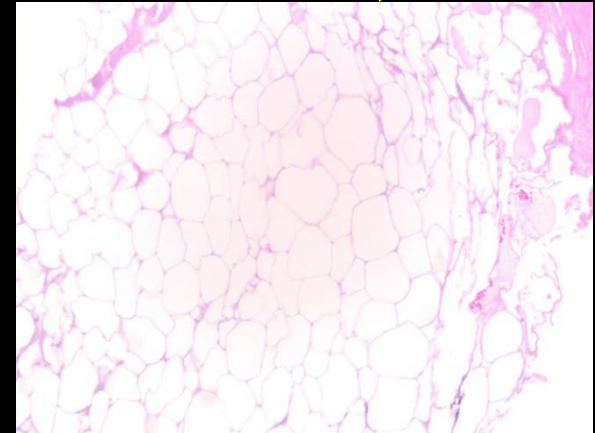
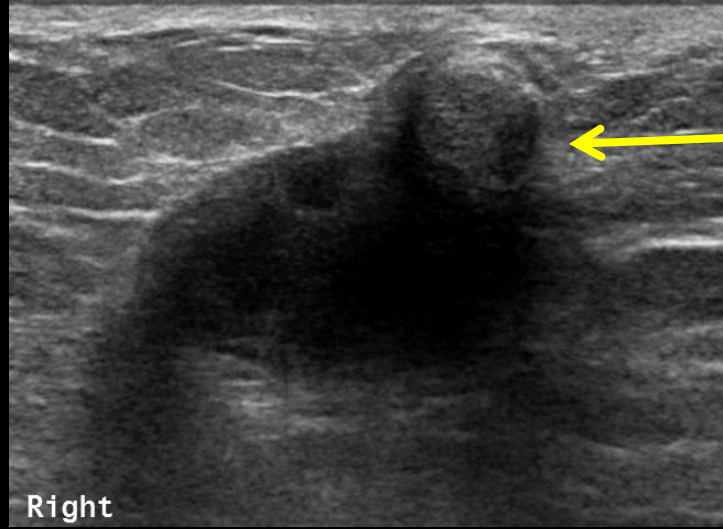
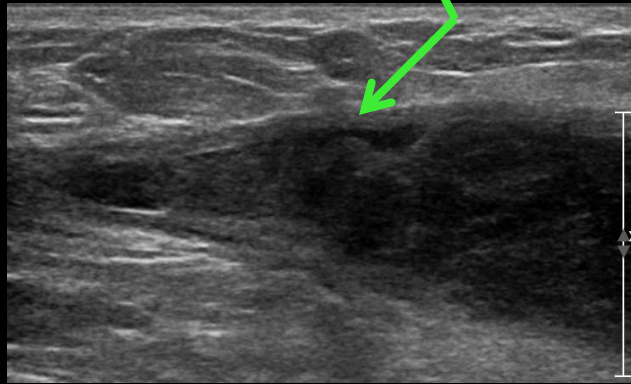
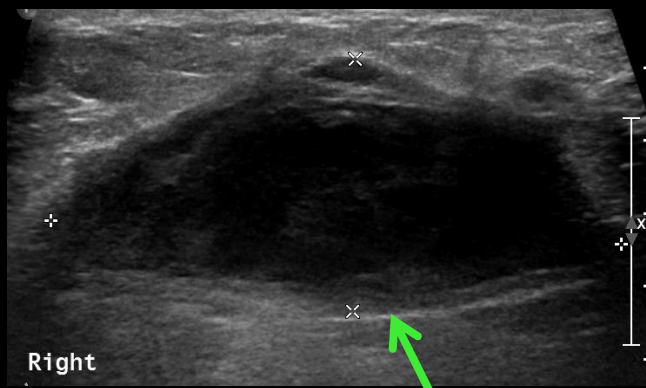CT: Rounded soft tissue density lesion in the left breast. ↑

Pathology: Well circumscribed neoplasm composed of haphazardly arranged spindle cells separated by bands of hyalinized collagen. Mast cells with a central round nucleus and basophilic granular cytoplasm are also prominent.

ANGIOLIPOMA



45 M with palpable left breast mass:
Mammogram: Circumscribed complex mass containing fat and numerous eggshell calcifications at the site of palpable lesion.
Ultrasound: Oval, heterogeneous, shadowing mass demonstrating internal vascularity.
Pathology: Classic features of angioliipoma with mature adipose tissue admixed with branching capillaries.



Fat Necrosis

51 M post right mastectomy for malignancy two years prior, with new palpable mass in the post surgical bed:

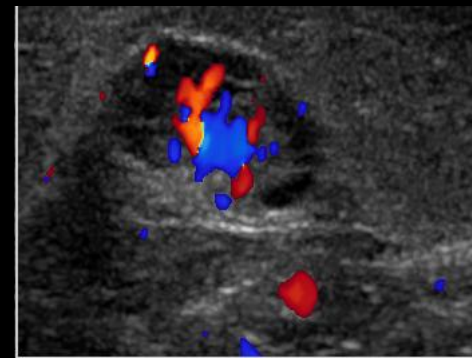
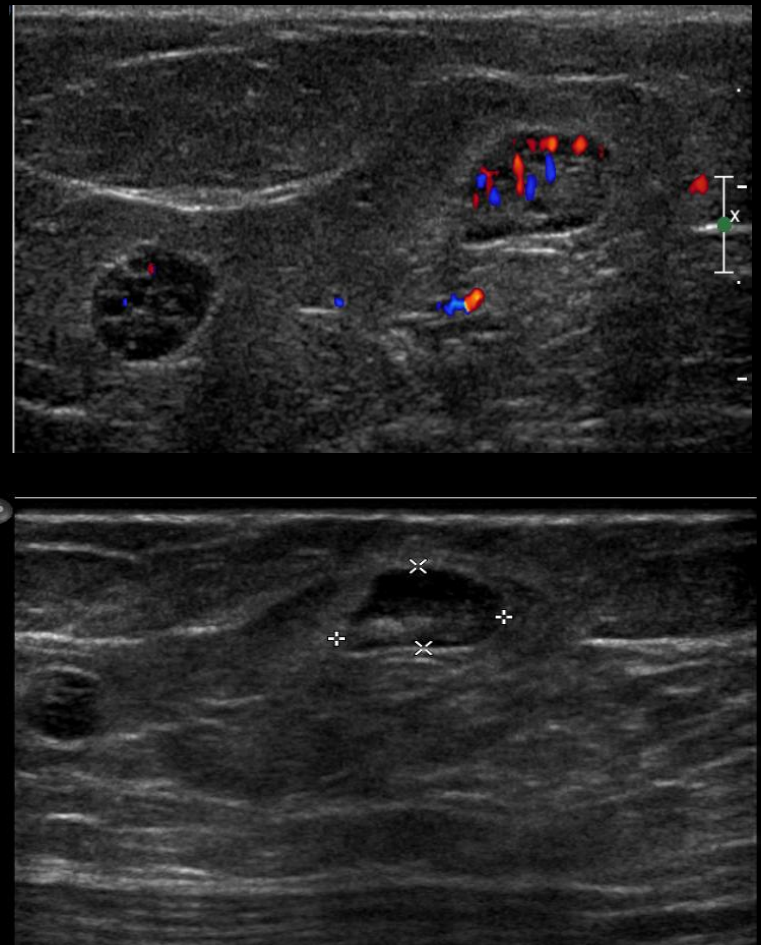
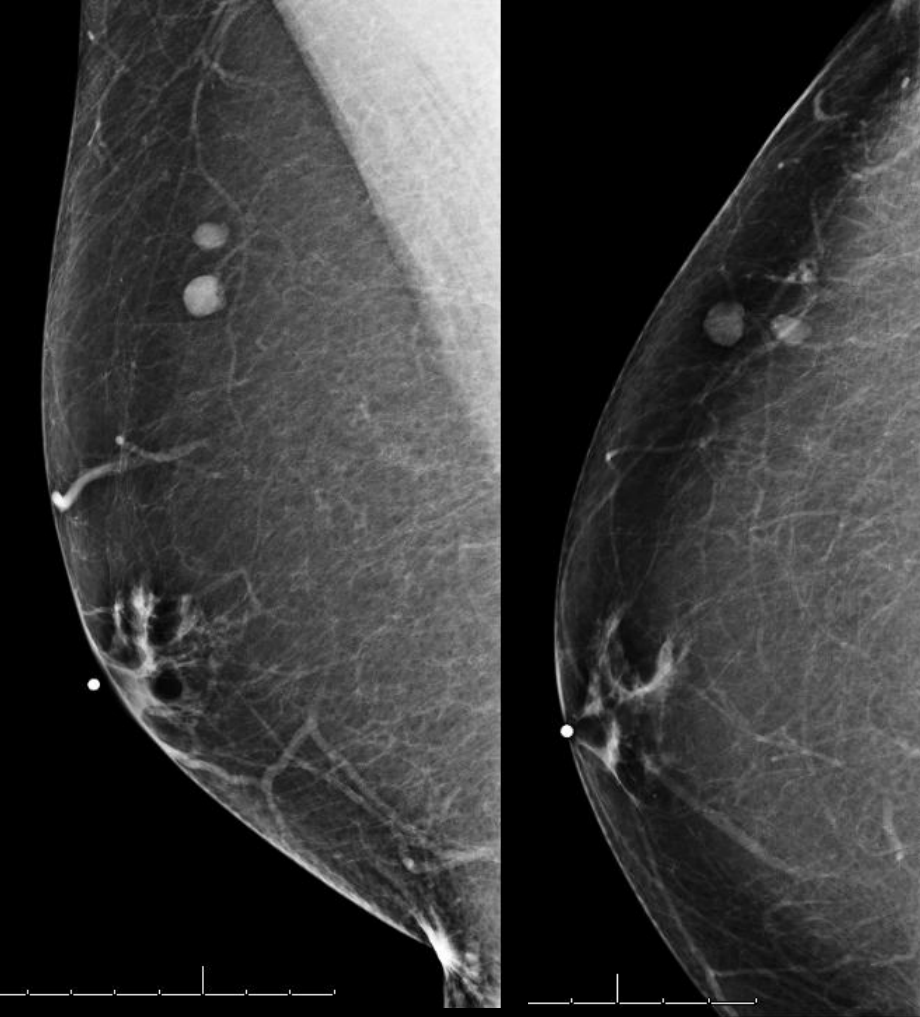
Ultrasound: Within the post surgical bed is a 38 x 17 mm complex fluid collection consistent with seroma. Along the lateral aspect of the seroma is wall thickening and echogenic internal debris. ↑

Additional round isoechoic mass measuring 9 x 7 mm anteriorly abutting the cavity wall. No internal flow. ↑

Pathology: Solid lesion fat necrosis- the architecture of the fat is preserved, nucleoli are uniformly absent in the individual adipocytes reflecting that cell death has occurred. ↑

Seroma- Fragments of fibrous tissue with fibrin deposits. ↑

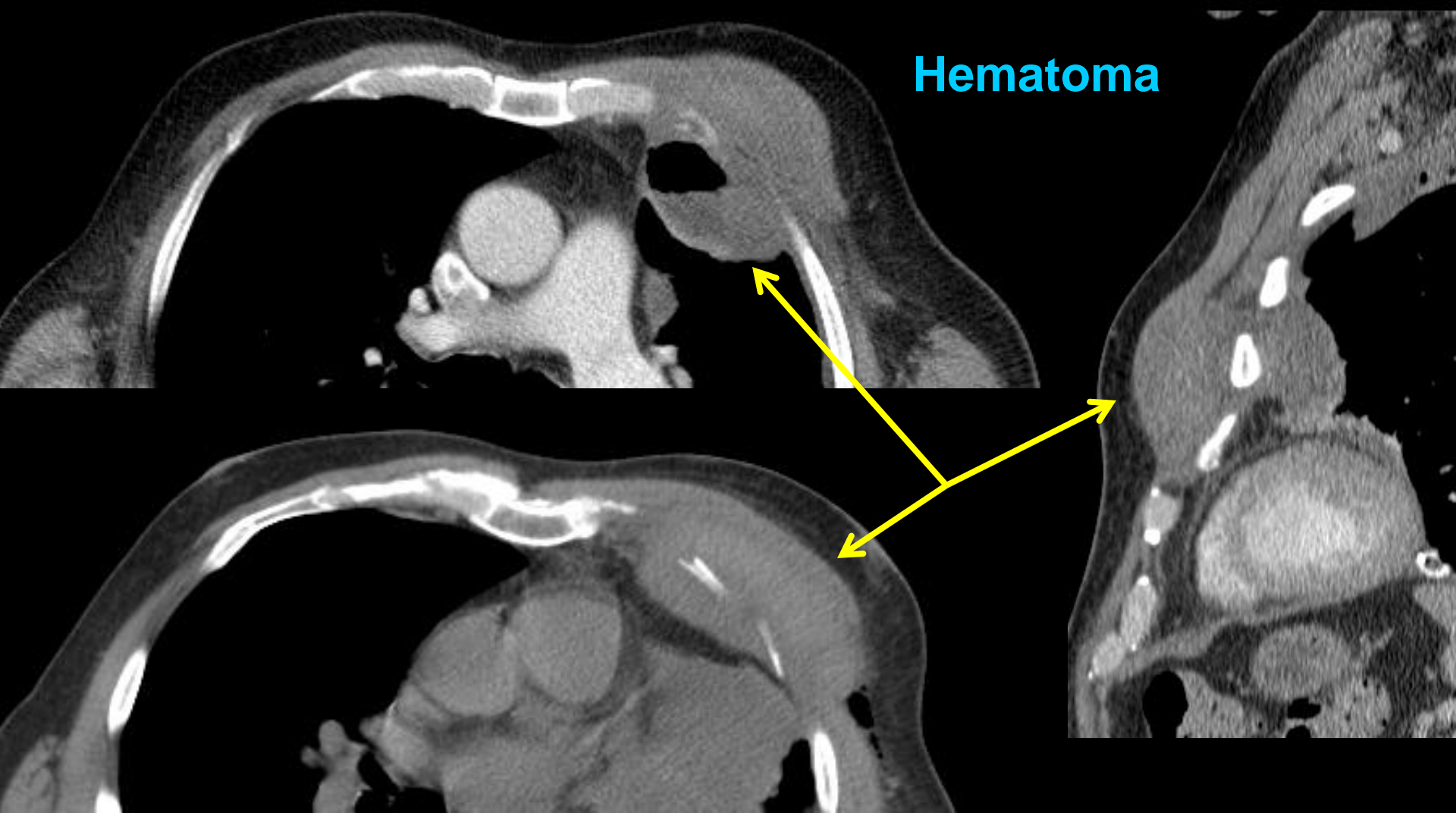
Intramammary Lymph Node



65 M with history of left breast cancer with two right breast intramammary lymph nodes:

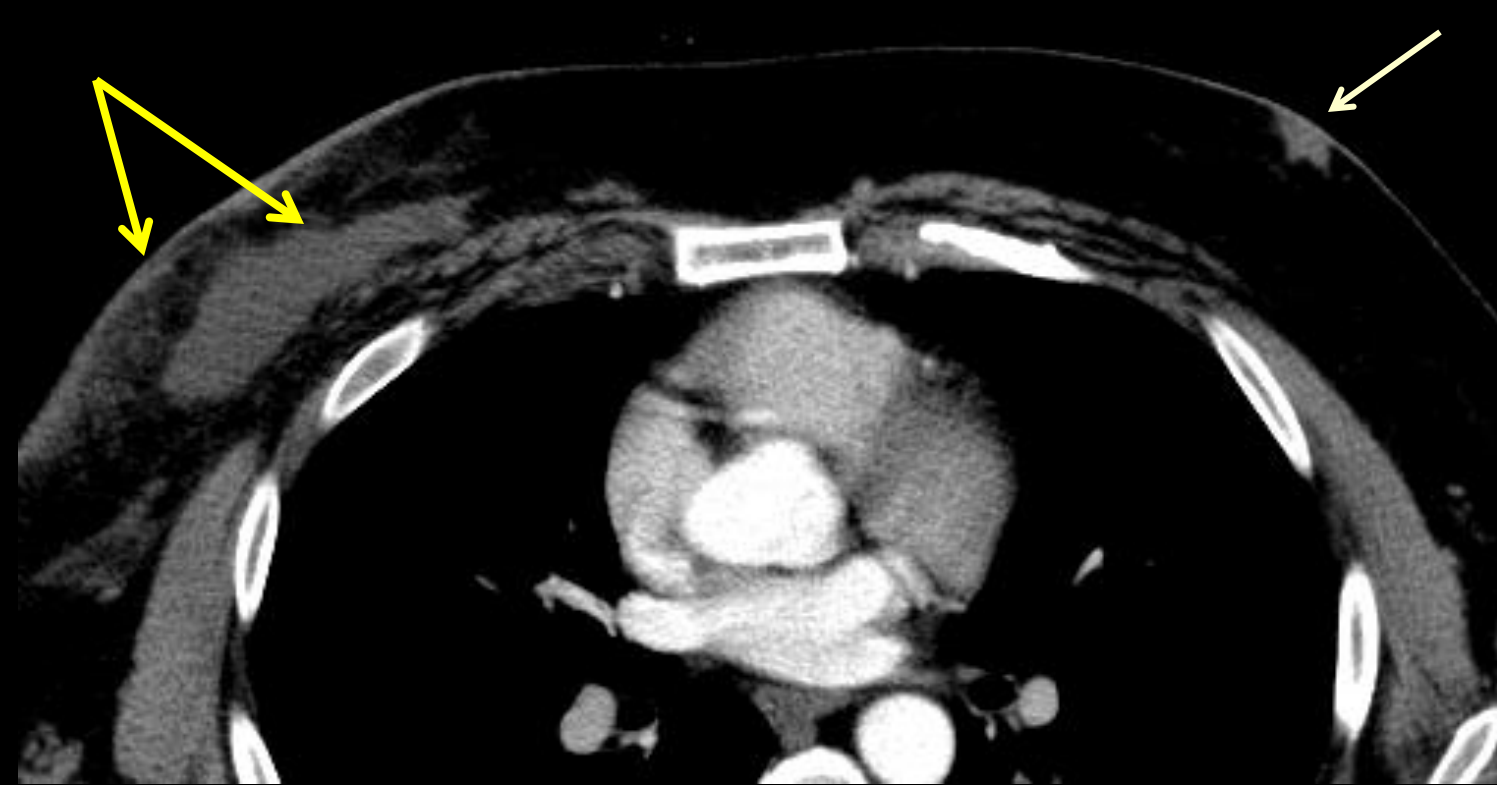Mammogram: Two well circumscribed round masses.

Ultrasound: Two lymph nodes with normal vascular fatty hilum, normal cortex and size.



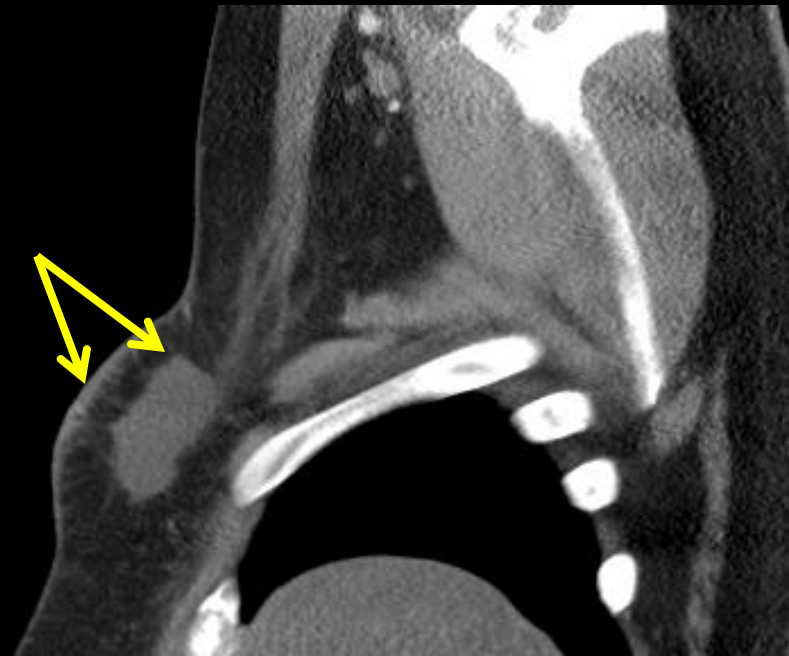
58 M post fall down stairs:

CT: Left retropectoral hematoma with underlying left anterior rib fractures as well as hemopneumothorax and hemomediastinum.

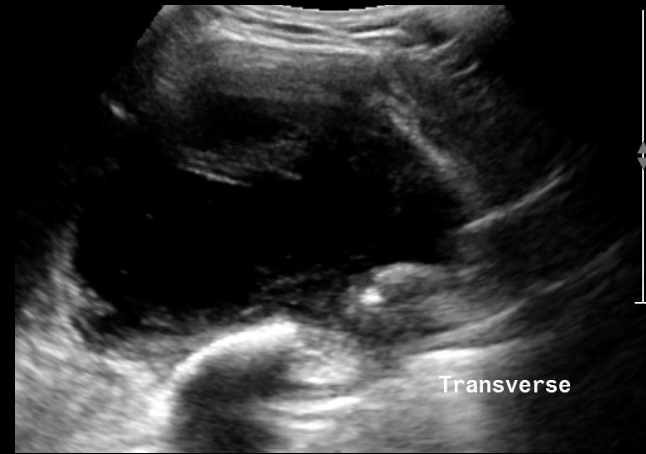
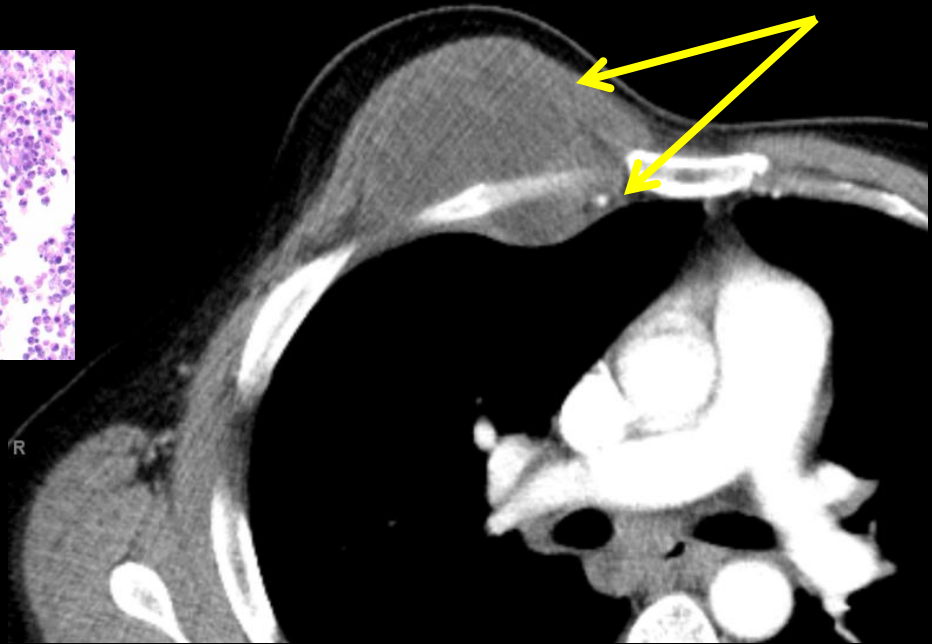
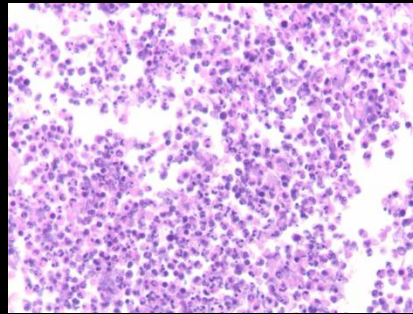
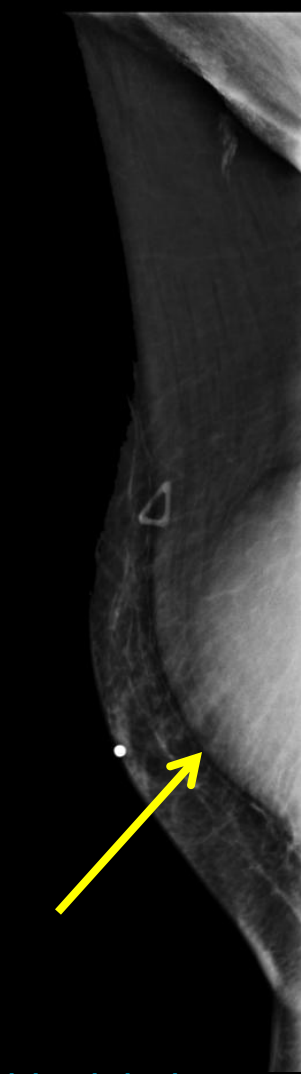
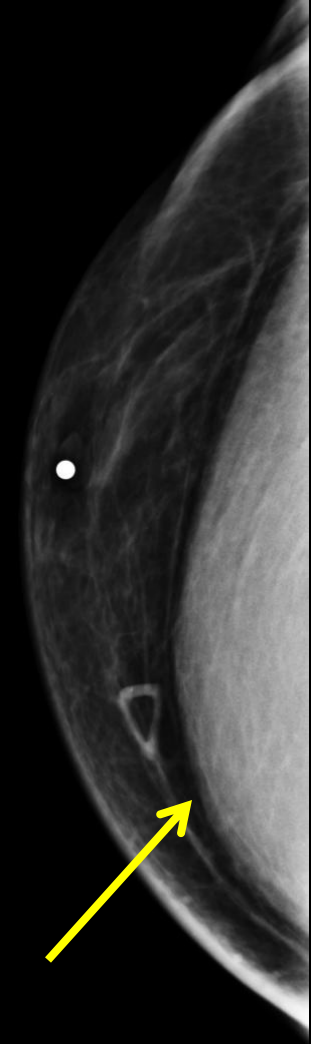


Seroma

49 M with post right mastectomy for cancer:
CT: Skin thickening and fluid density within the right post
mastectomy bed consistent with post operative seroma. ↑
Incidental note of left gynecomastia. ↑



RETROPECTORAL ABSCESS



46 M with palpable right breast mass:

Mammogram: Round retropectoral mass. ↑

CT: Heterogeneous cystic mass extending through the chest wall.

Ultrasound: Complex cystic mass with thick internal septations and debris.

Pathology: Neutrophils in various stages of activation and apoptosis reflecting an acute inflammatory process. Final culture positive for *Mycobacterium tuberculosis*.

Male Breast Cancer

- Common presentation:
 - Painless palpable mass retroareolar region or UOQ
 - Nipple retraction, bloody nipple discharge, skin thickening, palpable axillary lymph nodes
- 80% are Invasive Ductal Cancer
- 5% are DCIS
- 5% are Papillary Carcinoma
 - Most are intracystic, therefore when dealing with male breast cysts consider Papillary Cancer

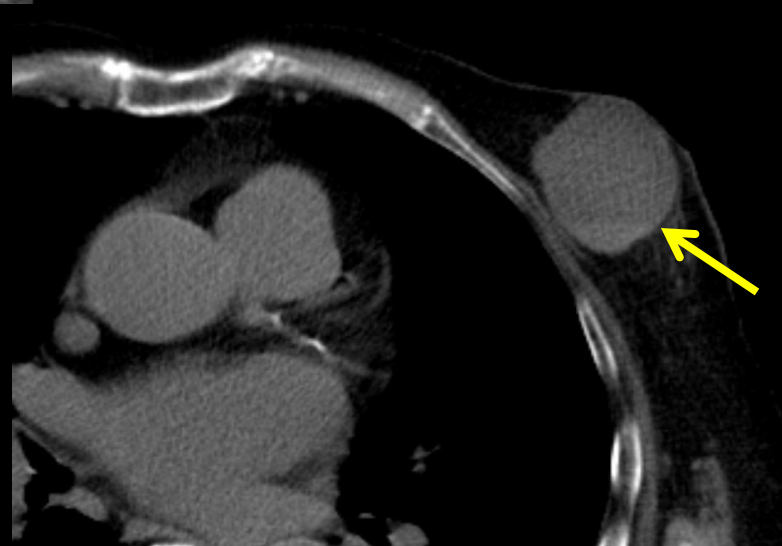
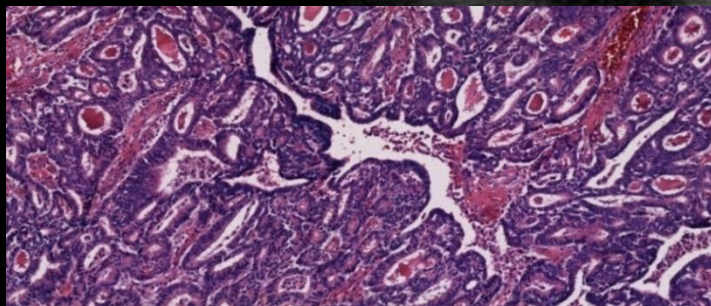
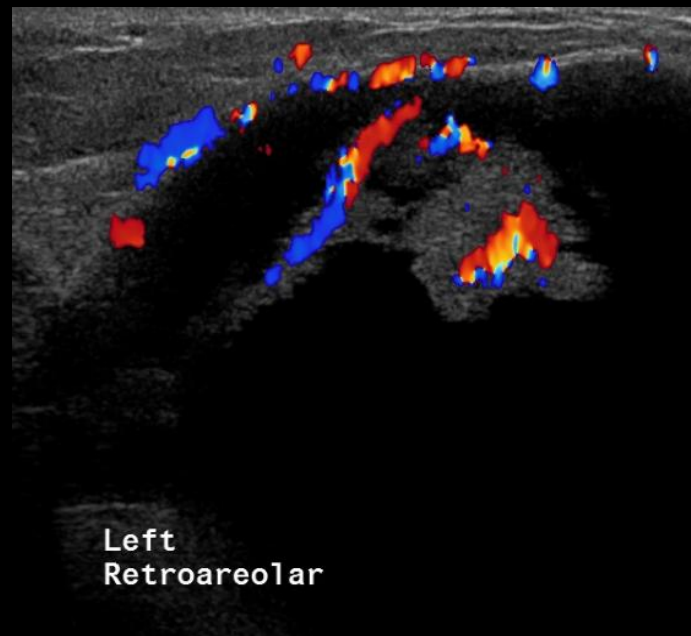
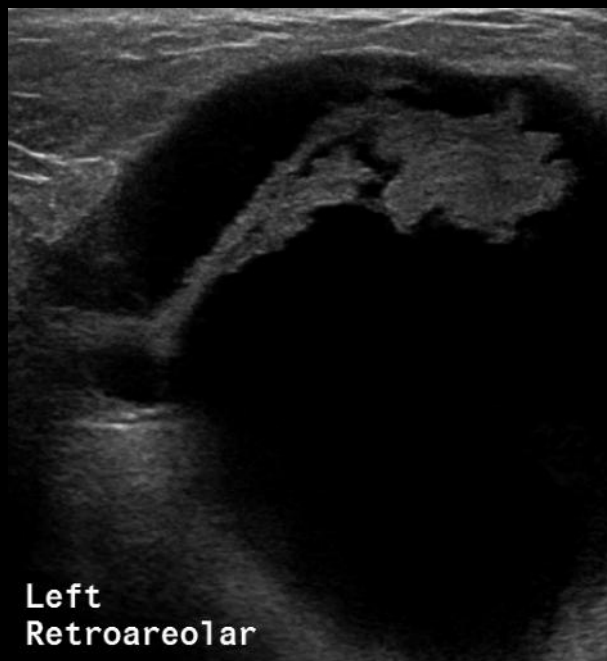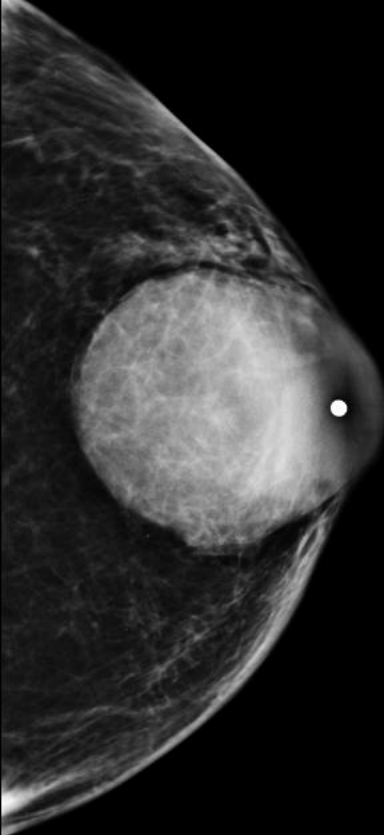
Risk Factors

- Prolonged elevation of the estrogen/androgen ratio
- BRCA carrier status, found in 4-16%
- Positive family history

Male Breast Cancer

- More often subareolar, eccentric to the nipple
- Larger percentage of invasive papillary and intracystic cancers in men than in women
- Men have lower incidence of benign circumscribed lesions of lobular origin, such as cysts and fibroadenomas, therefore all circumscribed lesions must be rigorously imaged to confirm or exclude an intracystic neoplasm

INTRACYSTIC PAPILLARY CANCER



88 M with palpable left breast mass:

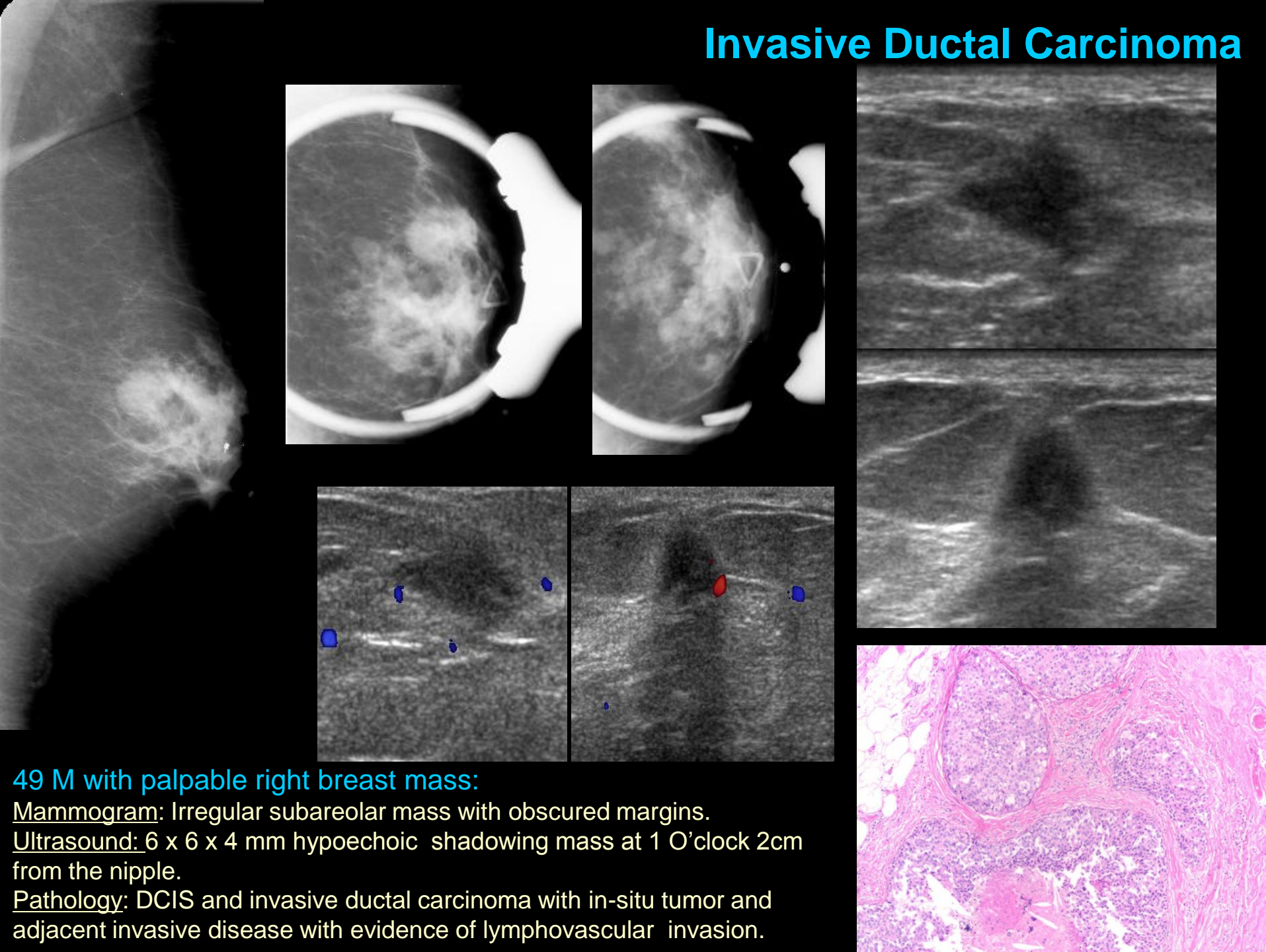
Mammogram: Large subareolar well circumscribed mass.

Ultrasound: 39 x 45 x 39 mm complex cyst with associated mural vascular polypoid mass and septation.

CT: Left subareolar soft tissue and fluid density breast mass with a layering fluid level. ↑

Pathology: Cribriform papillary arrangement of intermediate grade cells.

Invasive Ductal Carcinoma



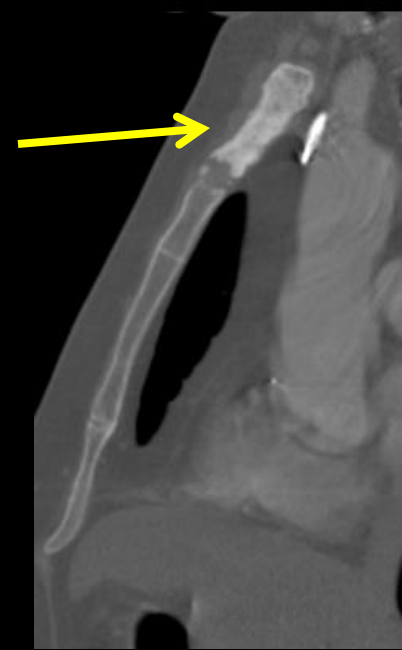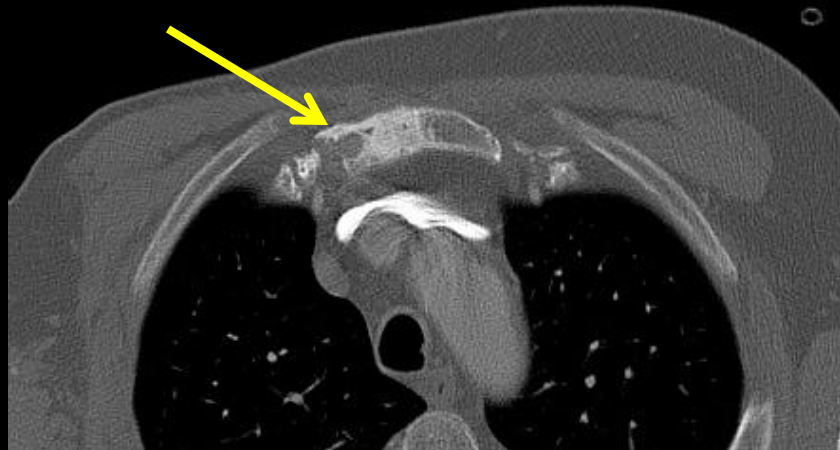
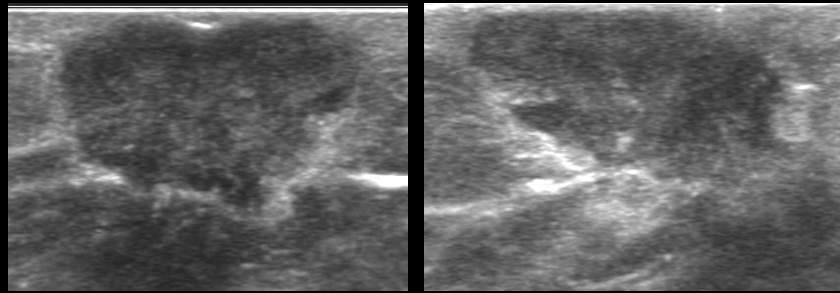
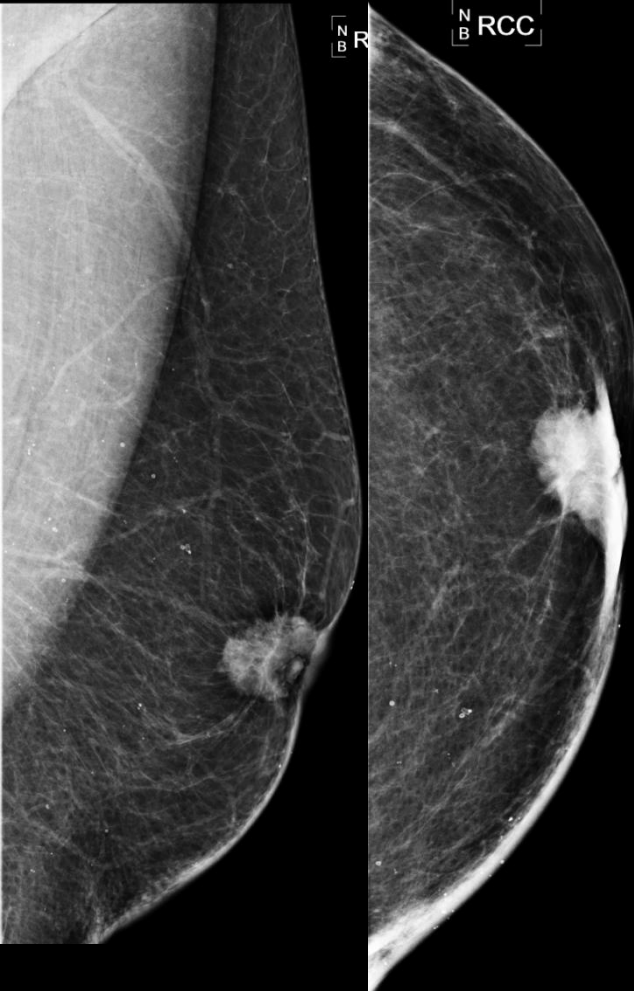49 M with palpable right breast mass:

Mammogram: Irregular subareolar mass with obscured margins.

Ultrasound: 6 x 6 x 4 mm hypoechoic shadowing mass at 1 O'clock 2cm from the nipple.

Pathology: DCIS and invasive ductal carcinoma with in-situ tumor and adjacent invasive disease with evidence of lymphovascular invasion.

Invasive Ductal Carcinoma



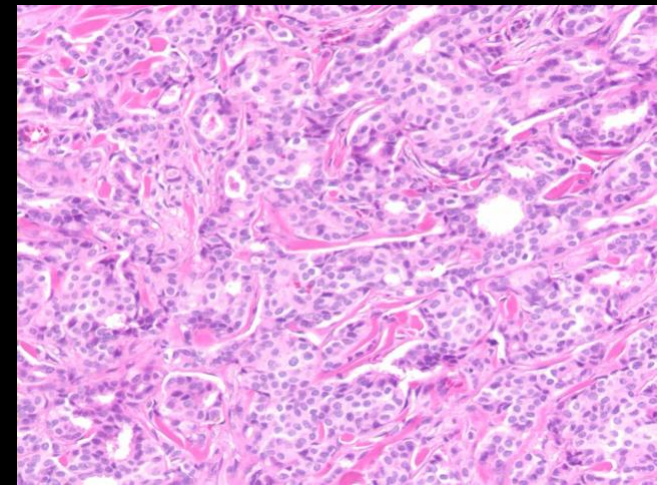
57 M with palpable right breast mass and skin retraction:

Mammogram: Irregular retroareolar mass spiculated margin and associated skin retraction.

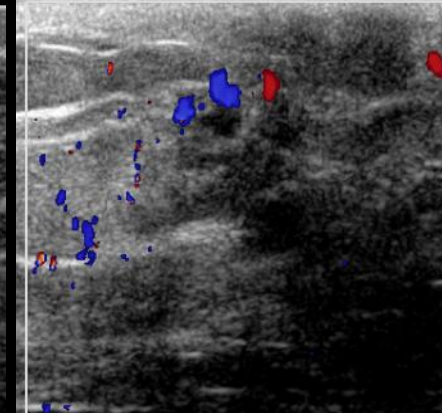
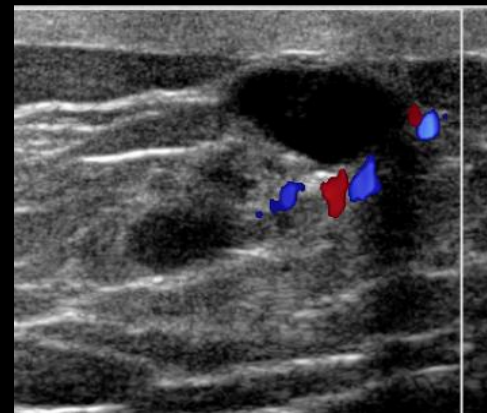
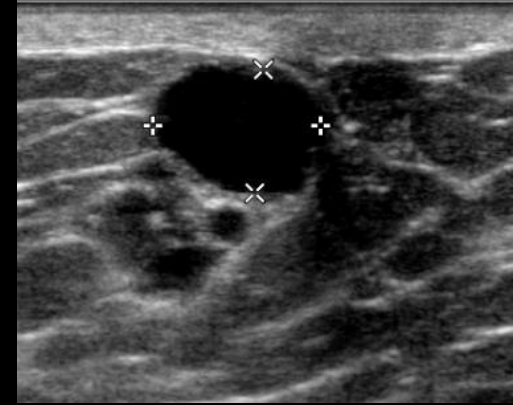
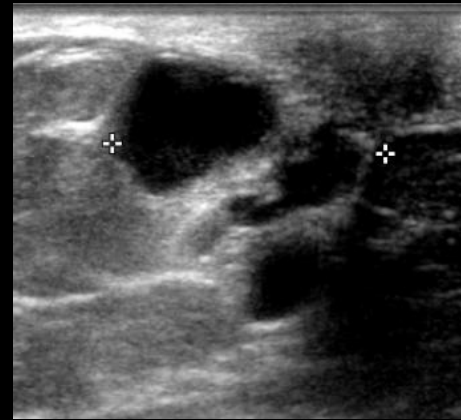
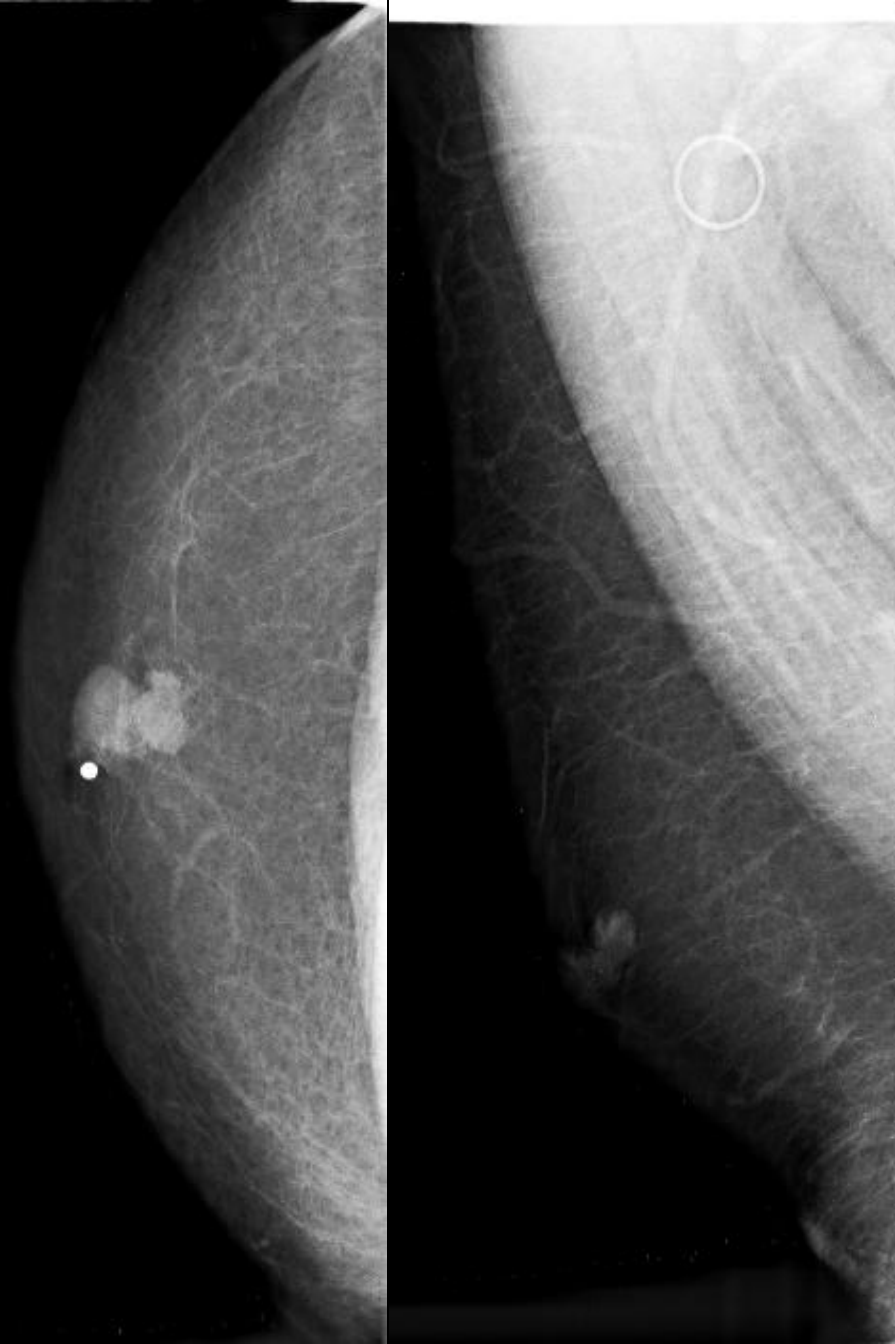Ultrasound: 2.3 x 2 x 1.1 cm irregular hypoechoic mass at 12 o'clock 1cm from nipple with microlobulated margin.

CT: Lytic and sclerotic destructive metastatic lesion within the manubrium. ↑

Pathology: Architecture of well developed tubules, bland nuclei and rare mitoses, making this a well differentiated invasive ductal carcinoma.



Invasive Ductal Carcinoma



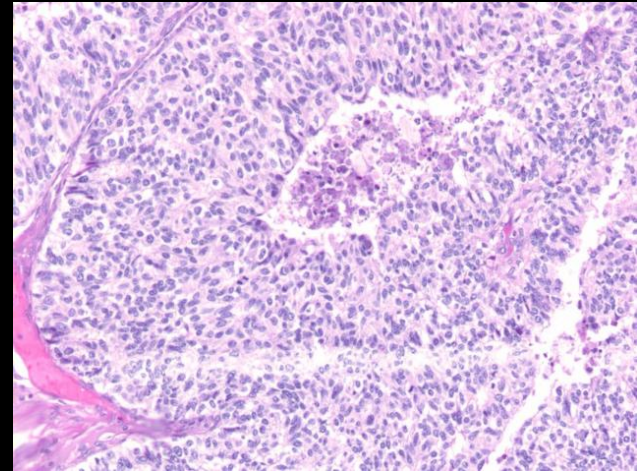
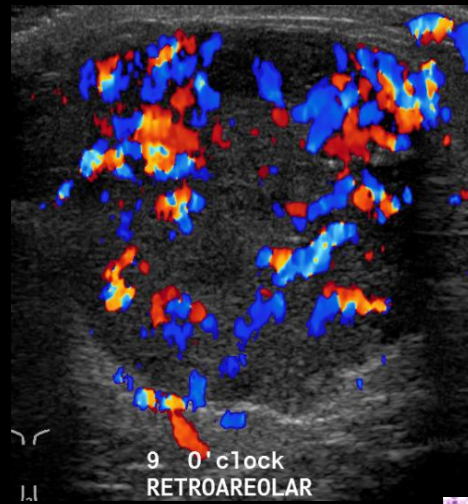
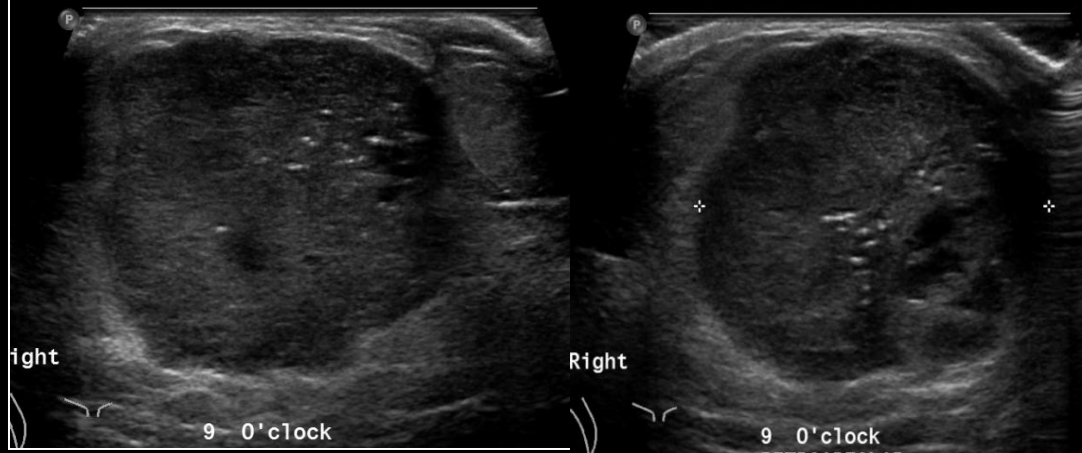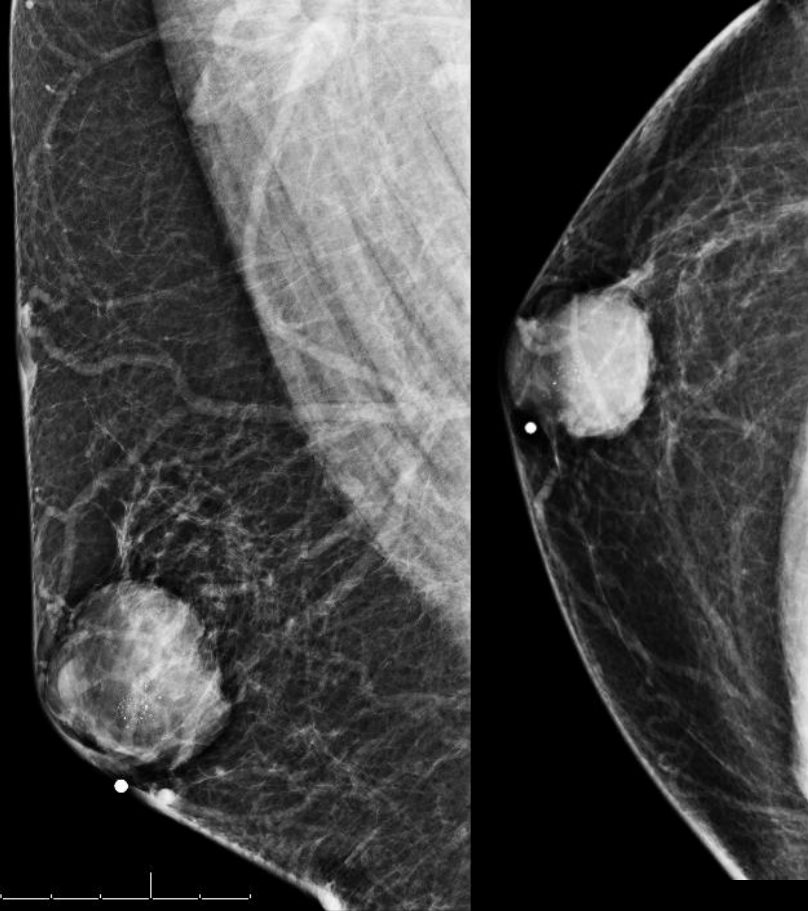
39 M with right palpable mass:

Mammogram: Round retroareolar masses with circumscribed margins and associated amorphous calcifications.

Ultrasound: 9 O'clock retroareolar anechoic cysts with thick internal septations and associated vascularity.

Pathology: Core showed focal papillary hyperplastic cells.

Resection advised. Patient was lost to follow up.

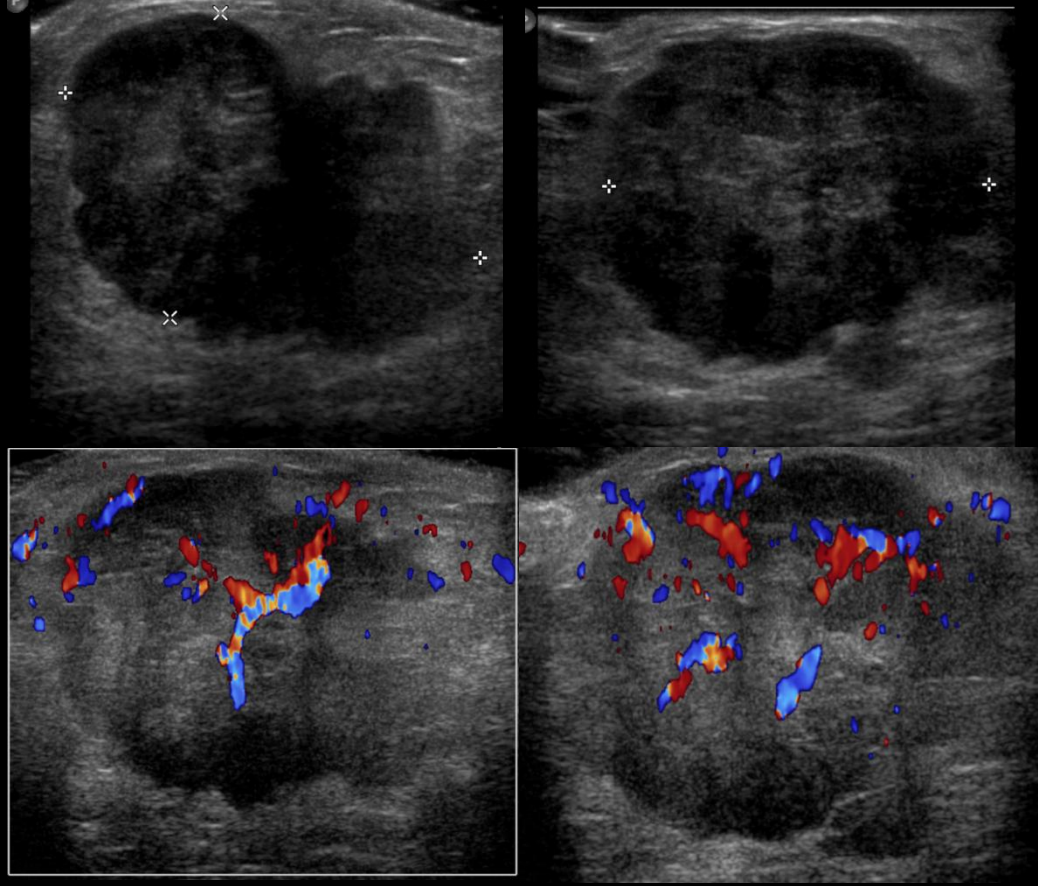
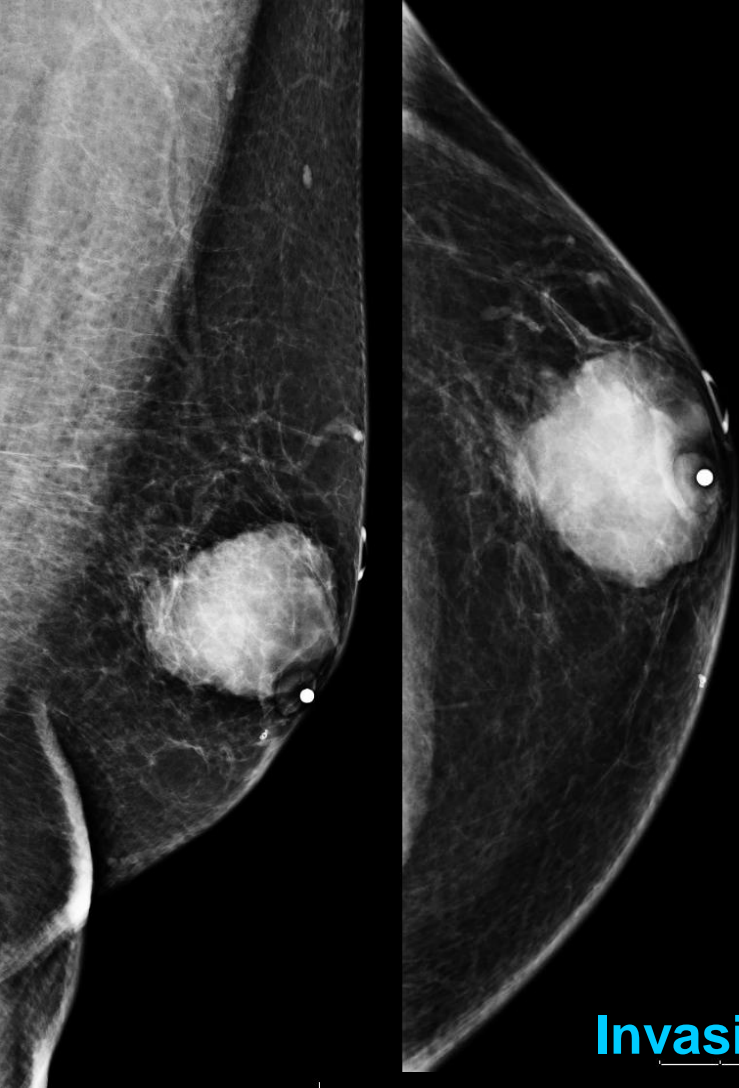


Patient returns 4 years later with Palpable Mass

Mammogram: Interval increase in size of round retroareolar mass with circumscribed margins and associated amorphous calcifications.

Ultrasound: 9 O'clock retroareolar solid mass with associated vascularity.

Pathology: Tumor cells appear to be confined within well circumscribed groups. Immunohistochemical stains for myoepithelial cells show it is invasive ductal carcinoma.



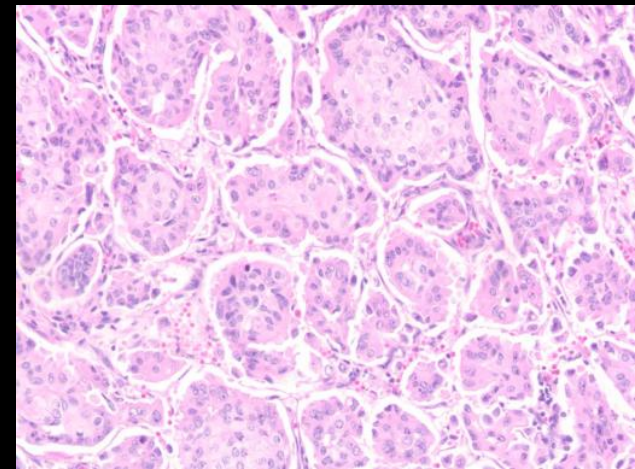
Invasive Ductal Carcinoma

77 M Palpable Left Breast Mass:

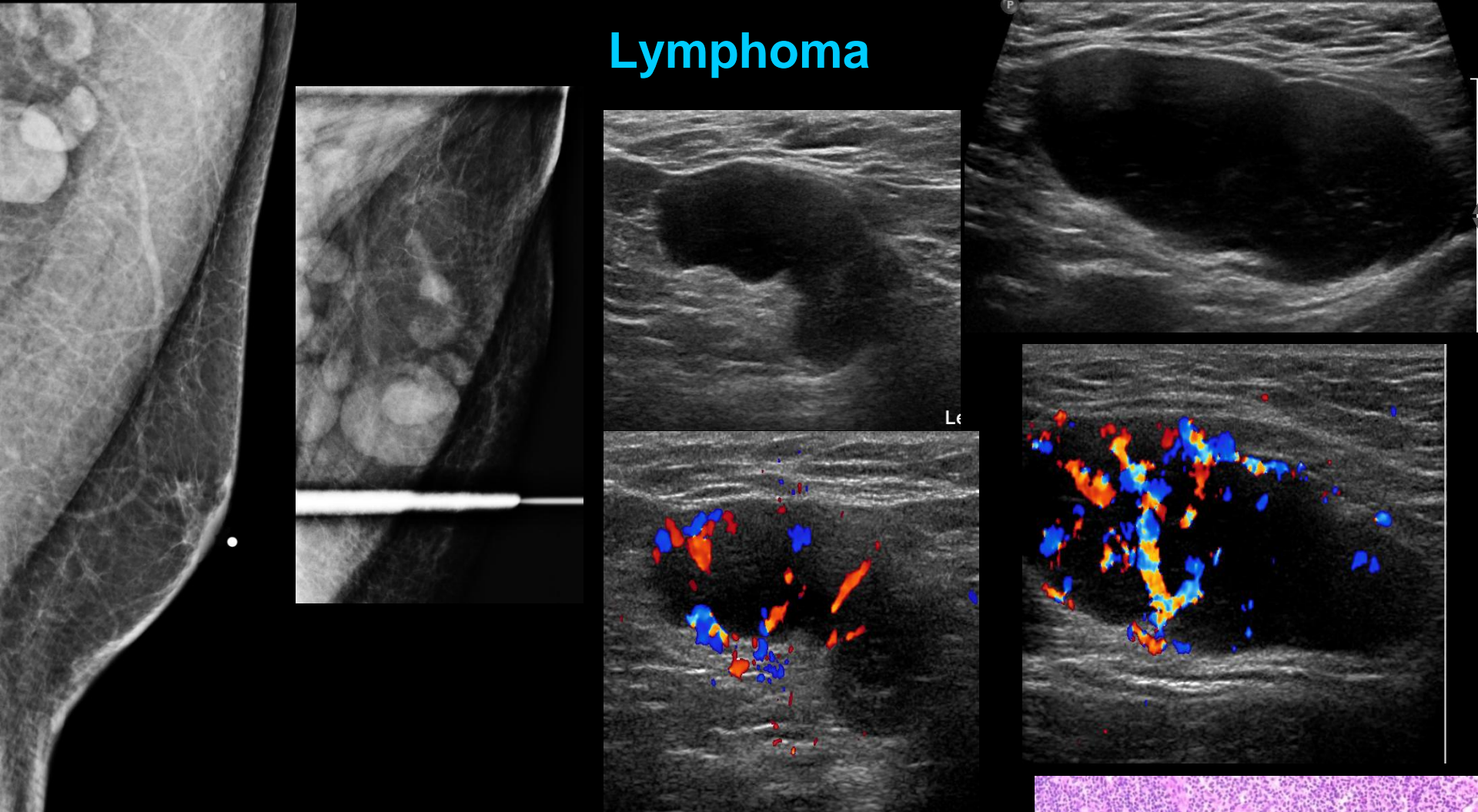
Mammogram: Circumscribed eccentric retroareolar mass.

Ultrasound: Solid hypoechoic irregular mass with microlobulated margin and internal vascularity.

Pathology: Invasive pattern of poorly differentiated ductal carcinoma infiltrating into adjacent adipose tissue with little duct formation and marked nuclear pleomorphism as well as increased mitotic activity.



Lymphoma

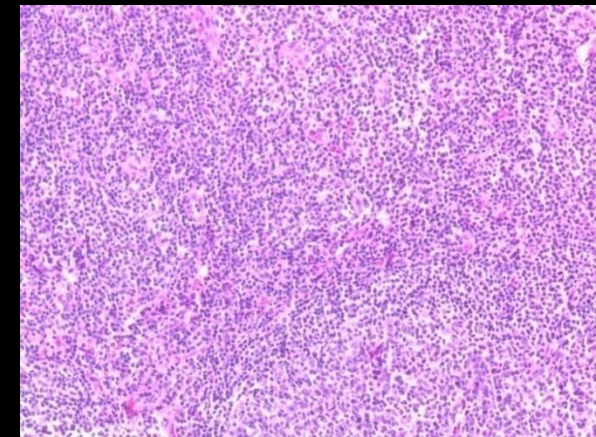


65 M with palpable right breast lump and prominent left axillary lymph nodes.

Mammogram: Left axillary lymphadenopathy

Ultrasound: Multiple enlarged lymph nodes with thickened cortex (12mm), displacement of central hilum and abnormal increased cortical vascular flow.

Pathology: Lymphocytes with larger atypical lobulated cells in a rosette pattern typical for Nodular Lymphocyte Predominate Hodgkins Lymphoma.



Summary

Distinguishing gynecomastia from cancer is an important part of the workup in a male breast lesion

Gynecomastia:

Usually presents as a soft, mobile, tender, subareolar mass

Lateral and deep margins can be indistinct or blend into surrounding fat

Majority are bilateral but often asymmetric

Male Breast Cancer:

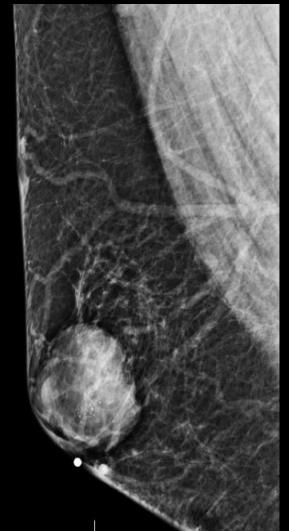
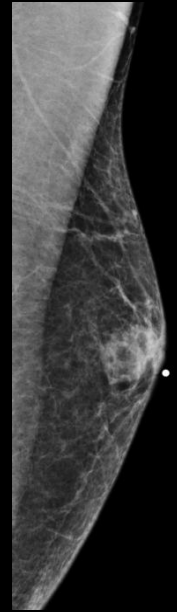
Often subareolar but eccentric to the nipple

Can often be well circumscribed

Cysts in men should be aggressively imaged due to high incidence of papillary and intracystic cancers

Lobular absence in men explains the rarity of

- Cyst formation
- Fibroadenomas
- Lobular cancer
- Phyllodes tumors



References:

- Kopans DB. Breast imaging. Philadelphia, Pa: Lippincott Williams & Wilkins, 2006.
- Iuanow E, Kettler M, Slanetz PJ. Spectrum of disease in the male breast. *AJR Am J Roentgenology* 2011; 196 (3): W247-W259.
- Chen L, Chantra PK, Larsen LH, et al. Imaging characteristics of malignant lesions of the male breast, *RadioGraphics* 2006; 26 (4):993-1006.
- Appelbaum AH, Evans GF, Levy KR, Amirkhan RH, Schumpert TD. Mammographic appearances of male breast disease. *RadioGraphics* 1999;19(3): 559–568.
- Braunstein GD. Clinical practice: gynecomastia. *N Engl J Med* 2007;357(12):1229–1237.
- Nguyen C, Kettler M.D, Swirsky M, Miller V.I, Scott C, Krause R, Hadro J.A. **Male Breast Disease: Pictorial Review with Radiologic-Pathologic Correlation. *RadioGraphics* 2013; 33:763–779.**
- Giordano SH. A review of the diagnosis and management of male breast cancer. *Oncologist* 2005;10(7):471–479.
- Jemal A, Siegel R, Xu J, Ward E. Cancer statistics, 2010. *CA Cancer J Clin* 2010;60(5):277–300.
- Weiss JR, Moysich KB, Swede H. Epidemiology of male breast cancer. *Cancer Epidemiol Biomarkers Prev* 2005;14(1):20–26.
- Mathew J, Perkins GH, Stephens T, Middleton LP, Yang WT. Primary breast cancer in men: clinical, imaging, and pathologic findings in 57 patients. *AJR Am J Roentgenol* 2008;191(6):1631–1639.
- Weinstein SP, Conant EF, Acs G. Case 59: angiolipoma of the breast. *Radiology* 2003;227(3): 773–775.
- Günhan-Bilgen I, Memiş A, Ustün EE. Metastatic intramammary lymph nodes: mammographic and ultrasonographic features. *Eur J Radiol* 2001;40(1): 24–29.
- Cho N, Moon WK, Han W, Park IA, Cho J, Noh DY. Preoperative sonographic classification of axillary lymph nodes in patients with breast cancer: node-to-node correlation with surgical histology and sentinel node biopsy results. *AJR Am J Roentgenol* 2009;193(6):1731–1737.
- Versluijs-Ossewaarde FN, Roumen RM, Goris RJ. Subareolar breast abscesses: characteristics and results of surgical treatment. *Breast J* 2005;11(3): 179–182.
- Chung EM, Cube R, Hall GJ, González C, Stocker JT, Glassman LM. Breast masses in children and adolescents: radiologic-pathologic correlation. *RadioGraphics* 2009;29(3):907–931.
- Johnson RE, Murad MH. Gynecomastia: pathophysiology, evaluation and management. *Mayo Clin Proc* 2009; 84:1010-1015.