



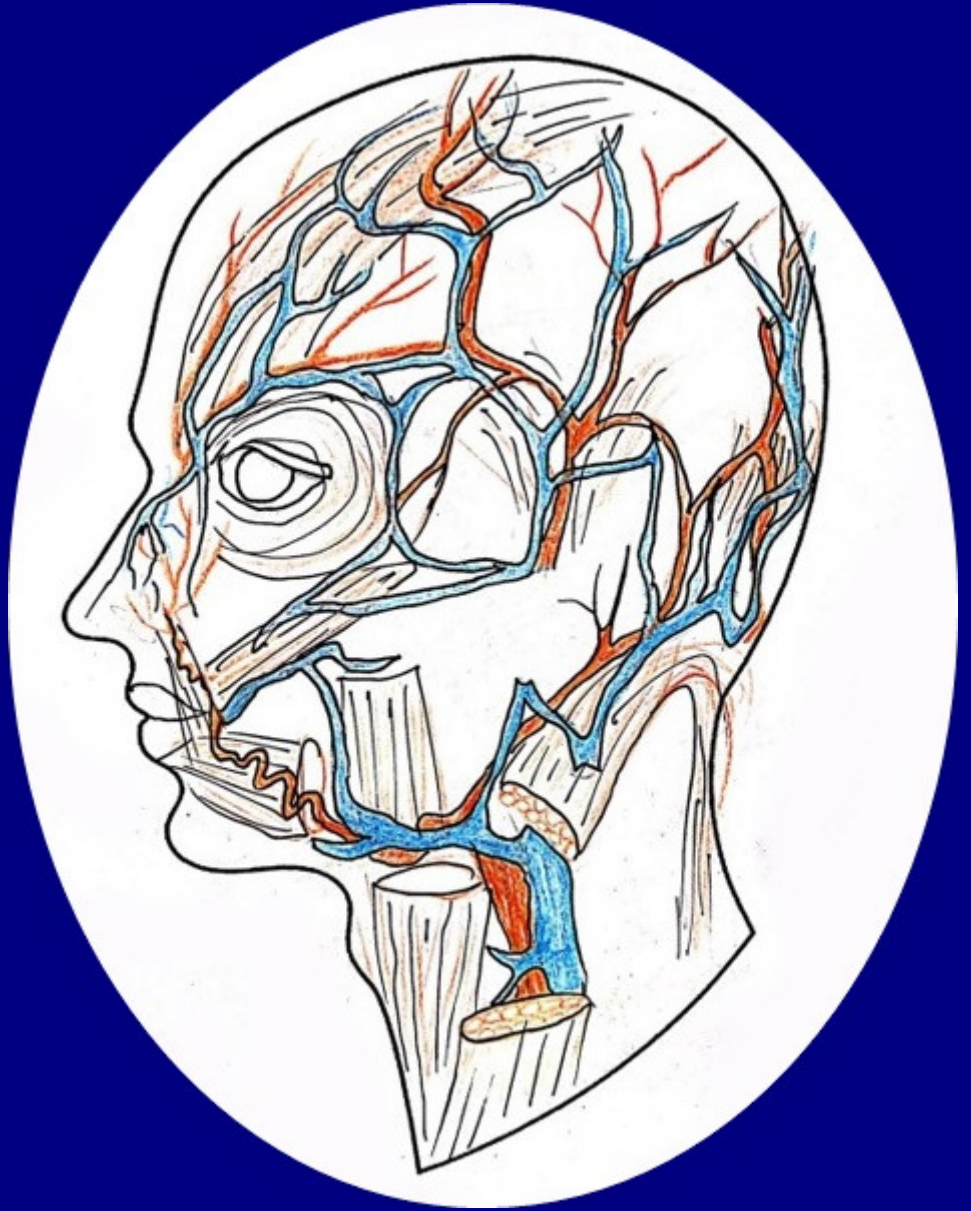
UNIVERSITATEA  
DE MEDICINĂ ȘI FARMACIE  
VICTOR BABEȘ | TIMIȘOARA

**Faur Alexandra**

**Bolintineanu Sorin**

**Țaga Roxana**

**Bîna Paul**



**Head and neck. Embryology. Topographic regions**

**Editura „Victor Babeș”**

**Timișoara, 2021**

Authors:

**Faur Alexandra**

Associate Professor, MD, PhD

**Bolintineanu Sorin**

Professor, MD, PhD

**Țaga Roxana**

Assistant Professor, MD, PhD Student

**Bîna Paul**

Assistant Professor, MD, PhD Student

**Acknowledgements:** The graphic illustration was made by Boldă Bogdan Emil  
(Liceul de Arte Plastice Timișoara)

**Editura „Victor Babeș”**

**Piața Eftimie Murgu 2, cam. 316, 300041 Timișoara**

**Tel./ Fax 0256 495 210**

**e-mail: [evb@umft.ro](mailto:evb@umft.ro)**

**[www.umft.ro/editura](http://www.umft.ro/editura)**

**Director general: Prof. univ. emerit dr. Dan V. Poenaru**

**Colecția: MANUALE**

**Coordonator colecție: Prof. univ. dr. Sorin Eugen Boia**

**Rerefent științific: Prof. univ. dr. Daliborca Vlad**

**ISBN 978-606-786-246-1**

**© 2021 Toate drepturile asupra acestei ediții sunt rezervate.**

**Reproducerea parțială sau integrală a textului, pe orice suport, fără acordul scris al autorilor este interzisă și se va sancționa conform legilor în vigoare.**

# CONTENT

<b>Chapter I. Head and neck embryology .....</b>	<b>5</b>
1. HEAD AND NECK EMBRYOLOGY ( <i>Faur A.</i> ) .....	5
2. References Chapter I.....	14
<b>Chapter II. Head and Neck - Topographic Regions .....</b>	<b>15</b>
1. FRONTO-PARIETO-OCCIPITAL REGION ( <i>Bolintineanu S.</i> ).....	16
2. TEMPORAL REGION ( <i>Faur A.</i> ).....	20
3. ZYGOMATIC REGION ( <i>Țaga R.</i> ) .....	24
4. INFRAORBITAL REGION ( <i>Țaga R.</i> ).....	25
5. BUCCAL REGION ( <i>Țaga R., Faur A.</i> ).....	28
6. MENTAL REGION ( <i>Țaga R., Faur A.</i> ) .....	32
7. NASAL REGION ( <i>Bîna P.</i> ).....	35
8. THE PAROTID REGION ( <i>Bîna P., Faur A.</i> ).....	42
9. THE PALPEBRAL REGION ( <i>Bîna P.</i> ) .....	47
10. THE LABIAL REGION ( <i>Bîna P.</i> ) .....	51
11. THE MASTOID REGION ( <i>Bîna P.</i> ).....	55
12. References Chapter II.....	56

# Chapter I.

## Head and neck embryology

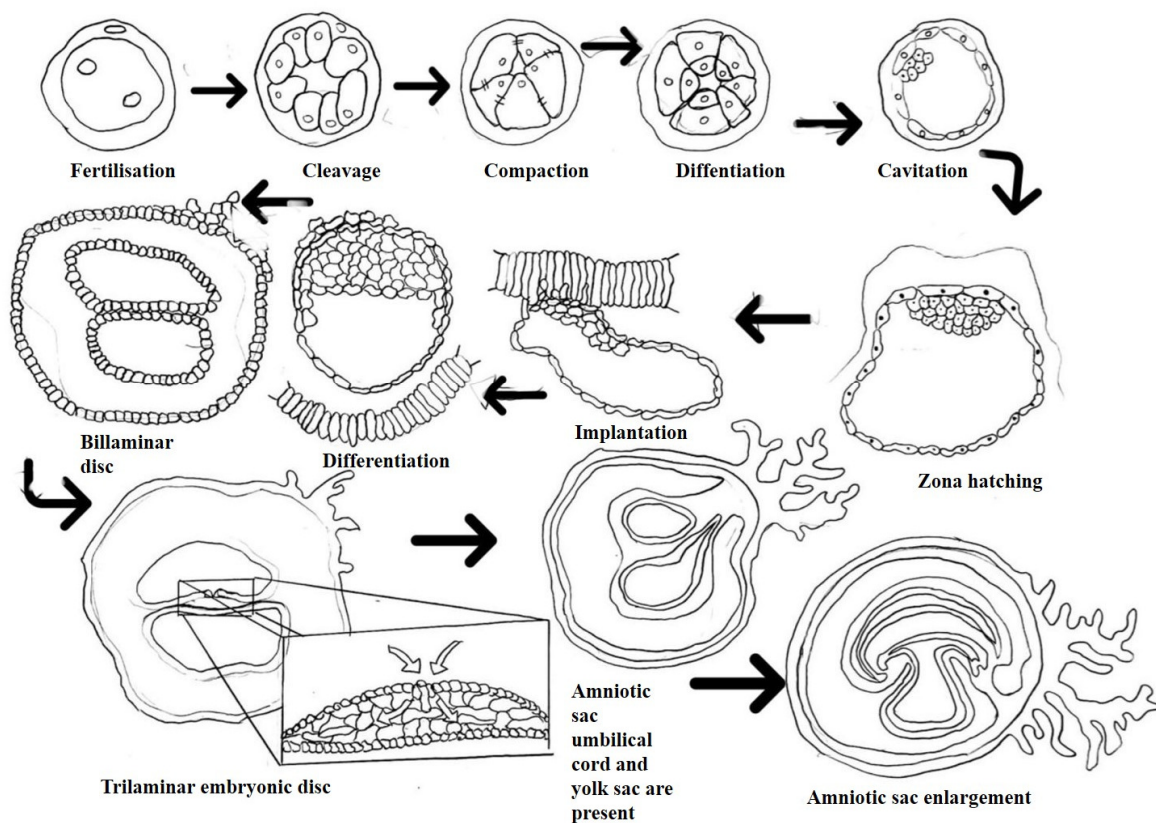
---

### 1. Head and neck embryology

*Assoc. Prof. Dr. Faur Alexandra*

The importance of the head and neck embryology allows the understanding of the normal craniofacial morphology but also provides insights into how congenital deformities occur. The sensitive period for the future living organism is represented by the **embryonic stage** which is the period between 16 days-8 weeks of the prenatal development. The embryonic stage is the stage in which the primary germ layers differentiate into organs and systems and this period ends when all organs are present. During this period of organogenesis, the shape of an embryo greatly changes and an exposure to certain agents may cause major congenital malformations. (1,2)

Around day 15 postconception the embryonic disc has two layers **the epiblast** and **the hypoblast** and it is flanked by two spaces the amniotic cavity and the yolk sac. On the embryonic disc along the midline of the epiblast a groove, the primitive streak, is formed. With this primitive streak the disc has two symmetric sides, the left and right side, two surfaces, dorsal and ventral surface and two ends, cephalic and caudal ends. During this 3rd week of development **the trilaminar embryonic disc** is formed and at this level three important structures are present the primitive streak, the notocord and the neural tube (fig 1). This disc **has three layers ectoderm, mesoderm and endoderm**. In the region of the primitive streak from the epiblast groups of cells move inward forming the mesoderm and some of the epiblast cells displace the hypoblast and the endoderm layer is formed. The cells which remain in the epiblast will be forming the ectoderm. The formation of the trilaminar disc is called **gastrulation**.(1,2).



**Fig. 1. Embryo development in the first 3 weeks of gestation**

Cells migrating cranially through the primitive node form the notochordal process, the future notochord, which defines the primitive axis of the embryo. The developing notochord induces the overlying ectoderm to form the neural plate the primordium of the central nervous system. The mesoderm layer and the notochord separate the ectoderm and endoderm layers entirely, with the exception of the prechordal plate cranially (future oropharyngeal membrane) and the cloacal membrane (future anus) caudally. The two membranes are demarcating the sites of the future end and exit of the gut. The invagination of the epiblast cells through the primitive streak results in an expansion of the embryonic disc at the cranial end of the embryo thus the cells will begin differentiating while in the caudal end the gastrulation is continuing. In the 18 day the neural plate is formed and the neurulation process begins. (1,2)

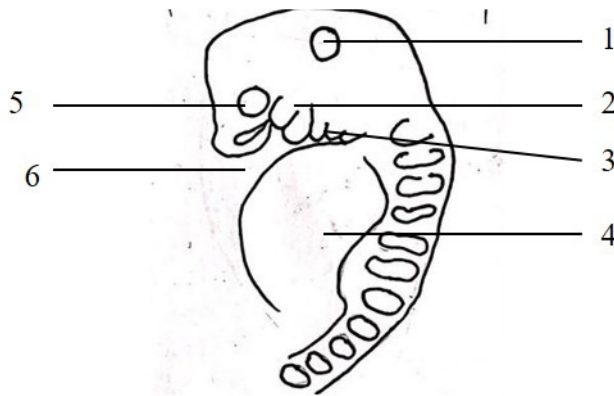
**Neurulation** is the process of the neural tube formation. This process begins with the appearance of the neural plate, which invaginates along its central axis to form the neural groove, with neural folds on each side. From the neural folds by approaching each other in the midline the neural crests are made. The neural crests fuse on the midline converting the neural

groove into a neural tube. Formation of the neural tube begins in the region of the future neck (the 4th somite) and proceeds in the cranial and caudal directions and it is open by way of the cranial (anterior) and caudal (posterior) neuropores. **Closure of the anterior neuropore occurs on the 25th day**, whereas the **posterior neuropore closes on the 27th day**. As the neural tube separates from the surface ectoderm, the neural crest cells migrate to the sides of the neural tube. The neural crest separates into the right and left part, and migrate to dorsolateral aspects of the neural tube. (1,2)

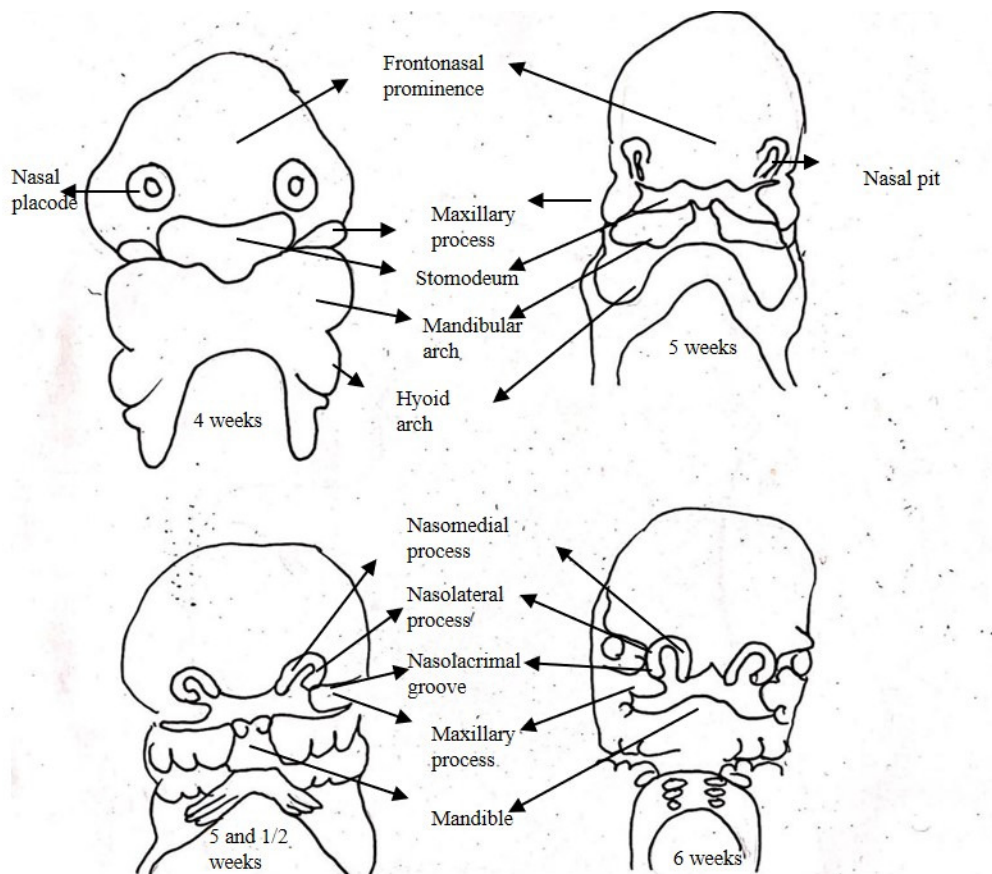
The development of the facial region includes contribution from the **ectoderm** which will help form the face and oral cavity and from **the neural crest mesenchyme** which has a major contribution in the branchial arch and their derivatives. The neural crest tissue has a pluripotent cell population derived from the crest of the neural folds during the neural tube closure. In this closure process the epithelial and mesenchymal interacts and transforms resulting the ectomesenchyme. Migration, proliferation and differentiation of the neural crest cells provide the prominences of the embryo head and neck region. Any deficiencies in the quantity and quality of the neural crest migration manifests in congenital anomaly ranging from holoprosencephaly to clefts of the lips and dimples in the cheeks. Neural crest cells typically emerge from the neural tube in a wave that spreads from anterior to posterior along almost the entire neuroaxis. The cranial neural crest cell population can be divided into forebrain, midbrain, and hindbrain domains of migrating cells. (3,4).

The skeletal and connective tissue of the face and the pharyngeal arches has as a component ectomesenchyme from the neural crest tissue. After the anterior neuropore is closed the oropharyngeal membrane region sinks and forms the **stomodeum**. The forebrain enlarges, pushes the overlying ectoderm and creates the **frontonasal process**. At the level of the oropharyngeal membrane region the ectoderm is in contact with the endoderm and forms the aforementioned membrane which disintegrates in the fifth week in which foregut opens to the outside. During these first 4-5 weeks of development the **stomodeum is surrounded by five facial prominences: frontonasal, maxillary (2) and mandibular (2) processes (Fig.2 and 3)**. The neural crest cells from the midbrain domain form part of the trigeminal, facial, glossopharyngeal, vestibulocochlear and vagal ganglia and part of the maxillomandibular placode. The migrating neural crest cells encounter pharyngeal endoderm with which they interact to form the five pharyngeal arches. The growth of the first pharyngeal arches bilaterally will produce the maxillary and mandibular prominences (4). The mandibular processes extend towards the midline and fuse in the fifth week (5). From the lateral areas of the frontonasal

prominences the **nasal placodes** develop which will sink to form first the nasal groove and then the nasal pits bordered by the nasal processes (4). For the nasal processes the mesenchyme from the neural crests has 2 origins. The midbrain neural crest cells migrate into forming the **lateral nasal process** and the forebrain neural crest cells appear to form **the medial nasal process** of the future face.



**Fig.2. Embryo at weeks 4-5.** 1 otic placode;2. maxillary process; 3. branchial arches; 4. cardiac proeminence;5. optic primordium;6. stomodeum



**Fig. 3. Embryo at 4-6 weeks**



**The nasal pits** will form the nasal sacs. The ectoderm which covers the 1/3 superior part of each enlarging nasal sac will become olfactory epithelium. The olfactory epithelia develop cellular buds and sends out nerve processes that encircles the neural cells of the olfactory lobe and in the 7<sup>th</sup> week the olfactory epithelium is in the proper location. The medial nasal process is more prominent than the lateral one and each medial one has an enlarged caudal end called the **globular process of His**.

The 2 medial nasal processes form the **intermaxillary segment** in the sixth week. The **maxillary and mandibular prominences form the commissures** of the oral cavity. The fusion between the **medial nasal process with the maxillary process will form most of the upper lip and jaw**. From the fusing of the medial nasal process results philtrum, columella and upper lip. The maxillary process migrates and forms the upper lip, cheek regions and upper jaw. The lateral nasal processes and the maxillary process form the lateral area of the nose. At the junction of these two processes the nasolacrimal groove is formed from which the nasolacrimal duct and the lacrimal sac is developing. Between the maxillary process and the medial nasal process is a groove called the bucconasal groove which fuses in the fifth week because of the medial on growing maxillary process. At the posterior end of this bucconasal groove is an epithelial membrane, the bucconasal membrane. In the 6<sup>th</sup> week the bucconasal membrane begin to thin in a 2 layer membrane called the oronasal membrane which in the middle of the 6<sup>th</sup> week will dissolve to form the primitive posterior choana. In the 7<sup>th</sup> week the nasal cavities are opened to outside through a nostril and posteriorly communicates with the pharynx. The mesenchyme of the frontonasal process and the cartilage from the body of the developing sphenoid bone will form the nasal septum, the turbinates and the paranasal sinuses. (5)

**The palate** is formed by elements deriving from the maxillary prominences and the frontonasal prominence. These three prominences are initially separated in the stomodeum by the developing tongue. As the stomodeum expands, the nasal septum descends and the tongue withdraws the palate is formed and the stomodeum has now three chambers, two nasal fossae and the mouth.

The lateral migration of the neural crest tissue surrounds the mesodermal cores of the pharyngeal arches. As a consequence, the five pairs of arches described for the human embryo are separated by ectodermal grooves externally, endodermal pharyngeal pouches internally and have a central core of mesenchyme invaded by neural crest cells. (4)

**Pouches differentiates into:**

- from the first pouch-middle ear tympanum and the Eustachian tube
- second pouch-palatine tonsils fossae
- third pouch- inferior parathyroid gland and thymus
- 4<sup>th</sup> -superior parathyroid gland
- 5<sup>th</sup> -forms ultimobranchial body, calcitonin C cells (4)

**Grooves differentiates into:**

- 1<sup>st</sup> arch-external acoustic meatus, ear hillocks, pinna
- from 2nd-5<sup>th</sup> disappears

**The 1st pharyngeal arch derivatives** are: body of tongue, Meckel cartilage, malleus, incus, external carotid artery, maxillary artery, the masticatory muscles, and also tensor tympani, mylohyoid, tensor palati, anterior belly of the digastric muscle, mandibular division of the trigeminal nerve and lingual nerve. (4)

**The 2nd pharyngeal arch derivatives** are: stapes, styloid process, superior part of the body of the hyoid bone, midtongue, thyroid gland anlage, tonsils, stapedia artery (disappears), the facial muscles, stapedius, stylohyoid and the posterior belly of the digastric muscle, facial nerve. (4)

**The 3rd pharyngeal arch derivatives** are: inferior part of the body of the body and greater conus of the hyoid bone, root of the tongue, oral fauces, epiglottis, internal carotid artery, stylopharyngeus muscle, and glossopharyngeal nerve. (4)

**The 4th pharyngeal arch derivatives** are: thyroid and laryngeal cartilages, pharynx, epiglottis, aorta, subclavian artery, pharyngeal constrictors, levator veli palatini, palatoglossus, palatopharyngeus and cricothyroid muscles, and the motor part of vagus nerve and superior laryngeal nerve and the sensory nerve auricular nerve to external acoustic meatus. (4)

**From the 5th pharyngeal arch** the cricoid, arytenoid, corniculate cartilages, larynx, pulmonary arteries, ductus arteriosus, the laryngeal and pharyngeal constrictors muscles, the inferior laryngeal nerve and a part of motor and the sensory part of vagus are formed. (4)

**Clinical correlations.** The possible anomalies derived from the anomaly in development of the pharyngeal system are:

- from the ectodermal groove derivatives: aplasia, atresia, stenosis and duplication of the external acoustic meatus, cervical (branchial) clefts, sinus, cysts, fistula.
- from the endodermal pouch derivatives: diverticulum of the auditory tube, aplasia, atresia and stenosis of the auditory tube
- from the arches derivatives: aplasia/dysplasia of malleus, incus and mandible; aplasia/dysplasia of stapes and styloid process; defective hyoid bone; congenital laryngeal stenosis, cleft, atresia; hypoplastic/absent external carotid and maxillary arteries, double aorta, aortic interruption, right aorta, persistent stapedia artery, aortico-pulmonary septation anomalies (Di-George anomaly); deficient masticatory, facial, stapedia and faucial muscles and absent or deficient nerves (mandibular nerve, facial nerve, chorda tympani nerve, glossopharyngeal and vagus nerves). (4)

The connective tissues **derivatives of neural crest cells** are considered to be: ectomesenchyme of facial prominences and pharyngeal arches, bones and cartilages of facial and visceral skeleton, portion of the ear ossicles, dermis of face and ventral aspect of the neck, corneal mesenchyme, sclera and choroid optic coats, blood vessel walls excepting endothelium; aortic arch and arteries, dentin, periodontal ligament and cementum. The muscle tissue derivatives of neural crest cells are considered to be: the ciliary muscles, connective tissues and sheaths of pharyngeal arch muscles combined with mesodermal components. Nervous tissue derivatives of neural crest cells are considered to be: leptomeninges of prosencephalon and mesencephalon (partly), glia, Schwann sheath cells, ganglia of vestibulocochlear nerve, autonomic ganglia, spinal dorsal root ganglia, part of the sensory ganglia for trigeminal, facial, glossopharyngeal and vagal nerves, sympathetic ganglia and plexuses, parasympathetic ganglia, enteric ganglia, adenohypophysis mesenchyme, adrenomedullary cells, carotid body, part of pineal body and the melanocytes in all tissues and melanophores of iris. (4)

**Clinical correlations.** If only a small number of neural crest cells are produced or they fail to migrate to their final destinations, this can result in babies with small noses, jaws, and ears as well as cleft palate. If neural crest cell differentiation is disrupted conditions known as craniosynostosis can arise which are characterized by dysmorphic cranial shape, midface hypoplasia, seizures and mental retardation. The suture mesenchyme separating the individual

bony plates in the skull is derived from neural crest and this tissue should stay undifferentiated to facilitate birth of the fetus as well as accommodate postnatal brain growth. Aberrant neural crest cell differentiation results in pre-mature ossification of the suture mesenchyme which fuses the individual skull bones (craniosynostosis) consequently restricting skull growth and impacting upon facial and brain growth, development, and maturation (3).

Abnormalities of the neural crest migration, proliferation or differentiation is considered responsible for a wide range of syndromes from von Recklinghausen neurofibromatosis, acoustic neuroma, Di George, Klein -Waardenburg and up to Treacher Collins syndrome and holoprosencephaly. (3,4). The term of holoprosencephaly (HPE) encompasses a variety of clinical signs. So, a fetus with HPE might have a single central incisor if it is mildly affected or a severe symptoms like unseparated eye (cyclopia) or an underdeveloped nose (3)

**In the skull development** the neurocranium has the the calvaria with membranous bone origin and the cranial base which has an endochondral bone formation and the viscerocranium derived from the facial prominences. Intramembranously or endochondrally ossification of the neurocranium and viscerocranium components starts at 8 weeks postconception in so called ossifications centers that coalesce to constitute the osseous components of the skull. The skull growth is a sum of events represented by bone remodeling, appositions at the sutures and synchondroses and transpositions and displacement of the bone tissues. (4). Remodelling of bones involves osteoclast induced bone breakdown on the inner surface of the skull and osteoblast-mediated thickening on the outer surface. In the normal human skull this mechanism is important for adapting the degree of curvature of the calvarial bones to the changing circumference of the brain; in craniosynostosis it is an important compensatory mechanism for the premature loss of sutural growth centres. The caudal boundary of the neural crest forms a part of the frontal bone and the tissue between the parietal bones. The interaction between the neural crest and mesoderm forms part of the coronal, sagittal and lambdoid suture. (6)

**Clinical correlations.** Premature synchondrosal and calvarian fusion will result in distorted skull shapes such as brachycephaly, plagiocephaly and scaphocephaly. (4)

### **The thyroid gland development**

In the 4<sup>th</sup> week-thyroid is described as a depression with epithelial thickening in the floor of the pharynx appearing like a point between the the body and the base of the tongue. The point invaginates and forms foramen cecum=blind duct from which the thyroid primordium develops and descends in the neck like a bilobed diverticulum to reach its location in front of

the trachea. During migration the thyroid gland is still connected to the floor of the oral cavity by an epithelial cord or duct-the **thyroglossal duct** which later becomes a solid core of cells. The thyroid becomes functional at the end of the third month when colloid containing follicles appear. (1,2,7)

The thyroglossal duct begins at the junction of the anterior two-thirds and posterior third of the tongue at the level of foramen caecum and ends at the 2<sup>nd</sup> and 3<sup>rd</sup> cartilage of the trachea where the descending pathway of the thyroid gland primordium ends and the thyroid gland matures. The distal part of the thyroglossal duct forms the pyramidal lobe of the thyroid while the thyroid gland is forming itself. The rest of the duct obliterates by the 10<sup>th</sup> week of gestation. (8)

*Clinical correlations.* The persistence of any portion of the thyroglossal duct is responsible for the formation of the thyroglossal duct cysts and the associated pathology of these cysts in the head and neck region. (8)

Lingual thyroid is considered to be an ectopic tissue which is due to the failure in migration of the thyroid gland tissue during embryogenesis along the midline of the neck from the floor of the pharynx to the usual location over the thyroid cartilage of the larynx. The patients with lingual thyroid have symptoms such as dysphagia, dysphonia, oral haemorrhages and hypothyroidism (9)

**The tongue develops** from the first three pharyngeal arches and also from the occipital muscles myotomes. The body of the tongue develops from the three elements of the arches represented by tuberculum impar and the two lateral swelling and the base of the tongue develops mainly from the 3<sup>rd</sup> pharyngeal arch and it is first present as the hypobranchial eminence. (7)

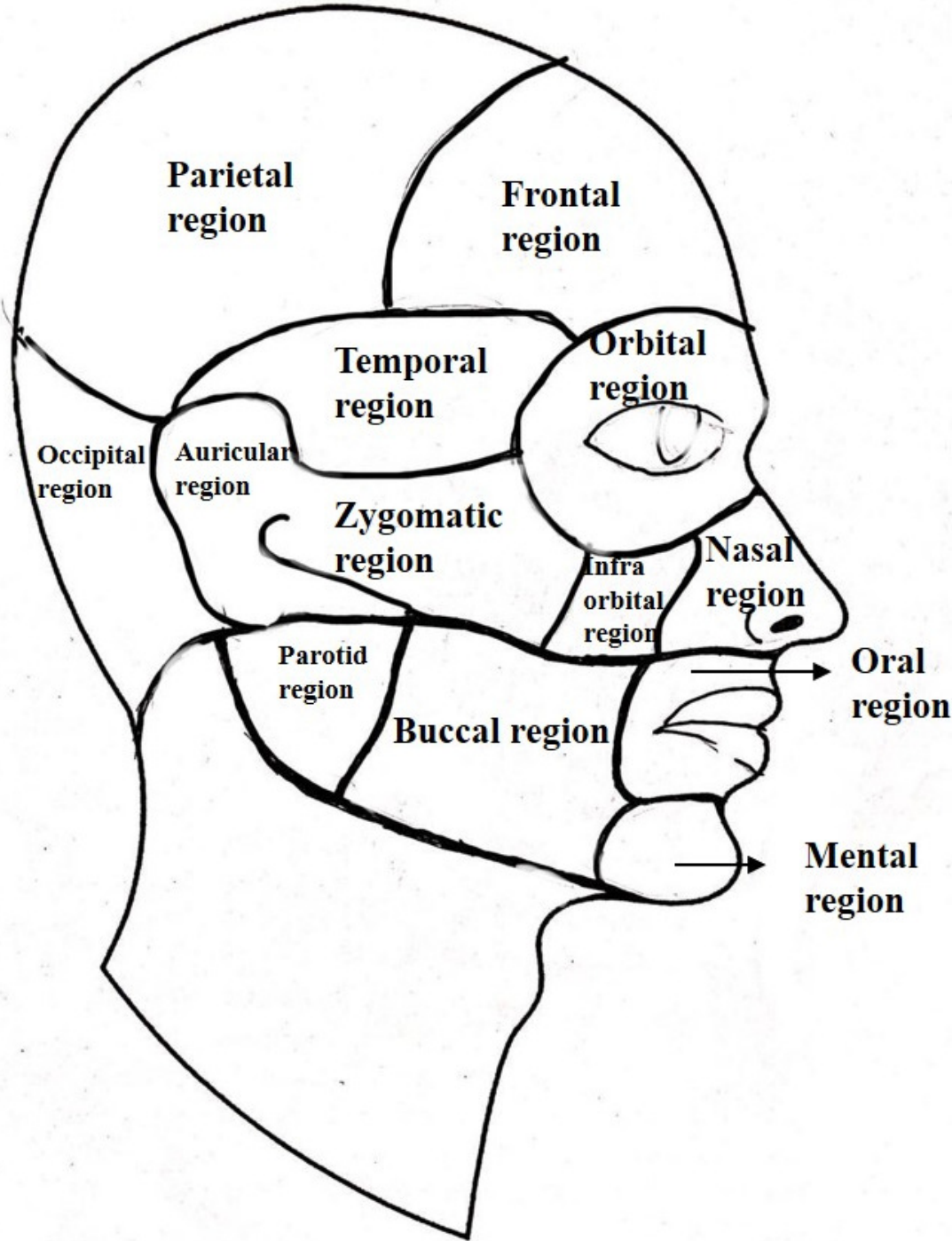
## 2. References Chapter I

1. Sadler TW, Langman`Medical Embryology, 12<sup>th</sup> edition,Lippincot Williams&Wilkins, 2012
2. <https://web.duke.edu/anatomy/embryology/embryology.html>
3. Trainor PA. Craniofacial birth defects§ the role of neural crest cells in the etiology and pathogenesis of Treacher Collins Syndrome and potential for prevention. Am J Med Genet 2010 December;0 (12): 2984-2994.doi:10.1002/ajmg.a.33454
4. Sperber GH.researchgate.net/publication/233927032. Head and Neck Embryology. Chap. 11 In Serletti at al (Eds). ” Current Reconstructive Surgery” New York. McGraw-Hill.2012
5. Som PM, Naidich TP. Illustrated rewiew of the embryology and development of the facial region, part 1: early face and lateral nasal cavities. AJNR AM J Neuroradiol 34: 2233-40, 2013. <http://dx.doi.org/10.3174/ajnr.A3415>
6. Morris-Kay GM, Wilkie AOM. Growth of the normal skull vault and its alteration in craniosynostoses: insights from human genetics and experimental studies. J Anat. 2005; 207:637-653
7. Avery JK. Oral Development and Histology, second Ed,1994, Thieme Medical Publishers, New York
8. Hussain A, Sajjad H. Anatomy, Head and Neck, Thyroid Thyroglossal Duct. [Updated 2021 Aug 11]. In: StatPearls [Internet]. Treasure Island (FL): StatPearls Publishing; 2021 Jan-. Available from: <https://www.ncbi.nlm.nih.gov/books/NBK554494/>
9. Kumar SLK, Kurien NM, Jacob MM, Menon PV, Khalam AS. Lingual thyroid. Ann Maxillofac Surg. 2015, 5(1): 104-107. doi: [10.4103/2231-0746.161103](https://doi.org/10.4103/2231-0746.161103)

# Chapter II.

## Head and Neck - Topographic Regions

---

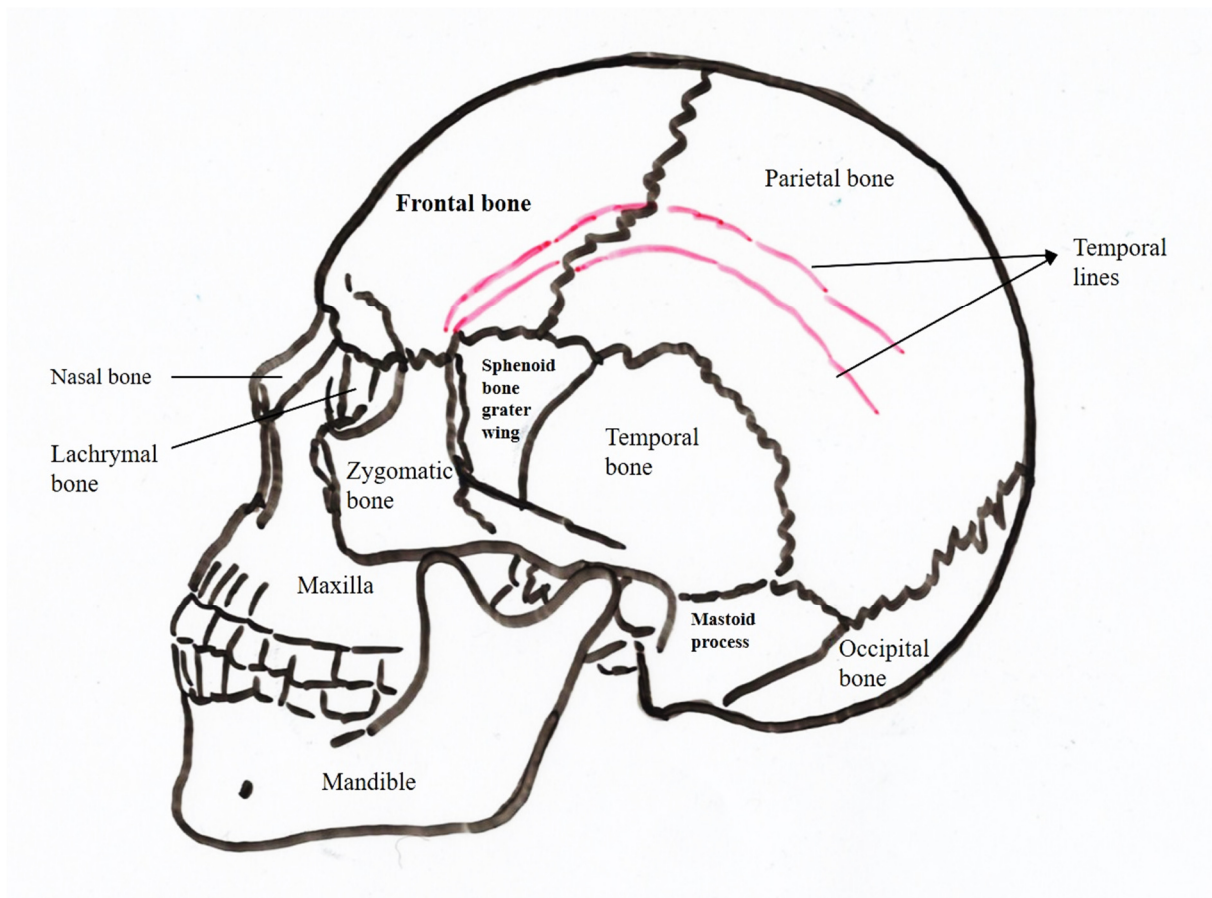


# 1. FRONTO-PARIETO-OCCIPITAL REGION

*Prof. Dr. Bolintineanu S.*

## Limits:

- Anteriorly: supraorbital border of frontal bone and glabella
- Posteriorly: superior nuchal line and external occipital protuberance
- Laterally: superior temporal lines



**Fig. 4. The skull external features**



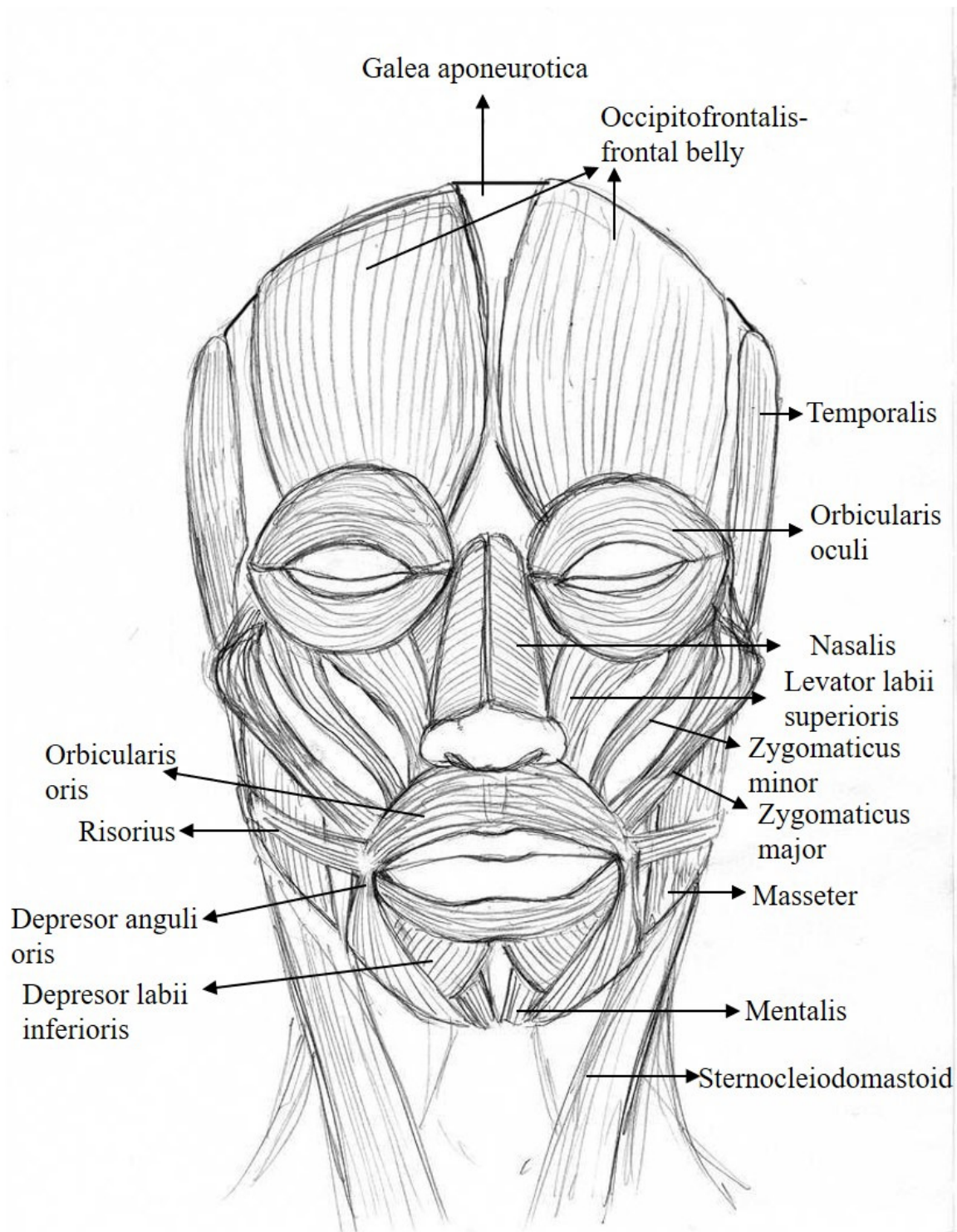
## Stratigraphy:

1. **Skin** is thick and covered by hair follicles, with the exception of antero-inferior part of the region where skin is thin and mobile. Alopecia is a condition where hair follicles are missing entirely; when some hair follicles are still present the condition is called calvitia and is more frequent in older males.
2. **Subcutaneous tissue** contains numerous spans situated between the skin's deep surface and the muscle layer that can be found inferiorly. Presence of these spans lead solidarizes the 3 superficial layers- skin, subcutaneous tissue and muscle layer- which form the scalp. These spans create compartments at the level of the subcutaneous tissue hence the lacking of spreading of a pathological process that can occur at the level of subcutaneous tissue. In the subcutaneous tissue of the fronto-parietal-occipital region the vessels and the nerves of the region are disposed as vasculo-nervous pedicles, which enter at the level of the inferior part of the region and orientate ascendingly towards the vertex. Because of this disposition, the surgical incisions are done in vertical manner, to protect the vasculo-nervous pedicles. If the pedicles are damaged during surgery, a circular tourniquet is applied. The region contains 10 vasculo-nervous pedicles, 5 on each side:
  - a. **Medial frontal pedicle**: formed by **supratrochlear vessels and medial branch of frontal nerve**. Supratrochlear artery arises from ophthalmic artery, branch of internal carotid artery. Medial branch of frontal nerve arises from frontal nerve, branch of ophthalmic nerve.
  - b. **Lateral frontal pedicle**: formed by **supraorbital vessels and lateral branch of frontal nerve**. Supraorbital artery arises from ophthalmic artery. Lateral branch of frontal nerve is a branch of frontal nerve, branch of ophthalmic nerve.
  - c. **Pre-auricular pedicle**: formed by **superficial temporal vessels and auriculo-temporal nerve**. Superficial temporal artery is a terminal branch of external carotid artery. Auriculo-temporal nerve is a branch of mandibular nerve.
  - d. **Retro-auricular pedicle**: formed by **posterior auricular vessels and auricular and mastoid branches of superficial cervical plexus**. Posterior auricular artery is a collateral branch of external carotid artery.
  - e. **Occipital pedicle**: formed by **occipital vessels and posterior branches of the first 3 cervical spinal nerves** which can anastomose and form the posterior cervical plexus. Occipital artery is a branch of external carotid artery.

- 3. Musculo-aponeurotic layer:** consists of occipito-frontalis muscle which is formed by 2 muscular parts connected by the epicranial aponeurosis (galea aponeurotica)
- **Occipital part** (*Venter occipitalis*): has a quadrangular shape with its origin onto supreme nuchal line and mastoid process. From there, its fibers orientate superiorly and anteriorly and end at the level of posterior border of epicranial aponeurosis and the postero-medial surface of ear auricle
  - **Frontal part** (*Venter frontalis*): is more developed than the occipital part, also has a quadrangular shape and it is situated in the anterior part of cranial vault. Origin is onto the anterior border of epicranial aponeurosis, anteriorly to coronal suture, and the insertion is at the level of the skin of the forehead.

Galea aponeurotica has 4 prolongations:

- Anterior prolongation: which protrudes between the frontalis muscle fibers, separating them in 2 halves
  - Posterior prolongation: which protrudes between the occipitalis muscle fibers, separating them in 2 halves
  - 2 lateral prolongations (right and left) which protrude in the temporal region until it reaches the zygomatic arch giving insertion to anterior auricular muscle and superior auricular muscle.
- 4. Subgaleal layer:** is represented by loose connective tissue which allow the scalp to glide onto the deep bony layer
- 5. Osteo-periosteal layer** consists of periosteum and a bony layer. The bony layer is formed by 2 structures: one external and one internal, both composed of compact bone. Between these layers spongy bone can be found, which is also called diploe. Below the osteo-periosteal layer lay the cerebral hemispheres covered by their meninges. (1-6)



**Fig. 5. Superficial facial muscles**

## 2. TEMPORAL REGION (*Regio temporalis*)

*Dr. Taga R, Assoc Prof. Dr. Faur Alexandra*

**Temporal region is a paired topographic region of the head, situated on the lateral sides of the scalp.**

### **Limits:**

- Superiorly: superior temporal line
- Inferiorly: zygomatic arch
- Antero-inferiorly: zygomatic process of frontal bone and frontal process of zygomatic bone
- Posteriorly: the line that prolongates inferiorly the superior temporal line of parietal bone

**(Consult fig. 4)**

Temporal region can be found between the frontal region anteriorly, occipital region posteriorly, parietal region superiorly and zygomatic, parotic-masseteric, auricular and mastoid regions inferiorly. At this level, temporalis muscle can be palpated by clenching the teeth repeatedly. Pterion represent the bony landmark where 4 bones meet: frontal, temporal, parietal and sphenoid bones and it is of high importance because it overlies the anterior division of middle meningeal artery. At this level, if a fracture occurs and the artery ruptures it can form an extradural hematoma, which can compress the brain and further can lead to loss of consciousness and even death. Therefore, Pterion represents the point of entry into the cranial vault during the removing of extradural hematoma, which need to be done as early as possible.

### **Stratigraphy:**

**1. Skin** is mostly covered by hair, with the exception of a small region situated antero-inferiorly. The name of the region comes from the Latin “tempo” meaning time, suggesting that the passing of the time is firstly visible in this region, as it is the first region where the white hairs appear.

## 2. Subcutaneous tissue:

- a. In the antero-inferior part: subcutaneous tissue is thin, permitting the visualization of the superficial temporal vessels.
- b. In the postero-superior part: subcutaneous tissue contains numerous connective spans which connect the skin with the aponeurotic layer. At this level muscles and blood vessels can be found:
  - **Superficial muscles:** anterior auricular muscle, superior auricular muscle, posterior auricular muscle, temporo-parietal muscle.
  - **Superficial blood vessels and superficial nerves:** are represented by the preauricular vasculo-nervous pedicle and retro-auricular vasculo-nervous pedicle
    - a) Pre-auricular vasculo-nervous pedicle: consists of **superficial temporal artery** (terminal branch of external carotid artery), **superficial temporal vein and auriculo-temporal nerve (from mandibular nerve)**. Superficial temporal artery enters the scalp in front of the root of zygomatic bone and gives off as frontal and parietal branches.
    - b) Retro-auricular vasculo-nervous pedicle consists of **posterior auricular artery, posterior auricular vein and auricular and mastoid branches of superficial cervical plexus**. Posterior auricular artery enters the scalp behind the root of the ear.
    - c) Lymphatic vessels drain into parotid and mastoid lymph nodes.

**3. Aponeurotic layer:** consists of 2 layers, one superficial and one deep layer separated by a layer of connective tissue. Superficial layer is represented by the lateral prolongation of galea aponeurotica. Deep layer is represented by temporalis muscle fascia.

**I. Galea aponeurotica (epicranial aponeurosis):** is a band of dense connective tissue which can be found between the frontalis and occipitalis muscle. Inferiorly and laterally, galea aponeurotica gets thinner in order to insert onto temporalis fascia. On the external surface of it superior auricular muscle, inferior auricular muscle and temporo-parietal muscle insert.

**II. Temporalis fascia:** has the same shape as the temporalis muscle. Insertions:

- i. Superiorly: onto the frontal process of zygomatic bone, zygomatic process of frontal bone, temporal line of frontal bone, superior temporal line of parietal bone; from the superior temporal line it is continuous with the periosteum
- ii. Inferiorly: the fascia splits into 2:

1. Superficial layer which will insert at the level of lateral surface of zygomatic arch
2. Deep layer which will insert at the level of zygomatic arch. Between the 2 layers middle temporal lodge can be found

**4. Muscular layer:** is represented by the temporalis muscle which has the origin on the temporal fossa, inferior temporal line and deep surface of temporal fascia. The muscle is contained inside of a lodge together with 3 deep temporal vasculo-nervous bundles. The temporalis muscle` fascicles have a fan-shape disposition and end through a tendon which insert onto the coronoid process of the mandible. Temporalis muscle has 3 muscular fascicles:

TEMPORALIS M.	Direction of fibers	Innervation	Action
<b>Anterior fascicle</b>	almost vertical direction	anterior temporal nerve	pulls the mandible upwards.
<b>Middle fascicle</b>	oblique fibers	middle temporal nerve	pulls the mandible upwards and posteriorly
<b>Posterior fascicle</b>	almost horizontal fibers	posterior temporal nerve	Pulls the mandible posteriorly.

**5. Deep blood vessels and deep nerves:** can be found between the deep surface of temporalis muscle and temporal region periosteum and are grouped into 3 bundles:

**a. Anterior deep temporal bundle:** Anterior deep temporal artery (branch of maxillary artery, which is a terminal branch of external carotid artery), anterior deep temporal vein (which drains into pterygoid plexus) and anterior deep temporal nerve (branch of mandibular nerve, from the trigeminal nerve)

**b. Posterior deep temporal bundle:** Posterior deep temporal artery (branch of maxillary artery, which is a terminal branch of external carotid artery), posterior deep temporal vein (which drains into pterygoid plexus), posterior deep temporal nerve (branch from mandibular nerve, from the trigeminal nerve)

**c. Middle deep temporal bundle:** Middle temporal artery (branch of superficial temporal artery, which is a terminal branch of external carotid artery), middle deep temporal vein (drains into pterygoid plexus), middle deep temporal nerve (branch from mandibular nerve, from the trigeminal nerve)

Deep temporal nerves: one anterior and one posterior, arise from anterior trunk of mandibular nerve. Posterior deep temporal nerve can sometimes arise from a common trunk together with masseteric nerve, and anterior deep temporal nerve can sometimes arise from buccal nerve. Other times, a middle deep temporal nerve can exist, arising from the anterior trunk of mandibular trunk.

**6. Bony layer** consists of:

- a. External periosteum layer which is continuous with the surrounding ones
- b. Bony layer: is formed by temporal fossa (*fossa temporalis*). Floor of temporal fossa consists of:
  - i. 4 bones joint together (their meeting point is called Pterion):
    - Superiorly: temporal surface of frontal bone and squamous part of parietal bone inferiorly to inferior temporal line
    - Inferiorly: temporal surface of greater wing of sphenoid bone, temporal surface of squamous part of temporal bone
  - ii. 4 sutures:
    - Lateral part of coronal suture
    - Sphenofrontal suture,
    - Squamous suture
    - Sphenosquamosal suture

Endocranial surface presents vascular grooves, mammillary eminences and digit-like impressions.

- c. Internal periosteum layer: between dura mater and the cerebral surface of the squamous part of temporal bone the meningeal artery can be found. Middle meningeal artery enters through the spinous foramen and ascends through the thickness of dura mater, together with its anterior, middle and posterior branches.

**7. Dura mater:** in this region, dura mater is firmly detached, favoring the appearance of extradural hematomas. (1-6)

### 3. ZYGOMATIC REGION (*Regio zygomatica*)

*Dr. Taga R*

**Zygomatic region is a prominent region of the face, situated superiorly to the buccal region and it overlies the zygomatic arch and zygomatic bone.**

#### **Limits:**

- Superiorly: orbital and frontal regions
- Inferiorly: parotid region
- Laterally: infratemporal region
- Medially: infraorbital region

#### **Stratigraphy:**

##### **1. Skin**

**2.Malar surface of zygomatic bone**, which forms the bony prominence of the region (cheeks) inferiorly and lateral to the orbital region.

- The malar surface is convex and perforated near its center by the zygomaticofacial foramen, which transmits the zygomaticofacial nerve and vessels; below this foramen is a slight elevation, which gives origin to the Zygomaticus.
- **Zygomatic arch** is formed by the articulation of zygomatic process of temporal bone together with temporal process of zygomatic bone, forming a bony ridge between the eye and the ear. Inferiorly to the zygomatic arch, the temporomandibular joint can be felt. (1-6)



## 4. INFRAORBITAL REGION (*Regio infraorbitalis*)

*Dr. Taga R*

**Infraorbital region is a paired lateral region of the face, situated inferiorly to the orbital region and infrapalpebral sulcus.**

### **Limits:**

- **Superiorly:** infraorbital border of maxilla
- **Inferiorly:** a conventional line which connects labial commissure with the tragus or the inferior border of the zygomatic arch with the posterior extremity of nasal wing
- **Anteriorly and medially:** nasolabial sulcus
- **Posteriorly and laterally:** a vertical line through the zygomatic process of frontal bone and anterior border of masseter muscle/ zygomaticomaxillary suture

Infraorbital region is situated between orbital region and infra-temporal groove superiorly, buccal region inferiorly, nasal region medially and zygomatic region laterally. The infraorbital region corresponds to the upper part of the anterior surface of the maxilla and at this level the infraorbital foramen can be found at about 1 cm inferiorly to the infraorbital margin. This aspect is important because at this level infraorbital nerve block can be performed.

### **Stratigraphy:**

1. **Skin** is thin and elastic and covered by hair follicles in males, containing numerous sebaceous and sudoriparous glands.
2. **Subcutaneous tissue** is poorly developed at this level.

**3. Muscular layer:** consists of the following muscles:

	<b>Origin</b>	<b>Insertion</b>	<b>Action</b>	<b>Innervation</b>
<b>M. levator labii superioris alaeque nasi</b>	Frontal process of maxilla, on the medial orbital wall	Nasal wing, upper lip	Lifts the lips and nasal wings (breathing through the nostrils, showing arrogance)	Facial nerve
<b>M. levator labii superioris</b>	Superior to the Foramen Infraorbitale on the maxilla	Upper lip	Pulls the superior lip laterally upwards, dilates the nostrils	Facial nerve
<b>M. levator anguli oris</b>	Canine fossa	Angle of the mouth	Pulls the angle of the mouth medially upwards	Facial nerve
<b>Orbital part of M. orbicularis oculi</b>	Anterior lacrimal crest Frontal process of maxilla Lacrimal bone Medial palpebral ligament	Lateral palpebral ligament	Powerful eyelid closure	Facial nerve

**4. Bony layer:** consists of the anterior surface of the maxilla`s body, where the following bony landmarks can be found:

**a. Foramen infraorbitale:** situated 4-10 mm inferiorly to the middle of the infraorbital border, on the vertical line drawn through the superior pre-molars, being in line with supra-orbital foramen. It represents the opening of the infraorbital canal and is located superiorly to the fossa canina. Infraorbital foramen transmits:

- Infraorbital artery
- Infraorbital artery
- Infraorbital nerve (branch of maxillary division of CN V). At the level of the infraorbital groove, the infraorbital nerve gives off the following sensory branches:
  - Posterior superior alveolar nerve
  - Middle superior alveolar nerve

- Anterior superior alveolar nerve
- b. Canine Fossa:** depression found laterally to the incisive fossa, being separated from it by the canine eminence. It corresponds to the socket of the canine tooth.

**5. Blood vessels and nerves:**

**a. Arteries:**

- Infraorbital artery, branch from maxillary artery
- Facial artery, situated on the medial limit of the region, in the nasopalpebral sulcus
- Transverse artery of the face, branch from superficial temporal artery

**b. Veins: drain into internal jugular vein through:**

- Angular vein
- Facial vein
- Transverse vein of the face.

**c. Lymphatics: drain towards the submandibular lymphatic group and superficial parotid lymphatic group**

**d. Nerves-Zygomatic and Buccal branches, which represent terminal branches of facial nerve innervate mimics muscles**

- ii. **Infraorbital nerve, branch of maxillary nerve (from trigeminal nerve)** ensures the sensory innervation of the region (1-6)

## 5. BUCCAL REGION (*Regio buccalis*)

*Dr. Taga R, Assoc Prof. Dr. Faur Alexandra*

**Buccal region represents a paired (even) topographic region situated in the central part of the face, with an almost quadrangular shape, irregular, which forms the vast majority of the lateral walls of the buccal vestibule- “cheeks”.**

### **Limits:**

- **Superiorly:** a conventional line which connects labial commissure with the tragus or the inferior border of the zygomatic arch with the posterior extremity of nasal wing
- **Inferiorly:** inferior border of mandibula
- **Anteriorly:** a vertical line drawn at 1 cm laterally to the labial commissure, to the posterior extremity of alaeque nasi to the inferior border of the mandible`s body
- **Posteriorly:** anterior border of masseter muscle

**(Consult fig.5)**

Buccal region can be found between infraorbital region and zygomatic region superiorly, submental region inferiorly, oral region and mental region anteriorly and parotic-masseteric region posteriorly. Buccal region overlies the buccinator muscle, having a quadrangular shape, extending vertically, but this aspect depends highly on the nutritional status, age, pathologies or physiological acts. Children and obese persons have a more prominent and round aspect of the region because of the presence of buccal (Bichat`s) fat pad, which contributes to the contour of the cheek area. Loss of adipose tissue in the facial region, a normal phenomenon that happens with age, will lead to a more excavated aspect of the buccal region. In the paresis of the facial nerve (central facial paresis) the muscles from the same part lose their tonus and facial asymmetry occurs.

## **Stratigraphy:**

**1. Skin** is thin and elastic and it is covered by hair follicles in males, containing numerous sebaceous glands. In healthy individuals, the skin colour is rose-pink due to its rich vascularization, but this aspect can be influenced by many physiological and pathological factors.

**2. Subcutaneous adipose tissue** passes through the muscles of the superficial layer and it continues at the intermuscular level. This layer is crossed by the facial vessels, parotid duct and the terminal branches of the facial nerve.

I. At this level the buccal fat pad (Bichat's fat pad) can be found, between the masseter muscle and buccinator muscle. Bichat's fat pad is an adipose mass covered by a connective layer which prolongates towards the temporal region and infra-temporal region.

II. Parotid duct (*Stensen duct, Ductus paroticus*): drains saliva from the parotid gland into the buccal vestibule. The duct bends around the frontal edge of masseter muscle in almost a 90 degree angle, perforates the buccinator muscle and opens at the level of the second superior molar into the buccal vestibule

III. Juxtaoral organ (Organ of Chievitz): a small epithelial organ embedded in connective tissue rich in nervous fibers and cells, surrounded by a perineural sheath, that lies on the buccinator muscle, near the site where parotid duct perforates the buccinator muscle, with an unknown function (presumably, it prevents biting of the cheeks when chewing)

**3. Muscular layer:** presents a superficial layer and a deep layer, separated by an intermuscular loose connective tissue which is continuous superficially with the subcutaneous adipose tissue.

- **Superficial muscular layer** consists of the following muscles:

	<b>Origin</b>	<b>Insertion</b>	<b>Action</b>	<b>Innervation</b>
<b>M. Levator labii superioris alaeque nasi</b>	Frontal process of maxilla, on the medial orbital wall	Nasal wing, upper lip	Lifts the lips and nasal wings (breathing through the nostrils, showing arrogance)	Facial nerve
<b>M. Levator labii superioris</b>	Superior to the Foramen Infraorbitale on the maxilla	Upper lip	Pulls the superior lip laterally upwards, dilates the nostrils	Facial nerve
<b>M. Zygomaticus major</b>	Malar surface of zygomatic bone	Angle of the mouth	Pulls the angle of the mouth laterally upwards ( <i>muscle of joy</i> )	Facial nerve
<b>M. zygomaticus minor</b>	Zygomatic bone, medial to zygomaticus major insertion	Angle of the mouth	Pulls the angle of the mouth laterally upwards	Facial nerve
<b>M. Risorius</b>	Parotic and masseteric fascias	Angle of the mouth	Broadens the mouth (muscle of grin) and creates dimples	Facial nerve
<b>M. Depressor anguli oris</b>	Inferior border of Mandible	Angle of the mouth	Moves the angle of the mouth downwards (discontent, grief)	Facial nerve

- **Deep muscular layer** is formed by buccinator muscle and levator anguli oris.
  - Buccinator muscle is the main cheek muscle, covered by its fascia (the other facial muscles do not possess a fascia). It originates from the pterygomandibular raphe (a ligament of the buccopharyngeal fascia, from the pterygoid hamulus of the medial pterygoid plate of sphenoid bone to the mylohyoid line of the mandible) and its fibers end superficially, towards the skin of the angle of the mouth. Parotid duct perforates this muscle.

	<b>Origin</b>	<b>Insertion</b>	<b>Action</b>	<b>Innervation</b>
<b>M. Buccinator</b>	Pterygo-mandibular raphe	Angle of the mouth	Increases the pressure within oral cavity (during blowing and chewing), prevents biting the cheeks during mastication	Facial nerve
<b>M. Levator anguli oris</b>	Fossa canina	Angle of the mouth	Pulls the angle of the mouth medially upwards	Facial nerve

4. **Mucous layer:** is represented by the vestibular mucosa which lines the lateral wall of the buccal cavity and adheres to the deep surface of buccinator muscle, explaining why when eating big mucosa folds do not appear. Between the mucosa and the muscle layer numerous small (minor) salivary glands can be found (buccal glands). Papilla of parotid duct is the opening of parotid duct and can be found at the level of maxillary second molar. This mucous layer is continuous with the gingival mucosa superiorly and inferiorly, between them existing gingivolabial sulci.
5. **Bony layer:** is represented by the mandible's body and anterior surface of the maxilla's body.
6. **Blood vessels and nerves:**
  - a. **Facial artery** enters the region at the level of inferior border of the mandible (a region where its pulsations can be felt) and crosses the region having a sinuous and ascending trajectory. In this region, from the facial artery arise also superior and inferior labial arteries for the oral region. At the level of internal eye angle, facial artery anastomoses with the angular artery, branch of ophthalmic artery, explaining why an infection at the level of the face can easily spread intracranially.
  - b. **Facial vein,** accompanies facial artery
  - c. **Mental artery,** branch of maxillary artery.
  - d. **Terminal branches of facial nerve (zygomatic, buccal and marginal branch of the mandible)** innervate mimics muscles. When facial paresis occurs patients cannot perform simple tasks as whistling or puffing and when trying to eat, aliments are contained between their cheek and gums.
  - e. **Branches of mandibular nerve from the trigeminal nerve** ensure the sensory innervation of the region. (1-6)

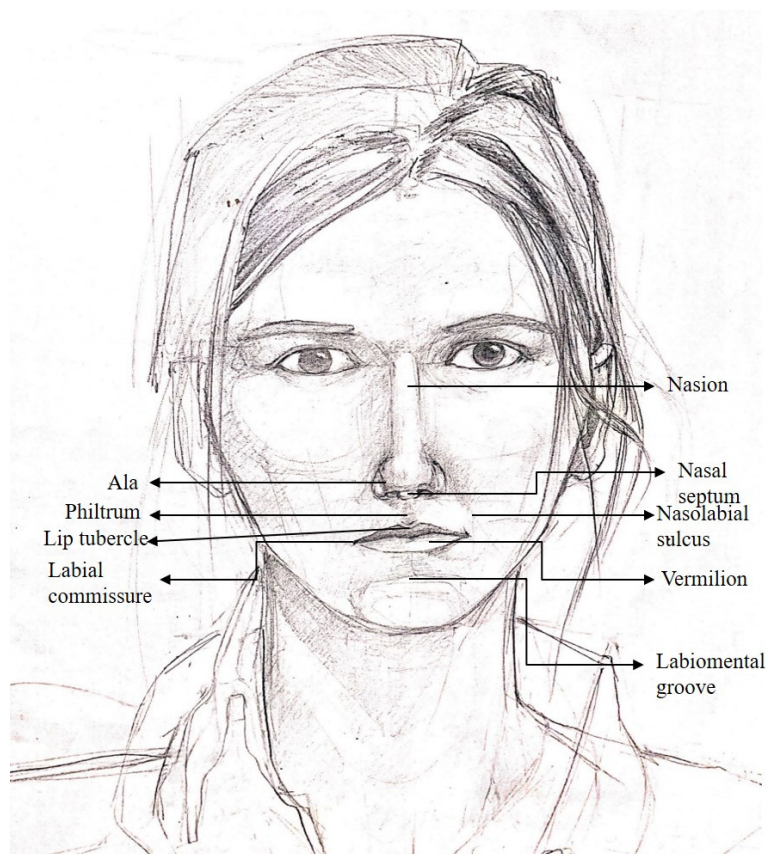
## 6. MENTAL REGION (*Regio mentalis*)

*Dr. Taga R., Assoc. Prof. Dr. Faur Alexandra*

**Mental region (chin region) represents a median region of the inferior part of the face, situated inferiorly to the labial region and superiorly to suprahyoid region from the cervical regions.**

### **Limits:**

- Inferiorly: inferior border of the mandible's body
- Superiorly: a line from the mento-labial groove prolonged towards the lines drawn at 1 cm laterally from the angle of the mouth, which represent the lateral border
- Laterally: a vertical line drawn at 1 cm laterally to the angle of the mouth to the inferior border of the mandible



**Fig. 6. External features of human face**



Mental region can be found between oral region superiorly, submental triangle inferiorly and buccal region laterally. The region represents the area inferior to the lower lip and it has a quadrangular shape, convex in all planes, sometimes presenting a median fossa called mental fossa. At the level of the anterior surface of the mandible 3 structures are distinctive: mental protuberance in the middle and 2 lateral paired structures called mental tubercles. Mental region dictates the physiognomy, prominent chin being a characteristic feature of human beings.

### Stratigraphy:

**1. Skin** is thick and covered by hair follicles forming the beard- in males. It contains numerous sebaceous and sudoriparous glands.

**2. Subcutaneous tissue** is poorly represented, containing the anterior fibers of platysma muscle and numerous connective spans. Skin is adherent to the underneath layers via connective tracts- sometimes between mental protuberance and mental tubercles mental fossa can be seen.

**3. Muscular layer:** is represented by 3 partly overlapping muscles:

	<b>Origin</b>	<b>Insertion</b>	<b>Action</b>	<b>Innervation</b>
<b>M. Mentalis</b>	Mandible, at the level of the lower lateral incisor	Skin of the chin	Creates chin dimple, everts and protrudes the lower lip (“pouting”)	Facial nerve
<b>M. Depressor labii inferioris</b>	Mandible, inferior to Foramen Mentale	Inferior lip	Pulls the lower lip laterally downwards, bulges the red margin of the inferior lip (dislike)	Facial nerve
<b>M. Depressor anguli oris</b>	Inferior border of mandible	Angle of the mouth	Moves the angle of the mouth downwards (showing grief or discontent)	Facial nerve

**4. Bony layer:** consist of a thick periosteum which covers the inferior border of mandible`s body and the anterior surface of mandible`s body where the following elements can be found:

- a. Mental symphysis
- b. Mental protuberance

- c. Mental tubercles
- d. Mental foramina

**5. Blood vessels and nerves:**

- a. Arteries** are small branches of:
  - i. mental artery (branch of inferior alveolar artery from the maxillary artery)
  - ii. submental artery (branch from facial artery)
  - iii. inferior labial artery (branch from facial artery)
- b. Submental vein**, which will drain into facial vein.
- c. Lymphatics drain towards submental lymphatic group and submandibular lymphatic group**
- d. Marginal branch of the mandible, branch of facial nerve** innervates mimics muscles
- e. Fifth inferior alveolar nerve, branch of the mental nerve** ensures the sensory innervation of the region (1-6)

## 7. NASAL REGION

*Dr. Bîna Paul*

The nose is the uppermost part of the respiratory tract and contains the peripheral organ of smell.

It consists of the external nose and the nasal cavity.

The functions of the nose are:

1. Respiration.
2. Olfaction.
3. Protection of the lower respiratory passages.
4. Air conditioning of the inspired air.
5. Vocal resonance.
6. Nasal reflex functions.

The external nose is a pyramidal projection in the mid face.

1. **Tip** (or apex), the lower free end, flexible when palpated because it is made up of cartilage
2. **Root or bridge**, the upper narrow part, between the eyes inferior to glabella it continued with the forehead.
3. **Dorsum**, a border between the tip and the root where sides of the nose meet.
4. **Nostrils or nares**, the two piriform apertures separated from each other by a midline nasal septum
5. **Ala**, the lower flared part on the side of nose. (Consult fig.6)

## Skeleton

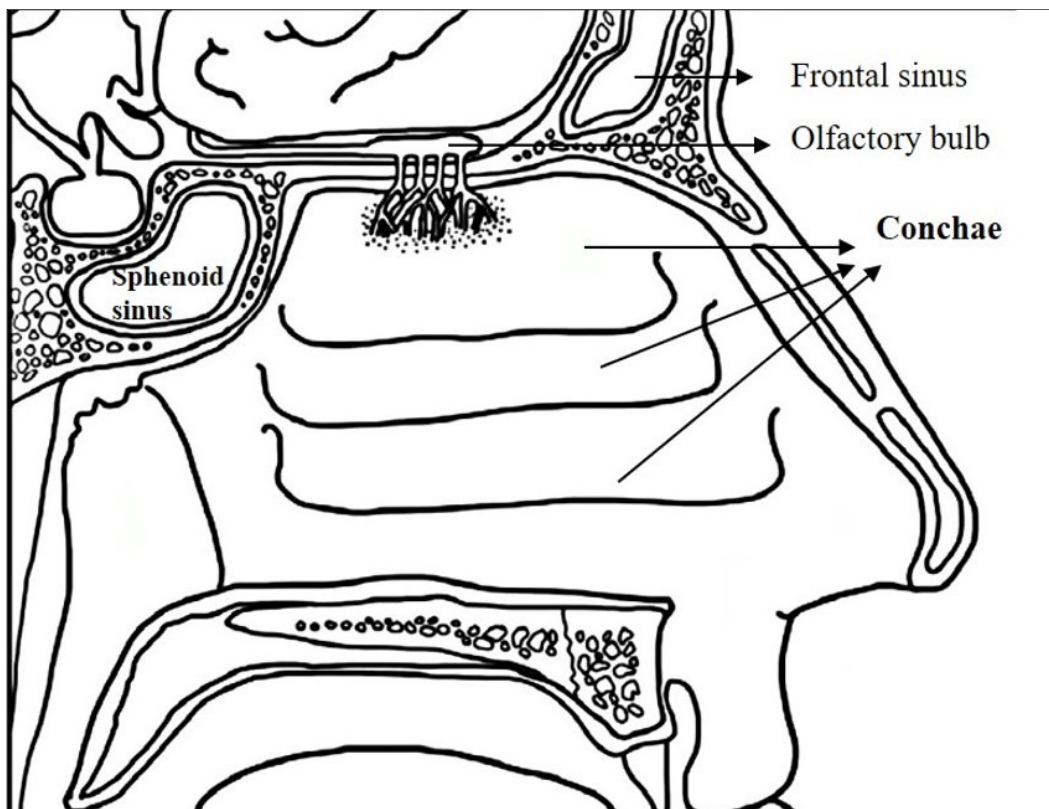
The skeletal framework of the external nose is bony and cartilaginous. The upper one-third of the external nose is bony and lower two-third is cartilaginous. The **bony framework** is formed by: *two nasal bones, frontal processes of the maxillae, the nasal part of the frontal bone and its nasal spine, and the bony parts of the nasal septum.*

The **cartilaginous framework** of the nose is formed by **five main cartilages**: two lateral cartilages, two alar cartilages, and one septal cartilage.

Noses aspect can vary considerably, mainly because of differences in these cartilages. The **dorsum of the nose** extends from the **root of the nose** to the **apex (tip) of the nose**. The skin over the cartilages of the nose contains many sebaceous glands. The skin extends into the **vestibule of the nose**, where it has a variable number of stiff hairs (*vibrissae*). Because they are usually moist, these hairs filter dust particles from air entering the nasal cavity. The junction of the skin and mucous membrane is beyond the hair-bearing area.

The interior of the nose is divided into right and left nasal cavities by a nasal septum

Each nasal cavity communicates with the exterior through nostril (or naris) and with the nasopharynx through the posterior nasal aperture.



**Fig.7. Anatomy of the nasal cavities**

## VESTIBULE OF NOSE

It is the anteroinferior part of nasal cavity, lined by skin. The skin contains sebaceous glands, hair follicles, and the stiff interlacing hair called **vibrissae**. Its upper limit on the lateral wall of nasal cavity is marked by **limen nasi**. Its medial wall is formed by a mobile **columella**.

### Boundaries

The nasal cavity proper presents the following boundaries:

**Roof:** The roof is narrow in front and widens near the choanae. It is horizontal in the middle third, where it is formed by the cribriform plate of the ethmoid. Through this olfactory nerves enter the cranial cavity from the nasal cavity. The anterior is formed by the nasal spine of the frontal, the nasal bone and the junction of the septal and lateral cartilages. The posterior is formed by the body of the sphenoid.

**Floor:** The floor is horizontal. It is formed by the upper surface of the hard palate, anterior palatine process of maxilla and posterior by the horizontal plate of the palatine bone.

**Medial wall:** It is formed by nasal septum. The nasal septum is a median osseocartilaginous

The **bony part** is formed by:

- (a) perpendicular plate of ethmoid, which forms the posterosuperior part of the septum, and
- (b) vomer, which forms the posteroinferior part of the septum.

The **cartilaginous part** is formed by

1. septal cartilage, which forms the major anterior part of the septum and fits in the angle between the vomer and perpendicular plate of ethmoid, and
2. septal processes of the two major alar cartilages.

**Lateral wall:** The lateral wall of the nose is complicated. It is formed by a number of bones and cartilages

The **bones** forming the lateral wall are:

nasal, frontal process of maxilla, lacrimal, conchae and labyrinth of ethmoid, inferior nasal concha, perpendicular plate of palatine and medial pterygoid plate of sphenoid.

The lateral wall is divided into three areas:

1. **Anterior part** presents a small depressed area, the **vestibule**. It is lined by the skin containing **vibrissae** (short, stiff curved hair).
2. **Middle part** is known as **atrium of the middle meatus**. It is limited above by a faint ridge of mucous membrane, the **agger nasi**.
3. **Posterior part** presents three scroll-like projections, the **conchae or turbinates**. The spaces separating the conchae are called **meatuses**. From above downwards the conchae are superior, middle, and inferior nasal conchae. Sometimes a 4th concha, the concha suprema is also present.

### ***Conchae:***

Superior and middle nasal conchae are the projections from the medial surface of the ethmoidal labyrinth

Inferior concha is the longest and broadest and is an independent bone. Covered by a mucous membrane that contains large vascular spaces

### ***Meatuses:***

Meatuses are the passages (recesses) beneath the overhanging conchae. They are visualized once conchae are removed.

1. **Inferior meatus** is the largest and lies underneath the inferior nasal concha.
2. **Middle meatus** lies underneath the middle concha. It presents following features:
  1. (a) *Ethmoidal bulla*
  2. (b) *Hiatus semilunaris*
  3. (c) *Infundibulum*
3. **Superior meatus** is the smallest and lies below the superior concha.

**Openings:** The lateral wall of the nose has a number of six openings.

Sites	Openings
Sphenoethmoidal recess	Opening of the sphenoidal air sinus
Superior meatus	Opening of the posterior ethmoidal air sinuses
Middle meatus	Opening of the middle ethmoidal air sinuses Opening of the frontal air sinus Opening of the anterior ethmoidal air sinuses Opening of the maxillary air sinus
Inferior meatus	Opening of the nasolacrimal duct (in the anterior part of meatus)

☉ The *arterial supply of the medial and lateral walls of the nasal cavity* is from 5 sources:

1. *Anterior ethmoidal artery* (from the **ophthalmic artery**).
2. *Posterior ethmoidal artery* (from the **ophthalmic artery**).
3. *Sphenopalatine artery* (from the **maxillary artery**).
4. *Greater palatine artery* (from the **maxillary artery**).
5. *Septal branch of the superior labial artery* (from the **facial artery**).

The greater palatine artery reaches the septum via the incisive canal through the anterior hard palate. The anterior part of the nasal septum is the site of an anastomotic arterial plexus involving all five arteries supplying the septum (*Kiesselbach area*).

A rich **submucosal venous plexus**, provides *venous drainage of the nose via* the sphenopalatine, facial, and ophthalmic veins. Venous blood from the external nose drains into the facial vein via the angular and lateral nasal veins. However, recall that it lies within the “danger area” of the face because of communications with the *cavernous (dural venous) sinus*.

*Nerve supply of the nose*, the nasal mucosa can be divided into postero-inferior and anterosuperior portions.

The nerve supply of the postero-inferior portion of the nasal mucosa is chiefly from the maxillary nerve, by way of the *nasopalatine nerve* to the nasal septum, and posterior superior lateral nasal and inferior lateral nasal branches of the *greater palatine nerve* to the lateral wall.

The nerve supply of the anterosuperior portion is from the ophthalmic nerve (CN V<sub>1</sub>) by way of the **anterior** and **posterior ethmoidal nerves**, branches of the nasociliary nerve. Most of the external nose (dorsum and apex) is also supplied by CN V. The **olfactory nerves**, concerned with smell, arise from cells in the **olfactory epithelium** in the superior part of the lateral and septal walls of the nasal cavity. The central processes of these cells (forming the olfactory nerve) pass through the *cribriform plate* and end in the **olfactory bulb**, the rostral expansion of the **olfactory tract**.

The paranasal air sinuses are air-containing cavities in the bones around the nasal cavity. The paranasal air sinuses develop as mucosal diverticula of the main nasal cavity invading the adjacent bones. They are lined by a **pseudostratified ciliated columnar epithelium** as in the nasal cavity.

1. **Frontal air sinuses** present in the frontal bone.
2. **Ethmoidal air sinuses** present in the ethmoid bone.
3. **Maxillary air sinuses** present in the maxilla.

**Sphenoidal air sinuses** present in the sphenoid bone. Paranasal air sinuses perform the following functions:

1. Make the skull lighter.
2. Add resonance to the voice.
3. Act as air conditioning chambers by adding humidity and temperature to the inspired air.
4. Aid in the growth of facial skeleton after birth.

## **ETHMOIDAL CELLS**

The **ethmoidal cells (sinuses)** are small invaginations of the mucous membrane of the middle and superior nasal meatus between the nasal cavity and the orbit. The **anterior ethmoidal cells** drain directly or indirectly into the middle nasal meatus through the ethmoidal infundibulum. The **middle ethmoidal cells** open directly into the middle meatus and are sometimes called “bullar cells”. The **posterior ethmoidal cells** open directly into the superior meatus. The ethmoidal cells are supplied by ethmoidal branches of the *nasociliary nerves* (CN V<sub>1</sub>).



## SPHENOIDAL SINUSES

The **sphenoidal sinuses** are located in the body of the sphenoid, but they may extend into the wings of this bone. They are divided and separated by a bony septum. Because of this extensive pneumatization, the body of the sphenoid is thin. Only thin plates of bone separate the sinuses from several important structures: the optic nerves and optic chiasm, the pituitary gland, the internal carotid arteries, and the cavernous sinuses. The posterior ethmoidal arteries and the posterior ethmoidal nerves that accompany the arteries supply the sphenoidal sinuses.

## MAXILLARY SINUSES

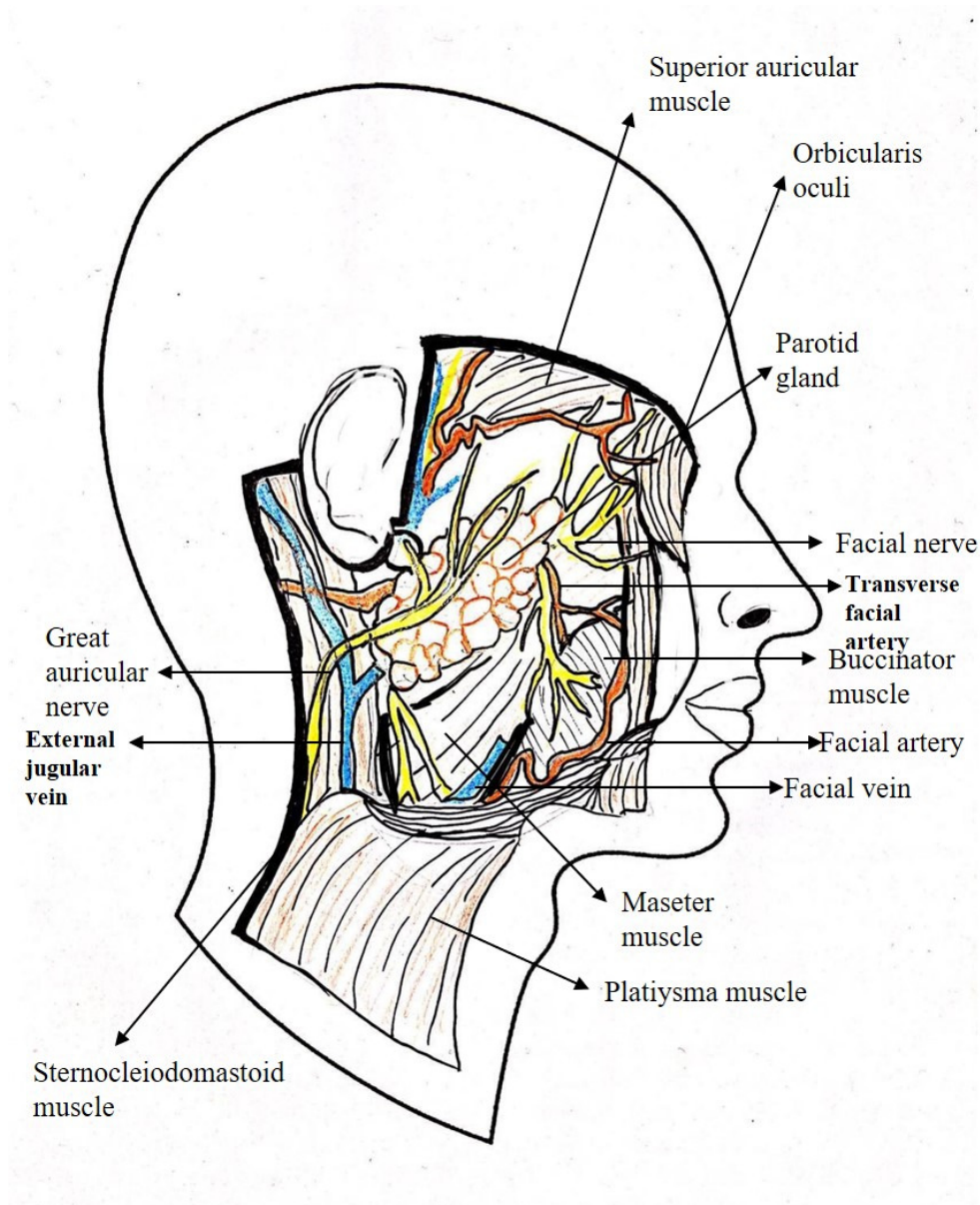
The **maxillary sinuses** are the largest of the paranasal sinuses. They occupy the bodies of the maxillae and communicate with the middle nasal meatus. Each maxillary sinus drains by one or more openings, the **maxillary ostium (ostia)**, into the middle nasal meatus of the nasal cavity by way of the semilunar hiatus. The **arterial supply of the maxillary sinus** is mainly from superior alveolar branches of the **maxillary artery**; however, branches of the *descending* and *greater palatine arteries* supply the floor of the sinus. (1-2,7-12)

## 8. THE PAROTID REGION

*Dr. Bina Paul, Assoc Prof. Dr. Faur Alexandra*

The parotid region is the area around the ear, bounded *anteriorly* by anterior border of masseter, *superiorly* by the zygomatic arch, *posteriorly* by mastoid process, and *inferiorly* by line joining the angle of the mandible to the mastoid process.

The principal structures in this area are **parotid gland** and **facial nerve**.



**Fig. 8. Parotid region**

## **The parotid gland**

The parotid gland is the largest of the three pairs of salivary glands. The parotid gland lies in the pyramidal area, posterior to the ramus of the mandible.

It extends from external auditory meatus *above*, to the upper part of the carotid triangle *below*; *Posteriorly* it overlaps/meets the anterior border of the sternocleidomastoid muscle and *anteriorly* it extends over the masseter for a variable distance. The accessory parotid gland lies between the zygomatic arch above and the parotid duct below. Several ducts from accessory gland open into the parotid duct.

The parotid gland is enclosed in a fibrous capsule called **parotid capsule**.

The gland resembles a three-sided pyramid.

### **Apex**

It projects downwards overlapping the posterior belly of digastric muscle and adjoining part of the carotid triangle.

### **Superior Surface or Base**

It is concave and related to the external acoustic meatus and posterior aspect of temporomandibular joint.

### **Superficial Surface**

It is the largest of the four surfaces. It is covered from superficial to deep by:

1. Skin.
2. Superficial fascia containing anterior branches of greater auricular nerve, lymph nodes, and platysma.
3. Parotid fascia.
4. Deep parotid lymph nodes.

### **Anteromedial Surface**

It is deeply grooved by the posterior border of the ramus of the mandible. The branches of facial nerve emerge on face from underneath the anterior margin of this surface.

### **Posteromedial Surface**

It is moulded onto the mastoid and styloid processes and their covering muscles. Thus it is related to:

1. Mastoid process, sternocleidomastoid, and posterior belly of digastric.
2. Styloid process and styloid group of muscles.

The styloid process and its muscles separate the gland from internal carotid artery, internal jugular vein, and last four cranial nerves.

The following structures enter the gland through this surface: 1. Facial nerve trunk in its upper part. 2. External carotid artery in its lower part.

### **Anterior Border**

It separates the superficial surface from the anteromedial surface. The following structures emerge underneath this border: 1. Temporal branch of the facial nerve. 2. Zygomatic branch of the facial nerve. 3. Transverse facial vessels. 4. Upper buccal branch of the facial nerve. 5. Parotid duct. 6. Lower buccal branch of the facial nerve. 7. Marginal mandibular branch of the facial nerve.

### **Posterior Border**

It separates the superficial surface from the posteromedial surface.

The following structures emerge underneath this border:

1. Posterior auricular vessels.
2. Posterior auricular branch of the facial nerve.

## STRUCTURES PRESENT WITHIN THE PAROTID GLAND

Three main structures either in part or in whole traverse the gland and branch within it. From superficial to deep these are: 1. Facial nerve. 2. Retromandibular vein. 3. External carotid artery.

The **facial nerve** is most superficial. It enters the gland through the upper part of the posteromedial surface and divides into its terminal branches within the gland.

The five terminal branches of the facial nerve radiate like a goose-foot through the anterior border of the gland and supply the muscles of facial expression.

The **external carotid artery** pierces the lower part of the posteromedial surface to enter the gland. Within the gland it divides into superficial temporal and maxillary arteries.

### Parotid Duct (Stenson's Duct)

Parotid duct, about 5 cm long, emerges from the middle of the anterior border of the gland and opens into the vestibule of the mouth opposite the crown of upper second molar tooth. The duct has a tortuous course to provide a valve-like mechanism to prevent the inflation of the duct system during excessive blowing of the mouth as in trumpet blowing.

## NERVE SUPPLY

1. **Parasympathetic (secretomotor) supply** through auriculotemporal nerve. The **preganglionic fibres** arise from the inferior salivatory nucleus in the medulla and pass successively through glossopharyngeal nerve, tympanic branch of glossopharyngeal, tympanic plexus and lesser petrosal nerve to relay into otic ganglion. **Postganglionic fibres** arise from the cells of the ganglion and pass through the auriculotemporal nerve to supply the parotid gland. The stimulation of parasympathetic supply produces watery secretion.

2. **Sympathetic supply**: It is derived from sympathetic plexus around external carotid artery formed by postganglionic fibres derived from superior cervical sympathetic ganglion. The preganglionic sympathetic fibres arise from the lateral horn of T1 spinal segment. The sympathetic fibres are vasomotor and their stimulation produces thick sticky secretion.

3. **Sensory supply**: It is derived from: (a) Auriculotemporal nerve. (b) Great auricular nerve (C2 and C3). The C2 fibres are sensory to the parotid fascia.

## VASCULAR SUPPLY

The **arterial supply** of parotid gland is derived from the external carotid and superficial temporal arteries.

The **venous drainage** of parotid gland takes place into retromandibular and external jugular veins.

### The facial nerve

The facial nerve comes out of cranial cavity through the stylomastoid foramen, between the styloid and mastoid processes of the temporal bone.

After emerging enters the posteromedial aspect of the parotid gland on the superficial plane. In the gland, it runs superficial to the retromandibular vein for about 1 cm and then divides into two trunks: (a) the temporofacial, and (b) the cervicofacial.

Branches:

1. **Posterior auricular nerve:** It supplies occipital belly of occipitofrontalis, auricularis posterior, and auricularis superior (intrinsic muscles of the ear).
2. **Branch to the posterior belly of digastric**
3. **Terminal branches:**
  - (a) *Temporal branch*—run upwards and cross the zygomatic arch.
  - (b) *Zygomatic branches*—run below and parallel to the zygomatic arch.
  - (c) *Buccal branches*—are two in number. The upper buccal nerve runs above the parotid duct and the lower buccal nerve runs below the duct.
  - (d) *Marginal mandibular (also called mandibular) branch*—runs forwards below the angle of the mandible, deep to the platysma. It then crosses the body of the mandible to supply the muscles of the lower lip and chin.
  - (e) *Cervical branch*—runs downwards and forwards to reach the front of the neck, to supply the platysma.

The long axis of each orbit (**orbital axis**) passes backwards and medially. (1-2,7-12)

## 9. THE PALPEBRAL REGION

*Dr. Bina Paul*

### **Limits:**

- Superior: Suprapalpebral sulcus
- Inferior: Infrapalpebral sulcus

### **Orbital region**

The **orbital region** is the area of the face overlying the orbit and eyeball and includes the upper and lower eyelids and lacrimal apparatus.

### **Orbits**

The **orbits** are a pair of pyramidal-shaped bony cavities in the facial skeleton located one on either side of the root of the nose and provides sockets for rotatory movements of the eyeballs. Each orbit is a quadrangular pyramid with apex directed behind at the optic canal and base forward. The medial walls of the two orbits, separated by the ethmoidal sinuses and the upper parts of the nasal cavity.

The orbits and orbital region anterior to them contain and protect the **eyeballs** and **accessory visual structures**, which include the:

- *Eyelids*, which bound anteriorly, protecting the anterior part of the eyeball.  
*Extra-ocular muscles*
- *Nerves and vessels* of the eyeballs and muscles.
- *Orbital fascia* surrounding the eyeballs and muscles.
- *Mucous membrane (conjunctiva)* lining the eyelids and anterior aspect of the eyeballs, and most of the *lacrimal apparatus*, which lubricates it.

All space within the orbits not occupied by these structures is filled with **orbital fat**; thus, it forms a matrix in which the structures of the orbit are embedded. The quadrangular pyramidal **orbit** has a base, four walls, and an apex:

- The **base of the orbit** is outlined by the **orbital margin**, which surrounds the **orbital opening**.
- The **superior wall** (roof) is horizontal and is formed mainly by the *orbital part of the frontal bone*, which separates the cavity from the anterior cranial fossa. Near the apex of the orbit, the superior wall is formed by the *lesser wing of the sphenoid*. Anterolaterally, in the orbital part of the frontal bone, is the **fossa for lacrimal gland** (lacrimal fossa).
- The **medial walls** of the orbits are parallel and are formed primarily by the **orbital plate of ethmoid bone**, along with contributions from the *frontal process of the maxilla*, *lacrimal*, and *sphenoid bones*. Anteriorly, the medial wall is dissected by the **lacrimal groove** and **fossa for lacrimal sac**;
- The **inferior wall** (orbital floor) is formed mainly by the *maxilla* and partly by the zygomatic and palatine bones. The thin inferior wall is shared by the orbit and maxillary sinus. It slants inferiorly from the apex to the inferior orbital margin. The inferior wall is demarcated from the lateral wall of the orbit by the **inferior orbital fissure**, a gap between the orbital surfaces of the maxilla and the sphenoid.
- The **lateral wall** is formed by the **frontal process of the zygomatic bone** and the *greater wing of the sphenoid*. This is the strongest and thickest wall, which is important because it is most exposed and vulnerable to direct trauma. Its posterior part separates the orbit from the temporal and middle cranial fossae. The lateral walls of the contralateral orbits are nearly perpendicular to each other.
- The **apex of the orbit** is at the **optic canal** in the *lesser wing of the sphenoid* just medial to the *superior orbital fissure*.
- The widest part of the orbit corresponds to the equator of the eyeball (Fig. 7.45A), an imaginary line encircling the eyeball equidistant from its anterior and posterior poles. The bones forming the orbit are lined with **periorbital**, the periosteum of the orbit. The periorbital is continuous:
- At the optic canal and superior orbital fissure with the periosteal layer of the dura mater.



- Over the orbital margins and through the inferior orbital fissure with the periosteum covering the external surface of the cranium (pericranium).
- With the orbital septa at the orbital margins.
- With the fascial sheaths of the extra-ocular muscles.
- With the orbital fascia that forms the *fascial sheath of the eyeball*.

### **Eyelids and Lacrimal Apparatus**

- The eyelids and lacrimal fluid, secreted by the lacrimal glands, protect the cornea and eyeballs from injury and irritation (e.g., by dust and small particles).

### **EYELIDS**

- The **eyelids** are moveable folds that cover the eyeball anteriorly when closed, thereby protecting it from injury and excessive light. They also keep the cornea moist by spreading the lacrimal fluid. The eyelids are covered externally by thin skin and internally by transparent mucous membrane, the **palpebral conjunctiva**. This part of the conjunctiva is thin and transparent and attaches loosely to the anterior surface of the eyeball.
- The **conjunctival sac** is the space bound by the palpebral and bulbar conjunctivae; it is a closed space when the eyelids are closed, but opens via an anterior aperture, the *palpebral fissure*, when the eye is open (eyelids are parted).
- The superior (upper) and inferior (lower) eyelids are strengthened by dense bands of connective tissue, the **superior** and **inferior tarsi** (singular = **tarsus**). Fibers of the palpebral portion of the *orbicularis oculi* (the sphincter of the palpebral fissure) are in the connective tissue superficial to the tarsi and deep to the skin of the eyelids. Embedded in the tarsi are **tarsal glands** that produce a lipid secretion that lubricates the edges of the eyelids and prevents them from sticking together when they close. The lipid secretion also forms a barrier that lacrimal fluid does not cross when produced in normal amounts.
- The **eyelashes** (L. *cilia*) are in the margins of the eyelids. The large sebaceous glands associated with the eyelashes are **ciliary glands**.

Between the nose and the medial angle of the eye is the **medial palpebral ligament**, which connects the tarsi to the medial margin of the orbit. The orbicularis oculi originates and inserts onto this ligament. A similar **lateral palpebral ligament** attaches the tarsi to the lateral margin of the orbit. The **orbital septum** is a fibrous membrane that spans from the tarsi to the margins of the orbit, where it becomes continuous with the periosteum. It keeps the orbital fat contained and, owing to its continuity with the periorbita, can limit the spread of infection to and from the orbit. The septum constitutes in large part the posterior fascia of the orbicularis oculi muscle. (1-2,7-12)

## 10. THE LABIAL REGION

*Dr. Bina Paul*

### **Limits**

- Superior: nasolabial groove (nasolabial sulcus), posterior border of the nose wing
- Inferior: the horizontal line passing through mento-labial fold (mento-labial sulcus)
- Lateral: the vertical line passing one centimeter lateral to the angle of the mouth (angulus oris)

(Consult fig.6)

### **Stratification:**

1. Skin layer is thicker and contains hair, sweat glands, and sebaceous glands
2. Subcutaneous cellular tissue, which is more to be found lateral
3. Muscular layer: The principal muscle of the lips is the circumferential orbicularis oris, functioning primarily as a sphincter for the oral aperture. The other ones are part of the peripheral system formed by radial muscle fascicles building ten muscles, considered muscles of facial expression. The majority of the mouth muscles are connected by a fibromuscular hub onto which their fibers insert. This structure is called the modiolus, it is located at the angles of the mouth and it is primarily formed by the buccinator, orbicularis oris, risorius, depressor anguli oris and zygomaticus major muscles.

A. **Orbicularis oris muscle** is one of the muscles of facial expression and its primary action is as the sphincter of the mouth. It consists of two parts; peripheral and marginal, with the border between them corresponding to the margin between the lips and the surrounding skin. Both portions originate from the modiolus, which is a fibromuscular structure found on the lateral sides of the mouth where several facial muscles converge. The peripheral portion passes medially into the labial areas to insert on the dermis of the lips. In the midline, some of the fibers blend with their respective counterparts, forming the philtrum of the mouth. The marginal portion passes from the modiolus on one side to the modiolus on the other side of the mouth. Some of the fibers curl upon themselves, forming the vermilion border, which is the demarcation between the lips and the adjacent skin.

**B. Buccinator muscle.** The buccinator muscle plays an active role along with orbicularis oris and superior constrictor muscle during swallowing, mastication, blowing, and sucking. It is composed of three parts; superior, inferior and posterior. The superior part originates from the alveolar process of maxilla, opposite the three maxillary molar teeth. The inferior part originates from the buccinator ridge of mandible, opposite the three mandibular molar teeth. The posterior part originates from the anterior margin of the pterygomandibular raphe behind the third mandibular molar. All three parts of the buccinator converge towards the angle of the mouth and fill the space between the upper and lower jaws. At the angle of the mouth, the fibers of the buccinator blend with other facial muscles, including orbicularis oris, risorius, depressor anguli oris and zygomaticus major, forming the modiolus. The buccinator muscle is pierced by the parotid duct (Stenson's duct) after it crosses the masseter muscle and turns medially at the anterior border of the muscle to open in the oral cavity into a small papilla opposite the maxillary second molar.

C. The levator labii superioris is a short triangular muscle that originates from the zygomatic process of maxilla and maxillary process of the zygomatic bone. It courses downwards and medially to attach on the skin. His action is significant in making certain facial expressions, such as smiling, grinning and contempt.

D. The levator labii superioris alaeque nasi is a slender, strap-like muscle found on both sides of the nose. It originates from the upper part of the frontal process of the maxilla and passes inferolaterally, inserting on the perichondrium and the skin over the major alar cartilage of the nose. Some of the fibers pass into the lateral part of the upper lip and with levator labii superioris and orbicularis oris. The function of the levator labii superioris alaeque nasi is to elevate and evert the upper lip, as well as to elevate, deepen and increase the curvature of the nasolabial furrow.

E. The zygomaticus minor, similarly to its major counterpart, arises from the lateral surface of the zygomatic bone and extends diagonally towards the lips. It inserts on the skin of the upper lip, medial to the zygomaticus major. The zygomaticus minor acts in harmony with other tractors of the upper lip to elevate and evert the upper lip, thereby contributing to a variety of facial expressions such as smiling, frowning or grimacing.

F. The zygomaticus major is a thin muscle that arises from the lateral surface of the zygomatic bone and extends diagonally to the angle of the mouth. Here, it contributes to the formation of the modiolus by interlacing with several other facial muscles. The function of the

zygomaticus major involves elevating and everting the angle of the mouth superolaterally, thereby producing a smile in synergy with other muscles.

G. The depressor anguli oris is a triangular muscle situated lateral to the chin on each side of the face. It arises from the oblique line and mental tubercle of mandible and courses almost vertically upwards to attach at the modiolus. The depressor anguli oris acts to depress the angle of the mouth, which contributes to expressing feelings of sadness or anger. In addition, this muscle assists in opening the mouth during speaking or eating.

H. The risorius is a highly variable and inconsistent muscle of the buccolabial group. It arises from several origin points that may include the fascia of the parotid gland, fascia of the masseter and platysma muscles, and occasionally the zygomatic arch. The fibers of the risorius converge medially and course horizontally towards the angles of the mouth.

I. The depressor labii inferioris is a short quadrangular muscle found in the chin region. It originates from the oblique line of mandible while being continuous with the labial part of the platysma. The muscle courses superomedially to insert on the skin and submucosa of the lower lip.

J. The mentalis is a short conical muscle located in the chin area. It arises from the incisive fossa of mandible and descends inferiorly to insert on the skin of the chin at the level of the mentolabial sulcus of the mandible. The mentalis muscle acts to depress and evert the base of the lower lip, while also creating wrinkles on the skin of the chin.

4. Glandular layer which contains a lot minor of salivary glands.

5. The reddish skin is a transition layer between the outer, hair-bearing tissue and the inner mucous membrane. The interior surface of the lips is lined with a moist mucous membrane that continues with the gum.

6. I. The labial arteries are branches from the facial artery. The labial artery perfuses the lips, nose, and muscles around the lip region. As the superior labial artery traverse across the upper lip, it will anastomose with the Kiesselbach plexuses and the contralateral superior labial artery. The upper lip region receives blood from the superior labial artery. The anastomosis between the two labial arteries provides collateral blood flow to each other.

II. The inferior labial artery branches off the facial artery around the same region as the superior labial artery. The inferior labial artery anastomoses with the contralateral inferior labial artery and mental arteries.

The branching of the labial arteries from the facial artery and the anastomoses with the contralateral side forms a network around the lips. This network helps perfuse the lips and the muscles in this region. The anastomose network of vessels can provide blood flow to either side if one side becomes compromised.

III. The nerve that is involved in opening and closing the mouth is the trigeminal nerve. This nerve innervates the muscles used for mastication. The orbicularis oris muscle receives innervation from the facial nerve. The facial nerve also innervates muscles that attach to the lips used in facial expression. (1-2,7-12)

# 11. THE MASTOID REGION

*Dr. Bîna Paul*

The mastoid region is located at the lateral part of the head and includes the mastoid part of the temporalis bone and the soft tissue layers that cover it.

## **Limits:**

- superior: supramastoid crest
- inferior: mastoid process
- anterior: vertical line of the posterior border of the external acoustic meatus
- posterior: margo occipitalis (occipital border temporal bone)

## **Stratification:**

1. Skin, which is thick at this level; superior and posterior covered by hair.
2. The subcutaneous tissue, traversed by fibrous fascial layer. Through this fibrous layer are muscles, blood vessels and nerves: posterior auricular muscle, posterior auricular artery, posterior auricular vein. Great auricular nerve originating from the cervical plexus and posterior auricular nerve from the facial nerve.
3. Muscular layer, at this level we find the tendons of the sternocleidomastoid muscle and splenius capitis covered by the superficial layer of the deep cervical fascia.
4. Bone structure, pneumatized or air filled by the mastoid air cells. (1-2,7-12)

## 12. References Chapter II

1. Bolintineanu Sorin, Vaida Monica, Saragan Izabella, Paduraru Dumitru, *Anatomie Topografica II*, Editura Eurostampa Timisoara 2008
2. Singh V. Textbook of Anatomy. Head, Neck and Brain-second edition, 2014
3. Albu 1998. *Anatomie topografica*
4. Pantea Corina,E Mirton 2008 *Ghid de Anatomy topografica*,
5. Bartleby Grey 1918
6. *Sobotta Atlas of Anatomy 16<sup>th</sup> Edition*, Elsevier ,2018
7. Moore K.L. Clinically Oriented Anatomy. Seved Ed. Lippincott Williams & Wilkins. 2014
8. Saladin K. Human Anatomy. The McGraw-Hill Companies.2004
9. <https://www.ncbi.nlm.nih.gov/books/NBK546631/>
10. <https://onlinelibrary.wiley.com/doi/pdf/10.1002/lio2.271>
11. Bolintineanu S., Vaida M., Şişu AM., Pop E., Petrescu C., Matu C., Samfirescu E., Roşu L., Pusztai A., Stoican L., Băcean A., *Anatomia Capului și Gâtului*, Editura Eurostampa, 2016.
12. Prundeanu H, Motoc A, Prundeanu C, Grigoriță L, Băcean O, Moise M. Anatomy Tests for Medical Students.Art Press, 2014