

# Oral Pathology

## *Developmental Disorders of teeth*

The development of teeth is regulated by genes, but the genetic program is very sensitive to disturbances in the environment such as infection, or toxic chemicals. The causes of developmental disorders of teeth are multifactorial, involving the interaction of genetic and environmental factors.

These disorders may be prenatal or postnatal in origin and may inherit or acquired. Disorders of development of teeth may be due to abnormalities in the differentiation of the dental lamina and the tooth germs, causing anomalies number, size, form of teeth and abnormalities of morph differentiation or abnormalities in the formation of the dental hard tissue resulting in disturbances in tooth structure ((abnormalities of histo differentiation)).

### *Developmental Alterations in the Number of Teeth*

**Hypodontia** ,when one or several teeth are missing.

**Hyperdontia** , is the development of an increased number of teeth, and the additional teeth are termed supernumerary.

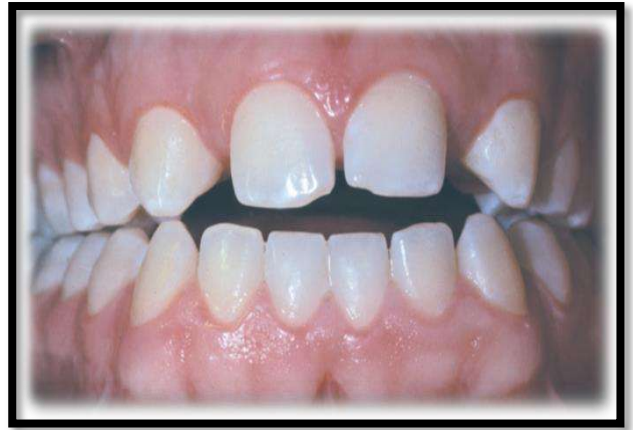**Anodontia** : Absence of teeth , when all teeth are missing.

**Pseudoanodontia** : when teeth are absent clinically because of impaction or delayed eruption.

**False anodontia** : when teeth have been exfoliated or extracted.

**Oligodontia** (a subdivision of hypodontia) indicates the lack of development of six or more teeth excluding third molars.

**Hypoanodontia:** Is relatively common. Congenitally missing teeth are usually [third molars](#), followed by [second premolars](#) and [maxillary lateral incisors](#).

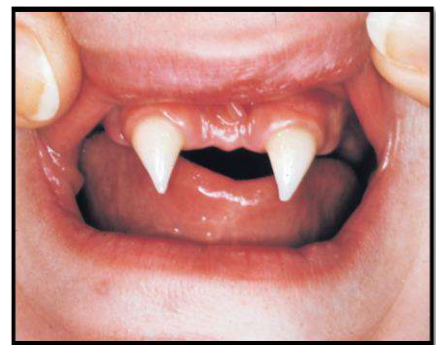
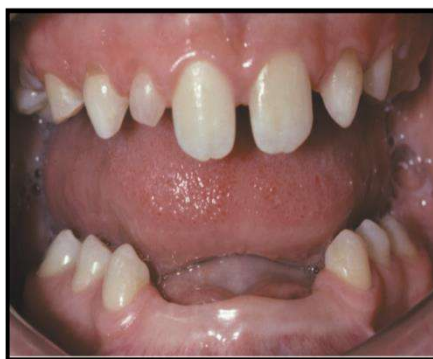
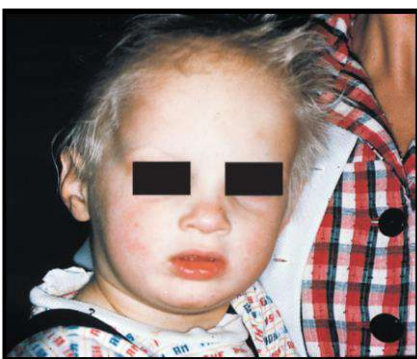Several regulatory genes are involved in tooth formation and development which may be mutated in hypodontia . Thus, hypodontia may be associated with other craniofacial anomalies and syndromes.

Hypodontia is more common in the permanent dentition, occurring in 2-10% in different population (excluding absent third molar) compared to the primary dentition where the prevalence is less than 1%. It is more common in females in racial differences

Hypodontia may be symmetrical when particular teeth or groups of teeth are involved or haphazard when the patient is discoverable. When the deciduous teeth to be congenitally absent, which is very unusual is likely that in such cases the permanent teeth will be also fail to form.

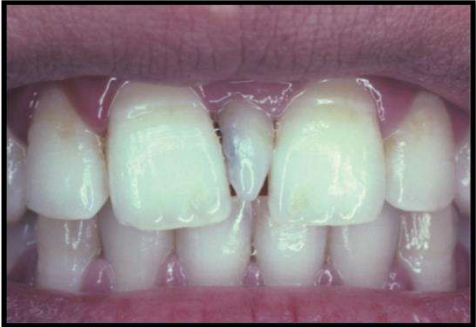**Complete anodontia** is rare but is often associated with a syndrome known as *hereditary ectodermal dysplasia*, which usually is transmitted as an X-linked recessive disorder. Partial anodontia is more typical of this syndrome, however. The few teeth that are present are usually conical. Hair, cutaneous appendages, and nails are also poorly developed in this syndrome.



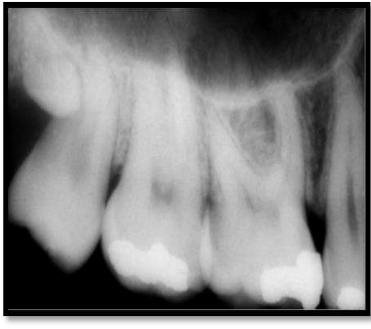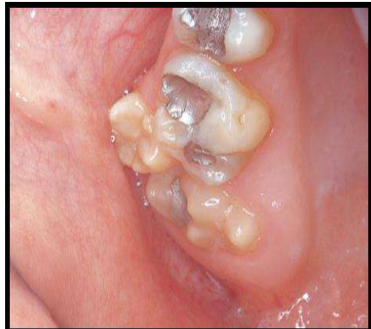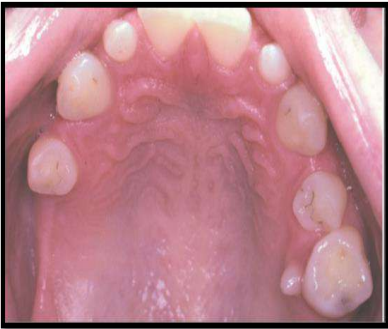
### **Hyperdontia (Supernumerary Teeth)**

Extra, or supernumerary, teeth in the dentition most probably result from continued proliferation of the permanent or primary dental lamina to form a third tooth germ. The resulting teeth may have a normal morphology or may be rudimentary and miniature.

Most are isolated events, although some may be familial and others may be syndrome associated (Gardner’s syndrome and cleidocranial dysplasia). Supernumerary teeth are found more often in the permanent dentition than in the primary dentition and are much more commonly seen in the maxilla than in the mandible. Mostly in the females than males .The anterior midline of the maxilla is the most common site, in which case the supernumerary tooth is known as a *mesiodens*.



The maxillary molar area is the second most common site ( distomolar or distodens) or situated lingually or buccally to a molar tooth is termed (paramolar ).



**Supernumerary teeth are divided into:**

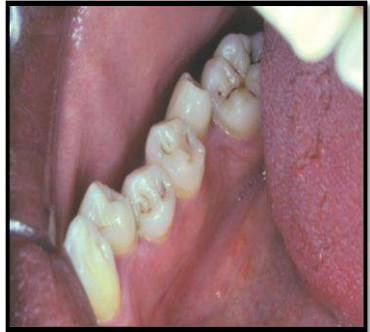- Supplemental (normal size and shape ).
- Rudimentary (abnormal shape and smaller size).

Another classification:

**Conical** (small, peg-shaped)

**Tuberculate** (barrel-shaped anterior with more than one cusp)

**Molariform** (small premolar-like or molar-like)



The significance of supernumerary teeth is that they occupy space. When they are impacted, they may block the eruption of other teeth, or they may cause delayed eruption or maleruption of adjacent teeth. If supernumerary teeth erupt, they may cause malalignment of the dentition and may be cosmetically objectionable.

Supernumerary teeth appearing after loss of the permanent teeth are known as *postpermanent dentition*. This is generally regarded as a rare event. Most teeth appearing after extraction of the permanent teeth are believed to arise from eventual eruption of previously impacted teeth.

### **Management**

The patient with hypodontia depends on the severity of the case . No treatment may be required for a single missing tooth . Prosthetic replacement often is needed when multiple teeth are absent. In some cases of hypodontia , orthodontic therapy may improve the restorative treatment.

The standard care in hyperdontia is removal of the accessory tooth during the time of the early mixed dentition to allow full eruption for permanent teeth.

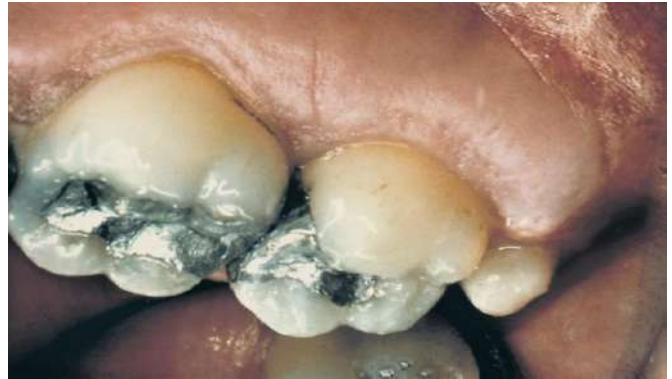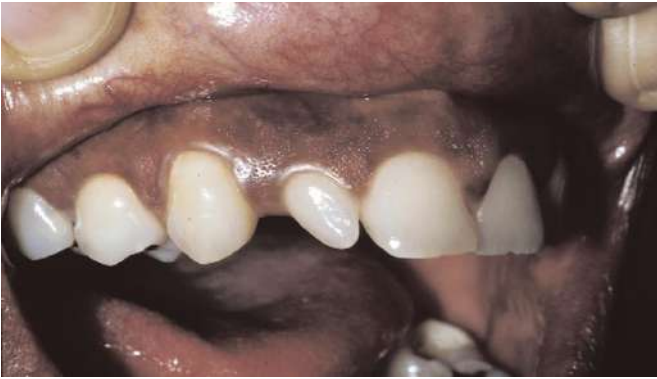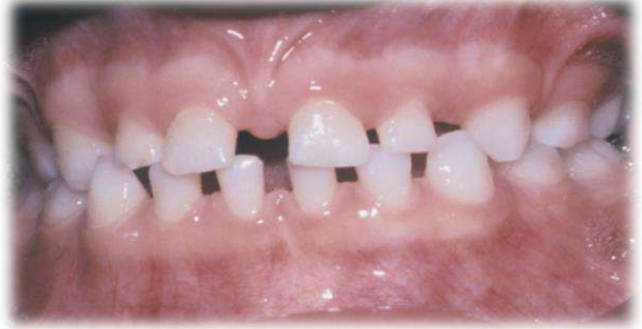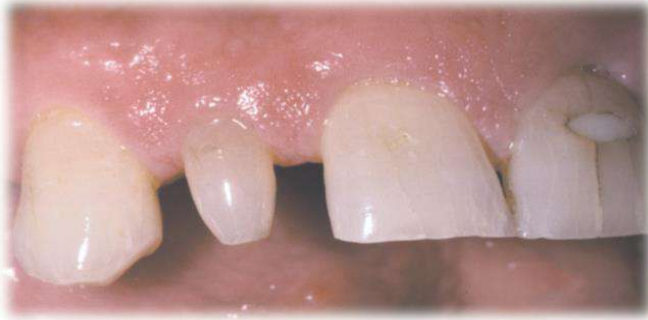Permanent teeth that fail to erupt are treated best by surgical exposure with orthodontic eruption.

### **Developmental Alterations in the Size of Teeth**

#### **Microdontia**

In *generalized microdontia*, all teeth in the dentition appear smaller than normal. Teeth may actually be measurably smaller than normal, as in pituitary dwarfism, or they may be relatively small in comparison with a large mandible and maxilla.

In *focal, or localized microdontia*, a single tooth is smaller than normal. The shape of these microdents is often altered with the reduced size. This phenomenon is most commonly seen with maxillary lateral incisors in which the tooth crown appears cone or peg shaped, prompting the designation *peg lateral*. An autosomal-dominant inheritance pattern has been associated with this condition. Peg laterals are of no significance other than cosmetic appearance. The second most commonly seen microdont is the maxillary third molar, followed by supernumerary teeth .



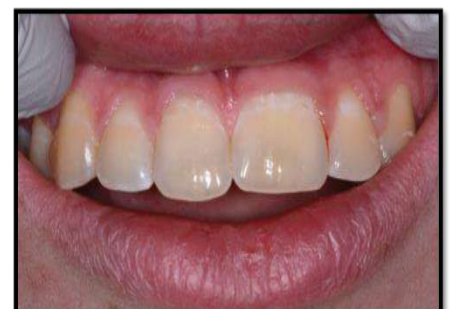## Macrodontia

**Generalized macrodontia** is characterized by the appearance of enlarged teeth throughout the dentition. This may be absolute, as seen in pituitary gigantism, or it may be relative owing to a disproportionately small maxilla and mandible. The latter results in crowding of teeth and possibly an abnormal eruption pattern caused by insufficient arch space.

**Focal, or localized, macrodontia** is characterized by an abnormally large tooth or group of teeth. This relatively uncommon condition usually is seen with mandibular third molars. In the rare condition known as *hemifacial hypertrophy*, teeth on the affected side are abnormally large compared with the unaffected side .

## Developmental Alterations in the Shape of Teeth

Disturbances in tooth form may involve the crown, the roots or both. The most frequent variations of the crowns of the teeth affect maxillary permanent lateral incisors which may be peg-shaped. Premolars and molars with an increased or decreased number of cusps are also frequently seen

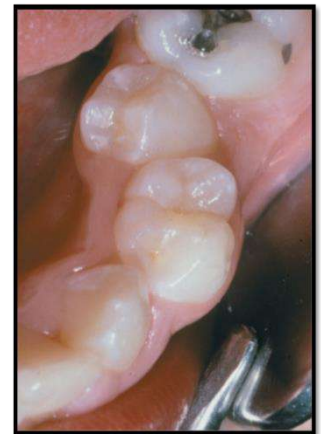
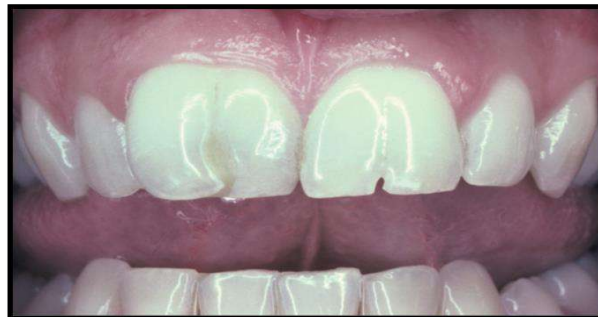
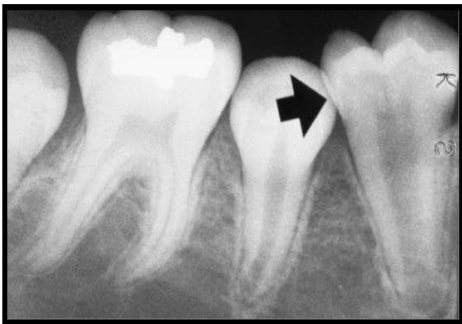**Double teeth:-** a descriptive term used to describe a developmental anomaly where two teeth appear joined together. This is variable and may involve the crown, roots, or both. The teeth are united by dentine or pulp. It occurs mostly in primary than permanent dentition especially anterior teeth. The etiology of double teeth remains unclear. A genetic basis has been suggested also double teeth should be differentiated from concrescence which is an acquired condition.

### **1-Gemination**

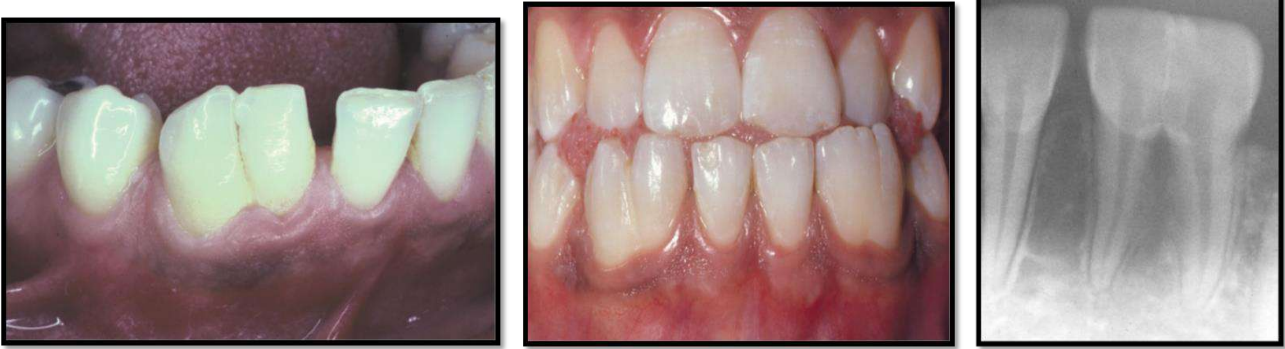Is defined as an attempt of a single tooth bud to divide, with the resultant formation of a tooth with a bifid crown and, usually, a common root and root canal. The typical result is partial cleavage, with the appearance of two crowns that share the same root canal.

Complete cleavage, or twinning, occasionally occurs, resulting in two teeth from one tooth germ. Although trauma has been suggested as a possible cause, the cause of gemination is unknown. These teeth may be cosmetically unacceptable and may cause crowding.



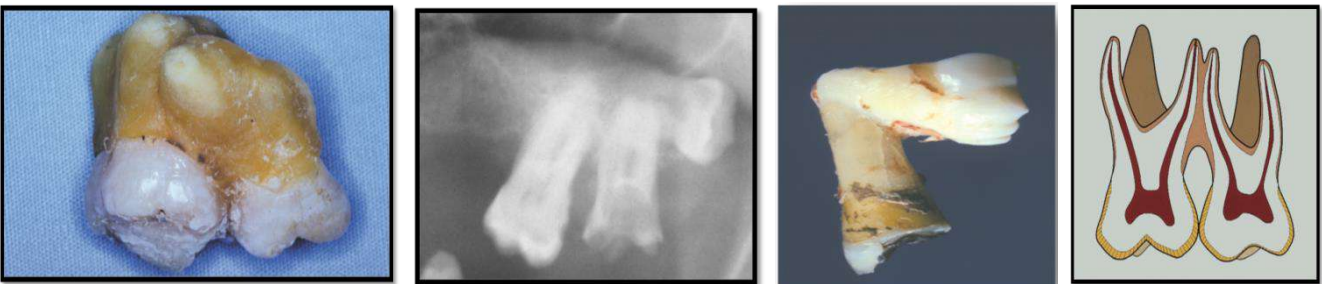
### **2-Fusion**

Is the joining of two developing tooth germs, resulting in a single large tooth structure. The fusion process may involve the entire length of the teeth, or it may involve the roots only, in which case cementum and dentin are shared. Root canals may also be separate or shared. It may be impossible to differentiate fusion of normal and supernumerary teeth from gemination. The cause of this condition is unknown, although trauma has been suggested.



### Concrecence:

Concrecence is an acquired union form in which adjacent, already formed teeth are joined by cementum only. This may take place before or after eruption of teeth and is believed to be related to trauma or overcrowding. Mostly seen in permanent than primary dentition. Concrecence is most commonly seen in association with the maxillary second and third molars. This condition is of no significance, unless one of the teeth involved requires extraction. Surgical sectioning may be required to save the other tooth.



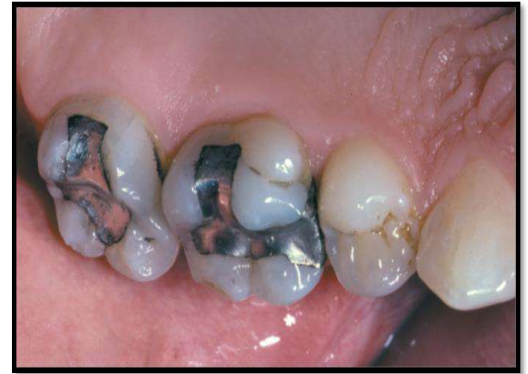### ACCESSORY CUSPS

The cuspal morphology of teeth exhibits minor variations among different populations; of these. Three distinctive patterns deserve further discussion:

- (1) Cusp of Carabelli.
- (2) Talon cusp.

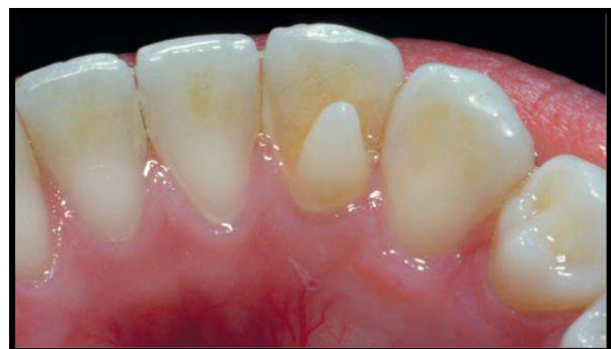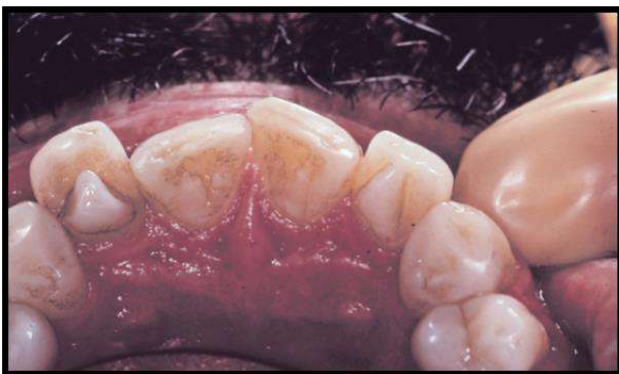
When an accessory cusp is present, the other permanent teeth often exhibit a slightly increased tooth size.

**1-The cusp of Carabelli** is an accessory cusp located on the palatal surface of the mesio lingual cusp of a maxillary molar. The cusp may be seen in the permanent or deciduous dentitions and varies from a definite cusp to a small indented pit or fissure. When present. The cusp is most pronounced on the first molar.



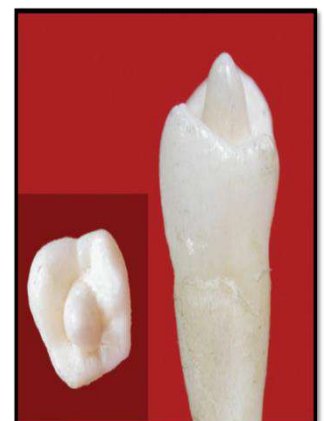An analogous accessory cusp is seen occasionally on the mesiobuccal cusp of a mandibular permanent or deciduous molar and is termed a protostylid.

**2-Talon cusp** A talon cusp (dens evaginatus of anterior tooth) is a well-delineated additional cusp that is located on the surface of an anterior tooth and extends at least half the distance from the cemento-enamel junction to the incisal edge. Three fourths of all reported talon cusps are located in the permanent dentition.



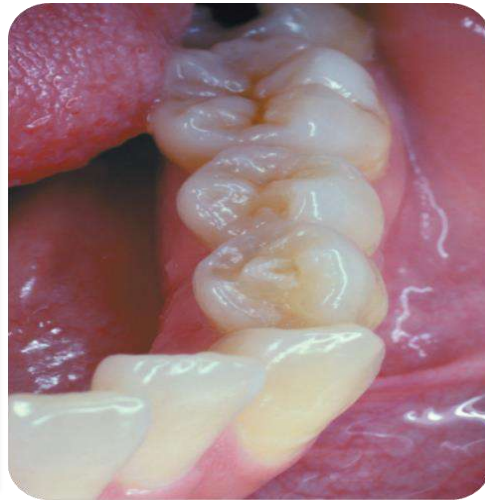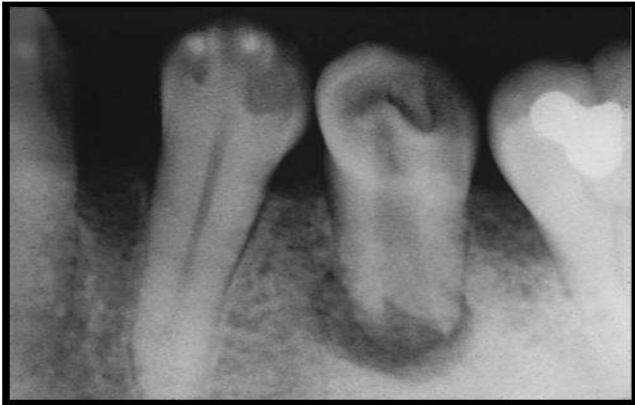**3-Dens Evaginatus** :- Is a relatively common developmental condition affecting predominantly premolar teeth (Leung's premolars).

It has been reported almost exclusively in Asians, Inuits, and Native Americans. The defect, which is often bilateral, is an anomalous tubercle, or cusp, located at the center of the occlusal surface. Because of occlusal abrasion, the tubercle wears relatively quickly causing early exposure of an accessory pulp horn that extends into the tubercle. This may result in periapical pathology in young, caries-free teeth, often





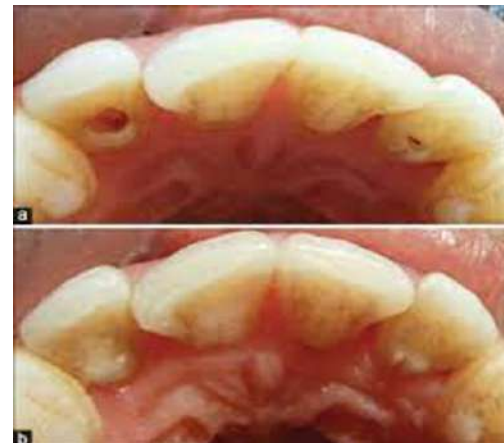before completion of root development and apical closure, making root canal fillings more difficult. Judicious grinding of the opposing tooth or the accessory tubercle to stimulate secondary dentin formation may prevent the periapical sequelae associated with this defect. Sealants, pulp capping, and partial pulpotomy have been suggested as measures to allow complete root development.



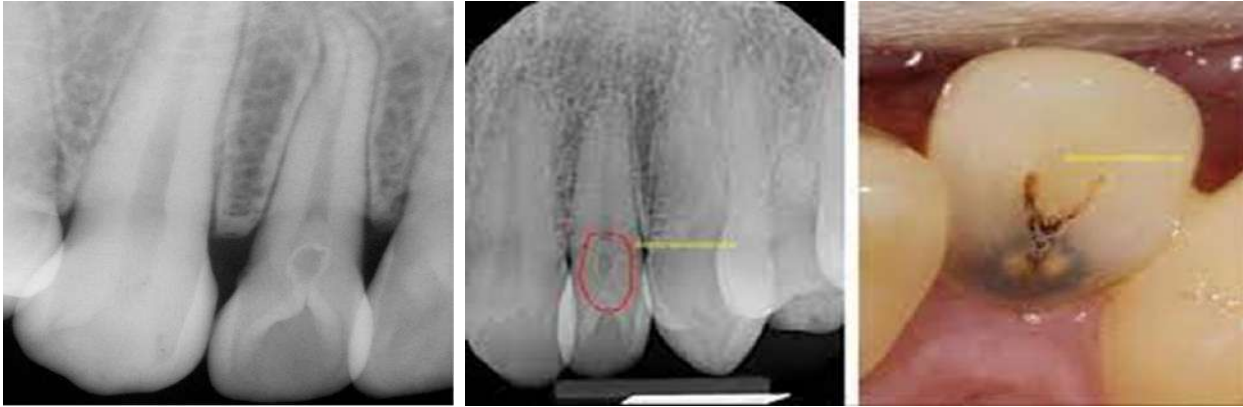**Dens Invaginatus :** Also known as **dens in dente** or tooth within a tooth arises as a result of invagination of a portion of enamel organ into the dental papilla at an early stage in odontogenesis before the formation of calcified tissue, dens invaginatus is an uncommon tooth anomaly that represents an exaggeration or accentuation of the lingual pit. This defect ranges in severity from superficial, in which only the crown is affected, to deep, in which both the crown and the root are involved.

The permanent maxillary lateral incisors are most commonly involved, although any anterior tooth may be affected. Bilateral involvement is commonly seen. The cause of this developmental condition is unknown. Genetic factors are believed to be involved in only a small percentage of cases.

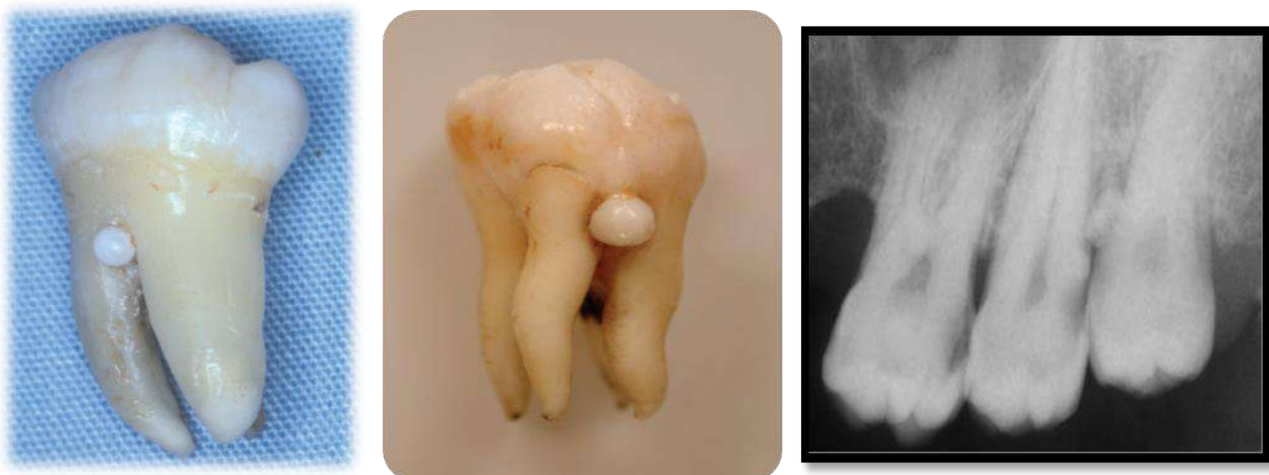
Because the defect cannot be kept free of plaque and bacteria, dens invaginatus predisposes the tooth to early decay and subsequent pulpitis. Prophylactic filling of the pit is recommended to avoid this complication. Because the defect



may often be identified on radiographic examination before tooth eruption, the patient can be prepared in advance of the procedure. In cases in which pulpitis has led to non-vitality, endodontic procedures may salvage the affected tooth.

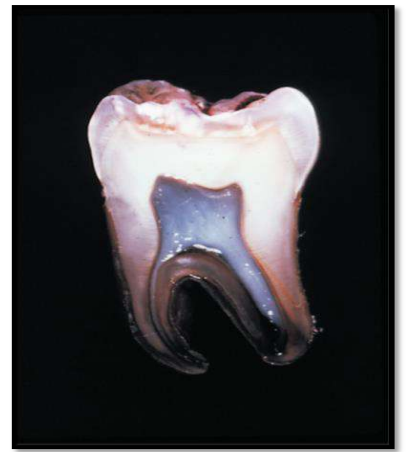

**Enamel Pearls (enameloma):** Droplets of ectopic enamel, or so-called enamel pearls, may occasionally be found on the roots of teeth. They occur most commonly in the bifurcation or trifurcation of teeth but may appear on single-rooted premolar teeth as well. Maxillary molars are more commonly affected than mandibular molars. These deposits are occasionally supported by dentin and rarely may have a pulp horn extending into them. This developmental disturbance of enamel formation may be detected on radiographic examination. It generally is of little significance except when located in an area of periodontal disease. In such cases, it may contribute to the extension of a periodontal pocket, because a periodontal ligament attachment would not be expected and hygiene would be more difficult.

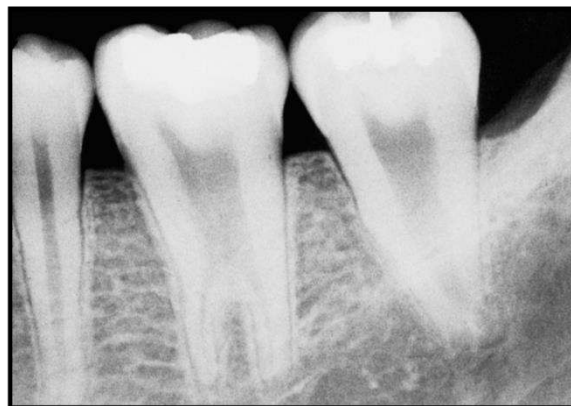
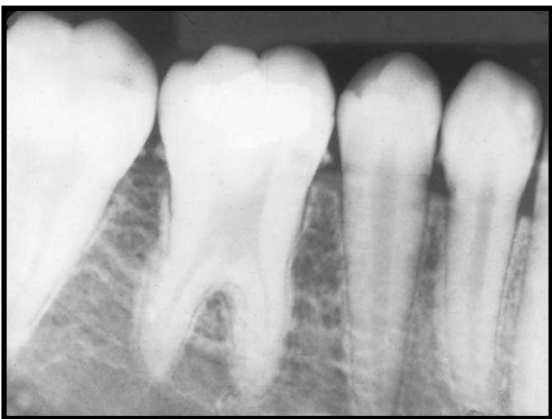
## Taurodontism

Taurodontism is a variation in tooth form in which teeth have elongated crowns or apically displaced furcations, resulting in pulp chambers that have increased apical-occlusal height. Because this abnormality resembles teeth in bulls and other ungulates, the term *taurodontism* was coined. Various degrees of severity may be seen, but subclassifications that have been developed to describe them appear to be of academic interest only.



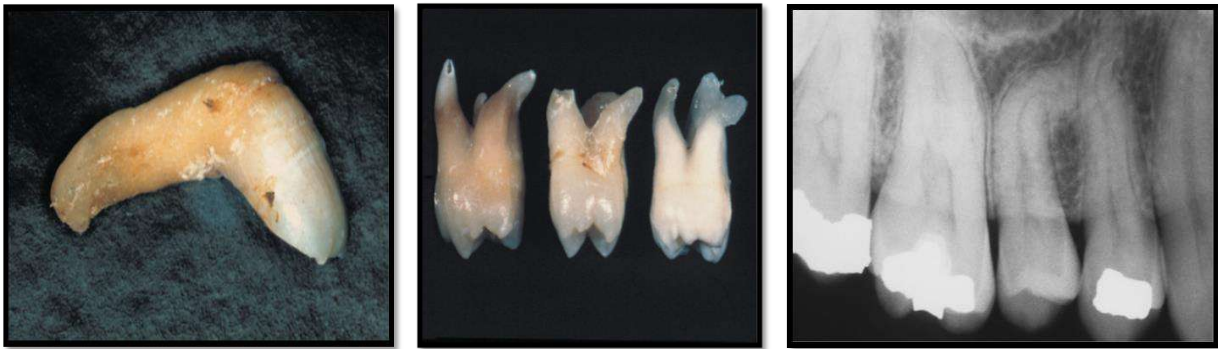Taurodontism may be seen as an isolated incident, in families, and in association with syndromes such as **Down syndrome** and **Klinefelter's syndrome**. Although taurodontism is generally an uncommon finding, it has been reported to have a relatively high prevalence in Eskimos, and incidence has been reported to be as high as 11% in a Middle Eastern population. Other than a possible relationship to other genetically determined abnormalities, taurodontism is of little clinical significance unless the tooth becomes nonvital, in which case it becomes a challenging endodontic problem. No treatment is required.



## Dilaceration

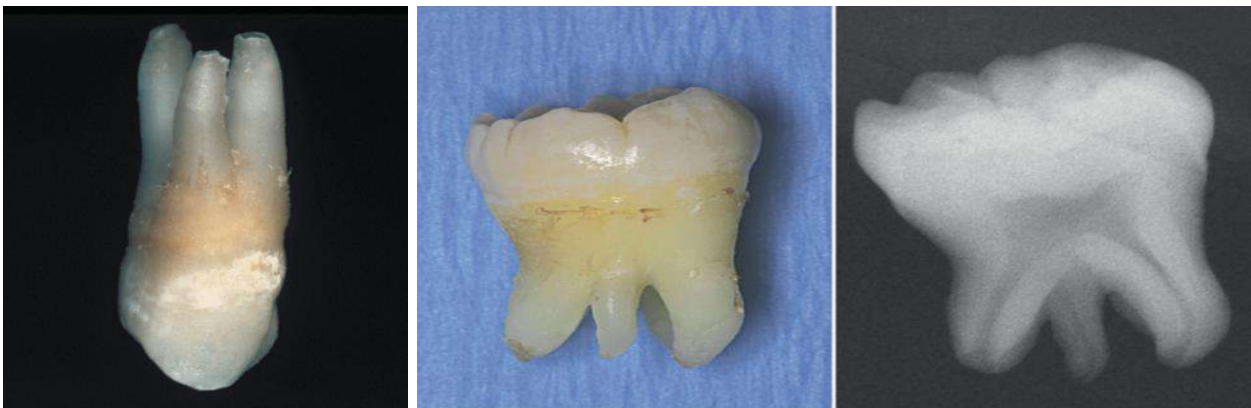A term used to describe a deformity in which the crown is displaced from its normal alignment with the root, so that the tooth is severely bent along its long axis. The cause of this condition has been related to trauma during root development. Movement of the crown or of the crown and part of the root from the remaining developing root may result

in sharp angulation after the tooth completes development. Hereditary factors are believed to be involved in a small number of cases. Eruption generally continues without problems. However, extraction may be difficult. Obviously, if root canal fillings are required in these teeth, the procedure is challenging.



### Supernumerary Roots

Accessory roots are most commonly seen in mandibular canines, premolars, and molars (especially third molars). They are rarely found in upper anterior teeth and mandibular incisors. Radiographic recognition of an extraordinary number of roots becomes important when extractions or root canal fillings are necessary.



### Localized Disturbances in Eruption

#### **I. Delayed eruption**

Refers to the first appearance of deciduous teeth relative to the normal age range.

This occurrence is relatively uncommon and is usually idiopathic or associated with certain systemic conditions such as rickets, cleidocranial dysplasia, or cretinism.

Local factors such as gingival fibromatosis, in which dense fibrous connective tissue impedes tooth eruption, can result in delayed eruption of the deciduous dentition.

Treatment of the systemic condition or the causative local factors may alleviate the eruption problem.

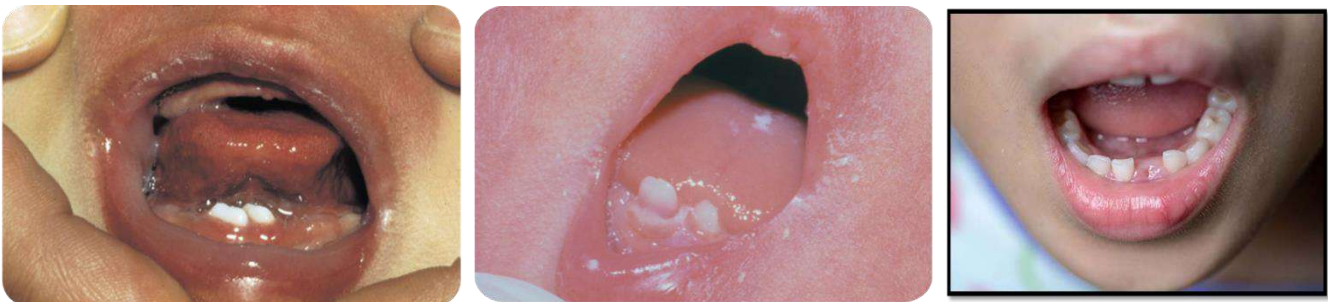## II. Premature Eruption

Premature eruption usually involves only one or two teeth, most commonly the deciduous mandibular central incisors.

**Natal teeth :** Teeth appearing at the time of birth.

**Neonatal teeth:** those appearing within 6 months following birth.

Most of these teeth represent prematurely erupted deciduous teeth, usually mandibular central incisors. A small percentage represent supernumerary teeth .Although the cause of this phenomenon is unknown, a familial pattern is sometimes observed. Prematurely erupted primary teeth should be preserved (If not cause injury to the infant or the mother).

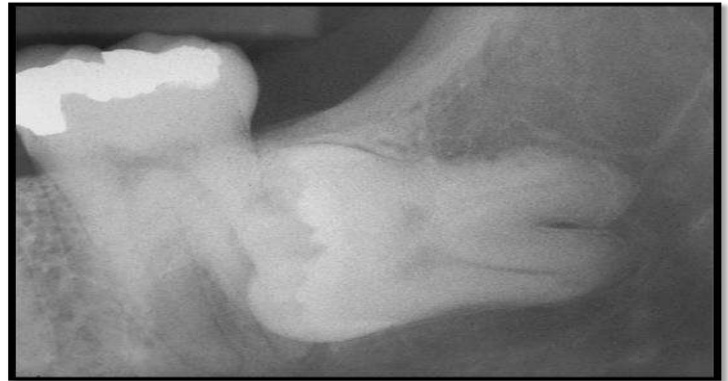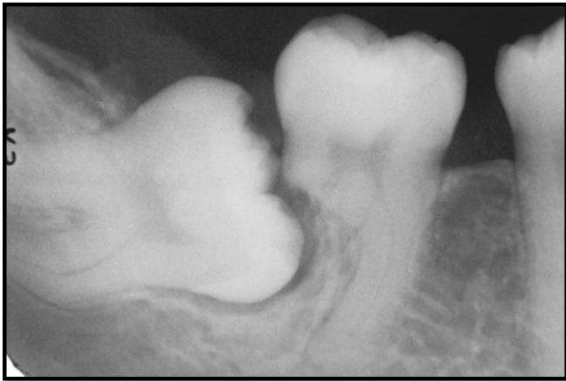


Premature eruption of permanent teeth is usually a consequence of premature loss of the preceding deciduous teeth . This becomes readily apparent when a single deciduous tooth has been prematurely lost . In the event that the entire permanent dentition is obviously erupting prematurely, the possibility of an endocrine dysfunction such as hyperthyroidism should be considered.

## Primary Impaction and Ankylosis

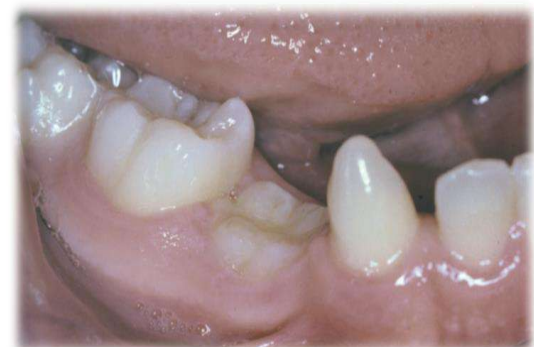**Impaction:** Impaction of teeth is a common event that most often affects the mandibular third molars and maxillary canines. Less commonly, premolars, mandibular canines, and second molars are involved. It is rare to see impactions of incisors and first molars. Impaction occurs because of obstruction from crowding or from some other physical barrier. Occasionally, it may be due to an abnormal eruption path, presumably caused by unusual orientation of the tooth germ.

*Ankylosis*, the fusion of a tooth to surrounding bone, is another cause of impaction. This usually occurs in association with erupted primary molars. It may result in impaction of a subjacent permanent tooth. The reason for ankylosis is unknown, but it is believed to be related to periapical inflammation and subsequent bone repair. With focal loss of the periodontal ligament, bone and cementum become inextricably mixed, causing fusion of the tooth to alveolar bone.



### Ankylosis:

Eruption continues after the emergence of the teeth to compensate for masticatory wear and the growth of the jaws. The cessation of eruption after emergence is termed ankylosis and occurs from an anatomic fusion of tooth cementum or dentin with the alveolar bone. Although the areas of union may be too subtle to be detected clinically and radiographically, histopathologic examination will demonstrate fusion between the affected tooth and the adjacent bone in almost all cases. Although any tooth may be affected, the most commonly involved teeth in order of frequency are the mandibular primary first molar, the mandibular primary second molar, the maxillary primary first molar, and the maxillary primary second molar. The reason for ankylosis is unknown, but it is believed to be related to periapical inflammation and subsequent bone repair. With focal loss of the periodontal ligament, bone and cementum become inextricably mixed, causing fusion of the tooth to alveolar bone. Other terms for this process within the literature include **infra occlusion, secondary retention submergence, Re impaction and re inclusion.**



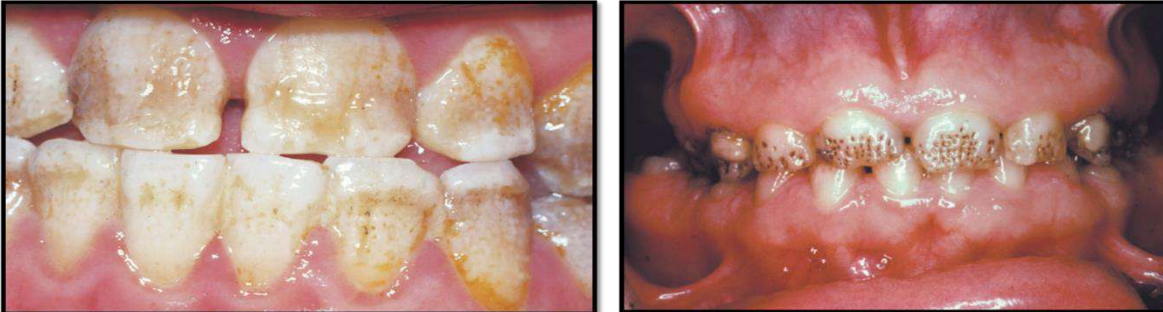
## *Developmental Alterations in the Structure of Teeth*

### Amelogenesis Imperfecta

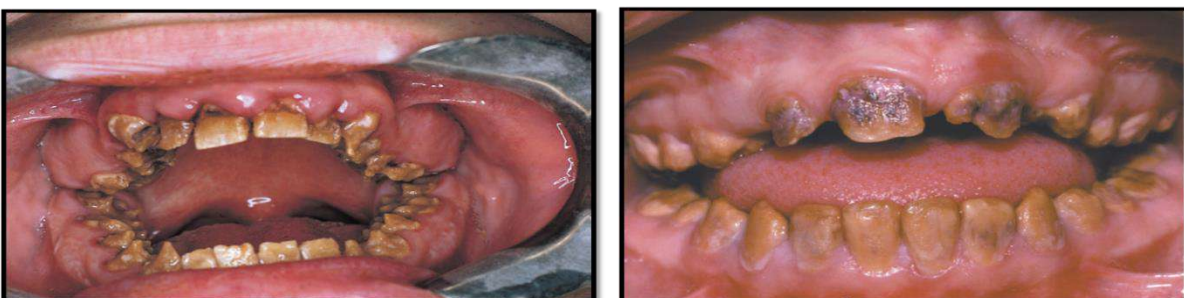
It is a clinically and genetically heterogeneous group of disorders of enamel formation that affect both dentitions. Most cases of amelogenesis imperfecta fall into one of two clinical types: *hypoplastic* or *hypocalcified*. A third type, known as *hypomaturation*, has been added to the list. Numerous subtypes of the three major groups are also recognized; these are based on different inheritance patterns, clinical appearances, and radiographic features.

Several genes that are involved in enamel formation (amelogenin, enamelin, kallikrein 4, MMP20, others) are mutated in various forms of this condition.

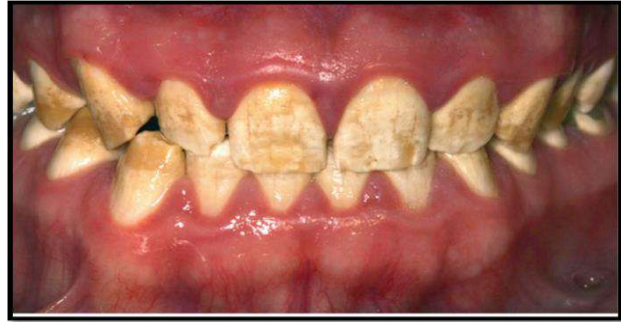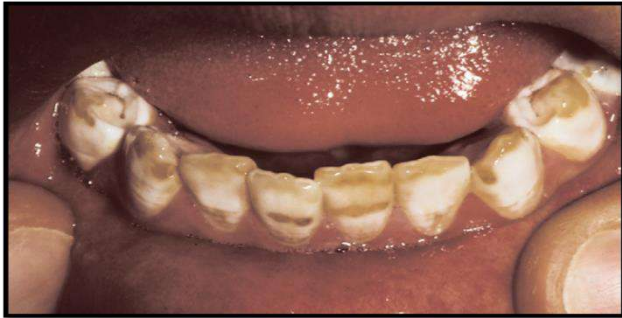
In the *hypoplastic* type of amelogenesis imperfecta, teeth erupt with insufficient amounts of enamel, ranging from pits and grooves in one patient to complete absence (aplasia) in another. Because of reduced enamel thickness in some cases, abnormal contour and absent interproximal contact points may be evident.



In the *hypocalcified* type, the quantity of enamel is normal, but it is soft and friable, so that it fractures and wears readily. The color of the teeth varies from tooth to tooth and from patient to patient—from white opaque to yellow to brown. Teeth also tend to darken with age as a result of exogenous staining.

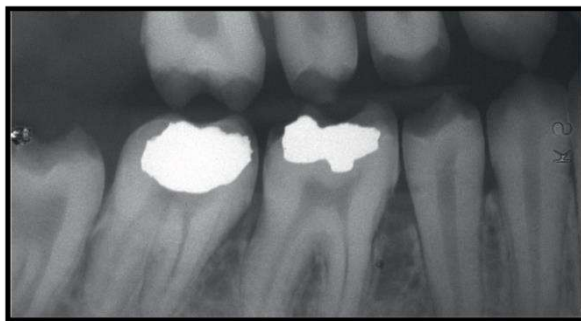
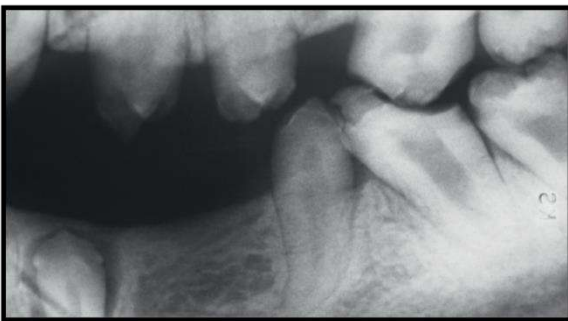

The hypomaturation type, which exhibits a less severe alteration in mineralization, the enamel is of normal thickness but not of normal hardness and translucency, enamel can be pierced with the point of a dental explorer with firm pressure and can be chipped away from the underlying normal dentin.



Radiographically, enamel appears reduced in bulk, often showing a thin layer over occlusal and interproximal surfaces. Dentin and pulp chambers appear normal. Although the enamel is soft and irregular, teeth are not caries prone.

Treatment focuses on esthetics and protection of tooth tissue. Restorative dental procedures at an early age not only preserve teeth but have a significant effect on the patient's self-esteem.



## DEFECTS OF DENTIN

### Dentinogenesis Imperfecta

It is an autosomal-dominant trait with variable expressivity. Mutations in the dentin sialoprotein gene have been described. It typically affects the dentin of both primary and permanent dentitions. Because of the clinical discoloration of teeth, this condition has also been known as (hereditary) *opalescent dentin*.



Dentinogenesis imperfecta has been divided into three types.

**1-Type I or syndrome-associated**, in which the dentin abnormality occurs in patients with concurrent osteogenesis imperfecta, primary teeth are more severely affected than permanent teeth.

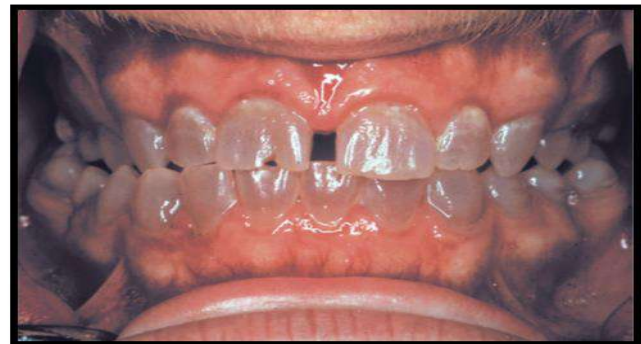
**2- Type II**, patients have only dentin abnormalities and no bone disease.

**3-Type III or the Brandywine type**, only dental defects occur. This type is similar to type II, but has some clinical and radiographic variations. Features of type III that are not seen in type I and II include multiple pulp exposures, periapical radiolucencies, and a variable radiographic appearance.

Dentinogenesis imperfecta type I (syndromal dentinogenesis imperfecta) is caused by mutations in the genes that encode collagen type I. Dentinogenesis imperfecta types II and III, on the other hand, have been shown to be related to mutations in a gene known as dentin sialophosphoprotein that encodes non-collagen proteins of dentin. Other genes that encode dentin proteins, such as osteopontin, do not appear to be mutated in dentinogenesis imperfecta.

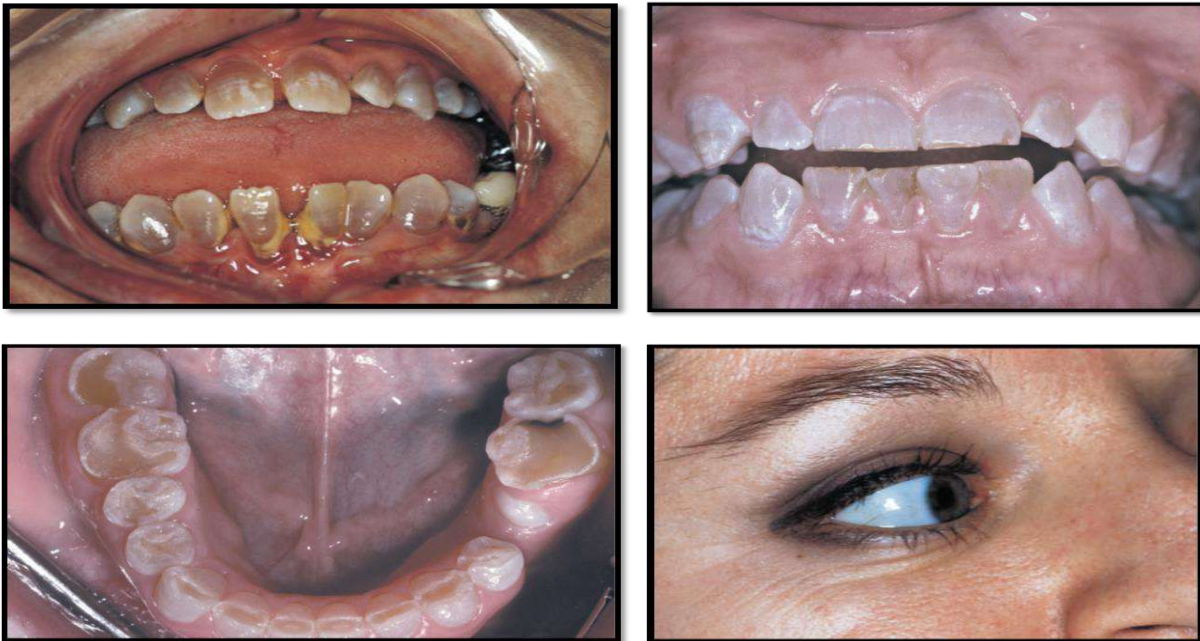
### **Clinically**

All three types share numerous features. In both dentitions, the teeth exhibit an unusual translucent, opalescent appearance, with color variation from yellow-brown to gray. The entire crown appears discolored because of the abnormal underlying



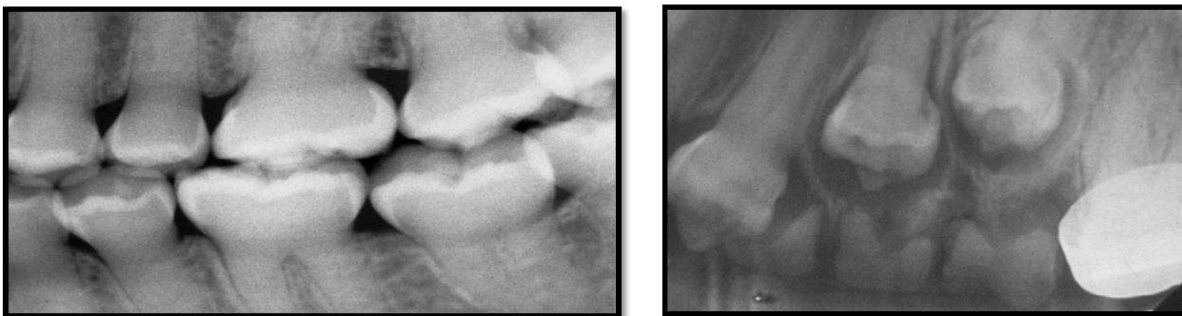
dentin. Although the enamel is structurally and chemically normal, it fractures easily, resulting in rapid wear. The enamel fracturing is believed to be due to the poor support provided by abnormal dentin, and possibly in part to the absence of the microscopic scalloping normally seen between dentin and enamel, which is believed to help mechanically lock the two hard tissues together. Overall tooth morphology is unusual for its excessive constriction at the cement-enamel junction, giving the crowns a tulip or bell shape. Roots are shortened and blunted. The teeth do not exhibit any greater susceptibility

to caries, and they may in fact show some resistance because of the rapid wear and absence of interdental contacts.

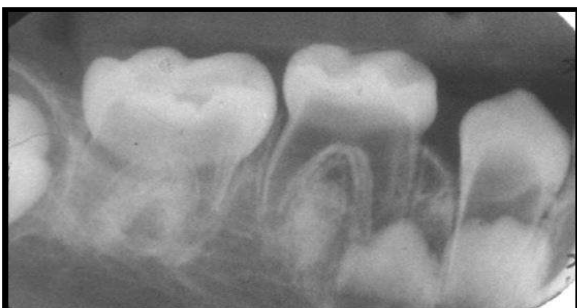

### Radiographically

Types I and II exhibit identical changes. Opacification of dental pulps occurs as the result of continued deposition of abnormal dentin. The short roots and the bell-shaped crowns are also obvious on radiographic examination.



In type III, the dentin appears thin and the pulp chambers and root canals extremely large, giving the appearance of thin dentin shells—hence the previous designation of *shell teeth*.



### **Microscopically**

The dentin of teeth in dentinogenesis imperfecta contains fewer, but larger and irregular, dentinal tubules. The pulpal space is nearly completely replaced over time by irregular dentin. Enamel appears normal, but the dentinoenamel junction is smooth instead of scalloped.

### **Treatment**

Directed toward protecting tooth tissue from wear and toward, thereby improving the esthetic appearance of the teeth. Generally, fitting with full crowns at an early age is the treatment of choice. Despite the qualitatively poor dentin, support for the crowns is adequate. These teeth should not be used as abutments because the roots are prone to fracture under stress.

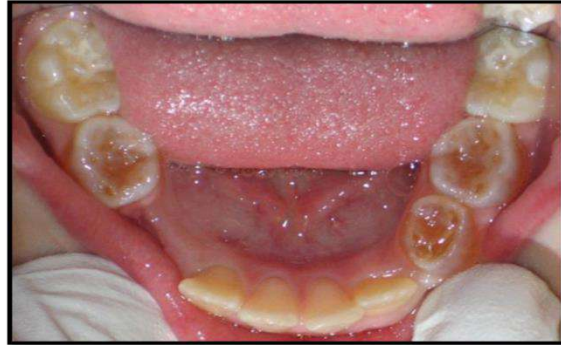
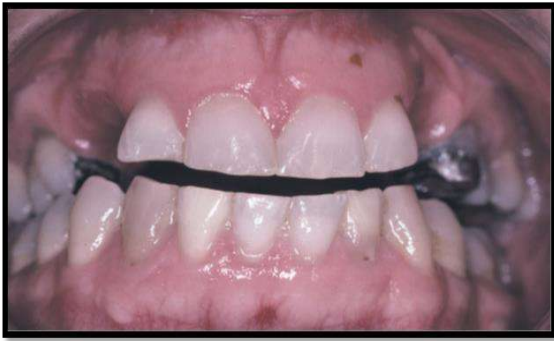### **Dentin Dysplasia**

Dentin dysplasia, subdivided into types I and II, is another autosomal-dominant condition that affects dentin. The incidence of this rare disorder is approximately 10 times less than that of dentinogenesis imperfecta. As in dentinogenesis imperfecta II and III, genetic mutations occur in the dentin sialophosphoprotein gene in dentin dysplasia type II. Genetic lesions have yet to be elucidated in dentin dysplasia type I.

In dentin dysplasia type II, the color of the primary dentition is opalescent and the permanent dentition is normal; in type I, both dentitions are of normal color. The coronal pulps in type II are usually large (thistle tube appearance) and are filled with globules of abnormal dentin. Also, periapical lesions are not a regular feature of type II, as they are of type I.

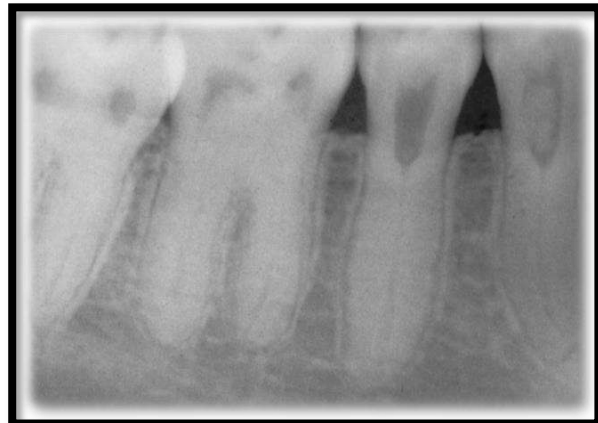
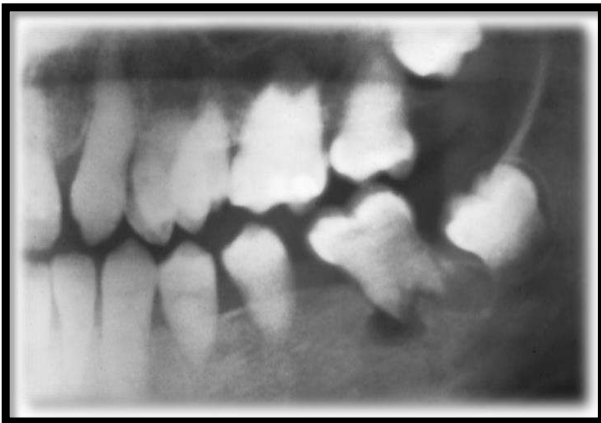
### **Clinically**

The crowns in dentin dysplasia type I appear to be normal in color and shape. Premature tooth loss may occur because of short roots or periapical inflammatory lesions. Teeth show greater resistance to caries when compared with normal teeth.



### **Radiographically**

In dentin dysplasia type I, roots appear extremely short and pulps are almost completely obliterated. Residual fragments of pulp tissue appear typically as horizontal lucencies (chevrons). Periapical lucencies are typically seen; they represent chronic abscesses, granulomas, or cysts. In dentin dysplasia type II, deciduous teeth are similar in radiographic appearance to those in type I, but permanent teeth exhibit enlarged pulp chambers that have been described as thistle tube in appearance.



### **Treatment**

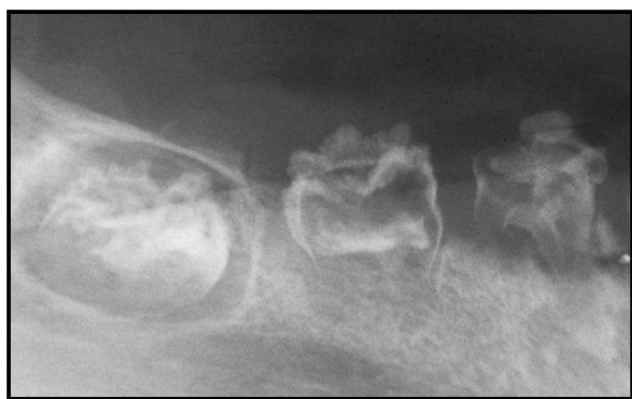
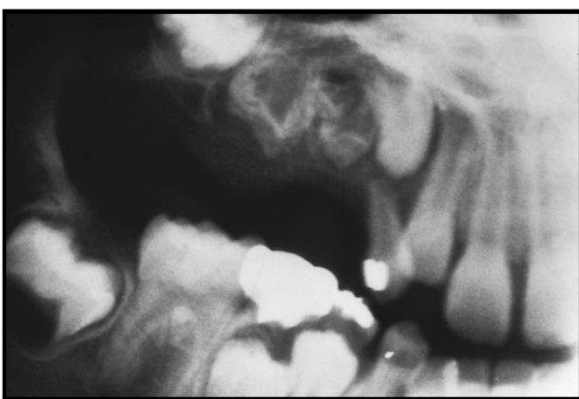
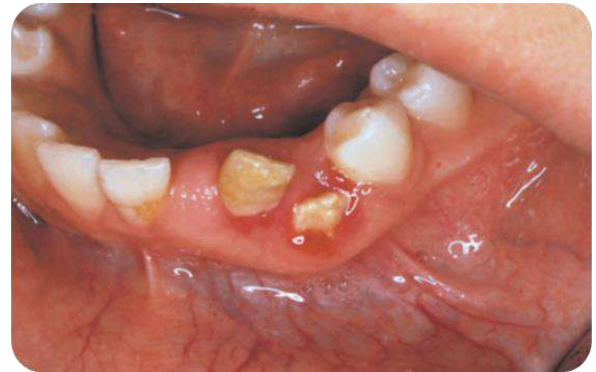
Directed toward retention of teeth for as long as possible. However, because of the short roots and periapical lesions, the prognosis for prolonged retention is poor. This dental condition has not been associated with any systemic connective tissue problems.

## ***DEFECTS OF ENAMEL AND DENTIN***

### **Regional Odontodysplasia**

Regional odontodysplasia is a dental abnormality that involves the hard tissues derived from both epithelial (enamel) and mesenchymal (dentin and cementum) components of the tooth-forming apparatus. The teeth in a region or quadrant of the maxilla or mandible are affected to the extent that they exhibit short roots, open apical foramina, and enlarged pulp chambers. The thinness and poor mineralization quality of the enamel and dentin layers have given rise to the term *ghost teeth*. One or both dentitions may be affected. The permanent teeth are more affected than the primary teeth, and the maxillary anterior teeth are more affected than other teeth. Eruption of the affected teeth is delayed or does not occur.

The cause of this rare dental abnormality is unknown, although numerous causative factors have been suggested, including trauma, nutritional deficiency, infection, metabolic abnormality, systemic disease, local vascular compromise, and genetic influences. Because of the poor quality of the affected teeth, their removal is usually indicated. The resulting edentulous zone can then be restored with a prosthesis or implant.



## ***ENVIRONMENTAL EFFECTS ON TOOTH STRUCTURE DEVELOPMENT***

### **DEFECTS OF ENAMEL**

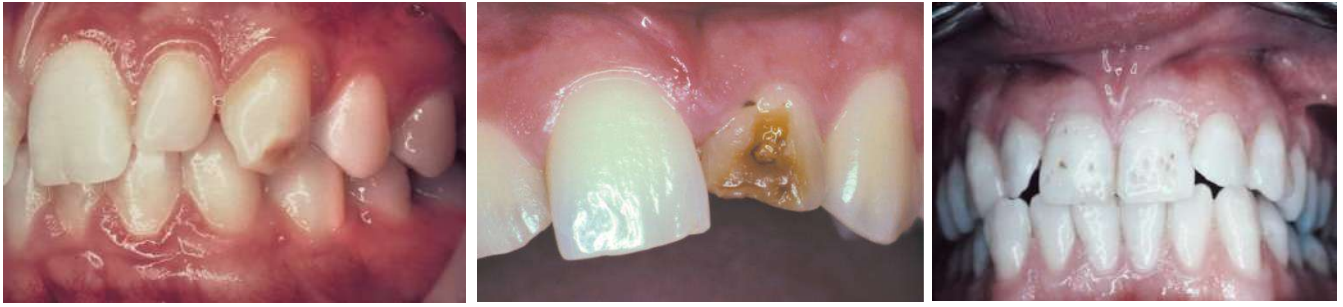#### **Environmental Defects of Enamel**

During enamel formation, ameloblasts are susceptible to various external factors that may be reflected in erupted teeth. Metabolic injury, if severe enough and long enough, can cause defects in the quantity and shape of enamel or in the quality and color of enamel. Quantitatively defective enamel, when of normal hardness, is known as *enamel hypoplasia*. Qualitatively defective enamel, in which normal amounts of enamel are produced but are hypomineralized, is known as *enamel hypocalcification*. In this defect, the enamel is softer than normal. The extent of the enamel defect is dependent on three conditions:

- 1- The intensity of the causative factor.
- 2- The duration of the factor's presence.
- 3- The time at which the factor occurs during crown development.

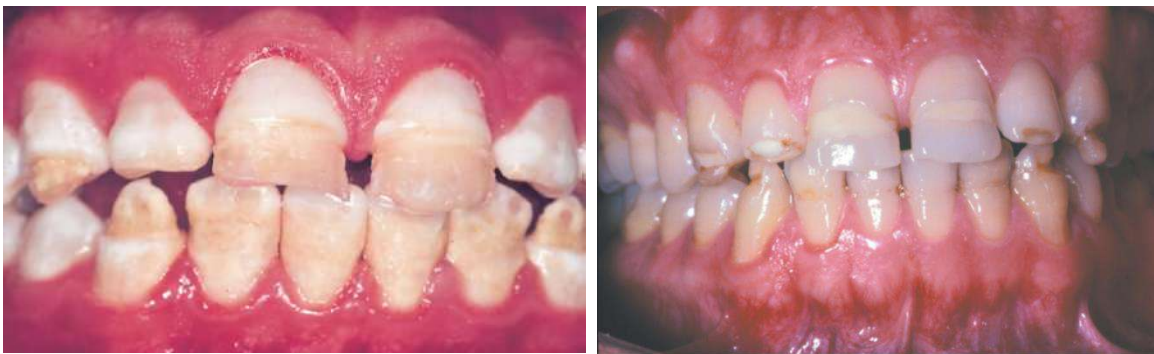Factors that lead to ameloblast damage are highly varied, although the clinical signs of defective enamel are the same.

Causative factors may occur locally (focal hypoplasia), affecting only a single tooth, or they may act systemically (generalized hypoplasia), affecting all teeth in which enamel is being formed. Local trauma or abscess formation can adversely affect the ameloblasts overlying a developing crown, resulting in enamel hypocalcification or hypoplasia. Affected teeth may have areas of coronal discoloration, or they may have actual pits and irregularities. This is most commonly seen in permanent teeth in which the overlying deciduous tooth becomes abscessed or is physically forced into the enamel organ of the permanent tooth. The resulting hypoplastic or hypocalcified permanent tooth is sometimes known as *Turner's tooth* (Turners hypoplasia).

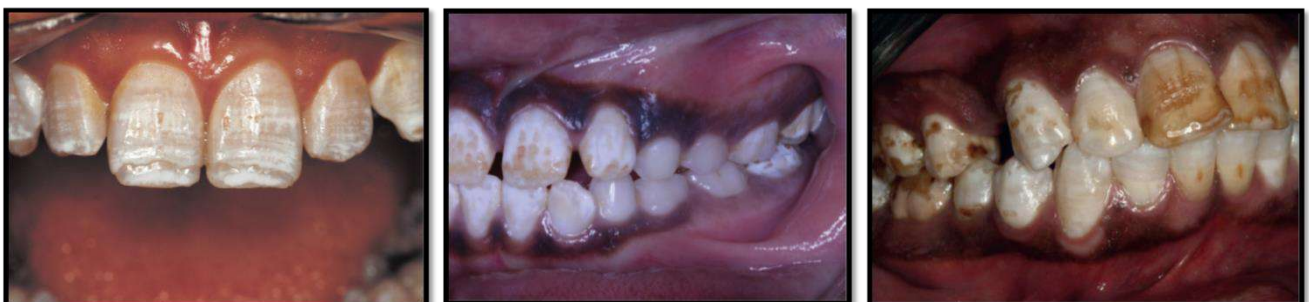

Short-term systemic environmental factors inhibit functioning ameloblasts at a specific period during tooth development and are manifested clinically as a horizontal line of small pits or grooves on the enamel surface that correspond to the time of development and the duration of the insult.

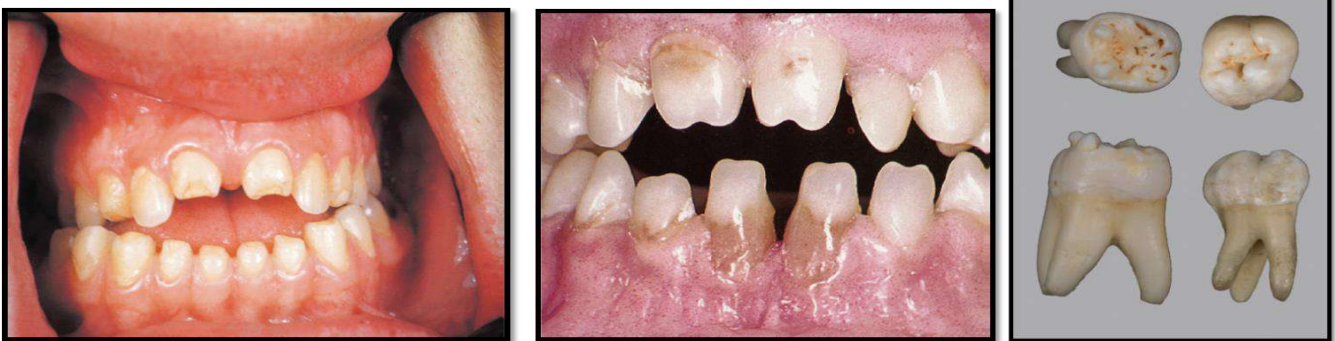
If the duration of the environmental insult is brief, the line of hypoplasia is narrow, whereas a prolonged insult produces a wider zone of hypoplasia and may affect more teeth.



**Dental fluorosis.** The ingestion of excess amounts of fluoride also can result in significant enamel defects known as dental fluorosis. Although the fluoride produced an unusual permanent dental stain, a resistance to caries also was noted. It was discovered that fluoride in the water at 1.0 ppm reduced caries by 50% to 70%. In addition, this level of fluoride in the water supply was associated with a low and mostly mild prevalence of mottled enamel.



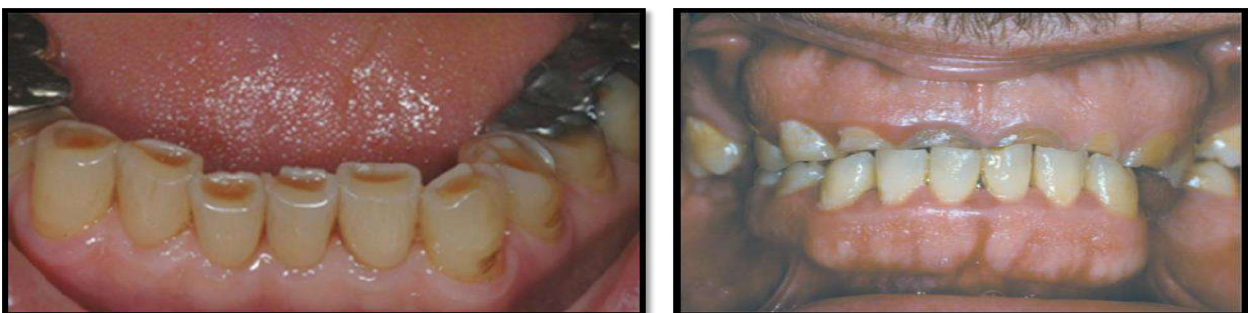**Syphilitic hypoplasia.** Congenital syphilis results in a pattern of enamel hypoplasia that is well known but currently so rare that lengthy discussion is not warranted. Anterior teeth altered by syphilis are termed **Hutchinson's incisors** and exhibit crowns that are shaped like straight-edge screw drivers. With the greatest circumference present in the middle one third of the crown and a constricted incisal edge. The middle portion of the incisal edge often demonstrates a central hypoplastic notch. Altered posterior teeth are termed **mulberry molars** and demonstrate constricted occlusal tables with a disorganized surface anatomy that resembles the bumpy surface of a mulberry.



### **Post developmental Loss of Tooth**

Attrition, Abrasion, Erosion and Abfraction

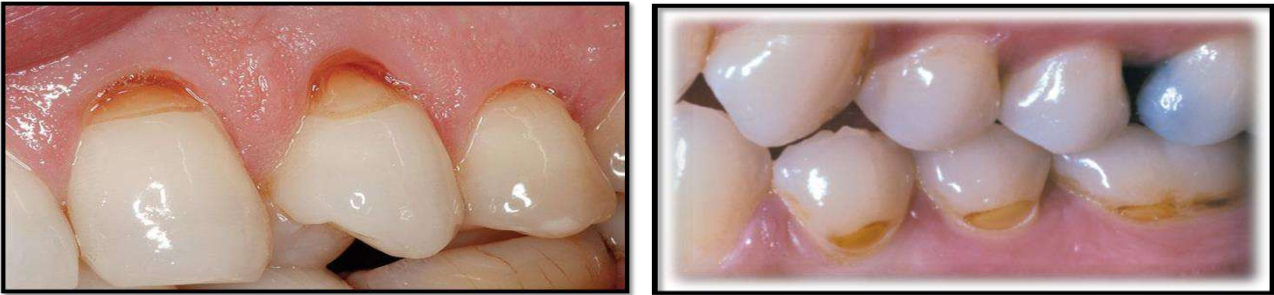**Attrition:** Is the physiologic wearing of teeth as a result of mastication. It is an age-related process that varies from one individual to another. Factors such as diet, dentition, jaw musculature, and chewing habits can significantly influence the pattern and extent of attrition.



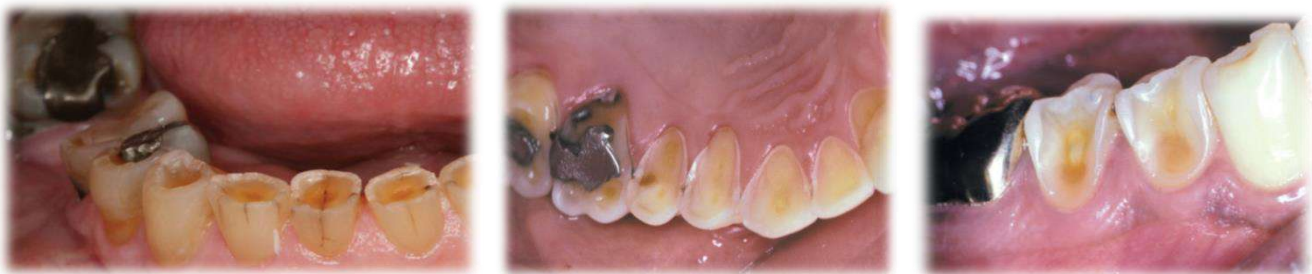**Abrasion** : Is the pathologic wearing of teeth caused by an abnormal habit or abnormal use of abrasive substances orally. Pipe smoki smoking, tobacco chewing, aggressive tooth brushing, and use of abrasive dentifrices are among the more common causes.



The location and pattern of abrasion are directly dependent on the cause, with so-called toothbrush abrasion along the cemento-enamel junction an easily recognized pattern.

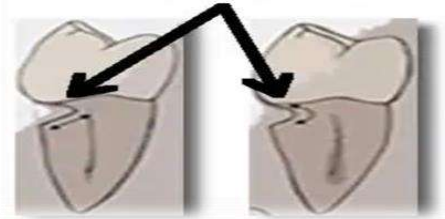


**Erosion:** Is the loss of tooth structure through a non-bacterial chemical process. Most commonly, acids are involved in the dissolution process from an external or an internal source. Externally, acid may be found in the work environment (e.g., battery manufacturing) or in the diet (e.g., citrus fruits, acid-containing soft drinks). The internal source of acid is most probably regurgitation of gastric contents. This may be seen in any disorder of which chronic vomiting is a part. Self-induced vomiting, as a component of bulimia or, less commonly, anorexia nervosa, has become an increasingly important cause of dental erosion and other oral abnormalities. The pattern of erosion associated with vomiting is usually generalized tooth loss on the lingual surfaces of maxillary teeth. However, all surfaces may be affected, especially in individuals who compensate for fluid loss by excessive intake of fruit juices. In many cases of tooth erosion, no cause is found.

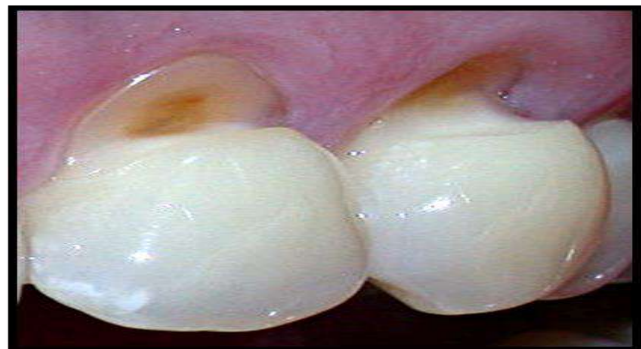
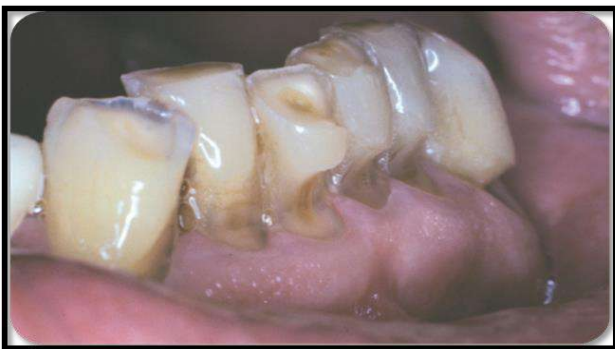
**Abfraction:** loss of tooth from occlusal stress that create repeated tooth flexure with failure of enamel and dentin at a location away from the point of locking, it appears as wedge-shaped defects limited to the cervical area of the teeth and may closely resemble cervical abrasion or erosion. Clues to the diagnosis include defects that are deep, narrow, and V-shaped (which do not allow the tooth brush to contact the base of the

## Tooth Abfraction



defect) and often affect a single tooth with adjacent unaffected teeth. In addition Occasional lesions are subgingival, a site typically protected from abrasion and erosion. The lesions are seen almost exclusively on the facial surface and exhibit a much greater prevalence in those with bruxism. A higher frequency is noted in the mandibular dentition, presumably because the lingual orientation makes them more susceptible to the concentration of tensile stresses at the cervical regions.

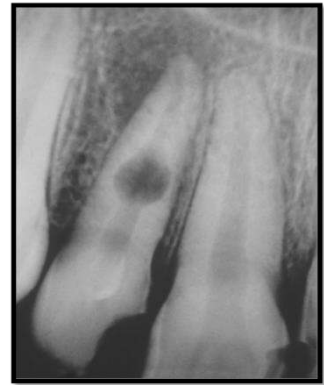
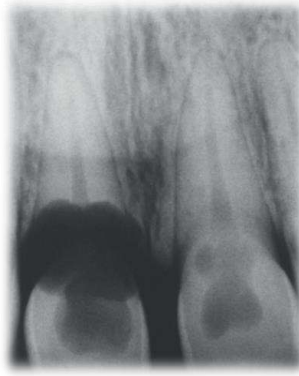
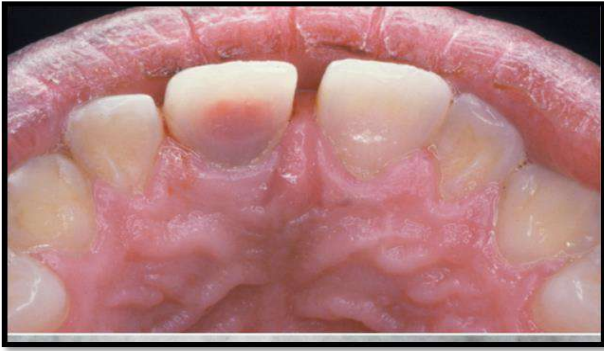## Internal and External Resorption

- **Internal Resorption**

Resorption of the dentin of the pulpal walls may be seen as part of an inflammatory response to pulpal injury, or it may be seen in cases in which no apparent trigger can be identified. The resorption occurs as a result of activation of osteoclasts or dentinoclasts on internal surfaces of the root or crown. Resorption lacunae containing these cells and chronic inflammatory cells are seen. Reversal lines may also be found in adjacent hard tissue, indicating attempts at repair. In time, the root or crown is perforated by the process, making the tooth useless.

Any tooth may be involved, and usually only a single tooth is affected, although cases in which more than one tooth is involved have been described. In advanced cases, teeth may appear pink because of the proximity of pulp tissue to the tooth surface. Until root fracture or communication with a periodontal pocket occurs, patients generally have no symptoms.



The treatment of choice is root canal therapy before perforation. Once communication between pulp and periodontal ligament occurs, the prognosis for saving the tooth is very poor. Occasionally, the process may spontaneously stop for no apparent reason.

- **External Resorption**

Resorption of teeth from external surfaces may have one of several causes. This change may be the result of an adjacent pathologic process, such as

- (1) Chronic inflammatory lesions
- (2) Cysts
- (3) Benign tumors
- (4) Malignant neoplasms.

The pathogenesis of external resorption from these causes has been related to the release of chemical mediators, increased vascularity, and pressure.

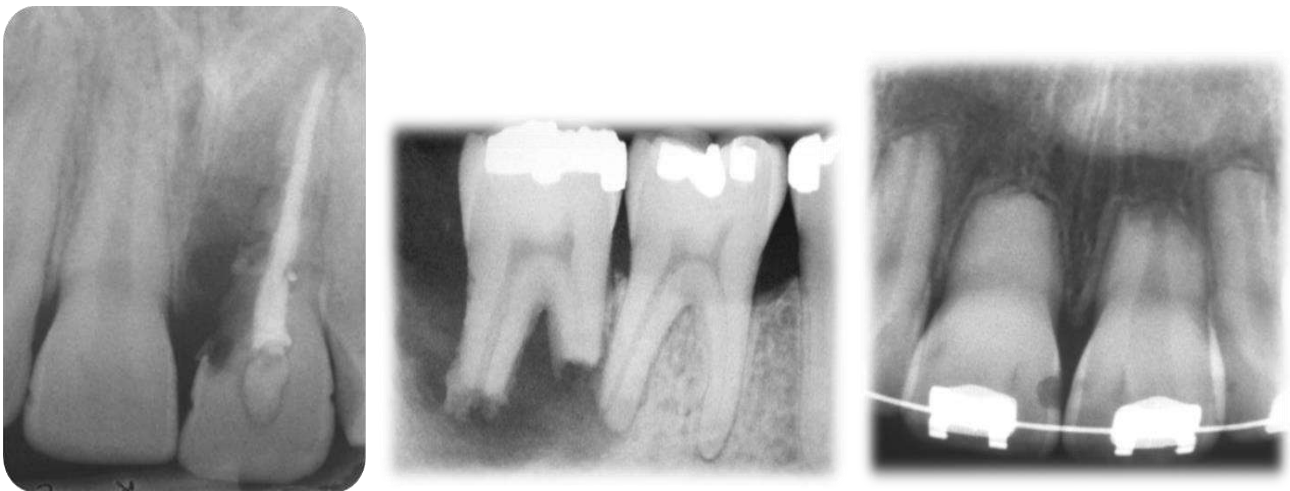
External resorption of teeth may also be seen in association with

- (1) Trauma
- (2) Reimplantation or transplantation of teeth
- (3) Impaction.

Trauma that causes injury to or necrosis of the periodontal ligament may initiate resorption of tooth roots. This trauma may result from a single event, from malocclusion, or from excessive orthodontic forces. Because reimplanted and transplanted teeth are nonvital and have no surrounding viable periodontal ligament, they eventually are resorbed and replaced by bone. This is basically a natural physiologic

process in which the calcified collagen matrix of the tooth serves as a frame-work for the deposition of new, viable bone. Impacted teeth, when they impinge or exert pressure on adjacent teeth, may cause root resorption of the otherwise normally erupted tooth. Impacted teeth themselves occasionally may undergo resorption. The cause of this phenomenon is unknown, although it is believed to be related to partial loss of the protective effect of the periodontal ligament or reduced enamel epithelium.

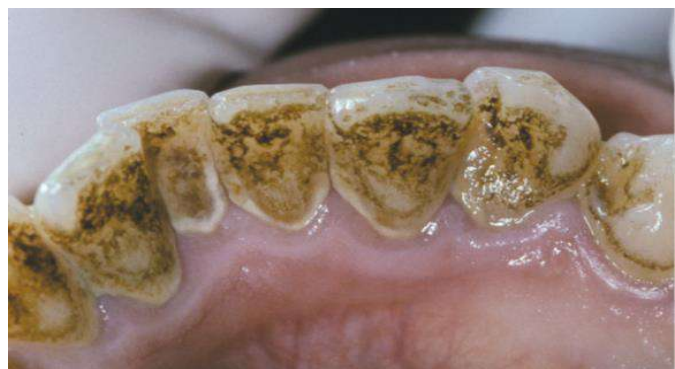Finally, external resorption of erupted teeth may be idiopathic. This may occur in one or more teeth. Any tooth may be involved, although molars are least likely to be affected . External resorption eventually causes loss of the affected teeth.



## **Environmental Discoloration of Teeth**

### **Exogenous Stains**

Stains on the surfaces of teeth that can be removed with abrasives are known as exogenous or extrinsic stains. The color change may be caused by pigments in dietary substances (e.g., coffee, “betel” areca nut, tobacco) or by the colored by-products of chromogenic bacteria in dental plaque. Chromogenic bacteria are believed to be responsible for brown, black, green, and orange stains observed predominantly in children. Brown and black stains typically are seen in the cervical zone of teeth, either as a thin line along

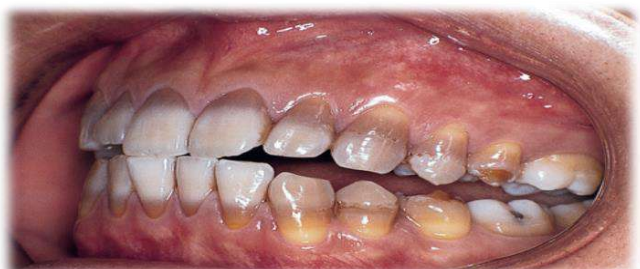
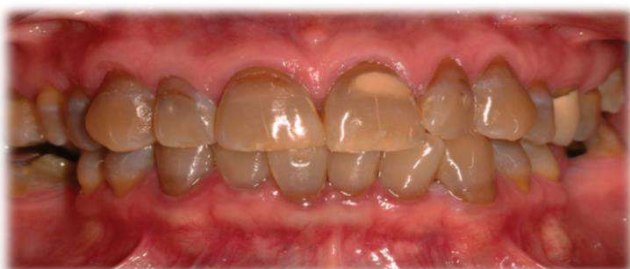
the gingival margin or as a wide band. This type of stain is also often found on teeth adjacent to salivary duct orifices. Green stain is tenacious and usually is found as a band on the labial surfaces of the maxillary anterior teeth. Blood pigments are thought to contribute to the green color. Orange or yellow-orange stains appear on the gingival third of teeth in a small percentage of children. These generally are easily removed.

### Endogenous Stains

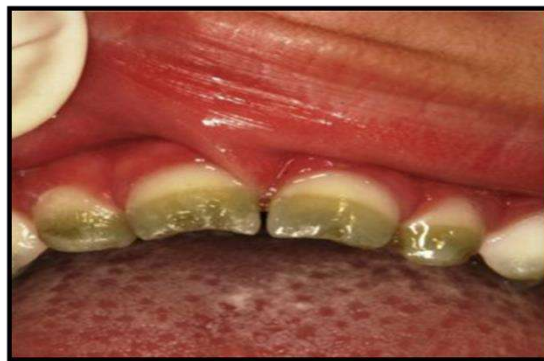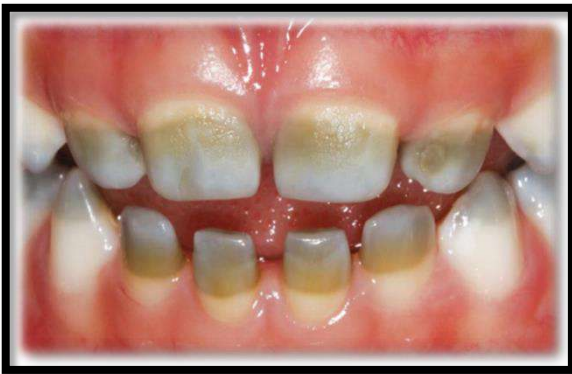Discoloration of teeth resulting from deposits of systemically circulating substances during tooth development is defined as endogenous or intrinsic staining.

**Systemic ingestion of tetracycline** during tooth development is a well-known cause of endogenous staining of teeth. Tetracycline binds calcium and therefore is deposited in developing teeth and bones. The bright yellow color of the drug is reflected in subsequently erupted teeth. The fluorescent property of tetracycline can be demonstrated with an ultraviolet light in clinically erupted teeth. Over time, the tetracycline oxidizes, resulting in a change from yellow to gray or brown with loss of its fluorescent quality. Because tetracycline can cross the placenta, it may stain primary teeth if taken during pregnancy. If it is administered between birth and age 6 or 7 years, permanent teeth may be affected. Only a small minority of children given tetracycline for various bacterial diseases, however, exhibit clinical evidence of discoloration. Staining is directly proportional to the age at which the drug is administered and the dose and duration of drug usage. The significance of tetracycline staining lies in its cosmetically objectionable appearance. Because other, equally effective antibiotics are available, tetracycline should not be prescribed for children younger than 7 years except in unusual circumstances.

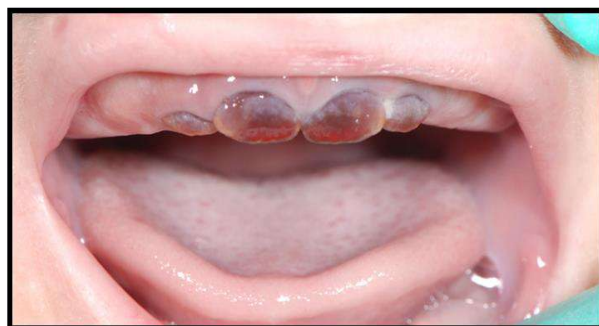
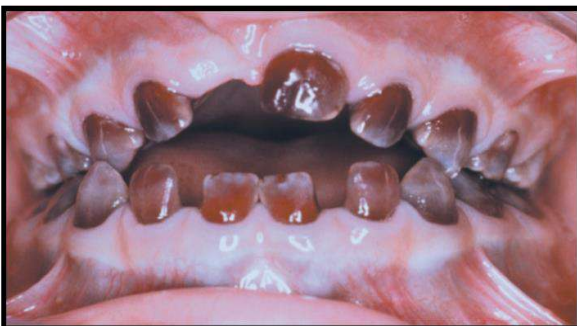
It should be noted that minocycline, a semisynthetic derivative of tetracycline, can stain the roots of adult teeth. It also may stain skin and mucosa in a diffuse or patchy pattern.

**Rh incompatibility (erythroblastosis fetalis)** has been cited as a cause of endogenous staining in primary teeth. Because of red blood cell hemolysis resulting from maternal antibody destruction of fetal red blood cells, blood breakdown products (bilirubin) are deposited in developing primary teeth. The teeth appear green to brown. Treatment is not required because only primary teeth are affected.



**Congenital porphyria**, one of several inborn errors of porphyrin metabolism, is also a potential cause of endogenous pigmentation. This autosomal-recessive trait is associated with photosensitivity, vesiculobullous skin eruptions, red urine, and splenomegaly. Teeth may appear red to brown because of deposition of porphyrin in the developing teeth. Affected teeth fluoresce red with ultraviolet light.



Liver disease, biliary atresia, and neonatal hepatitis may produce discoloration of the primary dentition. In biliary atresia, the teeth may assume a green discoloration; a yellowish-brown color is noted in cases of neonatal hepatitis. This is a result of the deposition or incorporation of bilirubin in developing enamel and dentin.

# Oral pathology

Dr. Ahlam Thabet

## Viral Infection

### HERPES SIMPLEX VIRUS

HSV-1 is spread predominantly through infected saliva or active perioral lesions . HSV-2 is adapted best to the genital zones, is transmitted predominantly through sexual contact, and typically involves the genitalia and skin below the waist.

Herpes simplex virus (HSVs) infections occur in two forms—primary (systemic) and secondary (localized). Both forms are self-limited, but recurrences of the secondary form are common because the virus can remain within ganglionic tissue in a latent state.

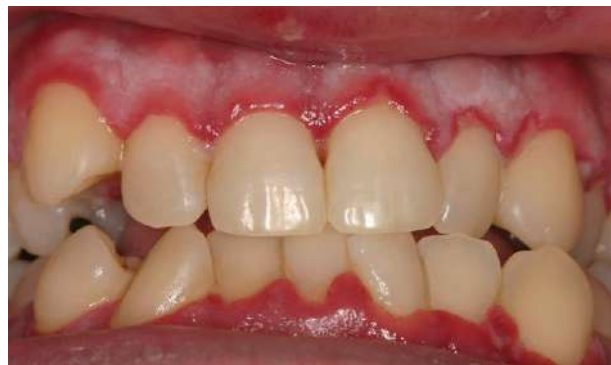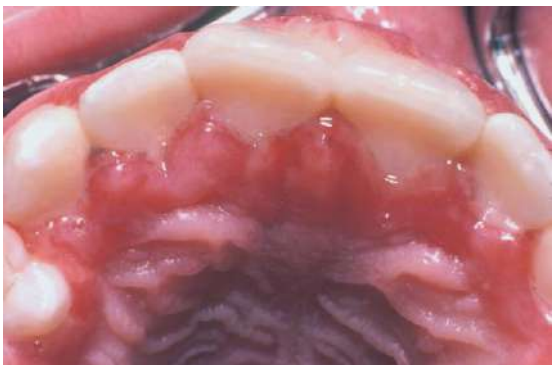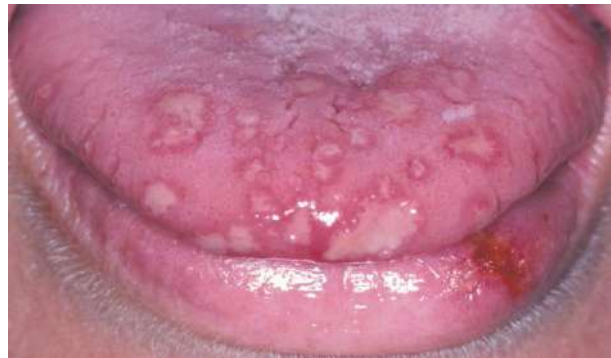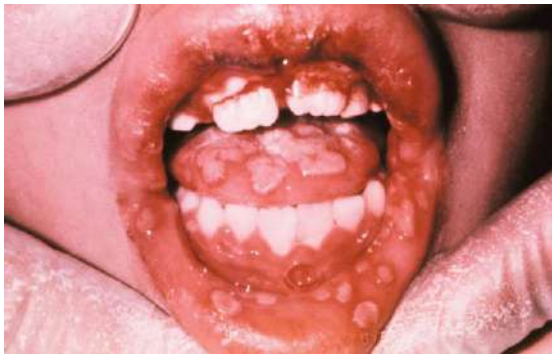**Primary infection** refers to initial exposure of an individual without antibodies to the virus. Primary infection with HSV-1 typically occurs at a young age, often is asymptomatic . After primary infection the virus remains in a latent state in trigeminal ganglion.

**Recurrent (secondary or recrudescient) infection** occurs with reactivation of the virus. Old age, ultraviolet light, physical or emotional stress, fatigue, heat, cold, pregnancy, allergy, trauma, dental treatment, respiratory illnesses, fever, menstruation, systemic diseases, and malignancy have been associated with reactivation.

### **Clinical Features**

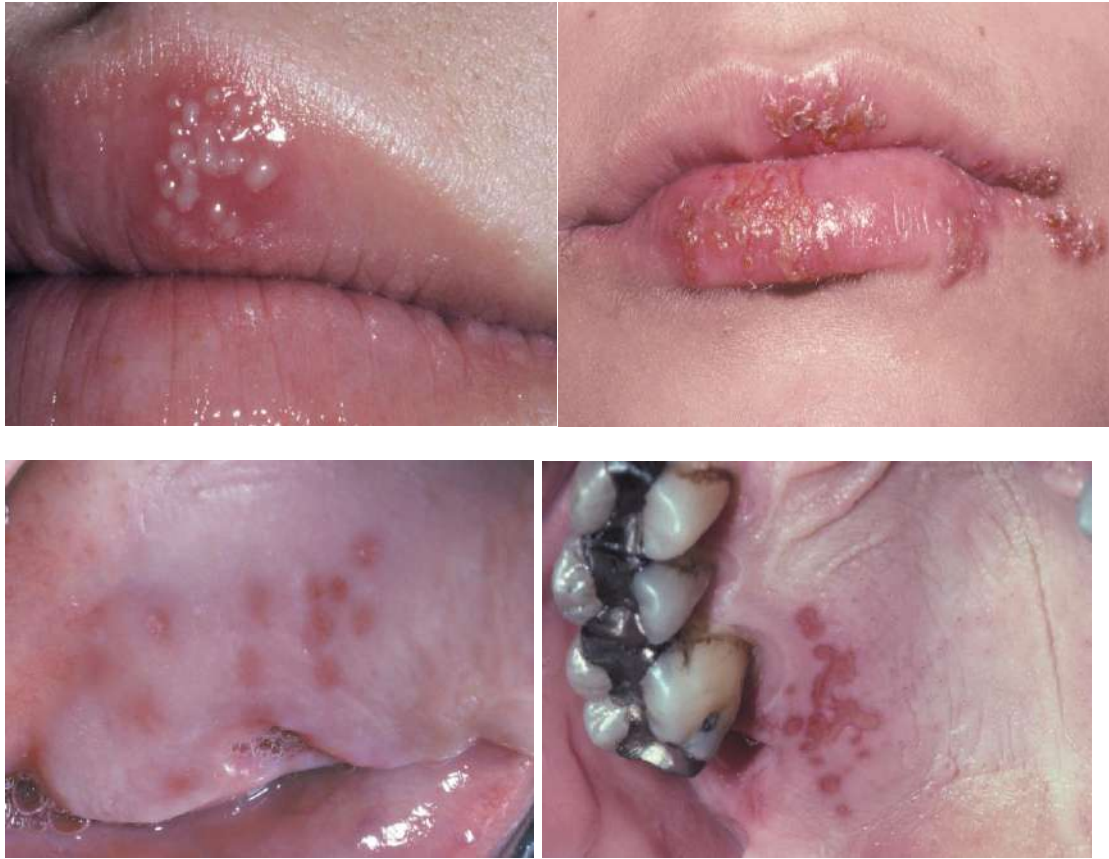**Acute herpetic gingivostomatitis (primary herpes)** is the most common pattern of symptomatic primary HSV infection, and more than 90% of cases are caused by HSV-1. Most affected individuals are children between the ages of 6 months and 5 years . The onset is abrupt and often accompanied by anterior cervical lymphadenopathy, chills, fever , nausea, anorexia, irritability, and sore mouth lesions.

Initially the affected mucosa develops numerous pinhead vesicles, which rapidly collapse to form numerous small, red lesions. These lesions enlarge slightly and develop central ulceration covered by yellow fibrin ulcerations may coalesce to form larger, shallow, irregular ulcerations . Mild cases usually resolve within 5 to 7 days; severe cases may last 2 weeks.



**Recurrent herpes simplex infections (secondary herpes)** may occur either at the site of primary inoculation or in adjacent areas of surface epithelium supplied by the involved ganglion. The most common site of recurrence for HSV-1 is the vermilion border and adjacent skin of the lips. This is known as herpes labialis (“**cold sore**” or “**fever blister**”). In some patients, ultraviolet light or trauma can trigger recurrences. Prodromal signs and symptoms (e.g., pain, burning, itching, tingling, localized warmth, and erythema of the involved epithelium) arise 6 to 24 hours before the lesions develop. Multiple small erythematous papules develop and form clusters of fluid-filled vesicles. The vesicles rupture and crust within 2 days. Healing usually occurs within 7 to 10 days. Symptoms are most severe in the first 8 hours.



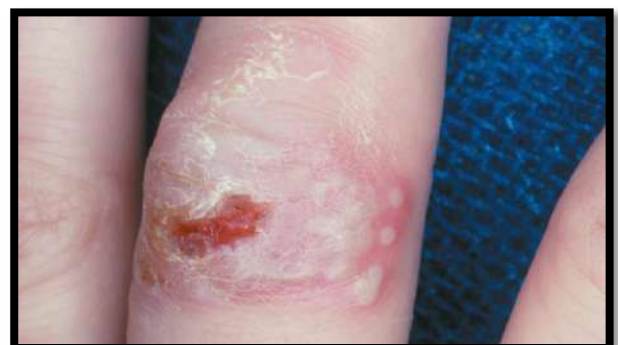

The lesions begin as 1- to 3-mm vesicles that rapidly collapse to form a cluster of erythematous macules that may coalesce or slightly enlarge . The damaged epithelium is lost, and a central yellowish ulceration develops. Healing occurs within 7 to 10 days. Several less common presentations also exist.

Primary or recurrent HSV infection of the fingers is known as herpetic whitlow (herpetic paronychia) This condition may result from self-inoculation in children with orofacial HSV-1 infection or adults genital HSV-2 infection. Recurrent digital infection may result in paresthesia and permanent scarring.

### **Histopathologic Features:**

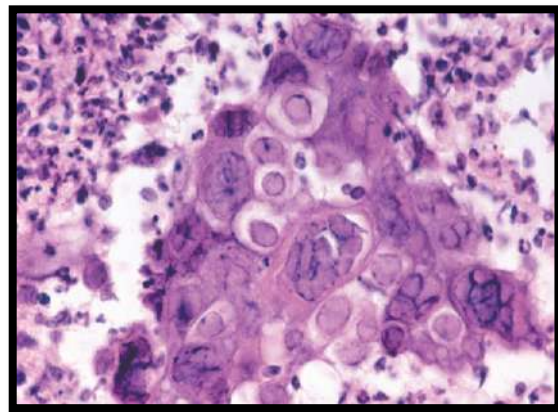
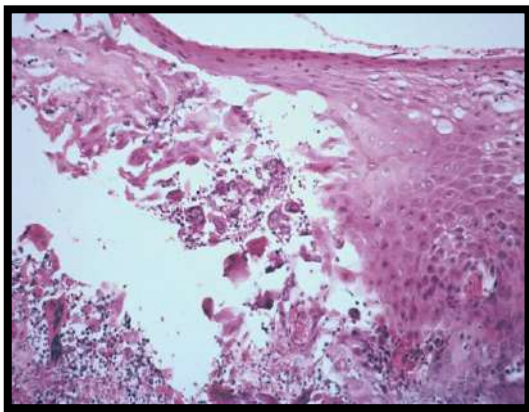
HSV-infected epithelial cells exhibit acantholysis, nuclear clearing, and nuclear enlargement (termed



ballooning degeneration).The acantholytic epithelial cells may be referred to as Tzanck cells. (This term refers to free-floating epithelial cells in any intraepithelial vesicle and is not specific for herpes.) Multinucleated epithelial cells are formed by fusion between adjacent cells .

### **Treatment and Prognosis:**

Symptomatic. In severe cases, systemic aciclovir or valaciclovir. Non-steroidal anti-inflammatory drugs (NSAIDs) used for more immediate pain relief.



### **VARICELLA (CHICKENPOX):**

**Varicella (chickenpox)** represents primary infection with the varicella-zoster virus (VZV or HHV-3). Secondary or reactivated disease is known as **herpes zoster** .

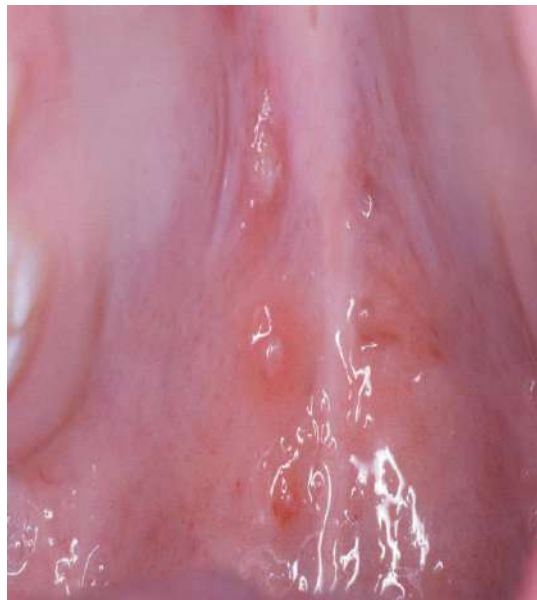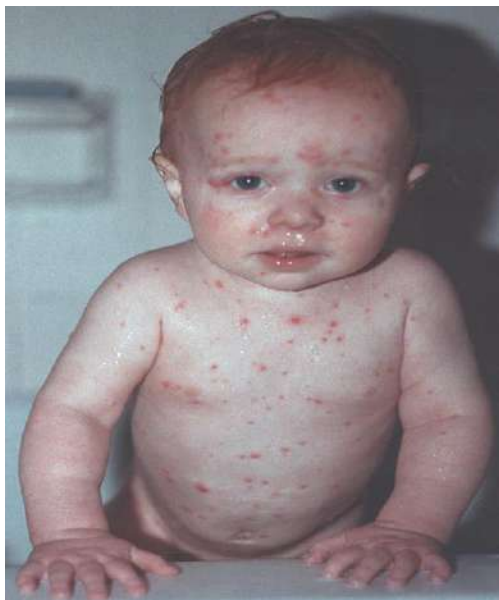The virus may be spread through air droplets or direct contact with active lesions. In contrast to primary HSV infection, most cases of primary VZV infection are symptomatic.

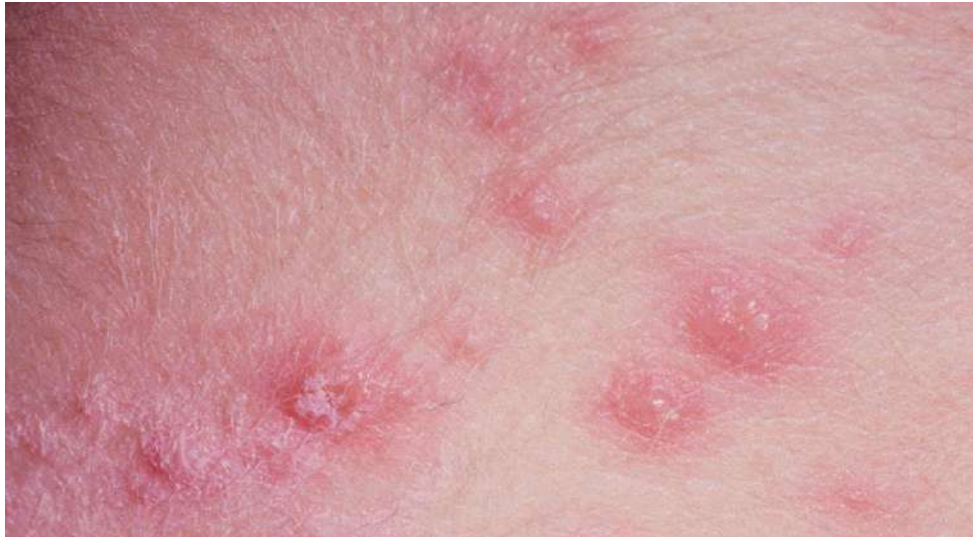## Clinical Features

A maculopapular, cutaneous rash with only a small number of lesions, few or no vesicles, low or no fever, and a shortened disease course of approximately 4 to 6 days are characteristic findings. Patients are contagious until no new lesions appear within a 24-hour period.

The symptomatic phase of primary VZV infection usually begins with malaise, pharyngitis, and rhinitis. In older children and adults, additional symptoms (e.g., headache, myalgia, nausea, anorexia, and vomiting) occasionally are seen. This is followed by a characteristic, intensely pruritic exanthem. The rash begins on the face and trunk and spreads to the extremities. Each lesion rapidly progresses through stages of erythema, vesicle, pustule, and hardened crust.

The vesicular stage is the classic presentation. Each vesicle is surrounded by a zone of erythema and has been described as “a **dewdrop on a rose petal.**” In contrast to herpes simplex, the lesions typically continue to erupt for 4 or more days.





Perioral and oral manifestations are fairly common and may precede the skin lesions. The vermilion border and palate are involved most often, followed by the buccal mucosa. Occasionally, gingival lesions resemble those noted in primary HSV infection, but distinguishing between the two is not difficult because the lesions of varicella tend to be relatively painless. The lesions begin as 3- to 4-mm white, opaque vesicles that rupture to form 1- to 3-mm ulcerations.

### **Treatment and Prognosis**

Supportive therapy is generally indicated. Warm baths with soap, application of calamine lotion; and systemic antihistamine still are used to relieve pruritus.

Acetaminophen is the preferred antipyretic for childhood cases. Peroral antiviral medications (such as, acyclovir, valacyclovir) .

### **HERPES ZOSTER (SHINGLES)**

Herpes zoster develops after reactivation of the virus, with involvement of the distribution of the affected sensory nerve. The prevalence of attacks increases with age, apparently due to age-related decline in cell-mediated immunity. Immunosuppression, HIV infection, treatment with cytotoxic or immunosuppressive , radiation, malignancy, old age, alcohol abuse, stress( emotional or physical), and dental manipulation are additional predisposing factors for reactivation.

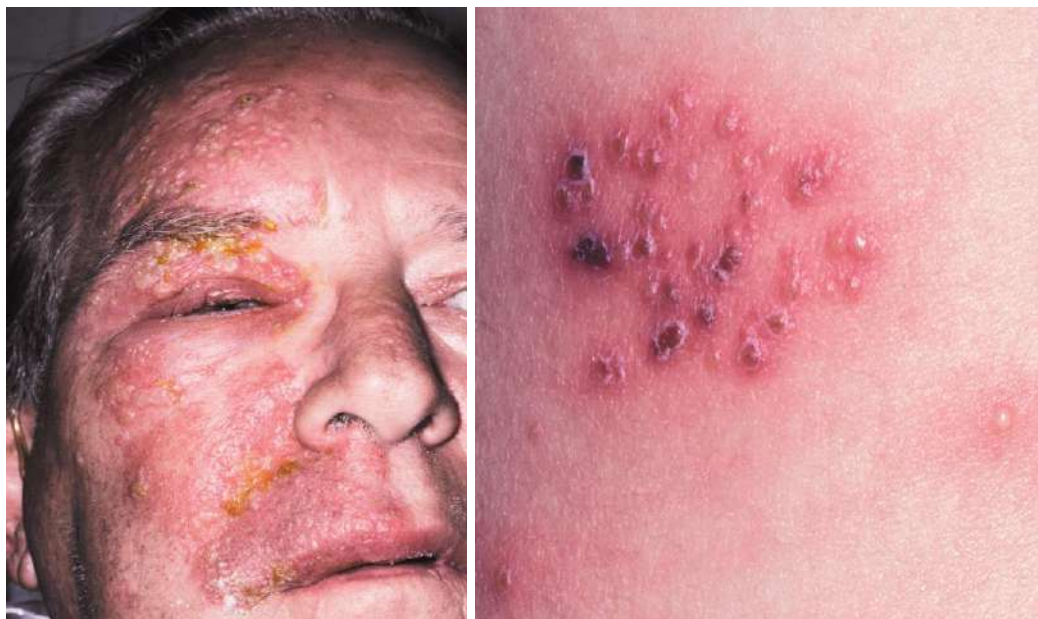## Clinical Features

The clinical features of herpes zoster can be grouped into three phases: prodromal , acute, and chronic.

During initial viral replication, ganglionitis develops with resultant neuronal necrosis and severe neuralgia. This inflammatory reaction is responsible for the prodromal pain present in more than 90% of cases. The pain intensifies and has been described as burning, tingling, itching, boring, prickly, or knifelike. and may be accompanied by fever, malaise, and headache.

This prodromal pain normally precedes the acute phase rash by 1 to 4 days and, depending on which dermatome is affected, may masquerade as sensitive teeth, otitis media, migraine headache, myocardial infarction, or appendicitis.

The acute phase begins as the involved skin develops clusters of vesicles set on an erythematous base . Within 3 to 4 days, the vesicles become pustular and ulcerate, with crusts developing after 7 to 10 days. The exanthem typically resolves within 2 to 3 weeks in otherwise healthy individuals. On healing, scarring with hypopigmentation or hyperpigmentation is not unusual.



Infrequently, there is dermatomal pain without development of a rash; this pattern is called **zoster sine herpete** (zoster without rash).

Oral lesions occur with trigeminal nerve involvement and may be present on the movable or bound mucosa. Like varicella, the individual lesions manifest as 1- to 4-mm vesicles or pustules that rupture to form shallow ulcerations. Reactivation of VZV in the geniculate ganglion may cause Ramsay Hunt syndrome. Approximately 15% of patients progress to the chronic phase of herpes zoster (termed **postherpetic neuralgia**), which is characterized by persistent pain after resolution of the rash.

### **Treatment and Prognosis**

Supportive therapy for herpes zoster may include antipruritics. Antiviral medications, such as acyclovir and valacyclovir has been found to accelerate healing of mucocutaneous lesions and reduce pain.

### **Hand-foot and- mouth disease**

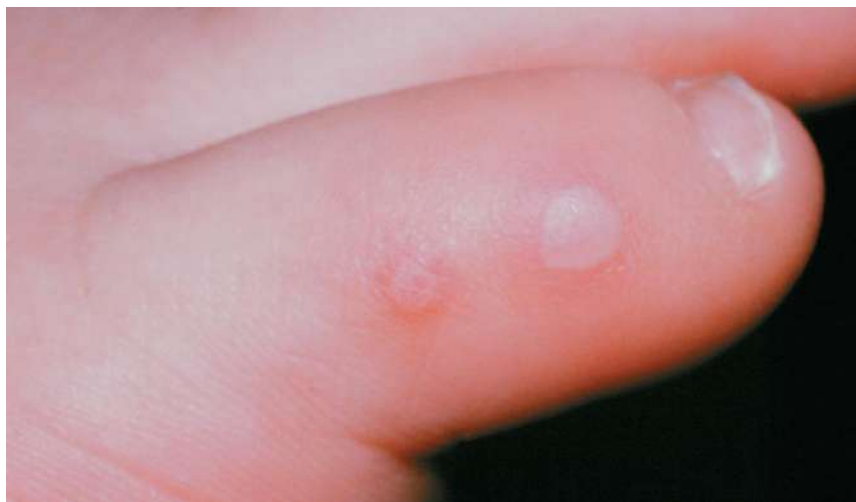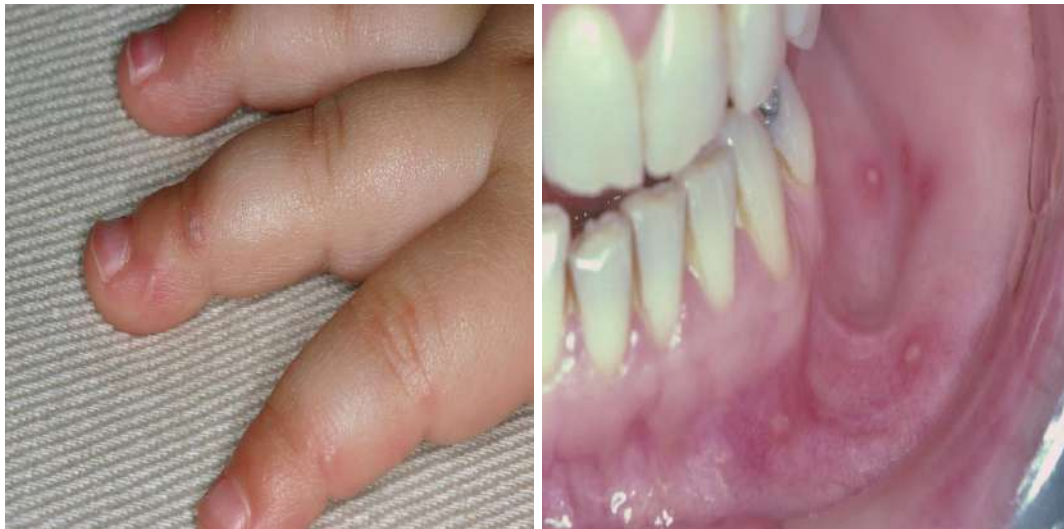Hand-foot-and-mouth disease is the best-known presentation of enterovirus infection. It is caused by coxsackievirus A16, but also may arise from coxsackie virus A5, A9, or A10.

### **Clinical Features**

The skin rash and oral lesions typically are associated with flulike symptom ( e.g., sore throat, dysphagia, and fever), occasionally accompanied by cough, rhinorrhea, anorexia, vomiting, diarrhea, myalgia, and headache. The name fairly well describes the location of the lesions.

Oral and hand lesions almost always are present. The oral lesions arise without prodromal symptoms and precede the development of the cutaneous lesions. Sore throat and mild fever usually are present also. The cutaneous lesions range from a few to dozens and primarily affect the borders of the palms and soles and the ventral surfaces and sides of the fingers and toes. The cutaneous lesions begin as erythematous macules that develop central vesicles and heal without crusting.

The oral lesions begin as numerous red macules, which form fragile vesicles that rapidly ulcerate and involve anterior regions of the mouth. The number of lesions ranges from 1 to 30. The buccal mucosa, labial mucosa, and tongue are the most common sites. The individual lesions typically measure 2 to 7 mm in diameter but may be larger than 1 cm. The lesions rapidly ulcerate and then typically heal within 1 week.



### **Treatment and Prognosis**

In most instances, enterovirus infections are self-limiting and without significant complications. Therapy is directed toward symptomatic relief;

non-aspirin antipyretics and topical anesthetics, such as dyclonine hydrochloride, often are beneficial.

## MEASLES (RUBEOLA):

Measles (rubeola) is a highly contagious infection produced by a virus in the family Paramyxoviridae and genus Morbillivirus.

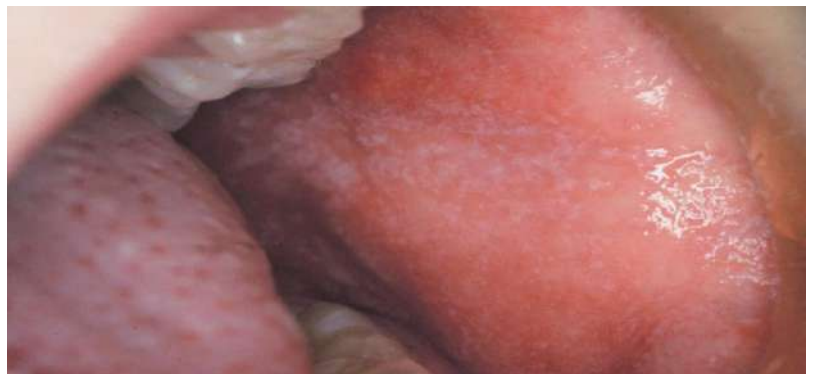
### Clinical Features

Most cases of measles arise in late winter or spring and are spread through respiratory droplets. The average incubation period is 14 days, and affected individuals are infectious from 4 days before until 4 days after appearance of the associated rash. The virus is associated with significant lymphoid hyperplasia that often involves the lymph nodes, tonsils, adenoids, and Peyer patches.

There are **three stages** of infection, with each stage lasting 3 days—hence the designation 9-day measles.

**The first 3 days** are dominated by the three Cs: coryza (runny nose), cough (typically brassy and uncomfortable), and conjunctivitis (red, watery, and photophobic eyes). Fever typically accompanies these symptoms. During this initial stage, the most distinctive oral manifestation, **Koplik spots**, is seen. These lesions represent foci of epithelial necrosis and appear as numerous small, blue-white macules (or “grains of salt”) surrounded by erythema. Typical sites of involvement include the buccal and labial mucosa, and less often the soft palate.

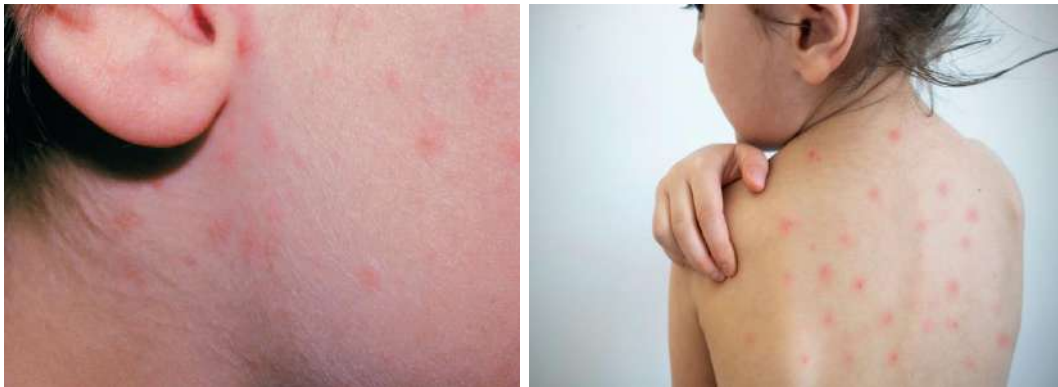**As the second stage** begins, the fever continues, the Koplik spots fade, and a maculopapular and erythematous (**morbilliform**)





rash begins. The face is involved first, with eventual downward spread to the trunk and extremities. Ultimately, a diffuse erythematous eruption is formed, which tends to blanch on pressure .

**In the third stage**, the fever ends. The rash begins to fade, with downward progression and replacement by brown pigmentation. Ultimately, desquamation of the skin is noted in areas previously affected by the rash.



#### **Treatment :**

No specific treatment for measles is known. Supportive therapy of bed rest, fluids, adequate diet, and analgesics generally suffices.

## **Fungal infections**

### **Candidal infection (Candidiasis)**

Candidiasis is the most common oral fungal infection. It is usually caused by *Candida albicans*.

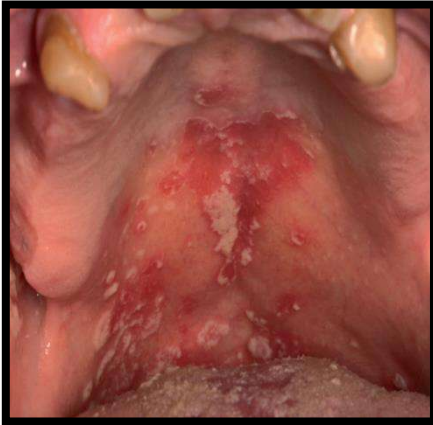
**Predisposing factors** are **local** (poor oral hygiene, xerostomia, mucosal damage, dentures, antibiotic mouthwashes) and **systemic** (broad-spectrum antibiotics, steroids, immunosuppressive drugs, radiation, HIV infection, hematological malignancies, neutropenia, iron-deficiency anemia, cellular immunodeficiency, endocrine disorders).

## Clinical features

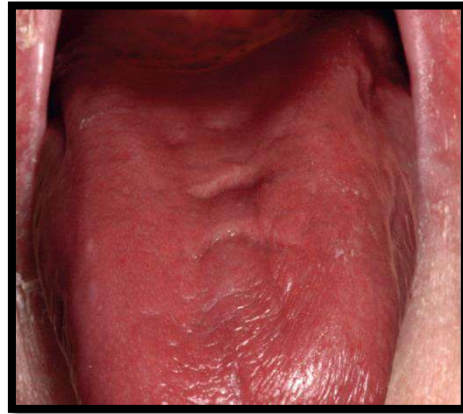Oral candidiasis is classified as **primary**, consisting of lesions exclusively on the oral and perioral area, and **secondary**, consisting of oral lesions of mucocutaneous disease.

**Primary candidiasis** includes many clinical varieties:

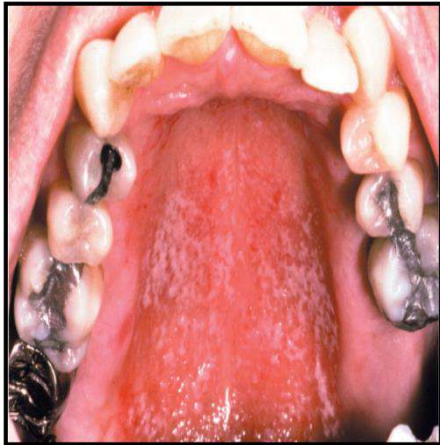
pseudomembranous (thrush) , erythematous( papillary hyperplasia of the palate), Chronic Hyperplastic Candidiasis , and Candida-associated lesions (angular cheilitis, median rhomboid glossitis, denture stomatitis) .



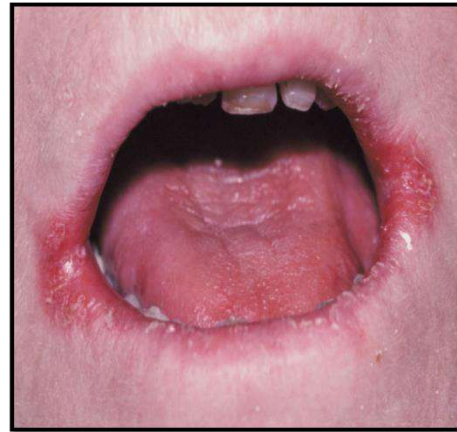-Pseudomembranous Candidiasis



- Erythematous Candidiasis



-Papillary hyperplasia of the palate



- Angular cheilitis

**Histopathology:** In acute candidiasis, fungal pseudohyphae are seen penetrating the upper layers of the epithelium at acute angles. Neutrophilic infiltration of the epithelium with superficial microabscess formation is typically seen.

**Treatment:** dealing with predisposing factors + topical and/or systemic antifungals.

## **Deep fungal infections**

Deep fungal infections are characterized by primary involvement of the lungs. Infections may disseminate from this focus to involve other organs. Deep fungal infections having a significant incidence of oral involvement include histoplasmosis, coccidioidomycosis, blastomycosis, mucormycosis, and cryptococcosis

**Clinical Features:** Initial signs and symptoms of deep fungal infection are usually related to lung involvement and include cough, fever, night sweats, weight loss, chest pain, and hemoptysis. The usual oral lesion is ulcerative. Whether single or multiple lesions are non-healing, indurated, and frequently painful.

**Histopathology.** The basic inflammatory response in a deep fungal infection is granulomatous. In the presence of these microorganisms, macrophages and multinucleated giant cells dominate the histologic picture

**Treatment :** Treatment of deep mycotic infection generally consists of antifungals such as ketoconazole, fluconazole, and amphotericin B .

## **Human immunodeficiency virus (HIV) infections and AIDS**

The oral manifestation of HIV infection are numerous and have been divided into three groups based on the strength of their association with HIV infection. the main lesions in each group are listed in table below

**Group 1-Lesions** strongly associated with HIV infections

- ❖ Candidiasis
  - Erythematous
  - Hyperplastic
  - Pseudomembranous
- ❖ Hairy leukoplakia (EB virus)
- ❖ HIV associated periodontal disease
  - HIV gingivitis
  - Necrotizing ulcerative gingivitis
  - HIV associated periodontitis
  - Necrotizing stomatitis

- ❖ Kaposi sarcoma
- ❖ Non-Hodgkins lymphoma

**Group 2-lesions** less commonly associated with HIV infections

- ❖ Atypical ulceration
- ❖ Ideopathic thrombocytopenic purpura
- ❖ Salivary gland disorders ( Dry mouth, decreased salivary flow rate  
Unilateral or bilateral swelling of major glands)
- ❖ Viral infection other than (EB virus)
  - Cytomegalo virus
  - Human papilloma virus
  - Varicella zoster virus

**Group 3-lesions** possibly associated with HIV infection

- ❖ Bacterial infections other than gingivitis/periodontitis
- ❖ Fungal infection other than candidiasis
- ❖ Melanotic hyperpigmentation
- ❖ Neurologic disturbances
- ❖ Facial palsy
- ❖ Trigeminal neuralgia

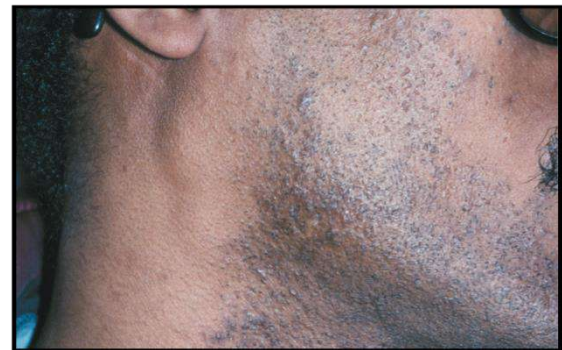
### **Oral Manifestation of Acquired immunodeficiency system (AIDS)**

#### **Persistent generalized lymphadenopathy.**

HIV lymphadenitis may be seen in the HIV scale, later in the course of the disease lymph node biopsies may be necessary to rule out lymphoma.

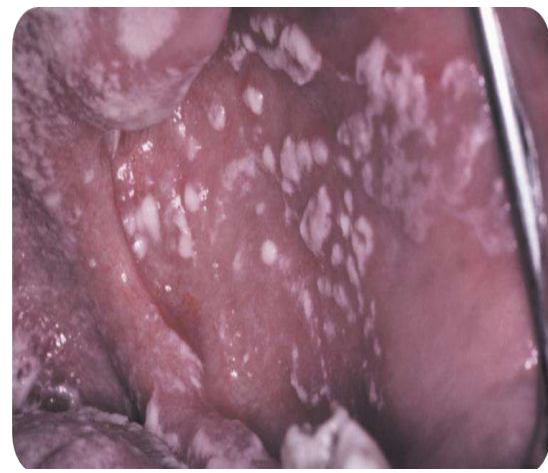#### **Candidiasis.**

Oral candidiasis is the most common intra oral manifestation of HIV infection and often is the presenting sign that leads to the initial diagnosis, Its presence in a patient infected with HIV is not diagnostic of AIDS but appears to be predictive for the subsequent development of full-blown AIDS in untreated patients within 2 years.



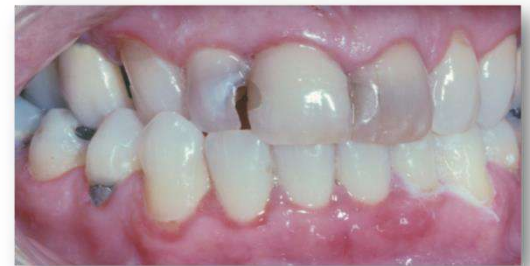The following four clinical patterns of oral candidiasis are seen:

- Pseudomembranous
- Erythematous
- Hyperplastic
- Angular cheilitis



**HIV-associated periodontal disease.** Three patterns of periodontal disease are associated strongly with HIV infection:

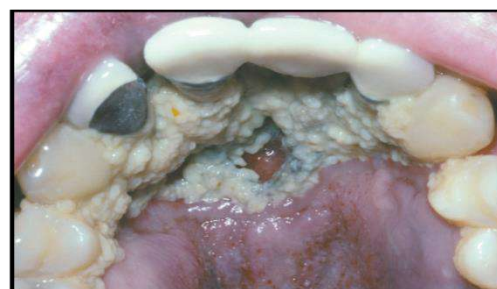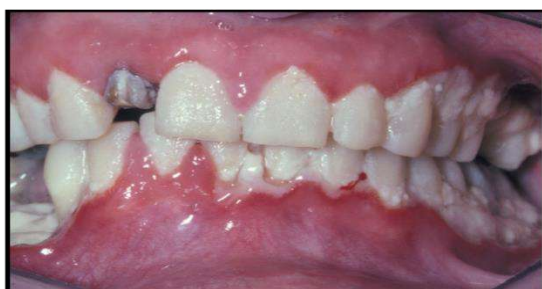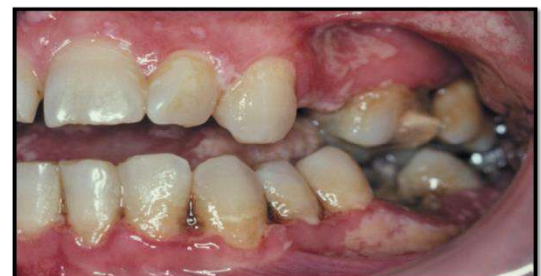- Linear gingival erythema
- Necrotizing ulcerative gingivitis
- Necrotizing ulcerative periodontitis



Linear gingival erythema initially was termed HIV"lated gingivitis but ultimately was noted in association with other disease processes. This unusual pattern of gingivitis appears with a distinctive linear band of erythema that involves the free gingival margin and extends 2 to 3 mm apically.

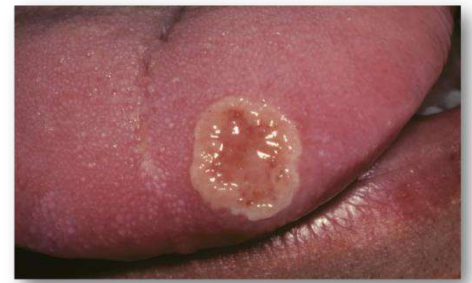### **Necrotizing ulcerative gingivitis (NUG)**

Refers to ulceration and necrosis of one or more interdental papillae with no loss of periodontal attachment. Necrotizing ulcerative periodontitis (NUP) was previously termed HIV-associated periodontitis; however, it has not been seemed to be specific for HIV infection. NUP is characterized by gingival ulceration and necrosis associated with rapidly progressing loss of periodontal attachment. Although severe cases can affect all teeth.



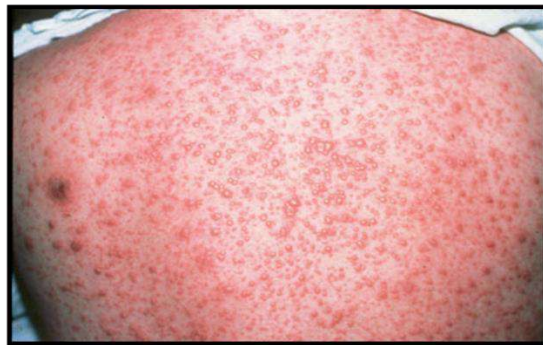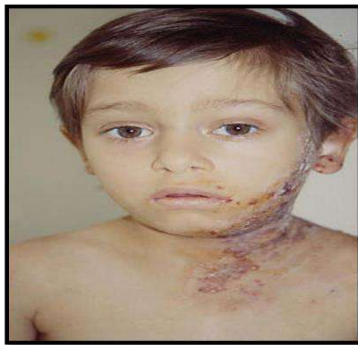### Herpes simplex virus (HSV).

Recurrent HSV infections occur in about the same percentage of HIV-infected patients as they do in the immunocompetent population (10% to 15%); however, the lesions are more widespread, occur in an atypical pattern, and may persist for months.



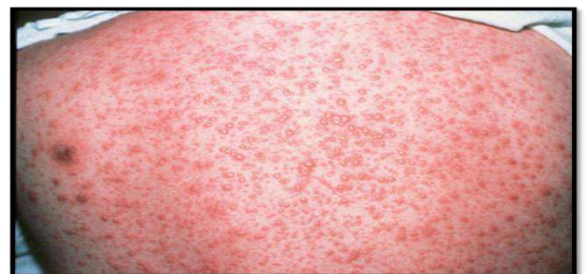### Varicella-zoster virus (VZV).

Recurrent VZV infection (herpes zoster) is fairly common in HIV-infected patients, oral involvement often is severe and occasionally leads to bone sequestration and loss of teeth. Associated pain typically is intense.



### Epstein-Barr virus (EBV).

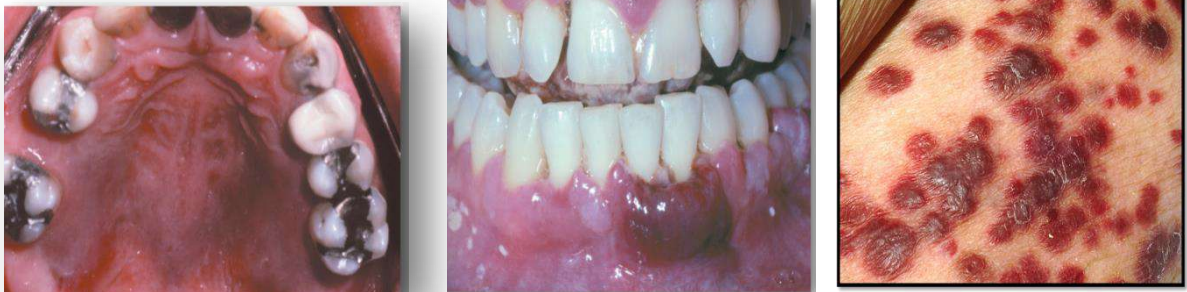Although EBV is thought to be associated with several forms of lymphoma in HIV infected patients, the most common EBV-related lesion in patients with AIDS is oral hairy leukoplakia (OHL). This lesion has a somewhat distinctive (but not diagnostic) pattern of hyperkeratosis and epithelial hyperplasia that is characterized by white mucosal lesions that do not rub off.



### Kaposi's sarcoma (KS).

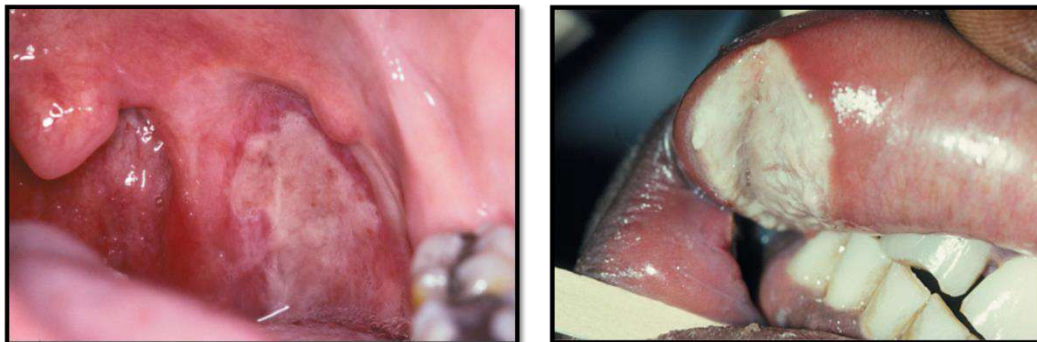
KS is a multifocal neoplasm of vascular endothelial cell origin, KS begins with single or, more frequently, Multiple lesions of the skin or oral mucosa. The trunk, arms, head, and neck are the most commonly involved anatomic sites. Oral lesions are seen in approximately 50% of affected patients and are the initial site of

involvement in 20% to 25%. Although any mucosal site may be involved, the hard palate, gingiva, and tongue are affected most frequently the neoplasm mean invade bone and create tooth mobility.



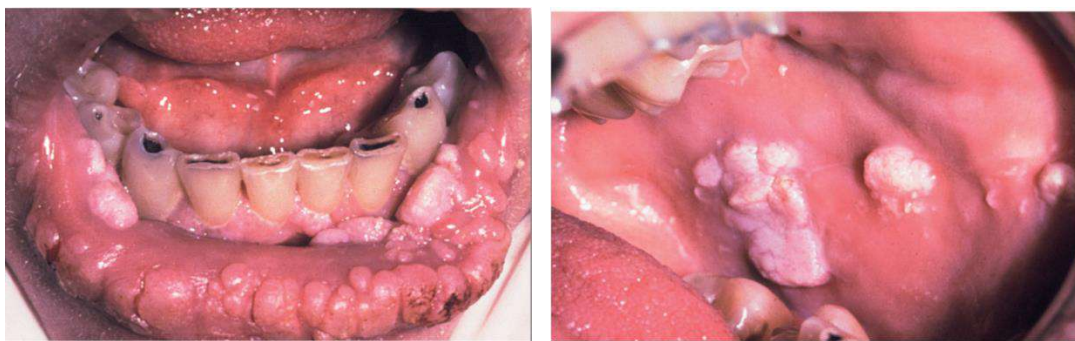
### Aphthous ulcerations.

Lesions that are similar clinically to aphthous ulcerations occur with increased frequency in patients infected with HIV. All three forms (minor, major, and herpetiform) are seen.



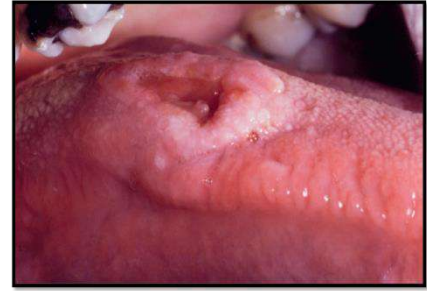### Human papillomavirus (HPV)

HPV is responsible for several facial and oral lesions in immunocompetent patients. The most frequent of which are the verruca vulgaris (common wart) and oral squamous papilloma.



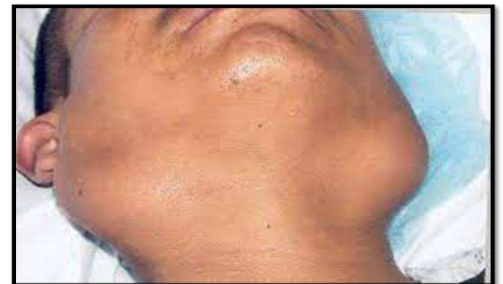### Histoplasmosis.

Histoplasmosis is produced by *Histoplasma capsulatum*. In healthy patients. The infection typically is subclinical and self-limiting, but clinically evident infections do occur in immunocompromised individuals. Although a number of deep fungal infections are possible in patients with AIDS.



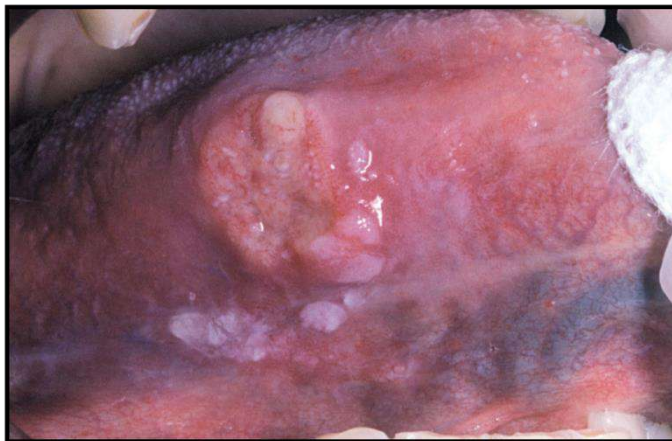### HIV-associated salivary gland disease.

Clinically obvious salivary gland disease is noted in approximately 5% of HIV infected patients, with a greater prevalence noted in children. The main clinical sign is salivary gland enlargement, particularly affecting the parotid. Bilateral involvement is seen in about 60% of the patients with glandular changes and often is associated with cervical lymphadenopathy.



### Oral squamous cell carcinoma.

Squamous cell carcinoma of the oral cavity, pharynx, and larynx has been reported in HIV-infected patients.





# General pathology

## Diseases of the Immune System

**Immunity:** It is protection against infections.. The immune system is the collection of cells and molecules that are responsible for:

- 1- Defending our body against pathogenic microbes in our environment.
- 2- Prevent the proliferation of cancer cells.
- 3- Mediate the healing of damaged tissue.

Immunity consists of two types of reactions:

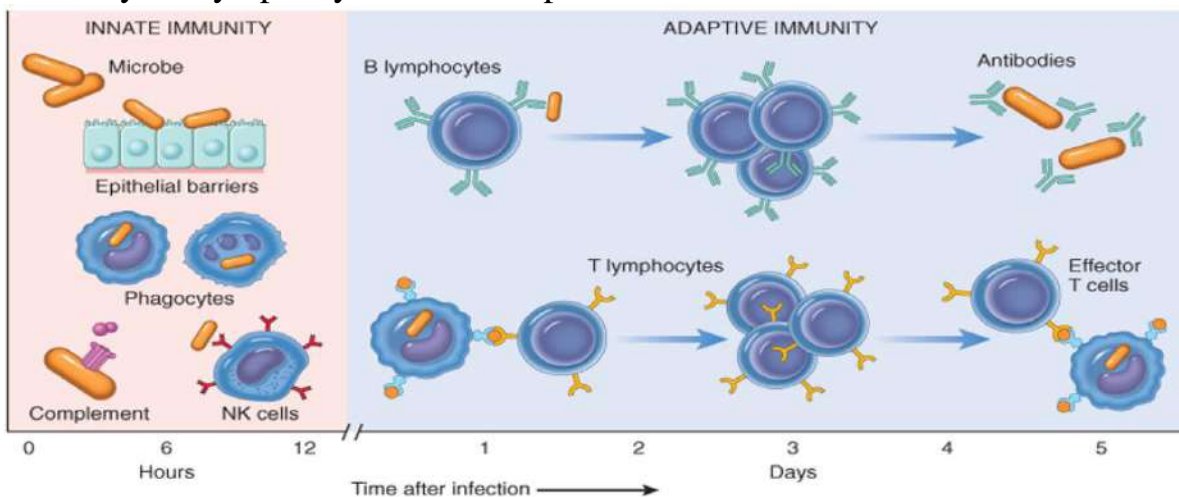
### 1- Innate immunity (natural or native immunity):

Is non-specific and is considered as the first line of defense without antigenic specificity. It is mediated by cells and proteins that are always present and act immediately against any infection. The major components of innate immunity are:

- a- **Physical** : Epithelial barriers of the skin, gastrointestinal tract, and respiratory tract, which prevent microbe entry.
- b- **Cellular** : Phagocytic leukocytes (neutrophils and macrophages) and a specialized cell type called the natural killer (NK) cell.
- d- **Humoral** : Several circulating plasma proteins, the most important of which are the proteins of the complement system.

### 2- Adaptive immunity (acquired or specific immunity).

Is specific and is characterized by antigenic specificity. It is normally silent and responds (or "adapts") to the presence of an infectious microbes by becoming active for neutralizing and eliminating the microbes. The components of the adaptive immunity are lymphocytes and their products.

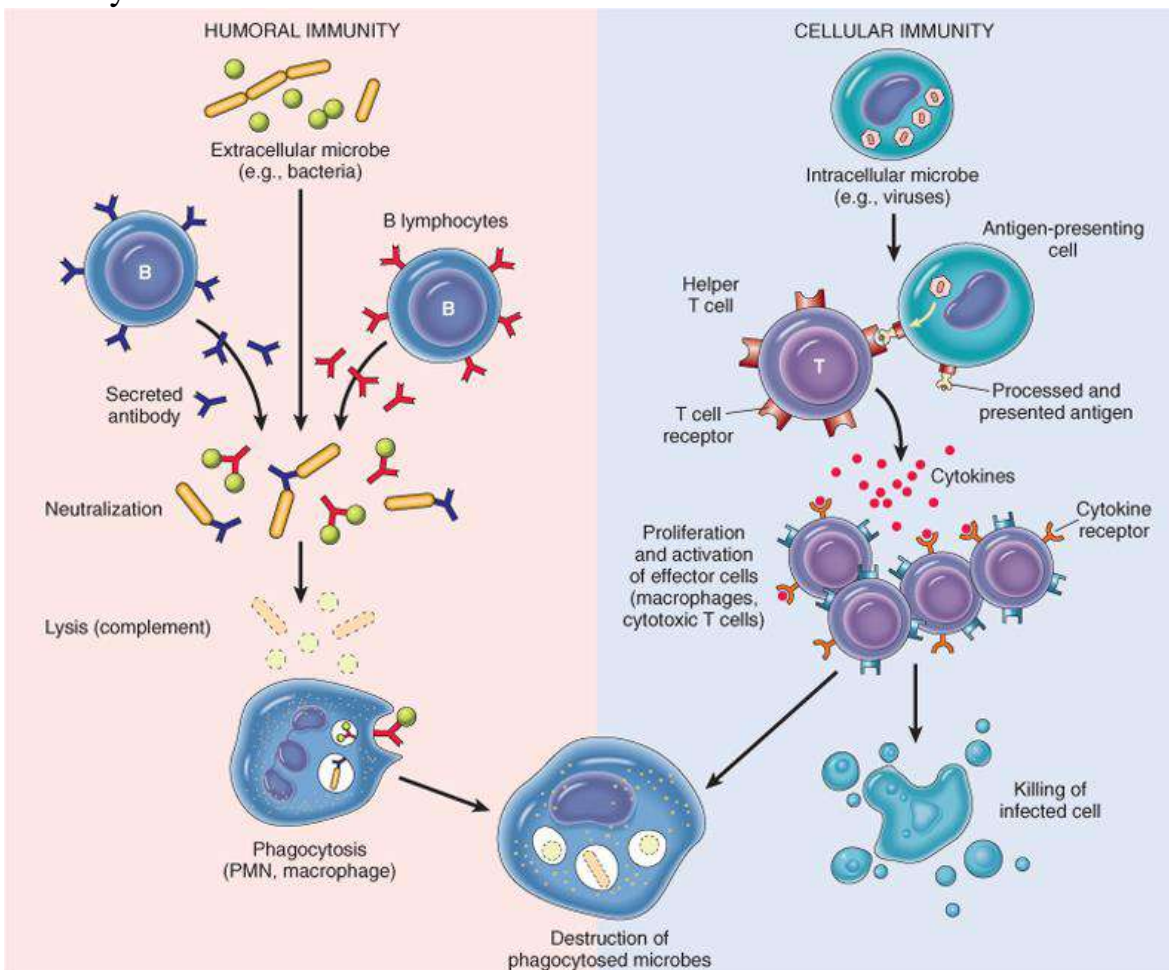


## Types of adaptive immunity:

**1-Humoral immunity:** Mediated by soluble **antibody** proteins that are produced by **B lymphocytes** (B cells). Antibodies provide protection against extracellular microbes in the blood, mucosal secretions, and tissues.

**2-Cell-mediated (or cellular) immunity:** Mediated by **T lymphocyte** (T cells) which are important in defense against intracellular microbes. They work by either directly killing infected cells (by cytotoxic T lymphocytes) or by activating phagocytes to kill ingested microbes, via the production of soluble protein mediators called cytokines (made by helper T cells).

When the immune system is inappropriately triggered or not properly controlled, the same mechanisms that are involved in host defense will cause tissue injury and disease. The reaction of the cells of innate and adaptive immunity may be manifested as **inflammation** which is a beneficial process, but it is also the basis of many human diseases.



## Cells and tissues of the immune system

### 1. Lymphocytes:

Lymphocytes are present in the circulation and in various lymphoid organs as two types:

**T- lymphocytes**(mature in the thymus).

**B- lymphocytes**(mature in the bone marrow).

Each T or B lymphocyte expresses receptors for a single antigen, and the total population of lymphocytes (numbering about  $10^{12}$  in humans) is capable of recognizing tens or hundreds of millions of antigens.

#### **T Lymphocytes:**

They are the effector cells of cellular immunity and provide important stimuli for antibody responses to protein antigens. T cells do not detect free or circulating antigens. Instead, the vast majority (>95%) of T cells recognize only protein antigens that are displayed on other cells bound to proteins of the major histocompatibility complex (MHC; or human leukocyte antigen [HLA] complex). The normal function of MHC molecules is to display protein for recognition by T lymphocytes thus perform their function of killing infected cells or activating phagocytes or B lymphocytes that have ingested protein antigens.

#### **B Lymphocytes**

B cells synthesize antibodies or immunoglobulins (Ig ) five classes: IgG, IgM, IgA, IgE and IgD. After stimulation, B cell will be differentiated into **plasma cells** which secrete large amounts of antibodies, which are the mediators of humoral immunity.

### 2. Natural Killer Cells

They are lymphocytes of innate immunity which have limited set of activating receptors so they do not have specificities as diverse as do T cells or B cells. They can recognize molecules expressed on stressed or infected cells or cells with DNA damage, and then kill these cells.

NK cells express inhibitory receptors that recognize self-class I MHC molecules, which are expressed on all healthy cells; so they avoid attacking normal host cells. Infections (especially viral infections) and stress are associated with loss of expression of class I MHC molecules so NK cells are released from their inhibition and destroy the unhealthy host cells.

### 3. Antigen-Presenting Cells

These cells are specialized to capture microbial antigens and display them to lymphocytes. These APCs are dendritic cells (DCs) and macrophage.

#### **a. Dendritic Cells**

Cells with fine dendritic cytoplasmic processes occur as two functionally distinct types.

**Interdigitating DCs**, are non-phagocytic cells that express high levels of class II MHC and T-cell co stimulatory molecules.

Immature DCs reside in epithelia, where they are located to capture entering microbes; an example is the Langerhans cell of the epidermis.

Mature DCs are present in the T-cell zones of lymphoid tissues, where they present antigens to T cells circulating through these tissues. DCs are also present in the interstitium of many nonlymphoid organs, such as the heart and lungs, where they can capture the antigens of microbes that have invaded the tissues.

**Follicular dendritic cells**(FDCs), located in the germinal centers of lymphoid follicles in the spleen and lymph nodes. These cells bear receptors for the Fc tails of Ig G and for complement proteins, and hence efficiently trap antigen bound to antibodies and complement.

#### **b. Macrophages:**

Ingest microbes and other particulate antigens and display them for recognition by T lymphocytes which in turn activate the macrophages to kill the microbes, the central reaction of cell mediated immunity.

#### **4. Effector Cells**

Many different types of leukocytes perform the adaptive immune response, which is to eliminate infections. These include **NK cells, Antibody-secreting plasma cells, T lymphocytes, Macrophages.**

### **Lymphoid Tissues:**

Divided into:

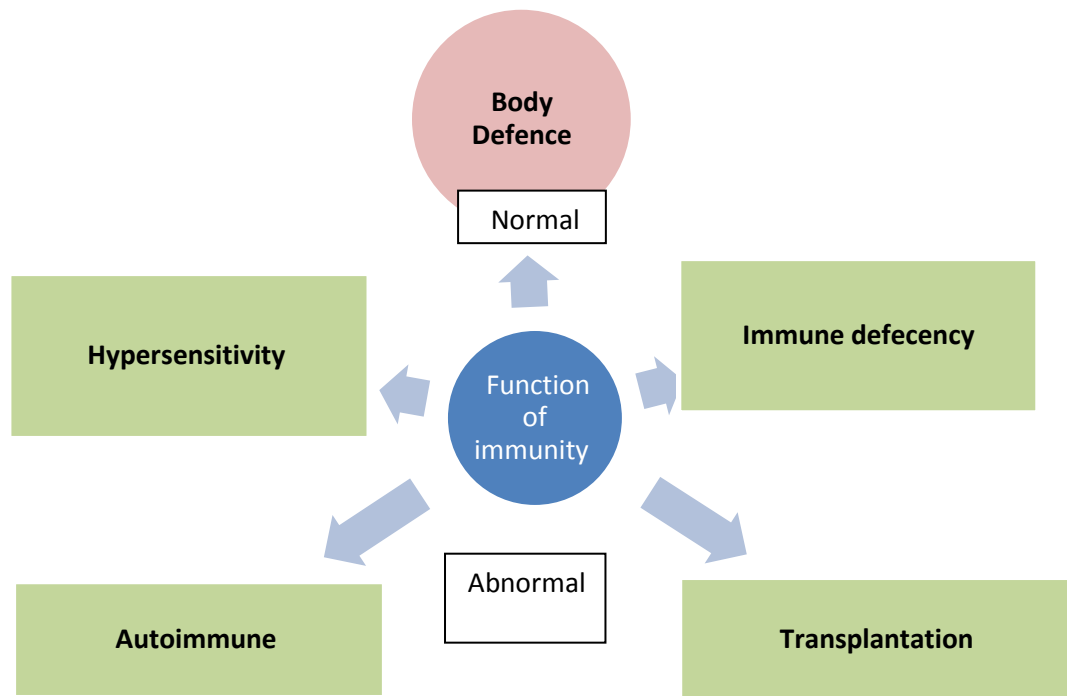
**1- Generative (primary) organs**, where lymphocytes express antigen receptors and mature. These include the thymus and bone marrow.

**2- Peripheral (secondary) lymphoid organs**, where adaptive immune responses develop. The peripheral organs are the lymph nodes, spleen, and mucosal and cutaneous lymphoid tissues.

## **Immune diseases**

Normally, the immune response prevents disease, It is a defense mechanism but it can be injurious to the human body in a variety of ways. Occasionally, the inappropriate activation of the immune system can lead to debilitating or life-threatening illnesses, like:

- 1- Allergic or hypersensitivity reactions.
- 2- Immunodeficiency states
- 3- Autoimmune disorders.
- 4- Transplantation immunopathology.



## 1- Allergic or hypersensitivity disorders:

**Hypersensitivity:** it is an exaggerated immune response to a foreign agent resulting in injury to the host. It is caused by immune responses to environmental antigens called **allergens** that produce inflammation and cause tissue injury.

**Allergens:** Any foreign substances capable of inducing an immune response. Many different chemicals of natural and synthetic origin are known as allergens. Complex natural organic chemicals, especially proteins, are more likely to cause an immediate hypersensitivity response, whereas simple organic compounds, inorganic chemicals, and metals more commonly cause delayed hypersensitivity reactions. Exposure to the allergen can be through inhalation, ingestion, injection, or skin contact.

### Hypersensitivity disorders are of four types:

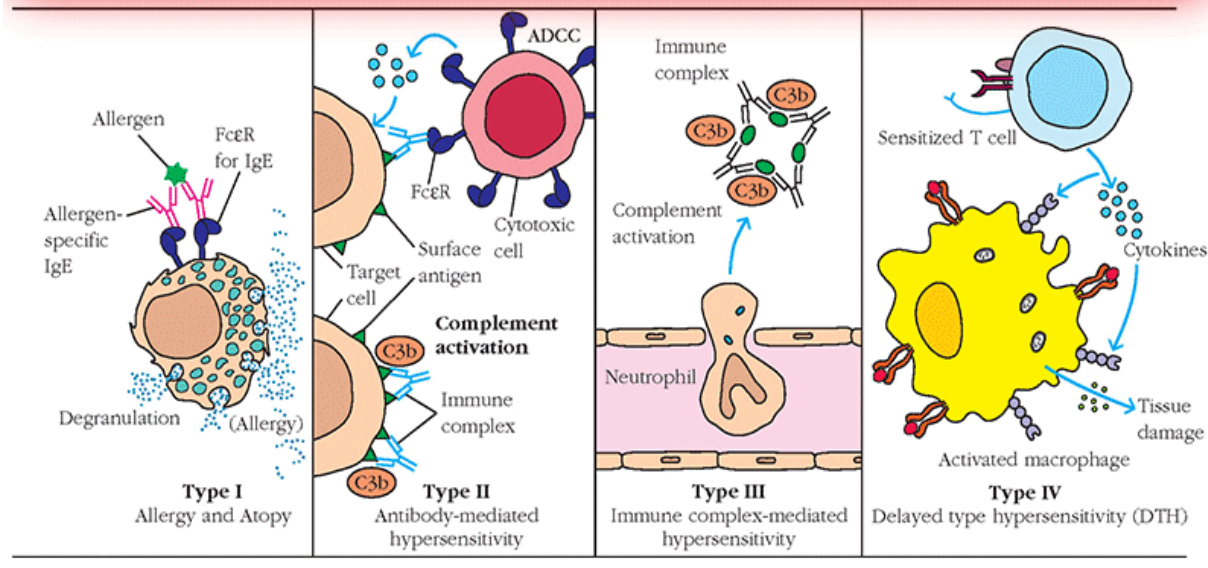
Type I: IgE-mediated disorders.

Type II: Antibody-mediated (cytotoxic) disorders.

Type III, Immune-Complex Disorders

Type IV: Cell-mediated hypersensitivity reactions.

# Type I vs Type II vs Type III vs Type IV

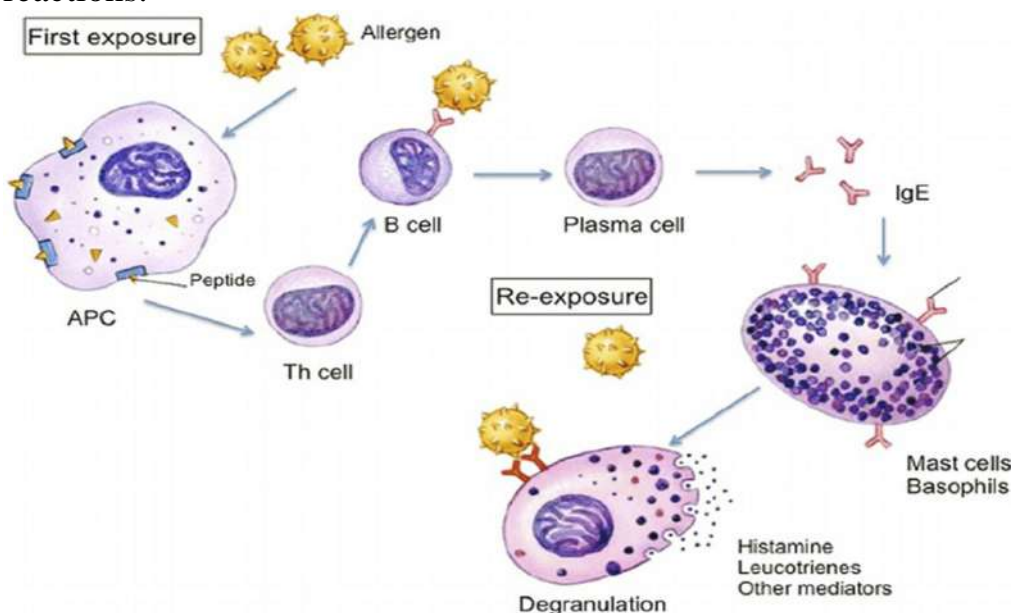


## Type I, IgE-Mediated Disorders (Immediate type):

They are immediate-type of hypersensitivity reactions that are triggered by binding of an allergen to a specific IgE found on the surface of mast cells or basophils.

Mast cells, (tissue cells), and basophils, (blood cells), are derived from blood precursor cells. Mast cells are distributed throughout connective tissue, near surfaces that are exposed to environmental antigens especially in areas beneath the skin and mucous membranes of the respiratory, gastrointestinal, and genitourinary tracts, and adjacent to blood and lymph vessels.

Mast cells and basophils have granules that contain potent mediators of allergic reactions.



During the sensitization, the allergen-specific IgE antibodies attach to receptors on the surface of these cells triggers a series of events that lead to degranulation of the sensitized cells, causing release of their allergy-producing mediators which include:

**Histamine**, a potent vasodilator that increases the permeability of capillaries and venules, causes bronchoconstriction and increased secretion of mucus.

**Acetylcholine** produces bronchial smooth muscle contraction and dilation of small blood vessels.

**Proteases** generate kinins and cleave complement components to produce additional chemotactic and inflammatory mediators.

**Leukotrienes and prostaglandins** produce responses similar to those of histamine and acetylcholine, although their effects are delayed and prolonged by comparison.

**Platelet-activating factor** result in platelet aggregation, histamine release, and bronchospasm. It also acts as a chemotactic factor for neutrophils and eosinophils.

**Cytokines** recruit and activate a variety of inflammatory cells.

Type I hypersensitivity reactions may present as a systemic disorder (anaphylaxis) or a localized reaction (atopy).

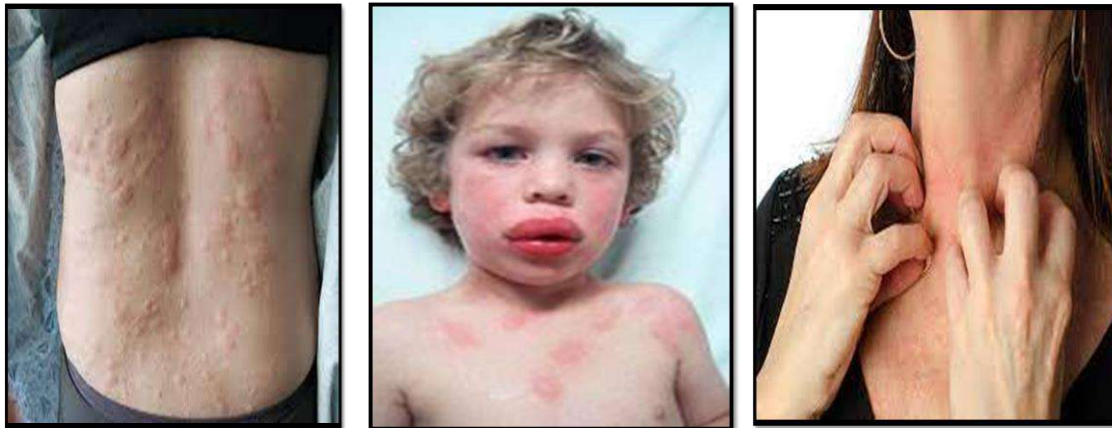#### ❖ **Systemic Anaphylactic Reactions:**

Result from injected allergens (*e.g.*, **penicillin, radiographic contrast dyes, and bee or wasp stings**).

More rarely, they may result from ingested allergens (seafood, nuts, and legumes).

**Sign and symptoms:** Anaphylaxis has a rapid onset, often within minutes, there will be:

- 1- Itching.
- 2- Urticaria.
- 3- Gastrointestinal cramps.
- 4- Difficulty in breathing caused by bronchospasm.
- 5- Angioedema (swelling of face and throat) may develop, causing upper airway obstruction.
- 6- Massive vasodilation may lead to peripheral pooling of blood, a profound drop in blood pressure, and life-threatening circulatory shock.

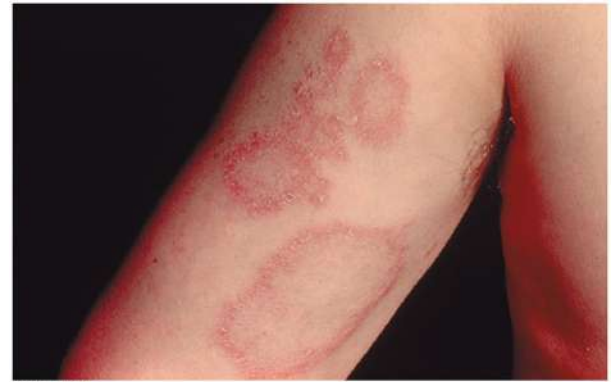

### ❖ Localized Atopic Disorders:

Occur when the antigen is confined to a particular site, usually related to the route of exposure. It is genetically determined and the term **atopy** is often used to imply a hereditary predisposition to such reactions.

They have high serum levels of IgE and increased numbers of basophils and mast cells and they are also responsive to the chemical mediators of allergic reactions.

Atopic disorders include **food allergies**, **allergic rhinitis**, **allergic dermatitis**, and certain forms of **bronchial asthma**.

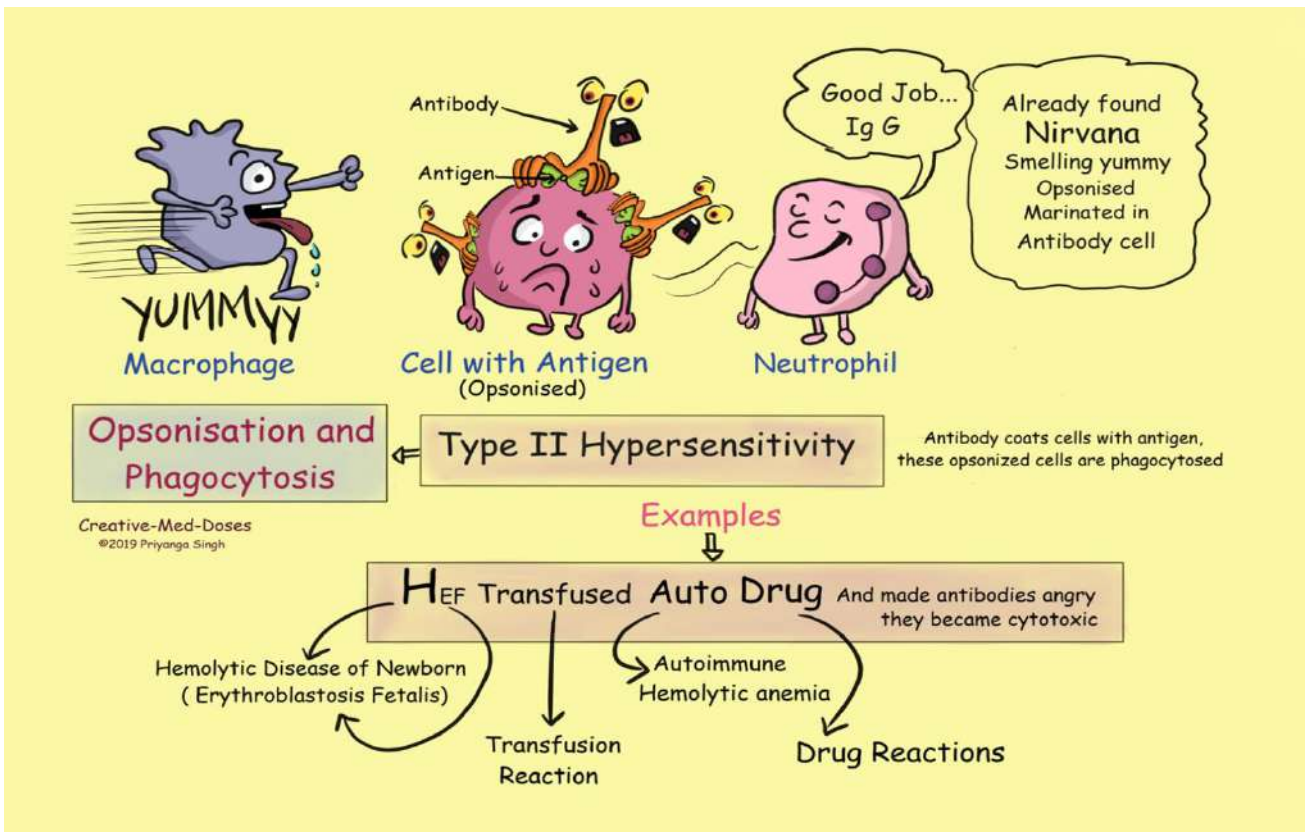
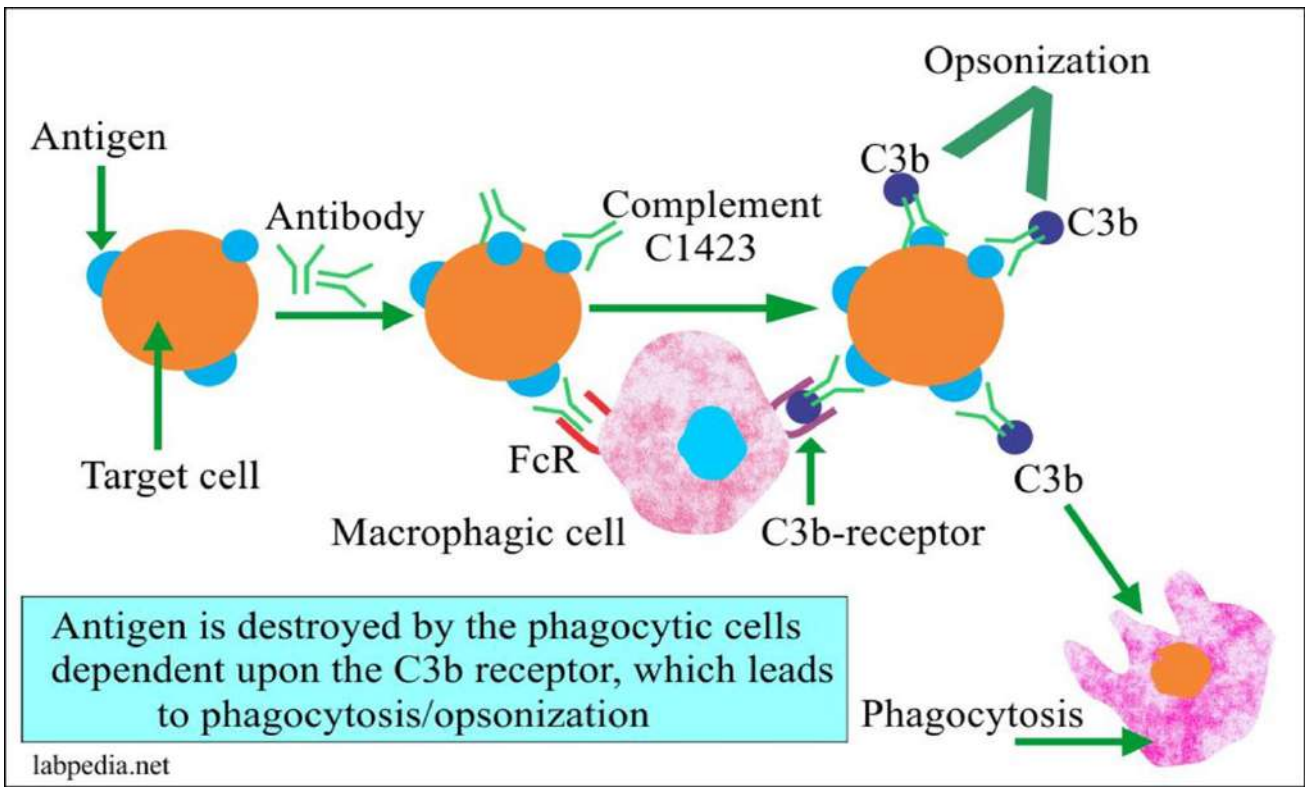


### Type II, Antibody-Mediated Cytotoxic Disorders:

They are the end result of direct interaction between IgG and IgM class antibodies and tissue or cell surface antigens, with subsequent activation of complement- or antibody dependent cell-mediated cytotoxicity.

Examples of type II reactions include **mismatched blood transfusions**, **hemolytic disease of the newborn** caused by ABO or Rh incompatibility, and **certain drug reactions**. In the latter, the binding of certain drugs to the surface of red or white blood cells elicits an antibody and complement response that lyses the drug-coated cell. Lytic drug reactions can produce transient anemia, leukopenia, or thrombocytopenia, which are corrected by the removal of the offending drug.



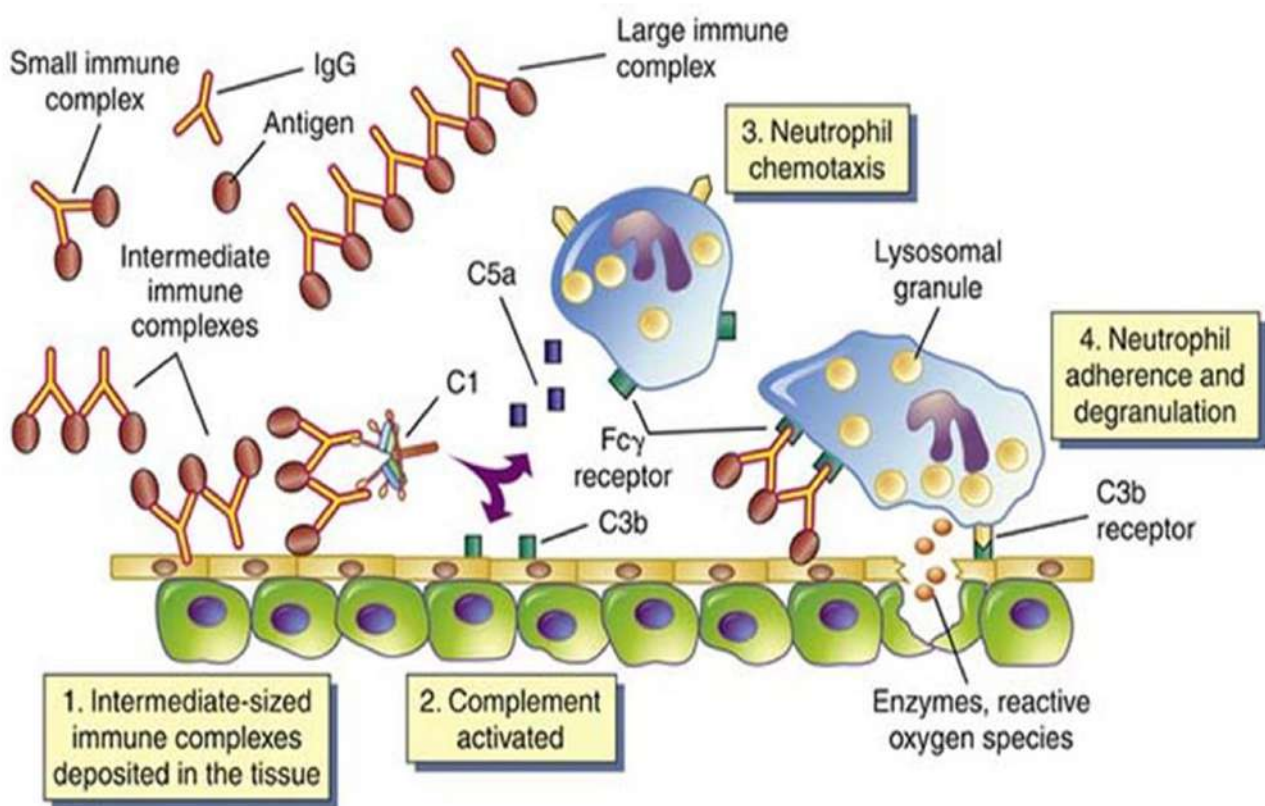


### Type III, Immune-Complex Disorders:

They are mediated by the formation of insoluble antigen-antibody complexes that activate complement which will generate chemotactic and vasoactive mediators that cause tissue damage by a variety of mechanisms, including alterations in blood flow, increased vascular permeability, and the destructive action of inflammatory cells.

The reaction occurs when the antigen combines with antibody, whether in the circulation (circulating immune complexes) or at extravascular sites where antigen may have been deposited.

Immune complexes formed in the circulation produce damage when they come in contact with the vessel lining or are deposited in tissues, including the renal glomerulus, skin venules, lung, and joint synovium.

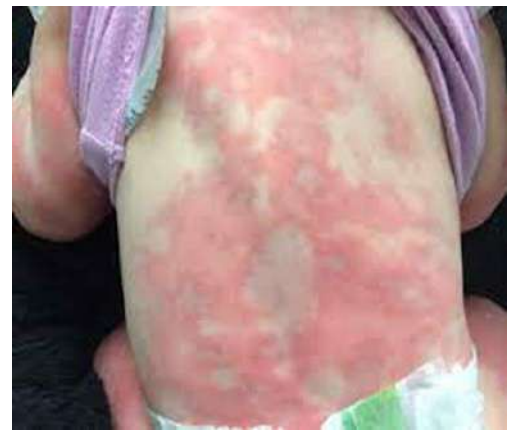

There are two general types of antigens that cause immune complex mediated injury:

- 1- Exogenous antigens such as viral and bacterial proteins.
- 2- Endogenous antigens such as self-antigens associated with autoimmune disorders.

Type III reactions are responsible for the **acute glomerulonephritis** that follows a streptococcal infection and the manifestations of **autoimmune disorders** such as systemic lupus erythematosus(SLE). Unlike type II reactions, in which the damage is caused by binding of antibody to body cells, the harmful effects of type III reactions are indirect (*i.e.*, secondary to the inflammatory response induced by activated complement).

**Acute serum sickness** is the type of a systemic immune complex disease. Serum sickness is a syndrome consisting of rash, lymphadenopathy, arthralgia, and occasionally neurologic disorders that appeared 7 or more days after injections of horse antisera for prevention of tetanus. Although this therapy is not used today, the name remains.



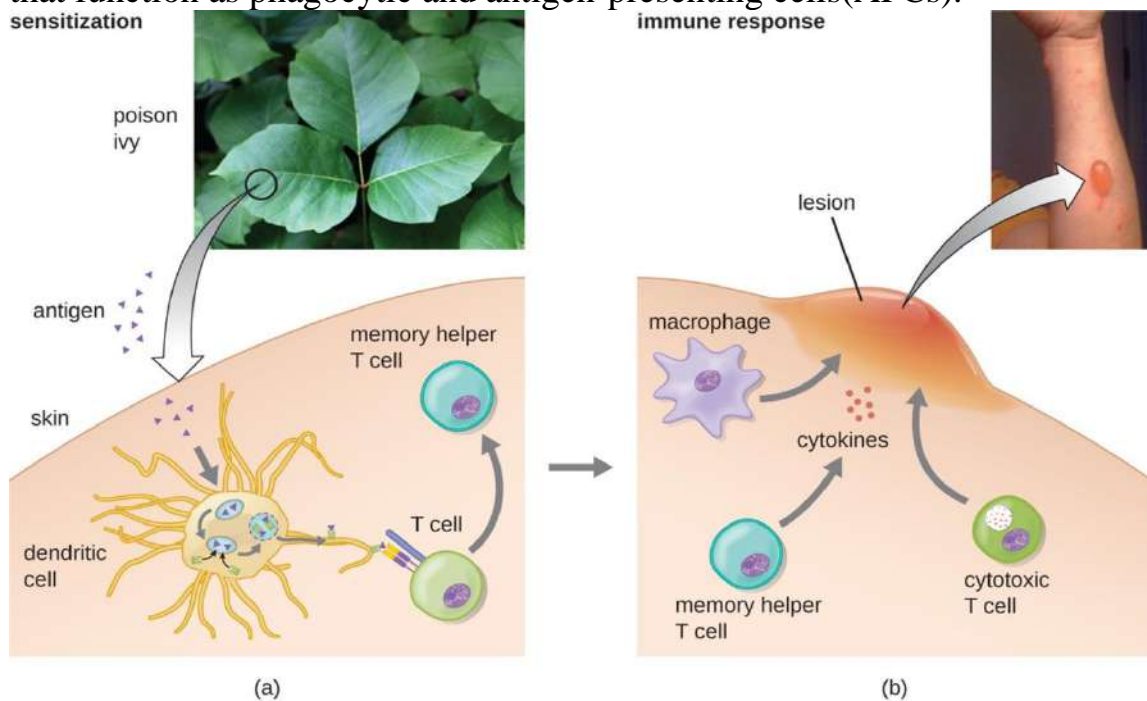
The most common causes of this allergic disorder include: **antibiotics** (especially penicillin), **various foods**, **drugs**, and **insect venoms**. Serum sickness is triggered by the deposition of insoluble antigen-antibody (IgM and IgG) complexes in blood vessels, joints, heart, and kidney tissue. The deposited complexes activate complement, increase vascular permeability, and recruit phagocytic cells, all of which can promote focal tissue damage and edema.

The signs and symptoms include:

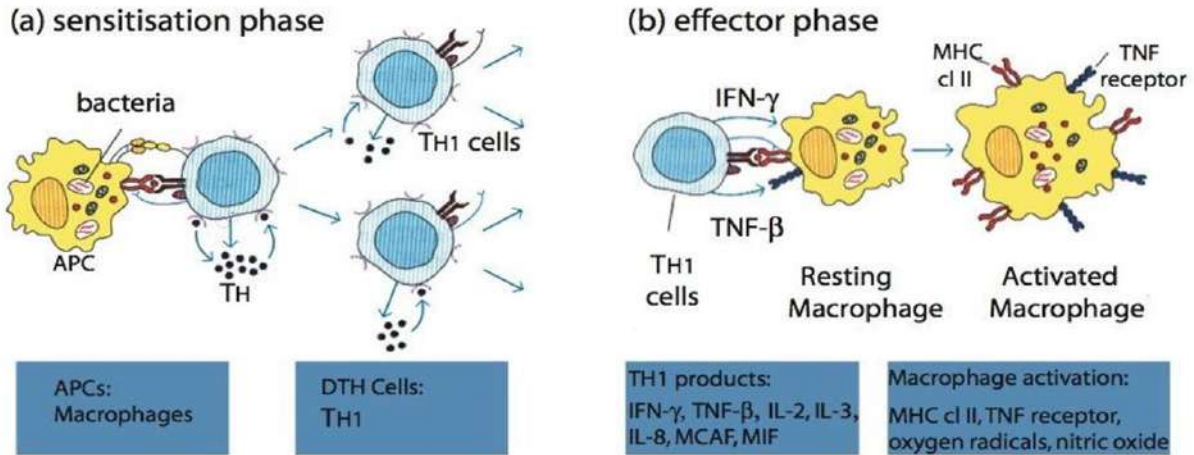
- 1-Urticaria. 2- Patchy or generalized rash.
- 3- Extensive edema (face, neck, and joints). 4- fever.

**Type IV, Cell-Mediated Hypersensitivity Disorders:**

It is mediated by cells, **not antibodies**; occur 24 to 72 hours after exposure of a sensitized individual to the offending antigen. They are mediated by helper T lymphocytes that are directly cytotoxic or that secrete inflammatory mediators like cytokines that cause tissue changes. Cytokines will attract T or B lymphocytes as well as monocytes, neutrophils, eosinophils, and basophils. Some of the cytokines promote differentiation and activation of macrophages that function as phagocytic and antigen-presenting cells (APCs).

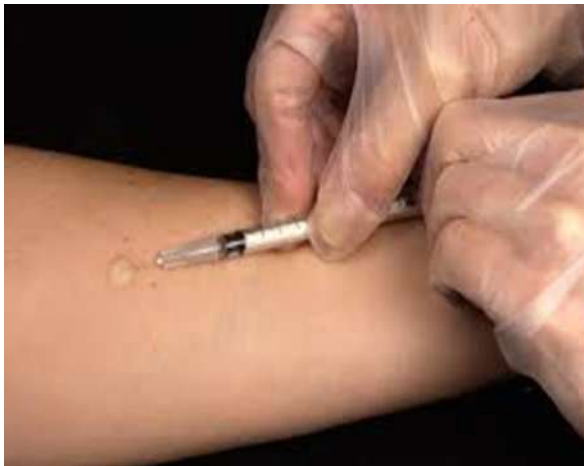

# Pathogenesis of type IV hypersensitivity



Goldsy RA et al. Immunology 5th Ed, 2003, p 384

The best-known type of delayed hypersensitivity response is the **reaction to the tuberculin test**, in which inactivated tuberculin or purified protein derivative is injected under the skin. In a previously sensitized person, redness and indurations of the area develop within 8 to 12 hours, reaching a peak in 24 to 72 hours. A positive tuberculin test indicates that a person has had sufficient exposure to the *M. tuberculosis* organism to incite a hypersensitivity reaction.



Certain types of antigens induce cell mediated immunity with an especially pronounced macrophage response. This type of delayed hypersensitivity commonly develops in response to particulate antigens that are **large, insoluble**, and difficult to eliminate. The accumulated macrophages are often transformed into so-called **epithelioid cells** because they resemble epithelium. A microscopic aggregation of epithelioid cells, which usually are surrounded by a layer of

lymphocytes, is called a **granuloma**. Inflammation that is characterized by type IV hypersensitivity is called **granulomatous inflammation**.

Direct T-cell-mediated cytotoxicity, will cause necrosis of antigen-bearing cells. It is important in the eradication of virus infected cells. **Autoimmune diseases** such as( Hashimoto's thyroiditis, and host-versus-graft or graft-versus host transplant rejection) , Allergic **contact dermatitis** and hypersensitivity **pneumonitis** are presented as examples of cell mediated hyper sensitivity reactions.

# Oral pathology

Dr. Ahlam Thabet

Lec. 14

## Oral mucosal lesions

The oral cavity is lined by a membrane composed of stratified squamous epithelium. This epithelium serves as a cover for the oral soft tissues as a barrier to the entry of external pathogenic factors. Depending on the intraoral site, the stratified squamous epithelium may be non-keratinized, orthokeratinized or parakeratinized. Knowledge of clinical aspects of oral mucosal diseases must be correlated with oral anatomy. E.g. recurrent aphthous stomatitis occurs primarily on the non-keratinized mucosa, whereas recurrent herpes simplex infections occur almost exclusively on the keratinized mucosa.

- Keratinized mucosa** (functional mucosa) e.g. gingiva and hard palate.
- Non –keratinized mucosa** (lining mucosa) e.g. floor of the mouth and buccal mucosa.
- Specialized mucosa** e.g. dorsal surface of the tongue .

In general, oral mucosal lesions could be divided into:

- **Oral infections**
  - Viral
  - Bacterial
  - Fungal
- **Ulcerative conditions**
- **Vesiculobullous diseases**
- **White lesions**

The clinician should be familiar with the following terms :

**Macule:** Focal area of color change which is not elevated or depressed in relation to its surroundings.

**Papule:** Solid, raised lesion which is less than 5 mm in diameter.

**Nodule:** Solid, raised lesion which is greater than 5 mm in diameter.

**Sessile:** Describing a tumor or growth whose base is the widest part of the lesion.

**Pedunculated:** Describing a tumor or growth whose base is narrower than the widest part of the lesion.

**Papillary:** Describing a tumor or growth exhibiting numerous surface projections.

**Verrucous:** Describing a tumor or growth exhibiting a rough, warty surface.

**Vesicle:** Superficial blister, 5 mm or less in diameter, usually filled with clear fluid.

**Bulla:** Large blister, greater than 5 mm in diameter.

**Pustule:** Blister filled with purulent exudate.

**Ulcer:** Lesion characterized by loss of the surface epithelium and frequently some of the underlying connective tissue. It often appears depressed or excavated.

**Erosion:** Superficial lesion. Often arising secondary to rupture of a vesicle or bulla, that is characterized by partial or total loss of the surface epithelium.

**Fissure:** Narrow, slit like ulceration or groove.

**Plaque:** Lesion that is slightly elevated and is flat on its surface.

**Petechia:** Round, pinpoint area of hemorrhage.

**Ecchymosis:** Nonelevated area of hemorrhage, larger than a petechia.

**Telangiectasia:** Vascular lesion caused by dilatation of a small, superficial blood vessel.

**Cyst:** Pathologic epithelium-lined cavity often filled with liquid or semi-solid contents.

### **Microscopic changes of oral mucosa:**

#### ❖ Epithelial changes:

**Hyperkeratosis:** refers to an increase in the thickness of stratum corneum, which yields a white appearance of the oral mucosa clinically. This hyperkeratinizations can occur in keratinized area or abnormally in non-keratinized area. When the nuclei are lost from the surface the condition is named (hyperorthokeratosis). When remnants of the nuclei persist the condition is named (hyperparakeratosis).

**Hyperplasia:** an increase in the thickness of the epithelium from surface to basal cell layer.

**Acanthosis :** An increase in the prickle cell layer is termed .

**Epithelial dysplasia** (dyskeratosis or epithelial atypia): an abnormal growth pattern of epithelial cells. Generally indicates a premalignant change.

**Acantholysis :** loss of adhesion between the cells of prickle cell layer (spinous cell layer) the cells appear to fall apart, which lead to vesicle formation, e.g. pemphigus vulgaris.

#### ❖ Connective tissue changes:

- Inflammatory infiltrate are common, as chronic inflammatory cells infiltration, e.g. gingivitis.

- Hyperplasia of connective tissue refers to an increase in the amount of collagen fibers.

- Ductal and glandular distension could be seen in many accessory mucous glands due to pressure and obstruction.



# Oral infections

## I-Bacterial Infections

### Tonsillitis and Pharyngitis

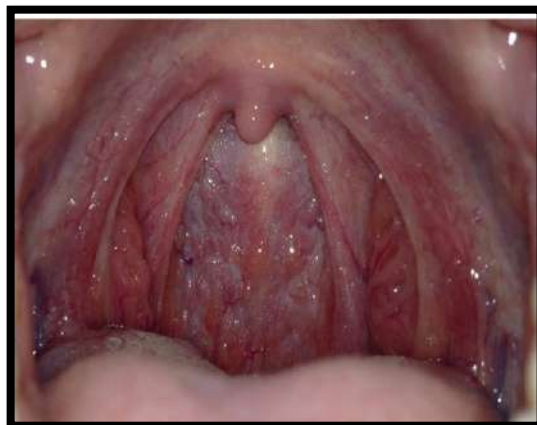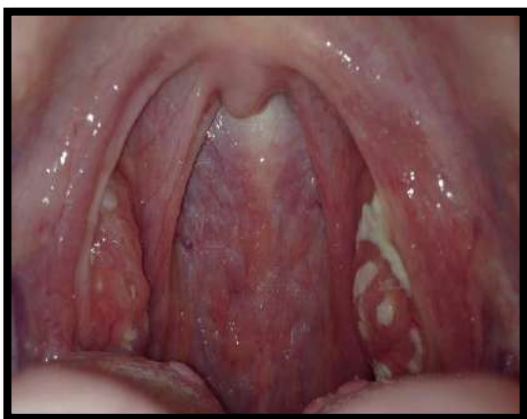Tonsillitis and Pharyngitis are extremely common and may be caused by many different organisms. Group A streptococci is responsible for 20% to 30% of acute pharyngitis cases in children and 5% to 15% of cases in adults. Spread is typically by person-to-person contact through respiratory droplets or oral secretions, with a short incubation period of 2 to 5 days.

#### **Clinical Features**

Although the infection can occur at any age, the greatest prevalence occurs in children 5 to 15 years old, with most cases in temperate climates arising in the winter or early spring.

The signs and symptoms of tonsillitis and pharyngitis vary from mild to intense. Common findings include sudden onset of sore throat, temperature of 101° to 104° F, dysphagia, tonsillar hyperplasia, redness of the oropharynx and tonsils, palatal petechiae, cervical lymphadenopathy, and a yellowish tonsillar exudate that may be patchy or confluent.

Systemic symptoms, such as headache, malaise, anorexia, abdominal pain, and vomiting, may be noted, especially in younger children.



### **Treatment :**

Streptococcal pharyngitis usually is self-limited and resolves spontaneously within 3 to 4 days after onset of symptoms.

The oral antibiotic of choice for group A streptococci is either penicillin V or amoxicillin. Other choices for penicillin-allergic patients include azithromycin, clindamycin, cephalosporins and macrolides (such as, erythromycin or clarithromycin).

### **Scarlet Fever (Scarlatina)**

Scarlet fever is a systemic infection produced by group A,  $\beta$ -hemolytic streptococci. The disease begins as a streptococcal tonsillitis with pharyngitis in which the organisms elaborate an erythrogenic toxin that attacks the blood vessels and produces the characteristic skin rash.

### **Clinical Features:**

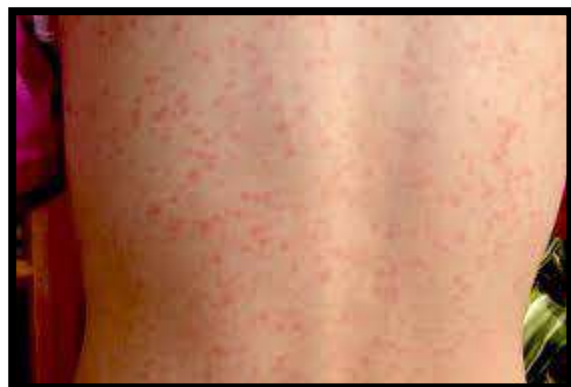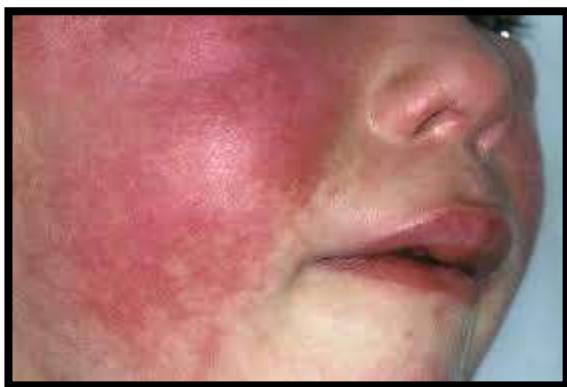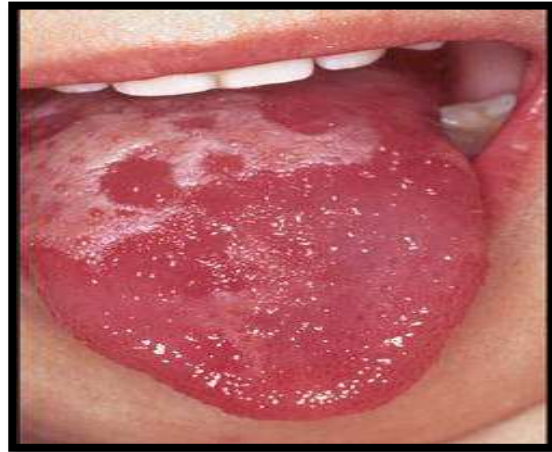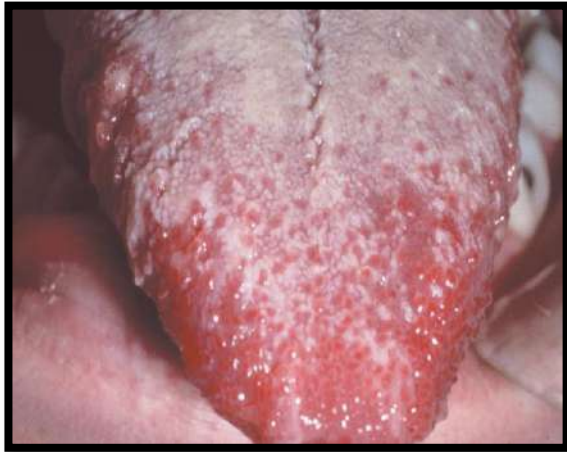Scarlet fever is most common in children from the ages of 3 to 12 years. The tonsils, soft palate, and pharynx become erythematous and edematous, and the tonsillar crypts may be filled with a yellowish exudate. In severe cases, the exudates may become confluent and can resemble diphtheria. Scattered petechiae may be seen on the soft palate in up to 10% of affected patients. During the first 2 days, the dorsal surface of the tongue demonstrates a white coating through which only the fungiform papillae can be seen; this has been called white strawberry tongue.

By the fourth or fifth day, red strawberry tongue develops when the white coating desquamates to reveal an erythematous dorsal surface with hyperplastic fungiform papillae.

Classically, in untreated cases, fever develops abruptly around the second day. The patient's temperature peaks at approximately 103° F and returns to normal within 6 days. Abdominal pain, headache, malaise, nausea, and vomiting frequently are present.

The exanthematous rash develops within the first 2 days and becomes widespread within 24 hours. The classic rash of scarlet fever is distinctive and often is

described as a “sunburn with goose pimples.” Pinhead punctate areas that are normal in color project through the erythema, giving the skin of the trunk and extremities a sandpaper texture. The rash is more intense in areas of pressure and skin folds. In contrast, the skin of the face usually is spared or may demonstrate erythematous cheeks with circumoral pallor. The rash usually clears within 1 week, and then a period of desquamation of the skin occurs.



### **Treatment:**

The oral antibiotic of choice for group A streptococci is either penicillin V or amoxicillin. Other choices for penicillin-allergic patients include azithromycin, clindamycin, cephalosporins such as, cefadroxil or cephalexin), and macrolides (such as erythromycin or clarithromycin). Ibuprofen can be used to reduce the fever and relieve the associated discomfort.

## Necrotizing Ulcerative Gingivitis

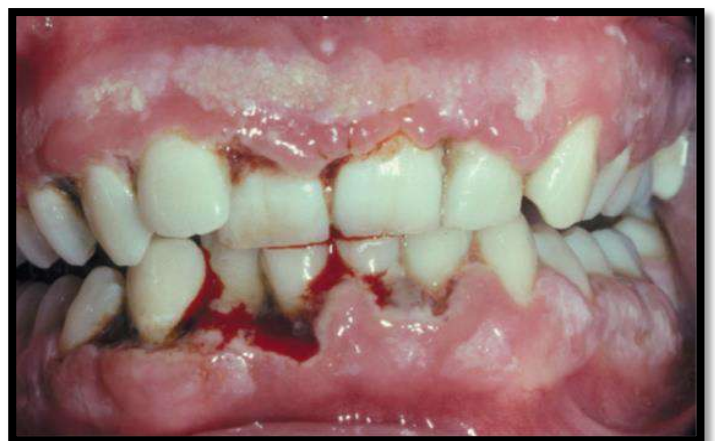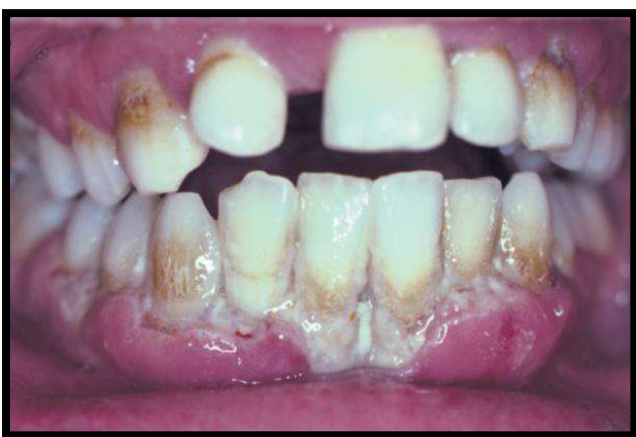Necrotizing ulcerative gingivitis is a relatively rare specific infectious gingival disease of young persons. *Fusobacterium nucleatum*, *Treponema vincentii*, and probably other bacteria play an important role. Predisposing factors are emotional stress, smoking, poor oral hygiene, local trauma, and HIV infection.

### **Clinical features:**

The characteristic clinical feature is painful necrosis of the interdental papillae and the gingival margins, and the formation of craters covered with a gray pseudo-membrane. Spontaneous gingival bleeding, halitosis, and intense salivation are common. Fever, malaise, and lymphadenopathy are less common. Rarely, the lesions may extend beyond the gingiva (necrotizing ulcerative stomatitis).

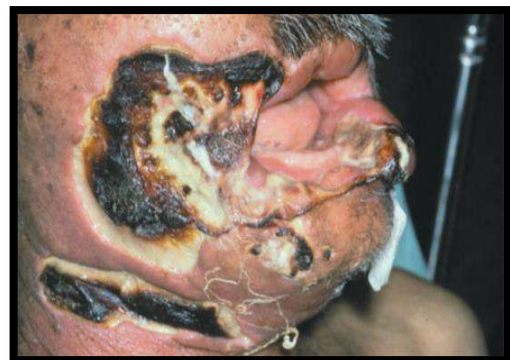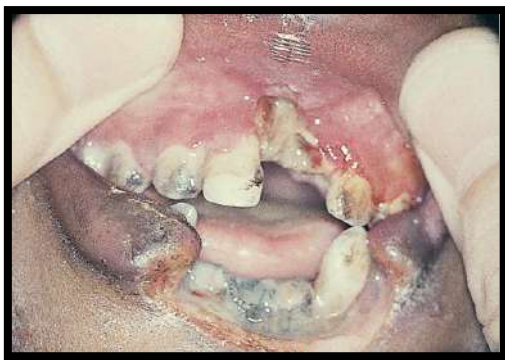### **Treatment:**

Systemic metronidazole and oxygen-releasing agents topically are the best therapy in the acute phase, followed by a mechanical gingival treatment.



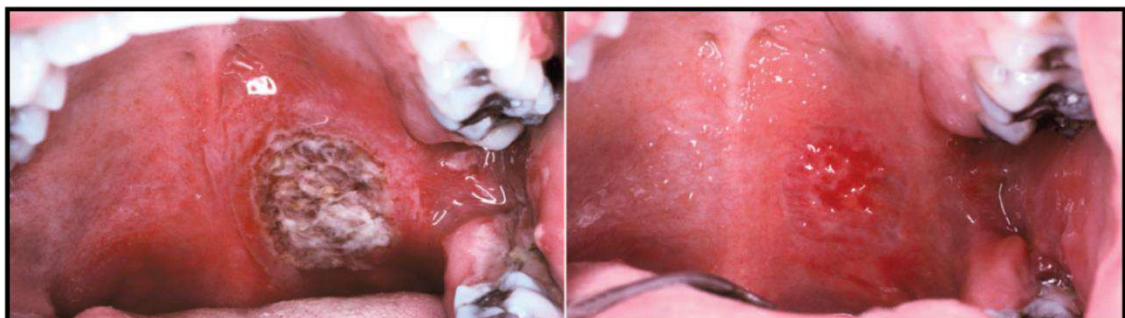
## Noma

Noma, also known as cancrum oris and gangrenous stomatitis, is a devastating disease of malnourished children that is characterized by a destructive process of the orofacial tissues. The condition is rare in developed countries. Necrosis of tissue occurs as a consequence of invasion by anaerobic bacteria such as *Fusobacterium necrophorum*, *Prevotella intermedia* and spirochaetes in a host whose systemic health is significantly compromised.



### ***Clinical Features :***

It typically affects children. also can occur in adults with a major debilitating disease (e.g., diabetes mellitus, leukemia, lymphoma, or HIV infection).The initial lesion of noma is a painful ulceration, usually of the gingiva or buccal mucosa, which spreads rapidly and eventually becomes necrotic. Denudation of involved bone may follow, eventually leading to necrosis and sequestration. Teeth in the affected area may become loose and may exfoliate. Penetration of organisms into the cheek, lip, or palate may also occur, resulting in fetid necrotic lesions.



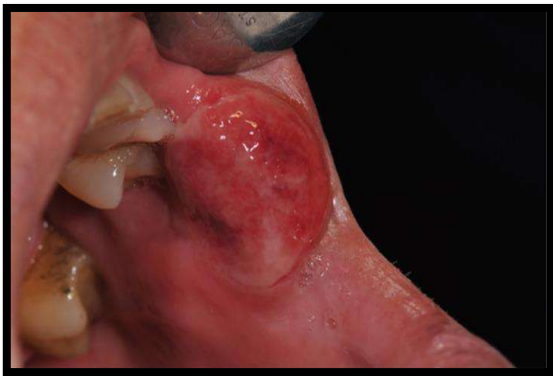**Treatment:** Therapy involves treating the underlying predisposing condition, as well as the infection itself. Therefore fluids, electrolytes, and general nutrition are restored, along with the introduction of antibiotics.

## Syphilis

Syphilis is a relatively common sexually transmitted disease Caused by *Treponema pallidum*.

### ***Clinical features:***

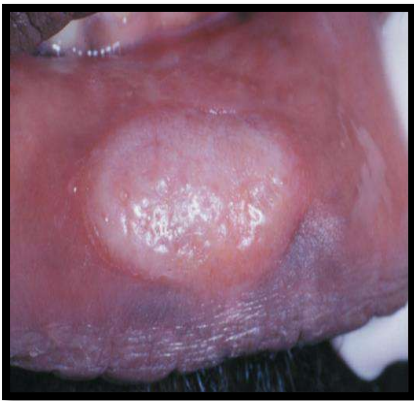Syphilis may be acquired (common) or congenital (rare). Acquired syphilis is classified as primary, secondary and tertiary. The characteristic lesion in the primary stage is the chancre that appears at the site of inoculation, usually three weeks after the infection. Oral chancre appears in about 5–10% of cases, and clinically presents as a painless ulcer with a smooth surface, raised borders, and an indurated base. Regional lymphadenopathy is a constant finding.



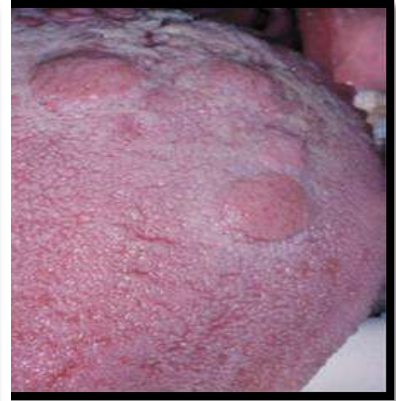
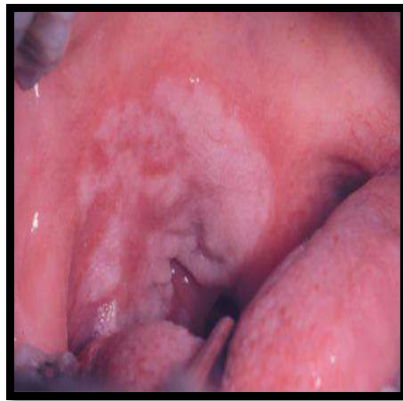
Oral Chancre

The secondary stage begins 6–8 weeks after the appearance of the chancre, and lasts for 2–10 weeks. Oral lesions are mucous patches (common), macular syphilids, and condylomata lata (rare). Constitutional symptoms and signs (malaise, low-grade fever, headache, lacrimation, sore throat, weight loss, myalgias and multiple arthralgias, generalized lymphadenopathy) as well as

cutaneous manifestations (macular syphilids, papular syphilids, condylomata lata, nail involvement, hair loss, atypical rash, etc.) are constant findings.

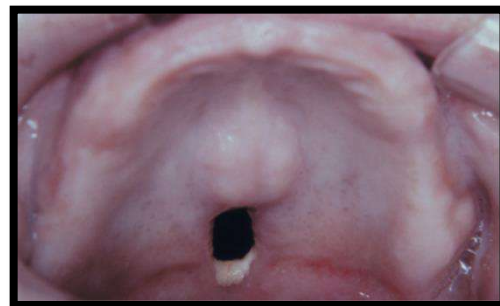

mucous patches

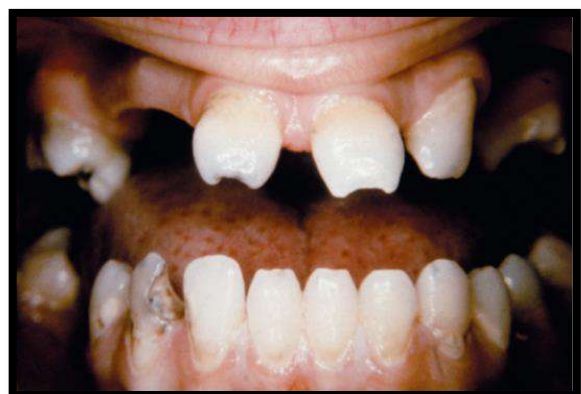
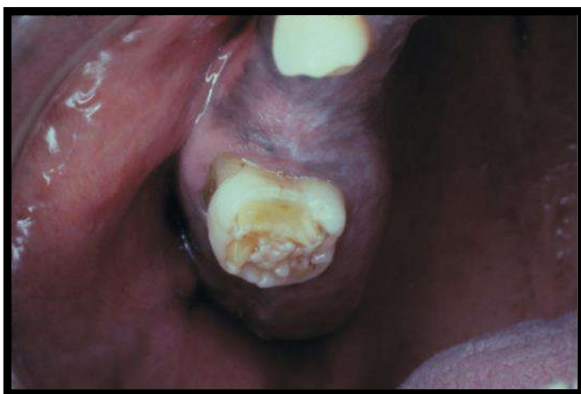
condylomata lata

Tertiary syphilis begins after a period of 4–7 years. Oral lesions are gumma, atrophic glossitis, and interstitial glossitis.

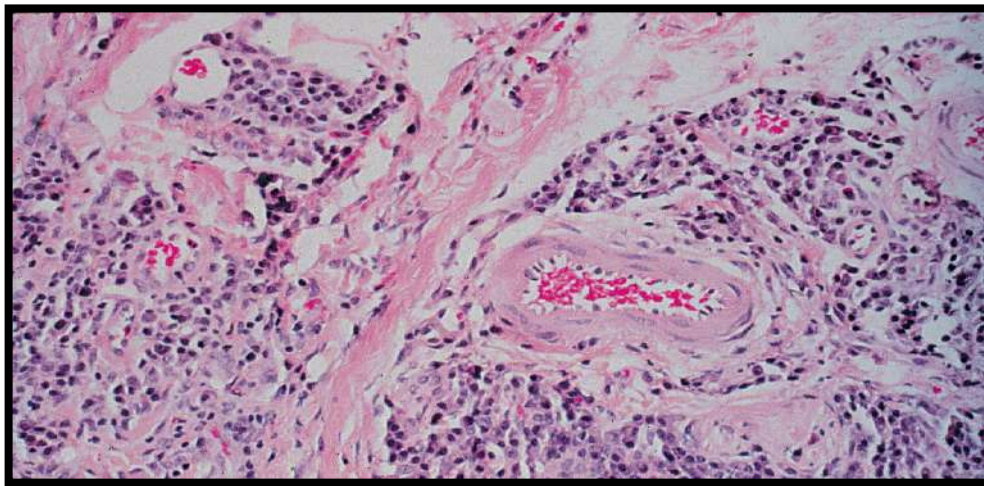


The most common oral lesions in congenital syphilis are a high-arched palate, short mandible, Hutchinson's teeth, and Moon's or mulberry molars.

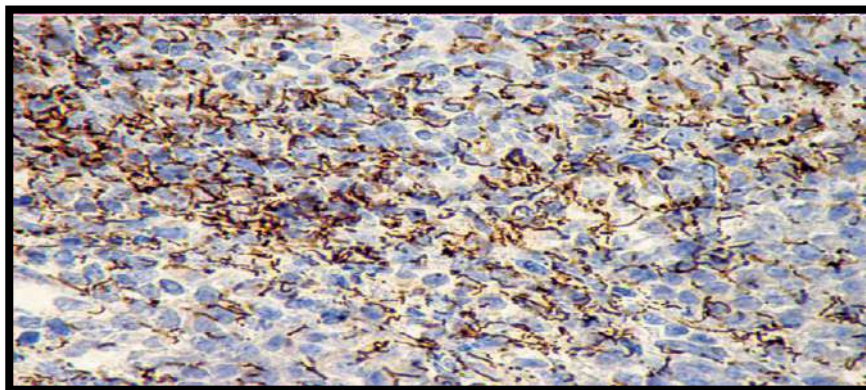


### ***Histopathology.***

The basic tissue response to *T. pallidum* infection consists of a proliferative endarteritis and infiltration of plasma cells. Spirochetes can be demonstrated in the tissues of various lesions of syphilis using silver stains, although they may be scant in tertiary lesions. Gumma may show necrosis and greater numbers of macrophages, resulting in a granulomatous lesion that is similar to other conditions, such as tuberculosis (TB).



A chronic perivascular inflammatory infiltrate of plasma cells and lymphocytes.



Immunoperoxidase reaction for *Treponema pallidum* demonstrating numerous spirochetes in the epithelium.

***Treatment.*** Penicillin is the antibiotic of choice. Erythromycin or cephalosporins are good alternatives.

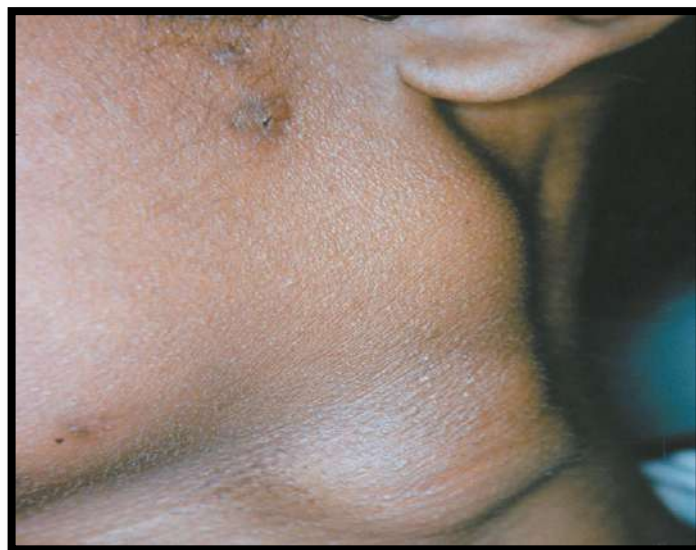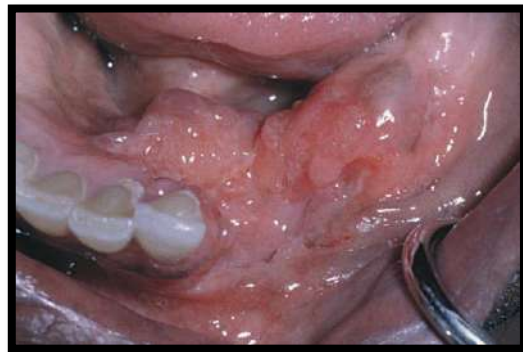

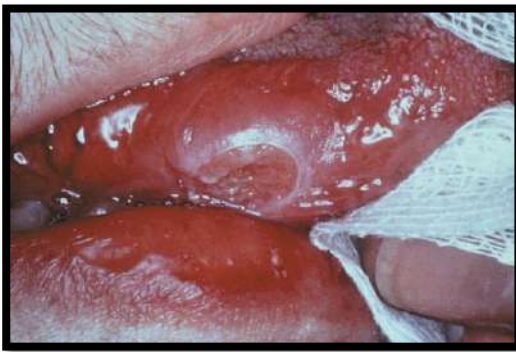
## Tuberculosis

Tuberculosis is a chronic, granulomatous, infectious disease that primarily affects the lungs, caused by *Mycobacterium tuberculosis*.

### *Clinical features:*

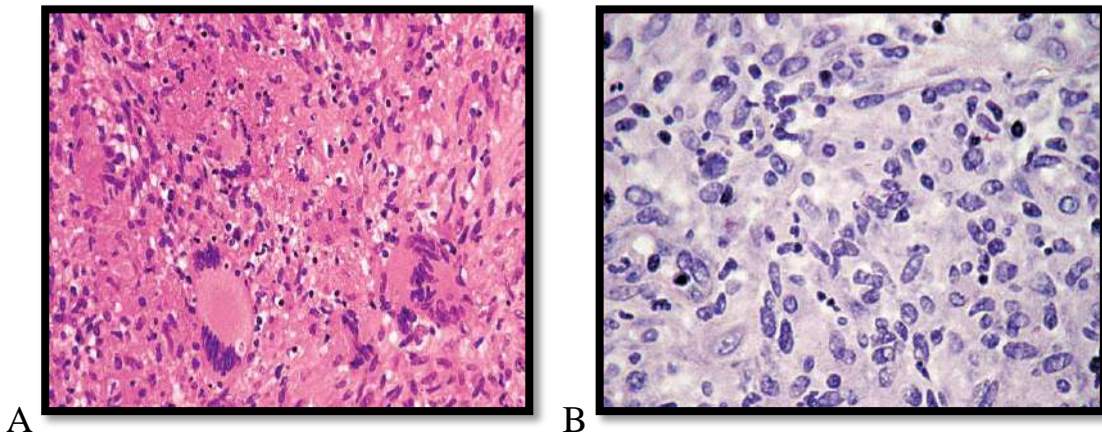
The oral lesions are rare, and usually secondary to pulmonary tuberculosis. The tuberculous ulcer is the most common feature. Clinically, the ulcer is painless and irregular, with a thin undermined border and a vegetating surface, usually covered by a gray-yellowish exudate. The surrounding tissues are inflamed and indurated. The dorsum of the tongue is the most commonly affected site, followed by the lip, buccal mucosa, and palate. Osteomyelitis of the jaws, periapical granuloma, regional lymphadenopathy, and scrofula are less common oral manifestations.



### ***Histopathology.***

The basic microscopic lesion of TB is granulomatous inflammation, in which granulomas show central caseous necrosis. In tissues, *M. tuberculosis* incites a characteristic macrophage response, in which focal zones of macrophages become surrounded by lymphocytes and fibroblasts. The macrophages develop an abundant eosinophilic cytoplasm, giving them a superficial resemblance to epithelial cells; for this reason, they are frequently called epithelioid cells. Fusion of macrophages results in the appearance of Langerhans giant cells, in which nuclei are distributed around the periphery of the cytoplasm. As the granulomas age, central necrosis occurs; this is usually referred to as caseous necrosis because of the gross cheesy texture of these zones.

A Ziehl-Neelsen or Fite stain must be used to confirm the presence of the organism in the granulomas, because several infectious and noninfectious conditions may produce a similar granulomatous reaction.



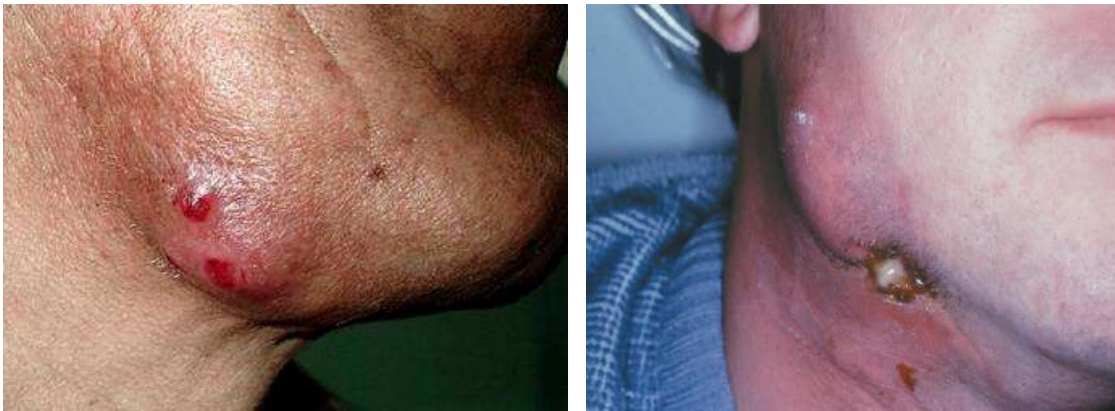(A) Sheets of histiocytes are intermixed with multinucleated giant cells and areas of necrosis.(B) Acid-fast stain exhibiting scattered mycobacterial organisms presenting as small red rods.

## Actinomycosis

Actinomycosis is a chronic bacterial disease caused by *Actinomyces israelii*, an anaerobic, gram-positive bacterium. Infection usually appears after trauma, surgery, or previous infection.

### *Clinically:*

It typically presents as swelling of the mandible that may simulate a pyogenic infection. The lesion may become indurated and eventually may form one or more draining sinuses, leading from the medullary spaces of the mandible to the skin of the neck. The clinical course ranges from acute to chronic. The skin lesions are indurated and are described as having a “woody hard” consistency. Pus draining from the chronic lesion may contain small yellow granules, known as sulfur granules, which represent aggregates of *A. israelii* organisms. Radiographically, this infection presents as a lucency with irregular and ill-defined margins.

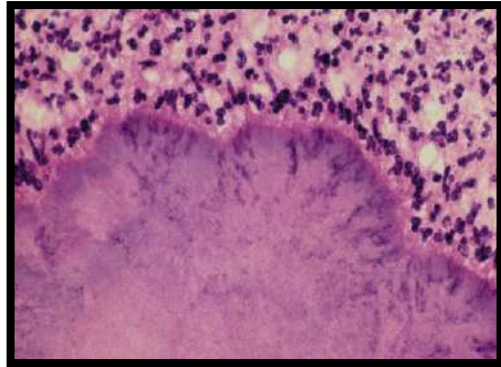
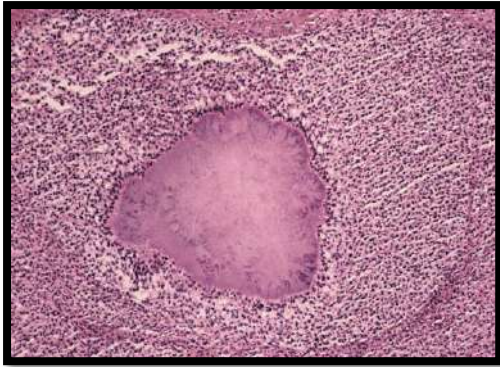


### *Histopathology.*

A granulomatous inflammatory response with central abscess formation is seen in actinomycosis. At the center of the abscesses, distinctive colonies of gram-positive organisms may be seen. Radiating from the center of the colonies are numerous filaments with clubbed ends.

### *Treatment.*

Long-term, high-dose penicillin or penicillin analogs are the required antibiotic regimen for actinomycosis.



## Oral Pathology

### Odontogenic Cysts

Odontogenic cysts and tumors constitute an important aspect of oral and maxillofacial pathology . Odontogenic cysts are encountered relatively commonly in dental practice ,while odontogenic tumors, by contrast, are uncommon lesions.

A cyst is defined as an epithelial-lined pathologic cavity . Cysts of the maxilla, mandible, and perioral regions vary markedly in histogenesis, incidence, behavior, and treatment. Most jaw cysts are lined by epithelium that is derived from odontogenic epithelium, so these are referred to as odontogenic cysts. Odontogenic cysts are sub classified as developmental or inflammatory in origin .Developmental cysts are of unknown origin, but they do not appear to be the result of an inflammatory reaction.Inflammatory cysts are the result of inflammation.

#### **DEVELOPMENTAL CYSTS**

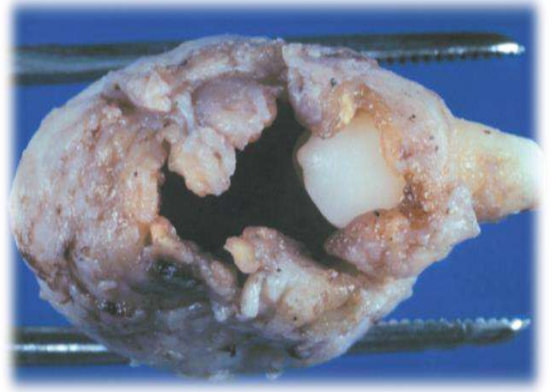
1. Dentigerous cyst
2. Eruption cyst
3. Odontogenic keratocyst
4. Orthokeratinized odontogenic cyst
5. Gingival (alveolar) cyst of the newborn
6. Gingival cyst of the adult
7. Lateral periodontal cyst
8. Calcifying odontogenic cyst .
9. Glandular odontogenic cyst.

#### **INFLAMMATORY CYSTS**

1. Periapical (radicular) cyst
2. Residual periapical (radicular) cyst
3. Buccal bifurcation cyst.

## Dentigerous Cyst

- Dentigerous or follicular cysts are the **second most common** type of odontogenic cyst, and the **most common developmental cyst of the jaws**. By definition, a dentigerous cyst is attached to the tooth cervix at the enamel-cementum junction, and it encloses the crown of the unerupted tooth.



### Etiology and Pathogenesis.

- A dentigerous cyst develops from proliferation of the enamel organ remnant or reduced enamel epithelium. As with other cysts, expansion of the dentigerous cyst is related to an increase in cyst fluid osmolality and the release of bone-resorbing factors.

### Clinical Features:

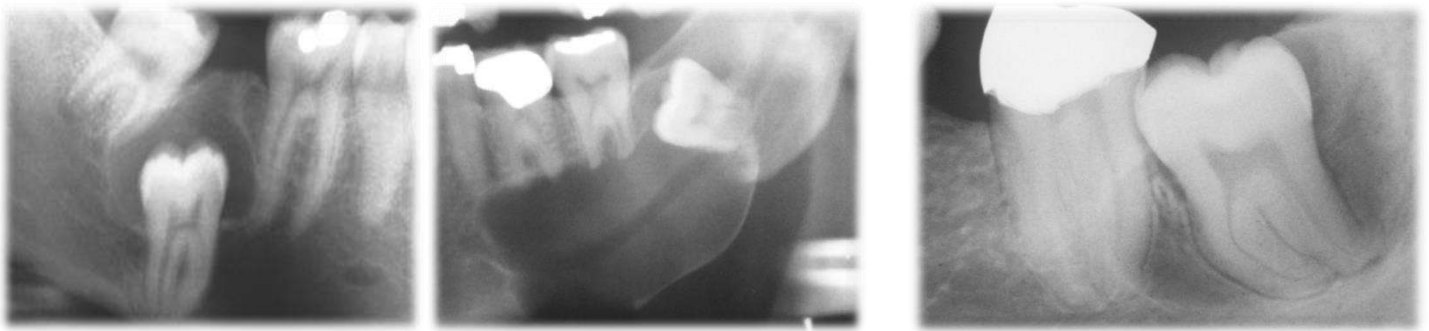
Dentigerous cysts are most commonly seen in association with third molars and maxillary canines, which are the most commonly impacted teeth. The highest incidence of dentigerous cysts occurs during the 2nd and 3rd decades. A greater incidence in males has been noted. Symptoms generally are absent, and delayed eruption is the most common indication of dentigerous cyst formation.

This cyst is capable of achieving significant size, occasionally with associated cortical bone expansion, but rarely does it reach a size that predisposes the patient to a pathologic fracture.

### Radiographically:

A dentigerous cyst presents as a well-defined, unilocular radiolucency with corticated margins in association with the crown of an unerupted tooth. The unerupted tooth is often displaced.

These cysts range in size from several millimeters to several centimeters, where they may compromise jawbone integrity and produce facial asymmetry. Resorption of roots of adjacent erupted teeth may occasionally be seen. The cyst-to-crown relationship shows several radiographic variations. In the **central variety (a)**, which is the most common, the cyst surrounds the crown of the tooth and the crown projects into the cyst. **The lateral variety (b)** is usually associated with mesioangular impacted mandibular third molars that are partially erupted. The cyst grows laterally along the root surface and partially surrounds the crown. In the **circumferential variant (c)**, the cyst surrounds the crown and extends for some distance along the root so that a significant portion of the root appears to lie within the cyst.



A

B

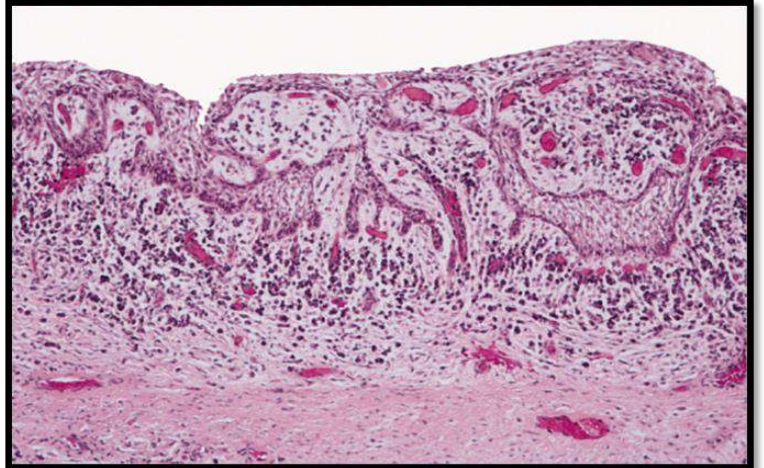
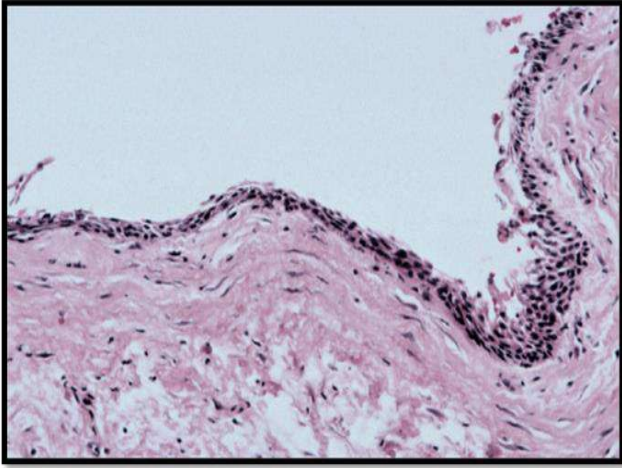
C

Rarely, a third molar may be displaced to the lower border of the mandible or higher up into the ascending ramus. Maxillary anterior teeth may be displaced into the floor of the nose, and other maxillary teeth may be moved through the maxillary sinus to the floor of the orbit. Dentigerous cysts may displace the involved tooth for a considerable distance. Root resorption of adjacent erupted teeth can occur.

A variant of the dentigerous cyst arising at the bifurcation of molar teeth is the paradental cyst or buccal bifurcation cyst. Originally, this cyst was described along the buccal root surface of partially erupted mandibular third molar teeth, but later involvement of other mandibular molar teeth was recognized. Often in these latter circumstances, the molar teeth are fully erupted. Radiographically, paradental cysts are characterized as well-circumscribed radiolucencies in the buccal bifurcation region. Often buccal tipping of the crown can be demonstrated by occlusal radiography.

### Histopathology:

Microscopically, the dentigerous cyst is formed by a fibrous connective tissue wall and is lined by stratified squamous epithelium. In an uninfamed dentigerous cyst, the epithelial lining is nonkeratinized and tends to be approximately four to six cell layers thick. On occasion, numerous mucous cells, ciliated cells, and, rarely, sebaceous cells may be found in the lining of the epithelium. The epithelium-connective tissue junction is generally flat, although in cases of secondary inflammation, epithelial hyperplasia may be noted.



### Treatment:

Removal of the associated tooth and enucleation of the pericoronal soft tissue component . In cases in which cysts affect significant portions of the mandible, an acceptable early treatment approach involves exteriorization or marsupialization of the cyst to allow for decompression and subsequent shrinkage of the lesion, thereby reducing the extent of surgery to be done at a later date.

Complications of untreated dentigerous cysts include transformation of the epithelial lining into an ameloblastoma and, rarely, carcinomatous transformation of the epithelial lining .

### Odontogenic Keratocyst/Keratocystic Odontogenic Tumor

OKCs/KCOTs may exhibit aggressive clinical behavior, a significant recurrence rate, and an association with nevoid basal cell carcinoma syndrome (NBCC). They are found anywhere in the jaws and can radiographically mimic other types of cysts. Microscopically, however, they have a consistent and unique appearance.

### Etiology and Pathogenesis :

It is generally agreed that OKCs/KCOTs develop from dental lamina remnants in the mandible and maxilla. However, origin of this cyst from extension of basal cells of the overlying oral epithelium has also been suggested.

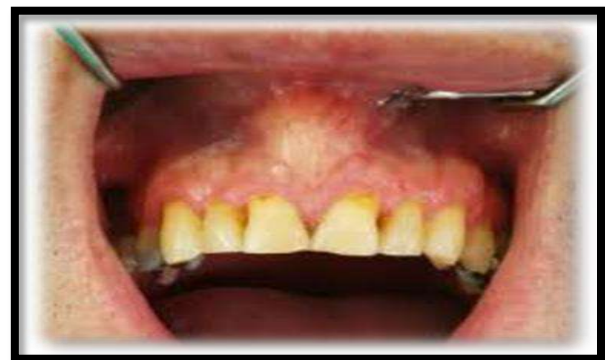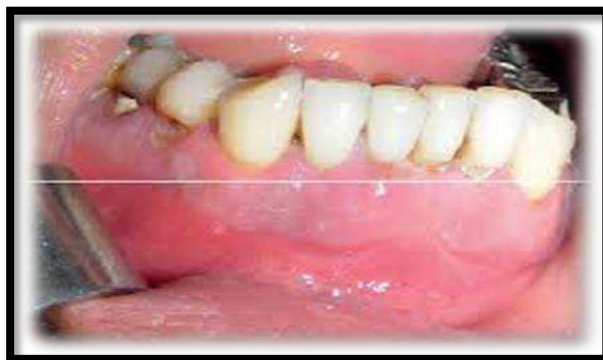This cyst shows a different growth mechanism and biologic behavior from the more common dentigerous cyst and radicular cyst. Most authors believe that dentigerous and radicular cysts continue to enlarge as a result of increased osmotic pressure within the lumen of the cyst. This mechanism does not appear to hold true for odontogenic



keratocysts. and their growth may be related to unknown factors inherent in the epithelium itself or enzymatic activity in the fibrous wall. Several investigators suggest that odontogenic keratocysts be regarded as benign cystic neoplasms rather than cysts. Although there are wide variations in the reported frequency of odontogenic keratocysts compared with that of other types of odontogenic cysts. several studies that include large series of cysts indicate that odontogenic keratocysts make up 3% to 11% of all odontogenic cysts.

### **Clinical Features:**

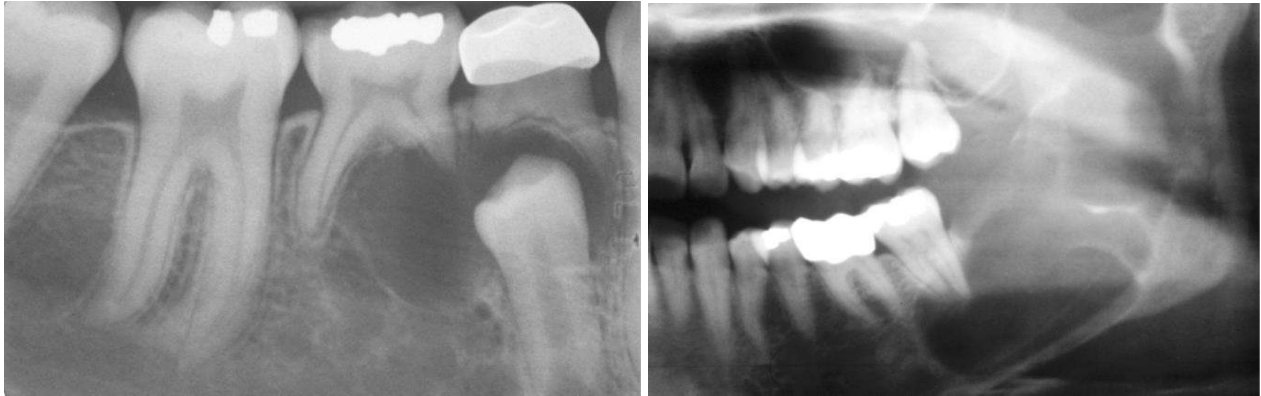OKCs/KCOTs are relatively common jaw cysts. .They occur at any age mostly ( 2nd and 3rd decades ).Lesions found in children are often reflective of multiple cysts as a component of NBCCS.OKCs/KCOTs represent 5% to 15% of all odontogenic cysts. Approximately 5% of patients with OKCs/KCOTs have multiple cysts, and another 5% have NBCCS. .OKCs /KCOTs are found in the mandible in 60% to 80% of cases, approximately a 2:1 ratio with a marked tendency to involve the posterior body and ramus. Small OKCs are usually asymptomatic and discovered only during the course of a radiographic examination. Larger OKCs may be associated with pain, swelling, or drainage. OKCs tend to grow in an anteroposterior direction within the medullary cavity of the bone without causing obvious bone expansion. This feature may be useful in differential clinical and radiographic diagnosis because dentigerous and radicular cysts of comparable size are usually associated with bony expansion.



### **Radiographically:**

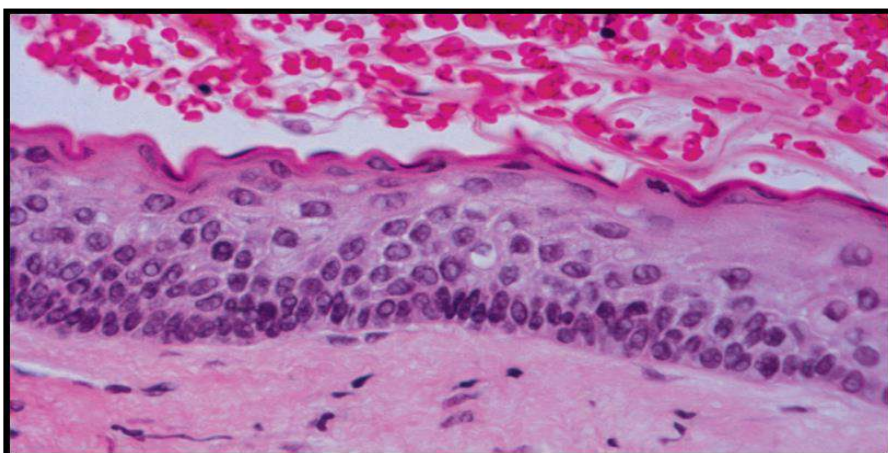
An OKC/KCOT characteristically presents as a well-circumscribed unilocular radiolucency with smooth radiopaque margins . Multilocularity is often present and tends to be seen more commonly in larger lesions .Noted adjacent to the crown of an unerupted tooth .Mandibular lingual enlargement is occasionally seen.The radiographic

findings, although often highly suggestive, are not diagnostic. Approximately 30% of maxillary and 50% of mandibular lesions produce buccal expansion. Mandibular lingual enlargement is occasionally seen.



### Histopathology:

The epithelial lining is uniform of stratified squamous epithelium, generally ranging from 6 to 10 cell layers thick .The basal layer exhibits a characteristic **palisaded pattern with polarized and intensely stained nuclei** of uniform diameter .The luminal epithelial cells are parakeratinized and produce an uneven or corrugated profile .Focal zones of orthokeratin are occasionally seen .Additional histologic features that may occasionally be encountered include budding of the basal cells into the connective tissue wall and microcyst formation. The fibrous connective tissue component of the cyst wall is often free of an inflammatory cell infiltrate and is relatively thin.The epithelium–connective tissue interface is characteristically flat . The cystic lumen may contain a clear liquid that is similar to a transudate of serum, or it may be filled with a cheesy material .

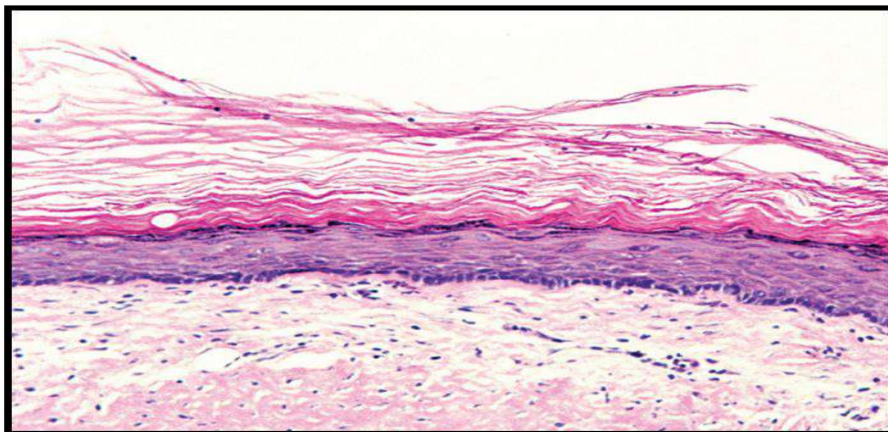


### Treatment and Prognosis:

Surgical excision with peripheral osseous curettage or ostectomy is the preferred method of management due to its high recurrence rate . Some have advocated marsupialization to permit cyst shrinkage, followed by enucleation as an alternative. The recurrence rate of 10% to 30% . Small dental lamina remnants or satellite cysts in the bone adjacent to the primary lesion may contribute to recurrence . Follow-up examinations are important for patients with this lesion. Patients should be evaluated for completeness of excision, new keratocysts, and NBCCS . Most recurrences become clinically evident within 5 years of treatment . Patients with multiple keratocysts have a significantly higher rate of recurrence than those with single keratocysts .

### ORTHOKERATINIZED ODONTOGENIC CYST

Originally called the orthokeratinized variant of odontogenic keratocyst, is **less clinically aggressive, has a lower rate of recurrence, and generally is not syndrome associated**. In the orthokeratotic odontogenic cyst, a prominent granular layer is found immediately below a flat, non-corrugated surface. The basal cell layer is less prominent and has a more flattened or squamoid appearance in comparison with the parakeratotic type.



### Nevoid basal cell carcinoma syndrome (gorlin syndrome)

Nevoid basal cell carcinoma syndrome (Gorlin syndrome) is an autosomal dominant inherited condition that exhibits high penetrance and variable expressivity. It is caused by mutations in patched (PTCH) , a tumor suppressor gene that has been mapped to chromosome 9q22,3-q31. The chief components are multiple basal cell

carcinomas of the skin , odontogenic keratocysts, intracranial calcification, and rib and vertebral anomalies. Many other anomalies have been reported in these patients and probably also represent manifestations of the syndrome, The prevalence of Gorlin syndrome is estimated to be about 1 in 60,000.

### **Clinical and Radiographic Features:**

There is great variability in the expressivity of nevoid basal cell carcinoma syndrome and no single component is present in all patients, The patient often has a characteristic faces, with frontal and temporoparietal bossing, which results in an increased cranial circumference, The eyes may appear widely separated, and many patients have true mild ocular hypertelorism. Mild mandibular prognathism is also commonly present. Basal cell carcinomas of the skin are a major component of the syndrome. They usually begin to appear at puberty or in the second and third decades of life, although they can develop in young children. The tumors may vary from flesh colored papules to ulcerating plaques. They are often appear on non-sun exposed skin but are most commonly located in the mid face area. The number of skin tumors may vary from only a few to many hundreds. Blacks with the syndrome tend to have fewer basal cell carcinomas than whites, probably because of protective skin pigmentation. Palmar and plantar pits are present in about 65% of patients. These punctate lesions represent a localized retardation of the maturation of basal epithelial cells. Basal cell carcinomas may develop at the base of the pits.

### **Lateral Periodontal Cyst & Gingival cyst in adult**

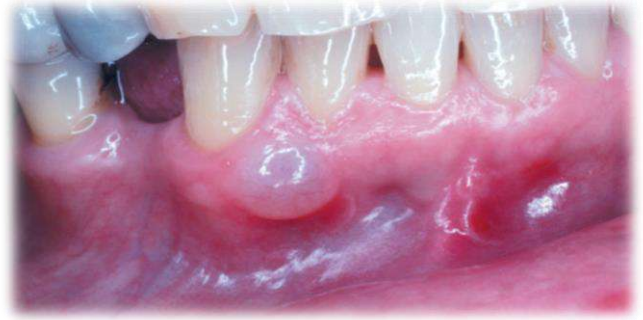Is a non-keratinized developmental cyst occurring adjacent or lateral to the root of a tooth .Gingival cysts of the adult are histogenetically and pathologically similar and are also discussed here.

### **Etiology and Pathogenesis:**

The origin of this cyst is believed to be related to proliferation of rests of dental lamina .The lateral periodontal cyst has been pathogenetically linked to the gingival cyst of the adult; the former is believed to arise from dental lamina remnants within bone, and the latter from dental lamina remnants in soft tissue between the oral epithelium and the periosteum (rests of Serres). The close relationship between the two entities is further supported by their similar distribution in sites containing a higher concentration of dental lamina rests, and their identical histology.

### Clinical Features:

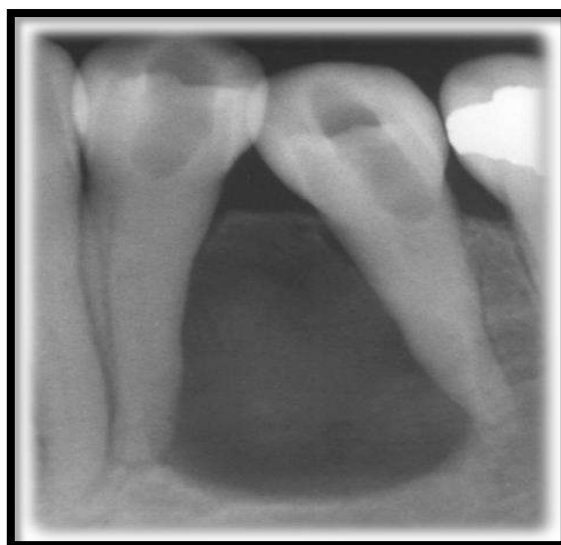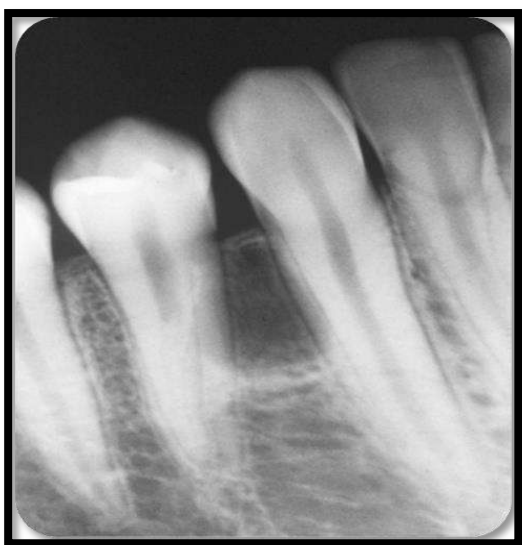Most lateral periodontal cysts and gingival cysts of the adult occur in the mandibular premolar and cuspid regions and occasionally in the incisor area .In the maxilla, lesions are noted primarily in the lateral incisor region .A distinct male predilection has been noted with greater than 2:1 distribution. Gingival cysts show a nearly equal gender predilection .The median age for both types of cysts is between the fifth and sixth decades of life, with a range of 20 to 85 years for lateral periodontal cysts, and 40 to 75 years for gingival cysts of the adult.



Clinically ,a gingival cyst appears as a small soft tissue swelling within or slightly inferior to the interdental papilla. It may assume a slightly bluish discoloration when it is relatively large. Most cysts are less than 1 cm in diameter. Radiography reveals no findings.

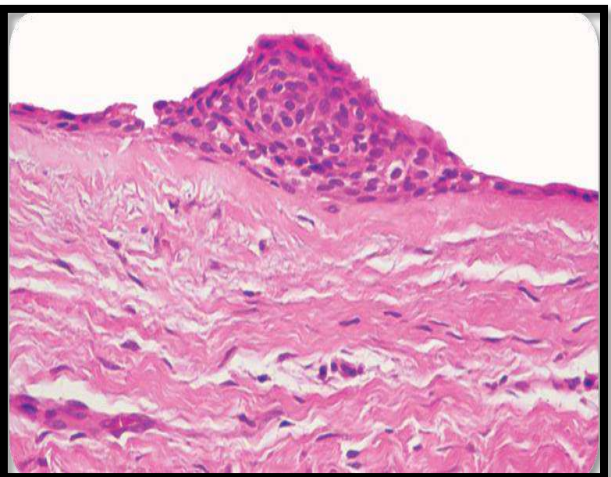
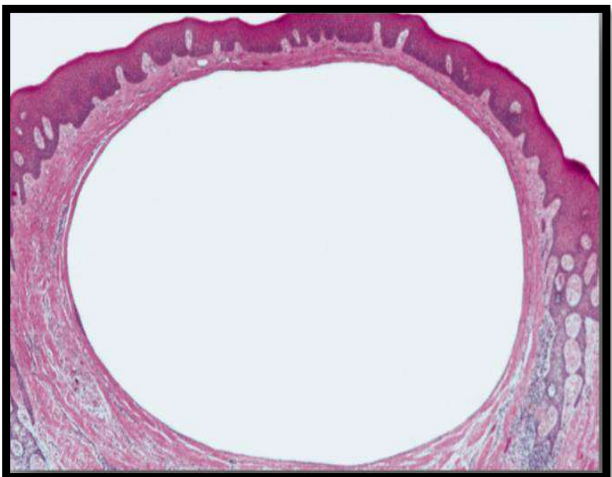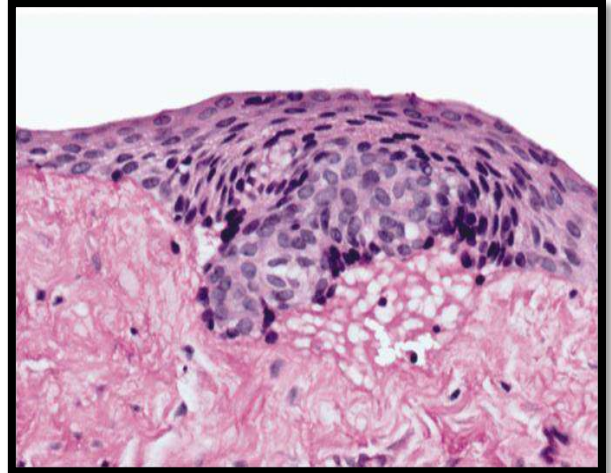
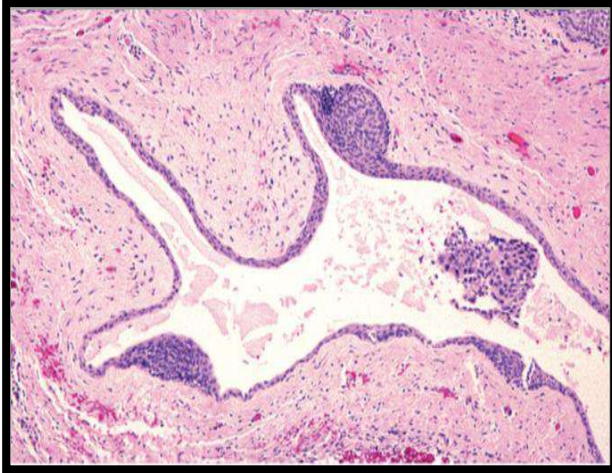
### Radiographically:

A lateral periodontal cyst presents as an asymptomatic, well-delineated, round or teardrop-shaped unilocular (and occasionally multilocular) radiolucency with an opaque margin along the lateral surface of a vital tooth root .Root divergence is rarely seen .The term botryoid odontogenic cyst is sometimes used when the lesion is multilocular.



### Histopathology:

Both the lateral periodontal cyst and the gingival cyst of the adult are lined by a thin, non-keratinized epithelium. Clusters of glycogen-rich, clear epithelial cells may be noted in nodular thickenings of the cyst lining.



### Treatment and Prognosis:

Local excision of both gingival and lateral periodontal cysts is generally curative. The multilocular variant, botryoid odontogenic cyst, seems to have increased recurrence potential. Follow-up, therefore, is suggested for treated multilocular odontogenic cysts.

## Gingival Cyst of the Newborn

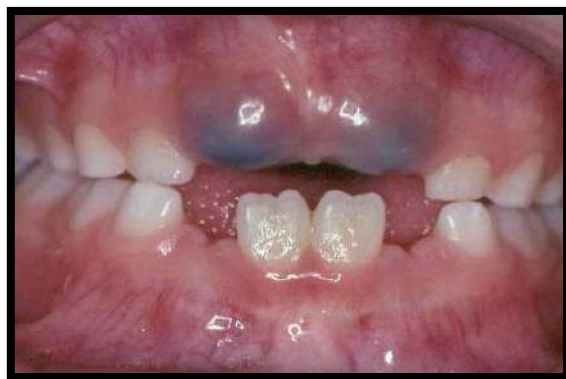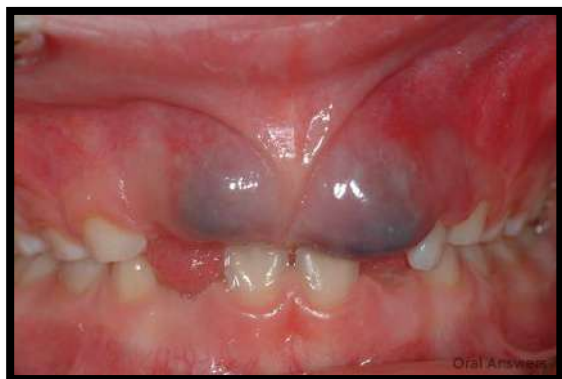Gingival cysts of the newborn are also known as dental lamina cysts of the newborn or Bohn's nodules. These cysts typically appear as multiple nodules along the alveolar ridge in neonates. It is believed that fragments of the dental lamina that remain within the alveolar ridge mucosa after tooth formation proliferate to form these small, keratinized cysts. In the vast majority of cases, these cysts are self-limiting and degenerate, and they involute or rupture into the oral cavity within a few weeks to a few months.

### Histologically:

This cyst is lined by a bland stratified squamous epithelium. Treatment is not necessary because nearly all involute spontaneously or rupture before the patient is 3 months of age. Similar epithelial inclusion cysts may occur along the midline of the palate (palatine cysts of the newborn, or Epstein's pearls). These cysts are of developmental origin and are derived from epithelium that is included in the fusion line between the palatal shelves and the nasal processes. No treatment is necessary because they fuse with the overlying oral epithelium, discharge their contents, and resolve spontaneously.

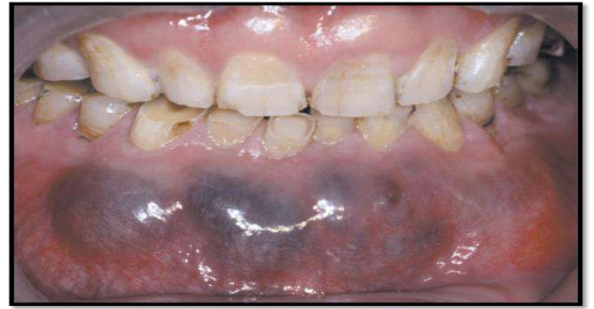## Eruption Cyst

An eruption cyst results from fluid accumulation within the follicular space of an erupting tooth. The epithelium lining this space is simply reduced enamel epithelium. With trauma, blood may appear within the tissue space, forming an eruption hematoma. No treatment is needed because the tooth erupts through the lesion. Subsequent to eruption, the cyst disappears spontaneously without complication.



## Glandular Odontogenic Cyst

The rare glandular odontogenic cyst, or sialo-odontogenic cyst, was first described in 1987 and has some histologic features that suggest a mucus-producing salivary gland tumor (low-grade mucoepidermoid carcinoma).

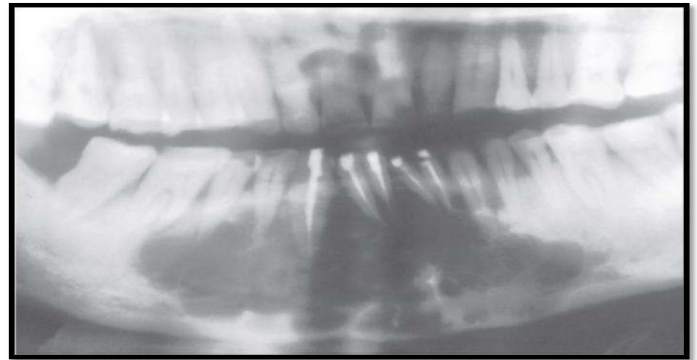


### Clinical Features:

The glandular odontogenic cyst mostly seen in the mandible (80 %) especially the anterior mandible. Maxillary lesions tend to be localized to the anterior segment. A slow growth rate is characteristic and symptoms are absent. Jaw expansion is not uncommon, particularly in association with mandibular lesions. The gender ratio is approximately 1:1. The mean age is 50 years, with a wide age range from the second through ninth decades.

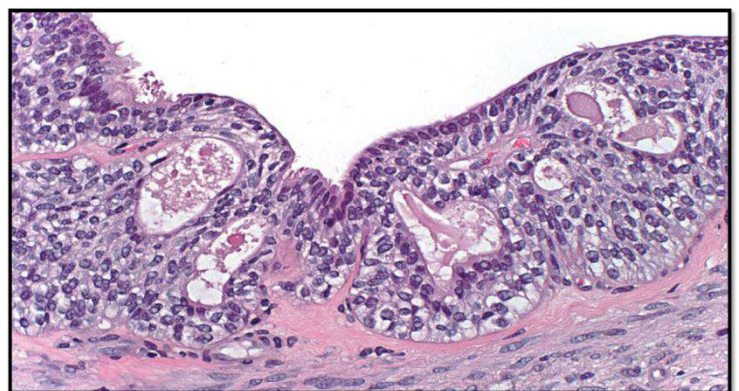
### Radiographic :

Most cases are radiographically multiloculated. In cases in which a unilocular radiolucency has been noted initially, recurrent lesions have tended to be multiloculated. Lesions that have been reported have exhibited a wide variation in size, from smaller than 1 cm to involving most of the mandible bilaterally. Radiographic margins are well defined and sclerotic and scalloped. Teeth may be displaced, and root resorption is noted in some cases. More aggressive lesions have shown an ill-defined peripheral border.



### Histopathology:

Multilocular cyst is lined by **non-keratinized epithelium** with **focal thickenings** in which the epithelial cells assume a **swirled appearance**.





The epithelial lining consists of cuboidal cells, often with cilia at the luminal surface . Mucous cells are clustered in the cyst lining along with mucin pools .The overall histomorphology is reminiscent of a cystic low-grade mucoepidermoid carcinoma.

### **Treatment and Prognosis:**

This lesion can be considered locally aggressive; therefore, surgical management should be dictated by the clinical and radiographic extent of the disease. Where adequate healthy bone remains beyond the extent of the cystic lesion, peripheral curettage or marginal excision is appropriate .Long-term follow-up is essential given the local aggressiveness and recurrence rate (approximately 25%) of this lesion.

### **Calcifying Odontogenic Cyst**

The calcifying odontogenic cyst is an uncommon lesion that demonstrates considerable histopathologic diversity and variable clinical behavior .Although it is widely considered to represent a cyst, some investigators prefer to classify it as a neoplasm. Some calcifying odontogenic cysts appear to represent non neoplastic cysts; other members of this group, variously designated as dentinogenic ghost cell tumors or epithelial odontogenic ghost cell tumors, have no cystic features, may be infiltrative or even malignant, and are regarded as neoplasms. The WHO Classification of odontogenic Tumors groups the calcifying associated with other recognized odontogenic tumors, most commonly odontomas. However. Adenomatoid odontogenic tumors and ameloblastomas have also been associated with calcifying odontogenic cyst with all its variants as an odontogenic tumor rather than an odontogenic cyst. although it admits that further experience may provide more reliable criteria for classification of the variants. Lesions with a cystic component represent 85% of the cases, whereas a solid pattern reminiscent of a neoplastic process is seen in 15%.A summary of the basic features follows:

- Cystic, non-proliferative:** In this predominantly cystic lesion, the epithelial lining may only be a few cells thick. Sparse dentinoid may be present, but no other hard tissues are seen. Such lesions constitute approximately 45% of all cystic calcifying odontogenic cysts.
- Cystic, proliferative/ameloblastomatous;** A prominent central cystic component is usually associated with various satellite cysts in the wall. Odontogenic epithelial

proliferations that superficially resemble ameloblastoma extend into the lumen as well as the connective tissue wall of the lesion.

- Odontoma-associated:** Odontoma-like tissues are seen in the wall of the lesion.

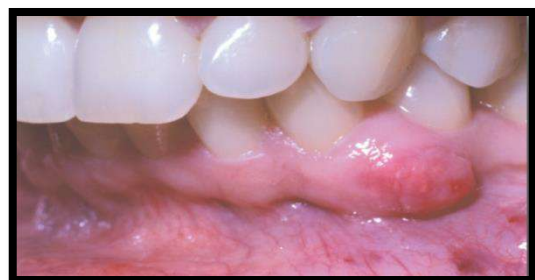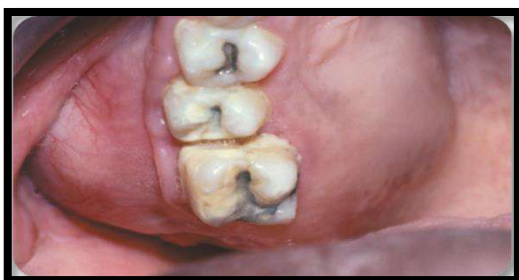- Epithelial odontogenic ghost cell tumor:** This form has a growth pattern that is most consistent with a neoplasm, characterized by ameloblastoma-like strands and islands of odontogenic epithelium that infiltrate the connective tissue. Varying amounts of an eosinophilic calcified material (dentinoid) are typically present; thus, this lesion has been termed dentinogenic ghost cell tumor, although epithelial odontogenic ghost cell tumor and odontogenic ghost cell tumor are other names that have also been used.

### **Etiology and Pathogenesis:**

COCs are believed to be derived from odontogenic epithelial remnants within the gingiva or within the mandible or maxilla .Ghost cell keratinization, the characteristic microscopic feature of this cyst, is also a defining feature of the cutaneous lesion known as calcifying epithelioma of Malherbe, or pilomatrixoma . In the jaws, ghost cells may be seen in other odontogenic tumors, including odontomas, ameloblastomas, adenomatoid odontogenic tumors, ameloblastic fibro-odontomas, and ameloblastic fibromas .Mutations of genes in the WNT signaling pathway, including the beta-catenin gene, have been reported in COCs.

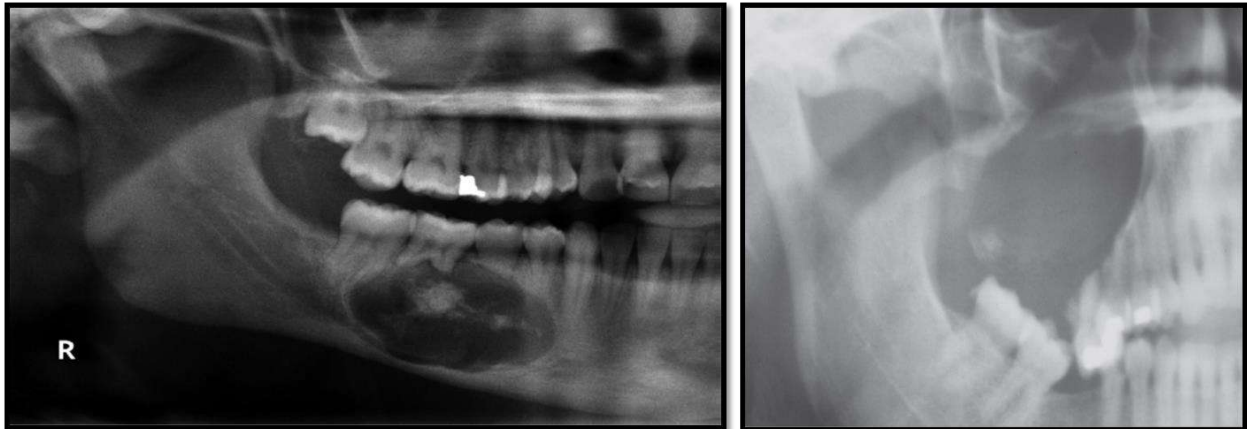### **Clinical Features:**

A peak incidence in the second decade .It usually appears in individuals younger than 40 years of age and has a decided predilection for females .More than 70% of COCs are seen in the maxilla. Rarely, COCs may present as localized extraosseous masses involving the gingiva.Those presenting in an extraosseous or peripheral location are usually noted in individuals older than 50 years of age and are found anterior to the first molar region.



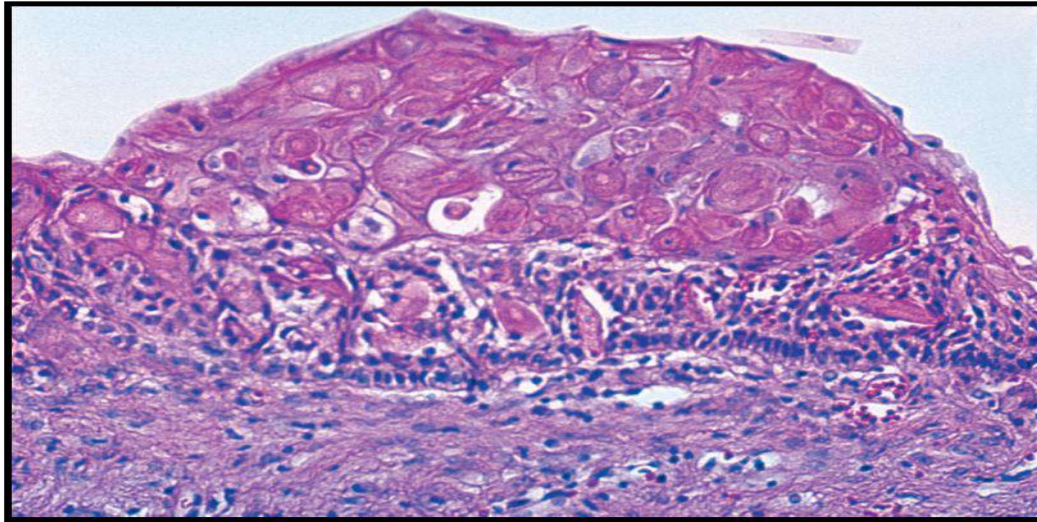
### Radiographically:

COCs may present as unilocular or multilocular radiolucencies with discrete, well-demarcated margins. Within the radiolucency may be scattered, irregularly sized calcifications. Such opacities may produce a salt-and-pepper type of pattern, with an equal and diffuse distribution. In some cases, mineralization may develop to such an extent that the radiographic margins of the lesion are difficult to determine.

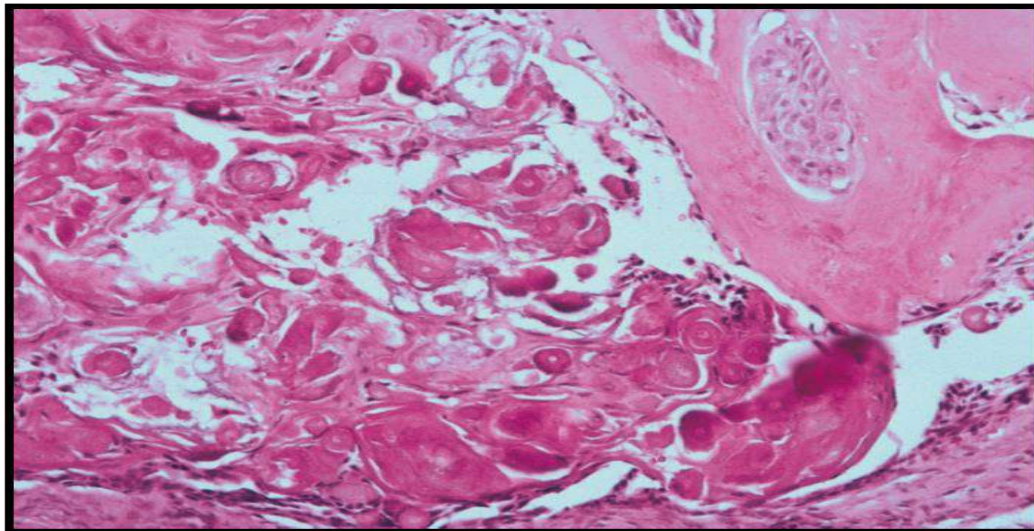


### Histopathology:

Most COCs present as well-delineated cystic proliferations with a fibrous connective tissue wall lined by odontogenic epithelium. Intraluminal epithelial proliferation occasionally obscures the cyst lumen, thereby producing the impression of a solid tumor. The epithelial lining is of variable thickness. The basal epithelium may be prominent focally, with hyperchromatic nuclei and a cuboidal to columnar pattern. Above the basal layer are more loosely arranged epithelial cells, sometimes resembling the stellate reticulum of the enamel organ. The most prominent and unique microscopic feature is the presence of so-called ghost cell keratinization. Ghost cells are anucleate and retain the outline of the cell membrane. These cells undergo dystrophic mineralization characterized by fine basophilic granularity, which may eventually result in large sheets of calcified material. On occasion, ghost cells may become displaced in the connective tissue wall, eliciting a foreign body giant cell response.



The cyst lining shows Ameloblastoma -like epithelial cells, with a columnar basal layer. Large eosinophilic ghost cells are present within the epithelial lining.



Eosinophilic dentinoid material is present adjacent to a sheet of ghost cells.

### **Treatment and Prognosis:**

Treatment is usually more aggressive than simple curettage due to the unpredictable biological behavior of this lesion. Patients should be monitored following treatment because recurrences are not uncommon. Management of the extraosseous or peripheral variant is conservative because recurrence is not characteristic.

# Oral Pathology

## Lec.7

### *Fibro-osseous Lesions*

A group of lesions affecting the *craniofacial skeleton* and characterized microscopically by *fibrous stroma* containing various combinations of bones and/or cementum-like material fall under the term ***benign fibro-osseous lesions***. They include a wide variety of lesions of *developmental, dysplastic, and neoplastic* origins with different clinical and radiographic presentation & behavior. Because of the histologic similarities between these diverse diseases, proper diagnosis requires ***clinical findings, radiographic features, surgical notes and histopathologic correlation*** to establish a specific diagnosis.

Commonly included among the fibro-osseous lesions of the jaw are the following:

1. Fibrous dysplasia.
2. Ossifying fibroma.
3. Juvenile Ossifying fibroma.
4. cemento-osseous dysplasia.

The conditions mentioned above have different clinical courses and outcomes, hence different treatment modalities ranging from non to surgical excision. For this reason a specific diagnosis is critical.

## **Fibrous Dysplasia (FD):**

Is a developmental skeletal tumor like condition characterized by replacement of normal bone by poorly organized & inadequately mineralized, immature, woven bone & fibrous connective tissue. The disease may affect a single bone (**monostotic**) or multiple bones (**polyostotic**). Polyostotic FD is less common, occurring in only 25% to 30% of cases. A few of these cases ( $\approx 3\%$ ) may be associated with skin pigmentation & endocrine abnormalities, a condition known as the **McCune-Albright syndrome**, which is more common in females.

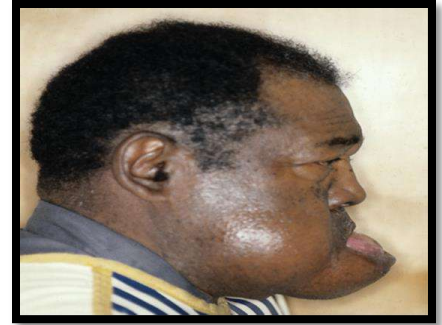
- **Etiology & Pathogenesis:**

The nature of this condition has not been firmly established. The name dysplasia was originally intended to indicate that the condition represented a dysplastic growth resulting from deranged mesenchymal cell activity or a defect in the control of bone cell activity. Although FD has been considered as a developmental tumor-like condition; genetic studies, however, has provided evidence that it may be better classified as a neoplastic process. FD is a sporadic condition that results from a postzygotic mutation in the **GNAS1** (guanine nucleotide binding protein,  $\alpha$ -stimulating activity polypeptide 1) gene.

Clinically FD may manifest as a localized process, as a condition involving multiple bones, or as multiple bone lesions in conjunction with cutaneous & endocrine abnormalities depending on the point in time during fetal or postnatal life that the mutation of GNAS1 occurs.

1. Mutation occurs in *early embryonic life*  $\longrightarrow$  mutation in one of undifferentiated stem cells  $\longrightarrow$  osteoblasts, melanocytes and endocrine cells  $\longrightarrow$  clinically presented as **multiple bone lesions, cutaneous pigmentation & endocrine disturbances**.
2. Mutation occurring during *later stages of embryonic development of the skeletal system*  $\longrightarrow$  the mutated cells that participate in the skeleton formation  $\longrightarrow$  **multiple bone involvements**.

3. Mutation during *postnatal life* → mutated cells confines to one site FD of a **single bone**.



- **Clinical Features of FD:**

The condition presents commonly an asymptomatic, slow enlargement of the involved bone. FD may involve a single

bone or several bones concomitantly. Monostotic FD is the term used to describe the process in one bone. Polyostotic FD applies to cases in which more than one bone is involved.

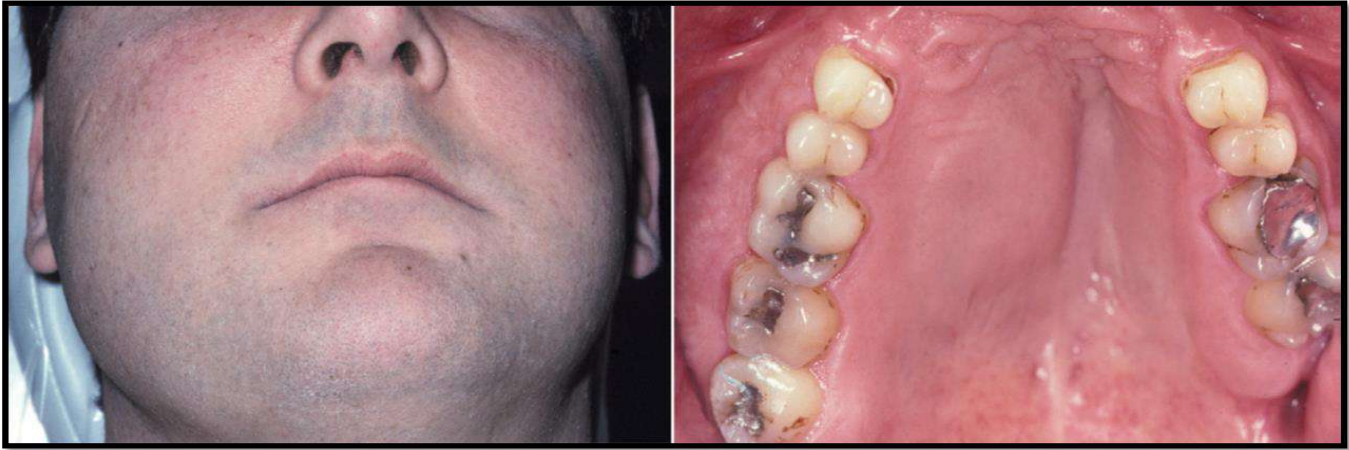– **McCune-Albright syndrome** consists of polyostotic FD, cutaneous melanotic pigmentations (*café-au-lait macules*) and endocrine abnormalities. The most commonly reported endocrine disorder consists of precocious sexual development in girls, acromegaly, hyperthyroidism, hyperparathyroidism, and hyperprolactinemia.

– **Jaffe-Lichtenstein syndrome** is characterized by multiple bone lesions of FD & skin pigmentations.

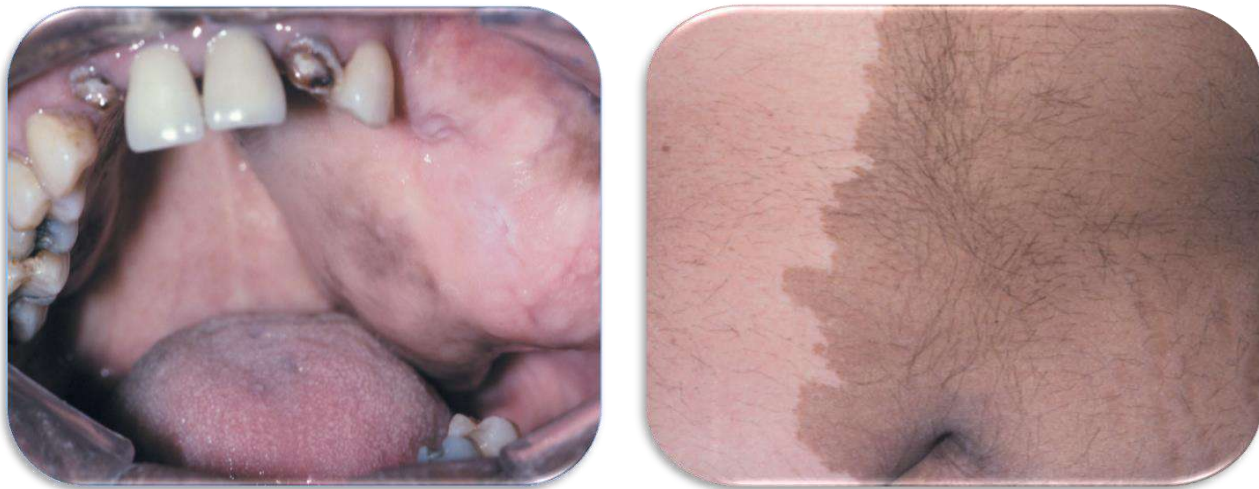
Monostotic FD is much more common than the polyostotic form, accounting for as many as 80% of cases.

Jaw involvement is common in this form of disease. Other bones that are commonly affected are the ribs & femur. FD occurs more often in the maxilla than in the mandible. Maxillary lesions may extend to involve the maxillary sinus, zygoma, sphenoid bone and the floor of the orbit. This form of the disease, with the involvement of several adjacent bones, has been referred to as **craniofacial FD**.

The most common site of occurrence with mandibular involvement is the body portion.



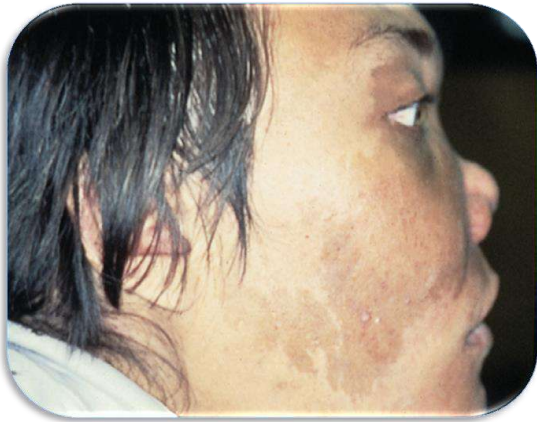Jaw involvement is usually slow & painless, typically a unilateral swelling. Teeth displacement may occur, with malocclusion and interference with tooth eruption, without tooth mobility.



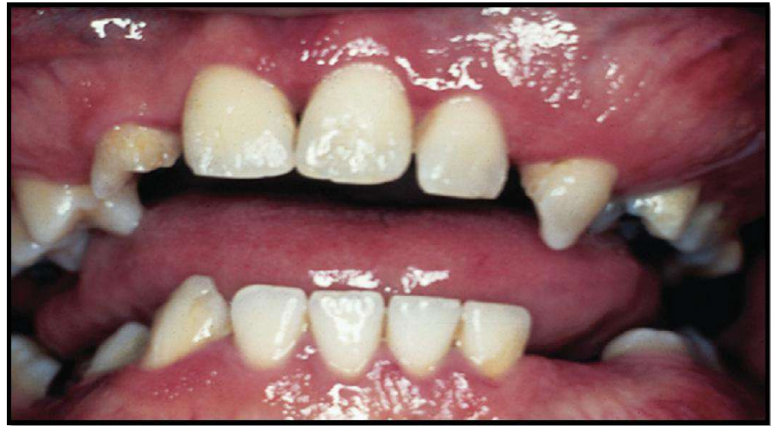The condition characteristically has its onset during the **1<sup>st</sup>&2<sup>nd</sup> decade of life**.

Monostotic FD usually exhibits an equal sex distribution & the polyostotic form tends to occur more commonly in females.





A



B

**Polyostotic fibrous dysplasia.** (A) Clinical appearance of patient exhibiting disproportionate bone growth caused by multiple fibrous lesions of the craniofacial bones and café-au-lait pigmentations. (B) Expansile lesions of the mandible and maxilla are evident in all quadrants.

- **Radiographic Findings:**

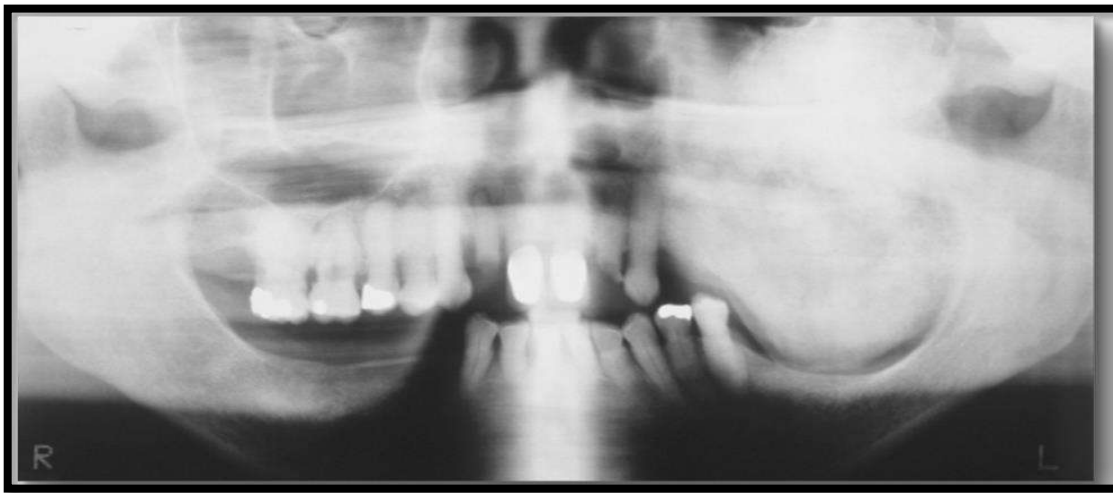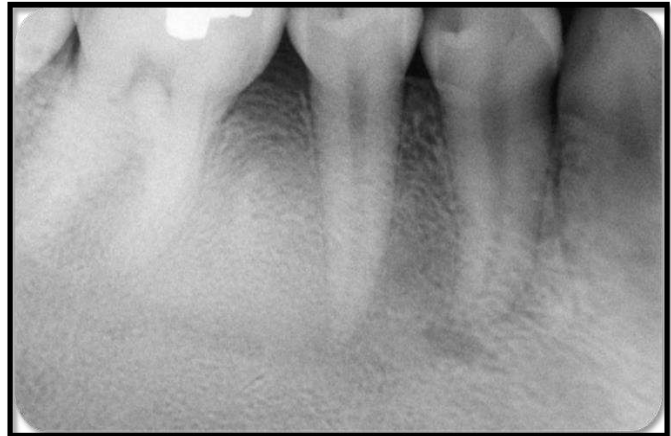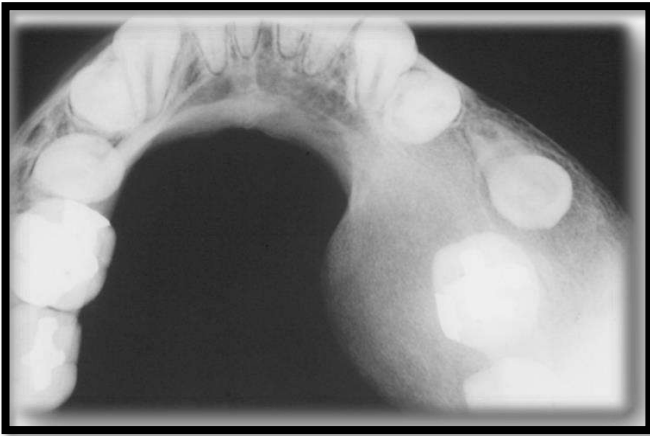
FD has a variable radiographic appearance that ranges from a radiolucent lesion to a uniformly radiopaque mass. Classical presentation is **ground-glass** effect, which results from the superimposition of poorly calcified bone trabeculae arranged in a disorganized pattern.

Radiographically, the lesions of FD are not well demarcated. The margins blend into the adjacent normal bone so that the limits of the lesion may be difficult to define.

- Involvement of the **mandible** results in:
  - Expansion of the lingual & buccal plates.
  - Bulging of the lower border.
  - Super displacement of the inferior alveolar canal.

- Periapical (PA) radiographs: narrowing of the periodontal ligament (PDL) space with ill-defined Lamina dura.
- Involvement of the **maxilla** results in:
  - Displacement of the sinus floor superiorly.
  - Obliteration of the maxillary sinus.
  - Increased density of the bone of the skull.

\*An important feature of FD is the poorly defined radiographic and clinical margins of the lesion that blend into the surrounding normal bone.



- **Lab Findings:**

Serum calcium, Phosphorus & Alkaline phosphatase are **normal** in monostotic FD, but **altered** in McCune-Albright syndrome.

- **Histopathology:**

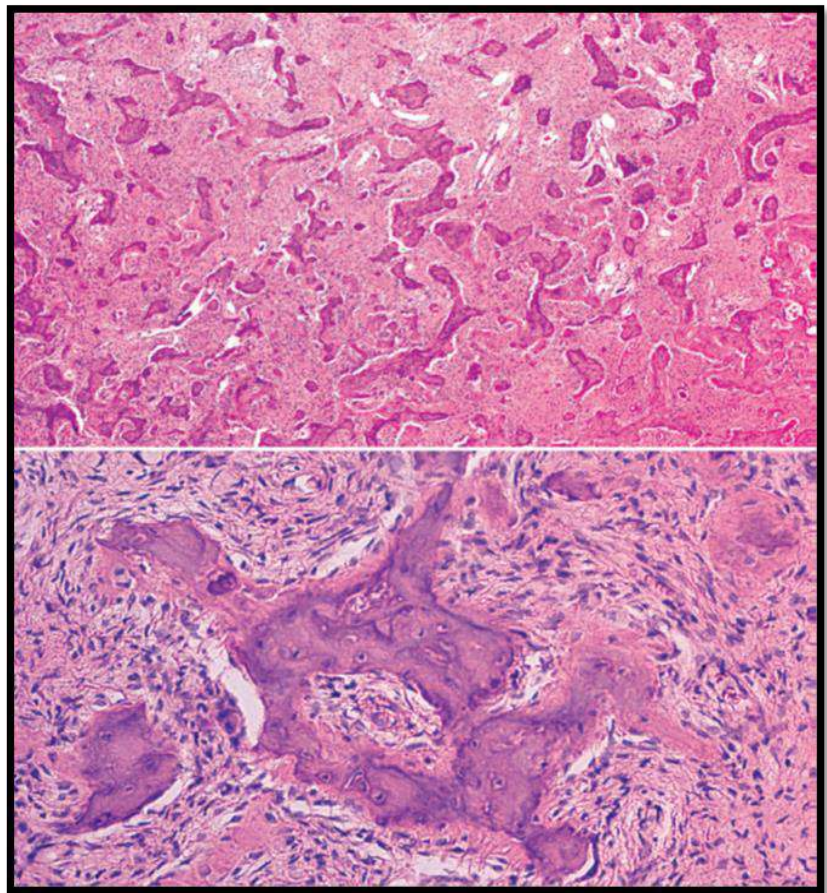
FD consists of a slight to moderate cellular fibrous connective tissue stroma that contains foci of irregularly shaped trabeculae of immature bone. The bone trabeculae assume irregular shapes linked to **Chinese characters** and they do not display any functional orientation, without osteoblastic activity at the bone trabeculae margins.

A, Irregularly shaped trabeculae of woven bone in a fibrous stroma.

- B, Medium-power view showing peripheral osteoid without osteoblastic rimming.

(A)

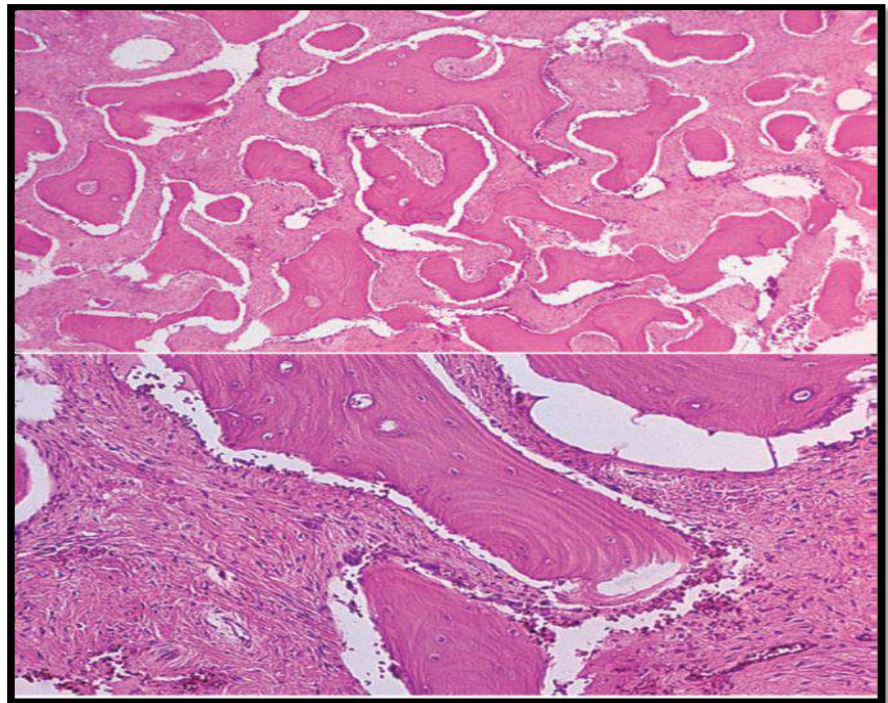
(B)



Mature Fibrous Dysplasia.

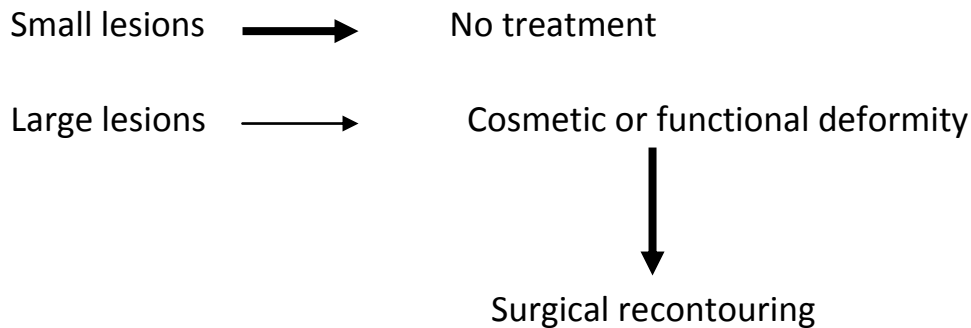
(A), This long-standing lesion shows separate, broad trabeculae of bone within fibrous connective tissue.

(B), Note the lamellar maturation of the bone.



• **Treatment & Prognosis:**

After a variable period of prepubertal growth, FD stabilizes, although a slow advance may be noted into adulthood.

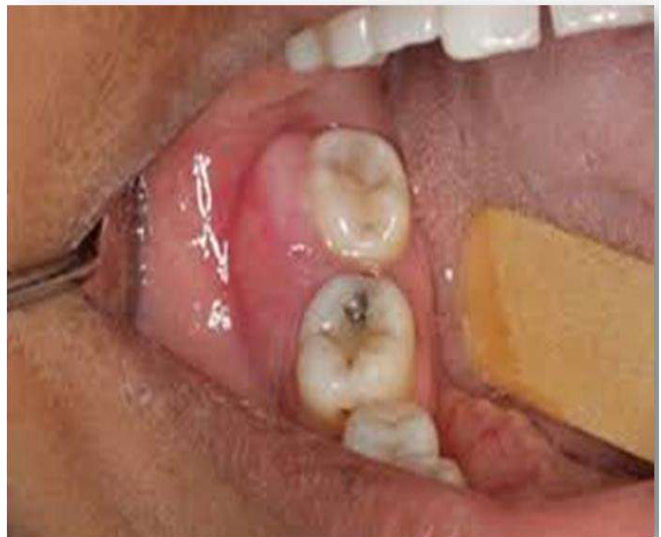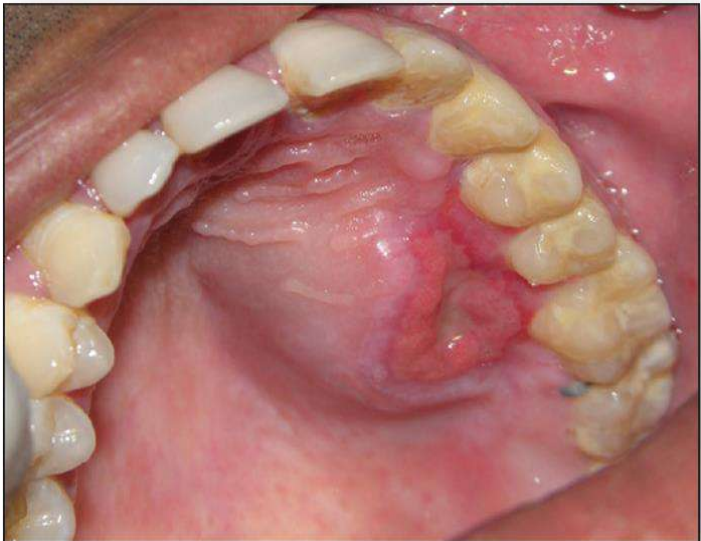


Malignant transformation is a rare complication of FD (less than 1%), usually in the polyostotic type. Many of them (osteosarcoma) were treated by radiation.

## **Ossifying Fibroma:**

OF is a benign neoplasm of bone that has the potential for excessive growth, bone destruction & recurrence.

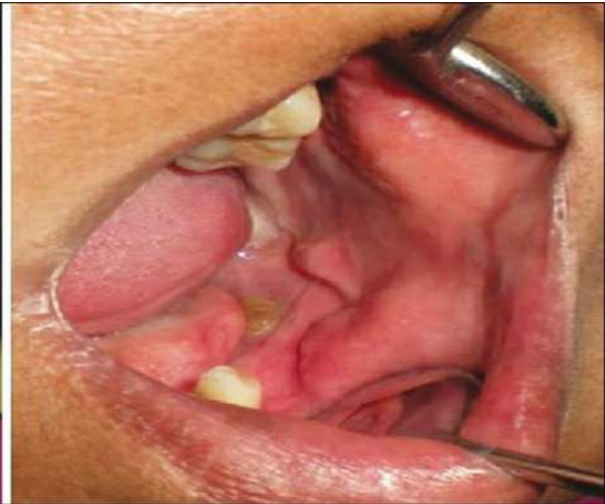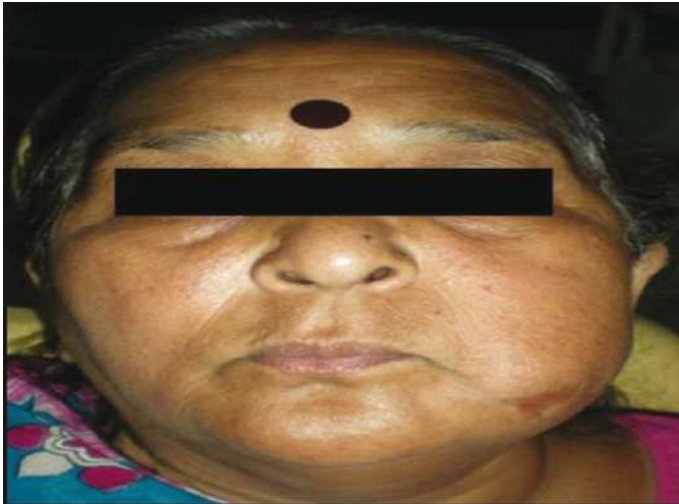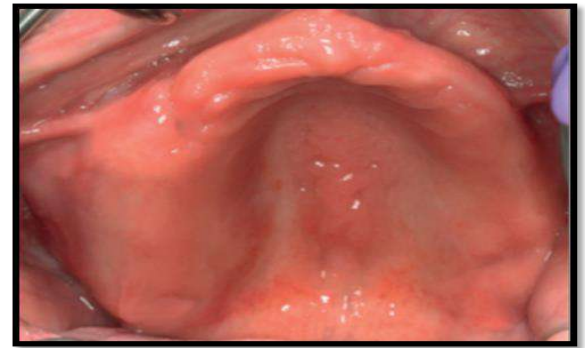
It is composed of a fibrous connective tissue stroma in which new bone is formed. OF is a true neoplasm with a significant growth potential. It has been suggested that the origin is odontogenic or from periodontal ligament .Recently, mutations in a tumor suppressor gene were identified.



- **Clinical Features:**

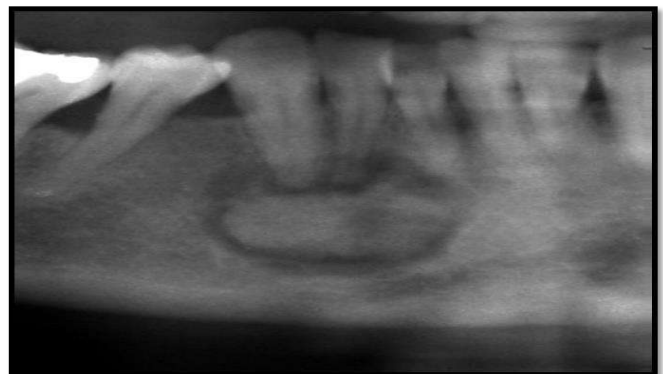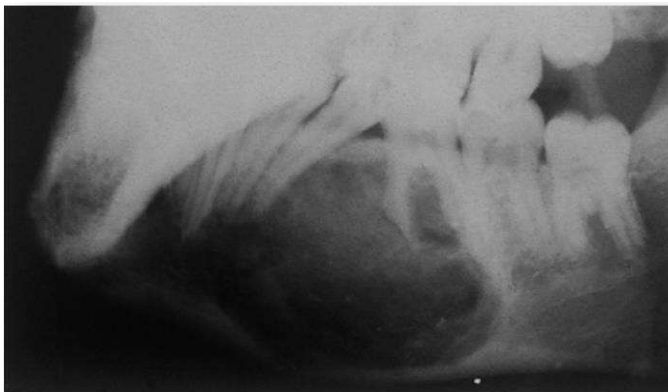
The epidemiology of Ossifying fibroma is unclear because many previous diagnosed cases were confused with focal cemento-osseous dysplasia (COD). For that reason what was thought to be OF, a common neoplasm, is now considered to be uncommon because most of the cases were in reality focal COD. tends to occur during the 3<sup>rd</sup> & 4<sup>th</sup> decades of life, in females more than in males. It is a slow growing asymptomatic & expansile lesion. OF may be seen in the jaw & craniofacial bones. Lesions in the jaw arise in the tooth-bearing region, mostly in the molar & premolar area. The tumor may cause expansion of the buccal and

lingual cortical plates, however perforation is very rare. OF is mostly a solitary lesion, although multiple lesions have been reported.



- **Radiographic Findings of COF:**

Well circumscribed, sharply demarcated border is the most common presenting radiographic feature, although OF may present as relatively lucent or opaque depending on the density of the calcification present. Also they may be unilocular or multilocular, mixed radiolucent-radiopaque image may be seen. The roots of the teeth present may be displaced & less commonly resorption is seen.



- **Histopathology:**

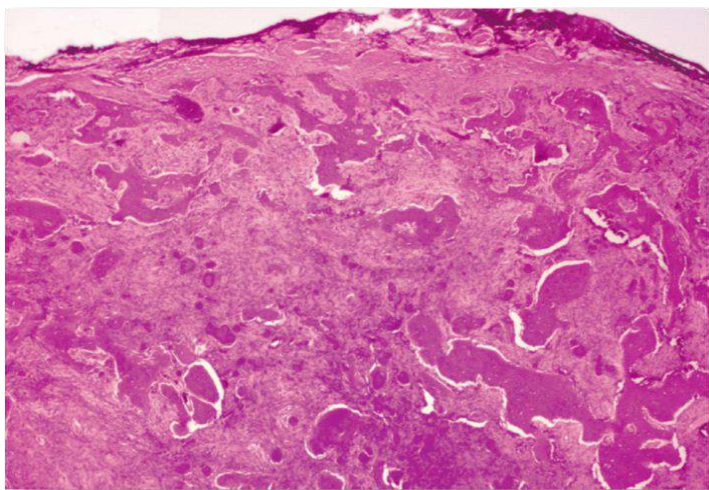
Cementifying fibroma, cemento-ossifying fibroma (COF), ossifying fibroma are terms used to describe the same condition, since the origin is the stem cells in the periodontal ligament which may give rise to both cementoblasts & osteoblasts forming both cementum & bone which cannot be differentiated on H&E stain. The last term (COF) is the one used by WHO classification.

COF is composed of fibrous connective tissue with well- differentiated spindle fibroblasts. Cellularity is uniform but may vary from one lesion to the next. Bone trabeculae or islands are evenly distributed throughout the fibrous stroma. The bone is immature & often

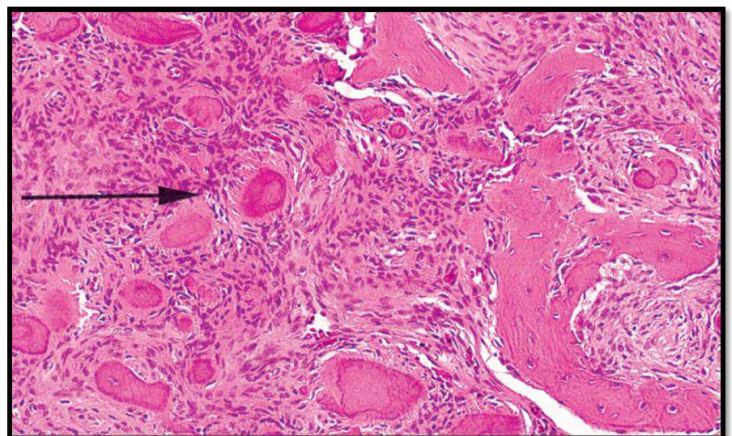

surrounded by osteoblast (***osteoblast rimming***).

Osteoblasts are infrequently seen.

← **(A)** well-circumscribed solid tumor mass. Trabeculae of bone and droplets of cementum-like material can be seen forming within a background of cellular fibrous connective tissue.



**(B)** High-power photomicrograph showing a mixture of woven bone and cementum-like material.



- **Treatment & Prognosis:**

Surgical removal using **curettage** or **enucleation**. The lesion can typically be separated easily from the surrounding bone. Recurrence is rare.

### **Juvenile Ossifying Fibroma:**

Is a well circumscribed rapidly growing neoplasm lack the continuity with adjacent normal bone. Lesions are circumscribed radiolucencies in some cases contain central radio-opacities (Ground glass) opacification may be observed. Those are present within a sinus may appear radiodense and create a clouding that could be confused with sinusitis. Two different neoplasm have been reported:

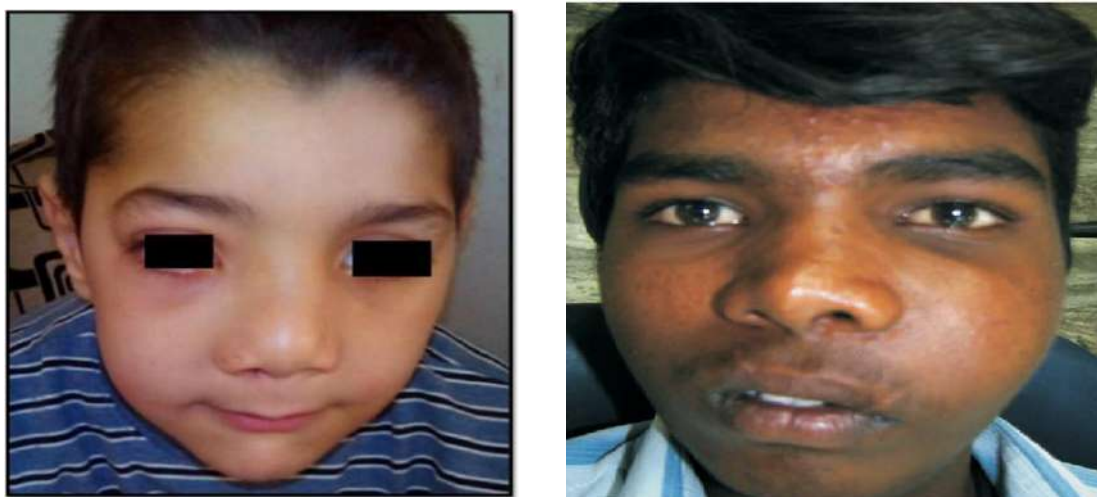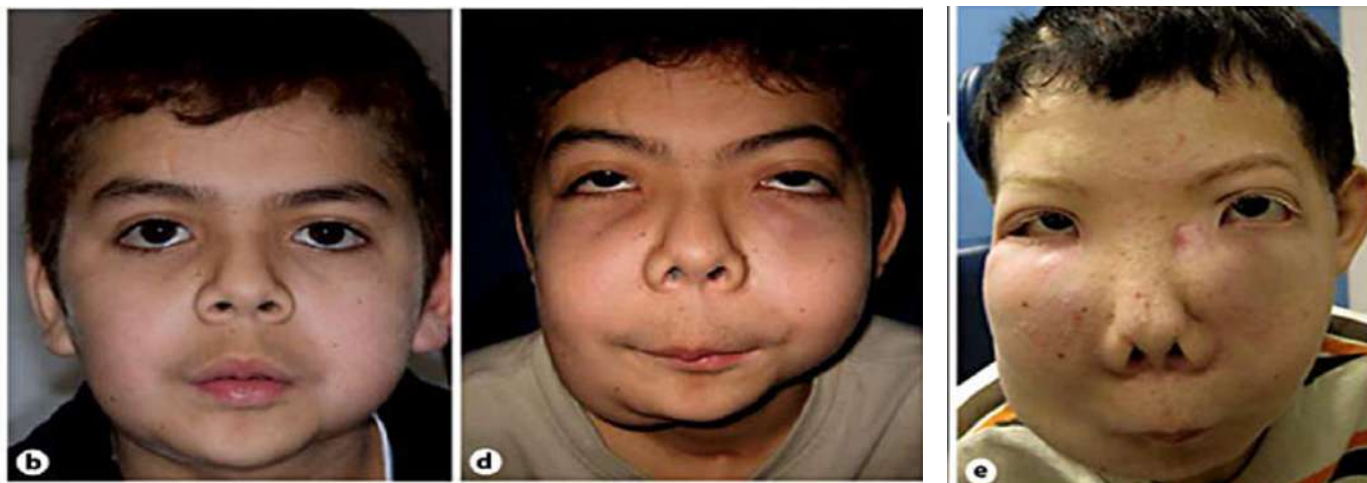
(1) **Trabecular** and (2) **Psammomatoid**. The latter neoplasm occur more than the trabecular type in a ratio of approximately 4:1

The trabecular variant arises primarily in the jaws , whereas the psammomatoid variant predominantly involves the paranasal sinuses and orbital region. In both variants, gnathic involvement favors the maxilla.

Most often arise in children, adolescents, and young adults. The average age at diagnosis is somewhat younger for the trabecular variant (range from 8 1/2 to 12 years) than the psammomatoid variant (range from 16 to 33 years). Small lesions may be discovered incidentally during routine radiographic examination, whereas larger lesions tend to cause painless swelling and obvious facial enlargement. Pain and paresthesia are infrequent findings. Those are present within a sinus may appear radiodense and create a clouding that could be confused with sinusitis.



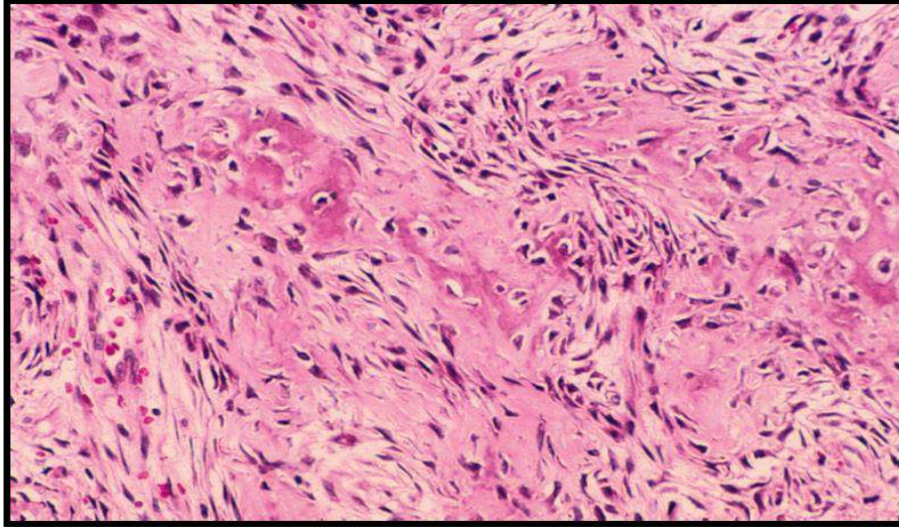
Lesions are circumscribed radiolucencies in some cases contain central radio-opacities (Ground glass) opacification may be observed.



- **Histopathology:**

Both patterns are none capsulated but well demarcated from the surrounding bone. Tumors consist of cellular fibrous connective tissue with variants areas of loose and other are so cellular, mitotic figures are found but rare, areas of hemorrhage and small clusters of multinucleated giant cells are usually seen.

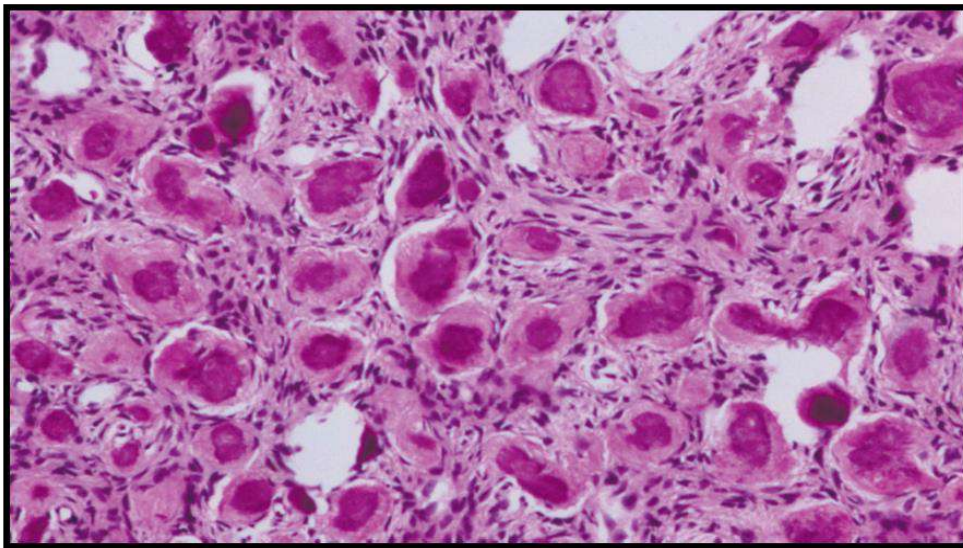
The trabecular type shows irregular strands of highly cellular osteoid encasing plump osteocytes. These strands are lined by plump osteoblast and in other areas by giant cells.



**Trabecular Variant.**

Trabeculae of cellular woven bone are present in a cellular fibrous stroma.

In psammomatoid pattern concentric lamellated and spherical ossicles that have basophilic centers with peripheral eosinophilic osteoid rims.



**Psammomatoid Variant.**

Cellular fibrous connective tissue containing spherical ossicles with basophilic centers and peripheral eosinophilic rims.

## **Treatment and Prognosis:**

For small lesions, complete local excision or thorough curettage appears adequate , While for large or aggressive lesions, wider resection may be required. Recurrence rates of 30% to 58% have been reported for juvenile ossifying fibromas.

## **Cemento-osseous Dysplasia (COD):**

The most common fibro-osseous lesion encountered in clinical practice. These poorly understood diseases are non-neoplastic disturbances of growth and remodeling of bone and cementum, Represents a reactive or dysplastic process rather than a neoplastic one. Some investigators have suggested that cemento-osseous dysplasia originates from the periodontal ligament. Others believe this condition represents a defect in extraligamentary bone remodeling that may be triggered by local injury or, possibly, an underlying hormonal imbalance.

COD includes:

- Periapical COD.
- Focal COD.
- Florid COD.

All the 3 disease processes have the same features, only distinguished on the basis of the extent of involvement of the affected portions of the jaw.

## 1. Periapical COD:

Represents a reactive or dysplastic process rather than a neoplastic one. It may represent an unusual response of periapical bone & cementum to some undetermined local factor.

➤ When not associated with a tooth apex → **Focal COD.**

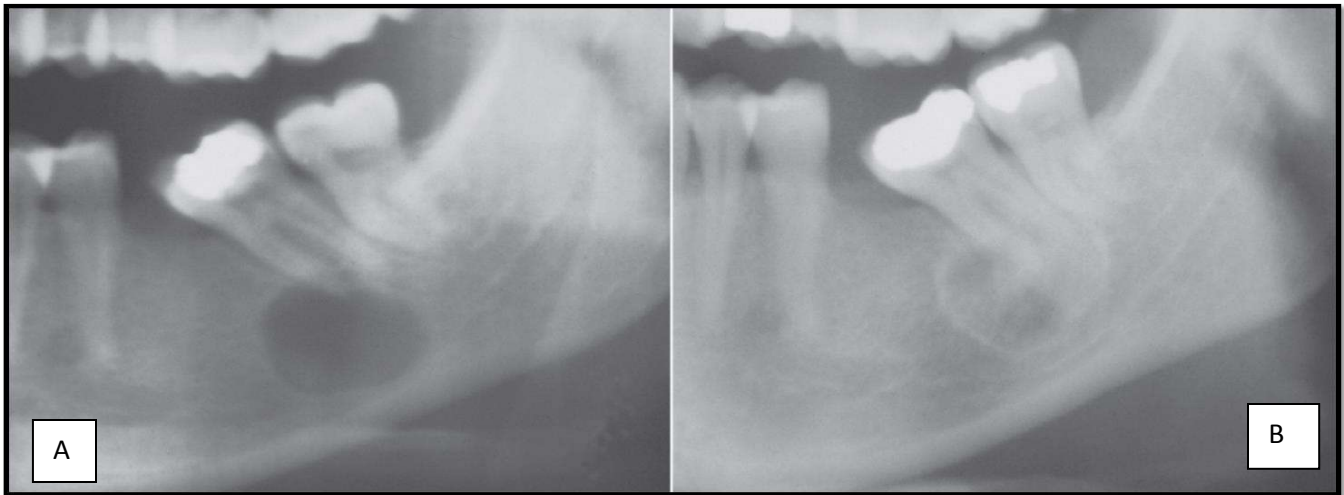
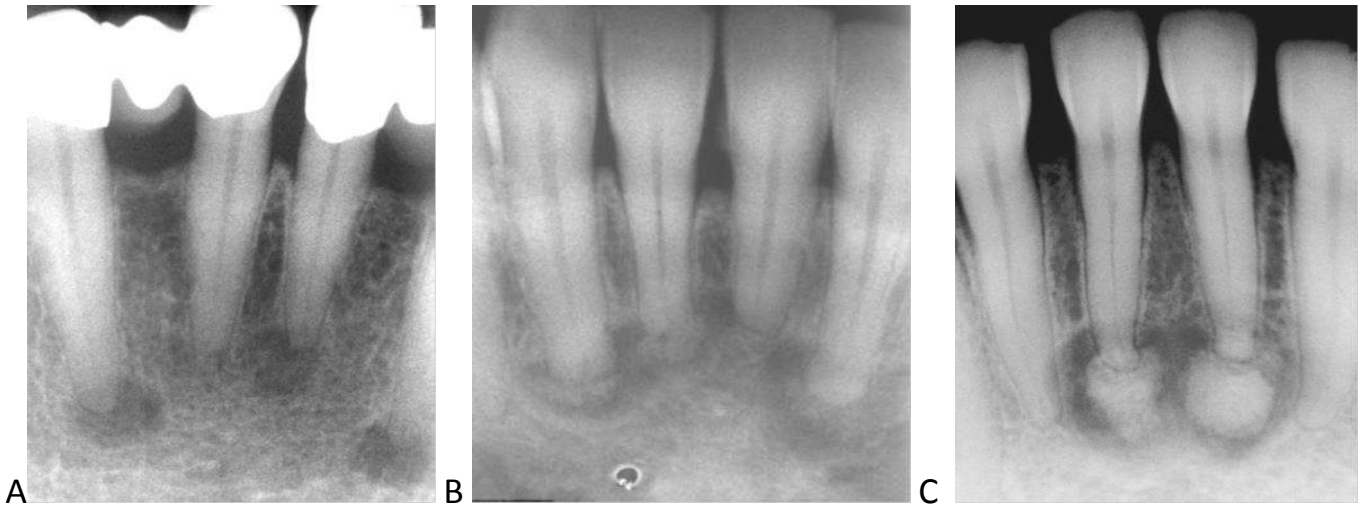
### • Clinical Features:

A common phenomenon, that occurs at the apex of vital teeth. A biopsy is unnecessary because the condition is usually diagnosed by clinical & radiographic features. Females are affected more than males. PACOD occurs in females at middle age (around 40 years) & rarely before the age 20. The mandible, especially the anterior periapical region, is far more commonly affected than other areas. More often, the apices of two or more teeth are affected.

➤ To be differentiated from **Periapical granuloma** → vitality test.

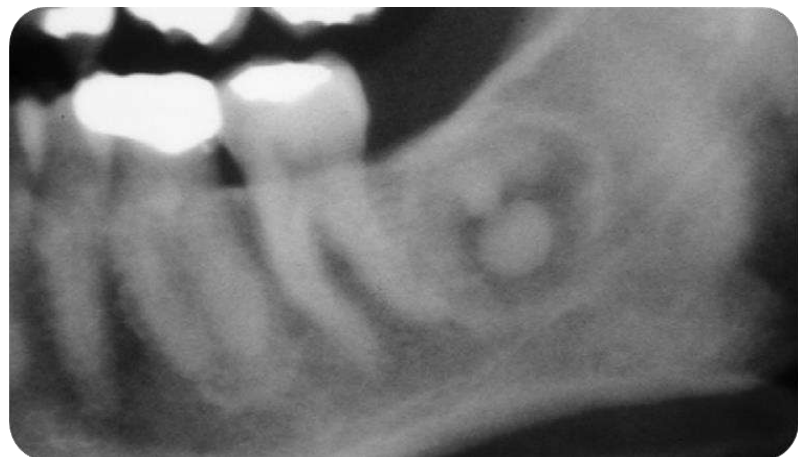### **Radiographically :**

- The condition appears 1st as a periapical lucency that is continuous with the periodontal ligament space.(A)
- As the condition progresses, the lucent lesion develops into a mixed or mottled pattern because of bone repair.(B)
- The final stage appears as a solid, opaque mass that is surrounded by a thin, lucent ring (after months – years).(C)



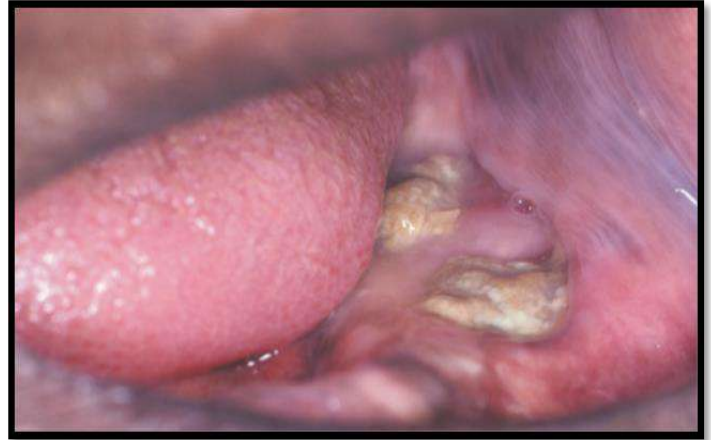**Focal Cemento-Osseous Dysplasia.**

- A)** A radiolucent area involves the edentulous first molar area and the apical area of the second molar.
- B)** Radiograph of the same patient taken 9 years later showing a mixed radiolucent and radiopaque pattern.

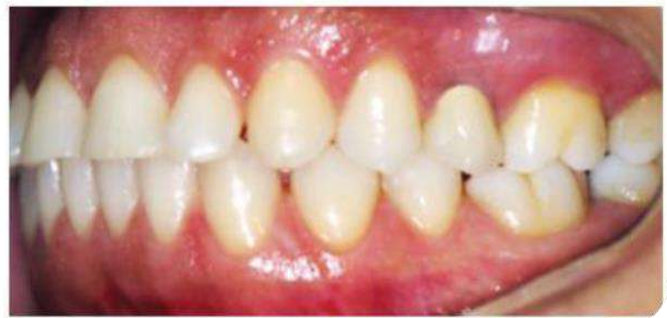
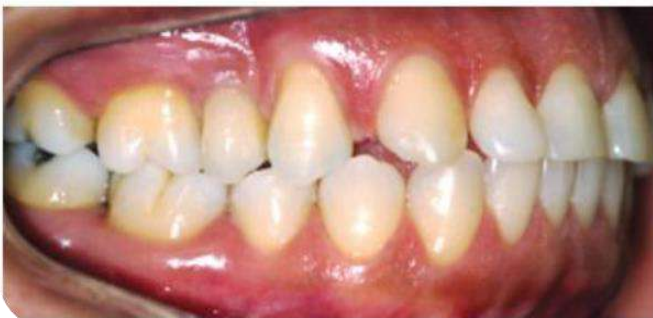
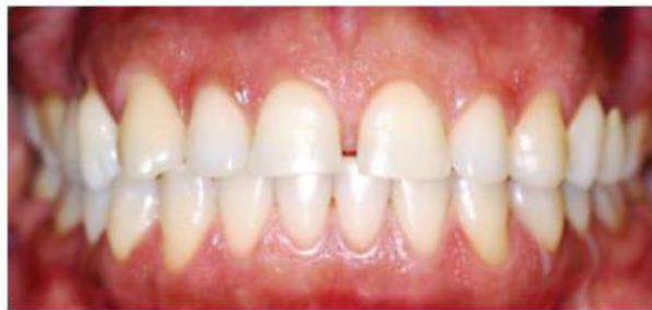## 2. Florid COD:

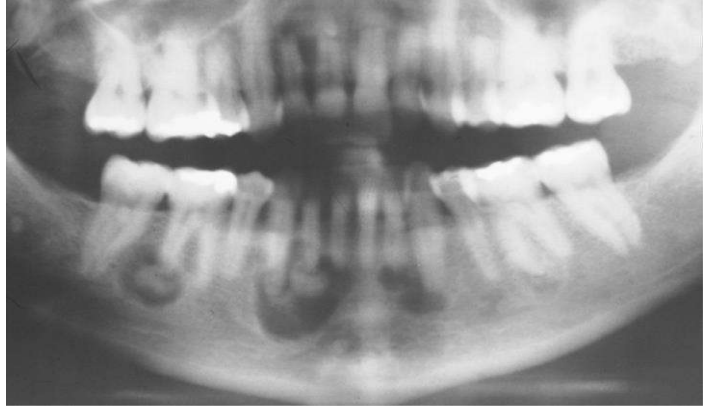
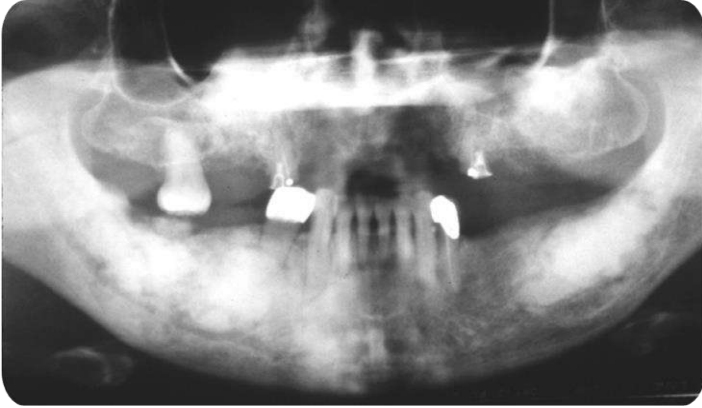
The FCOD is an exuberant<sup>1</sup> form of PACOD. FCOD represents the severe end of the spectrum of this unusual process. The patient is asymptomatic except when complication of osteomyelitis occurs. Females are more commonly affected (**black**



**women**); between 25-60 years of age. The condition is typically bilateral & may affect all four quadrants.



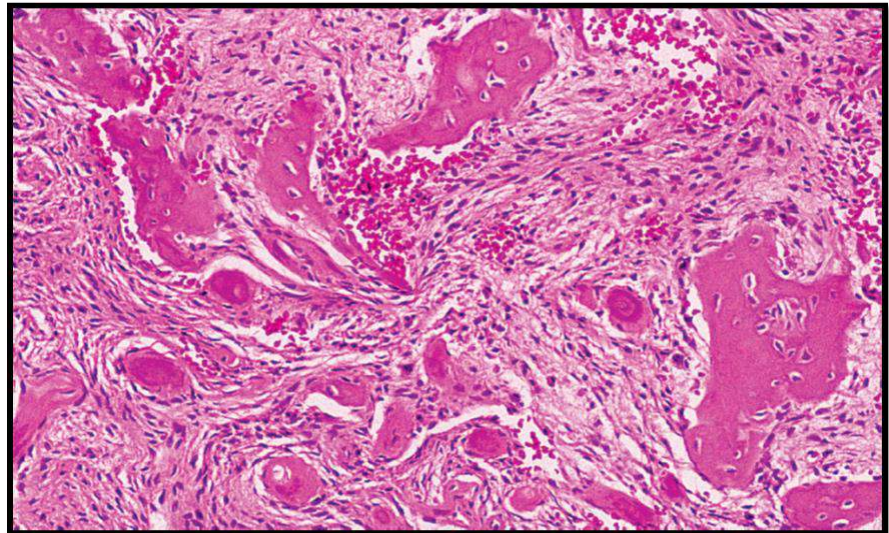
Radiographically, FCOD appears as diffuse radiopaque masses throughout the alveolar segment of the jaw. A ground-glass or cyst-like appearance may also be seen.



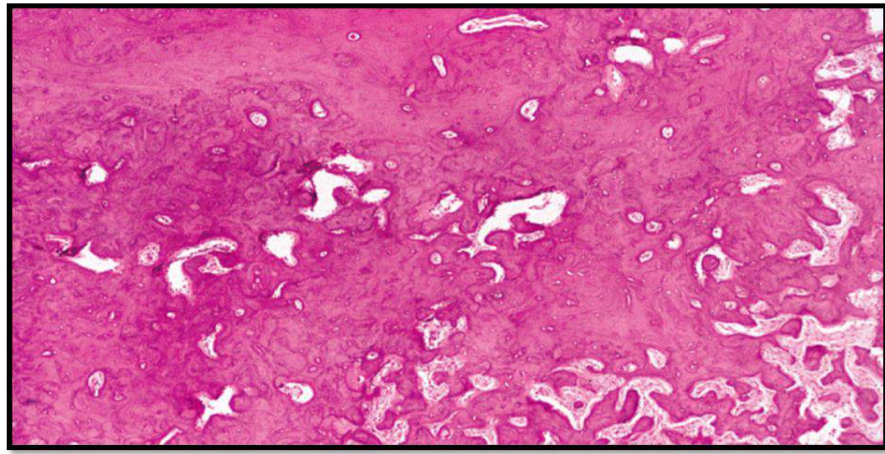
- **Histopathology of COD:**

All 3 types show a mixture of benign fibrous tissue, bone, and cementum. The calcified tissue is arranged in trabeculae, spicules or larger irregular masses. Numerous small blood vessels & free hemorrhage is typically noted throughout the lesion. The proportion of the mesenchymal component to the mineralized material is variable depending on the stage and from area to area in the same lesion.

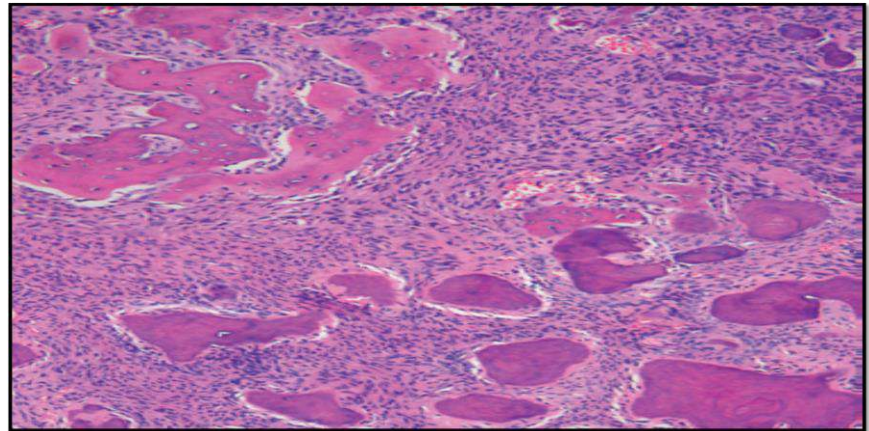
spicules of bone and cementum-like hard tissue within moderately cellular fibrous connective tissue. Note the hemorrhage around the bony trabeculae. →



**Late-stage lesion** showing a sclerotic mass of cemento-osseous material.



**Cemento-osseous dysplasia.** A very cellular fibrous tissue containing trabeculae of woven and sclerotic bone and islands of dense basophilic cementum-like bone. →



**Treatment:**

No treatment. For the asymptomatic patient, the best management consists of regular recall examinations with prophylaxis and oral hygiene reinforcement to control periodontal disease and prevent tooth loss

FCOD → sclerotic stage → decrease of vascularity → prone to necrosis & osteomyelitis → instruction for good oral hygiene to prevent infection.

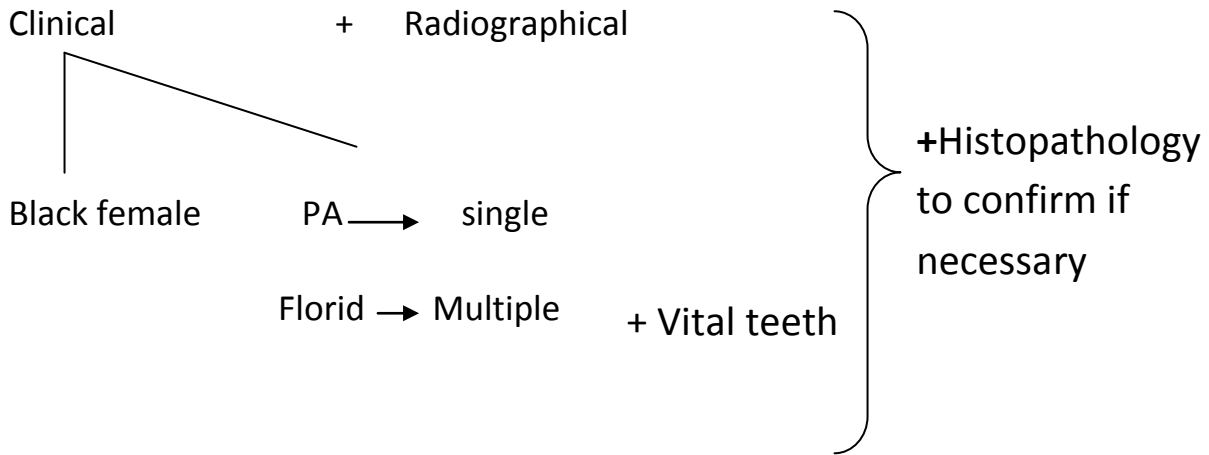
Management of the symptomatic patient who has developed secondary osteomyelitis is more difficult.



Antibiotics + Saucerization .



**Diagnosis:**



# Oral pathology

Lec.3

Dr.Ahlam Thabet

## Periapical Pathology

Inflammation in the periapical part of the periodontal ligament is similar to that occurring elsewhere in the body, but, because of the confined space within which the process develops; a particular feature of inflammation in this site is that the adjacent bone and occasionally the root apex may resorb. However, the periapical tissue heals, if the cause of inflammation is removed.

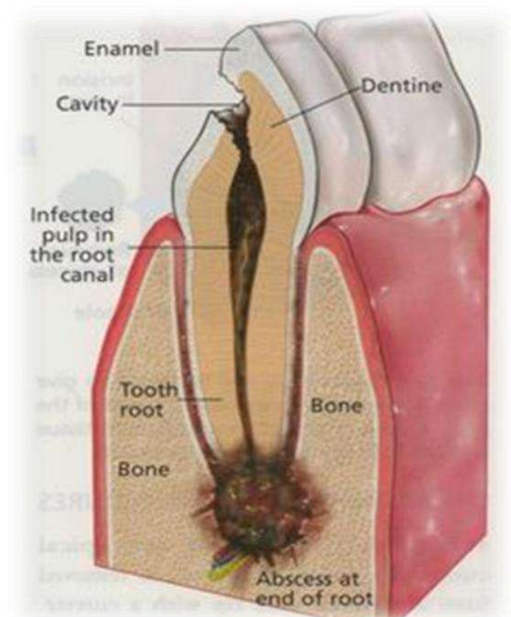
The periapical periodontitis is different from pulpitis in the following:

- 1 -The periapical periodontitis differs markedly from pulpitis where the potential for healing is very limited.
- 2 -The symptoms are also different in that they are generally well located by the patient to a particular tooth, due to the presence of the proprioceptive nerve ending in the periodontal ligament.

**The factors which may affect these lesions are :**

- 1- The presence of open or closed pulpitis.
- 2- Virulence of the involved micro organisms .
- 3- Extent of sclerosis of the dentinal tubules.
- 4- Competency of the host immune response of the individual.

Where these factors are optimal e.g. the presence of an open chronic pulpitis, bacteria of few virulence, and an older tooth with sclerotic dentinal tubules in a healthy ((immune component)) individual, the changes at the apex of the tooth are mild and chronic.



Where the conditions are mostly adverse e.g. the presence of a closed acute pulpitis, large numbers of highly virulent bacteria, and open dentinal tubules of young teeth, the inflammation at the apex of the tooth will rapidly intensify and large amounts of bacterial toxins and autolytic enzymes will be produced and disseminated leading to rapid destruction of the periapical tissue and the surrounding bone ((e.g. acute periapical abscess).

## A etiology of periapical periodontitis

### 1 -Pulpitis and pulp necrosis:

If pulpitis is untreated, bacteria, bacterial toxins and the product of inflammation will extend down the root canal and through the apical foramina to cause periodontitis.

### 2 -Trauma :

**Occlusal trauma** either from a high restoration or less frequently associated with bruxism, may result in periapical periodontitis under **pressure during orthodontic treatment**, a **direct blow** on tooth insufficient to cause pulp necrosis and **biting unexpectedly on a hard body** in food may all cause minor damage to the periodontal ligament and localized inflammation .

### 3- Endodontic treatment

Mechanical instrument through the apex during endodontic treatment as well as chemical irritation from root filling material may result in inflammation in the periapical periodontium. Instrumentation of an infected root canal may be followed by periapical inflammation, due to bacterial proliferation in the root canal or due to bacteria being forced into the periapical tissues .

#### 1. Acute periapical periodontitis

Spread of infection through the apex brings the causative bacteria from a protected site into an environment where the host can mount an effective host response . Acute inflammation and an immune reaction are trigger.

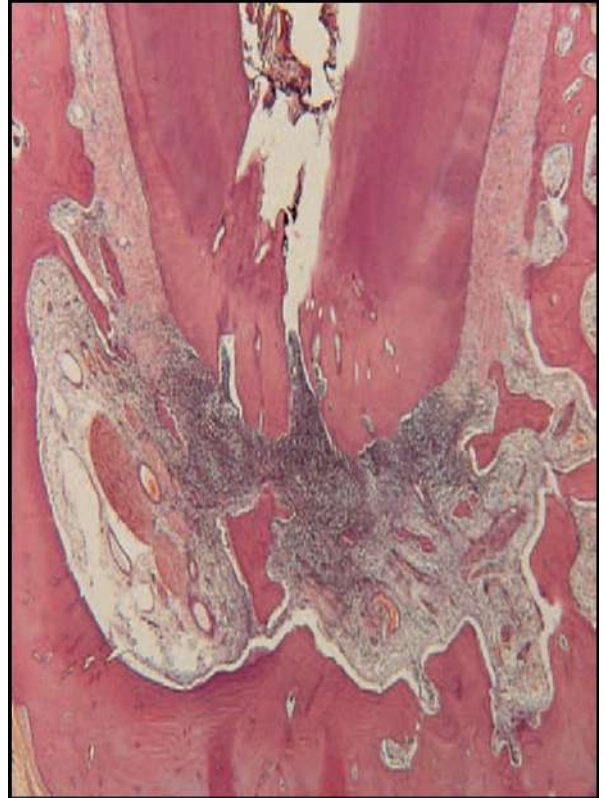### ❖ **Clinically:**

Pain is intense when external pressure is applied to the tooth, as the pressure is transmitted through the fluid exudates to the sensory nerve endings. Even light load may be sufficient to induce pain, as the fluid is not compressible; the tooth feels elevated in its socket. Hot and cold stimulation does not cause pain.

### ❖ **Histopathological findings:**

Vascular dilatation, exudates of neutrophils, and oedema, in the periodontal ligament situated in the confined space between the root apex and the alveolar bone

The findings are often normal as there is generally insufficient time for bone resorption to occur between the time of injury to the periodontal ligament and the onset of symptoms. If radiological changes are present, they consist of slight widening of periodontal ligament and the lamina dura around the apex.



### ❖ **Sequela and prognosis**

The inflammation may be transient if it is due to acute trauma rather than infection and the condition seen resolves. If the irritant persists the inflammation becomes chronic and may be associated with resorption of the surrounding bone. Suppuration may occur associated with necrosis and bacterial infection with continued exudation of neutrophils leading to abscess formation, called acute periapical abscess.

## **2. Chronic apical periodontitis (periapical granuloma)**

The term periapical granuloma refers to a mass of chronically or sub acutely inflamed granulation tissue at the apex of a non-vital tooth. The formation of the periapical granuloma represents a definitive reaction secondary to the presence of microbial infection in the root canal with spread of related toxic products into the apical zone .

In the early stages of infection, neutrophils predominate, and radiographic changes are not present, this phase of periapical inflammation is termed acute periapical periodontitis.

The neutrophils release prostaglandins which activate osteoclasts to resorb the surrounding bone leading to detectable periapical radiolucency. With time, chronic inflammatory cells begin to dominate the host response. Mediators released by lymphocytes reduce further osteoclastic activity while also stimulating fibroblast and microvasculature.

For this reason chronic periapical granuloma is often asymptomatic and demonstrates little additional changes radiographically.

#### ❖ **Clinical features:**

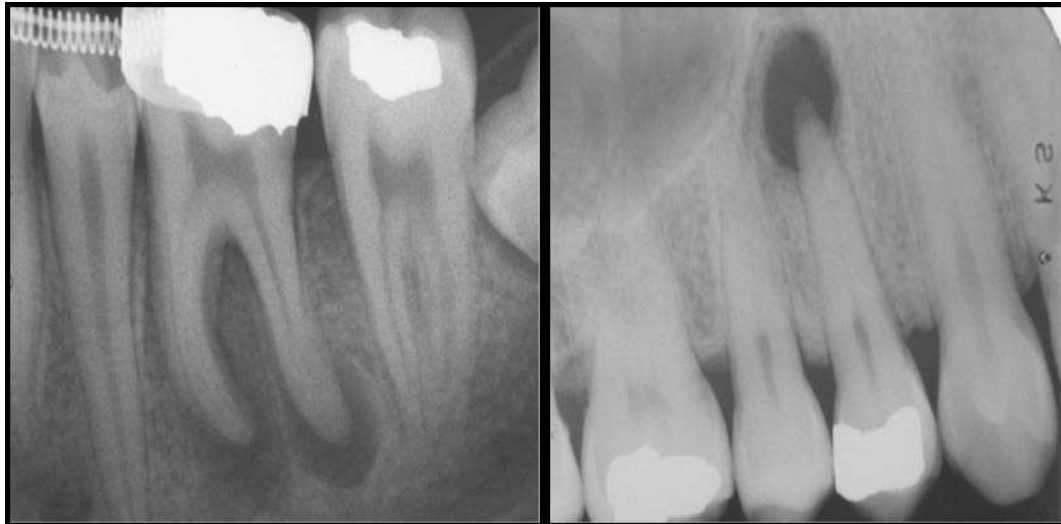- 1-Most of periapical granulomas are asymptomatic.
- 2 -Pain may develop if acute exacerbation occurs.
- 3 -Typically the involved tooth does not demonstrate mobility or significant sensitivity to percussion.
- 4 -The soft tissue overlying the apex may or may not be tender
- 5- The tooth does not respond to thermal or electric pulp tests unless the pulp necrosis is limited to a single canal in a multirooted tooth.

#### ❖ **Radiographic features**

Most lesions are discovered on routine radiographic examination which may show:

- 1-Variable radiolucencies ranging from very small to 2 cm in diameter.
- 2 -Affected teeth typically reveal loss of the apical lamina dura.
- 3 -The lesion may be circumscribed or ill-defined and may or may not demonstrate a surrounding radiopaque rim.
- 4 -Root resorption may be seen.

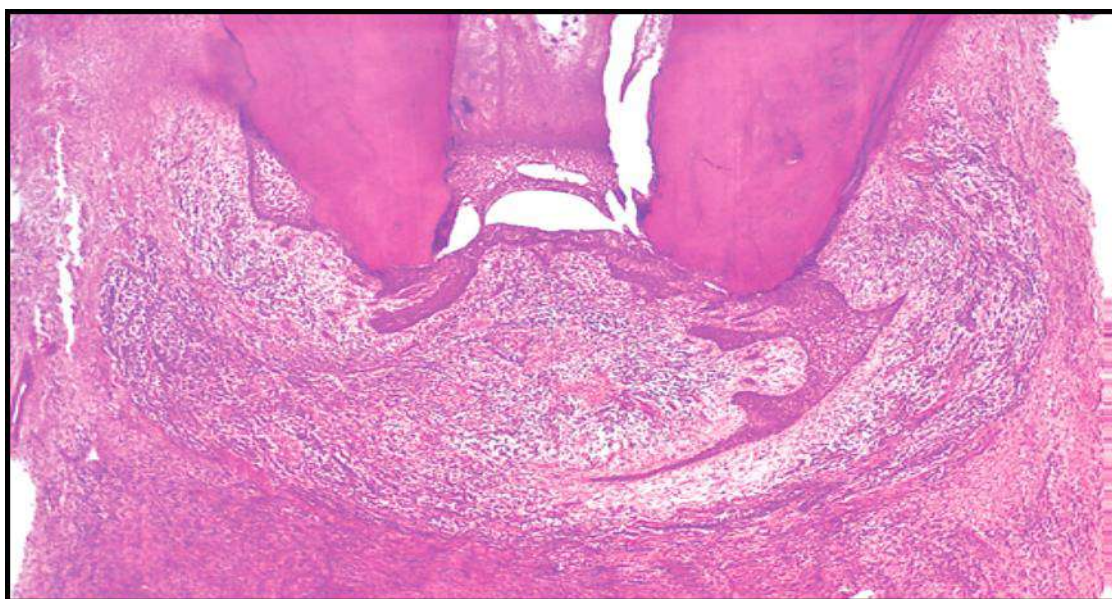
The radiographic features are suggested but not diagnostic

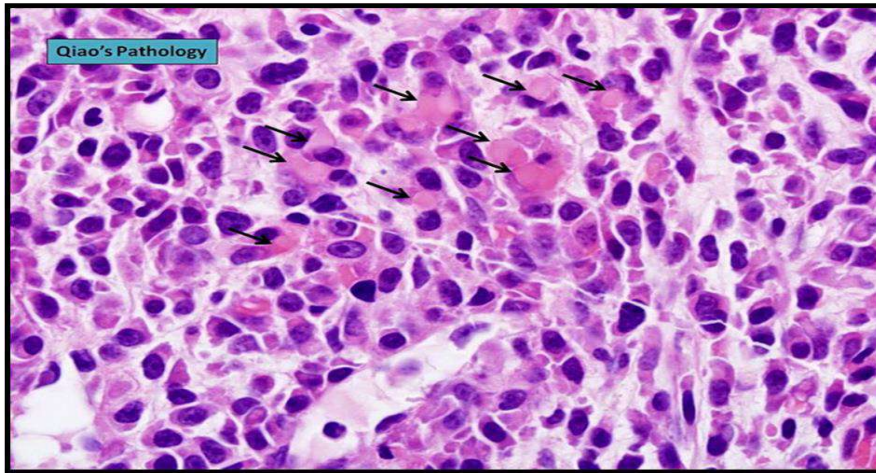


### ❖ Histopathological Features

Periapical granulomas consist of an inflamed granulation tissue surrounded by fibrous connective tissue wall. The central part of the lesion contains macrophages with **foamy cytoplasm** caused by the phagocytosis of cholesterol.

Cholesterol crystals may be present surrounded by multinucleated giant cells. A diffuse infiltrate of lymphocytes and plasma cells. When numerous plasma cells are present, scattered eosinophilic globules of gamma globulin (**Russell bodies**) may be seen. A frequent finding is the presence of irregular islands of epithelium, a result of prolonged, mild stimulation of the rest malassez, which are remnants of the Hertwig root sheath.





Russell bodies

### ❖ Treatment and prognosis:

Treatment depend on the reduction and control of the offending micro-organisms or their toxic products in the root canal or apical tissues. A successful treatment depends on the complexity of the canal system and size of the periapical granuloma (more than 2 canals is difficult to be treated by conservative endodontic therapy).

Non restorable teeth may be extracted, followed by curettage of all apical tissues, with non-steroidal anti-inflammatory drugs in symptomatic cases. Antibiotic are not recommended unless systemic signs and symptoms are present

The teeth after conventional endodontic should be evaluated at 1-3-6 months and 1-2 years.

If initial conventional therapy is unsuccessful, periapical surgery is indicated which include through curettage of all periradicular soft tissue, amputation of the apical portion of the root and scaling of the lumen of the canal, all tissues should be submitted for histopathological examination to exclude more serious conditions, like neoplastic process.

### ❖ Sequelae:-

- 1- Periapical granuloma may continue to enlarge with continued bone resorption
- 2 - Acute exacerbation to an acute periapical periodontitis
- 3- A suppuration to form an acute periapical abscess

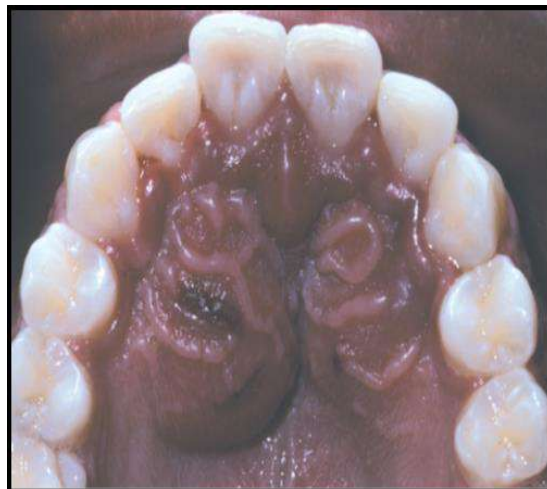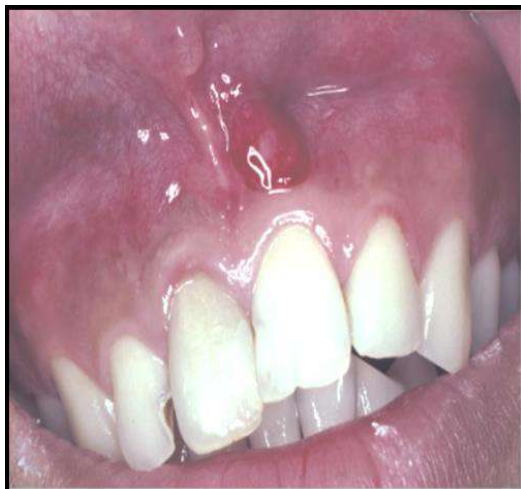
- 4 - Formation of a radicular cyst
- 5- Low grade irritation may cause osteosclerosis (bone apposition) or cementum apposition (hypercementosis).

### **3. Acute Periapical Abscess**

The accumulation of acute inflammatory cells at the apex of a nonvital tooth is termed a periapical abscess.

#### **Causes :**

1. It is a progression of an acute pulpitis in which exudates extend into the adjacent soft and hard tissue. Because it often contains one or more strains of virulent bacterial organisms, the exudates usually contains potent exotoxins and lytic enzymes capable of rapidly breaking down tissue barriers.
2. Another cause is the acute exacerbation of a chronic periapical granuloma.



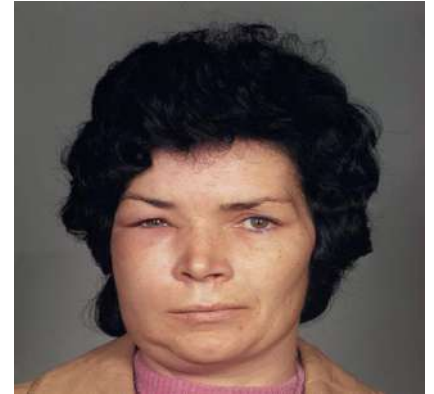#### **❖ Clinical features**

Patients have severe pain in the area of the non-vital tooth because of pressure and the effects of inflammatory chemical mediators on nerve tissue. The exudates and neutrophilic infiltrate of an abscess cause pressure on the surrounding tissue, often resulting in slight extrusion of the tooth from its socket.

Pus associated with a lesion, if not focally drained from the tooth ((e.g. by endodontic treatment)), seeks the path of least resistance and spread into

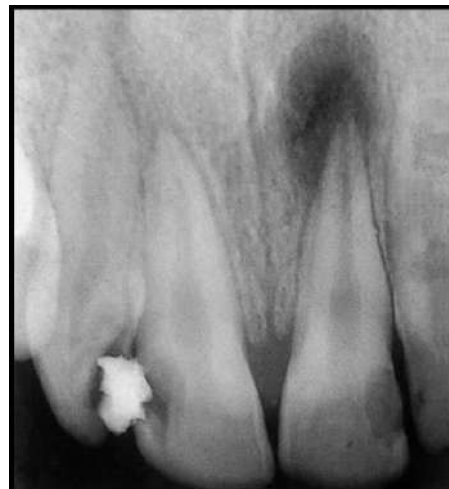
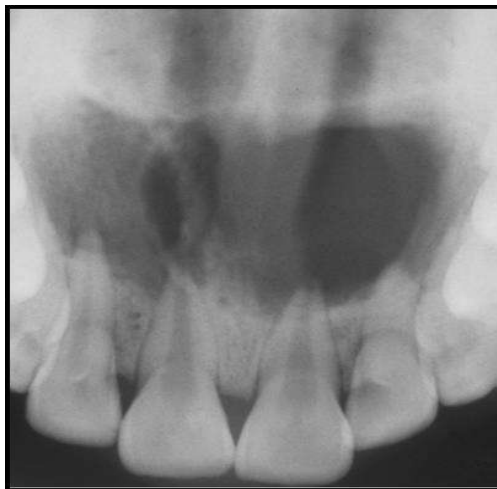
contagious structures. The affected area of the jaw may be tender to palpation, and the patient may be hypersensitive to tooth percussion. The tooth is not responding to electric pulp tester, or thermal stimuli, headache, malaise, fever and chills may be present.



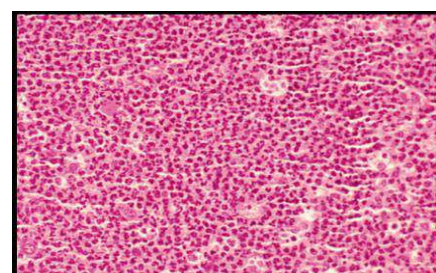
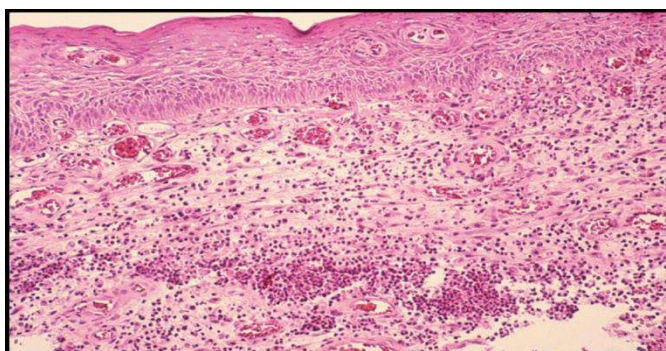
### ❖ Radiographic features:-

Abscess may demonstrate a thickening of apical periodontal ligament, an ill-defined radiolucency, or both. However, often no appreciable alterations can be detected because insufficient time has occurred for significant bone destruction. If the condition is an exacerbation of a chronic periapical periodontitis or periapical granuloma. It could demonstrate the outline of the original chronic lesion with or without the associated bone loss.



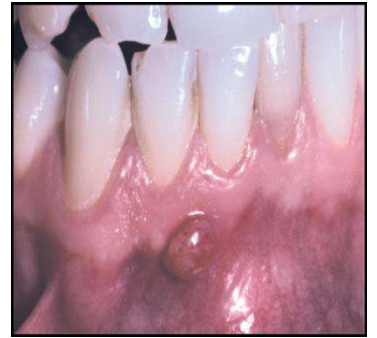### ❖ Histopathology-Microscopically

A periapical abscess appears as a zone of liquefaction, composed of pertinacious exudates, necrotic tissue and viable and dead neutrophils, (pus). Adjacent tissues containing dilated vessels and a neutrophilic infiltrate surrounds the area of liquifactive necrosis.



### ❖ Sequelae:

1-With progression, the abscess spreads along the path of least resistance and discharge into the oral cavity through a sinus tract following local penetration of overlying periosteum and mucosa. This is usually not painful.



2- On other occasions the pus may accumulate beneath the mucosa and the patient may complain of a swelling at the intraoral opening of a sinus tract, which is a mass of subacutely inflamed granulation tissue known as parulis ((Gum boil))

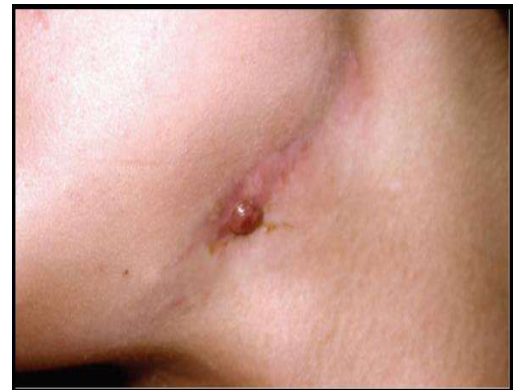3- May extend through the medullary spaces away from the apical area, resulting in osteomyelitis

4 -It may perforate the cortex and spread diffusely through the overlying soft tissue as cellulitis.

5 -Dental abscesses may discharge through the skin and drain via a cutaneous sinus. —————>

6- Periapical infection occasionally spread the blood stream and result in systemic symptoms such as fever, lymphadenopathy and malaise.

7 -It may spread diffusely through facial planes of the soft tissues. This acute and edematous spread of an acute inflammatory process is termed cellulitis.



### Cellulitis

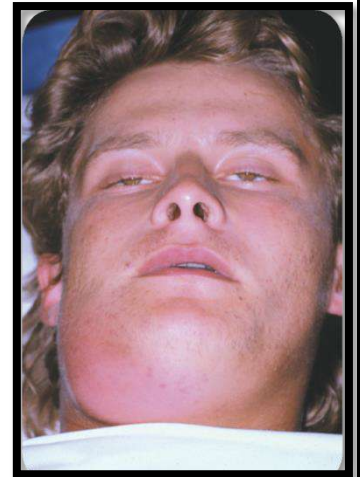
Is a misnomer, because the process is not an inflammation of the cells but an acute condition in which purulent forms of bacteria, involve the facial and perioral mucosa.

The most common cause is extension from a periapical abscess. However other causes may also results in cellulitis like fractures.

### Sequelae:

1. **Oroantral fistula** : Occasionally the exudates tracks onto the palate, producing a large swelling, when a periapical abscess erodes into the maxillary sinus, destroying the intervening bone and lining, and the

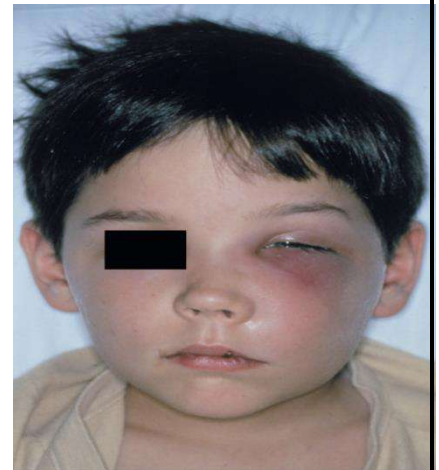offending tooth is extracted, a communication between the floor of the maxillary sinus and the oral cavity may result. This tract may remain permanently patent, particularly if it becomes lined by epithelium of the maxillary sinus and the oral cavity. This abnormal open communication is called oroantral fistula.



2. **Ludwig's angina:** When the muscle layers overlying the body of the mandible are involved, patients experience a puffy swelling on the side of the face. Extension of the pus linguallly into the tissue spaces of the posterior floor of the mouth may result in swelling of the structures around the epiglottis which is a life threatening, as it restricts the airway and may cause suffocation.

So a Cellulitis of this area ((submental , submandibular and sublingual spaces)) is called Ludwig's angina.

3. **Thrombophlebitis :** Another serious complication is the extension of the exudates into the maxillary cavernous sinus area, resulting in thrombophlebitis. From this location fatal forms of brain abscess or acute meningitis are possible unless rapid intervention is undertaken.



### ❖ **Treatment and prognosis**

Treatment of periapical abscess consist of drainage and elimination of the focus of infection

Localized abscess should be drained by incision and drainage. If the abscess is localized with no systemic features ((fever, lymphadenopathy and malaise)), the patient is healthy, antibiotics are not recommended. However if the patient is compromised (e.g. diabetic) or, systemic symptoms are present antibiotics are recommended.

NSAID is needed if not contraindicated. The tooth should be endodontically treated or extracted. Sinus and fistula tracts if not treated spontaneously after extraction, should be removed surgically

## **Radicular cyst**

### **1- Apical radicular cyst**

Apical radicular cyst are the most common cystic lesions in the jaws and are always associated with apex of non-vital teeth , they account for about 75% of all radicular cyst. When small they are frequently symptomless and are usually discovered during routine radiographical examination as they enlarge, they produce expansion of alveolar bone and ultimately may discharge through sinus. However the majority of radicular cyst does not grow to large dimension. The expansion of the alveolar bone is due to deposition of successful layers of new bone by overlying periosteum. As the cyst enlarge and cause bone resorption centrally. Increments of new subperiosteal bone are lead down to maintain the integrity of the cortex. Producing a bony hard expansion. However the rates of expansion tens to out strip the rate of subperiosteol deposition. Leading to progressive thinning of the cortex which can be default on palpitation producing the clinical signs of oil can bottoming and egg shell is crackling. Eventually the cyst may perforate the cortex and present as a bluish fluctuant sub mucosal swelling.

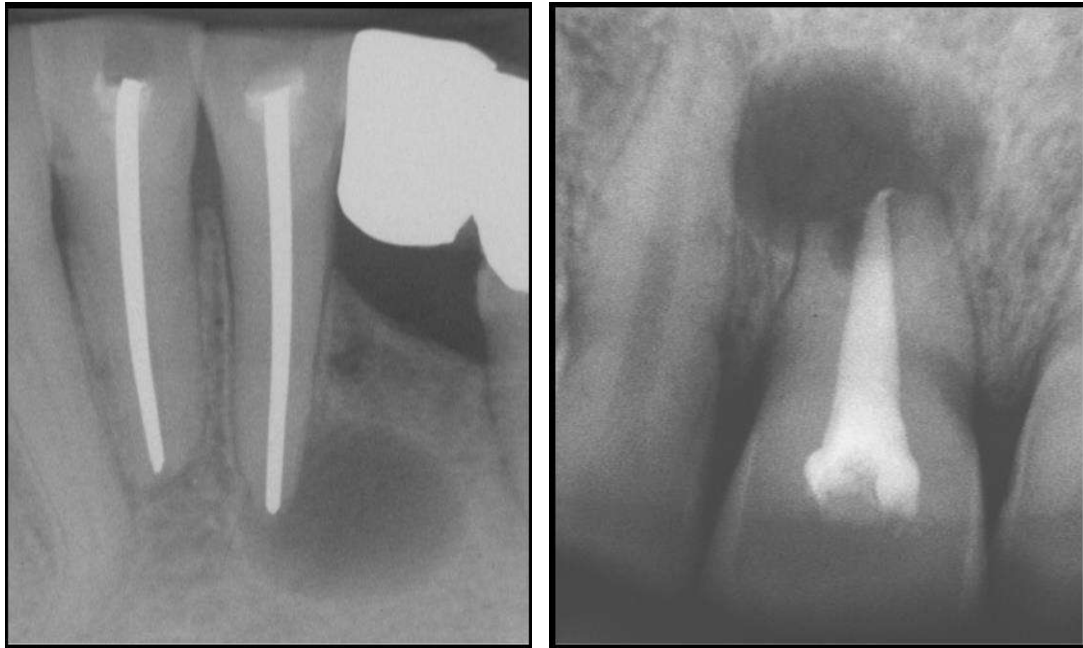### **Clinical Features :**

Pain is seldom a feature unless there is an acute exacerbation which may readily progress to abscess formation. The cyst can rise at any age after the tooth eruption but are rare in deciduous dentition. They are most common between the ages of 20-60. They can occur in relation to ant tooth in the arch although 60% are found in the maxilla where there is a particular high incidence in anterior teeth. In addition to dental caries pulp death from trauma and irritant restorative material is more likely in anterior teeth than at other sites. Pulp death in maxillary lateral incisors may also be associated with an invaginated odontoma in the mandible the majority of cyst occur posterior to the canine tooth.

### **❖ Radiographically**

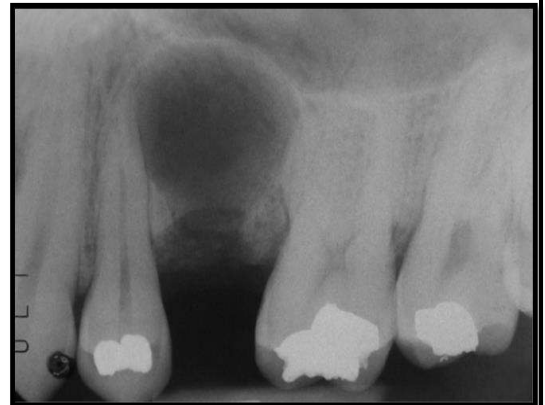The apical radicular cyst presents as a round or avoid radiolucency at the root apex. The lesion is often well circumscribed and may be surrounded by peripheral radio-opaque margins continues with lamina dura of the involved

tooth. However whether or not cyst formation has occurred in an apical radiolucency cannot be detected from radiographic appearance alone.



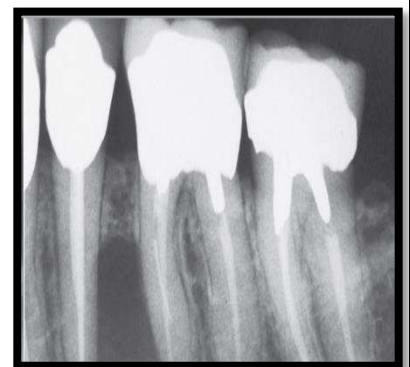## 2- **The residual cyst**

Is a radicular cyst that has remained in the jaw and failed to resolve following extraction of the involved tooth. About 20% of radicular cysts are of this type. However it should be noted that most periapical inflammation will resolve after removal of the causative agents. The reasons why some lesion persists as residual cyst are unknown. Are more frequent in older persons and present with expansion of the jaw.



## 3-**The lateral cyst**

Is very uncommon and arises as a result of extension of inflammation from the pulp to into the lateral periodontal along the lateral root canal



## ❖ **Pathogenesis**

Radicular cyst arises from proliferation of rest of malassez within chronic periapical granulomas but not all granulomas progress to cyst. The factors

which determine why cystic transformation occurs in some and the mechanism involved in the formation of cyst are controversial. Persistence of chronic inflammatory stimuli are derived from the necrotic pulp appears essential since as mentioned above. Most periapical inflammation will resolve spontaneously once the causative agent has removed. It is assumed that the environment within chronically inflamed granuloma. Which is likely to be rich in cytokines including growth factors? Stimulates the rate of malassez to proliferate strands and sheets of squamous epithelium derived from proliferation of the rest are common finding in the periapical granulomas. The mechanism of formation of an epithelial lined cyst cavity within granuloma is unclear. Two main mechanism have been proposed

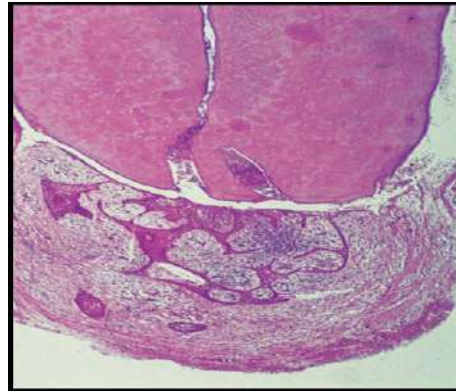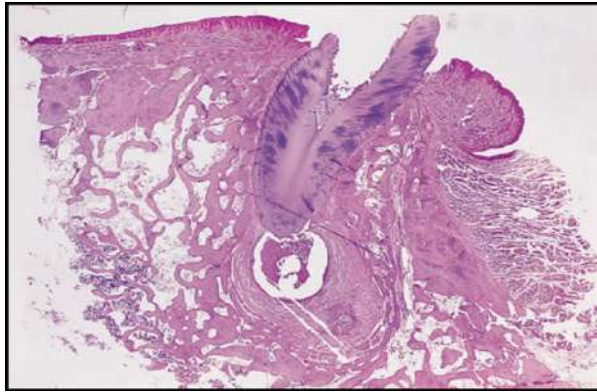
1- Degeneration and death of central cells within a proliferating mass of epithelium. Epithelium is a vesicular and transport of metabolites and gaseous exchange occur by diffusion. It argued that when the mass proliferating epithelium within granuloma reaches a critical size. The central cells furthers away from the surrounding vascular bed. Degenerate and die, the micro cyst so formed then continues to expand

2 - Degeneration and liquifactive necrosis of granulation tissue. It is suggested that areas of granulation tissue within the granuloma may undergo necrosis due to enclavement by proliferating strands of epithelium or to release toxic products from a dead pulp or from infecting organism. Epithelial proliferation to surround such an area of necrosis results in the formation of cyst.

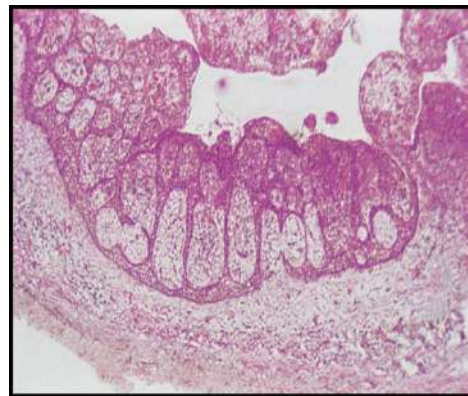
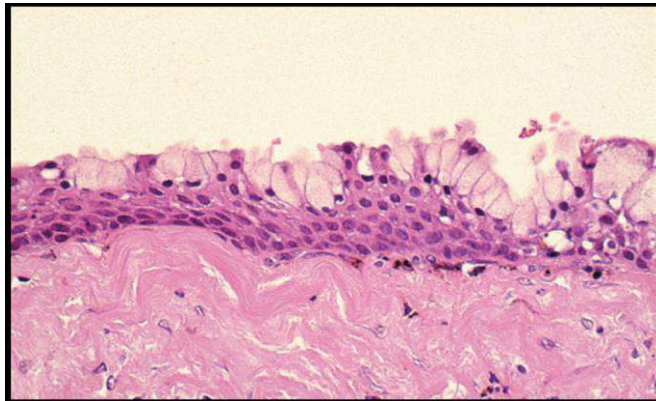
### ❖ **Histopathology:**

Radicular cyst are lined wholly or impart by know keratinized stratified squamous epithelium supported by a chronically inflamed fibrous tissue capsule.

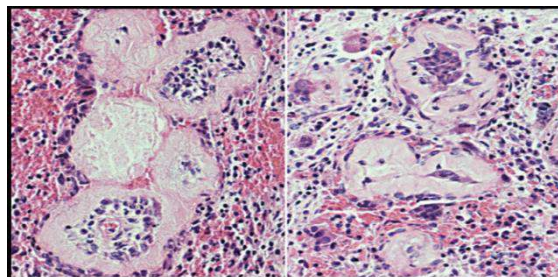
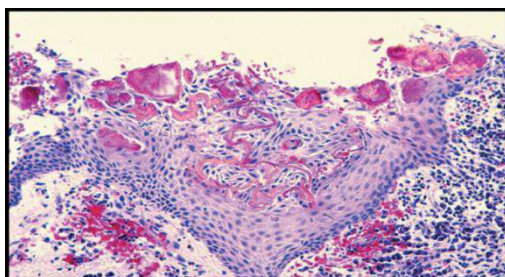
In a newly formed cyst the epithelial lining is irregular and may vary considerably in thickness. Hyperplasia is a prominent feature in long anastomosing cords of epithelium forming complex arcades extending into the surrounding capsule. The latter is richly vascular and diffusely infiltrated by inflammatory cells often predominant.



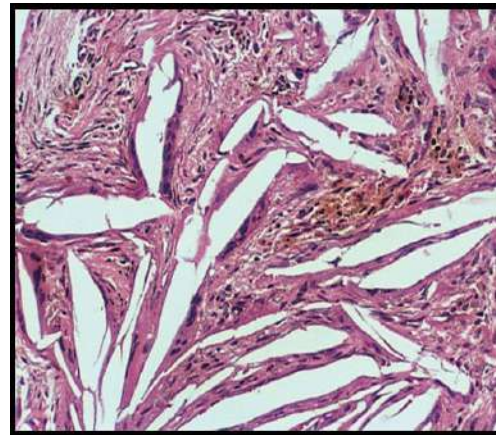
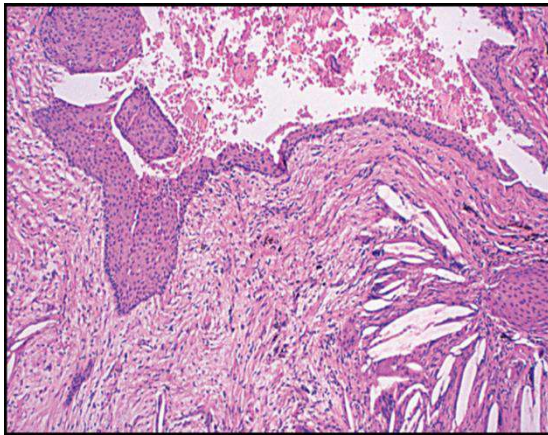
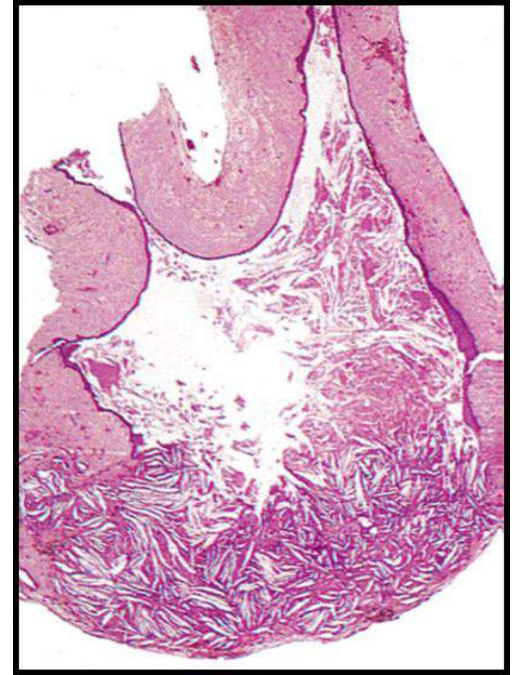In established cyst the epithelial lining is more regular in appearance and fairly even thickness breaks in the linings epithelial discontinuities are common. Metaplasia of epithelial lining may give rise to a mucus cell. Found in about 40% of radicular cyst lining and more rarely ciliated cells and area of respiratory type epithelium.



In most cases the lining contains hyaline eosinophilic bodies **Rushton bodies** of varying size and shape. They appear to have no clinical or diagnostic significant and they origin is unknown. But they may represent some type of epithelial product. Within time the connective tissue capsule tends to become more fibrous and less vascular and there is reduction in the density of inflammatory cell infiltration, myofibroblast in capsule may help to constrain the tendency of the cyst to expand.



Deposits of cholesterol crystals are common within the capsules of many radicular cysts. In histological sections cholesterol clefts may be few in number of forms large mural nodules in which case they are often associated with epithelial discontinuity and project into cyst lumen. They are the probable of cholesterol crystals found in the cyst fluid; mural cholesterol clefts are associated with foreign body giant cells. As a periapical granulomas the cholesterol probably derived from the breakdown of red blood cells as a result of hemorrhage in the cyst capsule and deposits of hemosiderin are commonly associated with the clefts.



### ❖ Cyst Contents :

The cyst contents vary from a watery straw color fluid through to semi solid brownish material of paste like consistency. Cholesterol crystals impart a shimmering appearance the composition of cyst fluid is a complex of variable it is hypertonic compared with serum and contents

- 1-Breakdown products of degenerating epithelial cell and inflammatory cell and connective tissue components
- 2 -Serum proteins all groups of serum proteins are present in cyst fluid Compared with serum the fluid contain higher level of immunoglobulin which probably reflect local production of plasma cells in the capsule
- 3 -Water and electrolytes
- 4 -Cholesterol crystal.



### ❖ Cyst expansion :

Cysts expansion is dependent on osteoclastic resorption of surrounding bone. Osteoclasts are derived from haematopoietic precursors and are transported via the blood.

- Osteoclasts are recruited to and activated at sites of resorption by mediators. The cytokines interleukin-1 and interleukin-6 (IL-1, IL-6), tumor necrosis factor and prostaglandin E2 are key mediators in cyst expansion.
- Mediators are generated locally by a variety of cells e.g.: macrophage, lymphocytes, epithelial cells, fibroblast.
- Activated osteoclast attached to the bone surface and release acids resulted in de mineralization. The organic matrix is then degraded by matrix metalloproteinase MMP's, collagenases, and lysosomal proteases.
- MMP's synthesized by other cells in the cyst wall e.g.: fibroblasts, epithelial and inflammatory cells, may contribute to matrix degradation.
  - \* • Bone resorption is followed by cyst expansion which may involve hydrostatic pressure.
- Cyst contents are hypertonic. The wall acts as a semi permeable membrane and retains the osmotically active molecules in the lumen creating an osmotic gradient. Water moves into the lumen along the gradient increasing the hydrostatic pressure in the cyst leading to enlargement.

### ❖ Treatment of radicular cyst:

The treatment of periapical radicular cyst depend on the condition of the tooth as whole, if the tooth is restorable, the root canals can be filled, if the root canals cannot be filled and the apical area is in a location accessible for surgery, an apicoectomy with complete surgical enucleation may be performed to remove the cystic lesion, followed by histopathological examination; otherwise, the tooth is extracted and the periapical cyst is curreted through the tooth socket.

# Oral pathology

Dr.Ahlam Thabet

Lec. 4

## Inflammatory diseases of the bone

Inflammatory diseases of bone can be divided into three broad but overlapping categories depending largely on the extent on involvement of the bone

**1-Osteitis:** - this term is used to describe a localized inflammation of bone with no progression through the marrow spaces. Particularly that associated with infected sockets following removal of teeth, (dry socket).

**2-Osteomyelitis:** - extensive inflammation of the interior of the bone involving, and typically spreading through the marrow spaces.

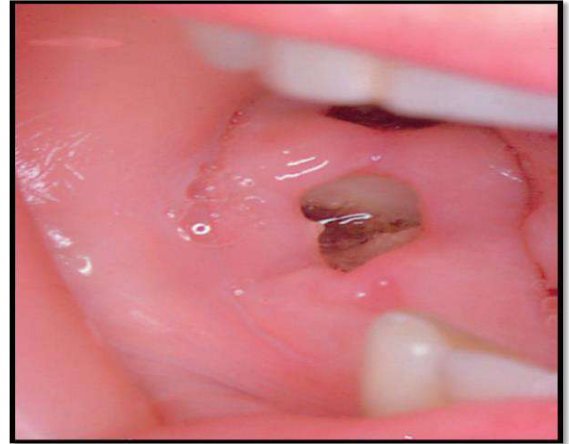
**3-Periostitis:** - inflammation of the periosteal spaces of the bone and may not be associated with osteomyelitis.

### **I. Alveolar osteitis (Dry socket ; fibrinolytic alveolitis)**

The most frequent painful complication of extraction . After extraction of a tooth, a blood clot is formed at the site, with eventual organization of the clot by granulation tissue, gradual replacement by coarse fibrillar bone, and, finally, replacement by mature bone. Destruction of the initial clot prevents appropriate healing and causes clinical syndrome known as alveolar osteitis . Extensive investigations have shown that the clot is lost secondary to transformation of plasminogen to plasmin, with subsequent lysis of fibrin and formation of kinins (fibrinolytic alveolitis): these are potent pain mediators. Local trauma, estrogens, and bacterial pyrogens are known to stimulate fibrinolysins.

### Causes:

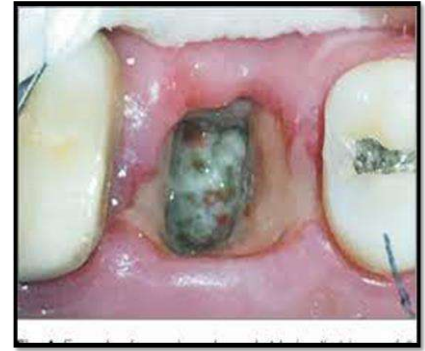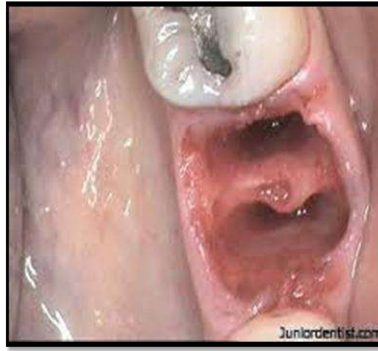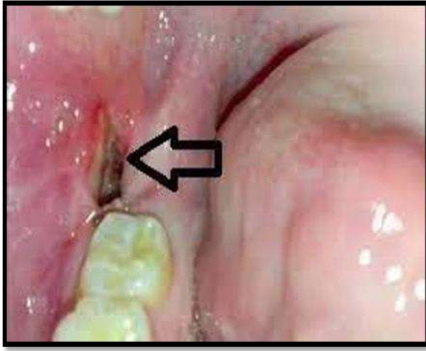
- Traumatic extractions ( inexperienced surgeons)
- Presurgical infections
- Oral contraceptive use
- Inadequate irrigation at surgery
- The use of tobacco products .
- Radiotherapy.
- Osteosclerotic disease: Paget's disease, cementoosseous dysplasia.



### Clinical Features

The frequency of alveolar osteitis is higher in the mandible and the posterior areas. After oral contraceptive use is taken into account. They do not appear to be a significant sex predilection. The prevalence is between 1% and 3% of all extractions, but it increases to 25% to 30% for impacted mandibular third molars. The frequency appears to be decreased when impacted teeth are prophylactically removed rather than for therapeutic reasons after development of chronic inflammation of pericoronal tissues.

The overall prevalence is highest between 20 and 40 years of age (when the majority of teeth are extracted. although the likelihood of developing alveolar osteitis appears greatest for extractions in the 40- to 45-year-old age group .The affected extraction site is filled initially with a dirty gray clot that is lost and leaves a bare bony socket (dry socket). The detection of the bare socket may be hindered by partial retention of the clot or by overlying inflamed tissue that covers the site. The diagnosis is confirmed by probing of the socket, which reveals exposed and extremely sensitive bone. Typically, severe pain, foul odor, and (less frequently) swelling and lymphadenopathy develop 3 to 4 days after extraction of the tooth. The signs and symptoms may last from 10 to 40 days.



### **Treatment and Prognosis**

On evaluation of the patient complaining of post extraction pain, a radiograph should be taken of the affected area to rule out the possibility of a retained root tip or a foreign body. All sutures should be removed. The socket is irrigated with warm saline, followed by thorough clinical inspection of the socket for any unexpected pathosis. Curettage of the socket is not recommended, because this typically increases the associated pain. Potent oral analgesics should be prescribed, and the patient should be given a plastic syringe with instructions to keep the socket clean via home irrigation with a chlorhexidine or saline solution. This irrigation should continue until debris no longer collects within the healing socket (usually 3 to 4 weeks).

## **II. Osteomyelitis**

Is an acute or chronic inflammatory process in the medullary spaces or cortical surfaces of bone that extends away from the initial site of involvement. Osteomyelitis of the jaw was a common complication of dental sepsis before the advent of antibiotics, now it is a rare disease. Various clinical subtypes were recognized, leading to confusion in typing and classification, due to variation in the clinical and pathological features of osteomyelitis being acute, chronic, suppurative or sclerotic, this reflecting the balance between the nature and severity of the irritant, the host defense, local and systemic predisposing factors.

### ***Predisposing factors:***

- 1- Chronic systemic diseases, immunocompromised status, and disorders associated with decreased vascularity of bone.
- 2- Tobacco use, alcohol abuse and intravenous drug abuse.
- 3- Diabetes mellitus.
- 4- exanthematous fever and malaria
- 5- sickle cell anemia
- 6- malnutrition
- 7- malignancy
- 8- collagen vascular disease
- 9- AIDS
- 10- Radiation.
- 11- osteopetrosis, dysosteosclerosis, pagets disease, end-stage cemento-osseous dysplasia, may result in hypovascularized bone that is predisposed to necrosis and inflammation.

### **Types of Osteomyelitis**

#### ➤ **Suppurative osteomyelitis ( bacterial osteomyelitis )**

Are caused by bacterial infections and result in an expanding lytic destruction of the involved bone, with suppuration and sequestra formation.

#### ➤ **Diffuse sclerosing osteomyelitis**

An ill-defined group of idiopathic inflammatory disorders of bone that do not respond consistently to antibacterial medications and typically demonstrate ultimate sclerosis of bone without suppuration or sequestra formation.

#### ➤ **Focal sclerosing osteomyelitis.**

## **A. Suppurative osteomyelitis:**

**Acute suppurative osteomyelitis** the condition results when an acute inflammatory process spreads through the medullary spaces of the bone and insufficient time has passed for the body to react to the presence of the inflammatory infiltrate.

**Chronic suppurative osteomyelitis**: the condition result when the defensive response leads to the production of granulation tissue, which subsequently forms dense scar tissue in an attempt to wall of the infected area. The encircled dead space acts as a reservoir for bacteria, and antibiotics are difficult to reach the site. This pattern begins to evolve about one month after the spread of the initial acute infection and results in a smoldering process that is difficult to manage unless the problem is treated aggressively.

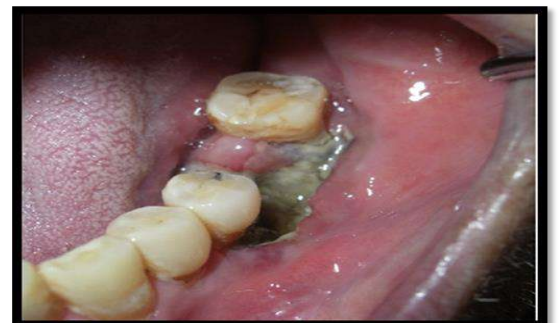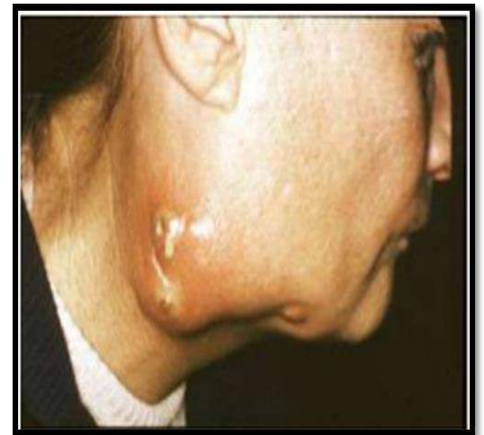
### **Clinical Features:**

#### **Acute osteomyelitis.**

Patients with acute osteomyelitis have signs and symptoms of an acute inflammatory process that has typically been less than 1 month in duration, Fever, leukocytosis, lymphadenopathy, significant sensitivity and soft tissue swelling of the affected area may be present.

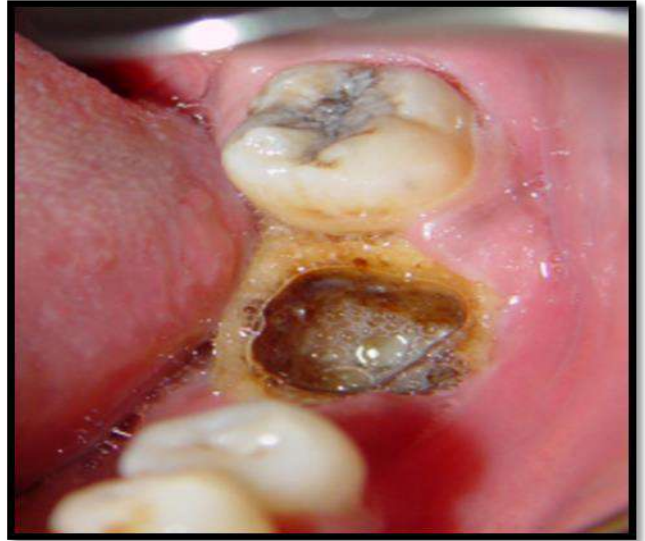On occasion; Paresthesia of the lower lip occur, drainage or exfoliation of fragments of necrotic bone may be discovered. A fragment of necrotic bone that has separated from the adjacent vital bone is termed a **sequestrum**.

Sequestra often exhibit spontaneous exfoliation, On occasion; Fragments of necrotic bone may become surrounded by vital bone and the mass of encased nonvital bone is called **an involucrum**.



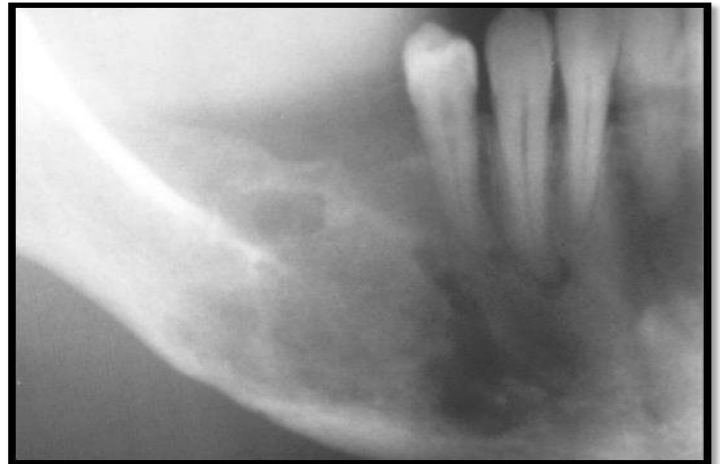
## Chronic osteomyelitis.

If acute osteomyelitis is not resolved expeditiously, the enhancement of chronic osteomyelitis occurs, or the process may arise primarily without a previous acute episode. There may be swelling, pain, sinus formation, purulent discharge, sequestrum formation, tooth loss, or pathologic fracture. Patients may experience acute exacerbation or periods of decreased pain associated with chronic smoldering progression.

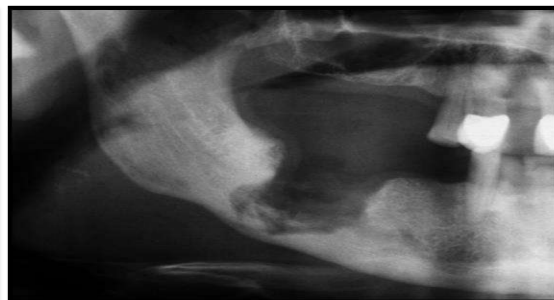
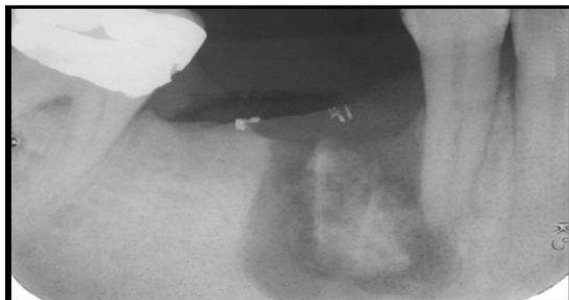

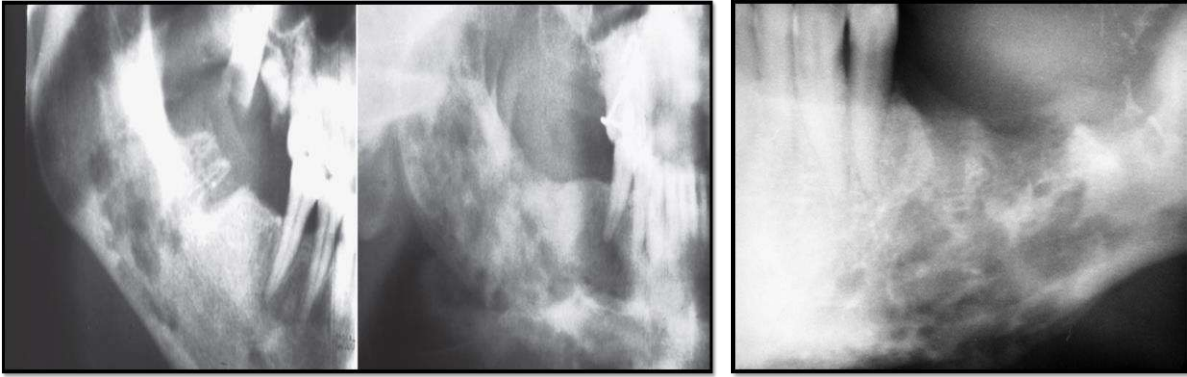
### Radiographically

**Acute osteomyelitis:** The radiographs may be unremarkable or may demonstrate an ill-defined radiolucency. —————>



**Chronic osteomyelitis :** Radiographs reveal a patchy, ragged and ill-defined radiolucency that often contains central radiopaque sequestra, occasionally; the surrounding bone may exhibit an increased radiodensity, and the cortical surface can demonstrate significant osteogenic periosteal hyperplasia. Sequestration that has involved an entire quadrant of the jaw has been reported in long-standing cases of chronic osteomyelitis.

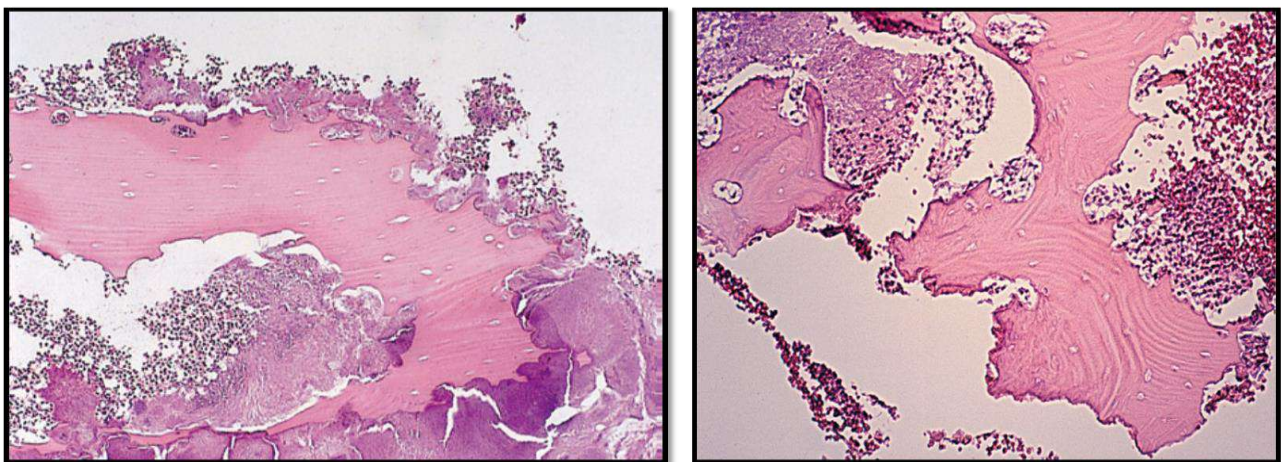




## **Histopathologic Features**

### ***Acute osteomyelitis.***

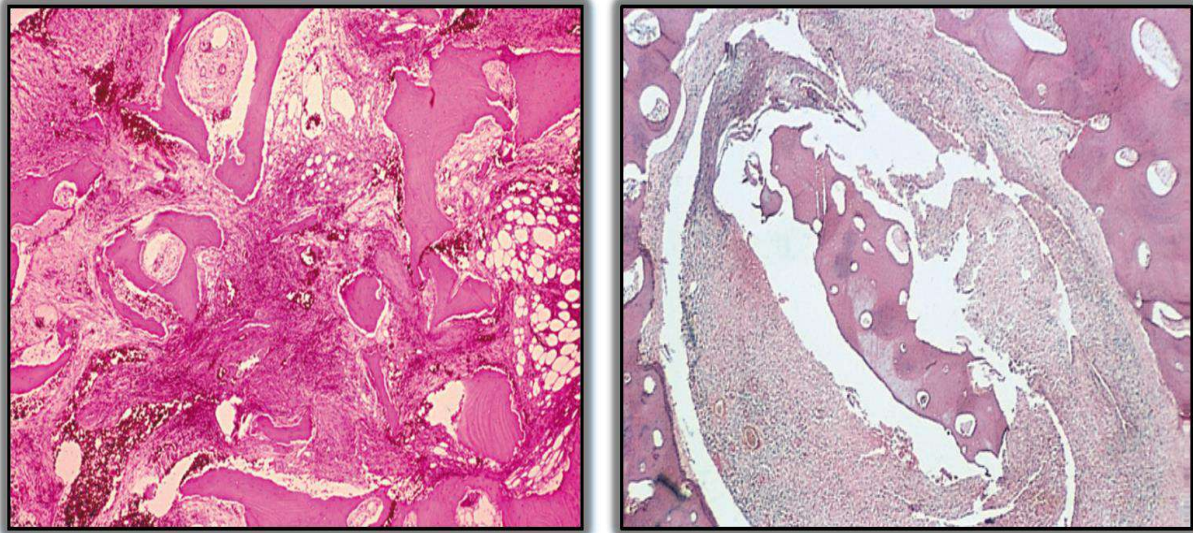
Generation of biopsy material from patients with acute osteomyelitis is not common because of the predominantly liquid content and lack of a soft-tissue component. When submitted, the material consists predominantly of necrotic bone. The bone shows a loss of the osteocytes from their lacunae. Peripheral resorption and bacterial colonization. The periphery of the bone and the haversian canals contain necrotic debris and an acute inflammatory infiltrate consisting of polymorphonuclear leukocytes. The submitted material will be diagnosed as a sequestrum unless a good clinicopathologic correlation points to the appropriate diagnosis of acute osteomyelitis.





### ***Chronic osteomyelitis.***

Biopsy material from patients with chronic osteomyelitis demonstrates a significant soft tissue component that consists of chronically or sub acutely inflamed fibrous connective tissue filling the Intertrabecular areas of the bone. Scattered sequestra and pockets of abscess formation are common.



### **Treatment and Prognosis**

***Acute osteomyelitis.:*** If obvious abscess formation is noted, the treatment of acute osteomyelitis consists of antibiotics and drainage. Microbiologic study of the infectious material typically reveals a polymicrobial infection of organisms normally present in the oral cavity. The antibiotics most frequently selected include penicillin, clindamycin, cephalexin, cefotaxime, tobramycin, and gentamicin. In most patients, a sufficient and appropriate antibiotic regimen aborts the infection and averts the need for surgical intervention. Several investigators have suggested that antibiotic therapy can bring about sterilization of the sequestra; therefore, these non vital bone fragments should be allowed to remain in place as scaffolding for the future development of new bone.

***Chronic osteomyelitis*** : Chronic osteomyelitis is difficult to manage medically, presumably because pockets of dead bone and organisms are protected from antibiotics by the surrounding wall of fibrous connective tissue. Surgical intervention is mandatory. The antibiotics are similar to those used in the acute form but must be given intravenously in high doses. The extent of the surgical intervention depends on the spread of the process; removal of all infected material down to good bleeding bone is mandatory in all cases. For small lesions, curettage, removal of necrotic bone, and saucerization are sufficient.

In patients with more extensive osteomyelitis decortications or saucerization often is combined with transplantation of cancellous bone chips. In cases of persisting osteomyelitis, resection of the diseased bone followed by immediate reconstruction with an autologous graft is required. Weakened jawbones must be immobilized. The goal of surgery is removal of all infected tissue. Persistence of chronic osteomyelitis is typically due to incomplete removal of diseased tissue. Upon successful elimination of all infected material, resolution is expected. Adjunctive procedures (e.g. hyperbaric oxygen) are rarely necessary if thorough surgical curettage and sequestrectomy have been accomplished. Hyperbaric oxygen is primarily recommended for the rare patient who does not respond to standard therapy or for disease arising in hypovascularized bone (e.g., osteoradionecrosis, osteopetrosis, Paget's disease. cemento-osseous dysplasia).

## **B. DIFFUSE SCLEROSING OSTEOMYELITIS**

Diffuse sclerosing osteomyelitis is an ill-defined, highly controversial, evolving area of dental medicine. This diagnosis encompasses a group of presentations that are characterized by pain, inflammation, and varying degrees of gnathic periosteal hyperplasia, sclerosis, and lucency. On occasion, diffuse sclerosing osteomyelitis can be confused with secondarily inflamed intraosseous pathoses (florid cementosseous dysplasia) or Paget's disease of bone. In spite of the clinical and radiographic similarities, these processes can be separated from diffuse sclerosing osteomyelitis because of various clinical, radiographic and histopathologic differences the remaining pathoses can be grouped under three major categories:

1-Diffuse sclerosing osteomyelitis

2-Primary chronic osteomyelitis

3-Chronic tendoperiostitis

### **1-Diffuse sclerosing osteomyelitis**

This term should be used only when an obvious infectious process directly is responsible for sclerosis of bone. In these cases, a chronic intraosseous bacterial infection creates a smoldering mass of chronically inflamed granulation tissue that incites sclerosis of the surrounding bone.

### **2-Primary chronic osteomyelitis**

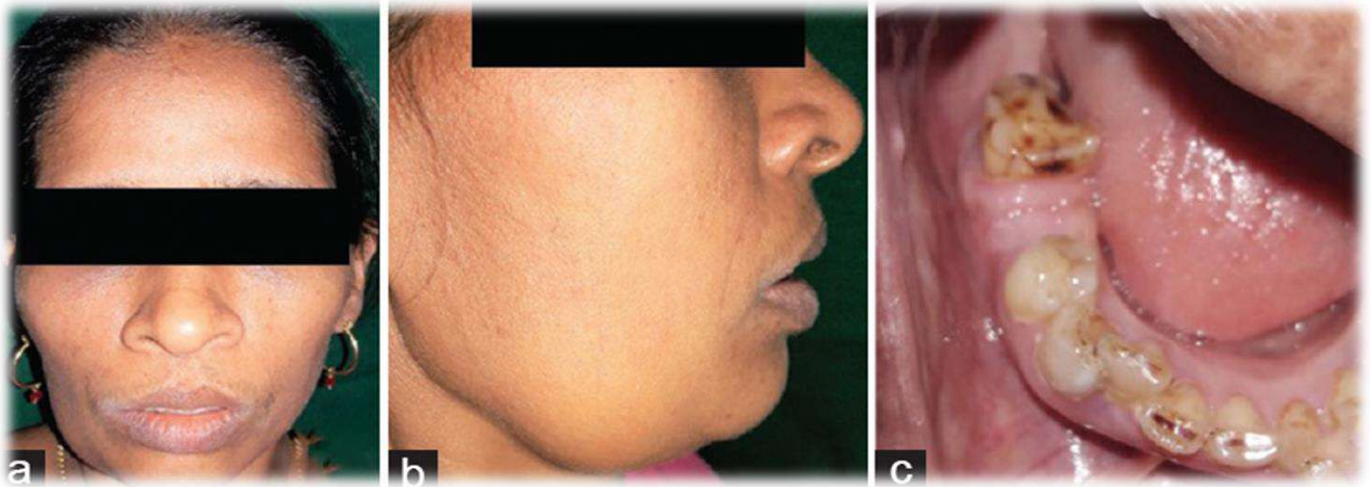Often is confused with, but must be distinguished from, chronic suppurative osteomyelitis (Secondary chronic osteomyelitis). In contrast to suppurative osteomyelitis, an association with a bacterial infection is not obvious, and suppuration and sequestration characteristically are absent. A number of causes have been proposed, such as an altered immune response to an organism of low virulence, but no single theory has received widespread acceptance. In contrast to suppurative osteomyelitis, a primary infectious cause cannot be proven, because many studies have been unable to culture organisms and the condition does not respond to long-term antibiotic therapy.

### **3.Chronic Tendoperiostitis:**

The clinical presentation is similar to that of primary chronic osteomyelitis; today many clinicians believe it represents a reactive alteration of bone that is initiated and exacerbated by chronic overuse of the masticatory muscles, predominantly the masseter and digastric. In a large series of patients, parafunctional muscle habits (e.g., bruxism, clenching, nail biting, co-contraction, and inability to relax jaw musculature) were known or became evident during follow-up. Some investigators believe this disorder may represent a variation of primary chronic osteomyelitis, in which parafunctional muscle habits exacerbate the process but are not the initial cause.

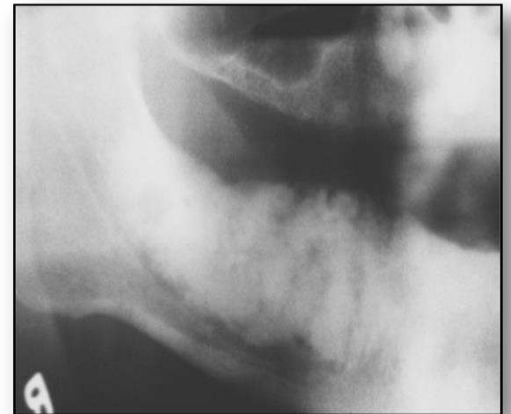## **Clinical Features**

This condition may be seen in any age, in either sex, and in any race, but it tends to occur most often in middle-aged black women. The disease is typified by a protracted chronic course with acute exacerbations of pain, swelling, limited mouth opening and occasionally drainage. In addition to trismus in cases of chronic tendoperiostitis .



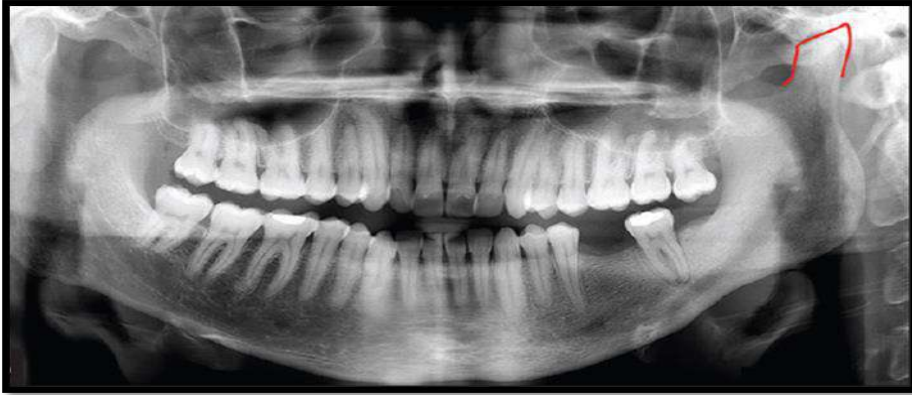## **Radiographically:**

In cases of diffuse-sclerosing osteomyelitis ,an increased radiodensity develops around sites of chronic infection (e.g., periodontitis, pericoronitis, and apical inflammatory disease) . Typically, the altered area is restricted to a single site but may be multifocal or extend to fill an entire quadrant.



In Primary Chronic Osteomyelitis, in the early stages of primary chronic osteomyelitis, radiographs tend to demonstrate a mixed pattern, with areas of radiolucent osteolysis intermingled with zones of sclerosis. Over time, the affected area becomes predominantly sclerotic. Overall, the predominant radiographic alteration of primary chronic osteomyelitis is medullary sclerosis.

While in Chronic Tendoperiostitis ,the sclerosis is limited to a single quadrant and centers on the anterior region of the mandibular angle and posterior portion of the mandibular Body.



### Histopathology

Diffuse sclerosing osteomyelitis demonstrates sclerosis and remodeling of bone. The haversian canals are scattered widely and little marrow tissue can be found. Although the sclerosis occurs adjacent to areas of inflammation, the bone is not typically intermixed with a significant inflammatory soft tissue component.

The same features seen on Primary Chronic Osteomyelitis and Chronic tendoperiostitis , where there are areas of sclerosis, numerous irregular trabeculae of pagetoid bone are present and demonstrate extensive evidence of remodeling with prominent reversal lines, osteoblastic rimming, and focal areas of osteoclastic activity .

### Differential Diagnosis

Chronic sclerosing osteomyelitis shares many clinical, radiographic, and histological features with florid osseous dysplasia. The two should be separated, because the former is an inflammatory process and the latter a bony dysplastic process. Treatment and prognosis are therefore dissimilar. Florid osseous dysplasia appears to be an extensive form of periapical cemental dysplasia and, unlike diffuse sclerosing osteomyelitis, may exhibit anterior periapical lesions and traumatic or simple bone cysts. Furthermore, florid osseous dysplasia is usually asymptomatic and appears as a fibroosseous lesion lacking an inflammatory cell infiltrate.

## **Treatment**

The management of diffuse sclerosing osteomyelitis is problematic because of the relative avascular nature of the affected tissue and because of the large size of the lesion. Even with aggressive treatment, the course is protracted. If an etiologic factor such as periodontal disease or a carious tooth can be identified, it should be eliminated. Antibiotics are the mainstay of treatment and are especially helpful during painful exacerbations. Surgical removal of the diseased area is usually an inappropriate procedure because of the extent of the disease. However, decortication of the affected site has resulted in improvement in some cases. Low-dose corticosteroids have also been used with some success. Hyperbaric oxygen therapy may prove to be a valuable adjunct. Recently, treatment with pamidronate has shown promising results.

## **C. Focal Sclerosing Osteitis**

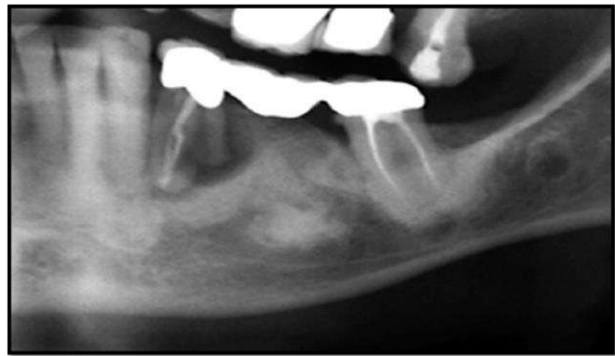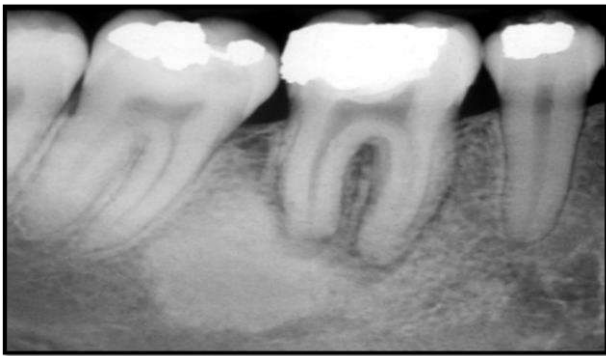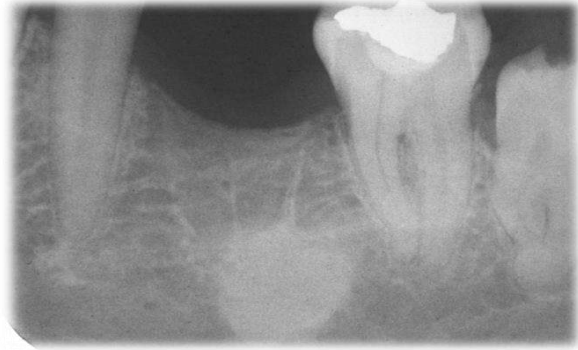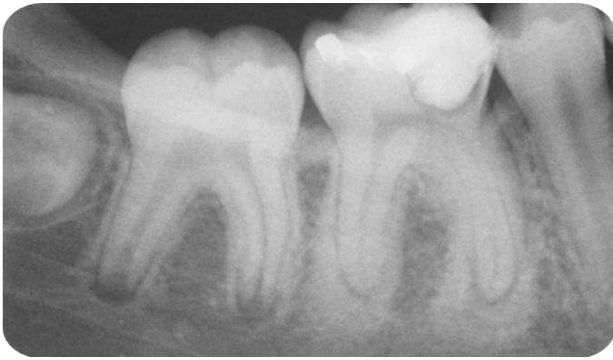### ***Etiology***

Focal sclerosing osteitis is a relatively common phenomenon that is believed to represent a focal bony reaction to a low-grade inflammatory stimulus. It is usually seen at the apex of a tooth with long-standing pulpitis. This lesion may occasionally be adjacent to a sound, unrestored tooth, suggesting that other etiologic factors such as malocclusion may be operative. Synonyms for focal sclerosing osteitis include focal sclerosing osteomyelitis, bony scar, condensing osteitis, and sclerotic bone. The term focal periapical osteopetrosis has also been used to describe idiopathic lesions associated with normal, caries-free teeth.

### ***Clinical Features:***

Focal sclerosing osteitis may be found at any age but is typically discovered in young adults. Patients are usually asymptomatic, and most lesions are discovered on routine radiographic examination. A majority are found at the apices of mandibular first molars, with a minority associated with mandibular second molars and premolars. When teeth are extracted, these lesions remain behind indefinitely.

**Radiographically:** One of several patterns may be seen. The lesion may be uniformly opaque, it may have a peripheral lucency with an opaque center, it may have an opaque periphery with a lucent center, or it may be composed of confluent or lobulated opaque masses.



**Histopathology:**

Microscopically, these lesions are masses of dense sclerotic bone; Connective tissue is scant, as are inflammatory cells.

**Differential Diagnosis**

Differential diagnosis should include periapical cemental dysplasia, osteoma, complex odontoma, cementoblastoma, osteoblastoma, and hypercementosis. In most cases, however, diagnosis can be made with confidence on the basis of historical and radiographic features.

**Treatment:**

Because it is believed to represent a physiologic bone reaction to a known stimulus, the lesion itself need not be removed. A biopsy might be contemplated to rule out more

significant lesions that received serious consideration in the differential diagnosis. The inflamed pulp that stimulated the focal sclerosing osteomyelitis should be treated. The decision about whether the tooth should be restored, treated endodontically, or extracted should be made on a case-by-case basis according to findings.

### **III. Chronic Osteomyelitis with Proliferative Periostitis:**

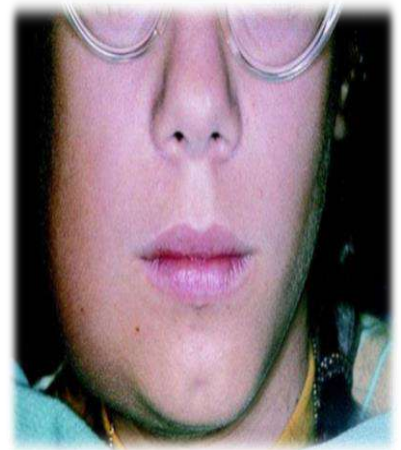
#### **(Garré's Osteomyelitis)**

##### ***Etiology***

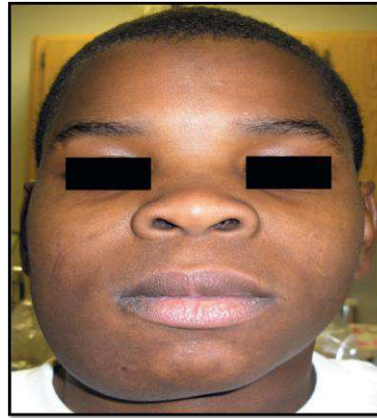
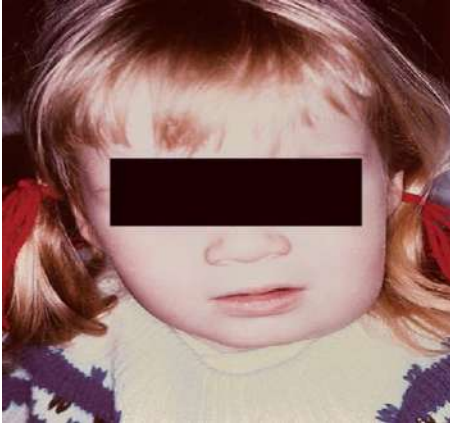Chronic osteomyelitis with proliferative periostitis, commonly known as Garré's osteomyelitis, is essentially a subtype of osteomyelitis that has a prominent periosteal inflammatory reaction as an additional component. It most often results from a periapical abscess of a mandibular molar tooth or an infection associated with tooth extraction or partially erupted molars. May due to Trauma, cysts , avitaminosis C , congenital syphilis, and neoplasms (such as, Ewing sarcoma, Langerhans cell histiocytosis, and osteogenic sarcoma).

##### ***Clinical Features***

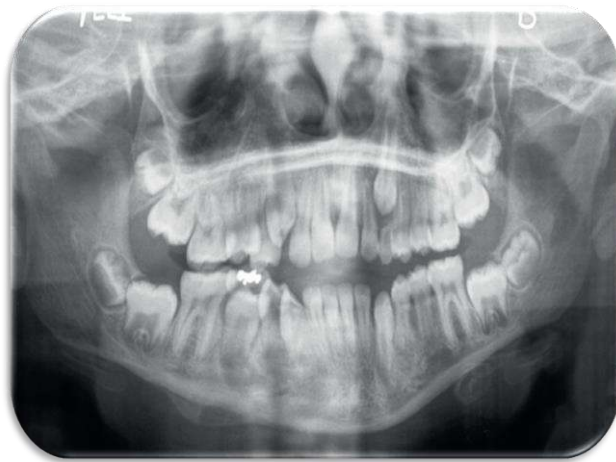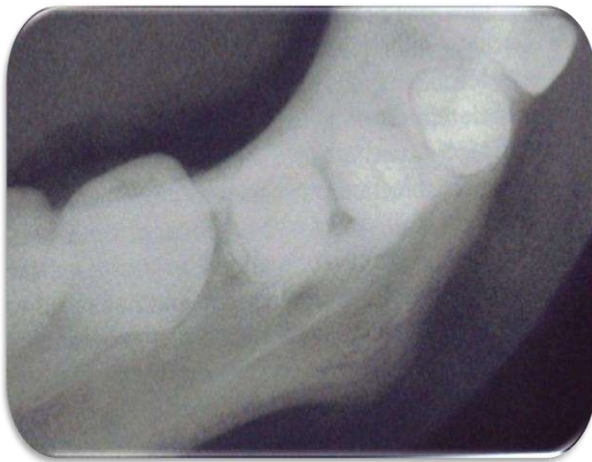This variety of osteomyelitis is uncommonly encountered. It has been described in the tibia, and in the head and neck area, it is seen in the mandible. It typically involves the posterior mandible and is usually unilateral. It is most common in children. Patients characteristically present with an asymptomatic bony, hard swelling with normal appearing overlying skin and mucosa. On occasion, slight tenderness may be noted. This presentation necessitates the differentiation of this process from benign mandibular neoplasms. Radiographs and a biopsy provide a definitive diagnosis.







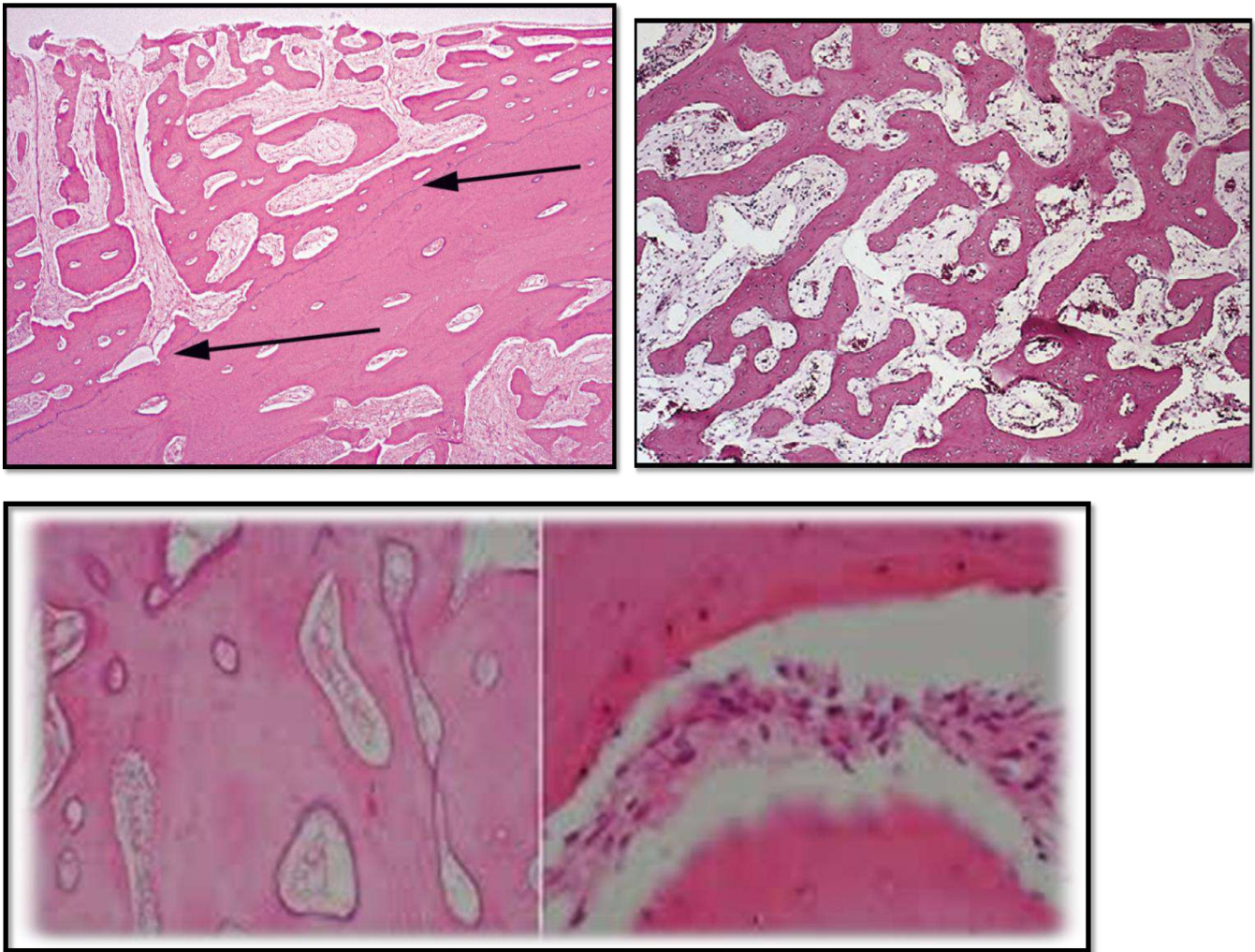
***Radiographically:*** the lesion appears centrally as a mottled, predominantly lucent lesion in a pattern consistent with that of chronic osteomyelitis. The feature that provides the distinctive difference is the periosteal reaction. This, best viewed on an occlusal radiograph, appears as an expanded cortex, often with concentric or parallel opaque layers. Trabeculae perpendicular to the onion skin layers may also be apparent.



### ***Histopathology***

Reactive new bone typifies the subperiosteal cortical response. Perpendicular orientation of new trabeculae to redundant cortical bone is best seen under low magnification. Osteoblasts dominate in this area, and both osteoblasts and osteoclasts are seen centrally. Marrow spaces contain fibrous tissue with scattered lymphocytes and plasma cells. Inflammatory cells are

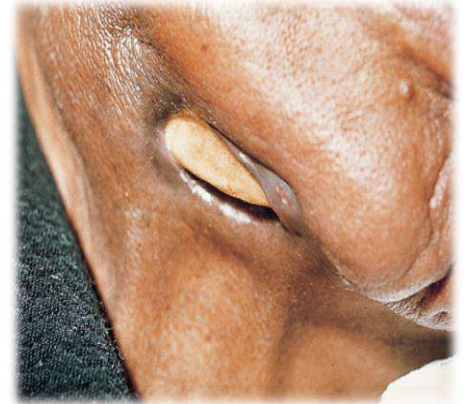often surprisingly scant, making microscopic differentiation from fibrous lesions a diagnostic challenge.



**Treatment :** Identification and removal of the offending agent are of primary importance in chronic osteomyelitis with proliferative periostitis. Removal of the involved tooth is usually required. Antibiotics are generally included early in this treatment. The mandible then undergoes gradual remodeling without additional surgical intervention.

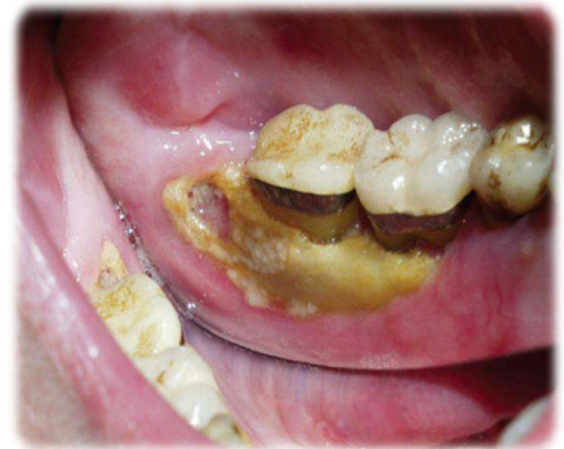#### IV. Osteoradionecrosis:

Osteoradionecrosis is one of the most serious complications of radiation to the head and neck but is seen less frequently today because of better treatment modalities and prevention. The current prevalence rate is less than 4%, whereas the frequency approached 15% less than 20 years ago. Although the risk is low, it increases dramatically if a local surgical procedure is performed within 21 days of therapy initiation or between 4 and 12 months after therapy. Radiation of bone results in permanent damage: ' to the osteocytes and microvasculature system. The altered bone becomes hypoxic, hypovascular, and hypocellular. Osteoradionecrosis is the result of nonhealing, dead bone; infection is not necessarily present.



#### V. Bisphosphonate-Associated Osteonecrosis

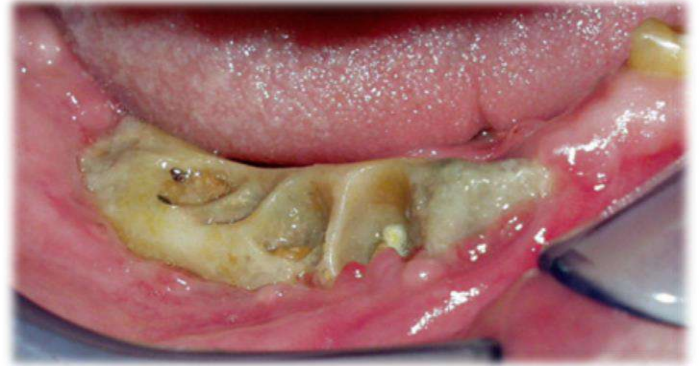A jaw necrosis may be seen as a complication of bisphosphonate therapy (e.g., pamidronate, and zoledronic acid ) especially when administered long term and in high doses intravenously ). This condition is now known to be induced by a variety of drugs that inhibit either osteoclast activity or angiogenesis. Bisphosphonates are currently used as part of the treatment regimen for patients with multiple myeloma, metastatic cancers to bone (e.g., breast or prostate cancer), Paget's disease, and osteoporosis because of their inhibitory effect on osteoclastic bone resorption.



The drugs are concentrated in osteoclasts and bound into bone matrix by osteoblasts, where they remain active in bone for many years, being slowly released on bone turnover . The osteoclast inhibition also delays bone healing.

### **Clinical features :**

The majority of patients affected are elderly and have metastatic malignant disease because this is the main indication for the causative drugs . As with osteoradionecrosis , the mandible is more commonly affected than the maxilla.



A striking presentation is painless exposed bone. Some patients may experience no acute symptoms or infection for prolonged periods.

Once infection is introduced, the condition develops into acute or chronic osteomyelitis depending on the virulence of the organism and resistance of the patient.

The drugs cause reduced bone turnover so that sequestra of necrotic bone separate very slowly and healing is inhibited. Later complications can include oroantral and cutaneous fistulas with suppuration.

### **Management:**

Prevention of infection is paramount. Potential problems should be eliminated before bisphosphonate treatment, infective foci eliminated and teeth of dubious prognosis removed.

Some authorities also suggest removal of tori and sharp ridges if prone to denture trauma.

Caries and periodontitis must be controlled.

Ideally, all surgical dentistry should be avoided for as long as possible after drug administration. If extractions cannot be delayed, they are probably best followed by postoperative antibiotics and chlorhexidine rinses until the sockets are fully epithelialised.

Unfortunately, these precautions are not always successful, and sometimes extraction of a tooth reveals an apparently already non-vital socket that does not bleed.