

Operative Dentistry

Lec.7

د. عبد المنعم
الحفاجي

CLASS V CAVITY PREPARATION FOR AMAGLAM

Indications

The selection of amalgam as a restorative material for class V cavity should involve the following considerations:

1- Caries:

When the caries rate is high, the amalgam is chosen over more expensive filling materials.

2- Erosion or abrasion, or both:

Erosion: tooth loss at the cervical area due to non bacterial acid attack.

Abrasion: tooth loss at the cervical area of the tooth due to abrasive slurry between two surfaces (mechanical action) e.g: tooth brush – dentifrice abrasion.

In both cases there is no caries if we prepare a class V cavity it is better to be filled by amalgam, because of high abrasive resistance of amalgam.

3- Sensitive areas at, or apical to, the cementoenamel junction :

Because of gingival recession or periodontal surgery or both the cementum may be extremely sensitive, when the method of desensitizing the area is failed, so a class v cavity preparation is necessary.

4- Esthetics:

Class V cavity for all anterior teeth should be filled by tooth colored restorative materials, because the metallic color of amalgam does not match the color of tooth. While for posterior, it is less visible, usually, the class V amalgam fillings at the buccal surface of mandibular premolar and molar are not visible; where as those at maxillary premolars and first molar are more visible.

Note: the patient's view of esthetics should be considered when planning treatment in area of esthetic concern.

Nowadays, improved tooth colored restorative material make them a good substitute for amalgam in class V cavity.

5- Abutment teeth for removable partial dentures:

Amalgam is chosen over a tooth colored restorative material when placed on abutment teeth for partial dentures because it is better to be contoured and less wear will occur as a clasps move on the restoration.

6- Economics:

The patient's economic situation may influence the selection of restorative materials such that the amalgam may be chosen over more expensive materials.

Isolation

Moisture in the form of saliva, gingival sulcus fluid or gingival hemorrhage must be excluded during caries removal, cementation, and filling procedure because:

- 1- It may contaminate the pulp during caries removal especially with pulp exposure.
- 2- Negatively affect the physical properties of the cement and filling material.

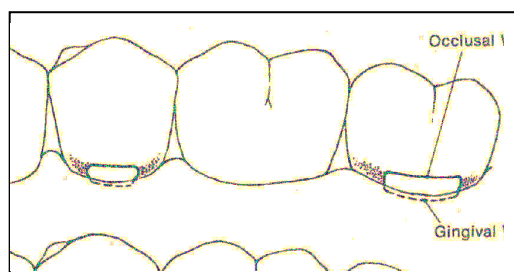
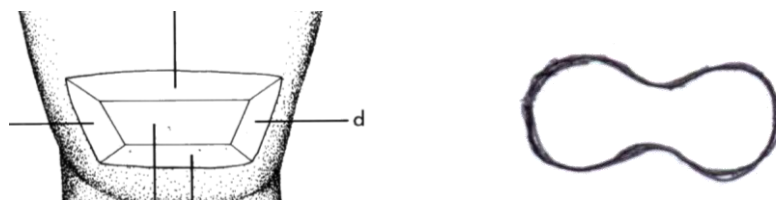
So isolation is important during class V cavity preparation because sometimes the caries may extend subgingivally and should extend the margin of the restoration subgingivally, so we do isolation to protect the gingiva and provide access while eliminating seepage of sulcular fluid into the cavity preparation or restorative material.

Isolation done by:

- 1- Cotton roll
- 2- Retraction cord
- 3- Rubber dam.

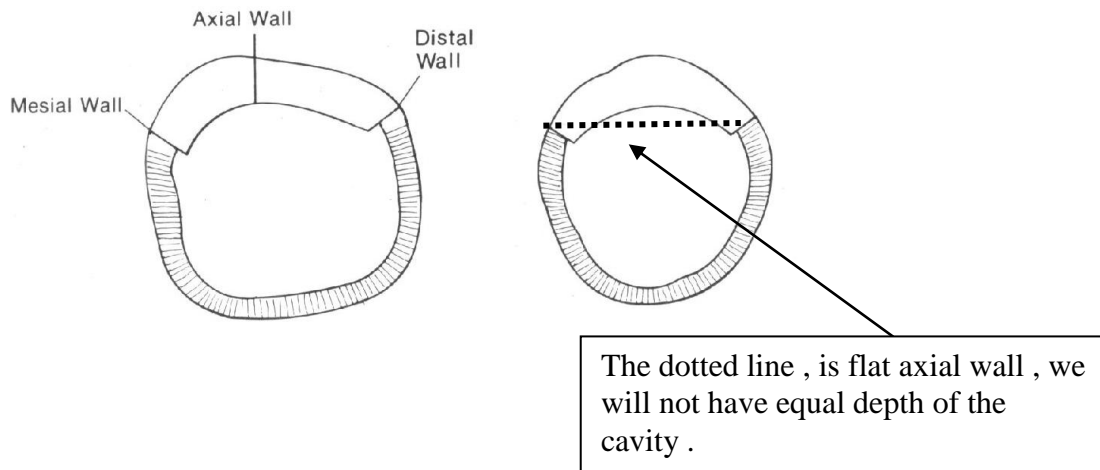
• Outline form :

Using round bur to start entry to the cavity, the direction of the bur should perpendicular to the buccal (or palatal) surface of the tooth , then using the fissure bur to do the outline form , just remove the caries and the margins should be in sound tooth structure , there is no need to "extension for prevention" the shape of class V cavity is trapezoidal in shape or could be kidney shaped to be more conservative.

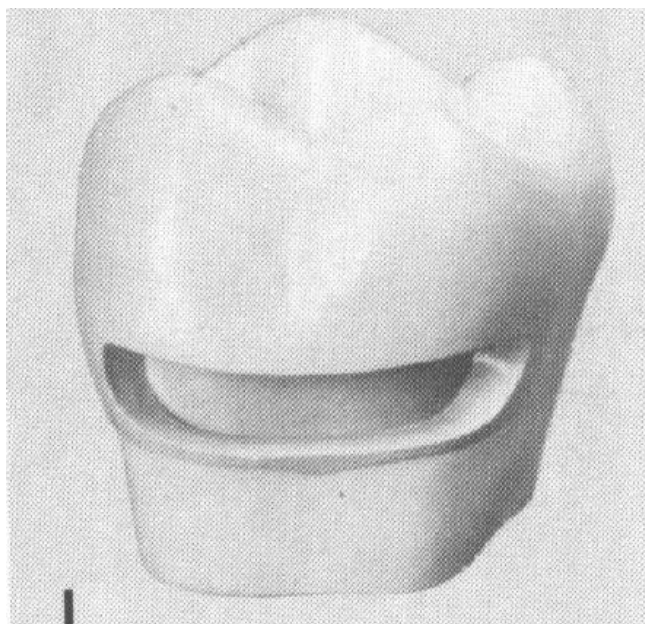


• Resistance form

- Depth of the cavity is 1.5 mm : the axial wall of the cavity should not be flat , if we do so will not have even depth of the cavity because of convexity of tooth structure , so the axial wall should be slightly convex .



- cavosurface line angle ($90-110^{\circ}$).
- Rounded internal line angles
- Removal of unsupported enamel
- Mesial and distal walls should be slightly diverge
- Occlusal and gingival walls should be perpendicular to the long axis of the tooth and parallel to each other, any convergence of these walls will create unsupported enamel.

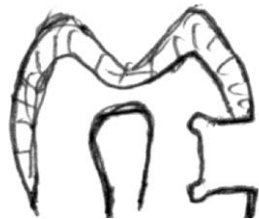

• Retention form

- I- Retention mean in class V cavity is made by making retention grooves or retention holes. This depend on the size of cavity , in small conservative cavity , retention holes is made , while in large class V cavity , retention grooves are necessary.
- II- In case of more extensive class V cavity we may need to (pins) as extraretention.

Position of the retentive means:

Best position is axioocclusal and axiokingival line angles.



Method of placement :

- 1- **Retention holes:** using a small round bur (no. 1/4) and make two holes at axioocclusal line angle and two holes at axiokingival line angle.
- 2- **Retention grooves:** using a small round bur (no. 1/4) making two holes at axioocclusal line angle then connecting between them by small round bur or by small fissure bur, holding the bur in oblique direction. Same thing is done on axiokingival line angle.

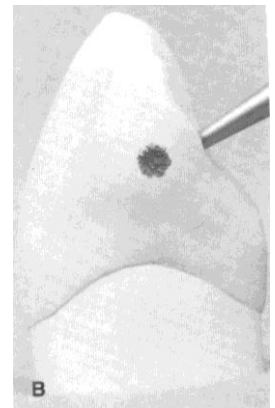
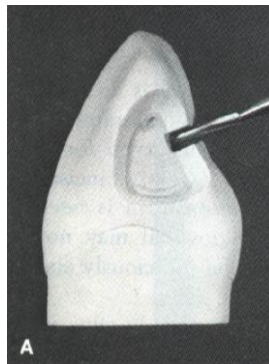
Note: if the retention means (holes or groves) are placed on the axial wall this increase the danger to the pulp and it will not prevent the displacement of the restoration. Also don't place the retentive means on mesial and distal walls, because of small amount of dentin at this area so the small holes "compared with the large surface area of the amalgam" will not resist the tipping or lifting force which may undergo fracture.

- **Removal of remaining caries at the axial wall and cleaning and drying the cavity.**

CLASS III CAVITY PREPARATION FOR AMAGLAM

Class III cavity is prepared when the caries occur at the proximal surface of all anterior teeth. All class III cavity should be filled with tooth colored restorative material (composite resin) except the distal surface of maxillary canine, it is better to be filled with amalgam, because the distal surface of the maxillary canine is the contact between anterior teeth and posterior teeth, and usually there is a mesial shifting of the posterior teeth, so there will be continuous force at the distal surface of the maxillary canine, if it is filled with composite, this cause wear of composite with time and decrease the mesiodistal width of canine, so it is better to fill it with amalgam because of higher wear resistance of amalgam compared with composite.

- Caries usually occur at the contact area of upper canine, the access to the cavity is from the lingual surface, never do access to the cavity form the labial surface because of esthetic purposes, only if the caries is extended to the labial surface, we can make access from the labial surface.



- Placing the bur on the distal marginal ridge at the contact area and do entry, then use the fissure bur moving it gingivally and labially and incisally creating the outline form removing all caries lesion.
- The contact with the adjacent tooth should be opened to be in a cleansable area.
- The gingival wall should be perpendicular to the long axis of the tooth, the axial wall should be parallel to the long axis of the tooth, to have good vision and good access to the cavity (convenience form).
- Remove any unsupported enamel.

- Cavo-surface line angle (90-110°).

Retention form

- Flat gingival wall and should be perpendicular to the long axis of the tooth.
- Lingual access area should be minimal.
- Lingual inclination of the incisal third of the labial wall.
- Labial and lingual walls are parallel as much as possible to prevent displacement of the filling material.
- Retention grooves axioincisally and axiogingivally.
- Dovetail on the lingual surface.

If we have extensive caries and large class III cavity and previous retentive means is not enough, so we do dovetail on the lingual surface of maxillary canine, but this should be as conservative as possible, it should not exceed the midpoint of the lingual surface also the depth should not be more than 1mm, if we make it with the same depth of the cavity, it may hit the pulp.

If we create a dovetail we will have axiopulpal line angle which should be beveled.

END

