

R adio Logical investigations of urinary system

There are 4 main radiological Ix:

1 —IVU: Intravenous urography.

2- U/S

3-CT scan

4-Radioisotope scan.

Others (not frequently used): MRI,
arteriography, antegrade or retrograde
pyelogram.



Imaging of urinary system:


1-IVU

2-pyelogram

3-cystogram

4-urethrogram





Pyelography mainly used to detect the level of obstruction

1. antegrade pyelogram

2. reterograde pyelogram






Pyelography

- Pyelography (direct injection of contrast medium into the collecting system from above or below) offers the best views of the collecting system and upper tract, and is commonly used to identify the cause of urinary tract obstruction .
- **Antegrade pyelography** requires the insertion of a fine needle into the pelvicalyceal system under ultrasound or radiographic control. Contrast is injected to outline the collecting system, and particularly to localise the site of obstruction.
- **Retrograde pyelography** can be performed by inserting catheters into the ureteric orifices at cystoscopy .



Antegrade pyelogram :

require insertion of a fine
needle in to pelvicalyceal
system under US or
radiographic control

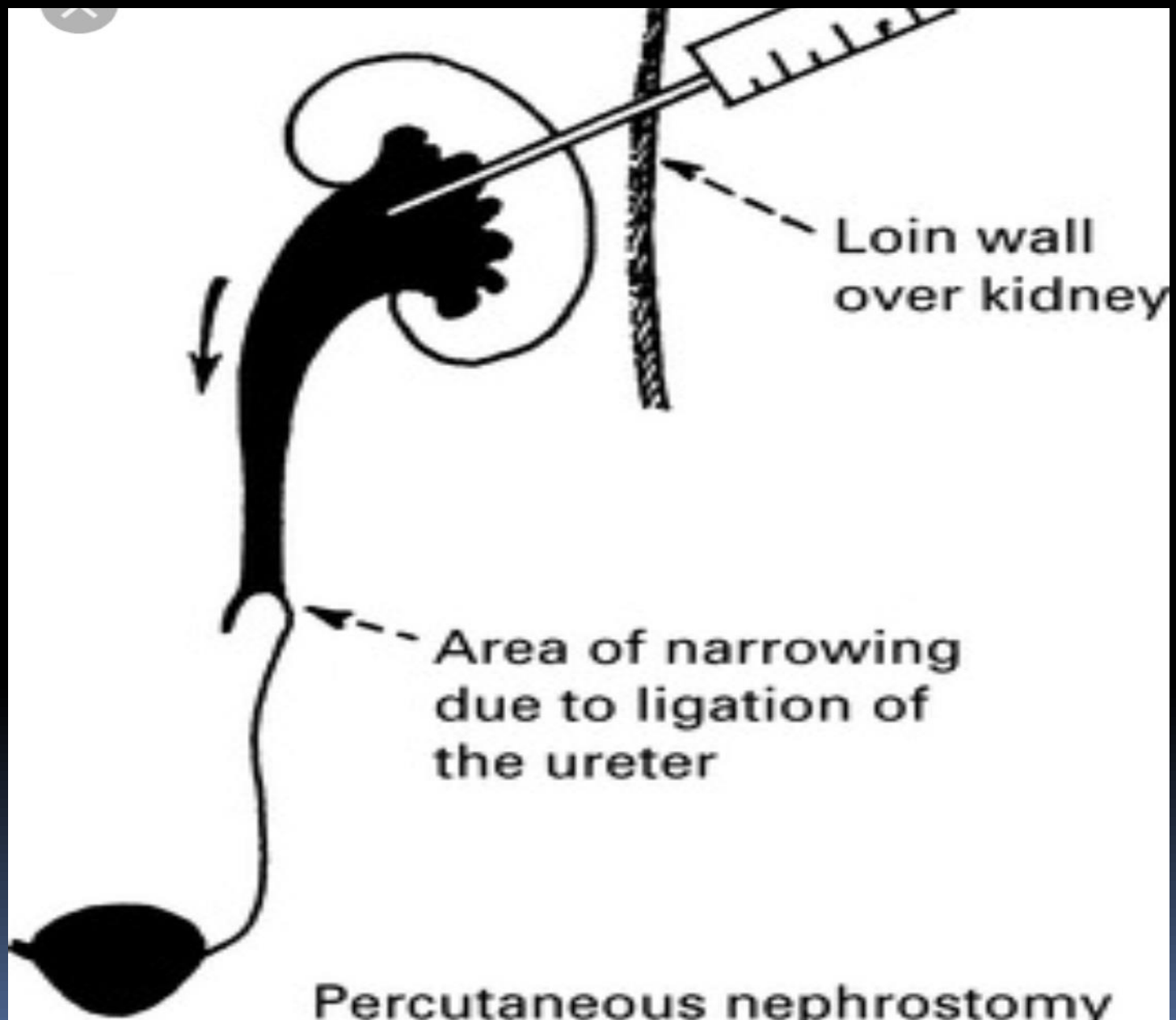


What is Antegrade Pyelography?

- ✓ Antegrade pyelography is a diagnostic test that uses special contrast agent (dye) to produce detailed X-ray pictures of the upper urinary tract (kidney and ureter).

What is the use of Antegrade Pyelography?

- ✓ It is commonly used to diagnose the following conditions hydronephrosis, ureteropelvic junction (UPJ) obstruction and obstruction of the ureters.



Percutaneous nephrostomy and antegrade pyelography

Complication of AGP:

1-bleeding

2-sepsis


3-formation of a urine -
filled cyst (urinoma)

4-blood clot in nephrostomy
tube



Retrograde pyelography:

can be performed by
inserting catheter in to
ureteric orifice at
cystoscopy



What is Retrograde Pyelography?

- ✓ Retrograde pyelography uses special contrast agent (dye) to produce detailed X-ray pictures of the ureters and kidneys. The difference is that in retrograde pyelography the dye is injected directly into the ureters rather than into a vein.
- ✓ It is better suited to see the definition of the upper urinary tract, particularly the ureter and kidney

What is Retrograde Pyelography?

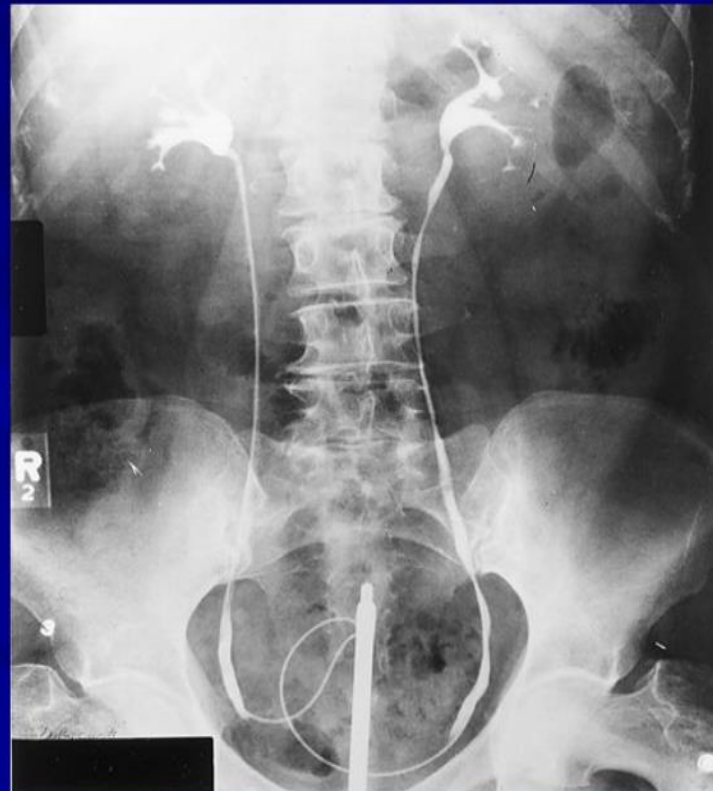- ✓ Retrograde pyelography uses special contrast agent (dye) to produce detailed X-ray pictures of the ureters and kidneys. The difference is that in retrograde pyelography the dye is injected directly into the ureters rather than into a vein.
- ✓ It is better suited to see the definition of the upper urinary tract, particularly the ureter and kidney

RETROGRADE PYELOGRAPHY

Opacification of the ureter and pelvicalyceal system by the retrograde injection of contrast media using ureteric catheter.

Indications

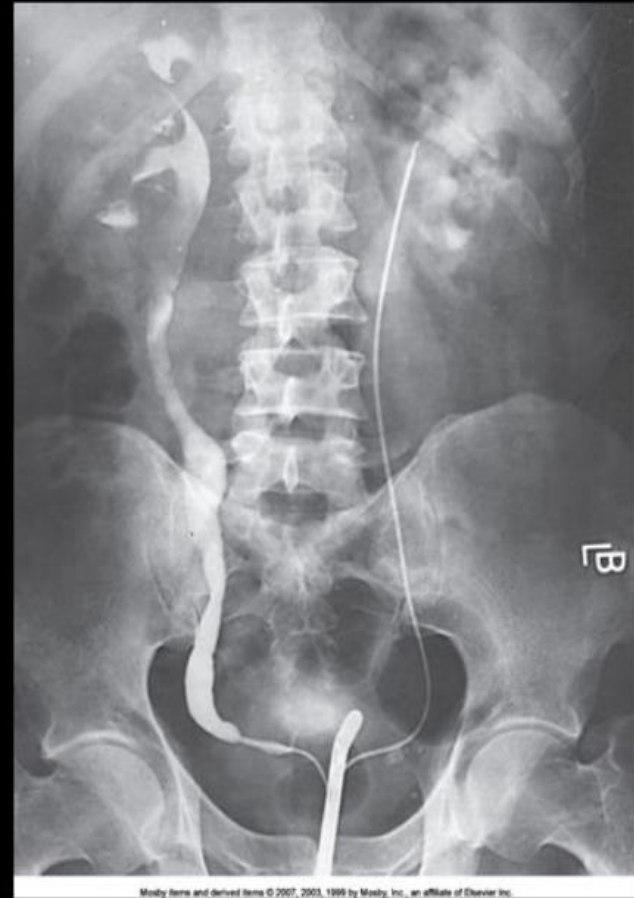- Employed after an excretory urogram that inadequately visualized the anatomy of the upper tract.
- when there are contraindications to do IVU





Retrograde Urography

- Requires **catheterization of ureters**
- Contrast injected directly into pelvicaliceal system via **catheters**
- Provides improved opacification of renal collecting system



X

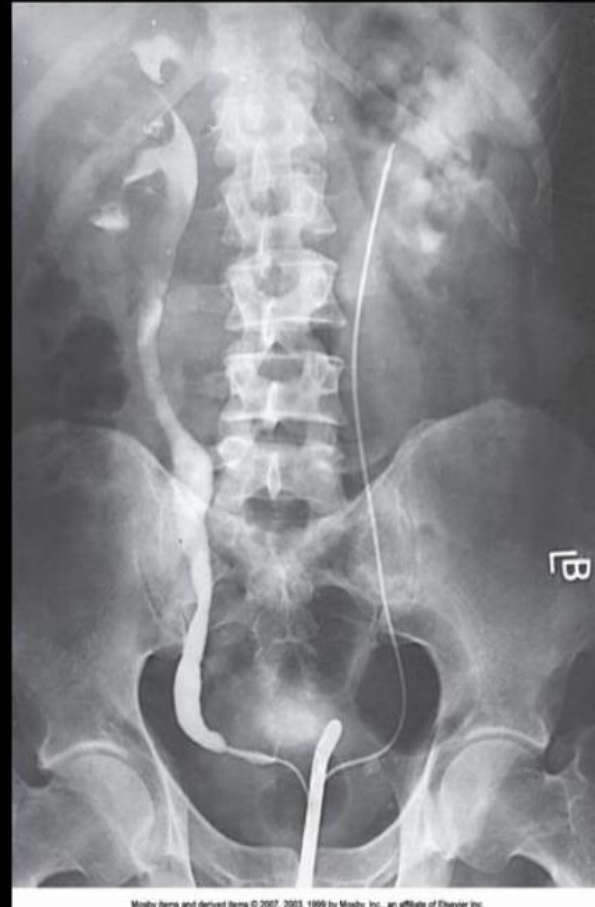
Retrograde Urography (cont'd)

Contrast does **not** enter
blood stream

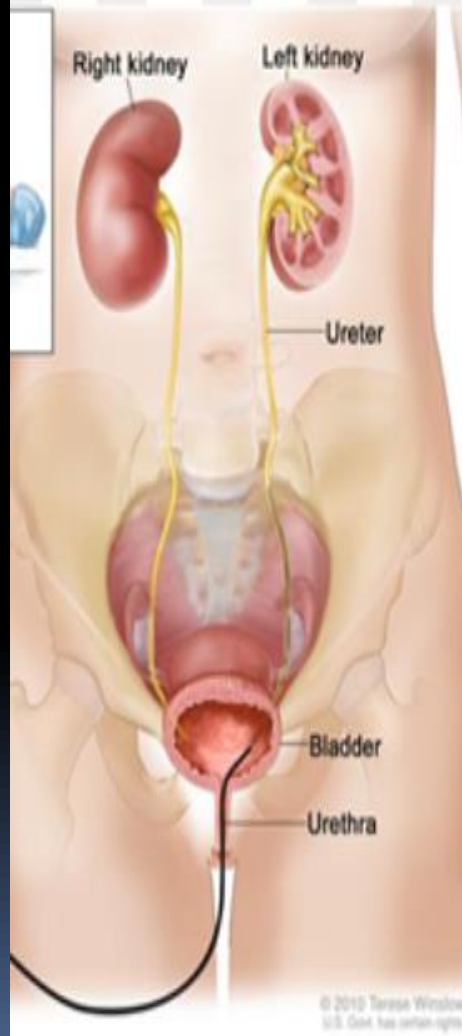
Used for patients with
renal insufficiency or
contrast sensitivity

Ureters, and collecting
systems can be
selectively imaged and
sampled

Little **physiologic**
information provided



Retrograde Pyelogram




A retrograde pyelogram uses X-rays to look at bladder, ureters and kidneys. This test is done using fiberoptic urethroscope during cystoscopy procedure wherein contrast dye is injected directly into the ureters. The contrast helps parts of the body show up more clearly on an X-ray. The exam is performed under anesthesia.



IVU STUDY



OBJECTIVES

- Indication
 - Advantages
 - Disadvantages
 - Procedure
 - Examples
- 



IVU

This is KUB taken post intravenous contrast injection

Also called IVP (intravenous pyelogram)

Demonstrates both function and structure of the renal system

- **Function ---→ Filtration**
- **Structure ---→ Contrast filled collecting system**

Indications:

- **Urolithiasis / calculus**
- **Pyelonephritis**
- **Hydronephrosis**
- **Trauma**
- **Tumour**
- **Renal hypertension**
- **Congenital abnormality**

Contra-Indications: (relative)

- **History of Allergy**
- **Asthma**
- **Cardiovascular disease**
- **Sickle cell disease**
- **Diabetes mellitus**

INDICATIONS


- Renal colic to visualize stones or obstructions
- Hematuria
- Recurrent UTI to assess congenital anomalies strictures or urothelial lesions
- Renal obstruction e.g. renal mass
- assessment of renal outline pyelocalyceal system ureters bladder urothelium
- Others e.g.
- Prostatitis
- Neurogenic bladder
- Trauma

IVU is not indicated in

- Pylonephritis
- Renal failure
- Renal parenchymal disease
- Disease of hyper tension




ADVANTAGE

- Widely available
 - Excellent to identify uroepithelium
 - Can visualize the whole length of ureters
 - Can quantify the degree urinary tract obstruction
- 

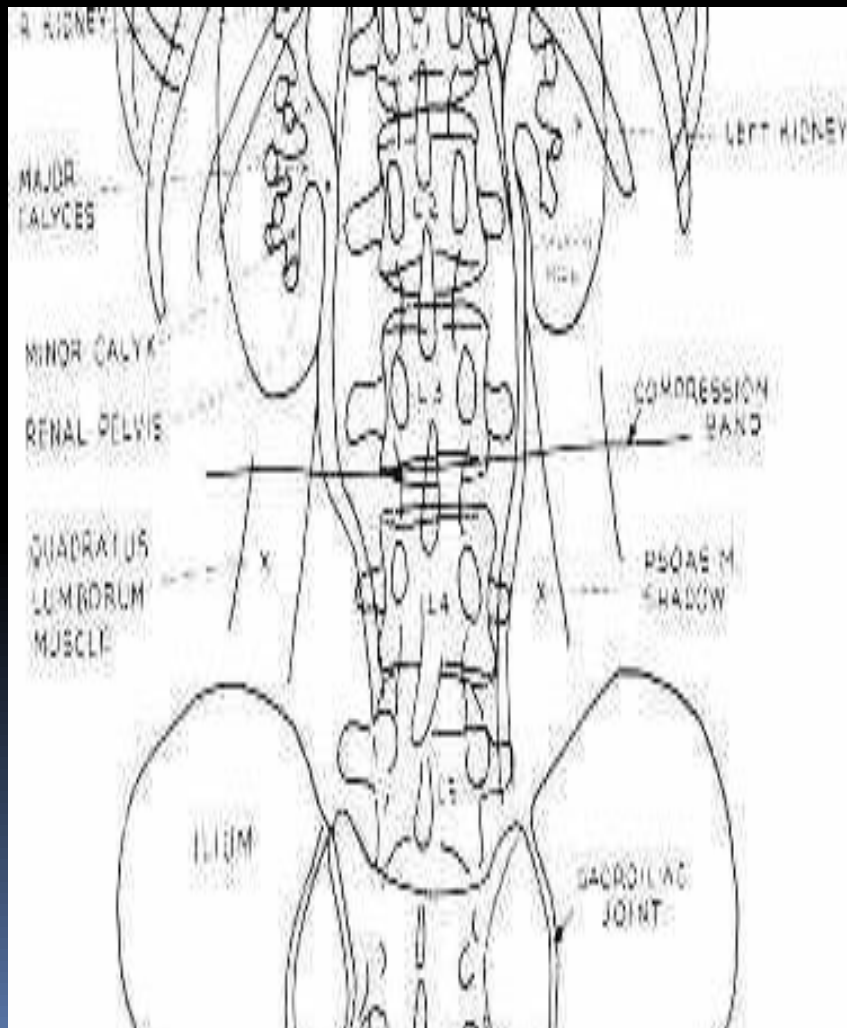



DISADVANTAGE

- ❑ Need for patient preparation
 - ❑ Risk of radiation
 - ❑ Contrast media problems such as allergy
 - ❑ May get suboptimal results due to
 1. Patient movement
 2. Overlying bowel gas
 3. Poor concentration media due to poor renal function
- 

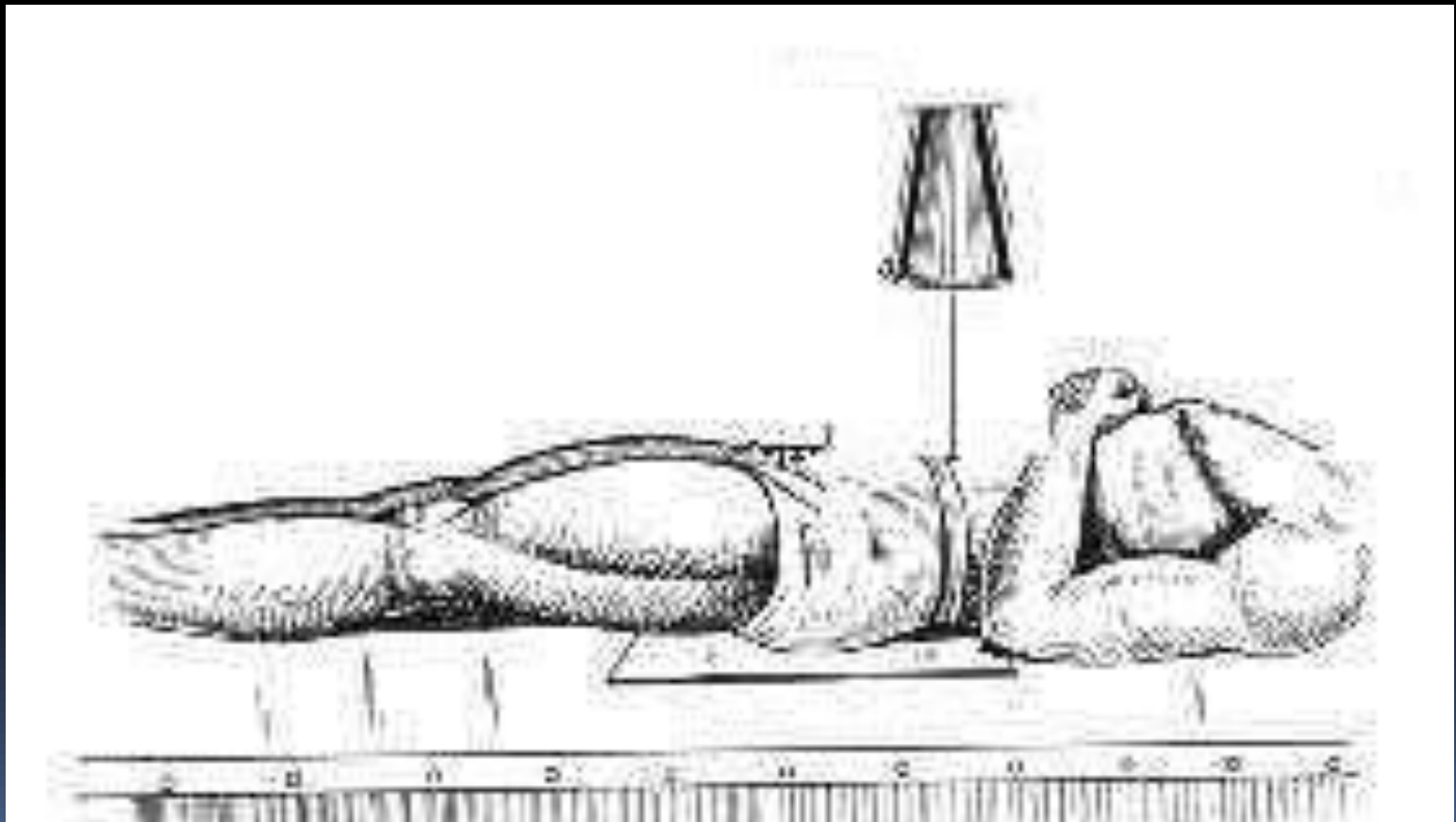

PATIENT PREPRATION

1. Laxatives is taken 24 hr before the examination
2. Nil by mouth for 4-6 hr before the examination
3. The patient should be ambulant as long as possible to decrease air swallowing
4. Certain measures is taken to certain group of patients e.g. DM and children



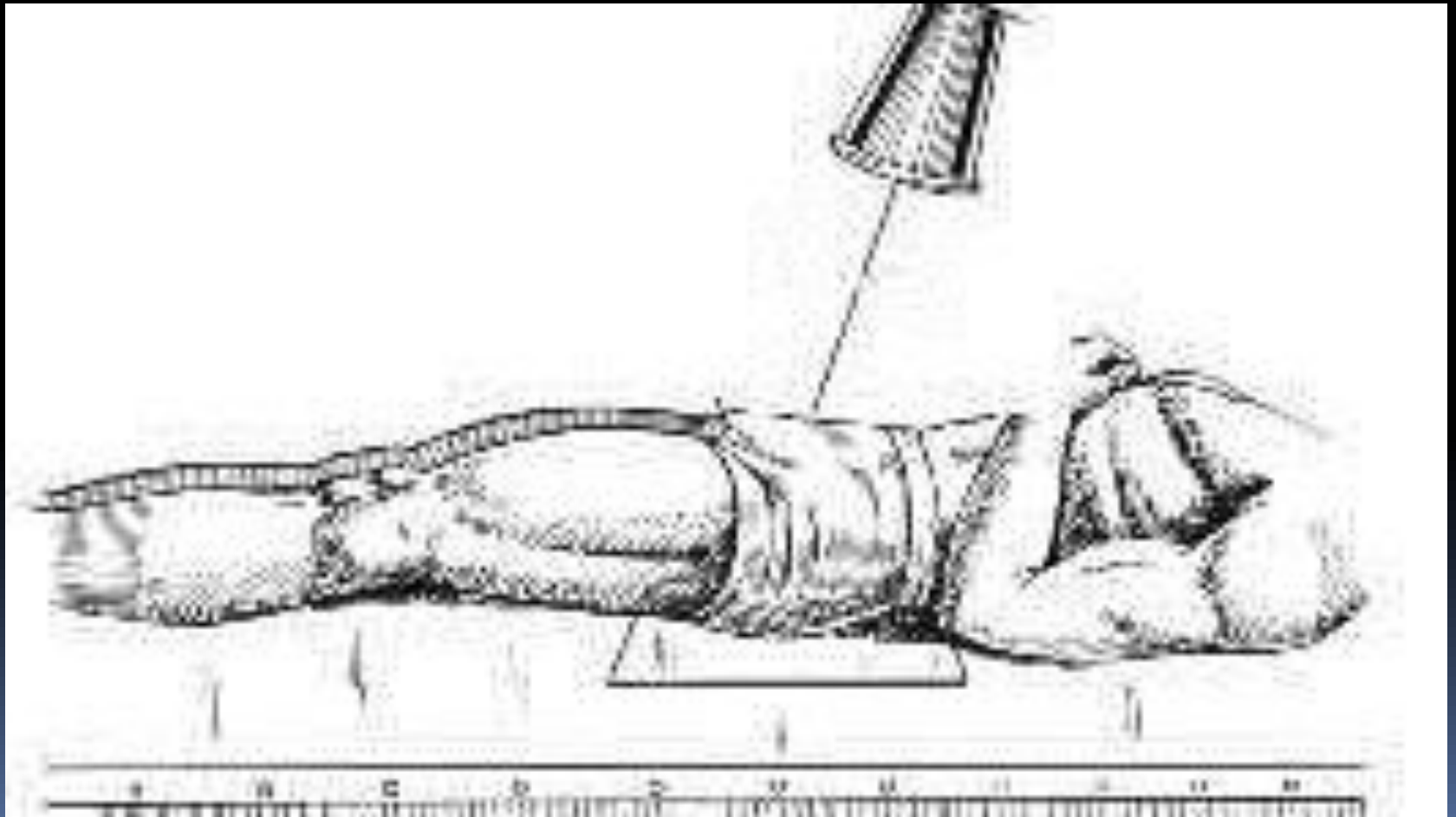

Basic position

AP position



BASIC PATIENT POSITION

The patient must lie supine at mid line of table



Plain film

- Calcification

- 1-T.B

- 2-stone

- 3-hydatid cyst

- 4- tumors

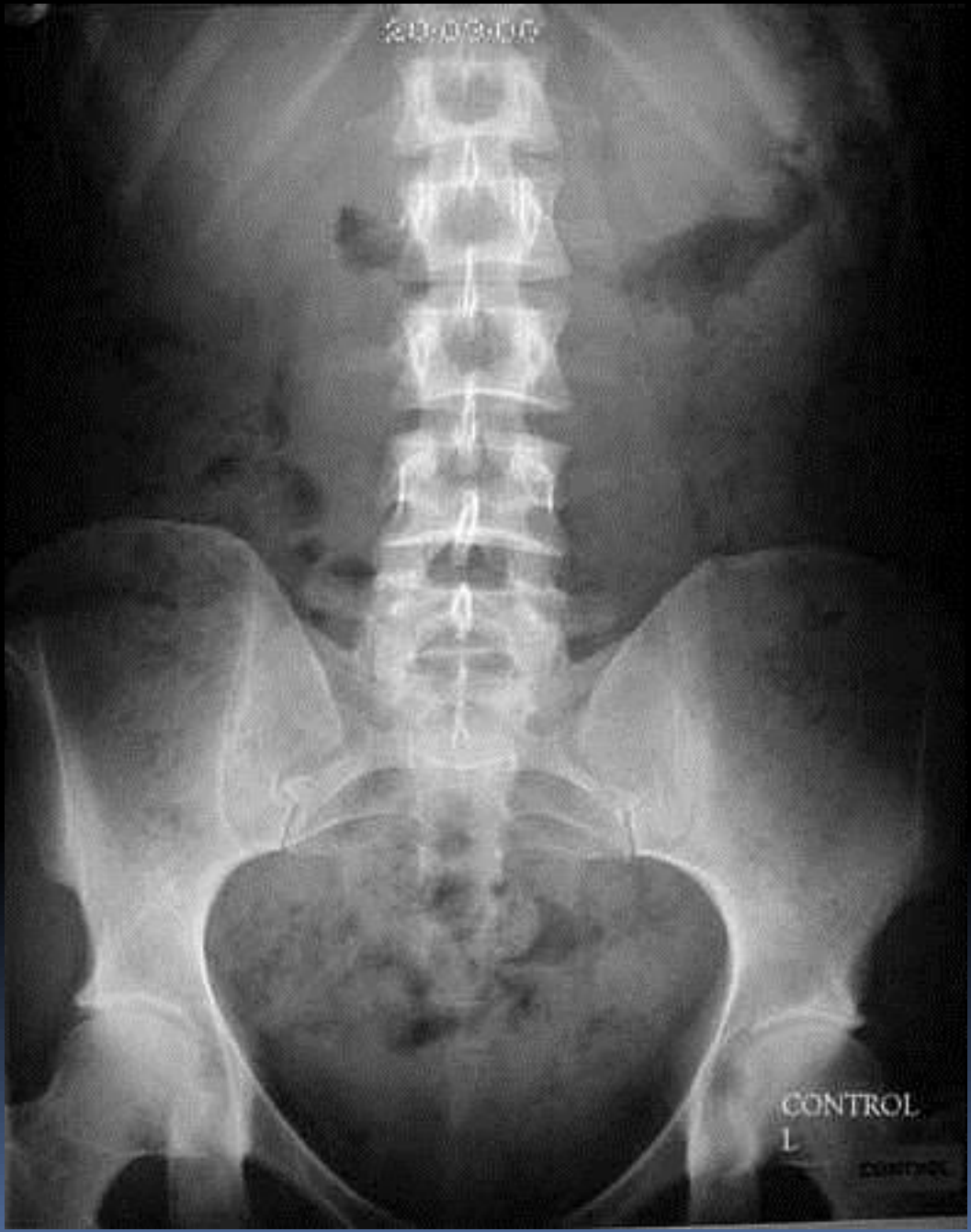- 5- fibroid in female

- Abdominal cavity

- 1- kidney outline

- 2- shadow of psoase muscle

- 3- bones



20-03-00

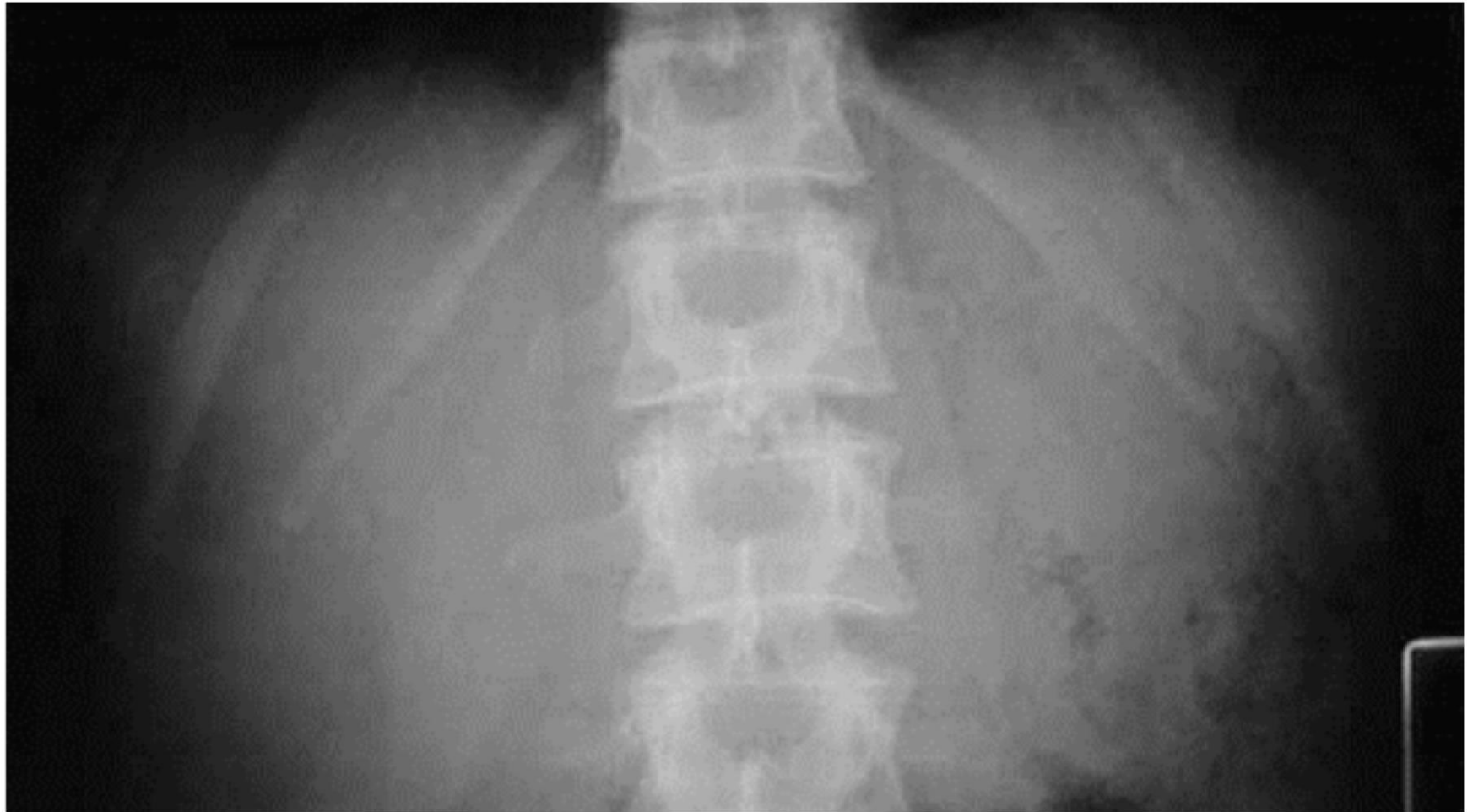
CONTROL

L

CONTROL

PreLiminary film (Control)

(24 x 30 cm) Inspiration

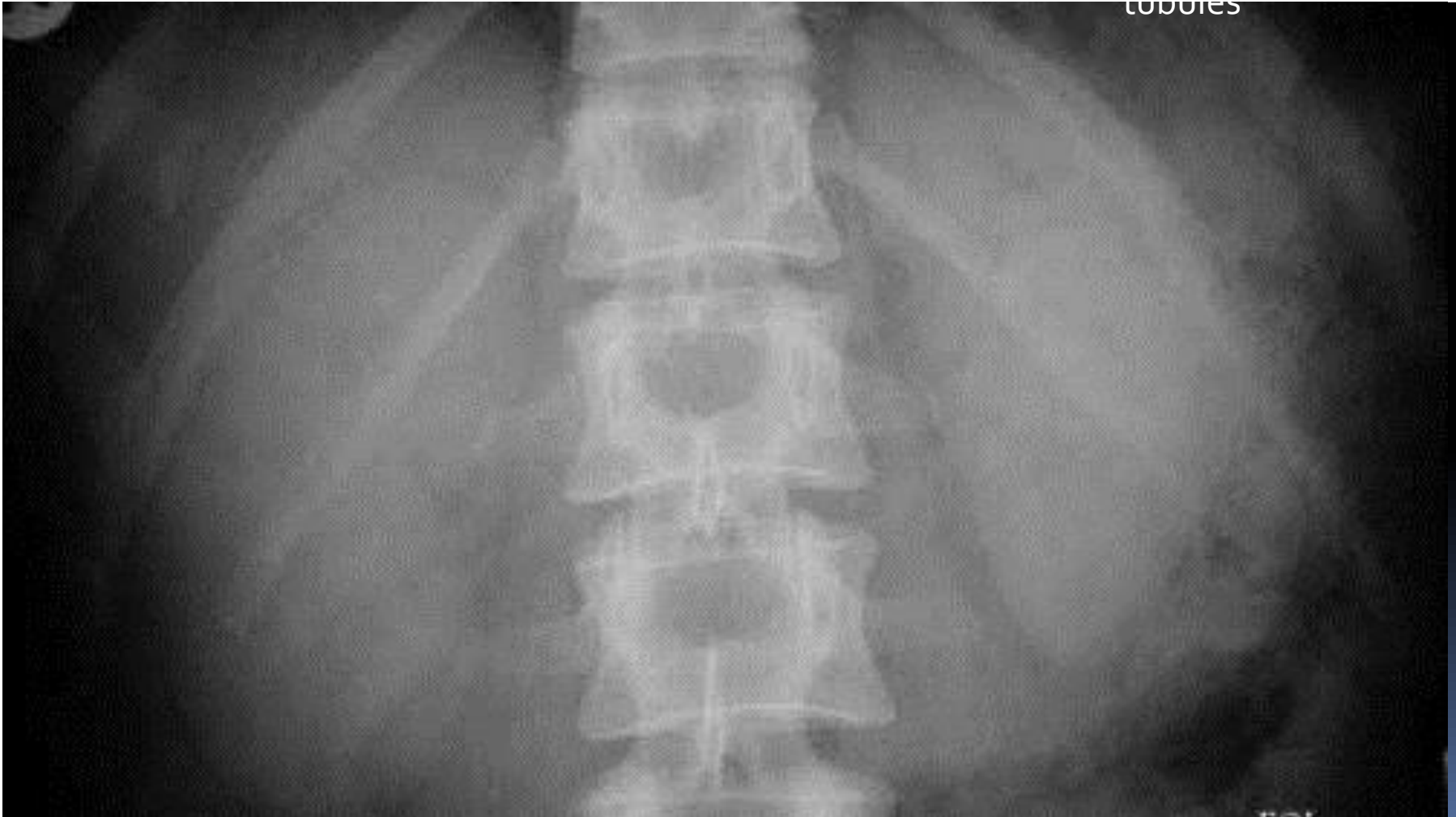


CONTRAST INJECTION

- The median cubital vein is punctured with a 19 gauge needle and the warmed (40°C) contrast agent is injected rapidly. Films are then taken at intervals to demonstrate the whole of the renal tract. The most common contrast used is non ionized iodine 350-370 strength

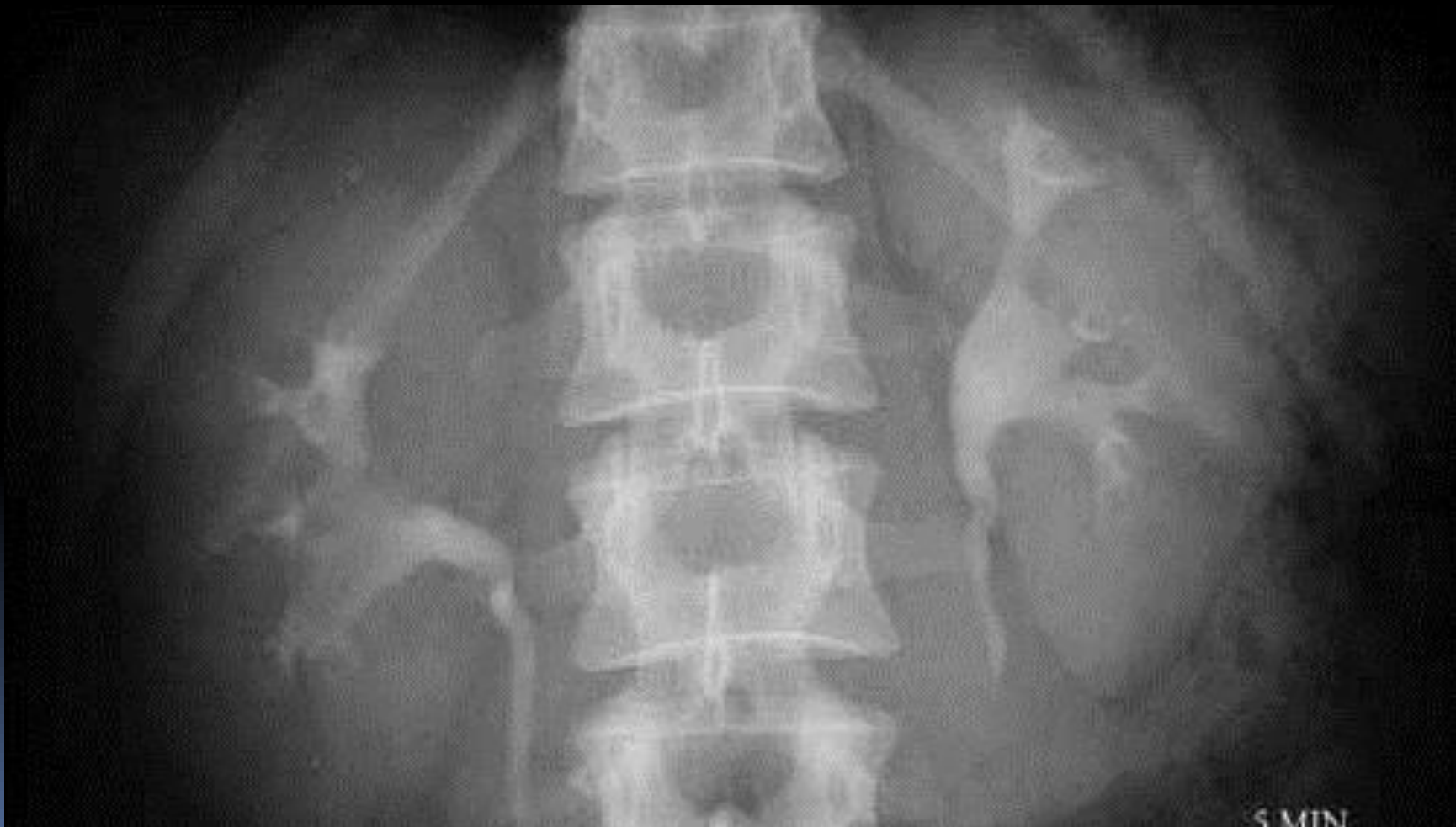
End of Injection

(24 x 30cm) A.P. of the renal areas to show the nephrogram, i.e. the renal parenchyma opacified by the contrast medium in the renal tubules



5 Minute film,

(24 x 30cm) A.P. of the renal areas to determine if excretion is symmetrical or if uptake is poor and a further dose of contrast agent is required

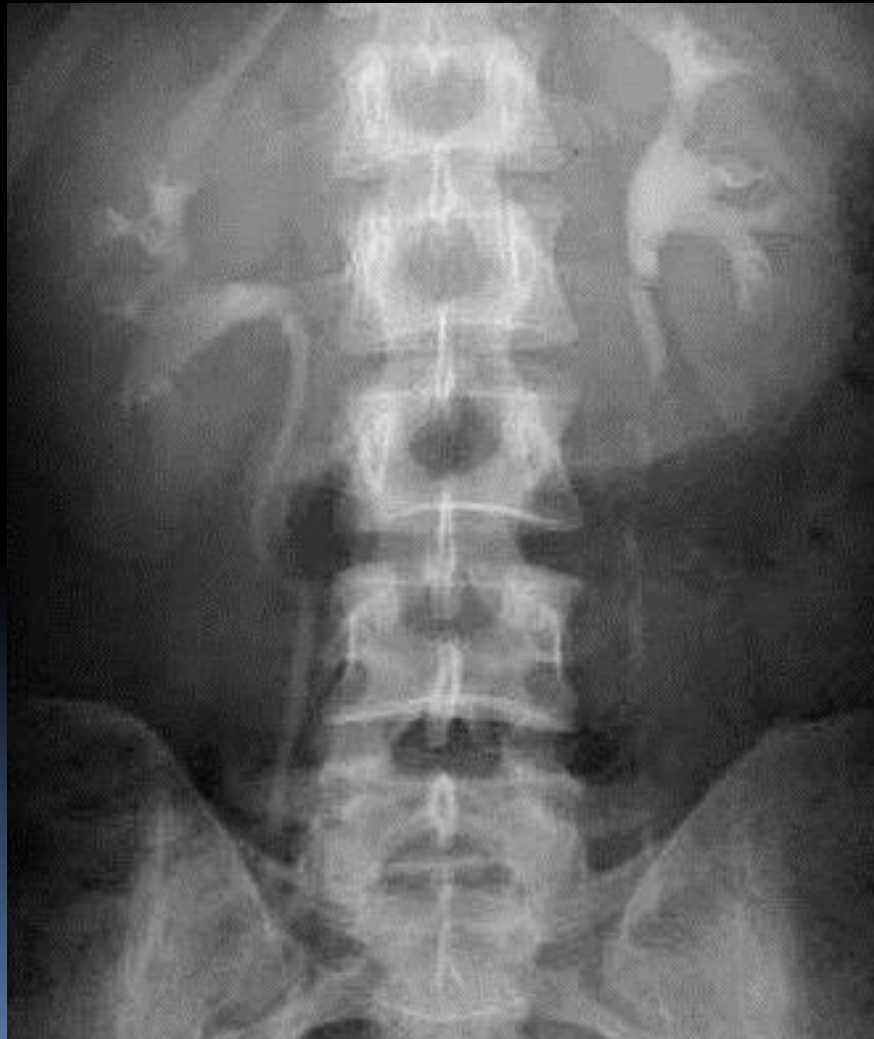


Compression

- may be applied in some centers at this point to distend the pelvicalyceal systems to demonstrate any filling defects and a film taken at 10 minutes of the renal areas. Compression should not be used in cases of suspected renal colic, renal trauma or after recent abdominal surgery

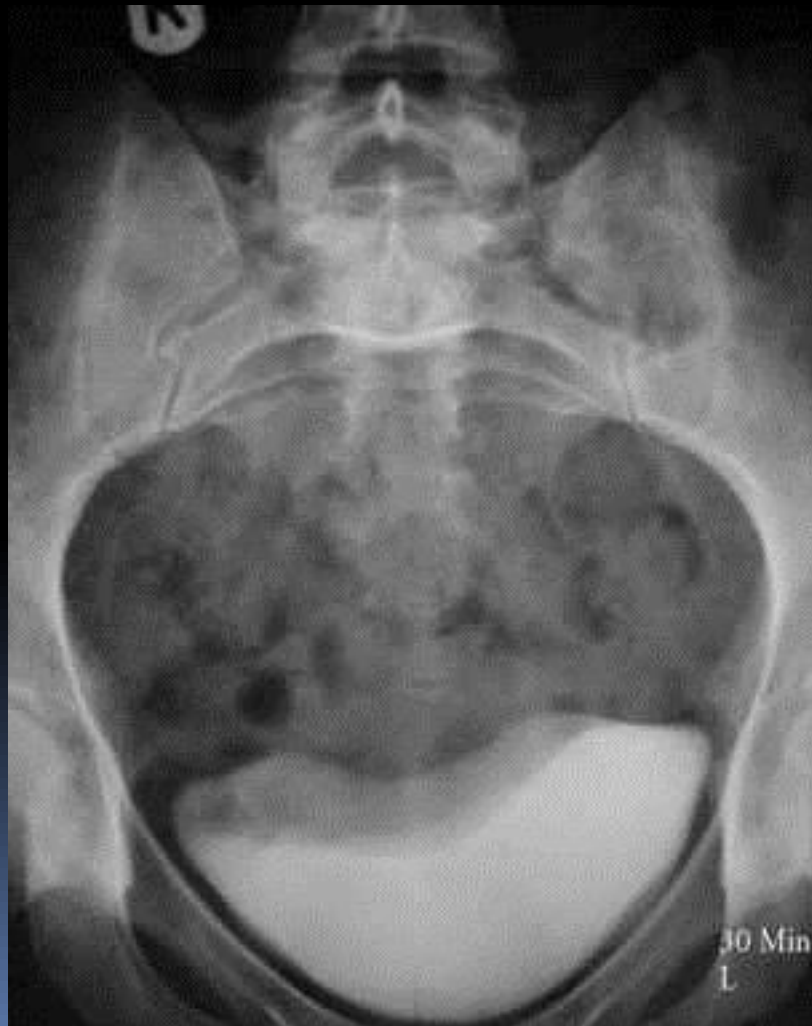
15 Minute film (35 x 43cm)

release if compression has been applied) to demonstrate the pelvicalyceal systems and the ureters.



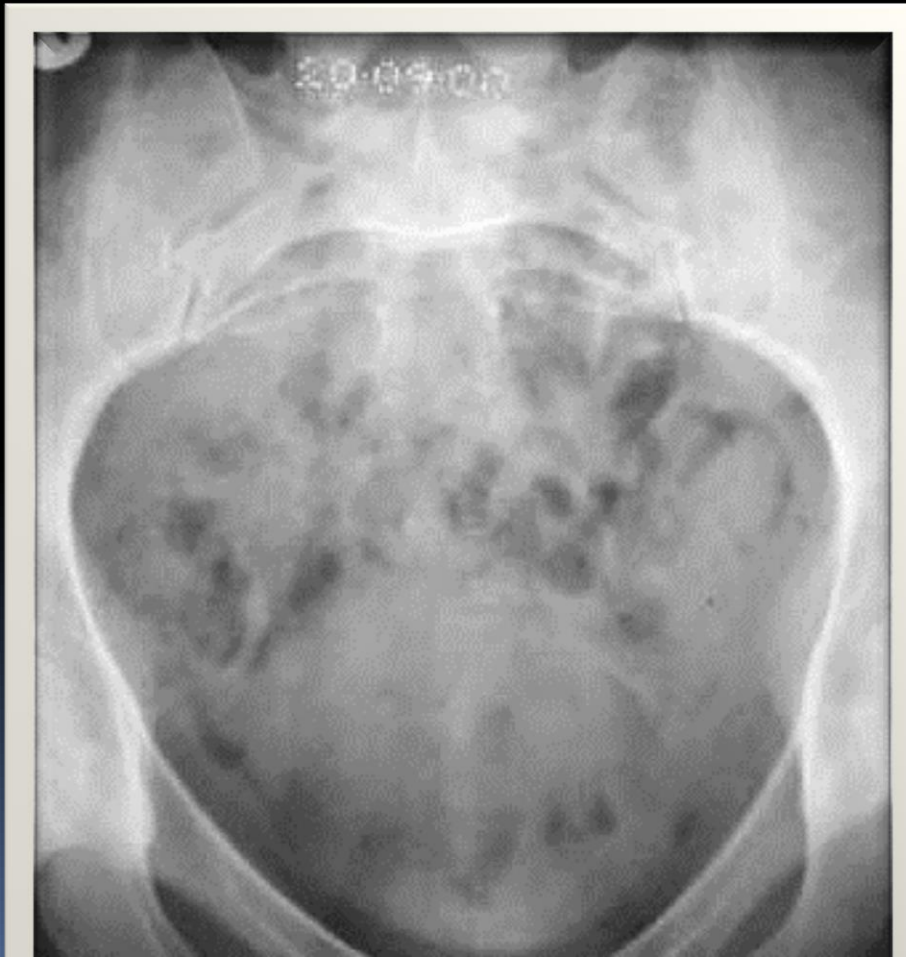
25 Minute film

24 x 30cm) 15° caudal angulation centered 5 cm above the upper border of the symphysis pubis to demonstrate the distended bladder.



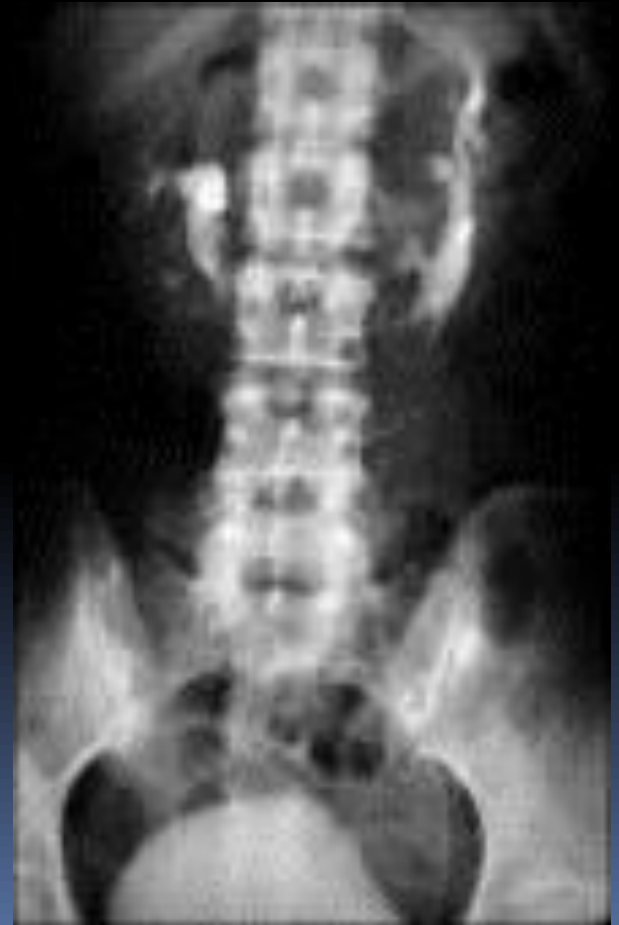
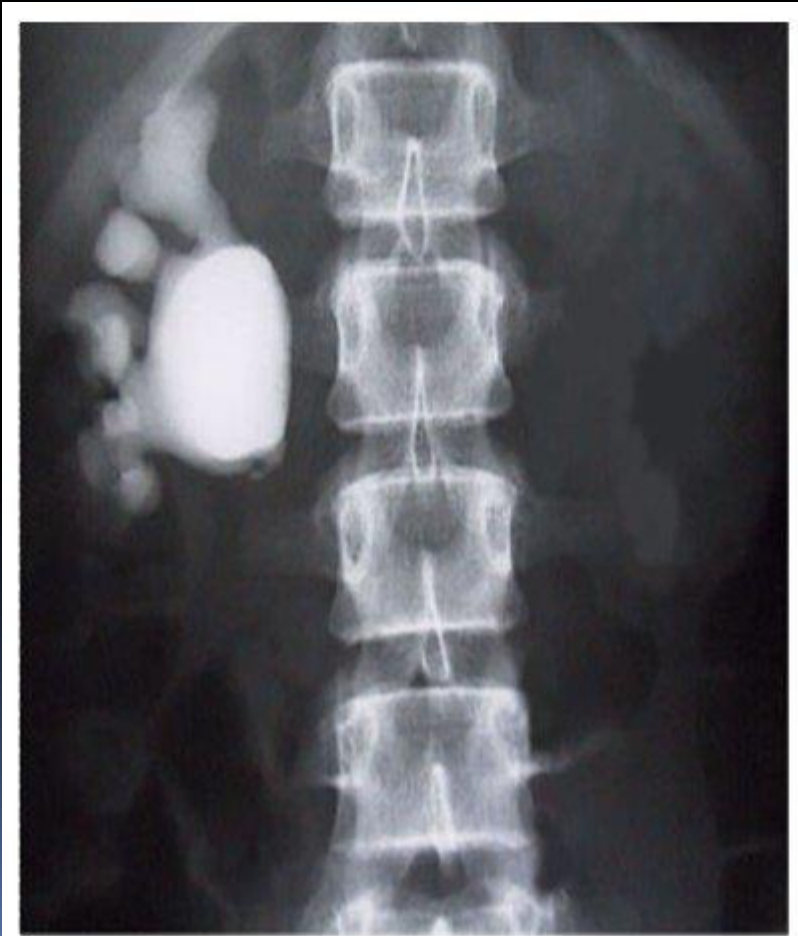Post Micturition film

24 x 30cm) 15° caudal angulation centered 5 cm above the upper border of the symphysis pubis to demonstrate the bladder emptying success, and the return of the previously distended lower ends of ureters to normal.



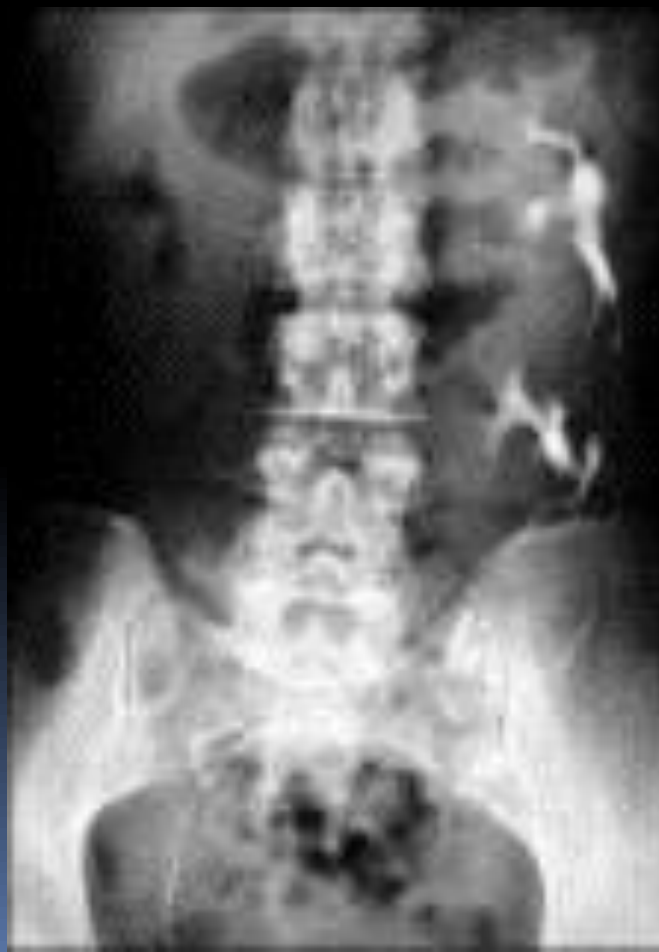
CONGENITAL ANOMALLY

RENAL agenesis and horse shoe kidney



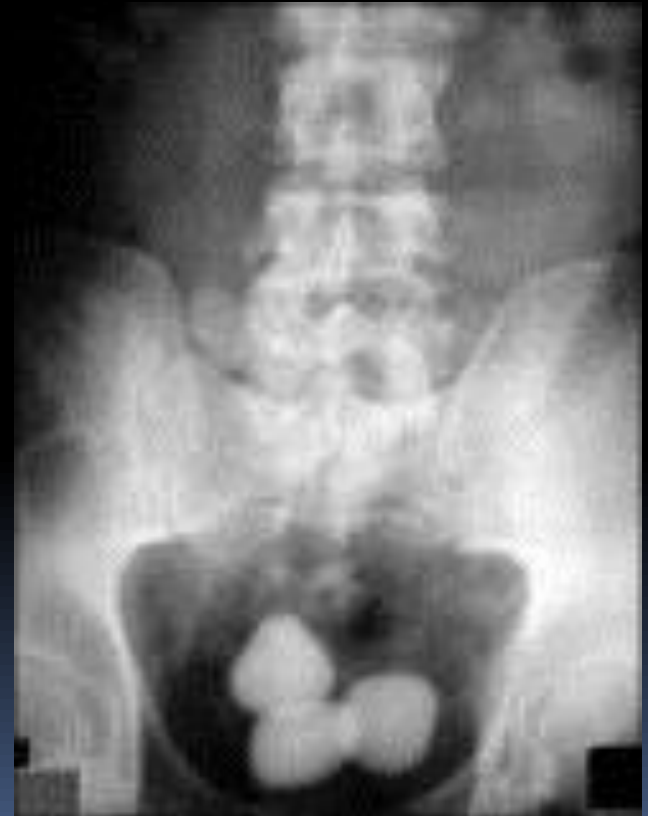
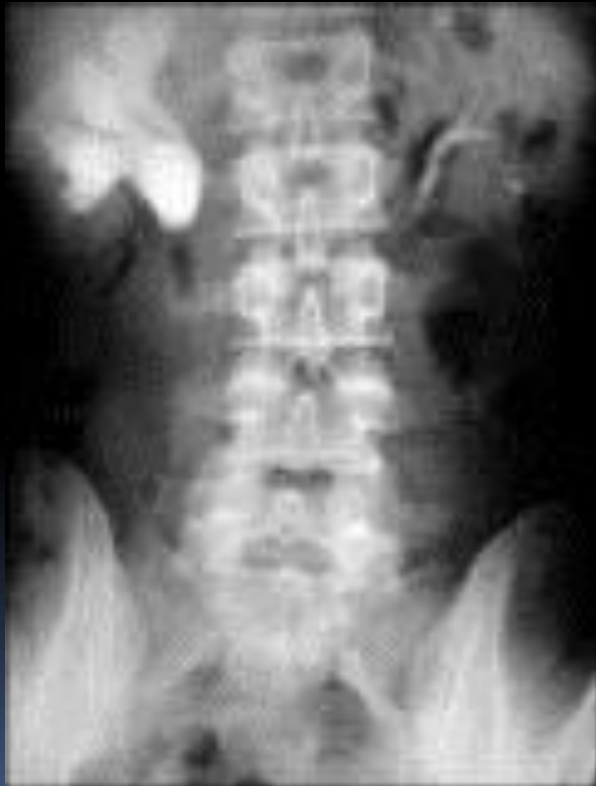Congenital anomaly

Duplex kidney



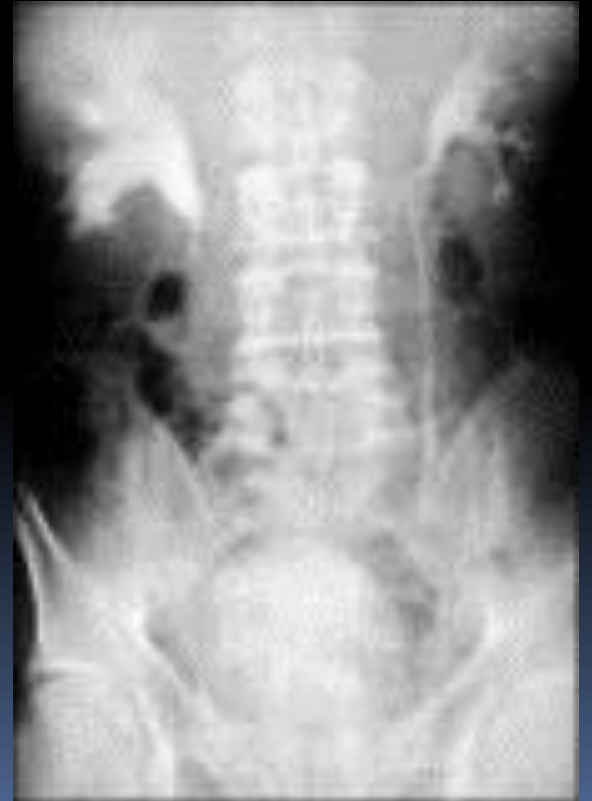
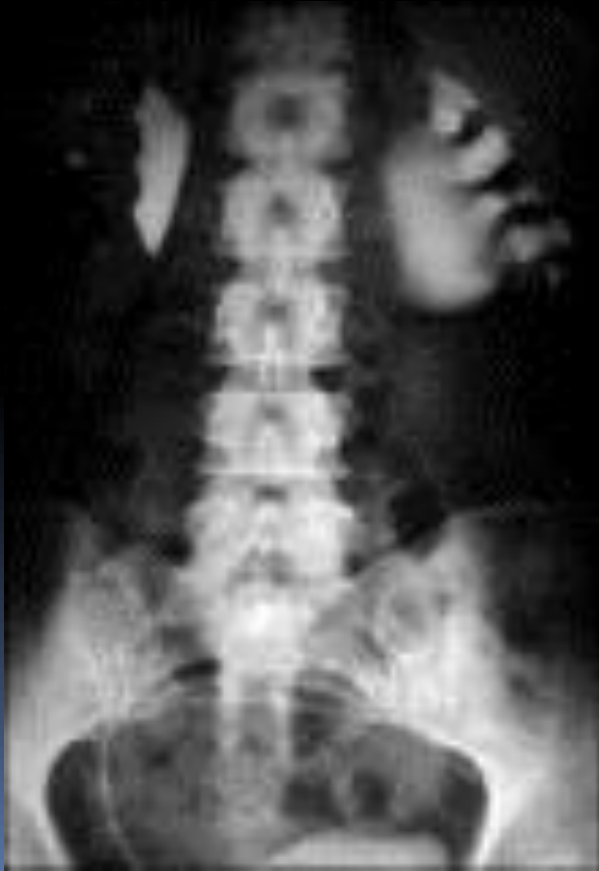RENAL CALCULI

Right URETERIC pelviureteric junction AND LOWER BLADDER CALCULUS



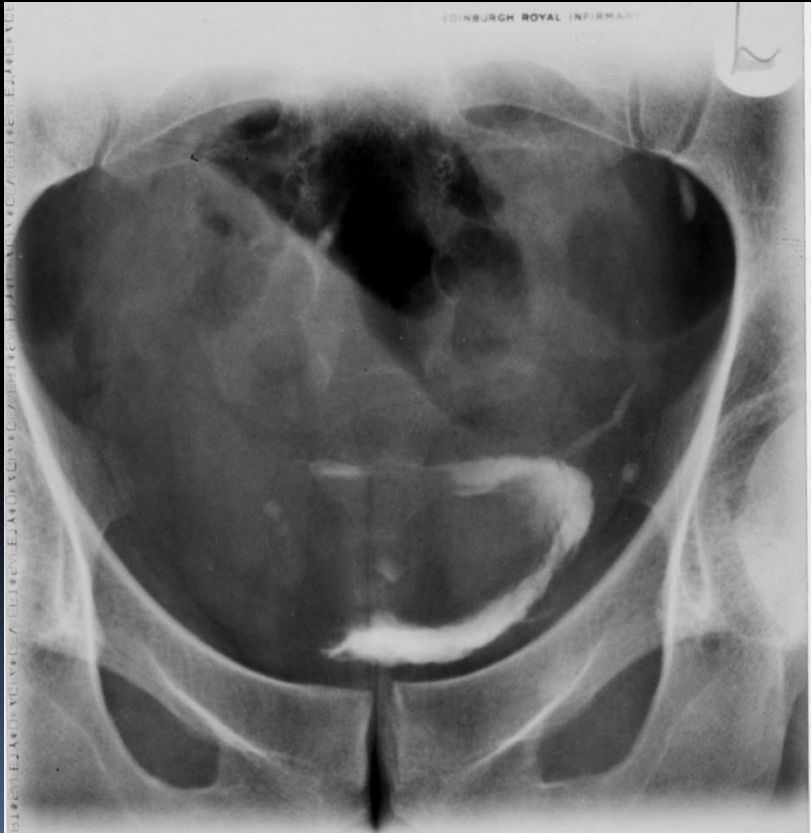
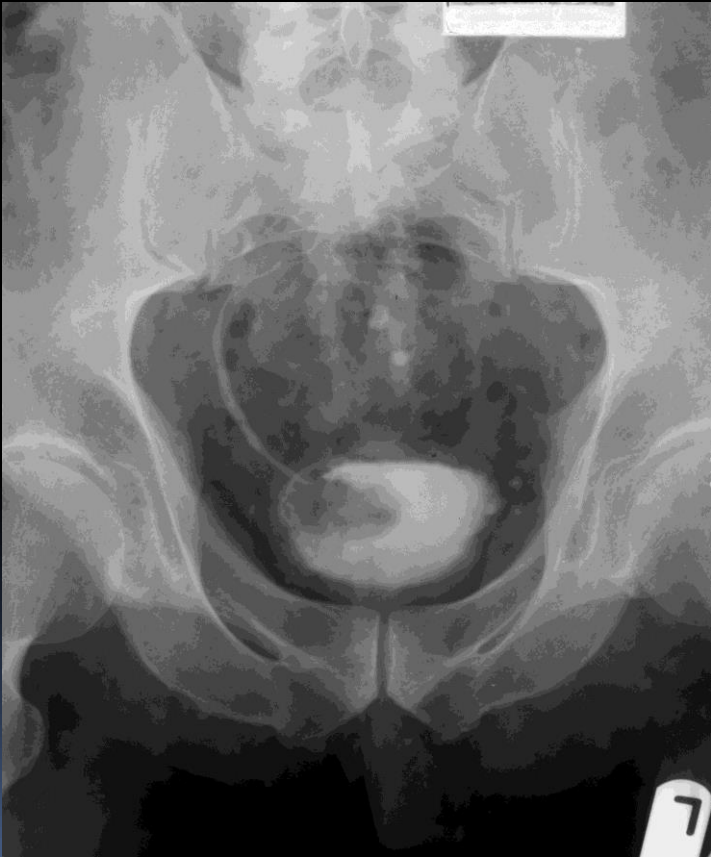RENAL CACULUS

Left stag horn calculus and right ureteric stone



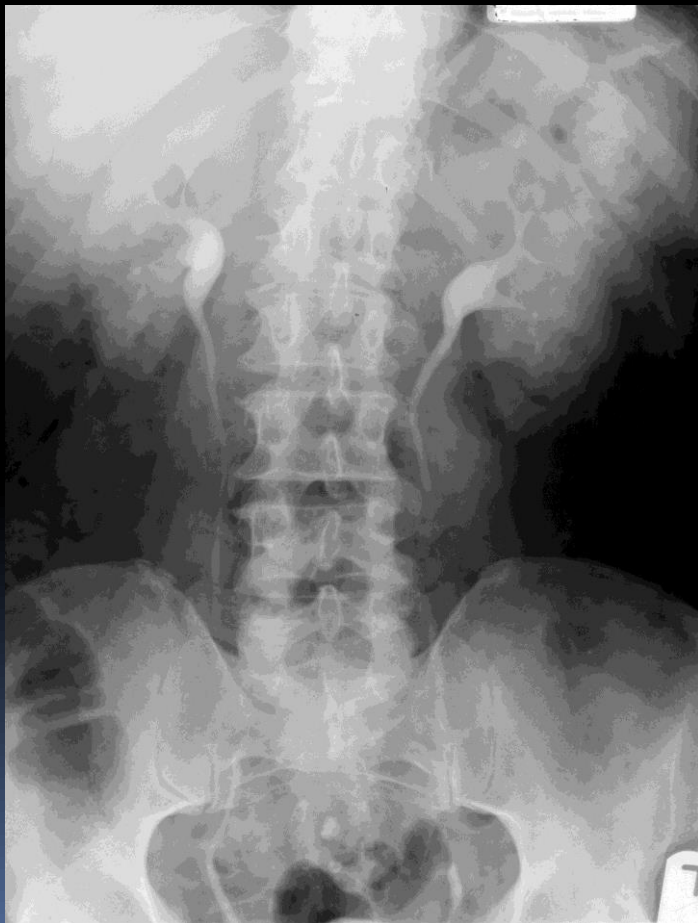
NEOPLASIM

CA BLADDER



RENAL NEO PLASIM

CA KIDNEY



Retrograde cystography - Indications

- Bladder cancer
- Vesicoureteral reflux
- Bladder polyps, and
- Hydronephrosis.



URETHROGRAM

TYPES

➤ **Antegrade -VCUG / MCU-**

Bladder is filled with contrast via suprapubic or retrograde catheterization and the urethra is assessed during voiding.

➤ **Retrograde urethrography (RGU) –**

Contrast is retrogradely injected with the urethral orifice occluded to prevent reflux of contrast.

➤ **Following IVU**

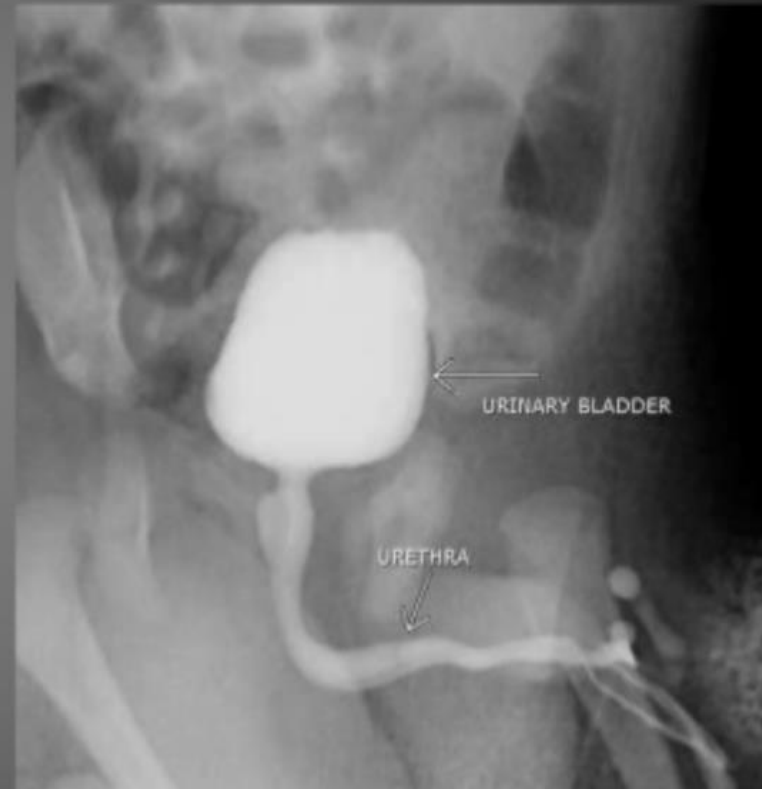X INDICATIONS :- Micturating cystourethrogram (MCU)/Anterior Urethrogram

CHILDREN

- UTI
- Voiding difficulties.
- Vesico-ureteric reflux.
- Baseline study prior to urinary tract surgery.
- Post operative evaluation of ureteric abnormalities.
- Trauma.
- Suspected anatomic abnormalities of bladder neck & urethra. (posterior urethral valve)

ADULTS

- Functional disorders of bladder & urethra.
- Suspected vesicovaginal / vesicocolic fistula.
- Suspected bladder / urethral trauma.
- Urethral diverticula



NORMAL MCU



ANTEROGRADE URETHROGRAPHY/ MICTURATING CYSTOURETHROGRAPHY

- **INDICATIONS**

- **CHILDREN**

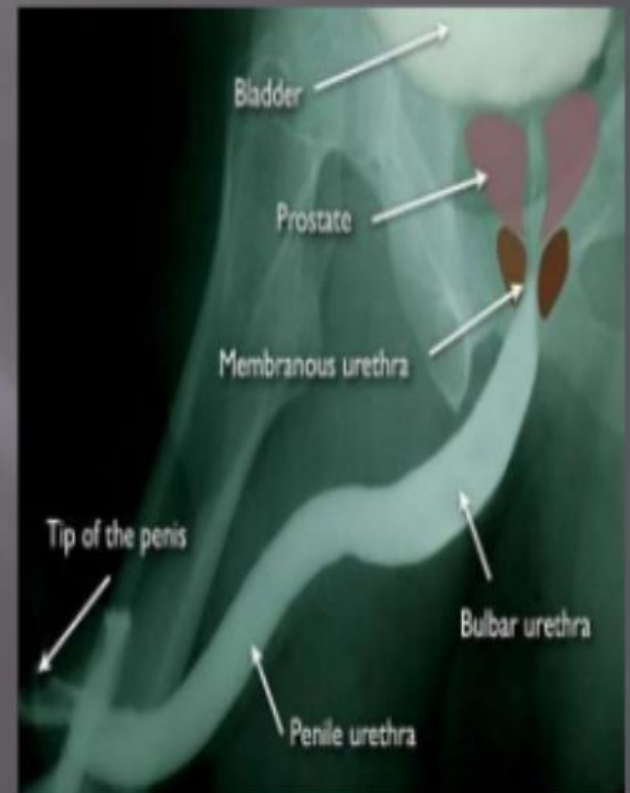
- UTI
- Voiding difficulties.
- Vesico ureteric reflux.
- Baseline study prior to urinary tract surgery.
- Post operative evaluation of ureteric abnormalities.
- Trauma.
- Suspected anatomic abnormalities of bladder neck & urethra. (posterior urethral valve)

- ADULTS**

- Functional disorders of bladder & urethra.
- Suspected vesicovaginal / vesicocolic fistula.
- Suspected bladder / urethral trauma.
- Urethral diverticula

Voiding Cystourethrogram (VCUG)

- ▣ The voiding cystourethrogram is a dynamic test used to demonstrate the lower urinary tract and helps to detect the existence of any vesico-ureteral reflux, bladder pathology and congenital or acquired anomalies of bladder outflow tract. It is performed by passing a catheter through the urethra into the bladder, filling the bladder with contrast material and then taking radiographs while the patient voids.





RETROGRADE / ASCENDING URETHROGRAPHY

- **INDICATIONS**

- Urethral stricture.
- Urethral tear.
- Congenital abnormalities.
- Periurethral / prostatic abscess.
- Fistula / false passages.

- **CONTRAST MEDIUM**

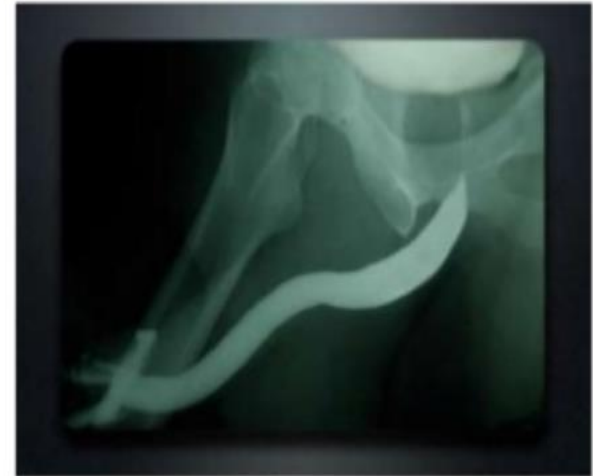
- Urograffin 60%.
- Pre warming the contrast helps to prevent external urethral sphincter spasms

- **EQUIPMENT**

- Tilting radiography table.
- Fluoroscopy / spot film device.
- Foley catheter no 8 / knutsson`s clamp.

- **PREPARATION**

- Patient micturates prior to the procedure



ULTRASOUND



Non invasive. cheap & easy

Indication :

- 1. Patient with urinary symptoms.**
2. Follow-up after lithotripsy
3. Patient with renal transplant to check rejection, stone & hydronephrosis.
4. Renal failure
5. Patient with recurrent UTI (in children) to diagnose reflux. ■

CT SCAN

Used for ■


1. Staging of tumor.
 2. Detection of radiolucent stones (xanthine & uric acid stones).
 3. Retroperitoneal mass, fibrosis
 4. Sagittal reformat (to see kidney in lateral viewer), coronal reformat.
 5. Renal trauma (bleeding, hernatoma).
- in CT scan we 1 take a plain CT without contrast to see if there's calcification.



RADIO-ISOTOPE

mainly for function of the kidney or when we can't do IVU. ■

We inject Tc 99m DTPA intravenously & only the functioning part of the kidney will appear.



MRI

Two main indications ■

1. Renal vasculature before transplant for both the donor & recipient.
2. Renal artery stenosis (5 mm normally) with post stenotic dilation

If we want to do operation, we do angiography also.