

# Cementum

Cementum is the calcified, avascular mesenchymal tissue that forms the outer covering of the anatomic root. In microscopic aspect, the cementum has **no** innervation , **no** blood or lymph vessel and **doesn't** undergo physiological remodeling(resorption and deposition),but it is characterized by continuous deposition throughout life.

## Functions of cementum:

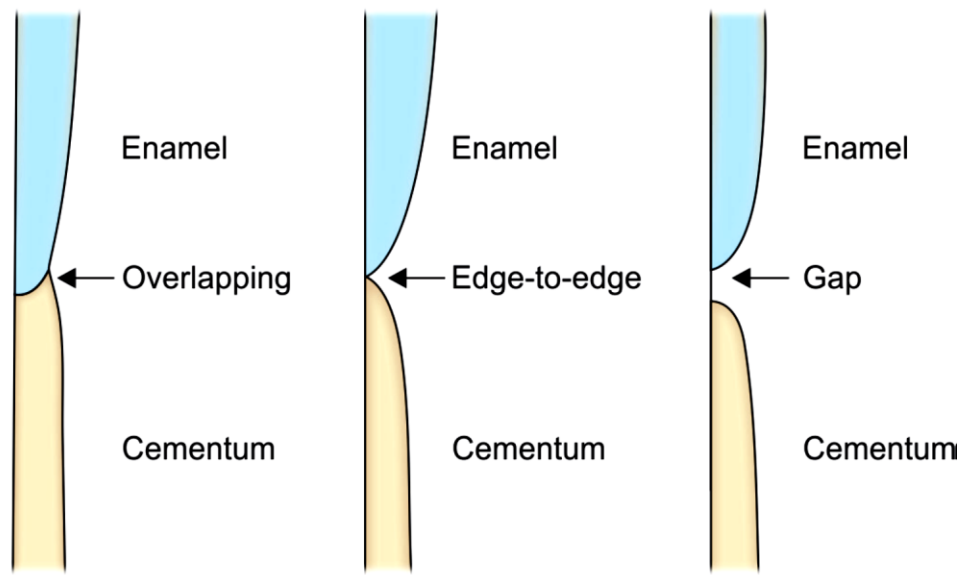
Anchorage of the tooth in the alveolus ,to attach the PDL fibers to the teeth and to contribute to the process of repair after damage to the root surface and following regenerative periodontal surgical procedures.

## Cemento-enamel junction (C.E.J)

### Three types of relationships :-

- ☒ Cementum overlaps the enamel (60%-65%).
- ☒ Edge-to edge (butt joint 30%).
- ☒ Cementum and enamel fail to meet (5%-10%).

In the last condition, there is a possibility of **gingival recession** which may result in **sensitivity** because the dentin is exposed.



**Fig. Schematic representation showing cemento-enamel junctions (CEJ)**

**The two main types of cementum are :-**

- 1- Acellular (primary) cementum** is the first cementum formed; it covers approximately the cervical third or half of the root, and it does not contain cells. This cementum is formed before the tooth reaches the occlusal plane. Sharpey's fibers make up most of the structure of acellular cementum, which has a principal role in supporting the tooth. Most fibers are inserted at approximately right angles into the root surface and penetrate deep into the cementum. Acellular cementum also contains intrinsic collagen fibrils.
- 2- Cellular (secondary) cementum** which is formed after the tooth reaches the occlusal plane, is more irregular and contains cells (cementocytes) in individual spaces (lacunae) that communicate with each other through canaliculi. Cellular cementum is less calcified than the acellular type. Sharpey fibers occupy a smaller portion of cellular cementum

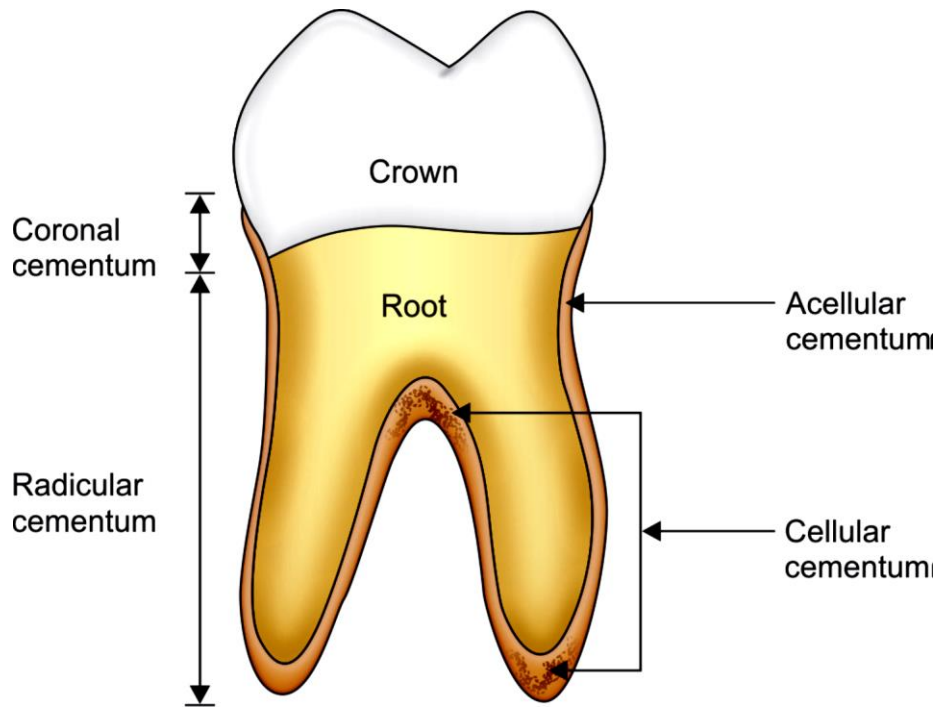


Fig. Schematic representation showing distribution of cementum on root surface.

## Structures of cementum:-

### 1-Fibrous elements:-

**A. Extrinsic fibers (Sharpey's fibers):** which are the embedded portion of the principal fibers of the PDL and are formed by the **fibroblast** cells. Sharpey's fibers make up most of the structure of acellular cementum

**B. Intrinsic fibers:** These fibers are produced by **cementoblast** cells and are oriented more or less parallel to the long axis of the root and form a cross banding arrangement with Sharpey's fibers.

**2-Cellular elements:** The cells associated with cementum are few and generally reside within the PDL.

**A- Cementoblast cells:** Responsible for the formation of both cellular and acellular cementum.

**B- Cementocyte cells:** are found **only** in cellular cementum , it located within spaces (**lacunae**) that communicate with each other through **canaliculi** for transportation of nutrients through the cementum and contribute to the maintenance of the vitality of the tissue.

**C- Fibroblast cells:** these cells belong to the PDL where they are responsible for synthesis of principal fibers but since these fibers become embedded in cementum, fibroblasts indirectly participate in the formation of cementum.

**D- Cementoclast cells:** these cells are responsible for extensive root resorption that lead to primary teeth exfoliation. Permanent teeth do not undergo physiologic resorption but localized cemental resorption may occur which appears as concavities in the root surface and may be caused by local or systemic causes. **Local conditions** include, trauma from occlusion, orthodontic movement, cyst and occur on mesial surfaces in association with mesial drift. Among **systemic conditions** are calcium deficiency and hypothyroidism.

**Reversal line:** The newly formed cementum is demarcated from the root by a deeply staining irregular line which indicating the cessation of resorption and the resumption of apposition

**Incremental lines of Salter :-** Mineralized areas with less collagen and more ground substance than other portions in cementum. The incremental lines are parallel to the long axis of the root.

**3-Interfibrillar matrix:** These are proteoglycans, glycoproteins and phosphoproteins formed by **cementoblast** cells. Proteoglycans are most likely to play a role in regulating cell-cell and cell-matrix interactions both during normal development and during the regeneration of cementum.

## **Cementum mineralization**

Occurs by the deposition of hydroxyapatite crystals, **first** within the collagen fibers, **later** upon the fiber surface and **finally** in the interfibrillar matrix. Cellular cementum is **less** calcified than acellular cementum and cementum mineralization is **less** than that of the bone, enamel and dentin.

## **Development of cementum**

Both cellular and acellular cementum are produced by **cementoblast** cells. **Cementoid** is first formed which is a non-calcified tissue containing collagen fibrils distributed in matrix. Cementum is characterized by continuous deposition and increase in thickness throughout life. Cementum formation is **most rapid** in the apical regions to compensate for tooth eruption and attrition. The thickness of cementum is more pronounced in the apical third and in the furcation areas than the cervical portion. Cementum is **thicker** in distal than in mesial surfaces because of functional stimulation from mesial drift over time.

## **Cemental defects**

**1-Hypercementosis:** Refers to a prominent thickening of the cementum. It is an age-related phenomenon and it may be localized to one tooth such as tooth without antagonists or with periapical lesion, and sometimes affect the entire dentition that may occur in patients with Paget's disease.

**2-Cemental aplasia or hypoplasia:** Refers to an absence or lack of cellular cementum.

**3-Ankylosis:** Fusion of the cementum and alveolar bone with obliteration of the PDL. It results in resorption of the cementum and its gradual replacement by bone tissue and it may develop after chronic periapical inflammation and occlusal trauma.

## Alveolar process(AP)

**Alveolar process(AP)** Is the portion of the maxilla and mandible that forms and supports the tooth sockets (alveoli). It develops in conjunction with the formation of and during the eruption of the teeth and is gradually resorbed if the teeth are lost, thus it is tooth dependent structure.

### Functions of alveolar process

- 1.Comprises the attachment apparatus and the supporting tissue of the teeth together with root cementum and PDL fibers.
- 2.Provide the osseous attachment to the PDL fibers
- 3.Distribute and resorb forces generated by mastication and other tooth contacts.

**Alveolus: Is the space in the alveolar bone that accommodates roots of the teeth.**

### Parts of the alveolar process

**1.Alveolar bone proper:** It is a thin layer of compact bone forming the inner socket wall (lines the alveolus), which is seen as the **lamina dura** in radiographs. A great number of sharpey's fiber bundles are embedded into this layer of bone which is adjacent to the PDL therefore it is called(**bundle bone**)).

**Histologically** this bone contains many small holes or openings called (**volkmann's canals**)) through which blood vessels , lymphatic's and nerves link the PDL with the cancellous bone thus it is called (**cribriform plate**)).

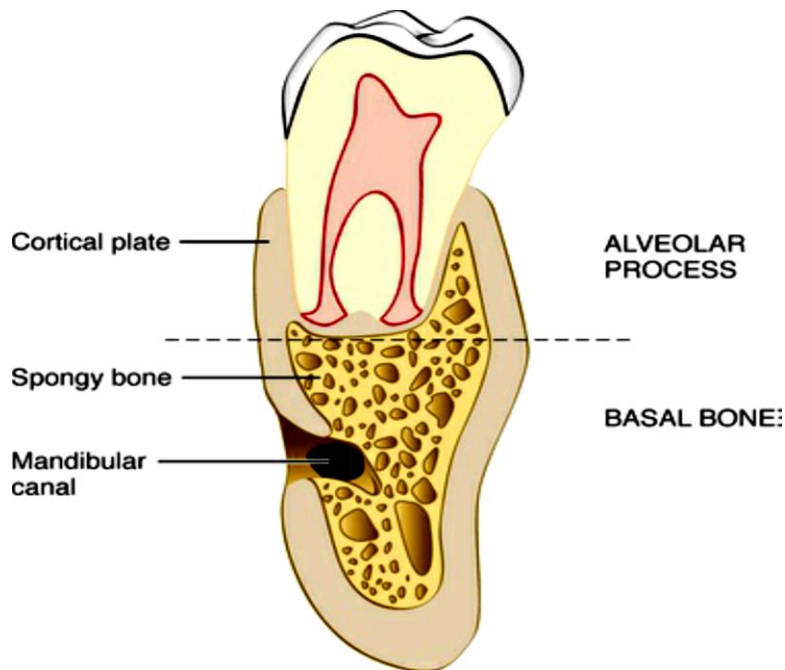
### 2. External plate of cortical bone

**3.Cancellous trabeculae or spongy bone:** Which is located in the space between the external cortical plate and alveolar bone proper, they meet and fuse to form the

**alveolar crest.** Cancellous bone, which act as supporting alveolar bone, with cortical bone surround the alveolar bone proper (ABP).

**Basal bone:-** is the portion of the jaw located apically but unrelated to the teeth.

**Lamina dura:-** Appears as white line surrounding the layer of ABP root of the tooth on radiographs.



**Fig. Schematic representation showing the alveolar bone and basal bone.**

The alveolar processes are subdivided according to their anatomical relationships to the teeth

**1. Interproximal bone (interdental septum):-** The bone located between the roots of adjacent teeth

**2. Inter radicular bone:-** the bone located between the roots of multirooted teeth.

**3. Radicular bone:-** the alveolar process located on the facial, lingual or palatal surfaces of the roots of teeth.

The distance between the crest of the alveolar bone and the cemento-enamel junction increases with age to an (**average of 2.81mm**). The thickness of alveolar process varies from one region to another depends on the position of the teeth in the arch and their relationship to one another, e.g. teeth that are labially positioned in the arch will have thin labial radicular bone and thicker lingual radicular bone.

**Bone marrow:-** The cavities of all bones of **new born** are occupied by red marrow while in the **adult** jaw occupied by fatty or yellow type of marrow, however foci of red bone marrow are seen in the jaw which may be visible radiographically as zones of radiolucency. Common locations are the maxillary and mandibular molar and premolar areas.

#### **Periosteum and Endosteum :-**

**Periosteum:-** It is a layer of tissue covering the outer surface of bone, it contains collagen fibers and cells (osteoblasts) with blood vessels, nerves and fibroblasts.

**Endosteum:-** The marrow spaces inside the bone are lined by endosteum, this tissue contains cells (osteoblasts).

#### **Anatomical defects of the bone:-**

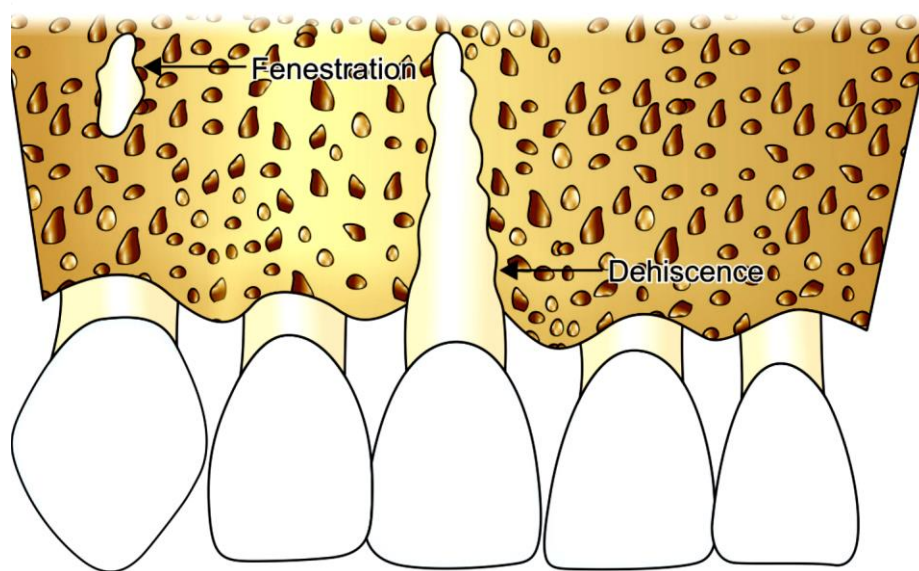
**1.Fenestration(window):-** This bony defect includes isolated areas in which the root is **not** covered with bone but covered **only** by periosteum and overlying gingiva and it does not extend to the marginal bone.

**2.Dehiscence:-** This bony defect includes the denuded areas which extend to the bone margin, exposing the root surface. The defects may extend to the middle of the root or farther.



Such defects occur on approximately 20% of the teeth, they occur more often on the facial bone than on the lingual bone are more common on anterior than on posterior teeth.

The cause of these defects is **not clear**, but may be related to some **factors** such as, prominent root, malposition or labial protrusion of the root with thin bony plate.



**Fig. Schematic representation showing dehiscence and fenestration.**

### **Haversian system or Osteon:-**

It is an internal mechanism that bring a vascular supply to bones, consists of central canal called (**Haversian canal**) which in their center contains the blood vessel. These blood vessels surrounded by bone lamellae which arranged in concentric layers constitute the center of an osteon. The blood vessels in haversian canal are connected with each other by anastomoses running in the Volkmann's canals, so the nutrition of bone is secured by the incorporation of blood vessels in the bone tissue.

## **Bone cells**

**1-Osteoblast cells (bone forming cells):** is responsible for the production of an organic matrix of bone which is consisting primarily of collagen fibers called (osteoid), this bone matrix undergoes mineralization by the deposition of minerals such as calcium and phosphate, which are subsequently transformed to hydroxyl apatite.

**2-Osteoclast cells:-** These are large multinucleated cells found in concavities on the bone surface called (**Howship's lacunae**) these cells responsible for bone resorption.

**3-Osteocyte cells:-** osteoblast cells that become trapped in the bone matrix and later on in the mineralized bone tissue ,called osteocyte cells, they are located in the lacunae and are connected with the one another by extending processes into canaliculi through which they get nutrients and removes metabolic waste products.

## **Resorption of bone**

The sequence of events in the resorptive process as follows:

1-Attachment of osteoclasts to the mineralized surface of bone

2-Creation of a sealed acidic environment, which demineralizes bone and exposes the organic matrix

3-Degradation of the exposed organic matrix to its constituent amino acids via the action of released enzymes(e.g.,acid phosphates, cathepsin).

4-Sequestering of mineral ions and amino acids within the osteoclast

## **Composition of the bone:**

Bone consists of 2/3 inorganic matter and 1/3 organic matrix. The inorganic matter is composed principally of the minerals calcium and phosphate, along with hydroxyl, carbonate, citrate, and lactate trace amounts of other ions such as sodium, magnesium and fluorine. The mineral salts are in the form of hydroxyapatite crystals.

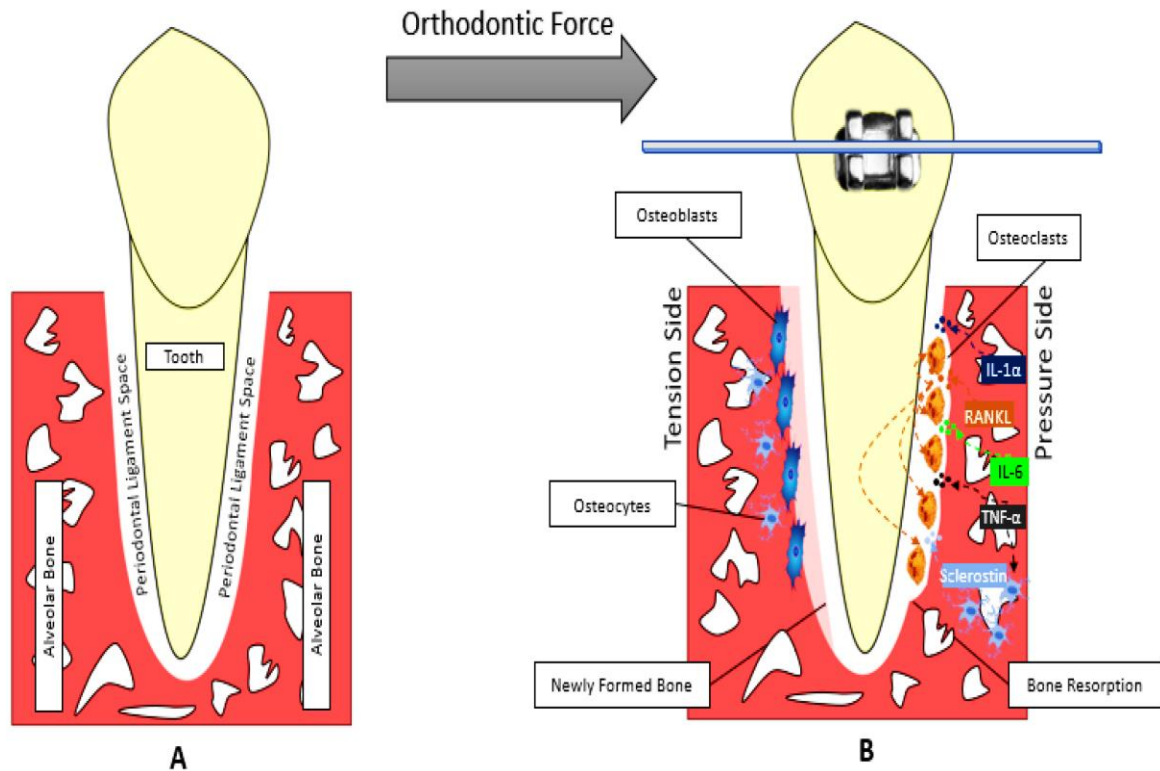
The organic matrix consists mainly of collagen type I fibers (90%), with small amounts of non-collagenous proteins such as osteocalcin and osteonectin.

Bone contains 99% of the body's calcium ions and therefore is the major source for calcium release when the calcium blood levels decrease, this is monitored by the parathyroid gland.

## **Remodeling of alveolar bone:**

Alveolar bone undergoes constant physiologic remodeling (resorption and formation) in response to external forces specially occlusal forces. Teeth erupts and tend to move mesially throughout life to compensate for wearing in the proximal contact areas with age which become flat, this referred to as physiologic mesial migration, thus osteoclast cells and bone resorption occur in areas of pressure on the mesial surface and osteoblast cells with new bone formed in areas of tension on the distal surface. This process of resorption and formation of bone is called bone remodeling and it is important in the orthodontic treatment.

Remodeling of alveolar bone is regulated by local influences include functional requirements on the tooth and age related changes in bone cells while, systemic influences are probably hormonal (e.g., parathyroid hormone, or vitamin D3).



**Fig. Orthodontic movement**