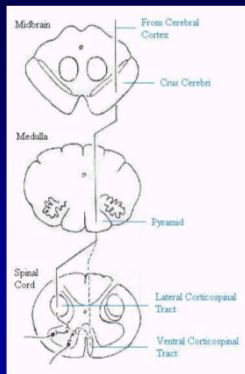


The upper motor neuron (supranuclear, central)

- Nerve cells are in the frontal lobe and adjacent (premotor and supplementary) cortical areas. These axons constitute **corticospinal tract**, known also as the **pyramidal tract**.
- This tract descends from the cerebral cortex (frontal motor and premotor cortices, **Brodman's area 4,6**), transverse corona radiata - subcortical white matter, internal capsule, brainstem and decussates in the lower end of the medulla.

The upper motor neuron (supranuclear, central)

- 80% of the fibres cross (decussatio pyramidum) and the remainder descend uncrossed ipsilaterally (**ventral corticospinal tract**). Crossed fibres continue in the lateral funiculus of the spinal cord (**lateral corticospinal tract**).
- Upper motor neurons terminate mainly in the synapses of the spinal gray matter, from which motor impulses are transmitted to the anterior horn cells.

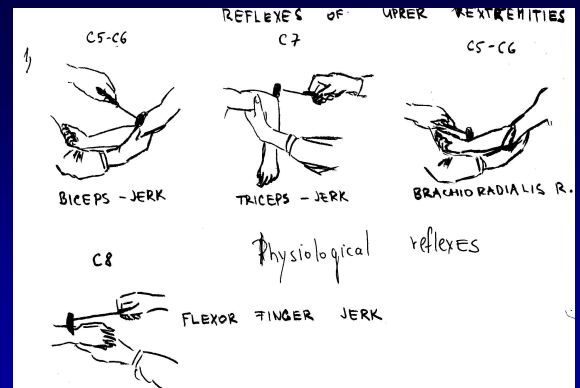


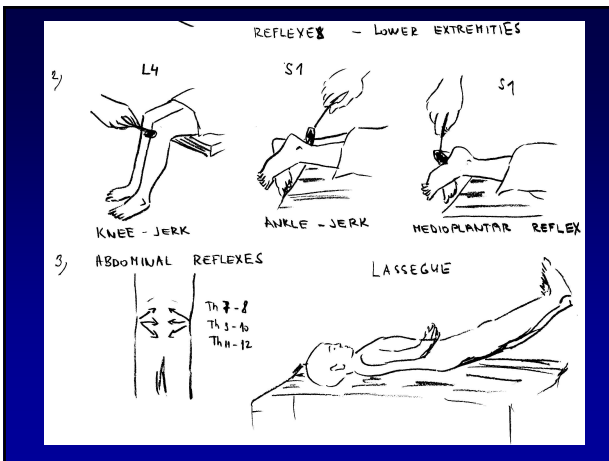The upper motor neuron (supranuclear, central)

- Similar to corticospinal tract is **corticobulbar pathway**, which ends in synapses with motor nuclei of cranial nerves in brainstem.

The upper motor neuron (supranuclear, central)

- Paralysis due to affection of upper (central) motor neuron is known as **central (spastic) type of paralysis**.
- **Tendon reflexes are increased**- hyperreflexia. The hyperreflexic state often takes the form of **clonus**, a series of rhythmic involuntary muscular contractions in response to an abruptly applied stretch stimulus (clonus of patella, ankle).





The upper motor neuron (supranuclear, central)

- The **cutaneomuscular** abdominal and cremasteric reflexes are usually abolished.
- Muscle atrophy** that follows upper motor neuron paralysis never reaches the proportions seen diseases of lower motor neuron. Atrophy in spastic paresis is **due to disease**.

The upper motor neuron (supranuclear, central)

- Characteristic feature increased muscle tone is **spasticity**. This term means a specific pattern of **response of muscles to passive stretch** (resistance increases linearly in relation to velocity of stretch). „clasp-knife“
- The antigravity muscles- flexors of the arms and the extensors of the legs- are predominantly affected. The arm tends to assume flexed and pronated position and the leg an extended and adducted during movement.
- Pathological reflexes are present**

The upper motor neuron pathological rr. at upper extremity

The upper motor neuron pathological rr. at lower extremity

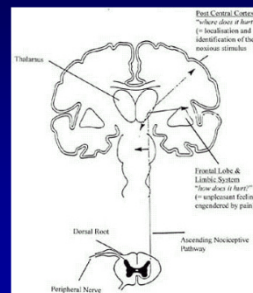
The upper motor neuron (supranuclear)

- The corticospinal pathway may be interrupted at any point along its course (cerebral cortex, internal capsule, brainstem, spinal cord). Neurologic picture depends on localization of lesion.

The lower motor neuron (infranuclear, peripheral)

- **Lower (infranuclear) motor neurons** are the final common path by which neural impulses are transmitted to muscle. Nerve cells of lower motor neurons are situated in the anterior horns of the spinal cord and motor nuclei of the brainstem. Axons of these cells comprise the anterior spinal roots, then the spinal nerves (or cranial nerves) and they innervate the skeletal muscles. These nerve cells and their axons constitute **peripheral or lower motor neurons**.

The lower motor neuron (infranuclear, peripheral)



The lower motor neuron (infranuclear)

- Paralysis due to affection of lower (peripheral) motor neuron is known as **peripheral (flaccid) type of paralysis**.
- Complete or incomplete interruption of peripheral motor fibres (anterior horn cells, their axons in anterior roots, peripheral nerves) is followed by all voluntary, postural and reflex movements abolition.

The lower motor neuron (infranuclear)

- The muscle becomes lax and soft and does not resist passive stretching. This condition is known as **flaccidity**. Muscle tone (muscle tone is defined as resistance to passive stretch) appears to be reduced-**hypotonia or atonia**.
- The denervated muscles undergo extreme atrophy within 3 to 4 months.

The lower motor neuron (infranuclear)

- The **electrodiagnosis** of denervation depends upon finding fibrillations, fasciculations and other abnormalities on needle electrode examination (EMG).
- These abnormalities appear only 2-3 weeks after nerve lesion (injury).

The lower motor neuron (infranuclear, peripheral)

- **Myotatic** tendon reflexes (bicipital, patellar, etc) are diminished or absent-**hyporeflexia or areflexia**.
- **Superficial reflexes are normal**. The term superficial reflexes is given to muscle responses evoked by cutaneous stimuli. Those in common clinical use include the abdominal and cremasteric reflexes.

The lower motor neuron (infranuclear)

- Within a few days after motor nerve section, the individual denervated muscle fibres begin to contract spontaneously.
- This contraction of isolated muscle fibre is known as **fibrillation** and cannot be seen through the intact skin, but it can be recorded as a small repetitive potential **in the EMG**.

The lower motor neuron (infranuclear)

- The result of sporadic contraction of one motor unit is isolated from other muscle units as visible twitch or **fasciculation**.
- This spontaneous contraction is explained by hypersensitivity to small doses of acetylcholine.

The lower motor neuron (infranuclear)

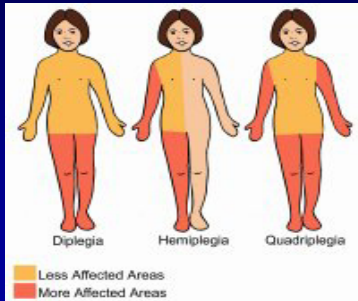
- If the motor neuron is completely destroyed, all muscle fibres that it innervates undergo **atrophy- denervation atrophy**.

	Upper motor neuron paralysis	Lower motor neuron paralysis
Atrophy	slight and due to disuse	pronounced, up to 80% of total bulk
Muscle tonus	increased- hypertonia, spasticity	decreased- hypotonia or atonia, flaccidity
tendon reflexes	hyperreflexia	hyporeflexia or areflexia
abnormal pyramidal signs	present	absent
fascicular twitches	absent	present
EMG	no denervation potentials normal nerve conduction	denervation potentials present (fibrillations, fasciculations in EMG)

- **Paralysis (palsy)** means loss of voluntary movement due to interruption of the motor pathway at any point from the motor cortex to the muscle fiber.
- **Complete loss** of motor function is paralysis or **plegia**. **Partial loss** of motor function is **pareisis** (lesser degree of paralysis).

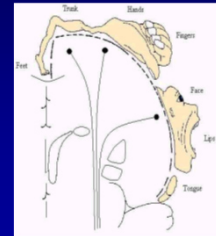
- **According to a localisation of the lesion are used terms**
- hemiparesis (hemiplegia)
- paraparesis (paraplegia)
- monoparesis (monoplegia)
- quadriparesis (quadriplegia).

The upper motor neuron (supranuclear)



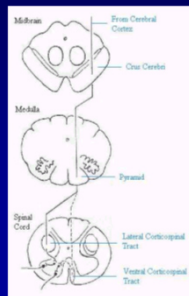
The upper motor neuron (supranuclear)

- Diseases localized to the **cerebral cortex** manifest themselves by weakness of the leg or arm or lower face on the opposite side - **monoparesis**.



The upper motor neuron (supranuclear)

Diseases localized to the **cerebral white matter** (corona radiata), and **internal capsule** manifest themselves by weakness of the leg, arm and lower face on the opposite side - **hemiparesis**.



The upper motor neuron

- Damage to corticospinal and **corticonuclear tract in the upper portion of brainstem** causes paralysis of the opposite side (**contralateral hemiplegia**-face, arm and leg) and lesion may in some patients involve **cranial nerves on the same side as the lesion** - **hemiplegia alternans**

The upper motor neuron alternative hemiplegia

- Lesion in the upper portion of brainstem (**mesencephalon**) causes **contralateral hemiplegia** and **homolateral lesion of third-nerve** - **Weber's syndrome** or **hemiplegia alternans superior**.
- Pontine lesion** causes **contralateral hemiplegia** and **homolateral lesion of abducens or facial nerve palsy** - **Millard-Gubler syndrome** - **hemiplegia alternans media**.
- Lesions in **medulla oblongata** can be associated with **tongue palsy (n.XII)** on one side and **contralateral hemiplegia** - **Jackson II syndrome**- **hemiplegia alternans inferior**.

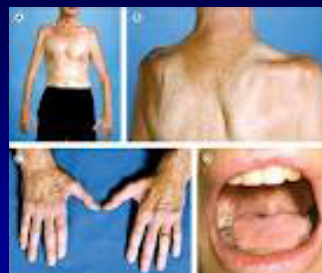The spinal cord lesion

- In **acute spinal cord diseases** with involvement of corticospinal tracts, the paralysis and weakness affects all muscles below a given level.
- C1-C4** – central lesion of UE and LE
- C5-Th2** – peripheral lesion UE, central LE
- Th2-Th11** – central lesion of LE
- Th12-L3** – peripheral lesion of LE
- In **bilateral spinal cord lesion**, the bladder and bowel and their sphincters are usually affected- **sphincter disease** (bladder incontinence)

Muscle weakness

- It is essential to establish the time- course of the symptoms.
- Recent weakness of the legs may indicate spinal cord compression (disc lesion, tumor) or demyelinating disorder (multiple sclerosis).
- Where a cord lesion is suspected, examiner is looking for sensory disturbances and bladder dysfunction.

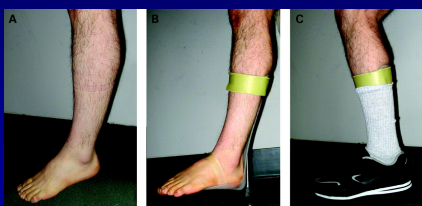
Periférna obrna



- Inervačná oblasť predných rohov miechy

Periférna obrna

- Inervačná oblasť koreňa



Periférna obrna

- Inervačná oblasť periférneho nervu

