

# Introduction to the Radiology of Fractures and Related Injuries

---

Matthew Cham  
Medical Student  
University of Rochester  
School of Medicine & Dentistry

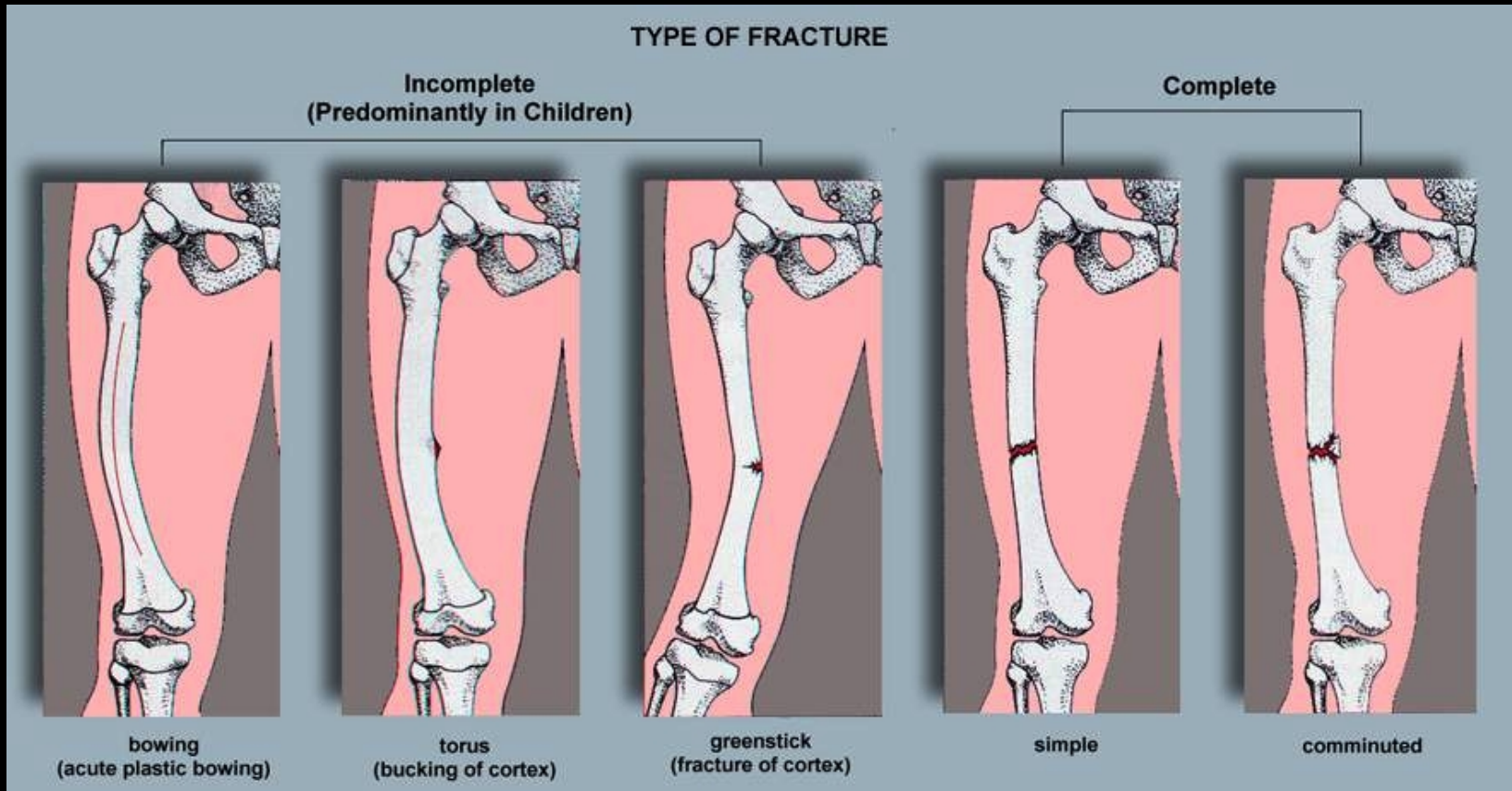
# Introduction to the Radiology of Fractures and Related Injuries

---

- ◆ Types: location and mechanisms of injury
- ◆ Classifications and grading
- ◆ Radiologic vs. Clinical features
- ◆ Variants

# Types of Fractures

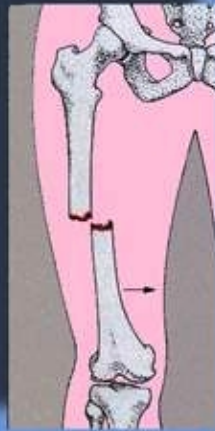## ◆ Incomplete vs Complete



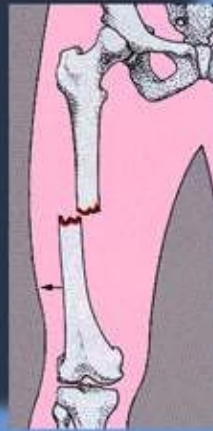# Simple Fractures

## ◆ Alignment & displacement of fragments

### ALIGNMENT OF FRAGMENTS



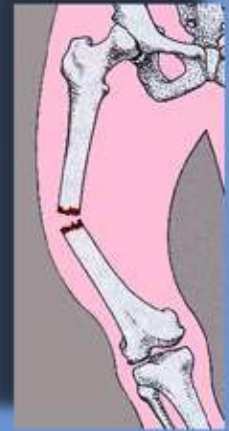medial displacement



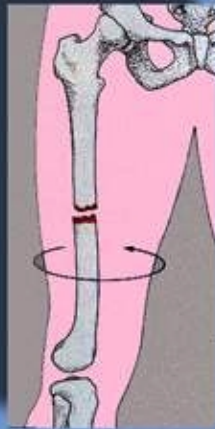
lateral displacement



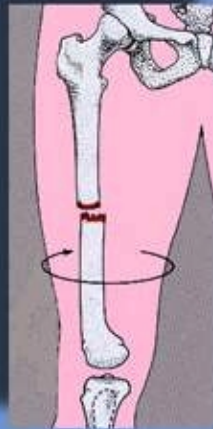
medial angulation  
(or lateral angulation of distal fragment—  
valgus configuration)



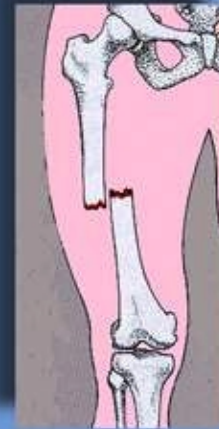lateral angulation  
(or medial angulation of distal fragment—  
varus configuration)



internal rotation



external rotation



overriding with foreshortening  
(bayonet apposition)

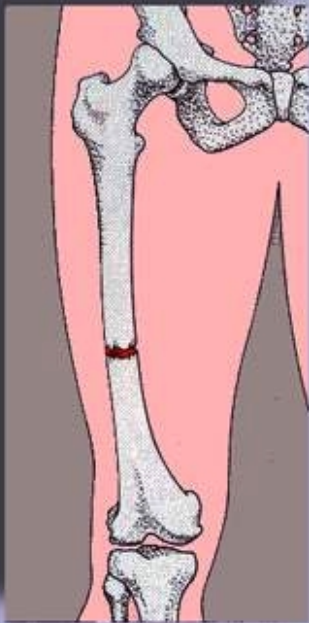


distraction

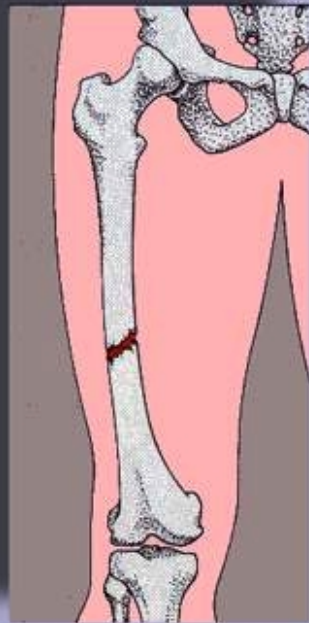
# Simple Fractures

- ◆ Directions of the fracture lines

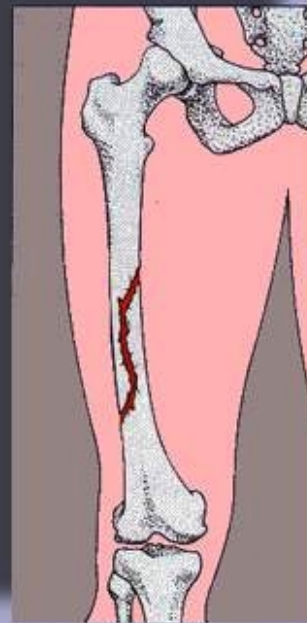
## DIRECTION OF FRACTURE LINE



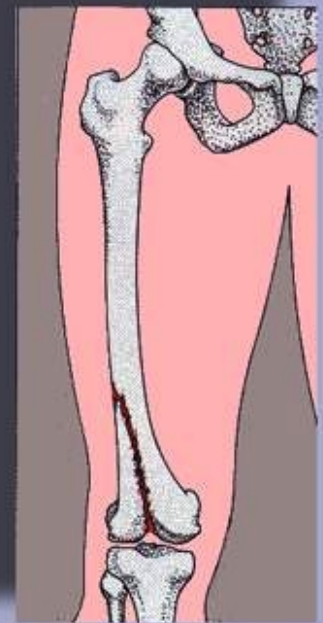
transverse



oblique



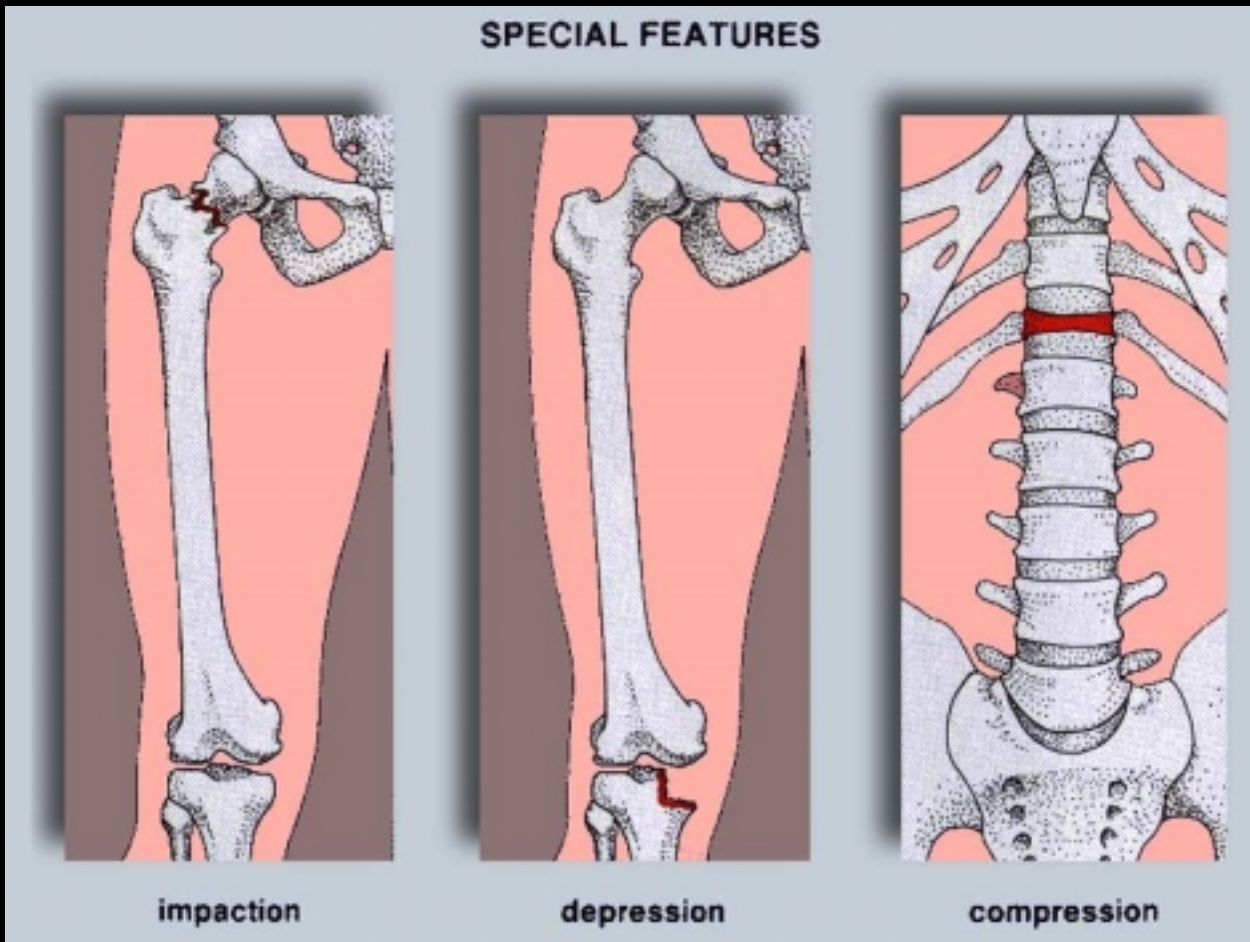
spiral



longitudinal

# Other terms: fracture line not seen

- ◆ Impaction, depression, and compression



©Greenspan 1992 IFIC4-22p.TIF

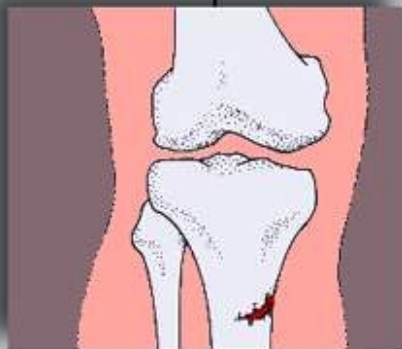# Uncommon fractures

- ◆ Stress and pathologic etiologies

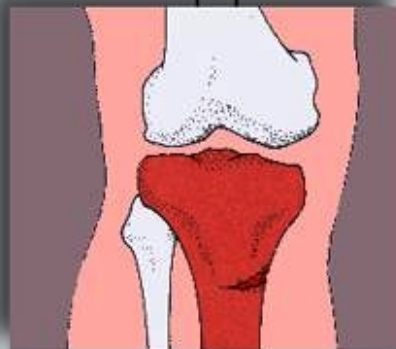## SPECIAL TYPES OF FRACTURES

Stress

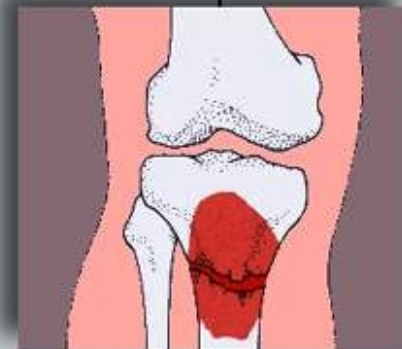
Pathologic



**fatigue**  
(normal bone,  
abnormal stress - e.g. jogging)



**insufficiency**  
(abnormal bone - e.g. osteoporotic;  
normal stress - e.g. walking)

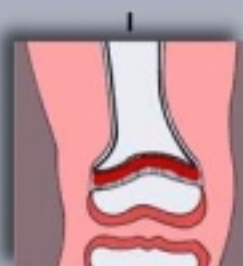

**secondary to pre-existing  
abnormality - e.g. bone tumor**

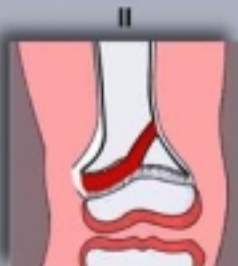# Fractures involving the growth plate

## ◆ Salter-Harris Classification

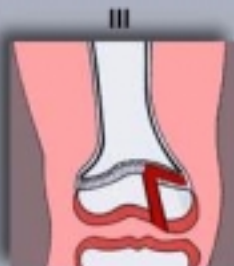### INVOLVEMENT OF THE GROWTH PLATE Salter-Harris Classification



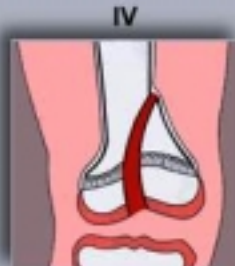I  
fracture through  
growth plate



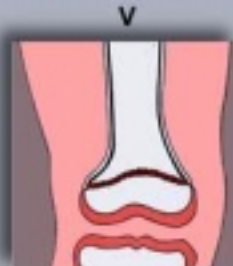II  
fracture through  
growth plate  
and metaphysis



III  
fracture through  
growth plate  
and epiphysis

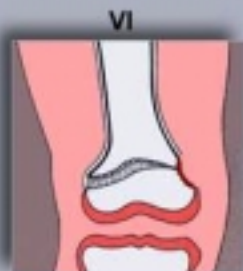

IV  
fracture through  
growth plate,  
metaphysis,  
and epiphysis

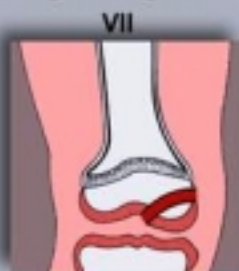

V  
compression  
fracture through  
growth plate

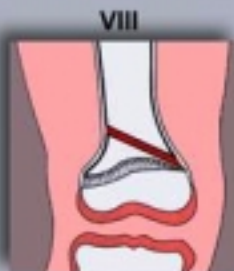### Rang and Ogden Additions to Salter-Harris



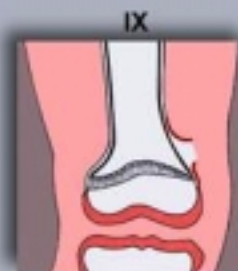VI  
trauma to  
perichondrium  
with tethering  
of growth plate  
(peripheral bridge)



VII  
epiphysis (chondral  
or osteochondral  
fracture)



VIII  
fracture of metaphysis

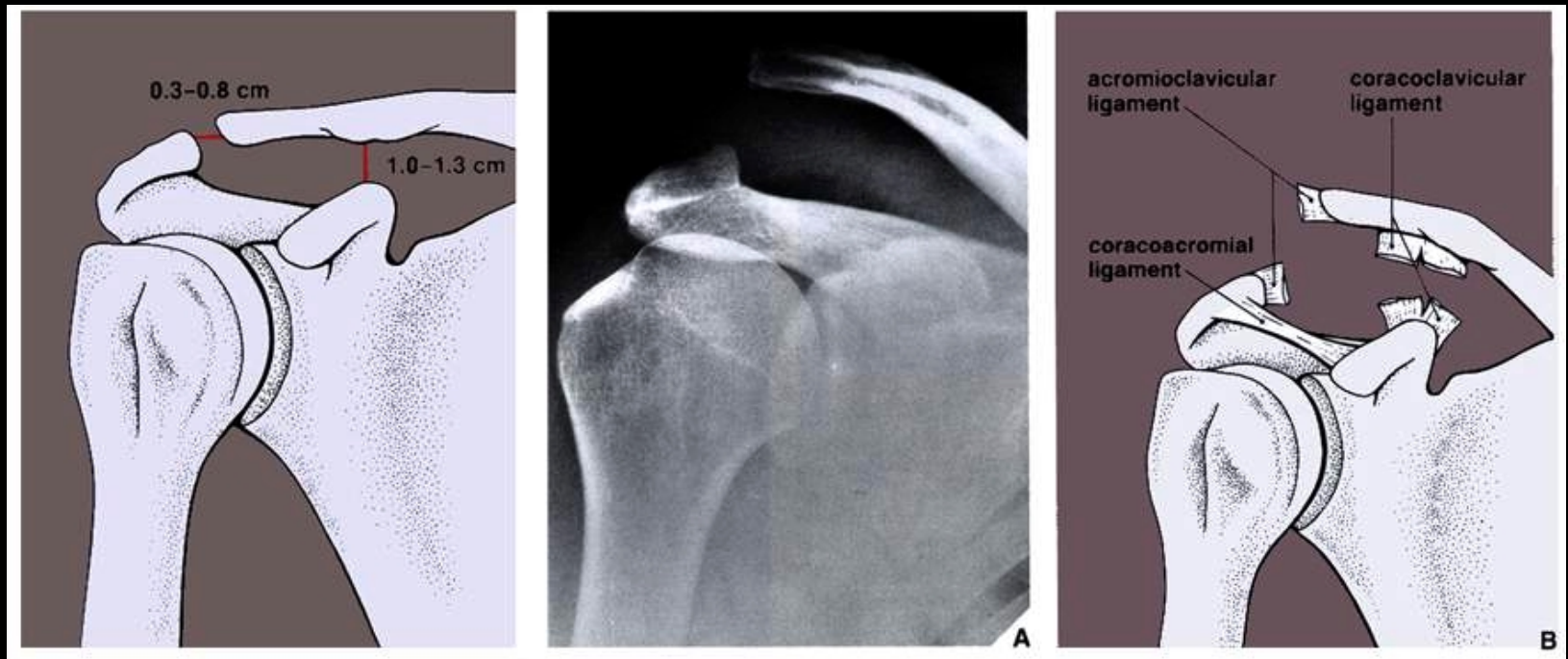


IX  
avulsion injury  
to periosteum



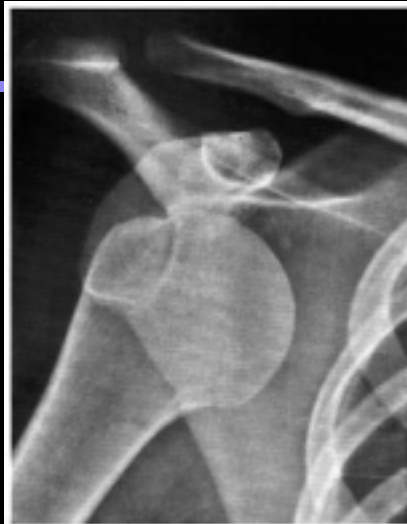# Injuries of non-articulating joints

- ◆ Acromioclavicular & coracoclavicular **separation**
- ◆ Sprain or tears in the AC and (or) CC ligaments, resulting in AC separation with inferior displacement of the scapula and extremity

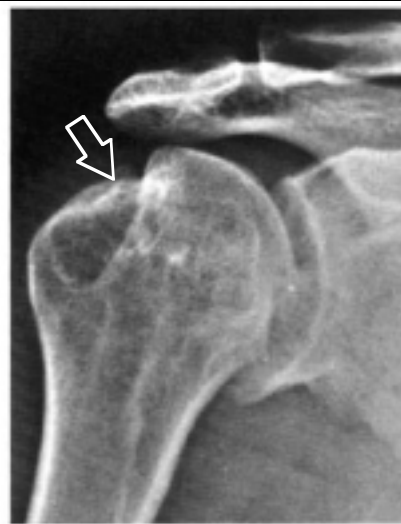

# Anterior dislocation of the humeral head

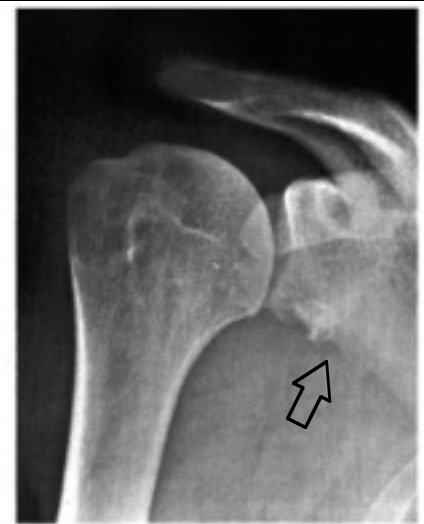- ◆ Depression fractures
- ◆ Hill-Sacks & Bankart lesions



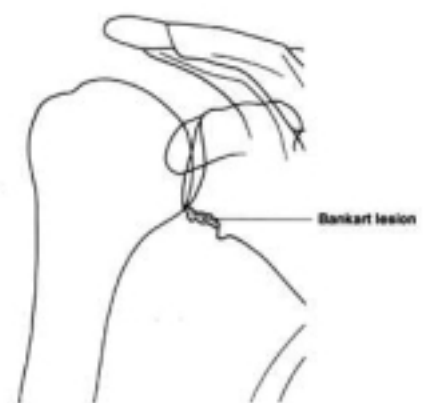
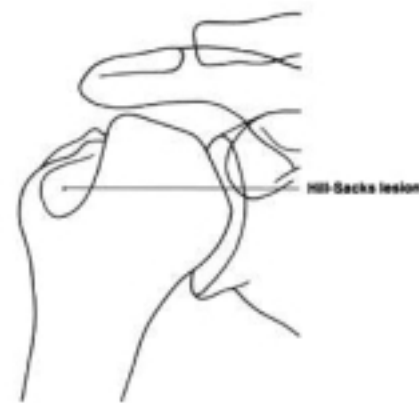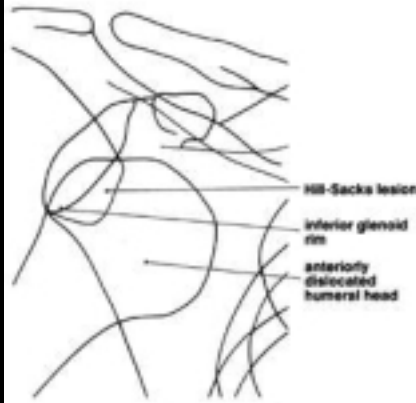**Anterior Dislocation**  
(humeral head lies beneath the inferior glenoid rim)



**Hill-Sacks Lesion**  
of the Humeral Head














**Bankart Lesion**  
(Compression Fracture of the Inferior Glenoid)











# Proximal Humeral Fractures

- ◆ Classification by location and extent of displacement

FOUR-SEGMENT CLASSIFICATION OF FRACTURES IN THE PROXIMAL HUMERUS				
Anatomic Segment	One-Part (no or minimal displacement; no or minimal angulation)	Two-Part (one segment displaced)	Three-Part (two segments displaced; one tuberosity remains in continuity with the head)	Four-Part (three segments displaced)
Any or all anatomic aspects				
Articular Segment (Anatomic Neck)				
Shaft Segment (Surgical Neck)		 impacted  unimpacted		
				
Greater Tuberosity Segment				
Lesser Tuberosity Segment				

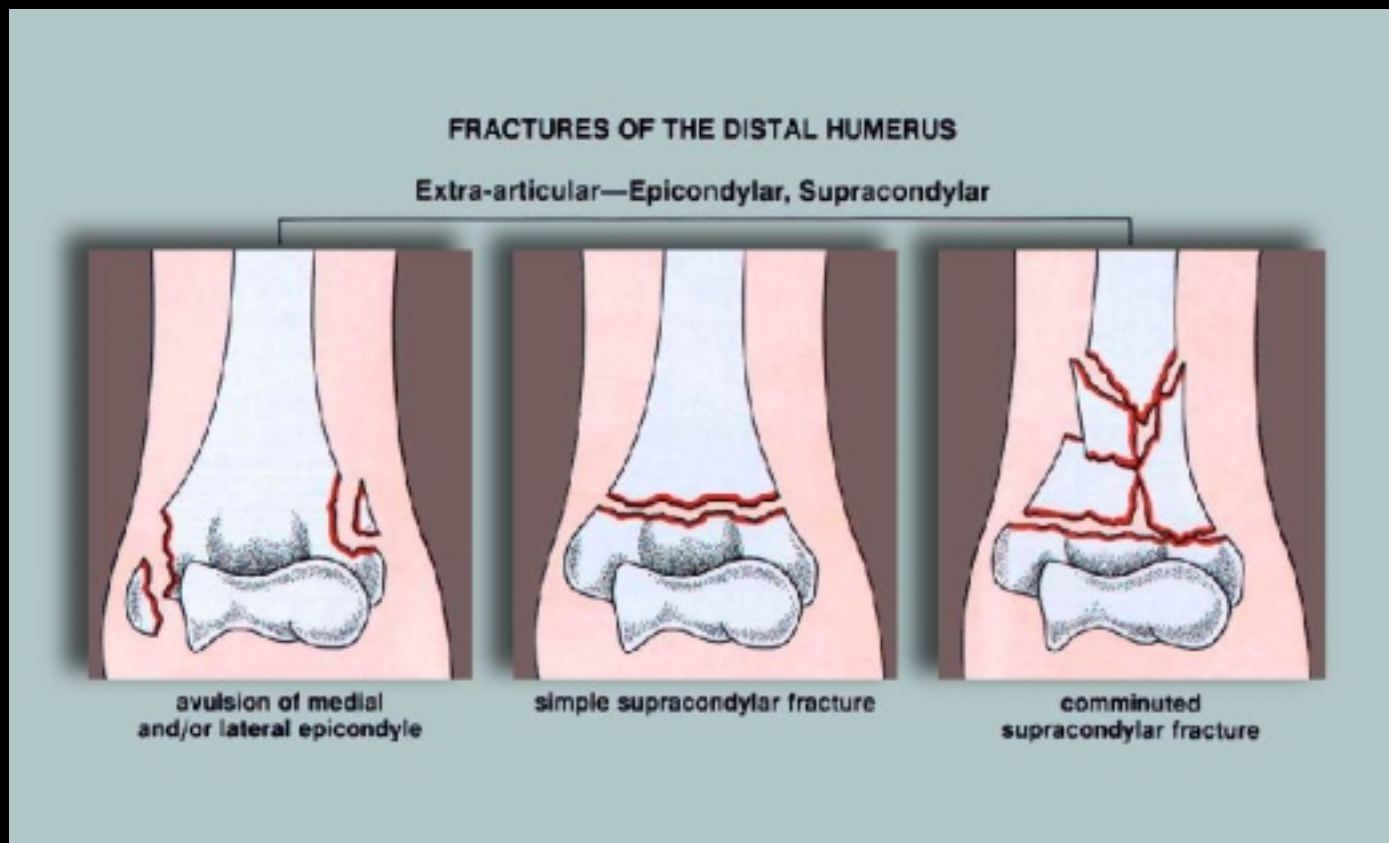
# Fracture-dislocation of the humeral head

## ◆ Classification by anatomic location and displacement

Fracture-Dislocation	Two-Part (one segment displaced)	Three-Part (two segments displaced; one tuberosity remaining in continuity with the head)	Four-Part (three segments displaced)	Articular Surface
Anterior	 <p>fracture of greater tuberosity</p>	 <p>fracture of surgical neck and greater tuberosity</p>	 <p>fracture of surgical neck and both greater and lesser tuberosity</p>	 <p>"head splitting"</p>
Posterior	 <p>fracture of lesser tuberosity</p>	 <p>fracture of surgical neck and lesser tuberosity</p>	 <p>fractures of surgical neck and both greater and lesser tuberosity</p>	 <p>"impression"</p>

# Distal Humeral Fractures

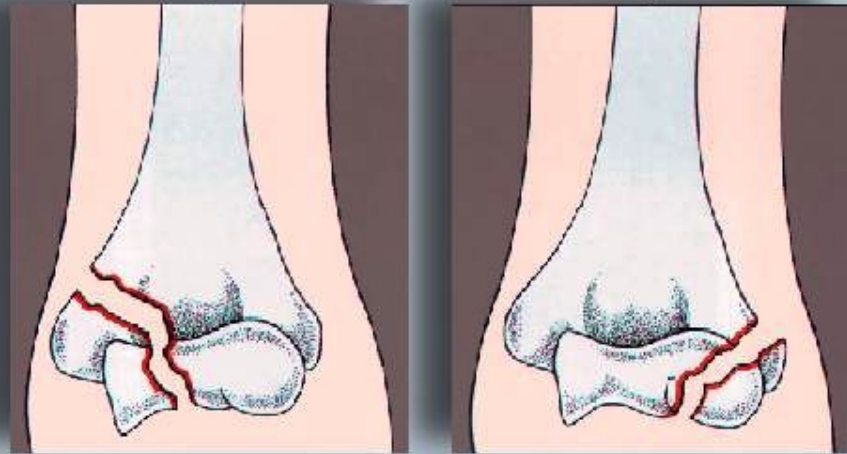
## ◆ Muller Classification of Extra-articular extension



# Distal Humeral Fractures

- ◆ Muller Classification of intra-articular extension

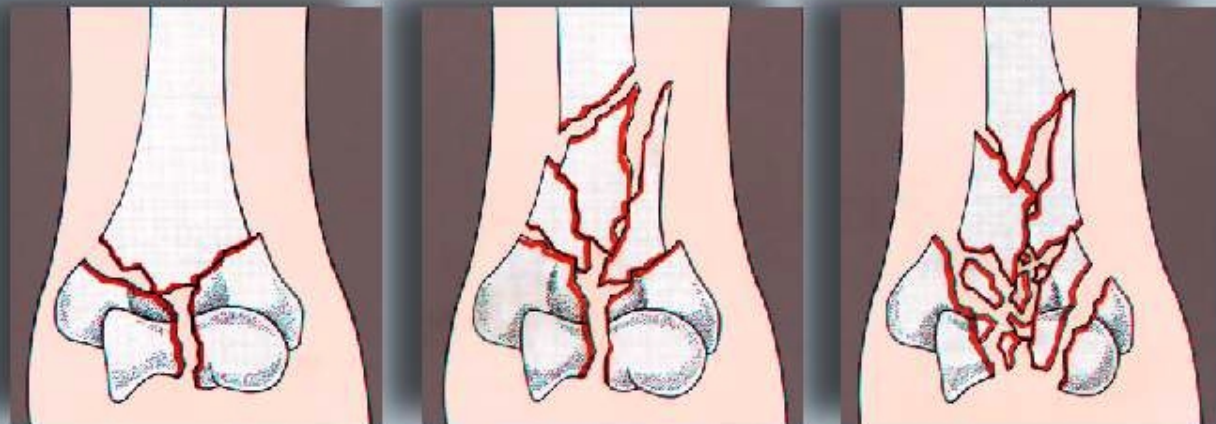
## Intra-articular: Transcondylar



fracture of trochles

fracture of capitellum

## Intra-articular: Bicondylar, Intercondylar



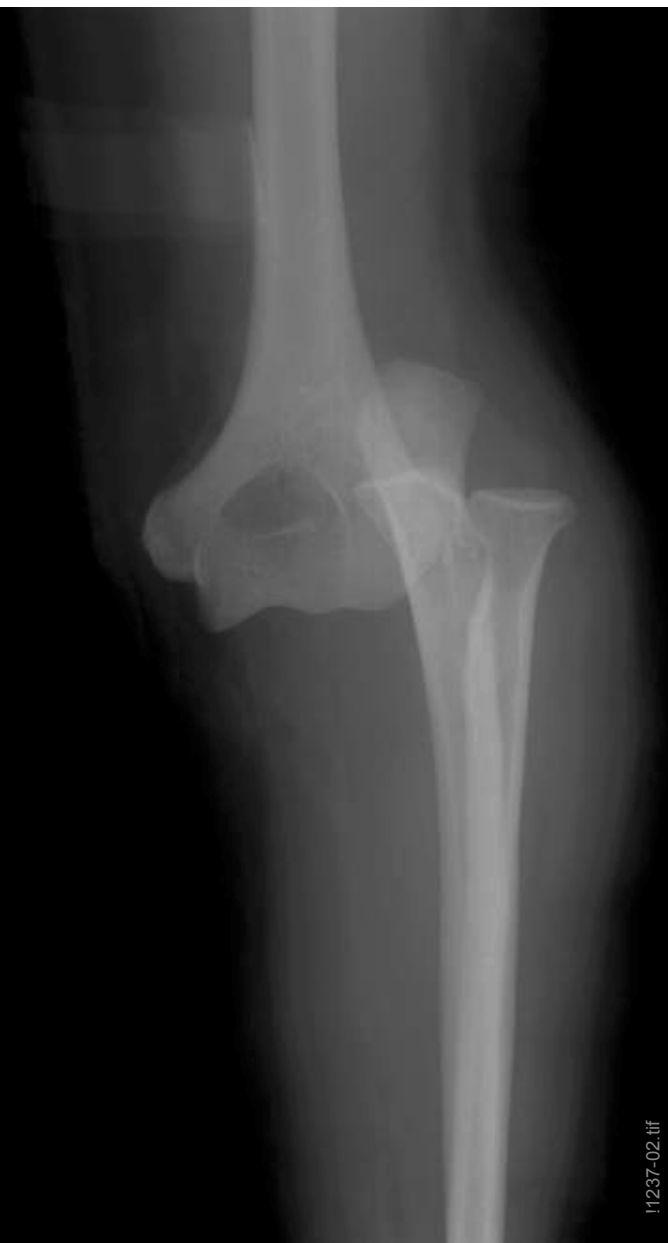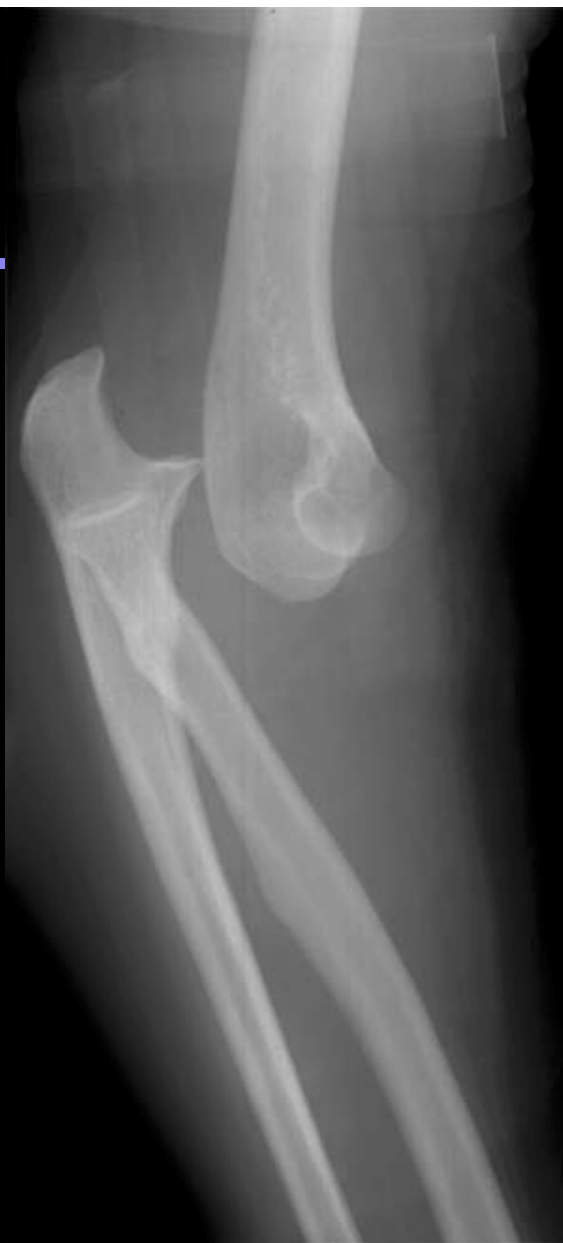Y-shaped bicondylar fracture

Y-shaped intercondylar fracture with supracondylar comminution

complex comminuted fracture

# Dislocations

- ◆ Posterior elbow



# Radial Head fracture

## ◆ Mason Classification

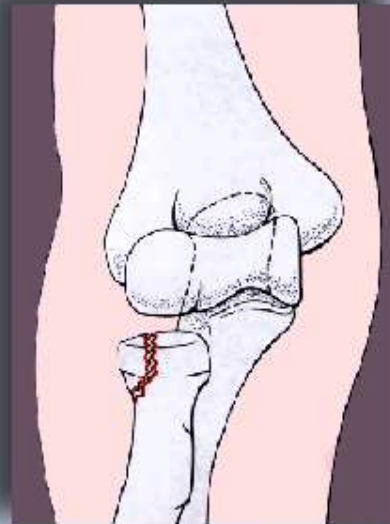
I = undisplaced

II = displaced

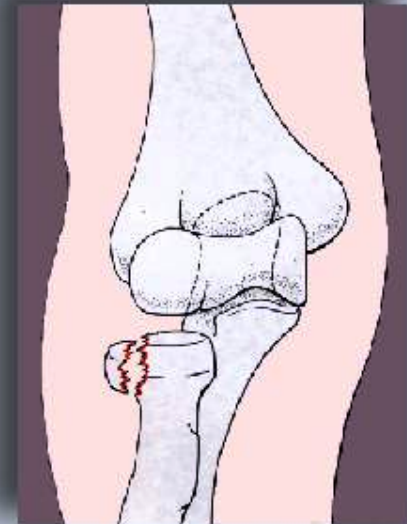III = comminuted

IV = dislocated

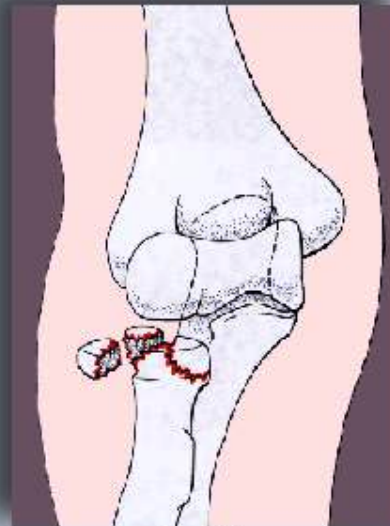
### MASON CLASSIFICATION OF FRACTURES OF THE RADIAL HEAD



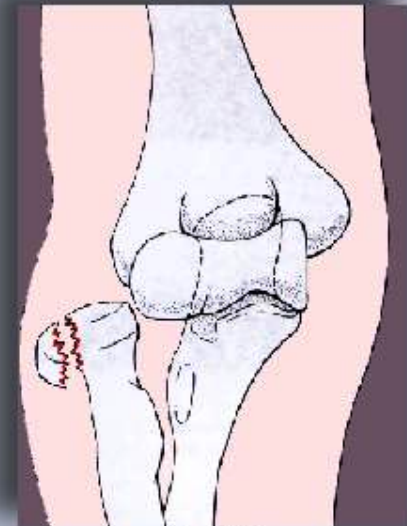Type I



Type II



Type III



Type IV



# Olecranon Fractures

## ◆ Horne-Tanzer Classification

IA = Oblique proximal 3rd

IB = Transverse proximal 3rd

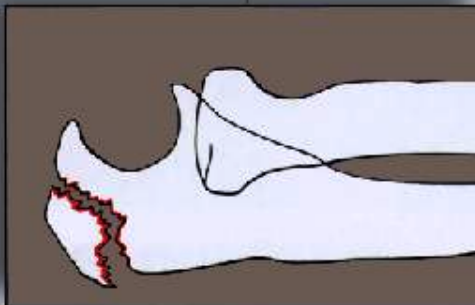
IIA = Oblique middle 3rd

IIB = Transverse middle 3rd

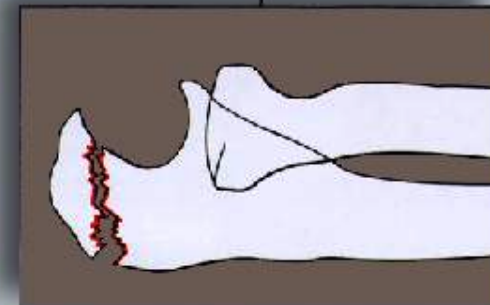
III = Oblique distal 3rd

### CLASSIFICATION OF OLECRANON FRACTURES

#### Type I

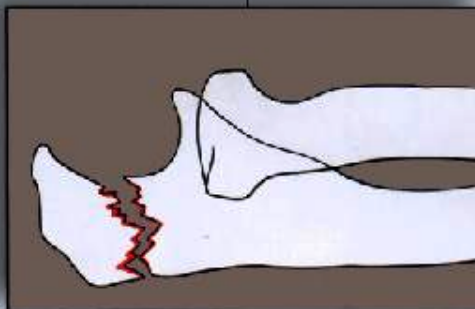


A

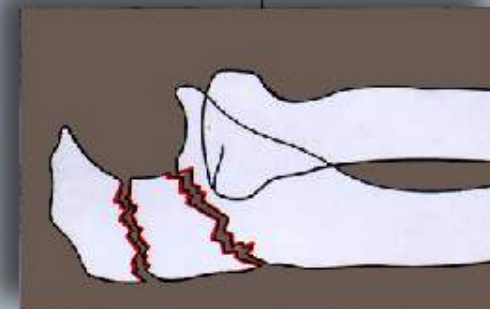


B

#### Type II

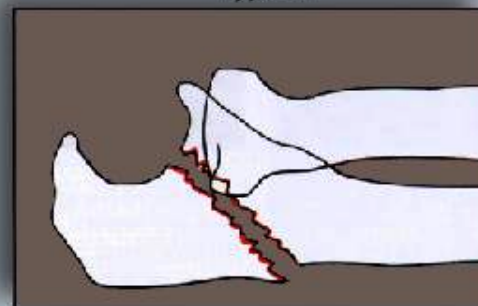


A



B

#### Type III



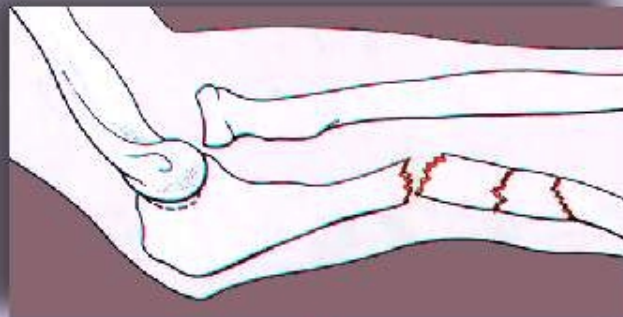
# Fractures of the forearm

## ◆ Monteggia fracture-dislocations

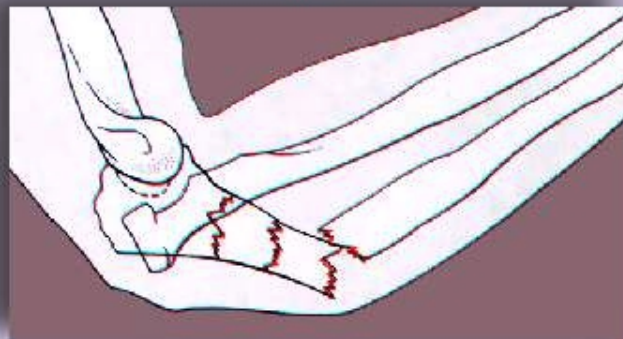
Bado classification of fractures of the proximal ulna:

- I = with anterior radial dislocation
- II = with posterior radial dislocation
- III = with lateral radial dislocation
- IV = with anterior radial dislocation and fracture

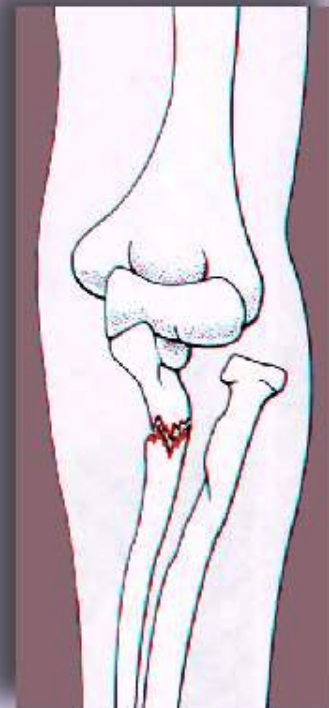
### BADO CLASSIFICATION OF MONTEGGIA FRACTURE DISLOCATION



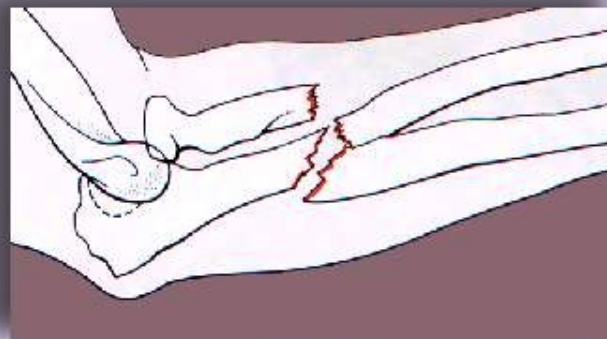
Type I



Type II



Type III



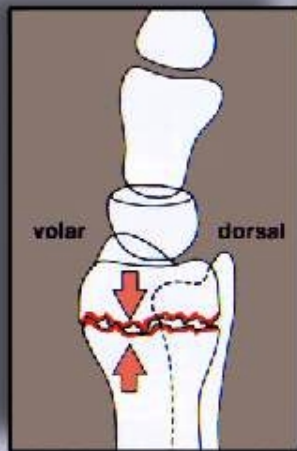
Type IV

# Fractures of the forearm

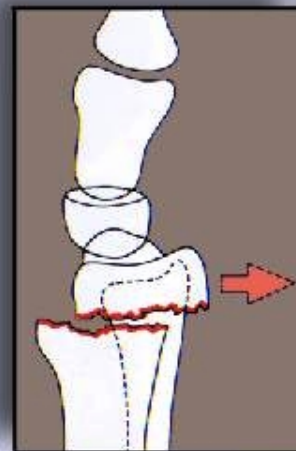
## ◆ Colles fracture

Fractures to the distal radius, usually with lateral or dorsal displacement of the distal fragment

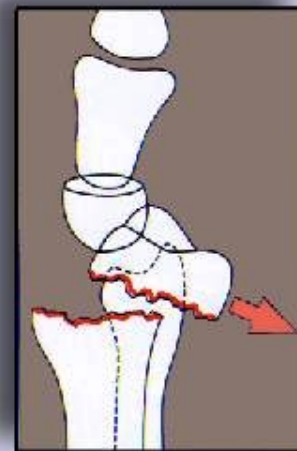COLLES FRACTURE: VARIANTS IN ALIGNMENT OF FRAGMENTS



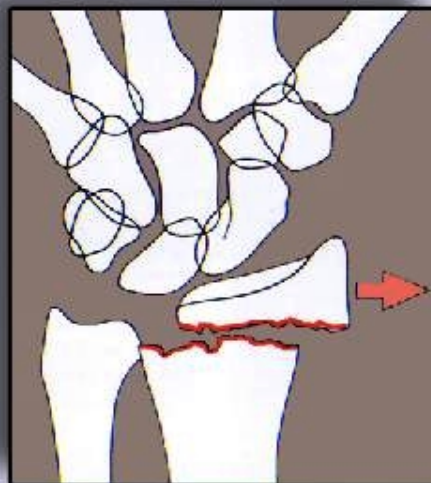
impaction without displacement



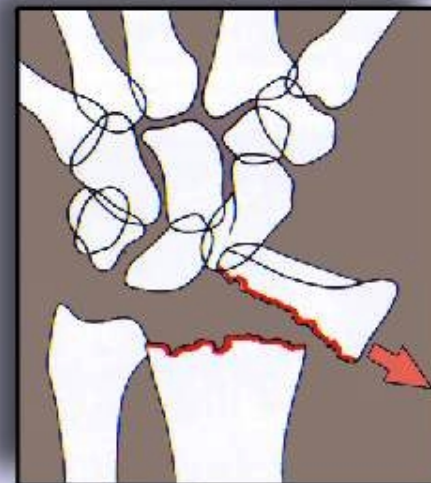
simple dorsal displacement



dorsal displacement and dorsal angulation



radial (lateral) displacement

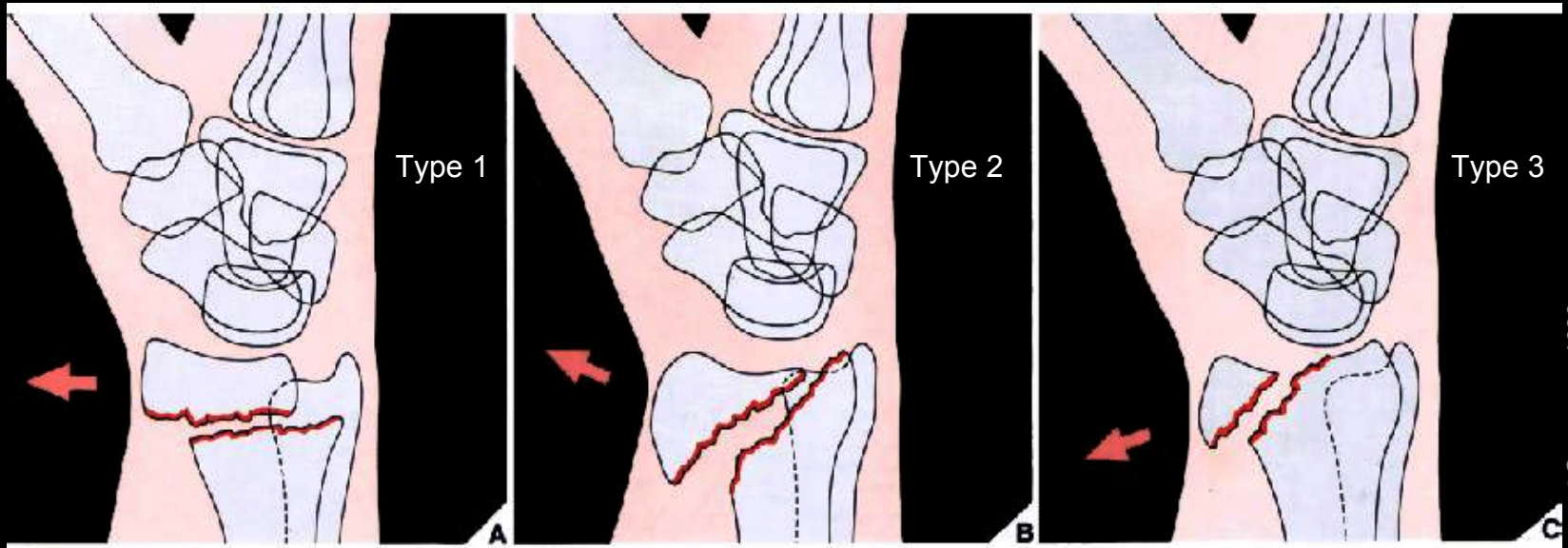


radial (lateral) displacement and radial angulation

# Fractures of the forearm

## ◆ Smith fractures (reverse Colle's fractures)

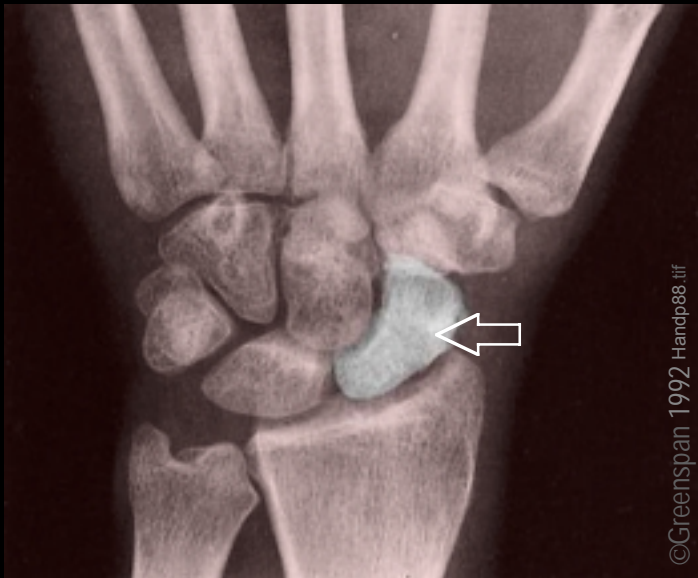
Fractures of the distal radius with volar displacement and angulation of the distal fragment



# Fractures of the wrist

## ◆ Scaphoid fractures

Second most common injury of the upper limb

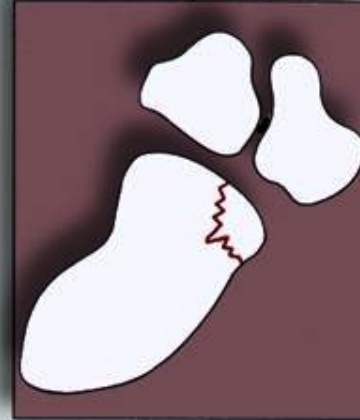


normal scaphoid bone

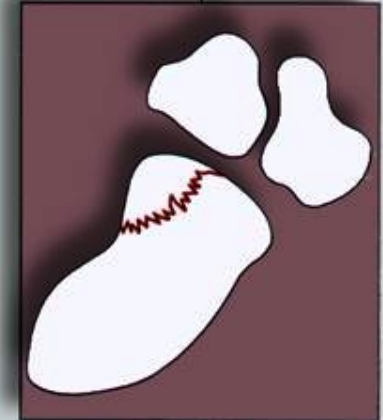©Greenspan 1992 Handp88.tif

## CLASSIFICATION OF SCAPHOID FRACTURES BY LOCATION

5%–10%

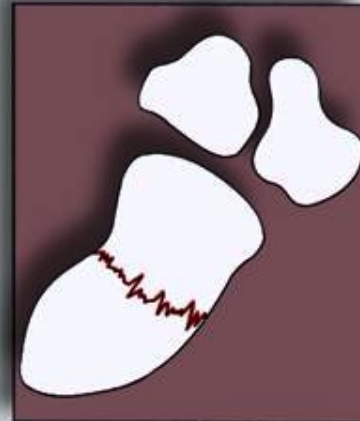

tubercle



distal pole

70%–80%



waist

15%–20%



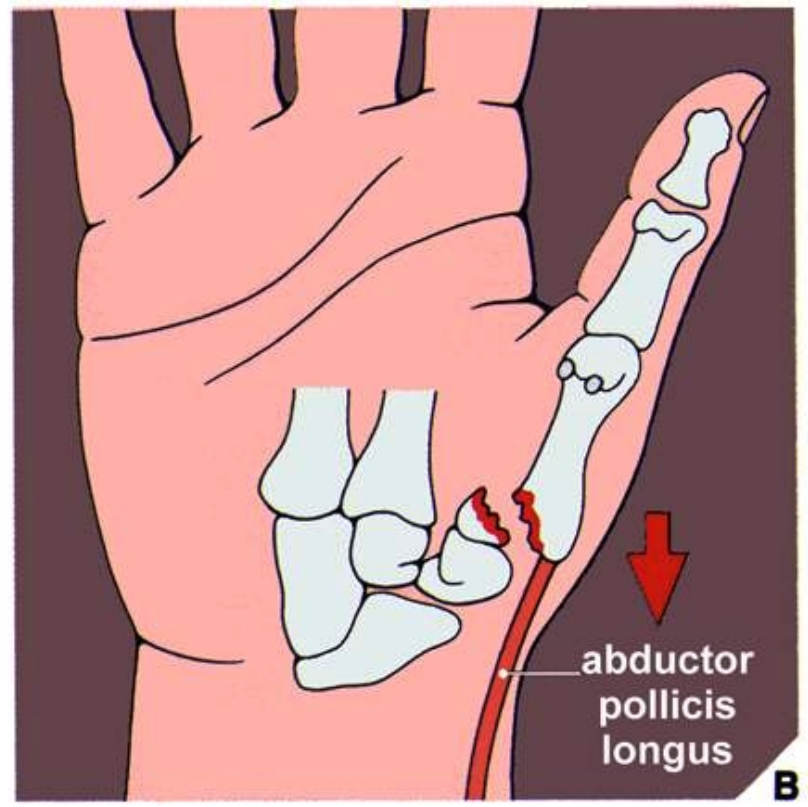
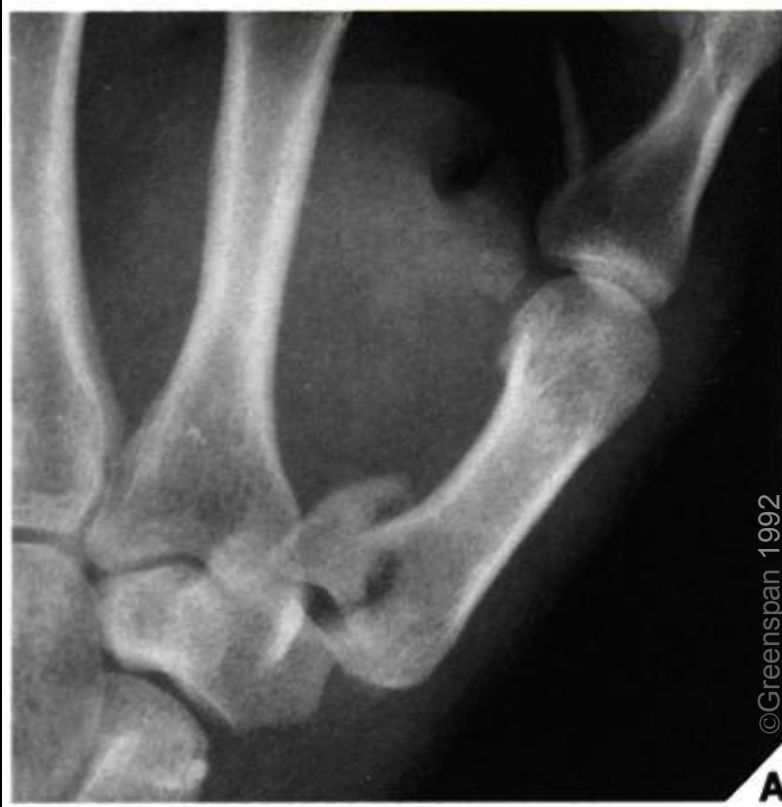proximal pole

©Greenspan 1992 IFIG6-32p.TIF

# Fractures of the hand

## ◆ Bennett fracture-dislocation

Intra-articular fracture of the proximal end of the first metacarpal, with dorsal and lateral dislocation of the distal segment.



# Fractures of the Proximal Femur

- ◆ Intra- and Extracapsular fractures

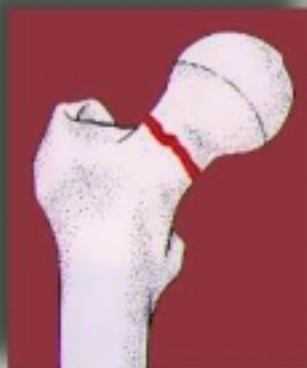## Intracapsular



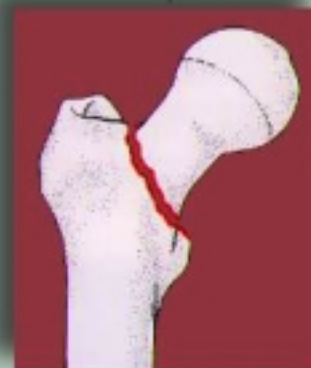capital (uncommon)



subcapital (common)

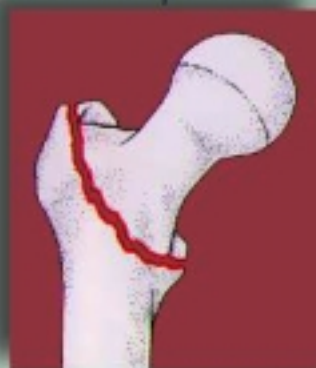

trans- or midcervical (rare)



basicervical (uncommon)

## Extracapsular



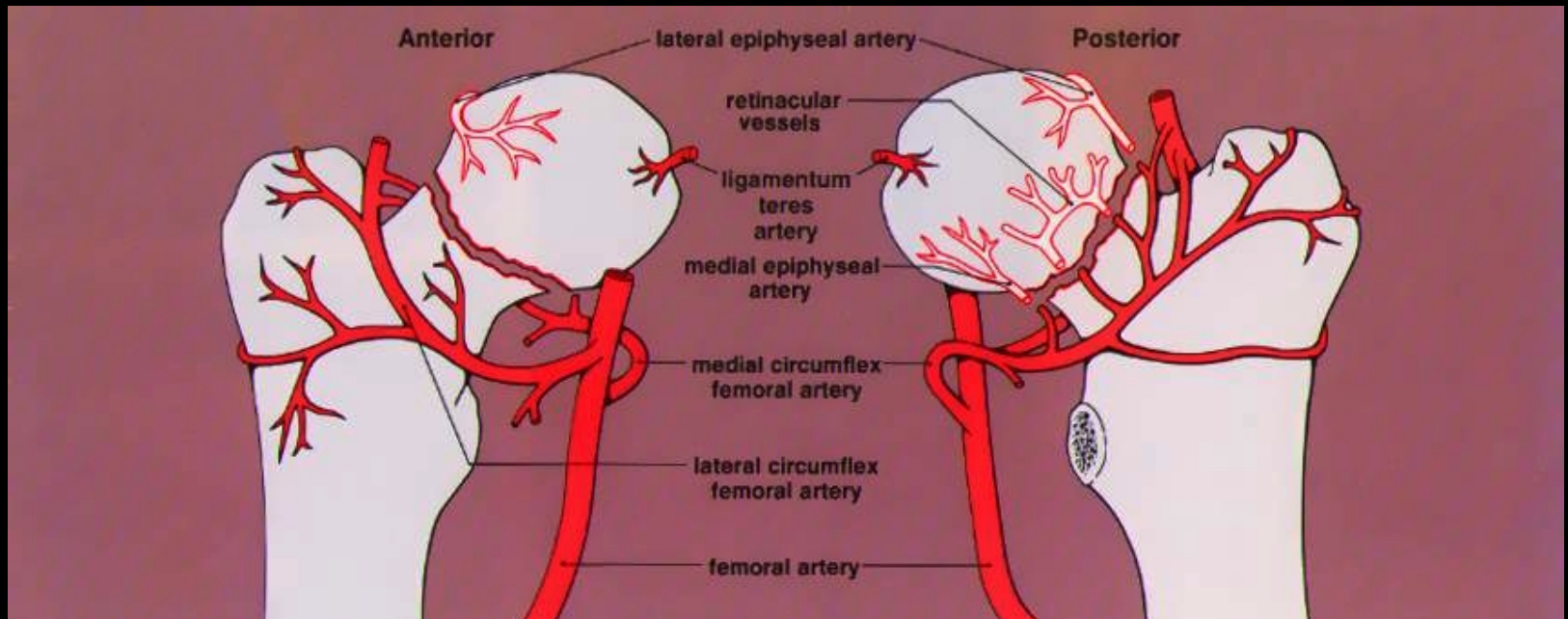
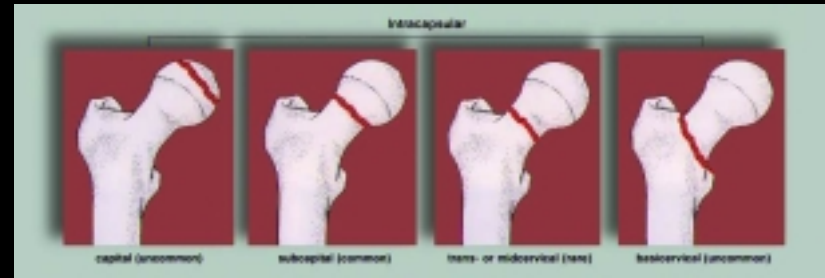intertrochanteric



subtrochanteric

# Blood supply of the femoral head

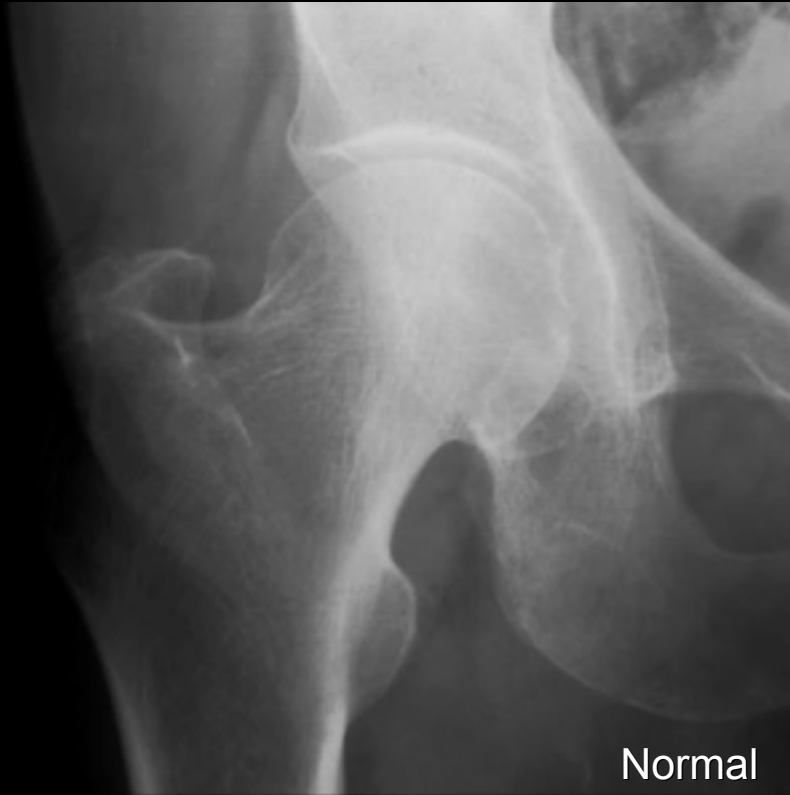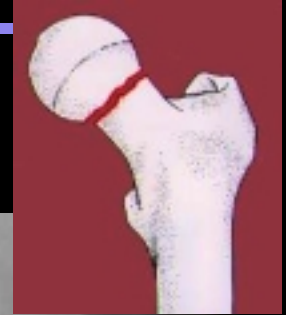- ◆ Interruption of this blood supply secondary to intracapsular fracture may lead to osteonecrosis



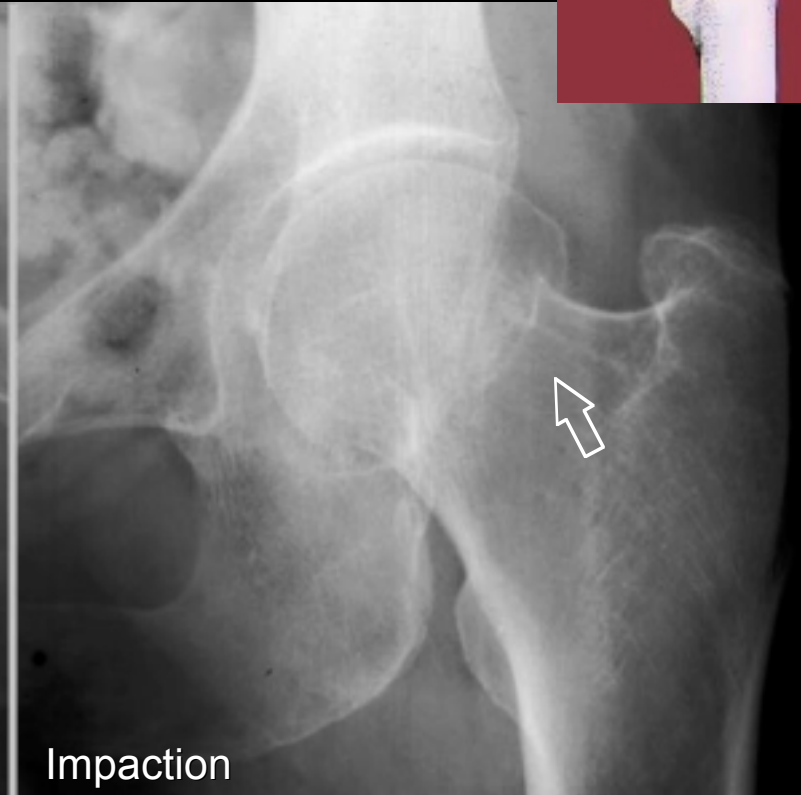

# Fractures of the Proximal Femur

- ◆ Impaction of the femoral neck into the femoral head



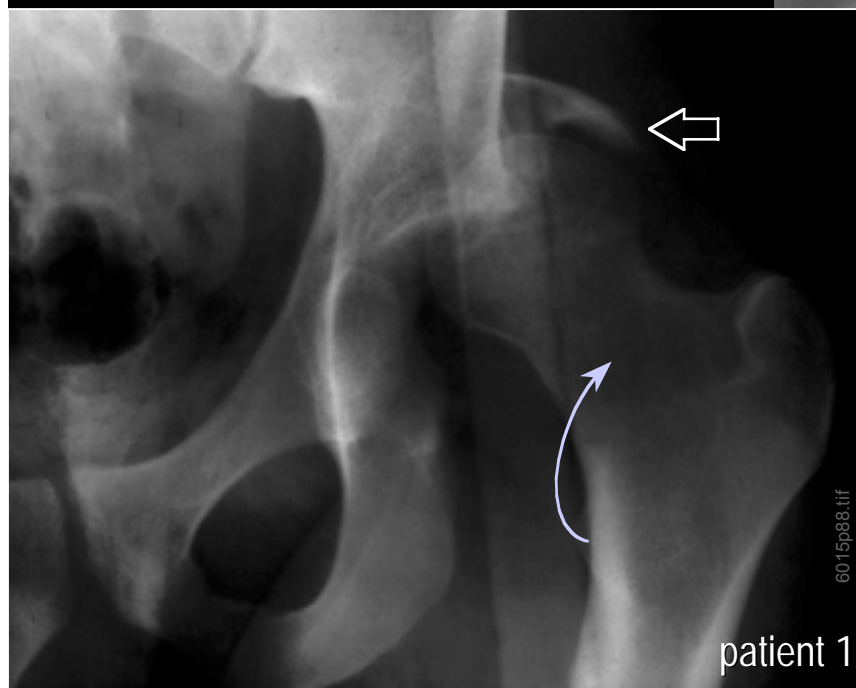
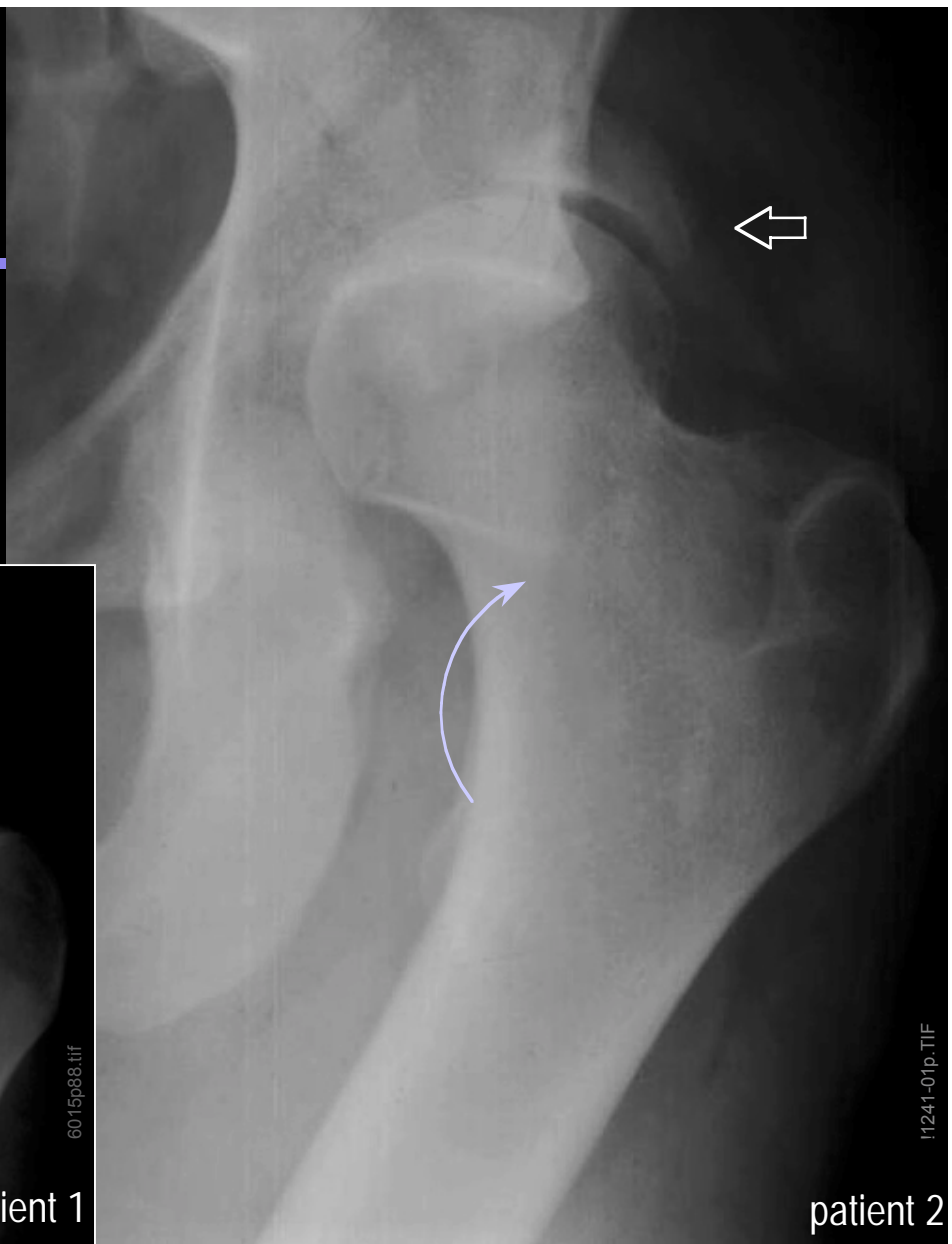Normal



Impaction

# Posterior column fx of acetabulum

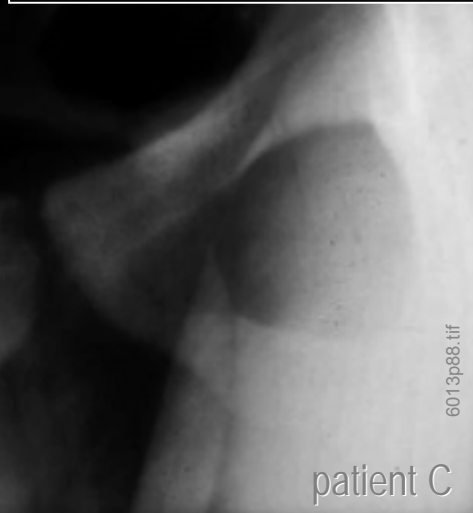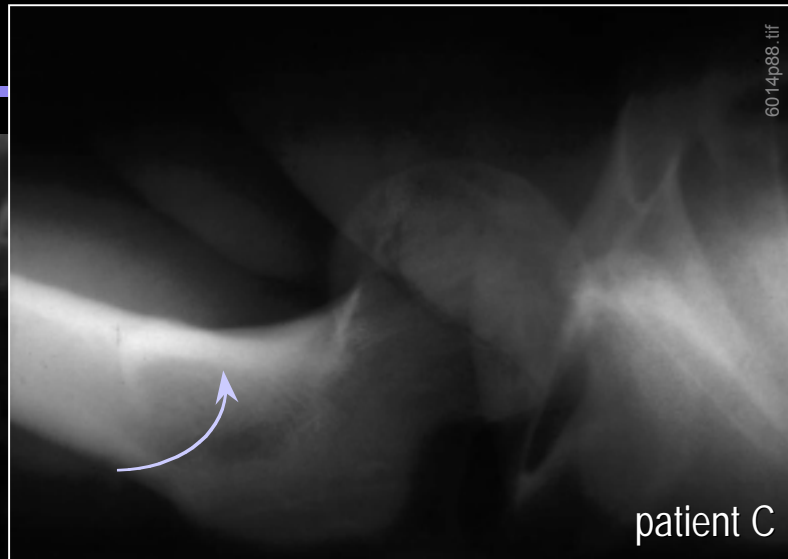
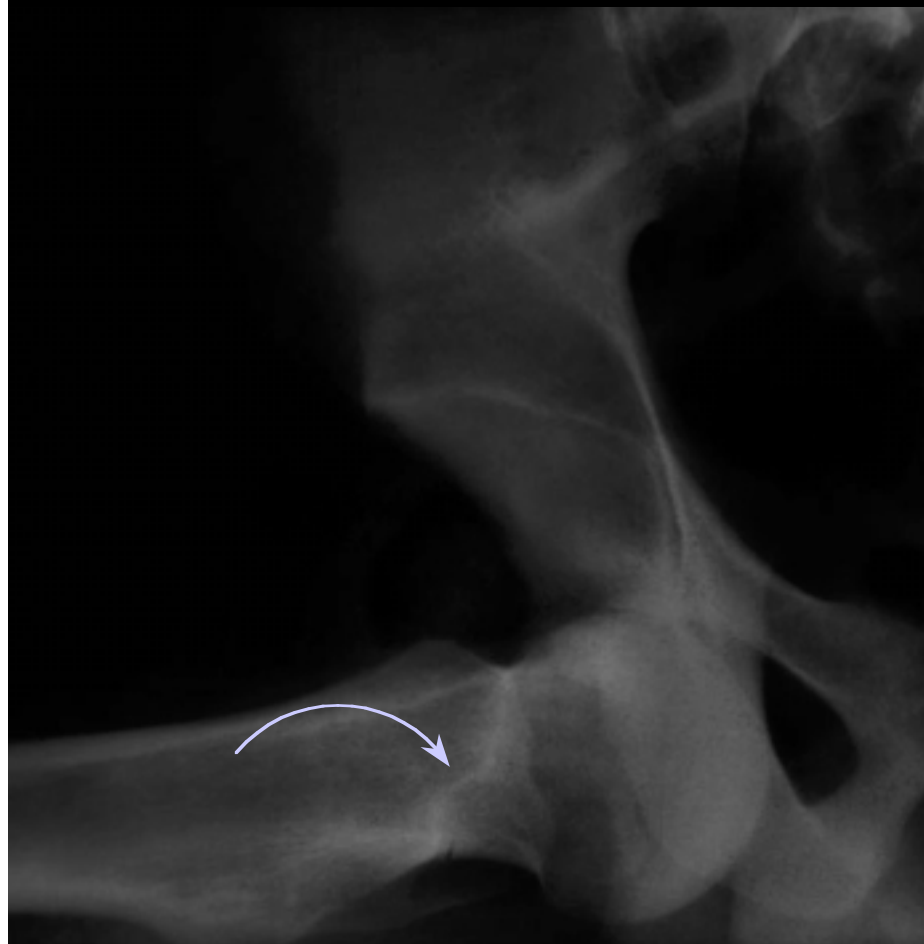- ◆ Acetabular fracture (⇐)
- ◆ Posterior dislocation of the femoral head



patient 1

patient 2

# Anterior dislocation of the femoral head



6014p88.tif

patient C

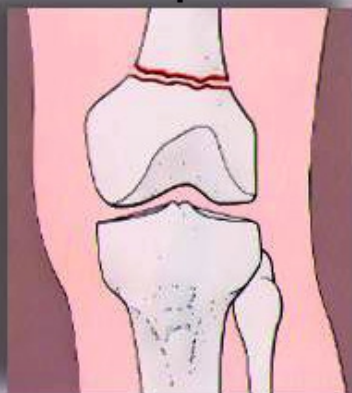
6013p88.tif

patient C

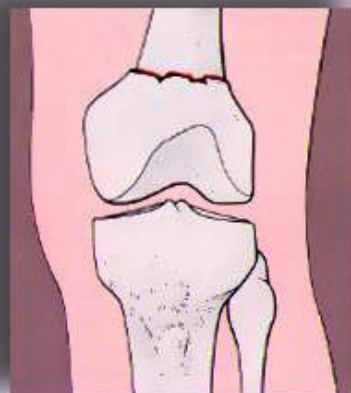
# Fractures of the distal femur

- ◆ Supracondylar, condylar, and intercondylar extension

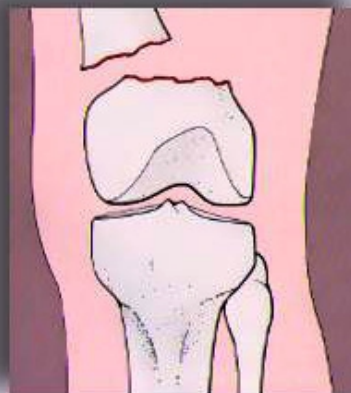
## Supracondylar



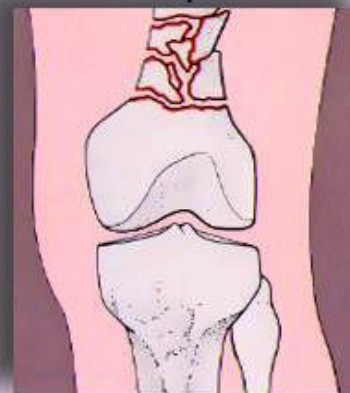
nondisplaced



impacted

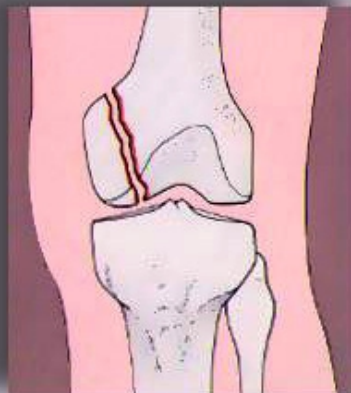


displaced

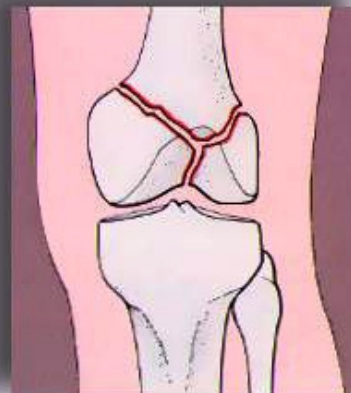


comminuted

## Condylar

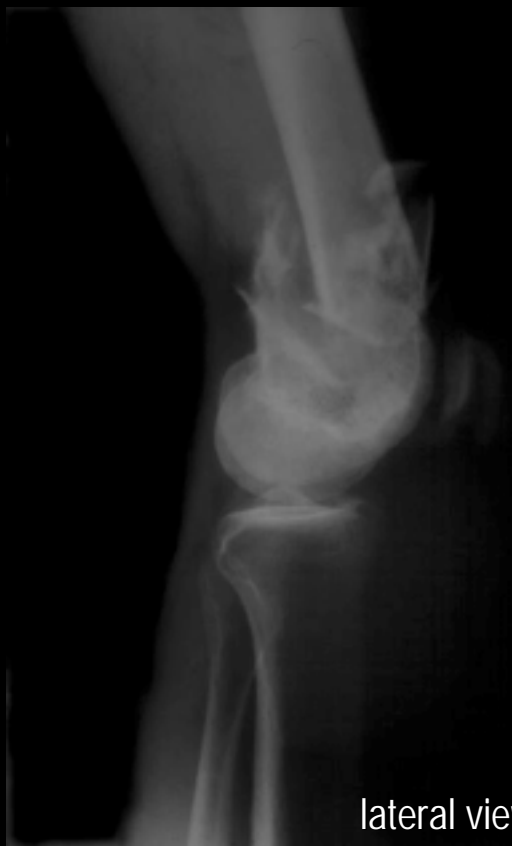

## Intercondylar



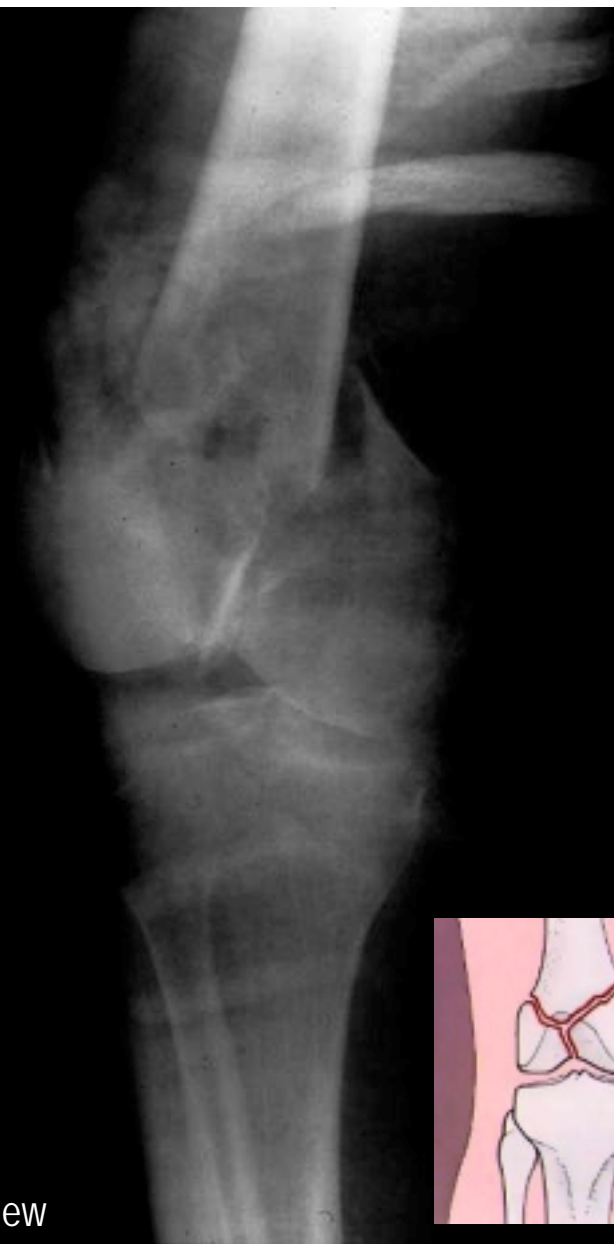# Fractures of the distal femur

- ◆ intercondylar fracture

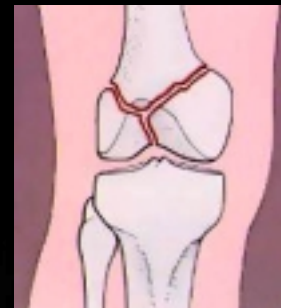


6044p88.tif

lateral view



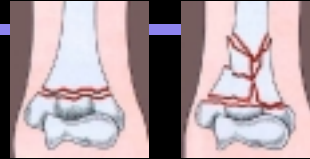AP view



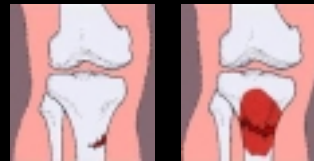©Greenspan 1992 6043p88.tif

# Summary

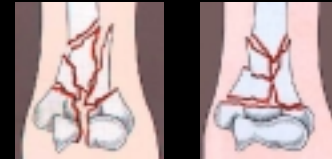- ◆ simple vs. comminuted fractures



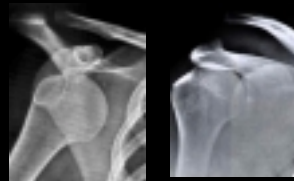- ◆ stress and pathologic fractures



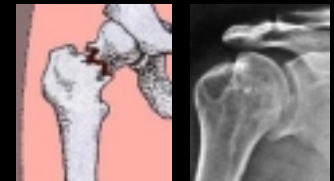- ◆ intra- vs. extra-articular involvement



- ◆ dislocation vs. separation



- ◆ depression fractures and associated lesions



- ◆ effects of fractures on blood supply

