

UT Southwestern Department of Radiology

Ultrasound – Renal Transplant Protocol

PURPOSE:

To evaluate the parenchyma and vasculature associated with the renal transplant for structural or vascular pathology.

SCOPE:

Applies to all ultrasound renal transplant studies performed in Imaging Services / Radiology

EPIC ORDERABLE:

- UTSW: US Doppler Kidney Transplant
- PHS: US Renal Transplant
- If a native kidney evaluation is also requested, it is performed under a separate order. Please refer to that exam's protocol of acquisition details.
 - UTSW: US Renal Complete
 - PHS: US Renal

INDICATIONS:

- Presence of a renal transplant with:
 - Immediate post-operative status, to establish baseline;
 - Signs (hypertension, renal failure) or symptoms (pain) associated with renal disease or transplant rejection;
 - Abnormal lab values (increased Cr, etc);
 - Suspicion for vascular complication (stenosis; thrombosis);
 - Suspicion for follow up of known fluid collection;
 - Suspicion for hydronephrosis;
 - Clinical findings such as pain, fever, sepsis, hematuria, etc.
 - Abnormal findings on other imaging studies

CONTRAINDICATIONS:

- No absolute contraindications

EQUIPMENT:

- Linear transducer with a frequency range of 2-18 MHz that allows for optimal penetration and resolution depending on patient's body habitus

PATIENT PREPARATION:

- Patient should be well hydrated.

EXAMINATION:

GENERAL GUIDELINES:

A complete examination includes evaluation of:

- The main renal artery and branches (including interlobar).
- The main renal vein and branches (including interlobar).
- Additional image acquisition protocols based on orderable (above)

EXAM INITIATION:

- Introduce yourself to the patient and explain test
- Verify patient identity using patient name and DOB
- Obtain patient history including symptoms. Enter and store in data page
- Place patient in supine position. Right or left lateral decubitus (RLD, LLD) positioning may be required.

TECHNICAL CONSIDERATIONS:

- Review any prior imaging, making note of abnormalities, prior velocity measurements, or other findings requiring further evaluation.
- Review surgical history and reconstruction technique. Make note if multiple renal anastomoses are present.
- For longitudinal renal images, include images without and with measurements
- Optimize gain and display setting with respect to depth, dynamic range, and focal zones on grey scale imaging first
- Optimize color Doppler setting to show optimal flow:
 - Adjust scale and gain to maximally fill the vessel of interest without artifacts
 - Uniform color with the lighter one in the middle of the vessel lumen
 - If “color bleed” occurs, turn down the color gain setting.
 - Use Power Doppler if flow is not seen using the regular color Doppler
 - Look for a stenotic jet (i.e. aliasing) and/or post-stenotic turbulence.
 - In severe stenosis, a soft tissue color “bruit” may be present
- Optimizing spectral Doppler:
 - Place time-gate centrally within the vessel of interest
 - Adjust scale to extend spectral waveform (amplitude adequate for interpretation)
 - Eliminate aliasing for high flow evaluation (i.e. increase velocity range and/or decrease the base line)
- As much as possible, utilize angle correction of $\leq 60^\circ$ to measure velocities
 - Angle correction should always be parallel to the vessel wall
 - For certain anatomy, may need to try from different approaches to optimize angle
- Evaluate the external iliac artery proximal to, at, and distal to the anastomosis.
- Renal Arteries:
 - Using color Doppler, survey the iliac artery for multiple renal arteries.
 - Obtain spectral Doppler velocity measurements of the main renal artery at the anastomosis, proximal, mid, and renal hilum.
 - If a stenosis is identified on color Doppler (often in area of color aliasing), measure the peak systolic velocity (with **angle correction**).
 - The majority of renal artery stenosis occurs at the anastomosis.
 - Obtain the Acceleration Time (AT) and Acceleration Index (AI) of the interlobar arteries in the upper pole, mid segment and lower pole. Several waveforms may be needed to obtain an optimal waveform for accurate AT and AI measurements. **Be patient!**
 - Choose a waveform that clearly shows an early systolic peak (ESP)
 - Beware of ESP variants (see “Renal Doppler Complete” protocol)
- Using color Doppler, survey the entire main renal vein for thrombus.
- Investigate any renal transplant with hematuria with color Doppler for arterial-venous fistula (AVF).

UT Southwestern Department of Radiology

- AV fistula is a common complication of renal biopsy, hence most commonly seen in the lower pole. On color Doppler, look for abnormally high flow - aliasing in the interlobar artery, and high-velocity, pulsatile flow in the draining vein compared to other vessels.
- Look for a “color bruit” or “color thrill” indicating the presence of turbulent, high flow, that may be present in an AV fistula.
- If a cystic structure is seen, use color Doppler to exclude a pseudoaneurysm, another vascular complication of renal biopsy.
- Scan all the way through the soft tissues between the transplant kidney and the bladder.
 - Assess for fluid collections. If seen, include images indicating size and location.
- During evaluation of the bladder, assess for urinary stent.
 - If seen, annotate on image.

IMAGE DOCUMENTATION:

For en bloc renal transplant, the following images/measurements are needed for each kidney. Label kidneys “medial” and “lateral”, or “#1” and “#2”, being consistent with prior imaging.

Anatomy	Grey Scale	Color Doppler	Waveform	PSV	RI	SAT	eSAI
Longitudinal TX kidney: medial	x						
*Longitudinal TX kidney: middle	*x						
Longitudinal TX kidney: lateral	x						
Transverse TX kidney: upper pole	x						
Transverse TX kidney: mid upper	x						
Transverse TX kidney: middle	x						
Transverse TX kidney: mid lower	x						
Transverse TX kidney: lower pole	x						
^TX Renal artery: origin	x	x	x	x			
^TX Renal artery: proximal	x	x	x	x			
^TX Renal artery: middle	x	x	x	x			
^TX Renal artery: distal	x	x	x	x			
TX Interlobar artery: upper pole	x	x	x		x	+x	x
TX Interlobar artery: middle pole	x	x	x		x	+x	x
TX Interlobar artery: lower pole	x	x	x		x	+x	x
TX Renal vein	x	x	x				
Iliac artery: proximal to anastomosis	x	x	x	x			
Iliac artery: at anastomosis	x	x					
Iliac artery: distal to anastomosis	x	x	x	x			
Survey collecting system for hydro	x	x					
Longitudinal bladder	x++						
Transverse bladder	x++						
Survey of perinephric space	x						
Data page with measurements							
*Include one image with length measurement and one without.							
^for multiple renal arteries, measurements should be repeated for each artery.							
++ obtain multiple longitudinal and transverse images of the bladder as per Renal Protocol.							
PSV = peak systolic velocity, RI = resistive index, SAT = systolic acceleration time, eSAT = early systolic peak acceleration time, eSAI = early systolic peak acceleration index, TX = transplant							

UT Southwestern Department of Radiology

PROCESSING:

- Review examination data
- Export all images to PACS
- Confirm data Imorgon (where applicable)
- Note any study limitations (in PACS or Epic Study Note, or Imorgon, per local workflow)

REFERENCES:

- Rad 1989;172(3,2):1027-30
- Acta Radiologica 1994;36(6):586-9
- Rad 1993;189(3):779-87
- IAME: Ultrasound Evaluation of Renal Transplant (MT Heller)
- Nephrol Dial Transplant 2003;18-1401-1404
- Clinical Radiology (2003) 58: 770–771
- AIUM Practice Parameters for the Performance of an Ultrasound Examination of Solid-Organ Transplants, 2020 Update, <https://doi.org/10.1002/jum.15261>

CHANGE HISTORY:

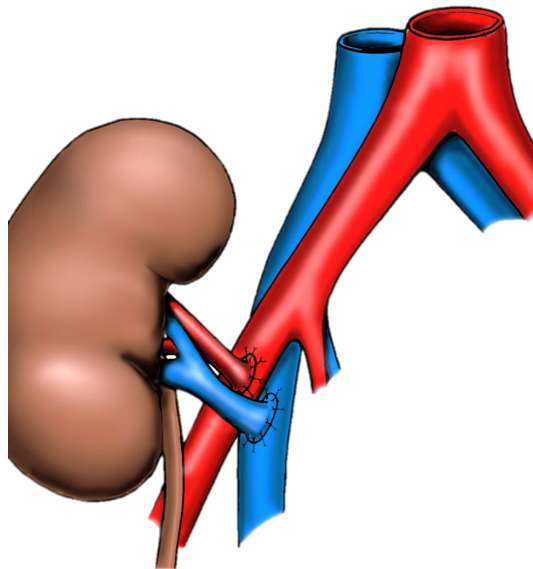
STATUS	NAME & TITLE	DATE	BRIEF SUMMARY
Submission	David Fetzer, MD, Director	11/25/2015	Submitted
Approval	David Fetzer, MD, Director	1/31/2016	Approved
Review	Anthony Setiawan, MD	11-14-2018	Reviewed
Revisions	David Fetzer, MD	07/25/2016	Segmental renal artery waveform descriptions
	David Fetzer, MD	05-31-2020	Updates based on 2020 AIUM Practice Parameters update

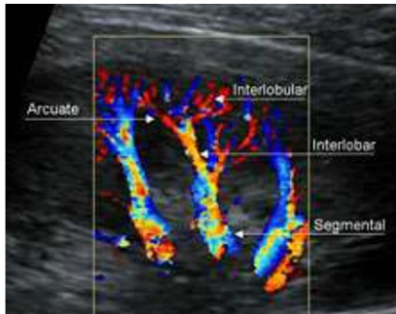
APPENDIX:

- Transplant Kidney Intrarenal Measurements
 - RI 0.6 – 0.7 Normal range
 - >0.8 Elevated (increased vascular resistance)
 - <0.5 – 0.6 Suspicious for renal artery stenosis

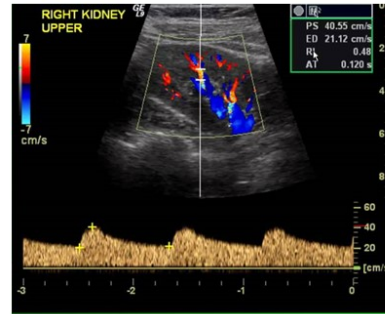
- Criteria for Severe (60-80%) Renal Artery Stenosis
 - SAT >0.07 sec
 - SAI <300 cm/sec²
 - PSV >200 cm/sec (150-300 cm/sec)
 - Post stenotic turbulence (color Doppler) and spectral broadening distal to stenosis
 - Consider >300 cm/sec for initial post surgery, then >250 cm/sec for surveillance
 - RA/IA ratio 2 PSV of Iliac Artery (IA) at Renal Artery (RA) anastomosis
 - RI <0.5 Not a primary criteria
 - AI (acceleration index) < 300 cm/sec²

- Renal Transplant:
 - Extraperitoneal, usually RLQ
 - Arterial Anastomosis:
 - End-to-side Renal Artery to External Iliac Artery
 - Carrell patch
 - End-to-end Renal Artery to Internal Iliac Artery
 - Living-related TX
 - Venous Anastomosis
 - End-to-side Renal Vein to External Iliac Vein





Goal is to obtain “segmental” waveforms from distal segmental, proximal interlobar arteries, at approximately the level of artery insertion into the renal cortex



- + Acceleration Time, measured from systolic inflexion point to first systolic peak (ESP, early systolic peak)
- + RI, measured from highest systolic peak to lowest diastole

