

## Systemic Lupus Erythematosus Choroidopathy

Lucia Sobrin, MD and C. Stephen Foster, MD

### Case Presentation

A 36-year old woman presented with a dark spot in her right eye for one week. She had a history of systemic lupus erythematosus (SLE) diagnosed on the basis of ANA positivity with a 1:320 titer, joint swelling, butterfly rash, idiopathic thrombocytopenic purpura and anti-phospholipid syndrome with positive anti-cardiolipin antibodies. She had been diagnosed with lupus choroidopathy two months prior to her visit and was being treated with CellCept and Prednisone. Her visual acuities were hand motions in the right eye and 20/20 in the left eye. Her slit lamp examination was normal. Dilated fundus exam revealed multiple areas of subretinal fluid and retinal pigment epithelial (RPE) detachments in the macular and peripapillary areas of both eyes (Figure 1). Optical computerized tomography (OCT) confirmed the subretinal fluid and RPE detachments (Figure 1).

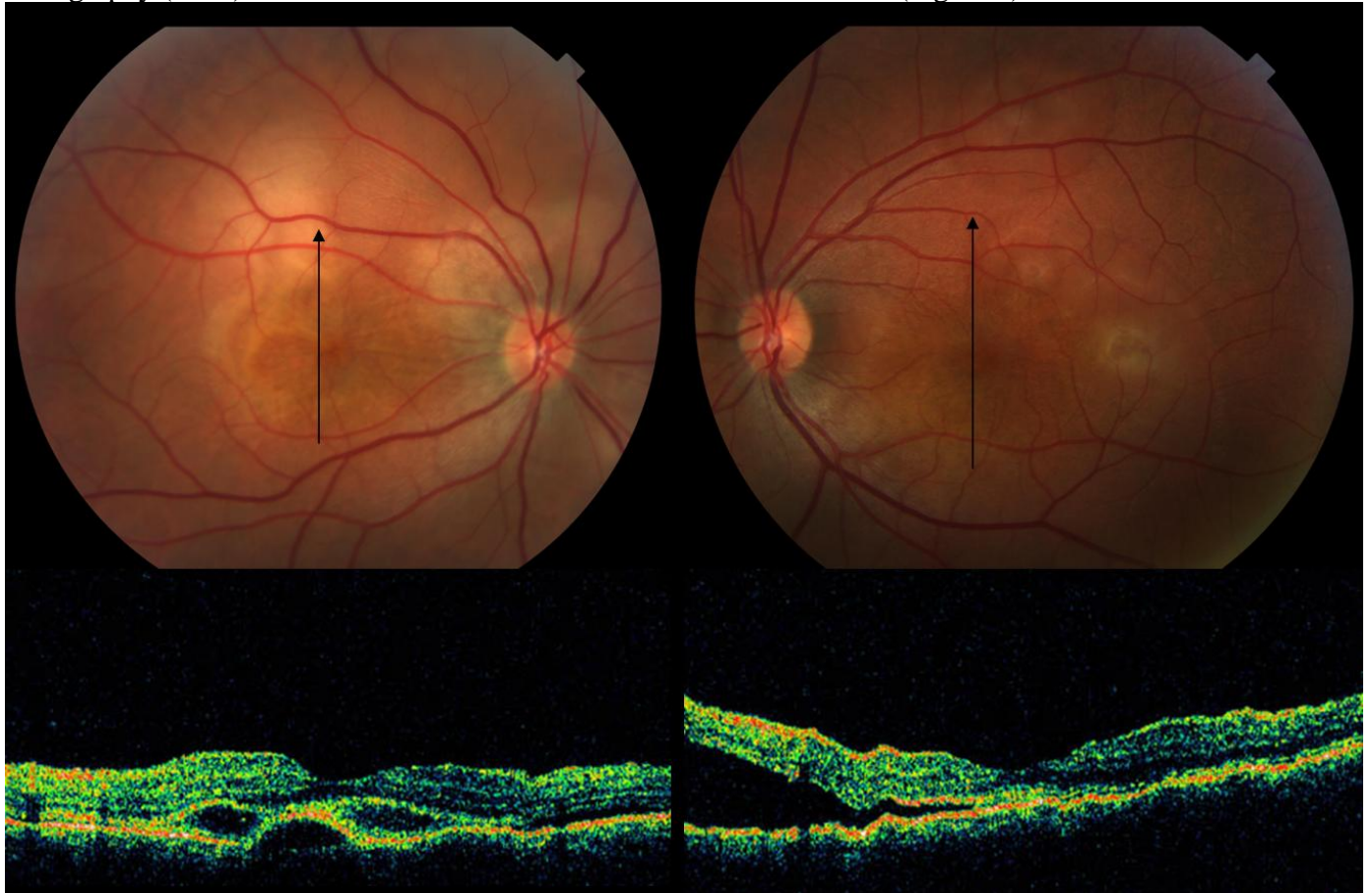
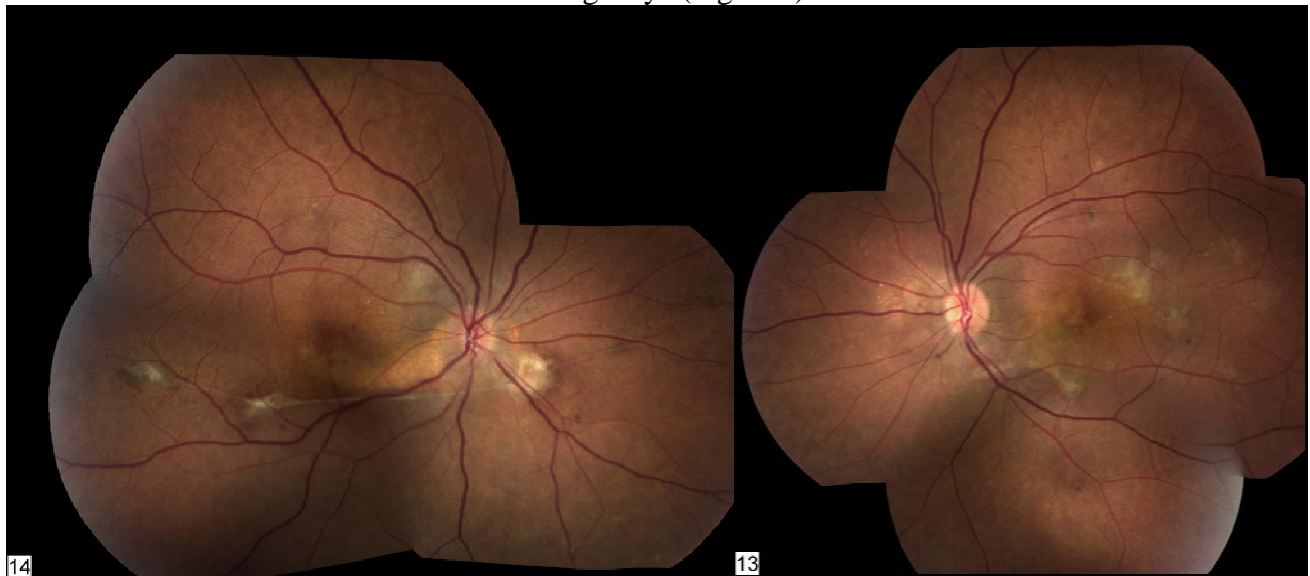


Figure 1

Fluorescein angiography (FA) showed multiple choroidal leaks into the subretinal space in both eyes (Figure 32). Because the FA appearance showed a smokestack-like configuration in the right eye and because the patient was worsening despite appropriate immunomodulatory therapy (IMT), the possibility of central serous chorioretinopathy (CSCR) was raised. Therefore, the Prednisone

was tapered as a diagnostic trial, but her vision worsened on the lower steroid dose. It was felt at this point that the patient's disease process represented worsening lupus choroidopathy and she was admitted to the hospital for intravenous pulse steroids. A full medical evaluation did not reveal any signs of active lupus disease in other organ systems.

She started on intravenous Cytoxan. Her visual acuity improved in the right eye to 20/50 but worsened in the left eye to 20/125. She then underwent treatment with laser photocoagulation directly to the active RPE leaks and around leaks associated with a mechanical defect in the RPE in both eyes. After four total months of Cytoxan treatment and an additional laser treatment to the right eye, her vision improved to 20/25 in both eyes. Fundus examination demonstrated resolution of the subretinal fluid and multiple areas of RPE pigmentary changes in both eyes and a subretinal fibrotic band under the inferior arcade in the right eye (Figure 3).



She was transitioned to oral Cytoxan therapy and then to oral methotrexate with no recurrences after six months of additional follow-up.

### **Systemic Lupus Erythematosus (SLE)**

Systemic lupus erythematosus (SLE) is a chronic, systemic, immunologically mediated disease of unknown etiology. Production of a number of pathogenic autoantibodies and immune complexes and an inability to suppress or clear them are the underlying abnormalities in SLE. The revised 11 diagnostic criteria proposed by the American Rheumatism Association are widely accepted.<sup>1</sup> The diagnosis of SLE can be made if four of these criteria are met. At the time of presentation, only one organ system may be involved, with or without the presence of autoantibodies. It should be noted, however, that there is a general consensus that these current criteria over-represent cutaneous lupus, may not capture early lupus, and do not capture some patients with lupus nephritis and neurologic lupus.

#### **Ophthalmic Manifestations: A Barometer of Systemic Disease**

It is unfortunate that ocular manifestations have not been included in the diagnostic scoring systems for establishing the clinical diagnosis of systemic lupus erythematosus. Indeed, it is not uncommon

to see patients who have not been diagnosed with SLE who have developed an ocular manifestation well in advance of definitive establishment of the diagnosis. For example, a woman with Raynaud's phenomenon, alopecia, nondeforming arthritis, and none of the other manifestations of SLE (including ANA positivity) may present to the ophthalmologist with episcleritis, peripheral keratitis, or scleritis. Through time, such a patient becomes ANA positive and develops other manifestations of SLE, in some instances severe ones, such as pericarditis and nephritis. If the clinical diagnosis of SLE could have been made earlier, some of these patients would have more careful follow-up at an earlier stage, with regular monitoring of the erythrocyte sedimentation rate and autoantibody production and therapeutic interventions before the development of potentially serious vital organ involvement.

The more common phenomenon, as in the patient presented here, is for the patient to have well-diagnosed SLE before the onset of an ocular manifestation. In particular, the development of scleritis and of retinal vasculitis in a patient with SLE is a harbinger of increased systemic disease activity. Therefore, patients with established SLE who develop one of these two lesions should be monitored more frequently and carefully even if the first evaluation after the onset of such a manifestation appears to suggest that the patient is perfect from a systemic disease standpoint.

#### External Ocular and Anterior Segment Involvement

The classic hallmark of discoid lupus is discrete, raised, scaly lesions of the skin. When they occur on the eyelids, they appear much like chronic blepharitis. Keratoconjunctivitis sicca (KCS) with or without xerostomia is the most common ocular manifestation of SLE, occurring in approximately 25% of patients. KCS may also precede the development of classic SLE, as emphasized by Zufferey and associates.<sup>2</sup> Conjunctivitis and interstitial keratitis can be seen as well but are rare. Superficial punctate keratitis and recurrent epithelial erosions have been reported in patients with discoid lupus erythematosus. The lesions responded well to systemic quinacrine hydrochloride therapy.<sup>3</sup> Episcleritis or scleritis can be the presenting manifestation of SLE and may precede more classic, diagnostic manifestations of SLE by 1 to 3 years. Uveitis, in the absence of retinal vasculitis, while rare, may also occur prior to other SLE manifestations.

#### Retinal Involvement

Retinal involvement in SLE is quite common, second only to KCS. It is almost certainly an under recognized manifestation of the disease. Reports of its prevalence vary greatly. A prospective clinical study revealed that 88% of patients with lupus retinopathy had active systemic disease. Furthermore, SLE patients with retinopathy had significantly decreased survival compared with SLE patients without retinopathy.<sup>4</sup>

The classic finding in lupus retinopathy is the cotton-wool spot. The cotton-wool spots may be isolated or may be surrounded by hemorrhage. Additional small, discrete spots may also be seen alone or in areas of retinal edema and infarction. The majority of patients with lupus retinopathy have this nonproliferative form of the disease. Severe visual loss is not usually seen in this group of patients, whose retinopathy improves with treatment of their systemic disease.<sup>5</sup> Far fewer patients with lupus retinopathy develop severe retinal vasculitis with progression to proliferative retinopathy. The visual prognosis is much worse; more than 50% of the affected eyes have visual acuity of

20/200 or worse.<sup>6,7</sup> The underlying process is characterized by diffuse arteriolar occlusion with extensive capillary nonperfusion. Retinal neovascularization may result. The severe retinopathy in this group of patients is typically associated with active systemic disease and with CNS lupus in particular. Indeed, many of the pathologic changes in the retinal and cerebral vasculature in lupus are quite similar.<sup>8</sup> However, some patients develop proliferative retinopathy with quiescent systemic disease. Close follow-up of these patients is essential. Immunosuppression is the mainstay of therapy. Even in the absence of other systemic manifestations of SLE, patients with retinal vasculitis require immunomodulatory therapy to prevent vision loss from ongoing inflammation. Any of the traditional IMT drugs, often including cytotoxic agents, may be required in isolated, sight-threatening retinal vasculitis.<sup>9</sup> Laser photocoagulation for proliferative retinopathy is also thought to be beneficial.<sup>10</sup> Patients may have, in addition to small-vessel disease, a vasoocclusive phenomenon involving larger retinal vessels that manifests as branch retinal vein occlusion, central retinal vein occlusion, central retinal artery occlusion, or a combination of these.<sup>11</sup> The association of large retinal vessel disease with the presence of antiphospholipid antibodies has been well documented.

### Choroidal Involvement

Although less common than retinopathy, lupus choroidopathy may be more common than generally appreciated.<sup>12</sup> It serves as a sensitive indicator of lupus activity. It may be seen in severely ill or hypertensive patients. An increased severity of nephropathy or presence of CNS vasculitis in a CNS patient should prompt evaluation of the choroid. Choroidopathy may also be seen, as in the patient described here, in patients with “lupus in remission.” Choroidopathy may precede a systemic flare by several months. It can be a signal of subclinical, reversible nephropathy or neuropathy.

Jabs and colleagues<sup>13</sup> described six patients with SLE with multifocal serous elevation of the RPE and sensory retina. Control of systemic disease in three of these patients resulted in improvement of their serous detachments. Matsuo and associates<sup>14</sup> reported two additional cases of SLE with multifocal RPE and serous retinal detachments. One of these patients showed deposits of immune complexes in Bruch's membrane, which led the researchers to suggest that the widespread RPE defects may be the result of injury caused by anti-RPE antibodies. The presence of antineuronal antibodies in serum and cerebrospinal fluid of SLE patients led them to speculate on the existence of anti-RPE antibodies. Immunopathologic studies show extensive deposition of immune complexes in the choroid, probably because of its profuse blood flow. Other findings include extensive mononuclear inflammatory cell infiltrates and diffuse thickening of medium-sized vessels. Fibrinoid necrosis of the vessels can also be seen. Other theories about immunopathogenesis emphasize that immune complex deposition in the choroid and choriocapillaris can lead to hypoperfusion and devitalization of RPE and secondary loss of blood-outer retina barrier tight junctions. Thrombosis from associated anti-phospholipid syndrome and hypertension may also contribute to choroidal hypoperfusion.

Fluorescein angiography typically shows multifocal round serous detachments of the retina and/or RPE. Indocyanine green angiography can provide information that is not detectable by clinical or fluorescein angiographic examination in patients with SLE choroidopathy.<sup>15</sup> Findings may include: focal, transient hypofluorescent areas in the very early phase; fuzziness of large choroidal vessels

with late diffuse zonal choroidal hyperfluorescence; poorly-defined area of choroidal hypofluorescence visible up to the late phase; and focal cluster of pinpoint spots of choroidal hyperfluorescence visible from the intermediate to late phase. As with retinal vasculitis, prompt and aggressive immunomodulatory therapy is crucial to limiting visual loss from choroidopathy. Focal laser to points of choroidal leakage may hasten the resolution of subretinal fluid and should be considered as an adjuvant therapy to immunomodulation.<sup>16</sup>

The differential diagnosis for lupus choroidopathy includes multifocal CSCR, hypertensive choroidopathy, Vogt-Koyanagi-Harada syndrome, and choroidal metastasis. CSCR is the most difficult to distinguish from lupus choroidopathy.<sup>17,18</sup> In general, lupus choroidopathy shows more leakage sites, a more protracted course, and evidence of underlying choroidal ischemia and delayed filling.

### Neuro-ophthalmologic Involvement

The neuroophthalmologic manifestations of SLE have been reviewed by Lessell.<sup>19</sup> The optic nerve and chiasm may be involved in SLE, most likely by an ischemic process, although the clinical presentations can be quite varied. Anterior and posterior ischemic optic neuropathy and a clinical picture similar to that of optic neuritis have been reported. Pathologic findings include demyelination and axonal necrosis or a combination of the two.

### References

1. Petri M, Magder L. Classification criteria for systemic lupus erythematosus: a review: *Lupus* 13: 829, 2004.
2. Zufferey P, Meyer OC, Bourgeois P, et al: Primary systemic Sjögren's syndrome preceding systemic lupus erythematosus: A retrospective study of four cases in cohort of 55 patients. *Lupus* 4:23, 1995.
3. Foster CS: Immunosuppressive therapy in external ocular inflammatory disease. *Ophthalmology* 87:140, 1980.
4. Stafford-Brady FJ, Urowitz MB, Gladman DD, Easterbrook M: Lupus retinopathy: Patterns, associations, and prognosis. *Arthritis Rheum* 31:1105, 1988.
5. Koch JW, Nawaiseh IA, Koch FHJ, et al: Severe occlusive bilateral retinal vasculitis within the scope of seronegative systemic lupus erythematosus. *Klin Monatsbl Augenheilkd* 201:330, 1992.
6. Vine AK, Barr CC: Proliferative lupus retinopathy. *Arch Ophthalmol* 102:852, 1984.
7. Jabs DA, Fine SL, Hochberg MS, et al: Severe retinal vaso-occlusive disease in systemic lupus erythematosus. *Arch Ophthalmol* 104:558, 1986.
8. Graham EM, Spalton DJ, Barnard RO, et al: Cerebral and retinal vascular changes in systemic lupus erythematosus. *Ophthalmology* 92:444, 1985.
9. Neumann R, Foster CS: Corticosteroid-sparing strategies in the treatment of retinal vasculitis in systemic lupus erythematosus. *Retina* 15: 201, 1995.
10. Read RW, Chong LP, Rao N: Occlusive retinal vasculitis associated with systemic lupus erythematosus. *Arch Ophthalmol* 118: 588, 2000.
11. Kleiner RC, Najarian LV, Schatten S, et al: Vaso-occlusive retinopathy associated with anti-phospholipid antibodies (lupus anticoagulant retinopathy). *Ophthalmology* 96:896, 1989.

12. Nguyen QD, Uy HS, Akpek EK, Harper SL, Zacks DN, Foster CS. Choroidopathy of systemic lupus erythematosus. *Lupus* 9:288, 2000
13. Jabs DA, Hanneken AM, Schachat AP, et al: Choroidopathy in systemic lupus erythematosus. *Arch Ophthalmol* 106:230, 1988.
14. Matsuo T, Nakayama T, Koyama T, Matsuo N: Multifocal pigment epithelial damages with serous retinal detachment in systemic lupus erythematosus. *Ophthalmologica* 195:97, 1987.
15. Gharbiya M, Bozzoni-Pantaleoni F, Augello F and Balacco-Gabrieli C: Indocyanine green angiographic findings in systemic lupus erythematosus choroidopathy. *Am J Ophthalmol* 134: 286, 2002.
16. Shimura M, Tatehana Y, Yasuda K et al. Choroiditis in systemic lupus erythematosus: systemic steroid therapy and focal laser treatment. *Jpn J Ophthalmol* 47: 312, 2003.
17. Khng CGYW, Yap EY, Au-Eong KG, Lim TH, Leong KH. Central serous retinopathy complicating systemic lupus erythematosus: a case series. *Clin Experiment Ophthalmol* 2000; 28: 309-13.
18. Cunningham ET, Alfred PR, Irvine AR. Central serous chorioretinopathy in patients with systemic lupus erythematosus. *Ophthalmology* 1996; 103: 2081 -90.
19. Lessell S: Neuro-ophthalmic symptoms and signs of systemic lupus erythematosus. *In* Glaser JS (ed): *Neuro-ophthalmology*, vol 10. St. Louis, CV Mosby, 1980, pp 44–61.

#### Figure Legends

Figure 1. Fundus photographs with corresponding OCTs show multiple RPE detachments and subretinal fluid in both eyes.

Figure 2. Early and late frames of the FA show multiple choroidal leaks in both eyes. In the right eye, the central leak has a smokestack-like appearance.



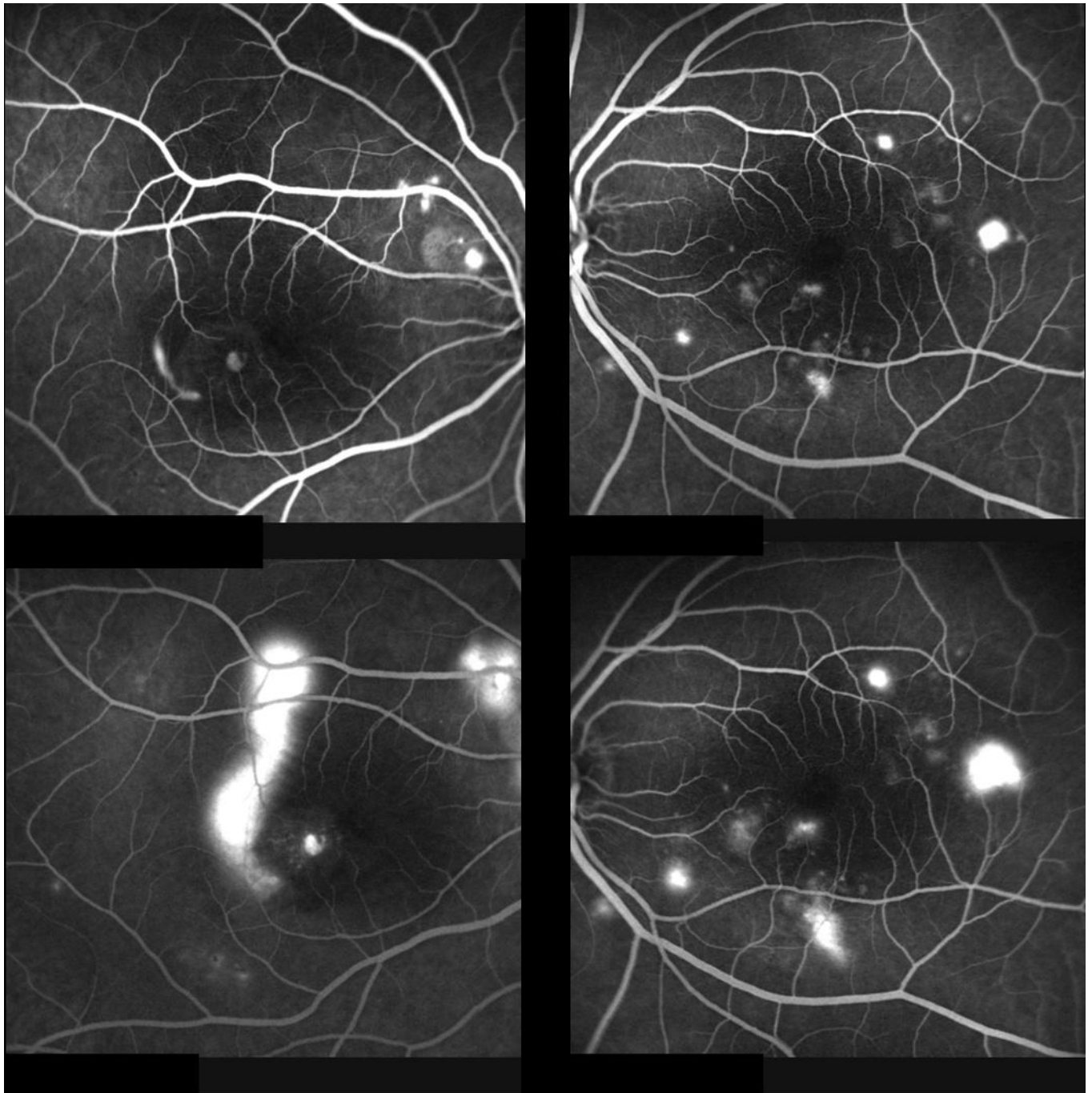


Figure2

Figure 3. Montage photographs of each eye show multiple areas of RPE pigment changes. There is a subretinal fibrotic band under the inferior arcade in the right eye.

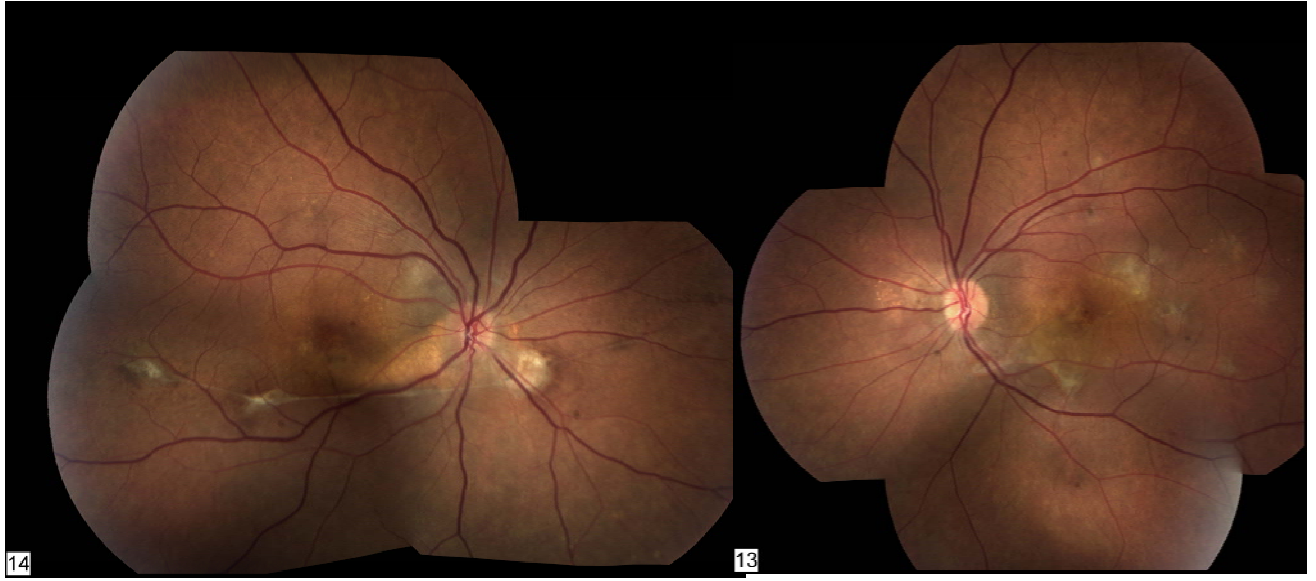


Figure 3