

SURGICAL ANATOMY

OF THE

HEAD AND NECK

BY

JOHN B. DEEVER, M.D.

SURGEON-IN-CHIEF TO THE GERMAN HOSPITAL, PHILADELPHIA

ILLUSTRATED BY 177 PLATES NEARLY ALL DRAWN FROM ORIGINAL DISSECTIONS

NECK; MOUTH; PHARYNX; LARYNX; NOSE; ORBIT; EYEBALL;
ORGAN OF HEARING; BRAIN; BACK OF NECK;
CRANIUM; SCALP; FACE.

PHILADELPHIA
P. BLAKISTON'S SON & CO.
1012 WALNUT STREET
1904

SURGICAL ANATOMY

OF THE

HEAD AND NECK

DEAVER

BY THE SAME AUTHOR

SURGICAL ANATOMY.—A Treatise on Human Anatomy in its Application to the Practice of Medicine and Surgery. In Three Royal Octavo Volumes, including 499 Full-page Plates. SOLD BY SUBSCRIPTION ONLY. Full Sheep or Half Morocco, \$30.00; Half Russia, \$33.00 net.

GENERAL ARRANGEMENT OF CONTENTS

Volume I.—Upper Extremity—Back of Neck—Shoulder—Trunk—Cranium—Scalp—Face.

Volume II.—Neck—Mouth—Pharynx—Larynx—Nose—Orbit—Eyeball—Organ of Hearing—Brain—Male Perineum—Female Perineum.

Volume III.—Abdominal Wall—Abdominal Cavity—Pelvic Cavity—Chest—Lower Extremity.

APPENDICITIS.—Its History, Anatomy, Etiology, Pathology, Symptoms, Diagnosis, Prognosis, Treatment, Complications and Sequelæ, with five Colored and many other Full-page Plates. Third Edition. Cloth, \$5.00.

ENLARGEMENT OF THE PROSTATE.—Its History, Anatomy, Pathology, Causes, Symptoms Diagnosis, Treatment, and Technique of Operations. Illustrated. Octavo. *In Press.*

COPYRIGHT, 1904, BY P. BLAKISTON'S SON & Co.

WM. F. FELL CO.
ELECTROTYPERS AND PRINTERS
1220-24 SAN OM STREET
PHILADELPHIA

WE
700
II347
1904

PUBLISHERS' NOTE.

This volume has been made up from those sections of Dr. Deaver's complete work on "Surgical Anatomy" which treat specially of the regions which are of greatest interest to those practitioners who confine their work to Diseases of the Eye, Ear, Nose, Mouth, Throat, and Nervous System, and provides this class of specialists with an absolutely unique book, useful, practical, new.

The illustrations which were prepared to exemplify the text have been drawn directly from dissections made for the purpose. They are accurate, artistic, realistic, and are reproduced in accordance with the highest standards of typography.

The text is clear, succinct and systematically arranged. It sets forth the principles of anatomy as applied to medicine and surgery and describes with thoroughness the anatomic conditions fundamental to the various surgical operations.

CONTENTS.

	PAGE
THE NECK,	17
SURFACE ANATOMY OF THE NECK,	17
DISSECTION OF THE NECK,	26
Triangles of Neck,	54
Cervical Plexus of Nerves,	65
Extrinsic Muscles of Tongue,	108
Thyroid Gland,	122
Axillary or Brachial Plexus,	148
Bursæ of Neck,	156
Lymphatic Glands of Neck,	159
LIGATION OF ARTERIES OF HEAD AND NECK,	160
OPERATIONS UPON NERVES OF HEAD AND NECK,	196
THE MOUTH,	209
THE TONGUE,	216
Muscles of the Tongue,	219
THE TONSILS,	224
THE PHARYNX,	227
RELATIONS OF THE PHARYNX,	237
VEINS OF THE PHARYNX,	238
LYMPHATIC VESSELS OF THE PHARYNX,	238
THE SOFT PALATE,	238
THE LARYNX,	247
VEINS OF THE LARYNX,	265
LYMPHATIC VESSELS OF THE LARYNX,	265
THE VOCAL CORDS,	266
THE CARTILAGES OF THE LARYNX,	270
THE NOSE,	284
THE NASAL BONES,	286
CARTILAGES OF THE NOSE,	286
THE FRONTAL SINUSES,	308
THE ANTRUM OF HIGHMORE,	312
THE ETHMOID SINUSES,	315
THE SPHENOID SINUSES,	315
THE ORBIT,	316
DISSECTION OF THE ORBIT,	317
MUSCLES OF THE ORBIT,	328
THE LACRYMAL APPARATUS,	351

	PAGE
THE EYEBALL,	357
THE ORGAN OF HEARING,	399
THE EXTERNAL EAR,	399
THE MIDDLE EAR,	407
THE INTERNAL EAR,	431
MEMBRANES AND VESSELS OF THE BRAIN,	438
THE ARTERIES OF THE BRAIN,	445
THE VEINS OF THE BRAIN,	454
THE BRAIN,	455
SURFACE MARKINGS OF THE BRAIN,	455
THE ORIGINS OF THE CRANIAL NERVES,	461
THE CEREBRUM,	467
Surface Markings,	467
Cranio-Cerebral Topography,	499
Motor Centers,	500
Interior of Cerebrum,	512
The Lateral Ventricles,	518
THE PONS VAROLII,	549
THE MEDULLA OBLONGATA,	553
THE CEREBELLUM,	558
SECTIONS OF THE BRAIN,	567
JOINTS OF THE HEAD AND NECK,	573
DISLOCATIONS OF THE BONES OF THE VAULT AND BASE OF SKULL,	579
DISLOCATION OF THE LOWER JAW,	579
EXCISION OF THE UPPER JAW,	579
EXCISION OF THE LOWER JAW,	583
FRACTURES OF THE SKULL,	584
SURFACE ANATOMY OF THE CRANIUM,	587
SURFACE ANATOMY OF THE FACE,	592
SCALP,	601
FACE,	625
PTERYGO-MAXILLARY REGION,	676
THE MEMBRANES AND VESSELS OF THE BRAIN,	704
INTRA CRANIAL COURSE AND MODE OF EXIT OF THE CRANIAL NERVES,	727
INDEX,	737

LIST OF ILLUSTRATIONS.

PLATE	PAGE
I. Lines of Incision for Exposure of Arteries and Nerves of Neck,	20
II. Surface Anatomy of Neck, and Lines of Incision in Laryngotomy, High Tracheotomy and Low Tracheotomy,	21
III. Incisions for Dissection of Neck, and Lines for Vessels and Nerves of Neck, . .	27
IV. Platysma Myoides Muscle,	30
V. Superficial Layer of Deep Fascia, Superficial Veins, and Nerves of Neck, . . .	34
VI. Veins of Scalp, Face, and Neck,	35
VII. Section of Neck at Sixth Cervical Vertebra,	39
VIII. Diagram of Deep Cervical Fascia,	41
IX. Cervical Plexus,	44
X. Superficial Structures of Neck,	50
XI. Superficial Structures of Neck,	51
XII. Diagram of Triangles of Neck,	55
XIII. Incisions for Dissection and Lines for Arteries, Veins, and Nerves of Neck, . .	67
XIV. Vessels and Nerves of Neck,	70
XV. Vessels and Nerves of Neck,	71
XVI. Deep Structures of Neck—Carotid Arteries and Pneumogastric Nerve,	78
XVII. Sympathetic Nerve and Laryngeal Nerves,	79
XVIII. Diagram of Subclavian and Carotid Arteries and Their Branches,	87
XIX. Veins of Head and Neck,	89
XX. Superficial Structures of Neck,	100
XXI. Superficial Structures of Neck,	101
XXII. Arteries of Tongue and Tonsil,	105
XXIII. Extrinsic Muscles of Tongue,	109
XXIV. Superficial Structures Near Median Line of Neck,	117
XXV. Thyroid Body,	123
XXVI. Thoracic Duct,	129
XXVII. Collateral Circulation after Ligation of Subclavian Artery,	133
XXVIII. Vertebral Artery in Transverse Processes,	137
XXIX. Vessels of Neck,	140
XXX. Vessels of Neck,	141
XXXI. Axillary or Brachial Plexus of Nerves,	149
XXXII. Prevertebral Muscles,	152
XXXIII. Lymphatic Glands and Lymphatic Vessels of Neck,	157
XXXIV. Lines of Incision for Operations on Nerves and Arteries of Head and Neck, . .	161
XXXV. Exposure of Innominate Artery,	164
XXXVI. Exposure of Third Portion of Subclavian Artery,	167
XXXVII. Diagram of Collateral Circulation after Ligation of Subclavian and Common Carotid Arteries,	171
XXXVIII. Exposure of Vertebral Artery and Inferior Thyroid at Origin—Left Side of Neck,	174
XXXIX. Ligation of First and Second Portions of Lingual Artery; Superior Thyroid Artery; Inferior Thyroid Artery,	177

PLATE	PAGE	
XI.	Exposure of Inferior Dental Nerve; Facial Artery; Spinal Accessory Nerve and Superficial Branches of Cervical Plexus; and Common Carotid Artery in Superior Carotid Triangle,	182
XL.	Exposure of External Carotid and Internal Carotid, and of the Superior Thyroid, Lingual, Facial, and Occipital Arteries at Their Origin, and Exposure of Common Carotid in the Inferior Carotid Triangle,	183
XLII.	Exposure of Occipital Artery for Ligation,	192
XLIII.	Exposure of Auriculo-temporal Nerve and Temporal Artery,	193
XLIV.	Exposure of Supraorbital Artery and Nerve,	197
XLV.	Exposure of Lingual Artery,	202
XLVI.	Exposure of Facial Nerve,	203
XLVII.	Exposure of Brachial Plexus of Nerves,	208
XLVIII.	Vertical Section of Mouth, Pharynx, Larynx, and Nose,	212
XLIX.	Superior Aperture of Larynx and Dorsum of Tongue,	218
L.	Transverse Section of One-half of Tongue,	221
LI.	Constrictor Muscles of Pharynx,	229
LII.	Pharyngeal Tonsil and Bursa,	233
LIII.	Interior of Pharynx,	236
LIV.	Anterior View of Mouth,	239
LV.	Muscles of Soft Palate—Anterior View,	242
LVI.	Muscles of Soft Palate,	243
LVII.	Superior Aperture of Larynx,	250
LVIII.	Larynx and Crico-thyroid Muscles,	251
LIX.	Anterior View of Larynx, Including the Crico-thyroid Membranes,	254
LX.	Muscles of Larynx—Posterior View,	258
LXI.	Muscles of Larynx—Lateral View,	259
LXII.	Nerves and Arteries of Larynx,	263
LXIII.	Lateral View of Interior of Larynx,	267
LXIV.	Cartilages of Larynx,	271
LXV.	Surface Marks of Neck and Lines of Incision for Laryngotomy and Tracheotomy,	278
LXVI.	Operation of Laryngotomy and High and Low Tracheotomy,	279
LXVII.	Lateral Cartilages of the Nose,	287
LXVIII.	Cartilages at Base of Nose,	290
LXIX.	Nasal Septum,	291
LXX.	Meatuses of Nose and Turbinate Bones—Lateral View,	296
LXXI.	Orifices of Accessory Air-chambers of Nose,	298
LXXII.	Olfactory Nerves,	303
LXXIII.	Anterior View of Nasal Fossæ,	306
LXXIV.	Posterior View of Nasal Fossæ,	309
LXXV.	Orifices of Nasal Duct and Accessory Air-chambers of Nose,	314
LXXVI.	Orbital Fascia and Capsule of Tenon—Sagittal Section,	320
LXXVII.	Orbital Fascia and Capsule of Tenon—Transverse Section,	321
LXXVIII.	Nerves and Muscles of Orbit,	326
LXXIX.	Muscles of Orbit,	330
LXXX.	Arteries and Veins of Orbit,	334
LXXXI.	Nerves of Orbit,	339
LXXXII.	Section of Cavernous Sinus—Structures Traversing Sphenoid Fissure,	343
LXXXIII.	Tensor Tarsi and Corrugator Supercilii Muscles,	346
LXXXIV.	Lacrimal Apparatus,	350
LXXXV.	Sagittal Section of Upper Eyelid,	353
LXXXVI.	Mebonian Glands and Lacrymal Apparatus,	355
LXXXVII.	Meridional Section of Eye,	360
LXXXVIII.	Meridional Section of Ciliary Region of Eyeball,	365
LXXXIX.	External and Middle Coats of Eyeball,	369
XC.	Ciliary Region of Eyeball (from Lion's Eye in Museum of Univ. of Penna.),	372

PLATE	PAGE
XCI. Ciliary Nerves,	376
XCU. Ciliary Arteries,	377
XCIII. Retina of Posterior One-half of Right Eyeball,	381
XCIV. Blood vessels of Eyeball (after Leber),	384
XCv. Lens, Iris, and Ciliary Body at Rest; the Same Structures During Accommodation. Emmetropic Eye,	388
XCVI. Myopic Eye; Myopic Eye with Concave Lens; Hyperopic Eye; Hyperopic Eye with Convex Lens,	389
XCVII. Annual Posterior Synechia,	394
XCVIII. Pinna of Ear,	398
XCIX. Intrinsic Muscles of Pinna,	401
C. External and Middle Ear,	405
CI. Anterior View of Right Tympanum,	409
CII. Membrana Tympani and Its Inclination,	413
CIII. External View of Membrana Tympani of Left Ear,	418
CIV. Internal View of Right Tympanum,	422
CV. External View of Bony Labyrinth and Semicircular Canals,	427
CVI. Interior of Osseous Labyrinth of Left Internal Ear,	430
CVII. Interior of Osseous Portion of Cochlea,	434
CVIII. Section of Osseous Portion of Cochlea,	435
CIX. Diagram of Membranous Labyrinth,	439
CX. Circle of Willis and Arteries of Brain,	444
CXI. Middle Cerebral Artery,	447
CXII. Arteries at Base of Brain,	452
CXIII. Base of Brain and Superficial Origin of Cranial Nerves,	458
CXIV. Diagram of Optic Tracts,	463
CXV. Island of Reil,	471
CXVI. Diagram of Lateral Surface of Cerebrum,	474
CXVII. External Surface of Cerebrum,	477
CXVIII. Superior Surface of Cerebrum,	480
CXIX. Inferior Surface of Frontal Lobe,	483
CXX. Median and Inferior Surfaces of Cerebrum,	488
CXXI. Inferior Surface of Occipital and Temporal Lobes,	494
CXXII. Median and Inferior Surfaces of Cerebrum,	497
CXXIII. Motor and Sensory Areas of Cerebrum (after Ferrier),	501
CXXIV. Lines for Fissures, Lower Level of Cerebrum,	506
CXXV. Corpus Callosum and Horizontal Section of Cerebrum,	513
CXXVI. Internal Surface of Cerebrum and Section of Ventricles of Brain,	516
CXXVII. Bodies, Anterior Cornua, and Posterior Cornua of Lateral Ventricles,	519
CXXVIII. Fornix and Lateral Ventricles, and Descending Cornu of Left Lateral Ventricle,	523
CXXIX. Diagram of the Ventricles—Superior View,	528
CXXX. Diagram of the Ventricles—Lateral View,	529
CXXXI. Velum Interpositum and Choroid Plexus,	533
CXXXII. Ventricles and Nuclei of Brain,	536
CXXXIII. Lateral View of Corpora Quadrigemina, Pons, and Medulla,	539
CXXXIV. Third and Fourth Ventricles and Corpora Quadrigemina,	542
CXXXV. Transverse Section of Cerebrum,	546
CXXXVI. Pons, Medulla, and Superficial Origins of Cranial Nerves,	552
CXXXVII. Third and Fourth Ventricles and Corpora Quadrigemina,	556
CXXXVIII. Inferior and Superior Surfaces of Cerebellum,	560
CXXXIX. Coronal Section of Cerebrum,	564
CXL. Coronal Section of Cerebrum, Anterior to Optic Chiasm,	565
CXLI. Coronal Section of Cerebrum Through Corpora Albicantia and Middle Commissure,	569
CXLII. Parietal and Transverse Occipital Fissures. Lines in which the Bone is Divided in Excision of the Upper Jaw,	572

PLATE	PAGE
CXLIII. Temporo-maxillary Articulation—External View,	576
CXLIV. Temporo-maxillary Articulation—Internal View,	577
CXLV. Fractures of Lower Jaw,	581
CXLVI. Cranial Landmarks and Lines of Cerebral Fissures,	589
CXLVII. Incisions for Dissection,	597
CXLVIII. Layers of Scalp,	599
Cirsoid Aneurysm,	599
CXLIX. Superficial Fascia of Scalp,	603
CL. Arteries of Scalp and Face,	608
CLI. Nerves of Scalp and Facial Nerve,	609
CLII. Arteries, Nerves, and Muscles of Scalp and Face,	613
CLIII. Temporal Fascia and Nerves of Face,	620
CLIV. Temporal Muscle,	621
CLV. Incisions for Dissection and Lines for Vessels and Nerves of Face,	623
CLVI. Muscles of Face and Scalp,	627
CLVII. Tensor Tarsi and Corrugator Supercilii Muscles,	632
CLVIII. Arteries of Scalp and Face,	640
CLIX. Arteries, Nerves, and Muscles of Scalp and Face,	641
CLX. Veins of Scalp, Face, and Neck,	645
CLXI. Palpebral Fissure and Eyeball—Eyelids Everted,	649
CLXII. Lacrymal Apparatus and Meibomian Glands,	653
CLXIII. Pinna,	661
CLXIV. Intrinsic Muscles of Pinna,	663
CLXV. Nerves of Scalp and Facial Nerve,	667
CLXVI. Operation for Exposure of Facial Nerve,	672
CLXVII. Temporal Fascia and Nerves of Face,	673
CLXVIII. Pterygoid Muscles and Internal Maxillary Artery,	678
CLXIX. Internal Maxillary Artery and Branches,	682
CLXX. Inferior Maxillary Nerve,	686
CLXXI. Olfactory Nerves and Internal View of the Spheno-palatine and Otic Ganglia,	690
CLXXII. Superior and Inferior Maxillary Nerves,	695
CLXXIII. Diploic Veins,	705
CLXXIV. Dura Mater, Arachnoid, and Meningeal Vessels,	709
CLXXV. Sinuses and Processes of Dura Mater,	714
CLXXVI. Sinuses and Cranial Nerves,	715
CLXXVII. Lines for Sinuses,	721

SURGICAL ANATOMY

OF THE

HEAD AND NECK.

DISSECTION OF THE NECK.

SURFACE ANATOMY.

The surface anatomy of the region of the neck should be considered in regard to its superficial veins and nerves, the upper portion of the respiratory tract, the prominent muscles, the pulmonary apices, the sterno-clavicular joints, and the large vessels. The skin of the front of the neck may lie either in horizontal or vertical folds, the former being more common, and always seen in infants. In stout persons the deposition of fat in the subcutaneous tissues makes these folds very prominent, producing the condition known as "double chin." Vertical folds occur in the aged, especially in those who have lost much adipose tissue, in consequence of which the old and inelastic skin can no longer adapt itself. The anterior and most prominent ridges of the surface of the neck are due to the anterior border of the platysma myoides muscles.

Length of the neck.—The variability which exists in the length of the necks of different persons is due, as Merkel points out, to three factors: First, to the position of the shoulder girdle; second, to the contour of the border of the trapezius muscle; third, to the thickness of the neck. The superior thoracic aperture is oblique from behind forward and downward; in some persons this obliquity is greater than in others, so that the supra-sternal notch may be on a level with the third thoracic vertebra; this will consequently cause the inner end of the clavicle to lie lower, and the neck will appear longer. When the border of the trapezius muscle slopes gradually toward the shoulder instead of curving rather abruptly outward, the neck will appear longer; a thin neck presents a longer appearance than a thick and muscular one.

The length of the cervical portion of the spinal column does not vary much in different persons.

The **sterno-cleido-mastoid muscle**, because of its prominence throughout its course, is the great landmark of the neck, and extends from the sterno-

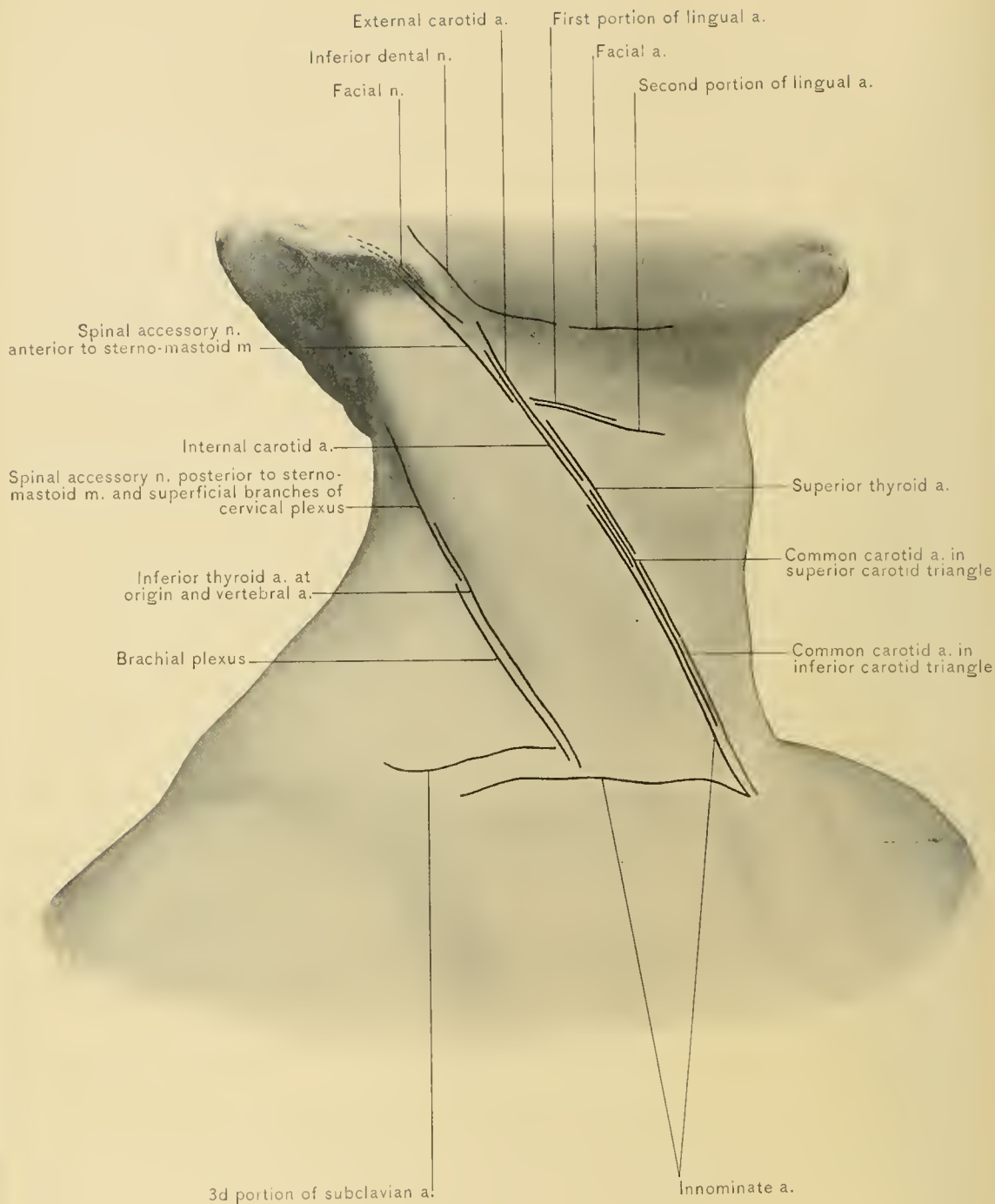
clavicular junction to behind the ear. Any movement of the head which draws the ear downward and forward renders the muscle prominent. It divides the side of the neck into the anterior and the posterior triangle. In subcutaneous section of the lower attachments of this muscle it must not be forgotten that the *fossa supraclavicularis minor*, the triangular interval between the sternal and clavicular origins, marks the position of the common carotid artery and internal jugular vein.

The **supra-sternal fossa**, termed "*fonticulus gutturis*" by the old writers, lies between the sternal origins of the two sterno-mastoid muscles. In beautiful necks it is, of course, filled with fat, but even then the rounded contour of the sternal attachment of this muscle is evident, though graceful withal. When the finger is deeply insinuated into the supra-sternal notch, the pulsations of the innominate artery can often be felt; those of a dilated aortic arch may also be perceived. Retraction of the tissues in the supra-sternal notch during inspiration is often seen in marked dyspnea, as in laryngeal obstruction.

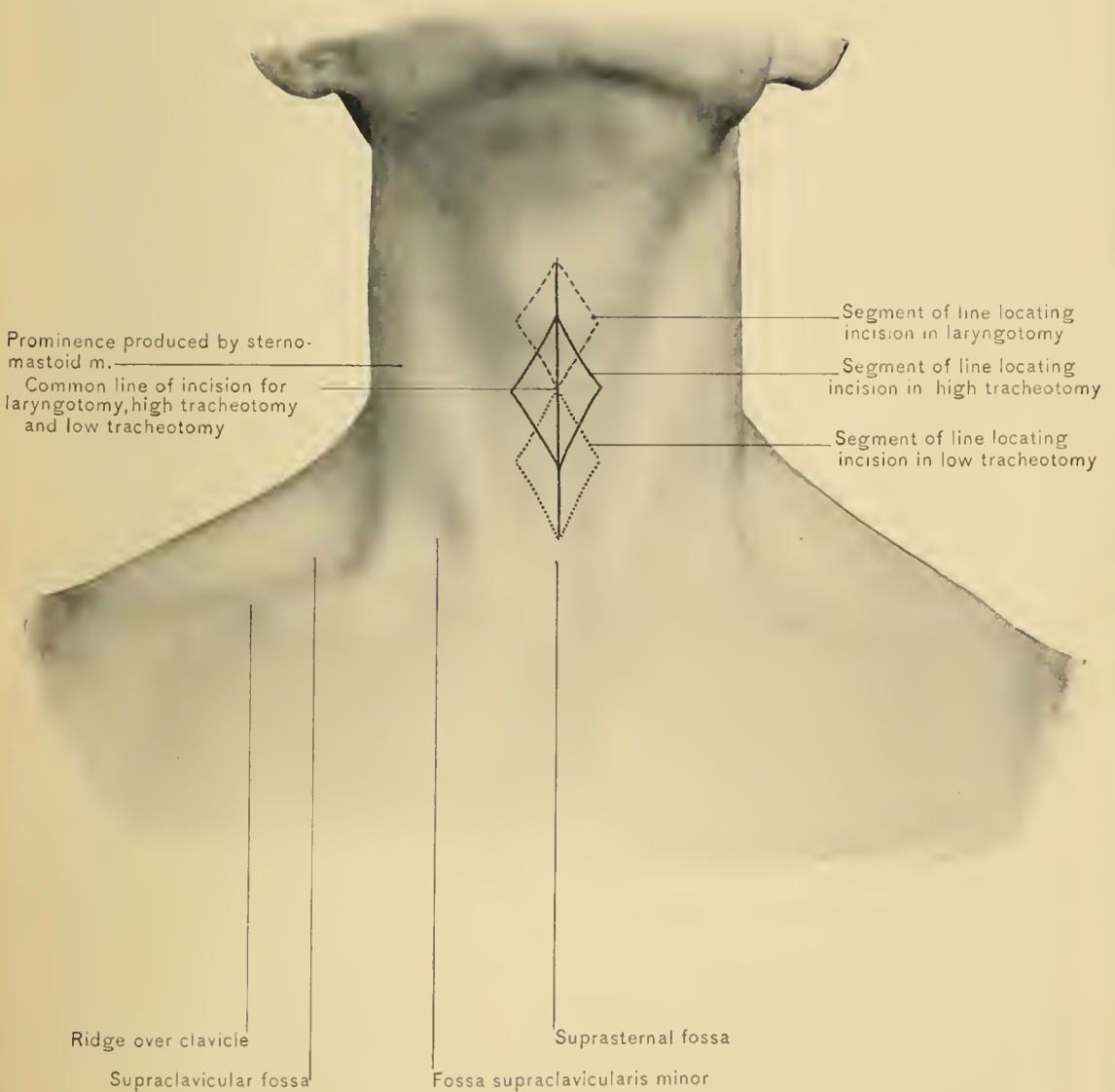
The **sterno-clavicular joint** may be readily identified at the side of the supra-sternal notch—in stout persons by movement, and by sight alone in thin individuals. Its upper border marks the origin of the innominate vein upon both sides, behind which, on the left side, lies the common carotid artery, and on the right side, the bifurcation of the innominate artery; still farther back is the apex of the lung. The innominate artery is relatively higher in children than in adults.

The **apex of the lung** extends from one to two inches above the clavicle, and higher in very long necks; it is also higher in women than in men. It is covered by part of the scalenus anticus, sterno-thyroid, and sterno-cleido-mastoid muscles, and to the inner side of the scalenus anticus muscle it is crossed transversely by the subclavian vessels. This portion of the lung is more commonly the site of tubercular deposits, and should be examined by percussion and auscultation immediately above and below the inner part of the clavicle.

The **supra-clavicular fossa** is the depression above the clavicle between the sterno-mastoid and trapezius muscles. The external jugular vein terminates here. It is well defined in emaciation due to wasting diseases and in old age. It marks the place where the vessels and nerves pass from the neck into the axilla, and a knife thrust backward, downward, and inward through this depression would injure a number of important structures. The transverse processes of the cervical vertebrae may be felt by pressure directed inward through the upper part of the fossa. In thin persons the posterior belly of the omo-hyoid muscle can also be felt in this space, just above and parallel to the clavicle. During inspiration the tension produced by the omo-hyoid muscle on the deep cervical fascia is plainly



LINEA OF INCISION FOR EXPOSURE OF ARTERIES AND NERVES.



SURFACE ANATOMY OF NECK, AND LINES OF INCISION IN LARYNGOTOMY, HIGH TRACHEOTOMY, AND LOW TRACHEOTOMY.

discernible. Holden likens its central tendon to a rudimentary cervical rib, its posterior belly to a digitation of the serratus magnus muscle, and its anterior belly to a sterno-hyoid muscle.

The **subclavian artery** extends from one-half of an inch to an inch above the clavicle, in the supra-clavicular fossa, close to the external border of the sterno-mastoid muscle, where, by moderate pressure directed downward, backward, and inward, it can readily be compressed against the first rib; pressure directed otherwise would meet no bony resistance, and bleeding could not be controlled.

The **carotid arteries** are readily found in the neck along the anterior or inner margin of the sterno-mastoid muscle, being covered by its anterior border, particularly in the lower part of the neck. The common carotid artery divides opposite the upper border of the thyroid cartilage. From this point at the anterior border of the sterno-mastoid muscle, a line drawn to the lobe of the ear indicates the course of the external carotid artery. The position of the common carotid artery is represented by a line drawn from the sterno-clavicular articulation to a point midway between the angle of the lower jaw and the mastoid process.

The **external jugular vein** passes down the neck in a line drawn from the angle of the inferior maxilla to the middle of the clavicle. By compression of its lower end the vein may be made to stand out prominently. Occasionally a *jugulo-cephalic branch* passes over the clavicle from the cephalic to the external jugular vein. The **anterior jugular vein** is usually found near the anterior margin of the sterno-mastoid muscle.

The **hyoid bone**, directly behind the lower border of the chin in the ordinary attitude of the head, may be felt in its entirety through the skin. To its upper border are attached the base of the tongue and the genio-hyoid and mylo-hyoid muscles, which form the floor of the mouth. Below the body of the bone are the thyro-hyoid space and membrane, the center of which corresponds to the position of the epiglottis. The greater cornu of the bone is the landmark which locates the origin of the superior thyroid, lingual, and facial arteries. The origin of the superior thyroid artery is just below the level of the greater cornu of the hyoid bone, that of the lingual artery is opposite to the greater cornu, and that of the facial artery is just above.

The **thyroid cartilage** forms the anterior projection in the neck called "Adam's apple"; it is larger in men than in women, so that there is increased length of the vocal cords, which have, therefore, in accordance with a well-established law of physics, a lower pitch, thus accounting for the deeper tones of the male. The entire cartilage is subcutaneous, its borders and cornua being easily traced by the finger. The lateral lobes of the thyroid gland can be indistinctly felt upon each side of the cartilage, and it is said the pulsations of the superior thyroid artery may readily be felt at the tip and front of the lateral lobe; this,

however, is exceptional. Below this cartilage is the crico-thyroid space, which is occupied by the crico-thyroid membrane. It is through this membrane that laryngotomy is performed, care being taken to hug the upper border of the cricoid cartilage, so that the incision may be as far as possible from the vocal cords and the crico-thyroid arteries.

The **vocal cords** are situated slightly below a point midway between the deepest part of the incisura thyroideæ and the lower border of the thyroid cartilage.

The **cricoid cartilage** is always prominent, and can readily be discerned. It lies opposite the sixth cervical vertebra. Its lower border is on a level with the commencement and narrowest part of the esophagus; for this reason all bodies which have entered the pharynx but are too large to pass through the gullet will lodge behind the cricoid cartilage. The cricoid cartilage is just above the level at which the omo-hyoid muscle and the inferior thyroid artery cross the carotid sheath, the muscle being in front of the sheath and the artery behind. Slightly below the level of this cartilage and beneath the anterior border of the sternomastoid muscle is the **carotid tubercle**, against which the common carotid artery may be compressed. This is the anterior tubercle of the transverse process of the sixth cervical vertebra.

The **movements of the larynx** are frequently overlooked. The larynx rises during deglutition, in singing a high note, and in expiration; it descends in singing low notes, in inspiration, after deglutition, and during retching and vomiting. When the larynx is moved from side to side, a grating sensation, due to the friction of the superior cornua of the thyroid cartilage against the spinal column, is perceived. The larynx is pushed forward in the passage of masses through the lower pharynx. The sudden upward rush of vomited matter produces suction upon the larynx, drawing out obstinately adherent false membrane and collections of glairy mucus; this is one reason for giving children emetics in croup.

The **trachea** is situated immediately below the cricoid cartilage. Ordinarily, not more than one and one-half inches of it appear above the sternum; an inch more, however, may be revealed if the neck be in extreme extension. This usually leaves about eight rings in the neck, of which the second, third, and fourth are covered by the thyroid isthmus. The front of the trachea may lie one and one-half inches deep at the top of the sternum, owing to the recession of the lower cervical and upper thoracic vertebra. Opening of the trachea to relieve dyspnea is beset with many difficulties not all demonstrable in the cadaver—the strong and rapid alternate muscular contractions, the heaving larynx, the distended anterior jugular veins, the flexed neck, the swollen thyroid isthmus, the distended thyroid plexus of veins, and, frequently, a middle thyroid artery. All incisions into the trachea should be in the median line, where fewer important structures need be severed. It is often advisable in cases of dyspnea to incise the crico-thyroid

membrane, and, if necessary, the cricoid cartilage may be divided. If a lower operation be required, it should be done when the patient has become quieted after relief of the dyspnea.

The **back of the neck** presents, above, the external occipital protuberance and the superior curved ridges of the occipital bone; below, the spinous process of the seventh cervical vertebra (*vertebra prominens*) and the ligamentum nuchæ, extending between the protuberance and the spine of the seventh cervical vertebra. For an inch below the superior curved ridges of the occipital bone the thin cerebellar fossæ of the occiput are not more than one-half of an inch from the surface; their walls are so thin at times that they may easily be penetrated with a sharp knife. About an inch below the external occipital protuberance a sharp, narrow instrument could be pushed forward, either above or below the posterior arch of the atlas, thus severing the upper end of the spinal cord and destroying life. About one or one and one-half inches on each side of the external occipital protuberance the occipital artery pierces the trapezius muscle, below the superior curved ridge, and passes over the occiput to the vertex; it is accompanied by the great occipital nerve. The outer margin of the trapezius muscle merges with the shoulder as it passes to it, and forms the graceful outline of the neck so well exhibited in some of the pictures of noted beauties. Deep pressure in the median line near the occiput reveals the bifid spine of the second cervical vertebra. The spines of the third, fourth, and fifth cervical vertebra, because of their shortness and recession, are not readily felt. The spine of the sixth, and more especially of the seventh, cervical vertebra may easily be detected. The fifth cervical spine is opposite the cricoid cartilage and the upper end of the esophagus; that of the seventh is behind the apex of the lung, which is higher in women.

Congenital cervical fistulæ.—A brief résumé of the development of the neck is here introduced in order to explain the mode of occurrence of certain interesting and important congenital defects.

The antero-lateral portion of the neck is formed largely from the *branchial* or *visceral* arches, four in number on each side, connected posteriorly with the spinal column, but not at first uniting anteriorly with one another. These arches are separated from one another by the branchial clefts, also four in number on each side, the fourth one being below the last arch.

The first or mandibular arch is concerned in the formation of the maxillæ; it is separated from the second arch by the first branchial cleft, which is the only cleft remaining in the adult.

The first branchial cleft persists as the external auditory meatus, middle ear, and Eustachian tube. Irregularities in development may lead to the formation of fistulous openings, which are usually found in the vicinity of the tragus of the ear.

The lower three arches are concerned in the formation of the tissues of the neck.

The visceral clefts open internally into the pharynx; no communication of the pharynx with the exterior ever occurs, for a delicate membrane divides the cleft into an inner (pharyngeal pouch) and an outer portion (branchial furrow).

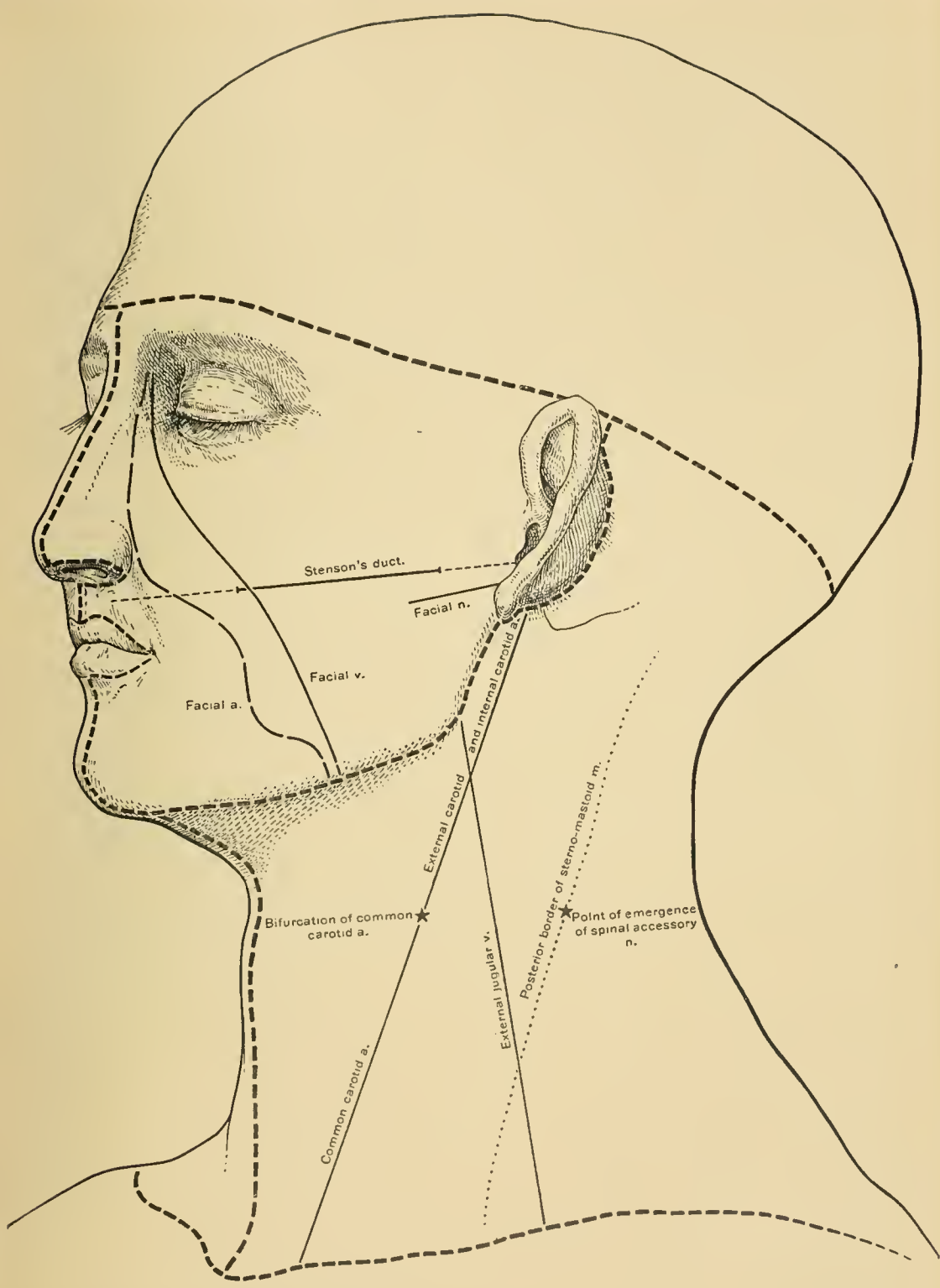
The lower three clefts normally disappear, certain traces found in the pharynx and larynx alone remaining.

The third and fourth arches are small, are gradually overlapped by the second arch, and lie in a depression known as the *sinus cervicalis*. It is through imperfect closure of this sinus that most of the congenital cervical fistulæ occur. These are narrow, epithelium lined tracts, opening externally near the anterior border of the sterno-mastoid muscle. When complete, they open internally into the pharynx. If the internal portion of a branchial cleft fail to become obliterated, while the outer portion is closed as normally, a *pharyngeal* or *esophageal diverticulum* may form. Furthermore, if the cleft become closed externally and internally and an intermediate, unobliterated portion persist, the epithelium lining this cavity may proliferate and undergo various changes, and thus a so-called *branchial cyst* result. These branchial cysts occur in the submaxillary and supra-clavicular regions and at the borders of the sterno-mastoid muscle.

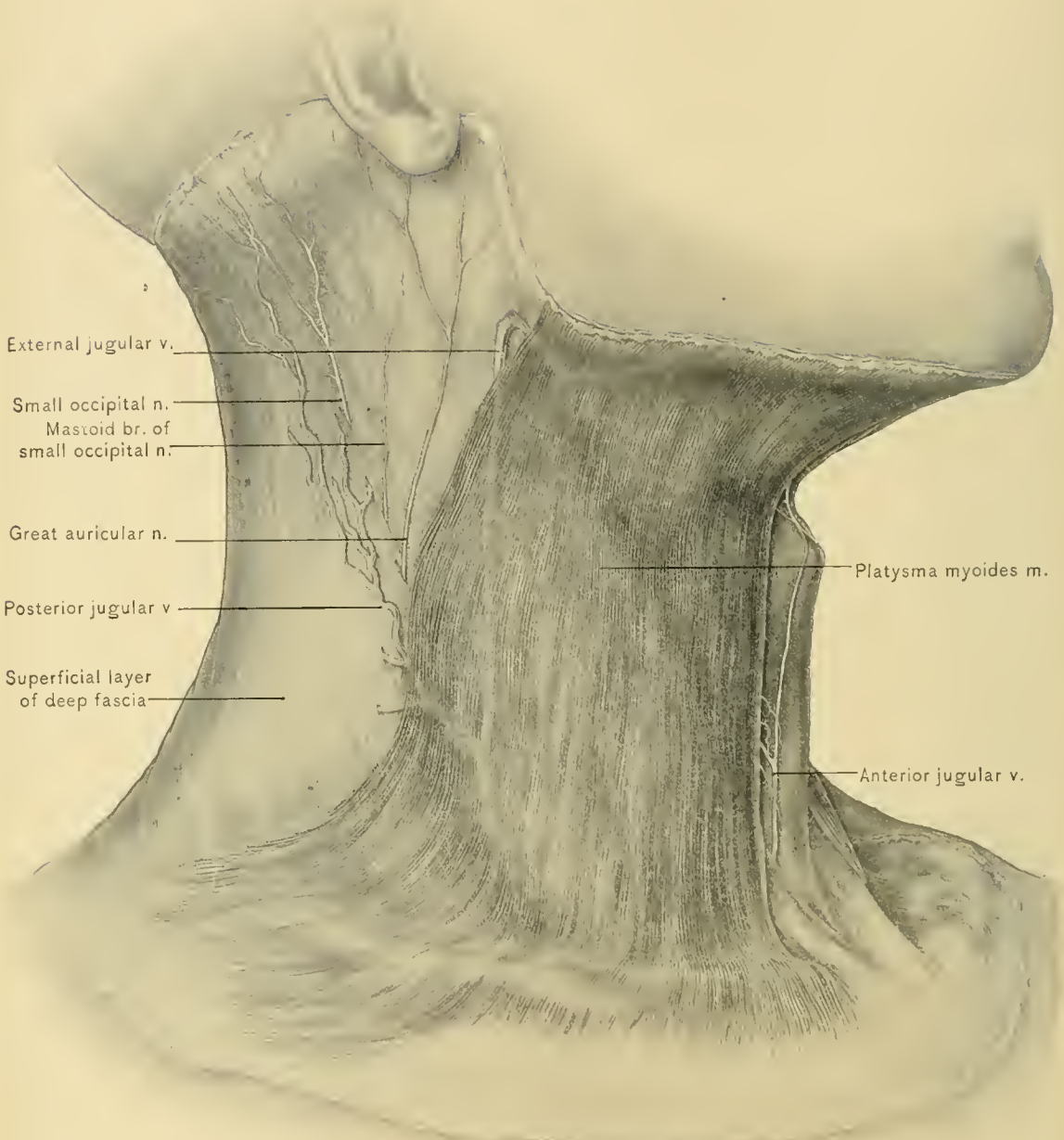
DISSECTION.—The neck should be extended and made prominent by placing a block beneath the shoulders. An incision should be carried from the symphysis of the lower jaw down the middle line of the neck, to the middle of the top of the sternum; a second and a third incision should be made, the former along the clavicle to the acromion process, the latter along the lower border of the lower jaw to the angle of the jaw, thence to the lobe of the ear, and behind the ear to the transverse incision made in dissecting the scalp. The face should then be turned away from the side on which the dissection is being made, and retained in position with hooks, the skin being raised and reflected from before backward to beyond the anterior border of the trapezius muscle.

The **skin covering the side of the neck** is thin, quite elastic, and can readily be raised into folds, which always contain the platysma myoides muscle; these conditions favor the performance of plastic operations. In these respects it differs from the skin over the nape of the neck, which is very dense and adherent and more freely supplied with nerves, but not nearly so well supplied with blood vessels. *Carbuncle* is usually seen at the lower part of the back of the neck near the median line. The nape of the neck was formerly a common site for the introduction of *setons* and the application of *issues*.

The **superficial fascia** now exposed is a very thin lamina of areolar and adipose tissue, divisible, as elsewhere, into two layers, the deep one being a very deli-



INCISIONS FOR DISSECTION AND LINES FOR VESSELS AND NERVES.



External jugular v.

Small occipital n.
Mastoid br. of
small occipital n.

Great auricular n.

Posterior jugular v.

Superficial layer
of deep fascia

Platysma myoides m.

Anterior jugular v.

PLATYSMA MYOIDES MUSCLE.

cate layer of laminated tissue. Between these two layers are the platysma myoides muscle, the external, anterior, and posterior jugular veins, the superficial branches of the cervical plexus of nerves, and the infra-maxillary branch of the cervico-facial division of the facial nerve. The fat in the superficial fascia above the hyoid bone may be extensively developed and produce the condition known as "double chin."

DISSECTION.—The superficial layer of the superficial fascia should be removed in the manner practised in reflecting the skin. This dissection exposes the platysma myoides muscle.

The **platysma myoides muscle** (the superficial cervical), a broad, thin muscle, lies immediately beneath the skin and the superficial layer of the superficial fascia; it covers the front and side of the neck, extending from the summit of the shoulder and front of the chest to the face. This muscle is a member of the panniculus carnosus group. It arises from the deep fascia covering the pectoralis major, deltoid, and trapezius muscles, and ascends obliquely forward along the side of the neck, for insertion into the lower border of the lower jaw, the superficial fascia of the cheek, the muscles at the angle of the mouth, and the integument of the chin. The anterior fibers cross those of the opposite side just below the symphysis of the lower jaw, and are inserted into the integument of the chin; the middle fibers are attached to the lower border of the lower jaw; the posterior fibers are prolonged over the masseter muscle, and are inserted into the superficial fascia of the cheek and the muscles at the angle of the mouth. Those fibers passing transversely to the angle of the mouth constitute the **risorius muscle**.

NERVE SUPPLY.—From the infra-maxillary branch of the cervico-facial division of the facial and the superficial cervical nerves.

BLOOD SUPPLY.—From the vessels ramifying in the superficial fascia of the neck.

ACTION.—It draws the lower lip downward and outward by contraction of its upper fibers; when all the fibers are contracted, however, the skin and superficial fascia of the neck between the clavicle and lower jaw are raised, being made taut between these two bones; it also helps to depress the lower jaw, or, if the jaw be fixed, assists the opposite sterno-mastoid muscle in flexion and rotation of the head toward its own side. The anterior edge of the muscle is distinctly visible in emaciated and aged persons, forming, with the platysma of the opposite side, two divergent folds descending from a little below the chin. As the muscle dips into a depression above the clavicle, by elevation of skin and fasciæ at the root of the neck, it relieves pressure upon the veins and favors the return circulation.

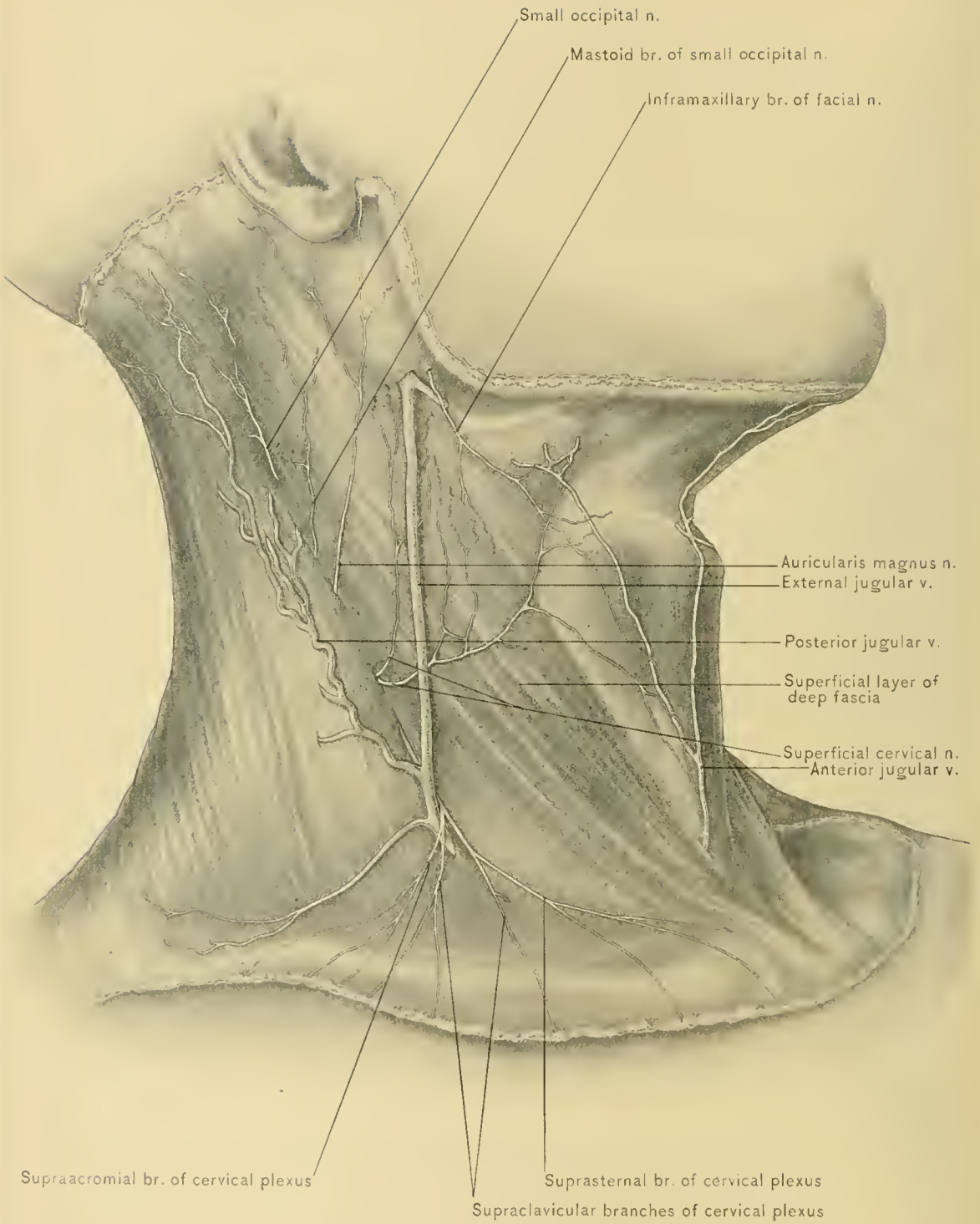
Injuries of the neck, with destruction of considerable portions of the integument and platysma, as in burns, are usually followed by deformity from cicatricial contraction. Pus in the loose tissues under the platysma may burrow extensively,

descending from the submaxillary region to the upper part of the chest-wall, where pointing may occur.

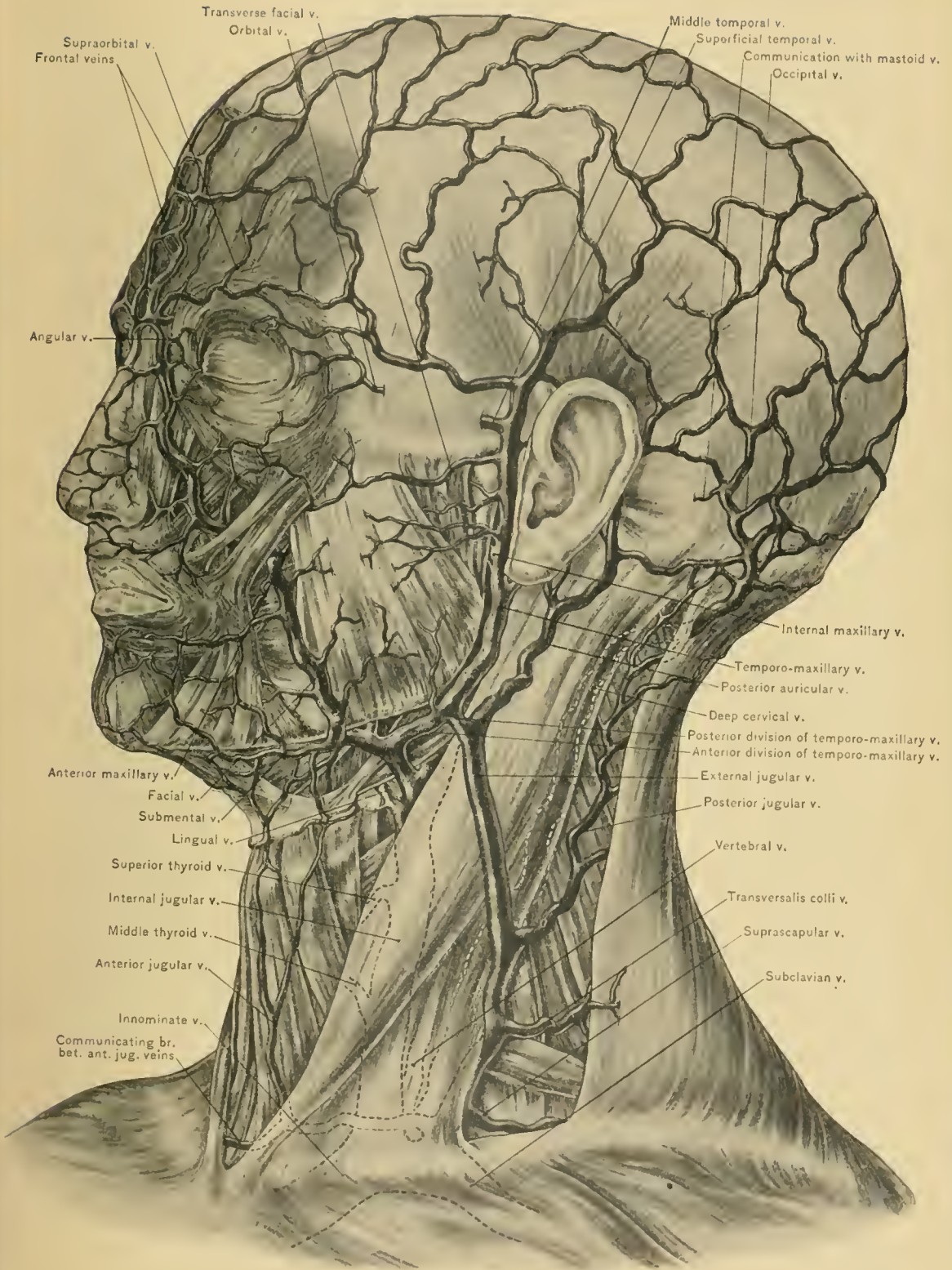
DISSECTION.—The platysma should now be removed, cutting it across near the clavicle and reflecting it upward to its insertion into the jaw, thus exposing the subcutaneous portions of the superficial branches of the cervical plexus of nerves, the infra-maxillary branch of the cervico-facial division of the facial nerve, and the anterior, external, and posterior jugular veins.

The **external jugular vein** arises in the substance of the parotid gland, and is formed by the union of the posterior auricular vein and the posterior division of the temporo-maxillary vein. It runs down the neck in a *line* drawn from the angle of the lower jaw to the middle of the clavicle, first passing over the sternomastoid muscle, and then along its posterior border to the root of the neck, there piercing the superficial layer of the deep cervical fascia to enter the subclavian vein in the subclavian triangle. This fascia is so closely attached to the vein that at the root of the neck, if the vein be divided, it will remain open. The **auricularis magnus nerve**, a branch of the cervical plexus, accompanies the vein in its upper part, and the superficial cervical branch of the same plexus passes beneath it at about the middle of the course of the vein. The posterior external jugular, transversalis colli, and supra-scapular veins empty into the external jugular vein. Near the angle of the lower jaw the external jugular communicates with the internal jugular vein by a large branch, farther down with the anterior jugular, and, at times, with the cephalic vein by a branch (jugulo-cephalic) which passes over the clavicle. The anterior jugular vein occasionally empties into the external jugular instead of into the subclavian vein. The external jugular vein contains a pair of valves at its point of entrance into the subclavian, and another pair about one inch or one and one-half inches above this point; these valves can not prevent the reflux of blood into the external jugular vein, and in certain cardiac and aortic diseases, especially in tricuspid insufficiency, a pulsation in the external jugular vein synchronous with the cardiac systole may be observed. The portion of the vein between the valves is dilated; this portion is called the **sinus**. The external jugular vein varies in size—when the anterior and posterior jugular veins are large, the external jugular vein is small, and vice versâ. In some instances two external jugular veins may be observed upon each side of the neck. The superficial cervical nerve may, at times, be seen to pierce the wall of the vein.

Venesection.—The operation of phlebotomy, or venesection, may be performed upon the external jugular vein. When the lower portion of the vein is selected for the operation, the direction the fibers of the platysma myoides muscle should be borne in mind, and the incision be made across them. They will then retract and pull the wound open, thus allowing the blood to flow freely and



SUPERFICIAL LAYER OF DEEP FASCIA, SUPERFICIAL VEINS AND NERVES.



VEINS OF SCALP, FACE, AND NECK.

avoiding its extravasation beneath the platysma. The vein is incised obliquely, not transversely, and should not be completely severed, as hemorrhage from a partially divided vessel is more copious. The hemorrhage may be checked by relieving the pressure applied to the vein at the root of the neck, and by application of a sterile compress over the wound. When the upper portion of the external jugular is selected, the incision should be carried in the line of the fibers of the sterno-mastoid muscle. The external jugular vein may be selected as one of the channels for the intra-venous injection of saline solution.

A chain of small lymphatic glands (superficial cervical), varying in number from four to six, lies along the course of the external jugular vein.

The **posterior external jugular vein** commences in the upper and back part of the neck, between the splenius and trapezius muscles, draining this territory and entering the lower portion of the external jugular vein. It occasionally receives the occipital vein. In the fetus it drains the intra-cranial region through a vein transmitted by the post-glenoid foramen, the remnant of which vein is the **mastoid vein**. The transversalis colli and supra-scapular veins frequently empty into the posterior external jugular vein.

The **anterior jugular vein** arises beneath the chin. It is formed by the mental, submental, inferior labial, and inferior hyoid veins, and passes downward, almost to the sternum, in advance of the anterior border of the sterno-mastoid muscle. Here it pierces the superficial layer of the deep cervical fascia, and occupies the interval (supra-sternal intra-aponeurotic space of Grüber) above the sternum, made by the division of the superficial layer of the deep cervical fascia into two layers; it then turns outward beneath the sterno-mastoid muscle, and enters the external jugular or the subclavian vein. It drains the skin and muscles of the anterior or median region of the neck. In making a subcutaneous section of the sterno-mastoid muscle for the correction of wryneck (*torticollis*), the tenotome must hug the under surface of the origins of the muscle closely, otherwise the anterior, external, and internal jugular veins may be injured. There are usually two anterior jugular veins, one upon each side of the median line of the neck, connected just above the sternum by a transverse branch. This branch also occupies the interval between the two layers of the superficial layer of the deep cervical fascia, and being quite large at times, should be borne in mind when performing the low operation of tracheotomy. In labored breathing, due either to laryngeal or tracheal obstruction, these veins will be much dilated, and care will be required in incising the median line of the neck, to prevent opening one or the other. Should this accident occur in the operation of tracheotomy, while not a serious complication, it may cause some embarrassment. Division of the transverse branch connecting the anterior jugulars at the root of the neck

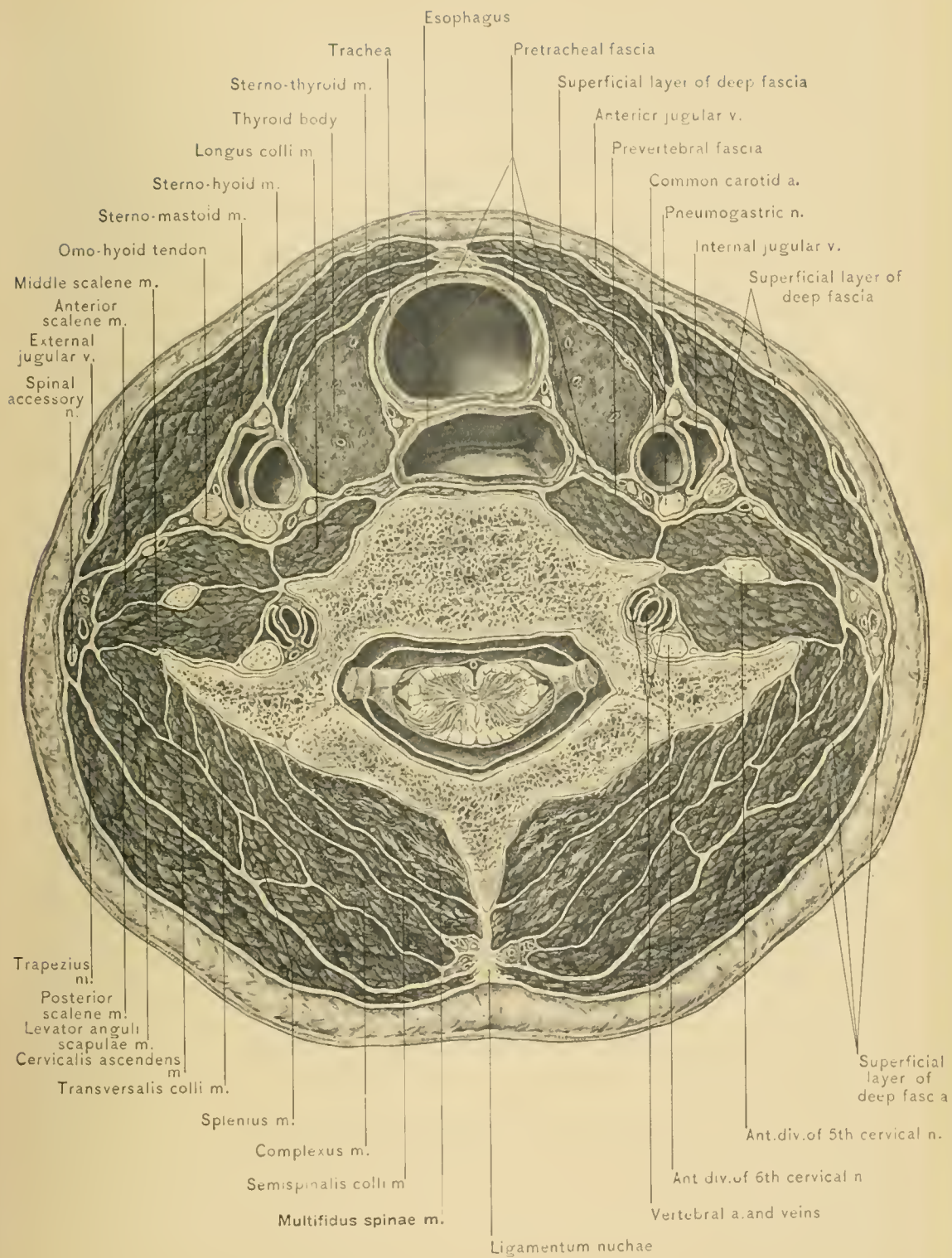
will occasion very free bleeding; this might mislead the surgeon in performing his first tracheotomy, leading him to think that he had opened an anomalously high left innominate vein. The anterior jugular vein contains no valves, and its variation in size, in inverse proportion to the other jugular veins, should be remembered.

DISSECTION.—Next trace the superficial branches of the cervical plexus and the infra-maxillary branch of the cervico-facial division of the facial nerve.

The **superficial branches of the cervical plexus of nerves** are divided into the ascending, transverse, and descending branches. The ascending branches are the occipitalis minor and auricularis magnus nerves. The transverse branch is the superficial cervical nerve. The descending branches are the supra-sternal, supra-clavicular, and supra-acromial nerves.

The **occipitalis minor nerve** arises from the anterior division of the second cervical nerve. It forms beneath the sterno-mastoid muscle a loop which embraces the spinal accessory nerve; it also furnishes a branch to the spinal accessory nerve, and emerges from beneath the posterior border of the sterno-mastoid just above the middle of the muscle. This loop acts as a guide in locating the spinal accessory nerve. The occipitalis minor nerve ascends along the upper half of the posterior border of the sterno-mastoid muscle to the occiput, where it pierces the superficial layer of the deep cervical fascia. It is distributed to the integument covering the occipitalis muscle, and communicates with the great occipital, the auricularis magnus, and the posterior auricular branch of the facial nerve. It also gives off an auricular branch which supplies the skin of the upper and back part of the auricle.

The **auricularis magnus nerve**, the largest of the superficial branches of the cervical plexus, arises from the anterior division of the second and third cervical nerves, and curves around the posterior border of the sterno-mastoid muscle immediately above the superficial cervical nerve. Here it pierces the superficial layer of the deep cervical fascia, ascends in relation with the upper part of the external jugular vein, and passes obliquely over the sterno-mastoid and beneath the platysma myoides muscle. Reaching the lobule of the ear it divides into the following branches: a *facial* or anterior, distributed to the skin over the parotid gland, and communicating with branches from the facial nerve through this gland, which it also supplies; an *auricular* or posterior, distributed to the integument on the back of the auricle, and communicating with the posterior auricular branch of the facial and the auricular branch of the pneumogastric nerve; and a *mastoid branch*, distributed to the skin over the mastoid process, communicating with the occipitalis minor and the posterior auricular branch of the facial nerve.



SECTION OF NECK AT SIXTH CERVICAL VERTEBRA.

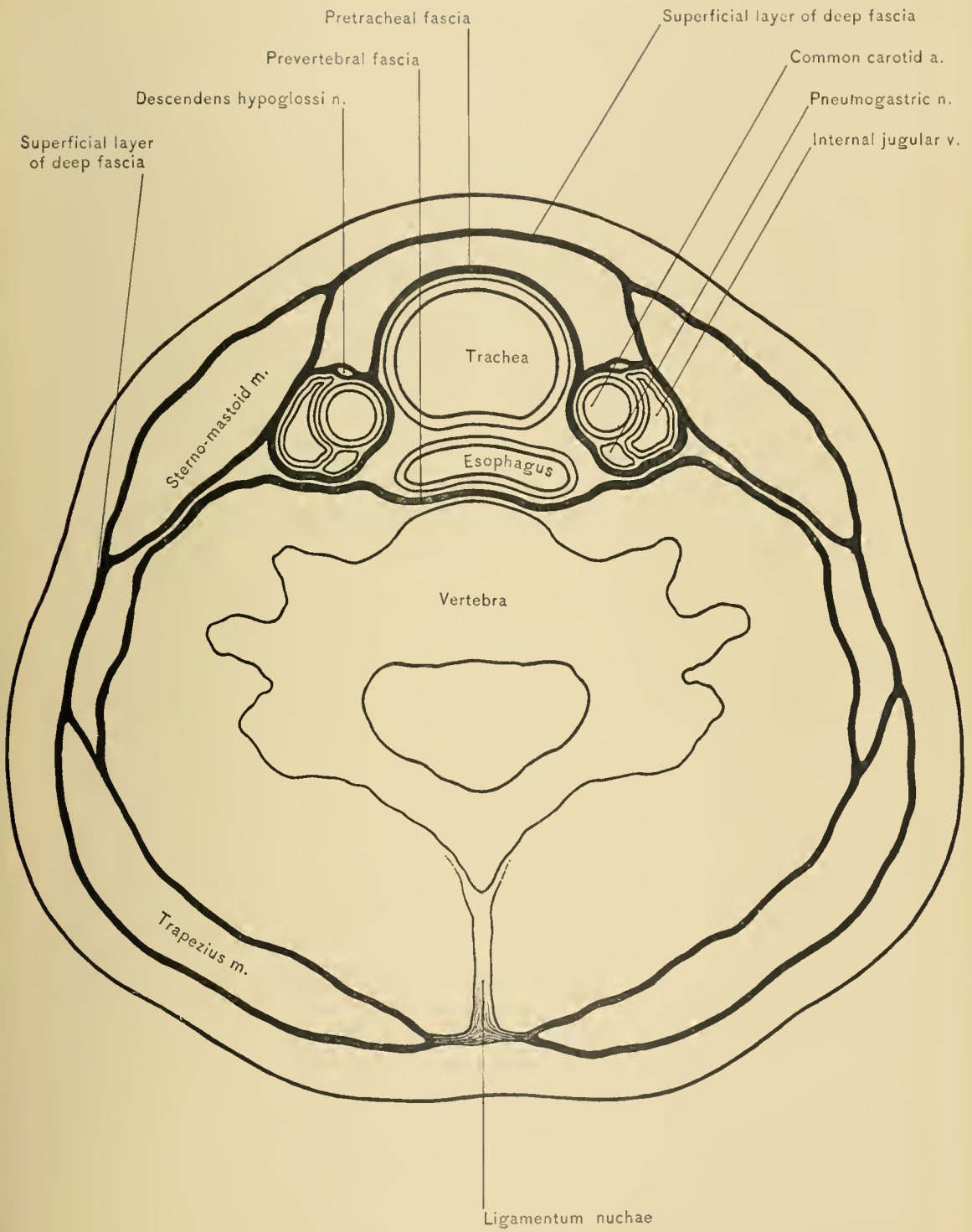

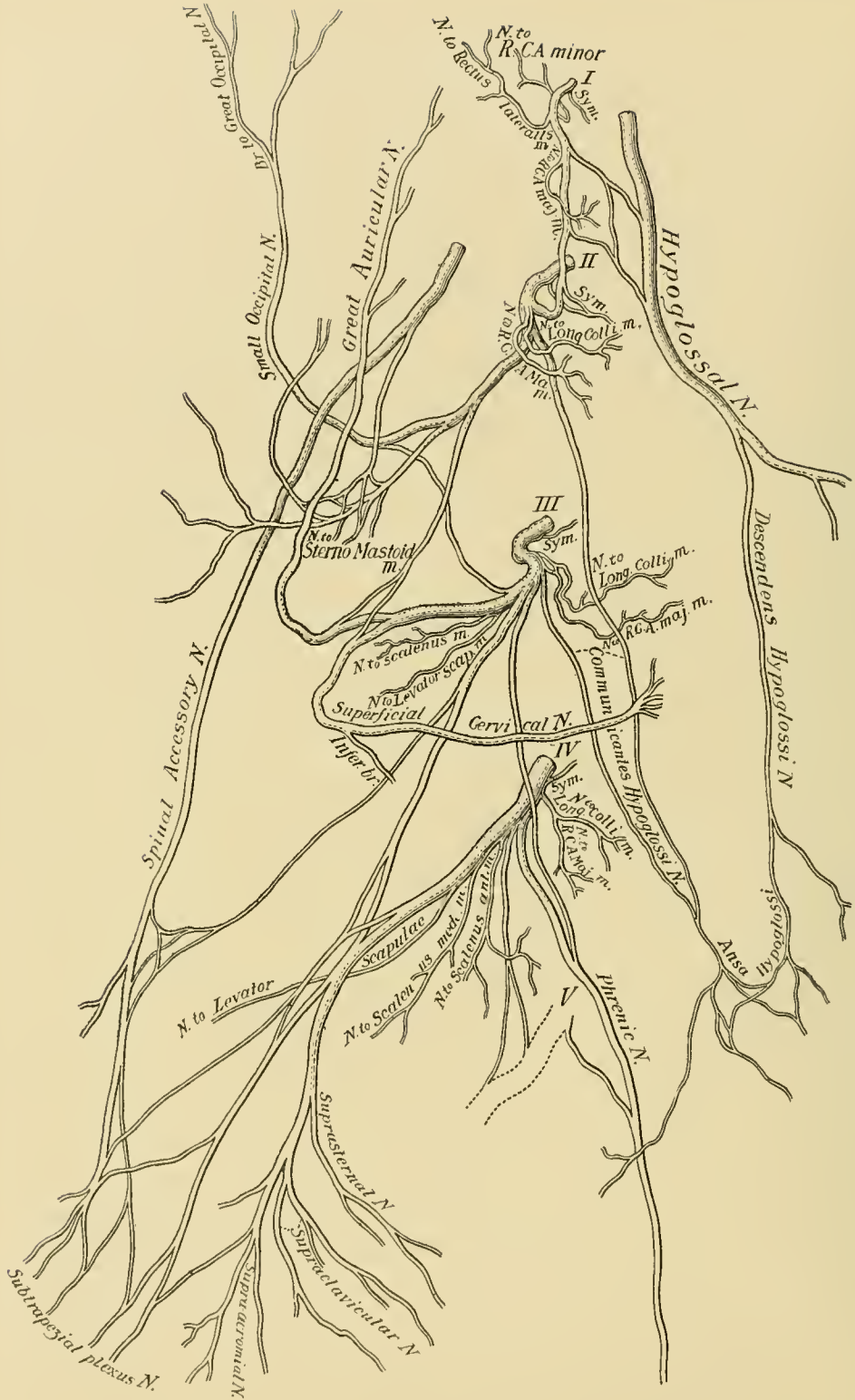


DIAGRAM OF DEEP CERVICAL FASCIA.





CERVICAL PLEXUS.

The **superficial cervical nerve** (*superficialis colli*) is a branch of the anterior divisions of the second and third cervical nerves. It winds around the middle of the posterior border of the sterno-mastoid muscle, pierces the superficial layer of the deep cervical fascia, and passes transversely over the muscle beneath the external jugular vein, receiving a communicating branch from the infra-maxillary branch of the facial nerve. It divides into an *ascending* and a *descending* branch; the former sends filaments to the external jugular vein, communicates with the infra-maxillary branch of the facial nerve, and supplies the platysma myoides muscle and the skin of the front of the neck as far as the chin; the latter supplies the skin of the lower half of the front of the neck.

The **descending branch of the plexus** arises from the anterior divisions of the third and fourth cervical nerves, emerges from beneath the posterior border of the sterno-mastoid muscle, pierces the superficial layer of the deep cervical fascia, and divides into the supra-sternal, supra-clavicular, and supra-acromial nerves. The inner or *supra-sternal* twigs pass over the clavicular and sternal origins of the sterno-mastoid muscle, and supply the integument over the inner end of the clavicle and the upper part of the sternum; the middle or *supra-clavicular* branches cross the middle of the clavicle, supply the integument over the upper fore part of the deltoid and upper part of the pectoralis major muscle and the mammary gland, and communicate with the small cutaneous branches of the upper intercostal nerves; the external or *supra-acromial* branches cross the upper surface of the trapezius muscle and the acromion process, and supply the integument of the upper, outer, and back part of the shoulder. Herpetic eruptions in the area of distribution of the superficial branches of the cervical plexus (*herpes cervico-occipitalis*) are occasionally seen. In caries of the cervical vertebræ pain may be referred to the areas of skin supplied by these nerves. It is through the descending branches of the cervical plexus that pain is referred to the neck in carcinoma of the mammary gland.

The **infra-maxillary branch of the cervico-facial division of the facial nerve** emerges from the lower border of the parotid gland, and passes downward and forward under the platysma myoides muscle, which it supplies, and communicates with the superficial cervical nerve.

The **deep cervical fascia**, like the deep fascia in other portions of the body, consists of a superficial layer which surrounds the underlying muscles, vessels, and nerves, and of processes prolonged inward to form separate sheaths for the muscles and vessels, thus isolating and helping to retain them in their proper positions. It varies in strength, being strongest below the angle of the lower jaw, above the clavicle, and in front of the trachea. In studying this fascia it will be found more satisfactory to trace it from behind, where it is attached to the ligamentum nuchæ

and the spinous process of the seventh cervical vertebra (vertebra prominens). At the ligamentum nuchæ the *superficial layer* immediately begins as two layers, which inclose the trapezius muscle. From the anterior border of the trapezius it passes as a single layer across the posterior triangle of the neck to the posterior border of the sterno-mastoid muscle. This portion of the superficial layer is attached above to the mastoid process of the temporal and superior curved line of the occipital bone, and below to the clavicle. It is pierced by the external jugular vein directly above the clavicle, behind the clavicular origin of the sterno-mastoid muscle. At the posterior border of the sterno-mastoid muscle it again splits into two layers to inclose the muscle, from the anterior border of which it is continued as a single layer across the anterior triangle of the neck to the middle line, where it joins the corresponding layer of fascia of the opposite side. This portion of the superficial layer is attached above to the lower border of the lower jaw and the styloid process of the temporal bone, and in front to the hyoid bone. Near the upper border of the sternum this layer of fascia divides into two layers, an anterior and a posterior, which are attached respectively to the anterior and posterior margins of the upper border of the sternum. Between these two layers is an interval (the supra-sternal intra-aponeurotic space of Grüber) containing some fat, perhaps one or two small lymphatic glands, the sternal head of the sterno-mastoid muscle, the anterior jugular veins, and the transverse branch connecting them. The layer of fascia overlying the sterno-mastoid muscle is continued upon the face over the parotid gland and the masseter muscle as the parotid and masseteric fasciæ, which are attached to the lower border of the zygomatic arch.

The portion of the superficial layer covering the trapezius and sterno-mastoid muscles is so thin that their fibers can be seen through the fascia. At the angle of the lower jaw this layer of fascia sends a process inward which is attached to the styloid process, and is known as the **stylo-maxillary ligament**. This ligament separates the parotid from the submaxillary gland. From the superficial layer two processes are given off, a posterior and an anterior. The *posterior process* (*prevertebral fascia*) arises from the superficial layer at the anterior border of the trapezius muscle, and covers the splenius, levator anguli scapulæ, scaleni and prevertebral muscles, subclavian, vertebral, inferior thyroid, supra-scapular, and transversalis colli vessels, cervical trunks of the axillary or brachial plexus, phrenic nerve, and cervical sympathetic nerve. This process of fascia passes behind the common carotid artery, internal jugular vein, pharynx, and esophagus. It is attached above to the base of the skull; below, to the first rib, as far forward as the anterior margin of the scalenus anticus muscle. To the inner side of this muscle it passes downward into the chest over the longus colli muscle and bodies of the vertebrae. To the outer side of the scalenus anticus muscle it splits to

envelop the subclavian vessels, which it accompanies into the axilla, where, with a process from the costo-coracoid membrane, it forms the sheath of the axillary vessels. As it passes behind the common carotid artery and internal jugular vein it reinforces the sheath of these vessels. The *anterior process* (*pretracheal fascia*) arises from the superficial layer near the anterior border of the sterno-mastoid muscle, passes beneath the sterno-hyoid and sterno-thyroid muscles, and in front of the trachea, enveloping the thyroid gland. It is attached to the first rib, to which it binds the tendon of the omo-hyoid muscle. This, with the posterior process just described, and the layer of deep fascia beneath the sterno-mastoid muscle, complete the formation of the sheath of the common carotid artery and internal jugular vein. The portion of the deep cervical fascia which envelops the trachea and great vessels extends downward along the great vessels into the chest, where it is continuous with the fibrous layer of the pericardium.

The superficial layer of the deep cervical fascia, with its two deep processes, divides the neck into three compartments: an anterior, a middle, and a posterior. The anterior compartment, between the superficial layer and the pretracheal fascia, contains the anterior belly of the omo-hyoid, the sterno-hyoid, and sterno-thyroid muscles. The middle or visceral compartment, between the pretracheal and prevertebral fasciæ, contains the thyroid gland, trachea, and esophagus. The posterior or muscular compartment, between the prevertebral fascia and the superficial layer, contains the prevertebral muscles, *scaleni*, *levator anguli scapulæ*, and the muscles of the back of the neck, excepting the *trapezius*.

Dr. Allan Burns first called the attention of the profession to the barrier at the upper opening of the chest, formed by the attachment of the deep cervical fascia to the sternum, the first rib, and the clavicle, supporting the soft parts and preventing them from yielding to the pressure of the atmosphere during inspiration. The internal jugular, subclavian, and innominate veins are so closely attached to the adjacent bones and muscles by the deep cervical fascia that they gape when divided, thus permitting air to enter. In operations on the neck, when these veins are exposed and division is necessary, it is best to ligate them before severing them.

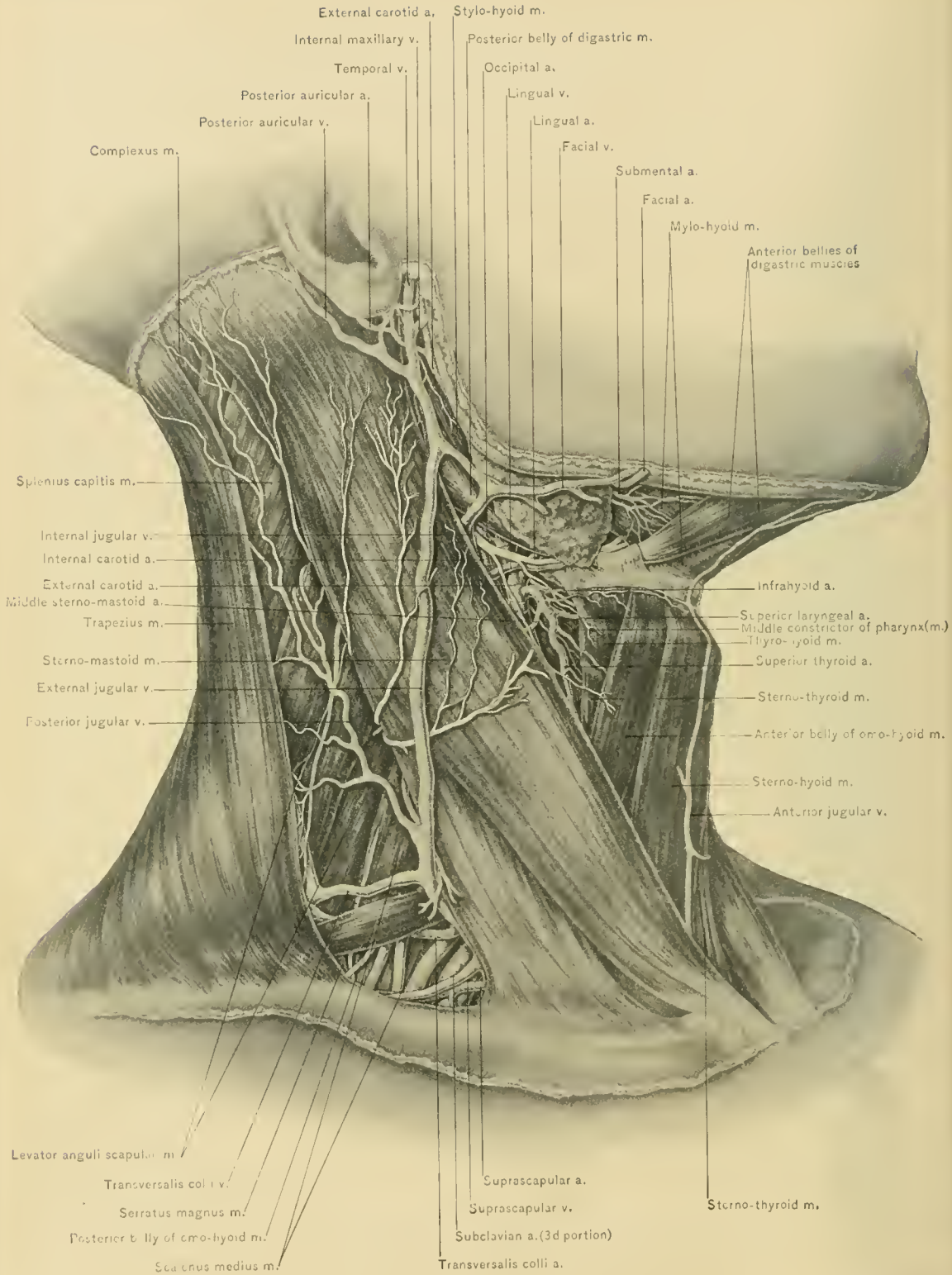
Abscess.—In order to become familiar with the course pus pursues in the neck, a correct knowledge of the attachments of the deep cervical fascia is necessary. A collection of pus situated beneath the superficial layer of the deep fascia at the side of the neck may burrow into the axilla, and, vice versâ, one in the axilla may work its way into the neck; if situated beneath the layer of deep fascia (posterior process or prevertebral fascia) covering the *scaleni* muscles, and attached to the first rib as far forward as the anterior border of the anterior scalene muscle, it may burrow into the chest cavity, reaching the posterior mediastinum, or follow

the sheath of the subclavian vessels into the arm-pit; if situated beneath the superficial layer of the deep fascia in the anterior portion of the neck, it may enter the chest, being guided into the anterior mediastinum by the pretracheal fascia; if it lie beneath the anterior process, or pretracheal fascia, it may extend into the posterior mediastinum. Abscesses of the neck have frequently burst into the esophagus or trachea, and even into the pleural sac; the great vessels at the side of the neck have in some instances been entered. "In one remarkable case, reported by Mr. Savory, not only was a considerable portion of the common carotid artery destroyed by the abscess, but a still larger portion of the internal jugular vein and a large part of the vagus nerve were also destroyed" (Treves). Mr. Jacobson (Hilton, on "Rest and Pain") states that "communication between abscesses and the deep vessels has usually taken place beneath two of the strongest fasciæ in the body—the deep cervical and the fascia lata." Prompt evacuation is indicated by the possibility that these abscesses may take one or more of the foregoing undesirable courses.

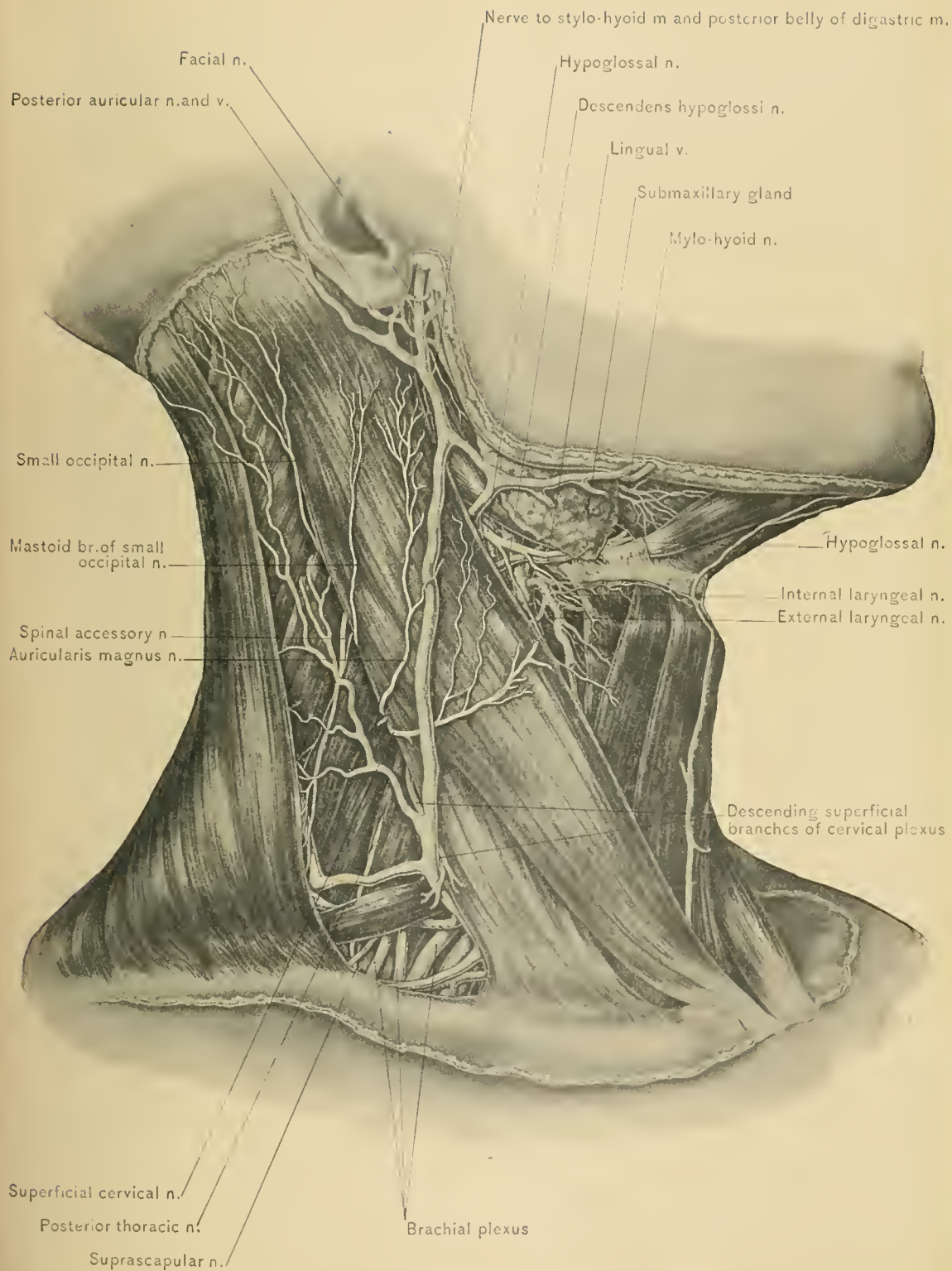
DISSECTION.—The superficial layer of the deep fascia should be removed by making incisions similar to those made for the removal of the skin and the superficial fascia, being careful not to destroy the superficial branches of the cervical plexus of nerves which pierce it. The removal of the superficial layer will expose its two processes and other underlying structures.

Cervical plexus.—Before taking up the description of the muscles of the neck and its dissection proper, the origins of the superficial branches of the cervical plexus of nerves should be studied. This plexus is formed by the communication of the anterior divisions of the upper four cervical nerves, all of which communicate with the sympathetic nerve. It lies under the sterno-mastoid muscle, opposite the upper four cervical vertebræ, and rests upon the levator anguli scapulae and scalenus medius muscles. Its branches consist of a superficial and a deep set. The *superficial branches*, as previously described, are the auricularis magnus, the occipitalis minor, the superficial cervical, the supra-sternal, the supra-clavicular, and the supra-acromial, all running to the skin and subcutaneous structures. The *deep branches* are the phrenic, the communicantes hypoglossi, communicating, and muscular. The superficial branches alone concern us in this stage of the dissection. They emerge at the side of the neck from beneath the posterior border of the sterno-mastoid muscle, at the level of the upper border of the thyroid cartilage.

The **sterno-cleido-mastoid muscle**, the largest muscle of the neck and its most important landmark, arises by two heads: one, round and tendinous, from the front of the upper portion of the sternum; the other, flattened, partly muscular and partly tendinous, from the inner one-third of the upper surface



SUPERFICIAL STRUCTURES OF NECK.



SUPERFICIAL STRUCTURES OF NECK.

of the clavicle. These two heads unite at a variable distance from the clavicle. The muscle is inserted into the external surface of the mastoid process of the temporal bone by a strong, thick tendon, and into the outer two-thirds of the superior curved line of the occipital bone by a thin aponeurosis. The muscle is narrower in the middle than at either extremity. Its anterior border is the surgeon's *guide* in the ligation of the common, external, and internal carotid arteries, the superior thyroid, lingual, facial, and occipital arteries at their origin, and the inferior thyroid artery as it enters the thyroid gland; in exposing the spinal accessory nerve; upon the left side in the operation of esophagotomy; and in all other operations upon the front of the side of the neck. The posterior border of the muscle is a guide in the ligation of the subclavian and vertebral arteries; the inferior thyroid artery at its origin; in stretching the spinal accessory nerve, the superficial branches of the cervical plexus, and the cervical trunks of the brachial or axillary plexus; and in all other operations upon the posterior portion of the side of the neck.

BLOOD SUPPLY.—From the superior, middle, and inferior sterno-mastoid arteries. The superior sterno-mastoid is a branch of the occipital artery, and enters the muscle with the spinal accessory nerve; the middle sterno-mastoid is a branch of the superior thyroid artery, and enters the middle one-third of the muscle, after crossing the sheath of the common carotid artery in the superior carotid triangle on a level with the thyroid cartilage; the inferior sterno-mastoid is a branch of the supra-scapular artery, and enters the lower one-third of the muscle. The muscle also receives a twig from the posterior auricular artery.

NERVE SUPPLY.—From the spinal accessory and the anterior divisions of the second and third cervical nerves.

ACTION.—The combined action of the sterno-mastoid muscles is to draw the head forward, elevating the chin at the same time; when one muscle alone acts, it turns the face to the opposite side, cooperating with the opposite splenius muscle; it also draws the head toward the shoulder of the same side. If the head be fixed, these muscles will raise the sternum, as in forced respiration.

Torticollis.—Permanent contraction of one of the sterno-mastoid muscles constitutes torticollis (wryneck). The deep muscles of the neck—splenius capitis et colli, complexus, superior oblique, inferior oblique, and rectus capitis posticus major—may also be involved in this deformity, particularly in cases of long standing.

In true congenital wryneck, due possibly to faulty position of the fetus *in utero*, the sterno-mastoid muscle has, in some instances, been found to be abnormally short. Some cases of wryneck are doubtless due to laceration of the muscle during birth, with subsequent cicatricial contraction. Facial asymmetry

and deformities of the cervical portion of the spinal column may be associated with long-standing cases of torticollis. In spasmodic wryneck the sterno-cleido-mastoid muscle is at fault, through the spinal accessory nerve, though some of the muscles previously mentioned, as well as the trapezius muscle, may be involved; resection of the spinal accessory and branches of the posterior divisions of the cervical nerves has been performed in these cases. It should not be forgotten that irritation of some of the cervical nerves, as by inflamed lymph glands and caries of the cervical vertebræ, may cause a faulty position of the head which may be mistaken for torticollis due to other conditions.

TRIANGLES OF THE NECK.

The sterno-mastoid muscle, owing to its oblique position, divides each half of the neck into two triangles—the anterior and posterior common triangles. The **Anterior Common Triangle** is bounded above by the lower border of the body of the lower jaw and a line extending from the angle of the lower jaw to the mastoid process of the temporal bone; in front, by a line extending from the symphysis of the lower jaw to the middle of the supra-sternal notch, or by the median line of the neck; and behind, by the anterior border of the sterno-mastoid muscle; its apex is below—at the sternum. This triangle is subdivided into three smaller ones by the posterior belly of the digastric muscle and the anterior belly of the omo-hyoid muscle. The three triangles, from above downward, are the *submaxillary or digastric*, the *superior carotid*, and the *inferior carotid*. The **Posterior Common Triangle** is bounded in front by the posterior border of the sterno-mastoid muscle; behind, by the anterior border of the trapezius muscle; and below, by the clavicle; its apex is above—at the occiput. This triangle is subdivided into two smaller triangles by the posterior belly of the omo-hyoid muscle, the upper, the larger of the two, being known as the *occipital*, and the lower, the smaller, as the *subclavian*, triangle.

The author would here remind the reader that the boundaries of these triangles by muscular margins do not harmonize with the enumeration of their contents, many of which are overlapped by the boundary muscles, particularly the sterno-mastoid, and are, therefore, really outside the spaces to which they are thus inaccurately accredited. The most accurate dividing line between the anterior and posterior triangles would be the middle line of the sterno-mastoid muscle rather than its two borders.

DISSECTION.—Having mapped out the triangles into which the side of the neck is divided, the dissection of the individual triangles should next be made, commencing with the occipital, the largest. After reflecting the superficial layer

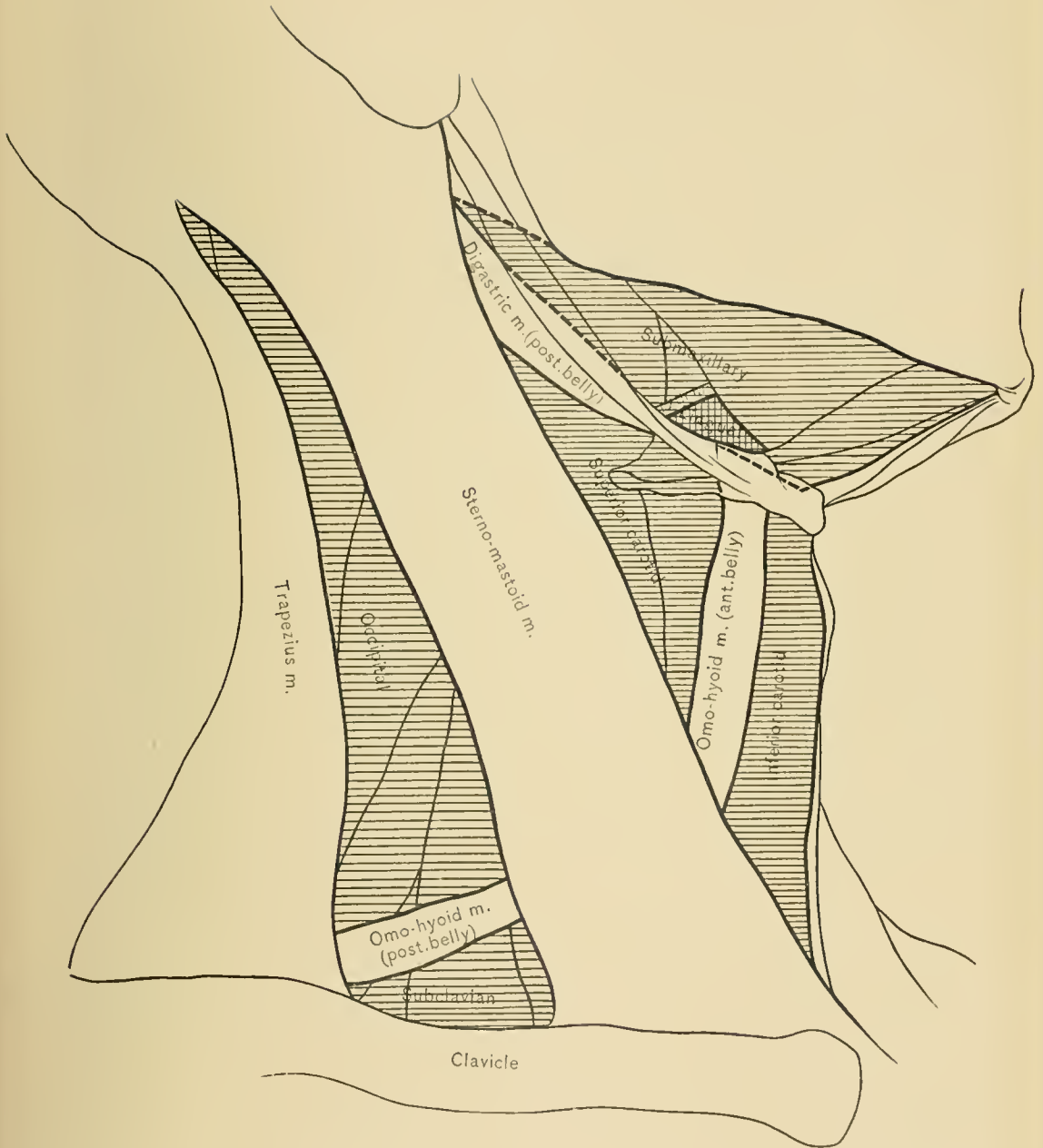


DIAGRAM OF TRIANGLES OF NECK.

of the deep cervical fascia which forms the roof of the occipital triangle, the fat and areolar tissue occupying the triangle should be dissected out, thus exposing its contents and the posterior process of the deep cervical fascia which covers the muscles forming its floor.

The occipital triangle.—The occipital triangle is bounded in front by the sterno-cleido-mastoid muscle; behind, by the trapezius muscle; below, by the posterior belly of the omo-hyoid muscle. Its *roof* is formed by the superficial layer of the deep cervical fascia, covered by the platysma myoides muscle, superficial fascia, and skin. When the sterno-mastoid and trapezius muscles do not meet at the apex of the triangle, a small portion of the occipital artery may be seen in the interval between the splenius and trapezius muscles. Crossing the triangle obliquely downward and backward from beneath the sterno-mastoid muscle are the spinal accessory nerve and the branches of the third and fourth cervical nerves, which enter the lower part of the trapezius muscle to supply it. Emerging from beneath the posterior border of the sterno-mastoid muscle are the superficial branches of the cervical plexus of nerves, which leave the triangle by piercing its roof. Occasionally the middle sterno-mastoid artery terminates in this triangle. Running along the posterior border of the sterno-mastoid muscle is a chain of lymphatic glands; this is known as the post-cervical chain, and is of special importance in the diagnosis of early secondary syphilis. Crossing the lower part of the triangle is the transversalis colli artery and its companion vein. The superficial cervical artery, one of the terminal branches of the transversalis colli, usually occupies the posterior inferior angle of this space; it runs upward, parallel with the anterior border of the trapezius muscle, but is, in some instances, concealed by the anterior border of the trapezius muscle. At the anterior inferior angle of the triangle the upper part of the brachial plexus may be seen. Branches of the third and fourth cervical nerves cross the floor of the triangle to supply the levator anguli scapulæ muscle.

The muscles forming the *floor* of the occipital triangle are, from above downward, the splenius capitis, the levator anguli scapulæ, the scalenus medius, and the scalenus posticus muscle, which can not be seen, however, until the posterior process of the deep cervical fascia is removed.

The spinal accessory nerve.—This nerve is the most important of the contents of the occipital triangle. It is the eleventh cranial nerve, and consists of two parts—the accessory, from the medulla oblongata, and the spinal, from the cervical portion of the spinal cord as low as the sixth or seventh cervical nerve. The spinal portion passes upward through the spinal canal between the ligamentum denticulatum and the posterior roots of the spinal nerves, and enters the cranial cavity through the foramen magnum to join the accessory portion. The two por-

tions emerge from the cranial cavity together through the jugular foramen, just external to which the accessory portion joins the ganglion of the root of the pneumogastric nerve. The spinal portion then passes successively behind the internal jugular vein, the posterior belly of the digastric, and the stylo-hyoid muscle, to enter the upper part of the sterno-mastoid muscle, entering its under surface midway between its two borders and one inch below the tip of the mastoid process. It leaves the muscle at the middle of the posterior border. Within the sterno-mastoid muscle it is joined by a branch of the second cervical nerve. The superior sterno-mastoid artery accompanies the nerve into the muscle, which it supplies. Having pierced the sterno-mastoid muscle, it crosses the occipital triangle obliquely downward and backward to enter and supply the trapezius muscle.

For the relief of spasmodic torticollis, *resection* of a portion of the spinal accessory nerve may be performed. The spinal accessory nerve may be exposed at one of three points—just before it enters the sterno-mastoid muscle, in the substance of the muscle, or at the posterior border of the muscle. Of these methods, the first is the best. To expose the nerve before it enters the muscle, the head and neck should be well extended, and an incision made along the anterior border of the upper one-third of the muscle, dividing skin, superficial fascia, some fibers of the platysma myoides muscle, and the superficial layer of the deep fascia, avoiding, if possible, the external jugular vein. Displace the sterno-mastoid muscle outward, when the nerve will be found beneath the prevertebral fascia and passing from beneath the sheath of the internal jugular vein, to enter the muscle about an inch below the tip of the mastoid process. The prominent transverse process of the atlas lies above the nerve, and serves as a deep guide in locating it.

To expose the nerve in the substance of the sterno-mastoid muscle an incision should be made in the middle line of the muscle. The muscle fibers are separated and the nerve exposed as it passes through the deeper portion just above the level of the thyroid cartilage. The skin, superficial fascia, fibers of the platysma myoides muscle, superficial layer of the deep fascia, the sterno-mastoid muscle, and the superior and middle sterno-mastoid arteries will be cut. The external jugular vein should, if possible, be avoided.

To expose the nerve along the posterior border of the muscle carry an incision along the middle one-third of that border. The skin, superficial fascia, fibers of the platysma myoides muscle, and the superficial layer of the deep fascia will be divided. The occipitalis minor nerve will be seen running upward along the posterior border of the sterno-mastoid muscle. Trace this nerve downward, and locate the spinal accessory nerve as it emerges from the posterior border of the sterno-mastoid muscle on a level with the upper border of the thyroid cartilage.

The **middle sterno-mastoid artery**.—The middle sterno-mastoid artery will

at times be of considerable size and extend well into, if not across, the occipital triangle, supplying the lymphatic glands and connective tissue contained therein. When, on opening an abscess in this triangle, more than the usual amount of bleeding follows, the probability is that an anomalously large middle sterno-mastoid artery has been severed. Under these circumstances the incision should be enlarged to sufficiently expose both ends of the bleeding vessel and permit their ligation. The author recalls a case in which this accident occurred, and the surgeon, believing that but a small subcutaneous vessel had been divided, relied on a compress, and the patient died from hemorrhage. The autopsy revealed a severed large middle sterno-mastoid artery.

The **transversalis colli artery** terminates in the lower part of this triangle, by dividing into the superficial cervical and the posterior scapular artery. The *superficial cervical artery* has been traced to the anterior border of the trapezius muscle, beneath which it anastomoses with the superficial branch of the princeps cervicis artery. The *posterior scapular*, occasionally a branch of the third part of the subclavian artery, passes beneath the levator anguli scapulae muscle, then along the vertebral border of the scapula, running between the insertions of the serratus magnus and rhomboidei muscles to the inferior angle of the scapula, where it anastomoses with the subscapular artery. In its course it gives off branches to the adjacent muscles and anastomoses with the supra-scapular and dorsalis scapulae arteries.

The subclavian or supra-clavicular triangle (trigonum omo-claviculare).—The subclavian triangle, the smaller of the two divisions of the posterior common triangle, is one of the most important triangles of the neck. It is bounded in front by the posterior border of the sterno-mastoid muscle; above, by the posterior belly of the omo-hyoid muscle; and below, by the clavicle. The base of the triangle, formed by the posterior border of the sterno-mastoid muscle, is directed forward. The *roof* of this triangle is formed of the superficial layer of the deep fascia, covered by the platysma myoides muscle, superficial fascia, and skin. The depth of this space is increased when the shoulder is raised and diminished when it is depressed. In all operations in this triangle the shoulder should be depressed, the contents of the triangle being thus brought nearer to the surface. Its size will depend on the extent of the attachment of the trapezius and sterno-mastoid muscles to the clavicle, and on the position of the omo-hyoid muscle.

DISSECTION.—The roof of the triangle having been reflected in removing the superficial layer of the deep fascia, some lymphatic glands, loose areolar tissue, and fat will be seen; a small portion of the external jugular vein is also visible; the termination of the transversalis colli and supra-scapular veins, the jugulo-cephalic vein, when present, and some additional veins from the muscles, the

layer of deep fascia (posterior process) covering the deeper structures,—namely, the scaleni muscles, the phrenic nerve, the cervical trunks of the axillary or brachial plexus of nerves,—and the subclavian, supra-scapular, and transversalis colli vessels will be seen. Remove the posterior process of the deep fascia from the triangle and study these deeper structures.

CONTENTS OF THE SUBCLAVIAN TRIANGLE.—Crossing the lower part of the triangle beneath the clavicle are the *supra-scapular artery and vein*; these vessels pass in front of the third portion of the subclavian artery (the point of election), and may be the source of severe hemorrhage if divided when ligating the artery. The relation of the supra-scapular to the subclavian artery at its point of election is the same as that held by the middle sterno-mastoid artery to the common carotid artery at its point of election. Crossing the upper angle of the triangle are the *transversalis colli artery and vein*. Entering the triangle behind the posterior border of the lower part of the sterno-mastoid muscle is the *external jugular vein*, which passes in front of the subclavian artery to reach the subclavian vein. The external jugular vein is here joined by the supra-scapular and transversalis colli veins, and at times by a small branch (jugulo-cephalic) which passes over the clavicle, connecting the cephalic with the external jugular vein. The supra-scapular, transversalis colli, jugulo-cephalic, posterior external jugular, and some smaller veins at times form a plexus in front of the subclavian artery. This plexus of veins, especially when distended, renders operations in this space difficult. Emerging from beneath the posterior border of the sterno-mastoid and scalenus anticus muscles is the third portion of the *subclavian artery*, which crosses the triangle obliquely downward and outward. The subclavian artery rises in the neck, about three-fourths of an inch above the clavicle. In nearly every instance it runs behind the scalenus anticus muscle, but it may pass in front of that muscle or between its fibers. Normally, the third part of the subclavian artery does not give off any branches; the posterior scapular, however, one of the terminal branches of the transversalis colli artery, often arises from this portion of the vessel; the transversalis colli artery itself, or the supra-scapular artery, may arise from the third portion of the subclavian artery. The *subclavian vein* occupies a position below and anterior to the artery, not being visible frequently in a dissection of the subclavian triangle. It lies upon the first rib, in front of the anterior scalene muscle, and behind the clavicle. Passing downward over the anterior scalene muscle, beneath the posterior process of the deep fascia, is the *phrenic nerve*, which enters the chest through its upper opening, and between the subclavian artery and vein. Running through the upper and outer part of the triangle, above and external to the subclavian artery, are the three cervical trunks of the *axillary or brachial plexus* of nerves, which emerge at the side of the neck from between the anterior and middle scalene muscles. In the opera-

tion of ligation of the third portion of the subclavian artery, the upper trunk of the plexus may be mistaken for the artery, and the ligature passed around it. This trunk is, therefore, a very useful guide in locating the artery, and should always be kept in mind. A few lymphatic glands, which are continuous with the axillary lymphatics, are found in this space. These glands should always be removed in the radical operation for removal of carcinoma of the mammary gland. The triangle is also crossed by the supra-scapular and posterior thoracic nerves and the nerve to the subclavius muscle.

The *floor of the triangle* is formed by the scalenus medius and posticus muscles, the first rib, and the upper digitation of the serratus magnus muscle.

The **inferior carotid triangle** is bounded in front by the median line of the neck; behind, by the anterior border of the sterno-cleido-mastoid muscle; and above, by the anterior belly of the omo-hyoid muscle. The *roof* is formed by the skin, the superficial fascia, which contains the platysma myoides muscle, and the descending branch of the superficial cervical nerve, and by the superficial layer of the deep fascia. The outer margins of the sterno-hyoid and sterno-thyroid, and the anterior margin of the sterno-mastoid muscle cover the more important contents of the triangle, and should be drawn aside before dissecting the deeper structures.

CONTENTS OF THE TRIANGLE.—The common carotid artery (not strictly in the triangle, as the vessels lie under the margin of the sterno-mastoid muscle, but so closely related to the contents of the triangle that mention of it here is proper), the internal jugular vein, and the pneumogastric nerve, all three inclosed in a common sheath, in front of which are filaments of nerves derived from the loop of communication between the descendens hypoglossi, a branch of the hypo-glossal, and the communicantes hypoglossi nerves, which are deep branches of the cervical plexus; behind the sheath of the vessels are the sympathetic nerve and its cardiac branches. Upon the inner side of the sheath of the vessels are the lateral lobe of the thyroid gland, the trachea, the larynx, the esophagus, the inferior or recurrent laryngeal nerve (motor nerve of the larynx), which occupies the groove between the trachea and the esophagus, and the terminal portion of the deep chain of cervical lymphatic glands. To the outer side of the sheath of the vessels, running over the scalenus anticus muscle, is the phrenic nerve. The inferior thyroid artery, a branch of the thyroid axis, passes upward and inward through this space to the outer side of and then behind the sheath of the vessels. Situated deeply in the interval between the longus colli and the scalenus anticus muscle, and behind the sheath of the vessels, are the vertebral artery and its accompanying vein. In this triangle the relation between the internal jugular vein and the common carotid artery differs upon the two sides of the neck; upon the right side the vein

is a little to the outer side of the artery, the two vessels being in the lower part of the triangle, separated by a narrow interval, while on the left side it lies closer to the artery and somewhat overlaps it.

The *floor of the triangle* is formed by the longus colli and scalenus anticus muscles.

The superior carotid triangle is bounded above by the posterior belly of the digastric muscle; behind, by the anterior border of the sterno-mastoid muscle; and below, by the anterior belly of the omo-hyoid muscle; its apex is directed toward the median line of the neck. Its *roof* is formed by the skin, the superficial fascia, the platysma myoides muscle, and the superficial layer of the deep fascia.

CONTENTS OF THE SUPERIOR CAROTID TRIANGLE.—These are: The common carotid artery and its terminal divisions,—the external and the internal carotid,—the internal jugular vein, and the pneumogastric nerve; these are all inclosed in a common sheath, the vein lying to the outer side of the artery and the nerve between, and on a plane posterior to both, resembling the ramrod in a double-barreled gun. The common carotid artery usually divides into the external and internal carotid arteries, on a level with the upper border of the thyroid cartilage; division may, however, take place below or above this point. In this triangle the external carotid artery gives off the superior thyroid, lingual, facial, occipital, and the ascending pharyngeal artery, all of which, excepting the occipital, are accompanied by their corresponding veins on their way to empty into the internal jugular vein. Passing downward in front of the carotid sheath is the descendens hypoglossi nerve, and behind the sheath, the sympathetic nerve. To the outer side of the sheath, above, is the spinal accessory nerve, which pierces the sterno-mastoid muscle; to the inner side of the sheath is the superior laryngeal nerve, a branch of the pneumogastric, accompanied by the superior laryngeal artery, a branch of the superior thyroid artery. Both the superior laryngeal artery and the internal laryngeal branch of the superior laryngeal nerve enter the larynx through the thyro-hyoid membrane. To the inner side of the sheath of the vessels, and a little lower, the superior thyroid artery and the external laryngeal nerve, a branch of the superior laryngeal nerve, are seen passing beneath the sterno-thyroid muscle. The hypoglossal nerve is seen in the upper part of the triangle, curving around the occipital artery at its origin from the external carotid, and crossing over the external and internal carotid arteries. Upon the inner side of the triangle are the upper part of the larynx and the lower portion of the pharynx. In the deep part of the triangle, to the inner side of the sheath of the vessels, are seen the pharynx, the esophagus, and the deep chain of the cervical lymphatic glands, the terminal portion of which has been observed when dissecting the inferior carotid triangle.

The superior carotid is the *triangle of election* for the ligation of the common carotid artery, the artery being more superficial and accessible here. Crossing the sheath of the vessels in this triangle is the middle sterno-mastoid, a small branch of the superior thyroid artery, which is severed in the ligation of the common carotid artery in this triangle.

The *floor of the triangle* is formed by the thyro-hyoid muscle, the hyo-glossus muscle, and the middle and inferior constrictor muscles of the pharynx.

The **submaxillary or digastric triangle**, the uppermost of the three anterior triangles, is bounded above by the lower border of the body of the lower jaw, and a line drawn from the angle of the lower jaw to the mastoid process of the temporal bone; below, by the posterior belly of the digastric and the stylo-hyoid muscle, and the line of these muscles extended to the median line of the neck; and, in front, by the middle line of the neck. Its *roof* is formed by the skin, the superficial fascia, the platysma myoides muscle, and the superficial layer of the deep fascia. The portion of the deep cervical fascia helping to form the roof of this triangle is very strong.

CONTENTS OF THE SUBMAXILLARY TRIANGLE.—The stylo-maxillary ligament, a process of the deep cervical fascia which extends from the styloid process of the temporal bone to the angle of the lower jaw and separates the submaxillary and parotid salivary glands, divides the submaxillary or digastric triangle into two portions, an anterior and a posterior. The posterior portion contains a part of the external carotid artery, embedded in the substance of the parotid gland, the internal carotid artery, the internal jugular vein, the pneumogastric, glosso-pharyngeal, hypo-glossal, and sympathetic nerves, the origins of the stylo-glossus and stylo-pharyngeus muscles, and the stylo-hyoid ligament. The last three of these structures, with the glosso-pharyngeal nerve, pass into the anterior part of the triangle between the internal and external carotid arteries. In addition to the terminal portion of the stylo-pharyngeus and stylo-glossus muscles the anterior portion contains the stylo-hyoid ligament and the glosso-pharyngeal nerve, which pass from the posterior portion, the submaxillary gland, the facial artery and vein, the ascending palatine, tonsillar, submaxillary, and submental branches of the facial artery, all of which arise within the triangle, the hypo-glossal nerve, the mylo-hyoid nerve, the mylo-hyoid artery, and lymphatic glands. A chain of lymphatic glands, ten to fifteen in number, is found below the body of the lower jaw. These glands belong to the superficial cervical lymphatics, and are known as the *submaxillary lymphatic glands*. In malignant growths of the lip, lower jaw, tongue, or oral and pharyngeal mucous membrane, this chain of glands will soon become infected and should always be removed, whether enlarged or not. In the operation for the removal of a malignant growth involving the areas which these glands

drain, the first step should consist in the removal of the submaxillary lymphatic glands of both sides of the neck, and, in some instances, of the submaxillary salivary gland; the final step consists of the removal of the growth. Tuberculosis of these glands is a not uncommon condition, because of the large area from which they receive lymph; infection from inflammatory affections of the pharyngeal, nasal, and oral mucous membranes, as well as from carious teeth, is very frequently the cause of disease of these glands. An extensive cervical cellulitis, known as *Ludwig's angina*, may originate from septic processes in the submaxillary lymphatic glands.

The *floor of the submaxillary triangle* is formed by the mylo-hyoid muscle, the anterior belly of the digastric, the hyo-glossus, the superior constrictor, and a small portion of the middle constrictor muscle of the pharynx.

DISSECTION.—The roof of the triangle having been reflected in removing the superficial layer of the deep cervical fascia, the submaxillary salivary gland, with the exception of its upper portion, which is hidden by the body of the lower jaw, will now be seen. The gland is surrounded by a fibrous capsule, which is derived from the superficial layer of the deep fascia. Displace the submaxillary gland upward upon the face, holding it there with hooks while further dissection of the triangle is made. In displacing the gland avoid severing the facial vein, which passes over it, and the facial artery, which passes through the groove on its deep surfaces.

The lingual triangle.—The portion of the submaxillary or digastric triangle, through which the lingual artery runs, is frequently spoken of as the lingual triangle. In relation with the triangle are the submaxillary gland, the posterior belly and the tendon of the digastric muscle, the hypo-glossal nerve, the hyo-glossus muscle, and the middle constrictor muscle of the pharynx. This subdivision of the submaxillary triangle is bounded above by the hypo-glossal nerve, posteriorly by the posterior belly of the digastric muscle, and anteriorly by the mylo-hyoid muscle; its *roof* is formed by the submaxillary gland, and its *floor* by the hyo-glossus and middle constrictor muscle of the pharynx. In ligating the lingual artery an incision is carried above and parallel with the greater cornu of the hyoid bone; the skin, the superficial fascia, the platysma myoides muscle, and the superficial layer of the deep fascia are divided, and the submaxillary gland is exposed. The gland is lifted upward, when the artery will be found beneath the hyo-glossus muscle and beneath the interval between the hypo-glossal nerve and the tendon of the digastric muscle. In making the incision through the hyo-glossus muscle care must be observed to avoid wounding the middle constrictor muscle, division of which would open the pharynx. It is not necessary to cut the hyo-glossus, as the artery is readily secured before it passes beneath that muscle without endangering the pharynx.

DISSECTION.—Divide the sterno-mastoid muscle at about its middle, and reflect the two portions. This exposes the descendens hypoglossi nerve, which lies upon the sheath of the vessels, the communicantes hypoglossi nerves, the ansa hypoglossi, the tendon of the omo-hyoid muscle, the sheath of the vessels, the spinal accessory nerve, the phrenic nerve, the cervical plexus, the anterior scalene muscle, and a portion of the subclavian vessels and some of their branches. The spinal accessory and phrenic nerves, the cervical plexus, the anterior scalene muscle, and the subclavian vessels are covered by the posterior portion of the two processes of the deep cervical fascia (prevertebral), overlaid by some areolar and fatty tissue. Remove the fat and areolar tissue with the layer of fascia (prevertebral) covering the structures just named, inferior thyroid, and the vertebral supra-scapular, transversalis colli, and vertebral arteries.

THE CERVICAL PLEXUS OF NERVES.

The cervical plexus is formed by the anterior branches of the upper four cervical nerves. It is situated in the upper part of the neck, beneath the sterno-mastoid muscle, and rests upon the scalenus medius and levator anguli scapulae muscles. It differs from the axillary or brachial plexus in resembling a network rather than a bundle of cords. Each nerve, excepting the first, divides into an ascending and a descending branch; these unite with similar parts of the contiguous nerves, thus forming a plexus. The branches of the plexus are divided into a superficial and a deep set; the *superficial set* of branches has been described with the superficial fascia of the neck. The *deep set* of branches is, for convenience, divided into an internal and an external series. The internal series includes the phrenic, communicantes hypoglossi, muscular, and communicating branches; the external series includes muscular and communicating branches.

The **phrenic nerve**, the internal respiratory nerve of Bell, supplies the diaphragm. It arises from the third and fourth cervical nerves, and receives a communicating branch from the fifth. It passes downward and inward over the anterior surface of the anterior scalene muscle, beneath the omo-hyoid muscle, the transversalis colli and supra-scapular arteries, and the thoracic duct (left side), and enters the upper opening of the chest behind the subclavian vein, and in front of the subclavian artery. It then crosses in front of the internal mammary artery, from without inward, and the root of the lung, and passes through the middle mediastinum between the mediastinal layer of the pleura and the pericardium, to reach the diaphragm, which it pierces for final distribution upon its lower surface. At the lower part of the neck it is joined by a filament of the sympathetic nerve, and at times by a branch from the nerve to the subclavius muscle. In the chest it

is accompanied by the *arteria comes nervi phrenici*, a branch of the internal mammary artery. The origin of the phrenic nerve is mainly from the fourth cervical segment of the spinal cord, which is situated behind the upper part of the body of the fourth cervical vertebra, and the fact that this nerve is the one which innervates the diaphragm, explains the fatality due to injury of the spinal cord through fractures and dislocations of the upper cervical vertebrae.

The **communicantes hypoglossi** (*communicantes noni*) arise from the second and third cervical nerves, pass downward to the outer side of the internal jugular vein, then cross in front of the vein, and join the *descendens hypoglossi*, a branch of the hypo-glossal nerve, in front of the sheath of the blood vessels, forming the loop known as the *ansa hypoglossi*. The *descendens* and *communicantes hypoglossi* supply the depressor muscles of the hyoid bone and larynx—namely, the *sterno-hyoid*, *sterno-thyroid*, and *omo-hyoid* muscles. This loop (*ansa*) may be behind the internal jugular vein, and within or outside the sheath of the vessels.

The **muscular branches** of the internal series arise from the first, second, third, and fourth cervical nerves; they supply the *rectus capitis anticus major* and *minor*, *rectus lateralis*, and *longus colli* muscles.

The **communicating branches** of the internal series connect the cervical plexus with the sympathetic, pneumogastric, and hypo-glossal nerves.

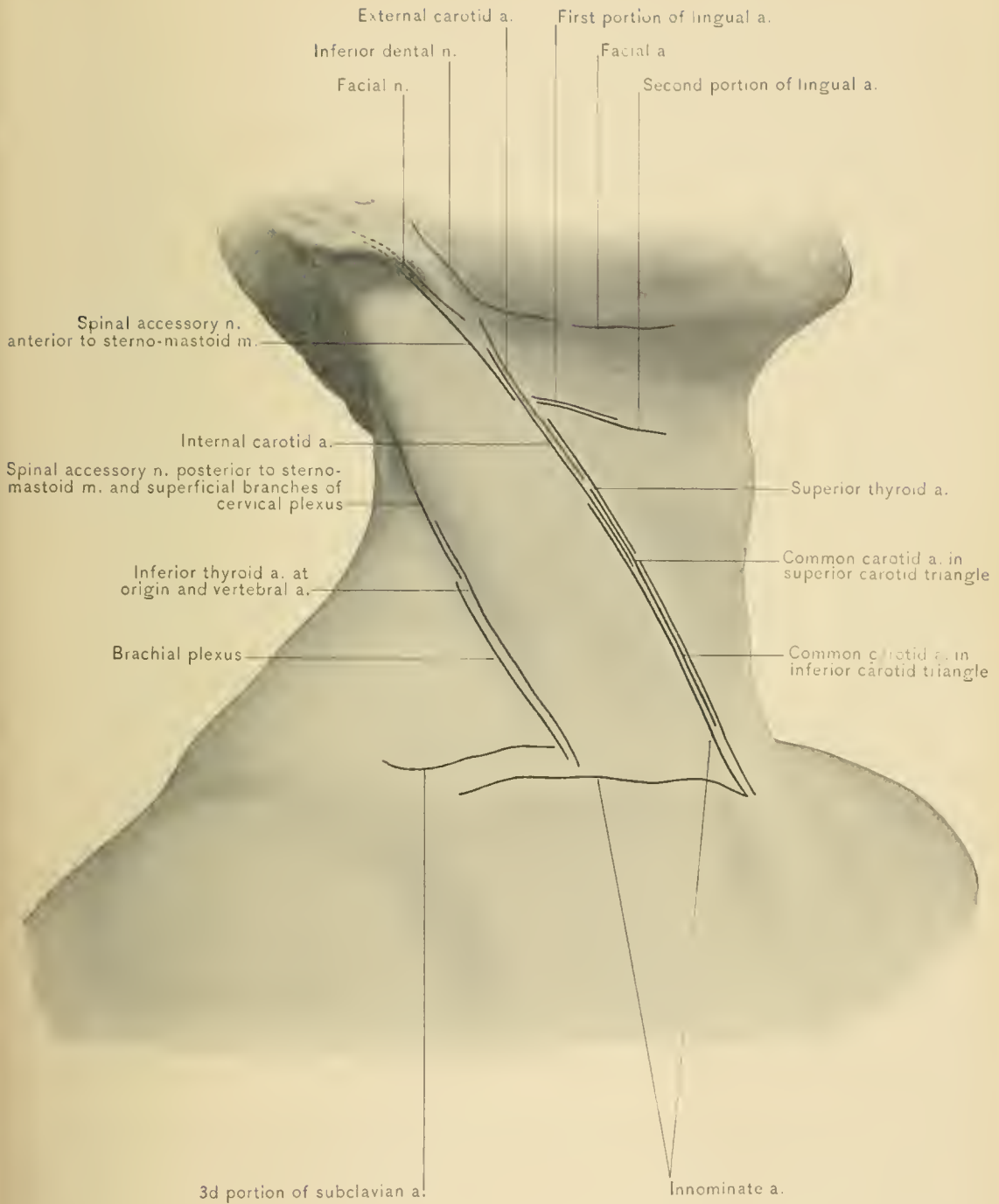
The **muscular branches** of the external series supply the *sterno-mastoid*, the *trapezius*, the *levator anguli scapulae*, and the *scalenus medius* muscle; the branch to the *sterno-mastoid* muscle arises from the second cervical nerve; the branches to the *levator anguli scapulae*, *trapezius*, and *scalenus medius* muscles from the third and fourth cervical nerves.

The **communicating branches** of the external series connect the cervical plexus with the spinal accessory nerve in the *sterno-mastoid* muscle, in the *occipital triangle*, and lastly beneath the *trapezius* muscle, forming the **subtrapezial plexus**.

Pain in one or more of the areas supplied by the various sensory branches of the cervical nerves may be caused by caries of the cervical vertebrae. Irritation of these nerves produces pain or spasm of the muscles in the regions supplied by the posterior branches of the nerves, as well as in those supplied by the cervical and brachial plexuses.

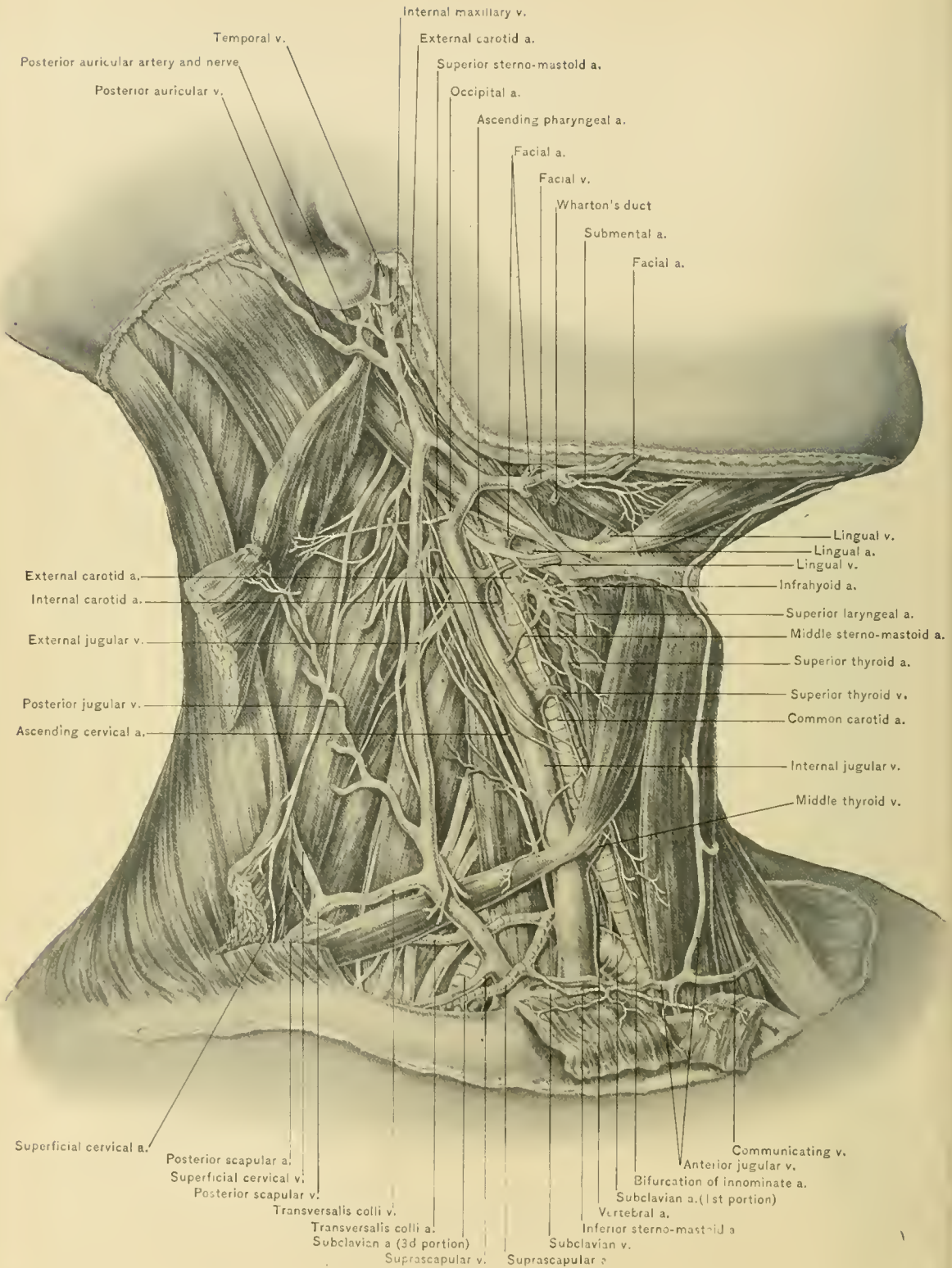
Next examine the carotid sheath and the structures in relation with it.

The **Carotid Sheath** is formed by the division of the superficial layer of the deep cervical fascia which passes beneath the *sterno-mastoid* muscle, by the pre-vertebral and pretracheal fasciae. It is divided by septa into three compartments:

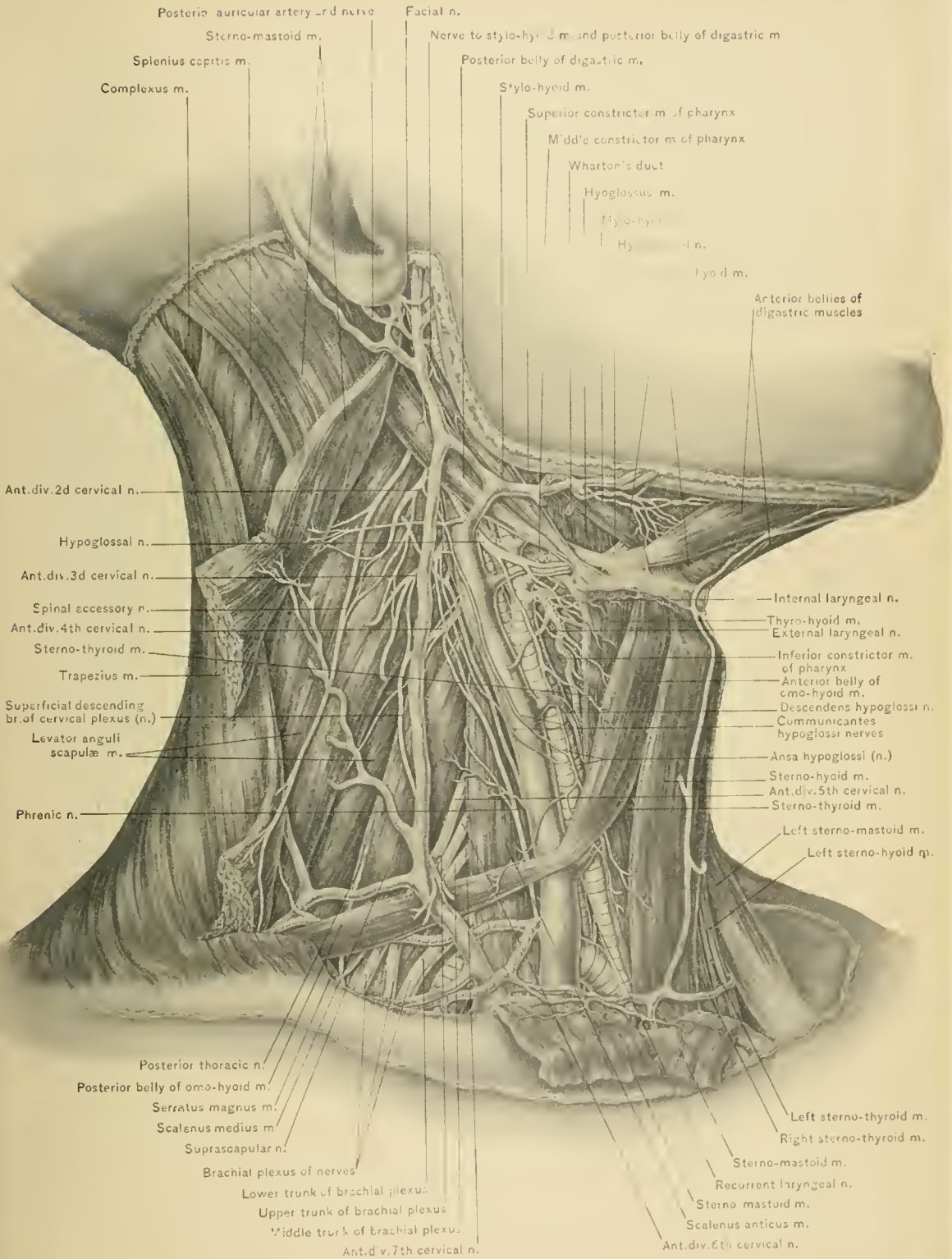


LINES OF INCISION FOR EXPOSURE OF ARTERIES AND NERVES.

PLATE XIV.



VESSELS AND NERVES OF NECK.



MUSCLES AND NERVES OF NECK.

the inner contains the common carotid artery, the outer the internal jugular vein, and the posterior the pneumogastric nerve.

The **descendens hypoglossi nerve** (*descendens noni*) is usually seen lying in front of the carotid sheath, but occasionally it lies within the anterior wall of the sheath. It is given off from the hypo-glossal nerve as the latter winds around the occipital artery. It is not a true branch of the hypo-glossal nerve, its fibers originally arising from the cervical plexus and running with the trunk of the hypo-glossal nerve for a short distance. It communicates with the *communicantes hypoglossi*, deep branches of the cervical plexus, thus forming a loop known as the *ansa hypoglossi*, which supplies the sterno-hyoid, sterno-thyroid, and both bellies of the omo-hyoid muscle.

Lymphatic glands.—In relation with the outer wall of the sheath of the vessels, observe the deep chain of lymphatic glands; these glands are in communication with the superficial chain, and therefore in enlargement of the latter the deep chain is more or less involved. Every surgeon who has had experience in the removal of glandular tumors of the neck appreciates this fact when forced to carry the dissection to the extent of exposing the carotid sheath for some distance if he would remove all enlarged glands. In cases where it is not possible to make a good exposure and dissect with safety around the vessels by simply displacing the sterno-mastoid muscle, it will be necessary to divide the muscle. In making a difficult dissection in a region rich in important structures success is obtained only by having a good exposure, which necessitates a large wound.

DISSECTION.—Remove the deep chain of lymphatic glands together with the fat and connective tissue around them, and lay open the sheath, when the carotid artery, the internal jugular vein, and the pneumogastric nerve will be brought into view. The internal jugular vein lies to the outer side of the common carotid artery, while the pneumogastric nerve lies between the vein and artery in a plane posterior to both.

The **internal jugular vein** is the continuation of the lateral sinus, and begins at the jugular foramen, where that sinus is joined by the inferior petrosal sinus. The vein is somewhat dilated at its origin, this enlargement constituting the so-called *bulb* or *sinus*, which lies in the jugular fossa. At the jugular foramen the vein lies behind and external to the glosso-pharyngeal, pneumogastric, and spinal accessory nerves. It passes down the side of the neck, at first beneath and external to the internal carotid artery, then on the outer side of the internal carotid, and, finally, on the outer side of the common carotid artery. It terminates by joining the subclavian vein just external to the upper margin of the sterno-clavicular articulation to form the innominate vein. It occupies the outer compartment of the carotid sheath, and is separated from the common carotid artery

and pneumogastric nerve by septa. At the lower part of the neck the internal jugular veins observe a slightly different course. At its termination the right internal jugular vein leaves the right common carotid artery to join the subclavian vein, forming a triangular interval between the artery and vein, while the left internal jugular vein turns forward to join the subclavian vein, and overlaps the left common carotid artery at the root of the neck. The internal jugular vein has a pair of valves about three-fourths of an inch from its termination. Opposite the angle of the lower jaw a communicating branch from the external jugular vein and some pharyngeal veins empty into it. Near the level of the greater cornu of the hyoid bone it receives the facial and lingual veins; lower, the superior thyroid vein; and opposite the cricoid cartilage, the middle thyroid vein.

The common carotid artery.—The right and left common carotid arteries are dissimilar in origin, but occupy similar positions in the neck (for this reason but one artery will be described). The right common carotid arises from the innominate artery behind the upper margin of the right sterno-clavicular articulation; the left common carotid arises from the highest part of the transverse portion of the arch of the aorta. As the left common carotid artery arises within the chest, it is the longer of the two vessels; it may be divided into a thoracic and a cervical portion. The thoracic portion of the left common carotid artery will be described with the chest.

The *course* of the common carotid, external carotid, and internal carotid arteries when the face is turned slightly to the opposite side, is represented by a line drawn from the sterno-clavicular articulation to a point midway between the angle of the lower jaw and the mastoid process of the temporal bone. That portion of the line below the level of the greater cornu of the hyoid bone indicates the course of the common carotid artery, and that part above the hyoid bone indicates the position of the internal carotid and external carotid arteries. The external carotid deviates slightly from this line toward the angle of the lower jaw.

At the lower part of the neck the common carotid artery is situated deeply beneath the sternal origin of the sterno-cleido-mastoid, the sterno-hyoid, and the sterno-thyroid muscle, being separated from its fellow by the trachea, which is about an inch in width. Thence it ascends in the inner compartment of the sheath of the vessels, beneath the anterior border of the sterno-cleido-mastoid muscle, to terminate opposite the upper border of the thyroid cartilage by bifurcating into the external and internal carotid arteries. As the artery ascends it diverges from the median line, on account of the interposition of the lateral lobe of the thyroid gland between it and the trachea, and as a result of the width of the larynx. It is covered by the skin, superficial fascia, platysma myoides muscle, superficial layer of the deep fascia, the anterior border of the sterno-mastoid mus-

cle, and the anterior wall of the carotid sheath; in addition to these, at the lower part of the neck are the sterno-hyoid and sterno-thyroid muscles, the thyroid gland, which slightly overlaps it, the omo-hyoid muscle and the anterior jugular vein, which cross it. The descendens hypoglossi nerve and ansa hypoglossi also lie in front of it, and the middle sterno-mastoid artery and the superior and middle thyroid veins cross it. Behind it are the rectus capitis anticus major and the longus colli muscle, the pneumogastric, sympathetic, and cardiac nerves, the recurrent laryngeal nerve, at the lower part of the neck, and the inferior thyroid artery crossing behind it at the level of the cricoid cartilage. To the inner side of the artery are the trachea and esophagus, the recurrent laryngeal nerve lying between them, the lateral lobe of the thyroid gland, the terminal portion of the inferior thyroid artery, the larynx, the pharynx, and the superior thyroid artery. To the outer side of the artery are the internal jugular vein and the pneumogastric nerve.

The common carotid artery seldom gives off branches, but may, when the bifurcation is higher than usual, give off the superior thyroid artery. The bifurcation of the artery may occur higher or lower than the upper border of the thyroid cartilage, and is not infrequently situated opposite the greater cornu of the hyoid bone.

Aneurysm of the common carotid artery most frequently develops near its bifurcation. Pressure upon the internal jugular vein by an aneurysm of the common carotid artery produces cyanosis or duskiuess of the face and scalp, headache, and puffiness or edema of the face; pressure upon the sympathetic cord causes dilatation of the pupil, and, later, contraction of the pupil; pressure upon the superior laryngeal nerve causes cough, and spasm or paralysis of one crico-thyroid muscle; and pressure upon the recurrent laryngeal nerve, spasm or paralysis of the muscles of one side of the larynx, hoarseness, and difficulty in phonation. These aneurysms at the side of the neck produce a pulsating swelling which resembles that seen in enlargement of one lateral lobe of the thyroid gland. As the thyroid gland adheres to the trachea, enlargements or tumors of that organ move upward and downward with the larynx and trachea during deglutition, whereas an aneurysm of the common carotid artery remains stationary.

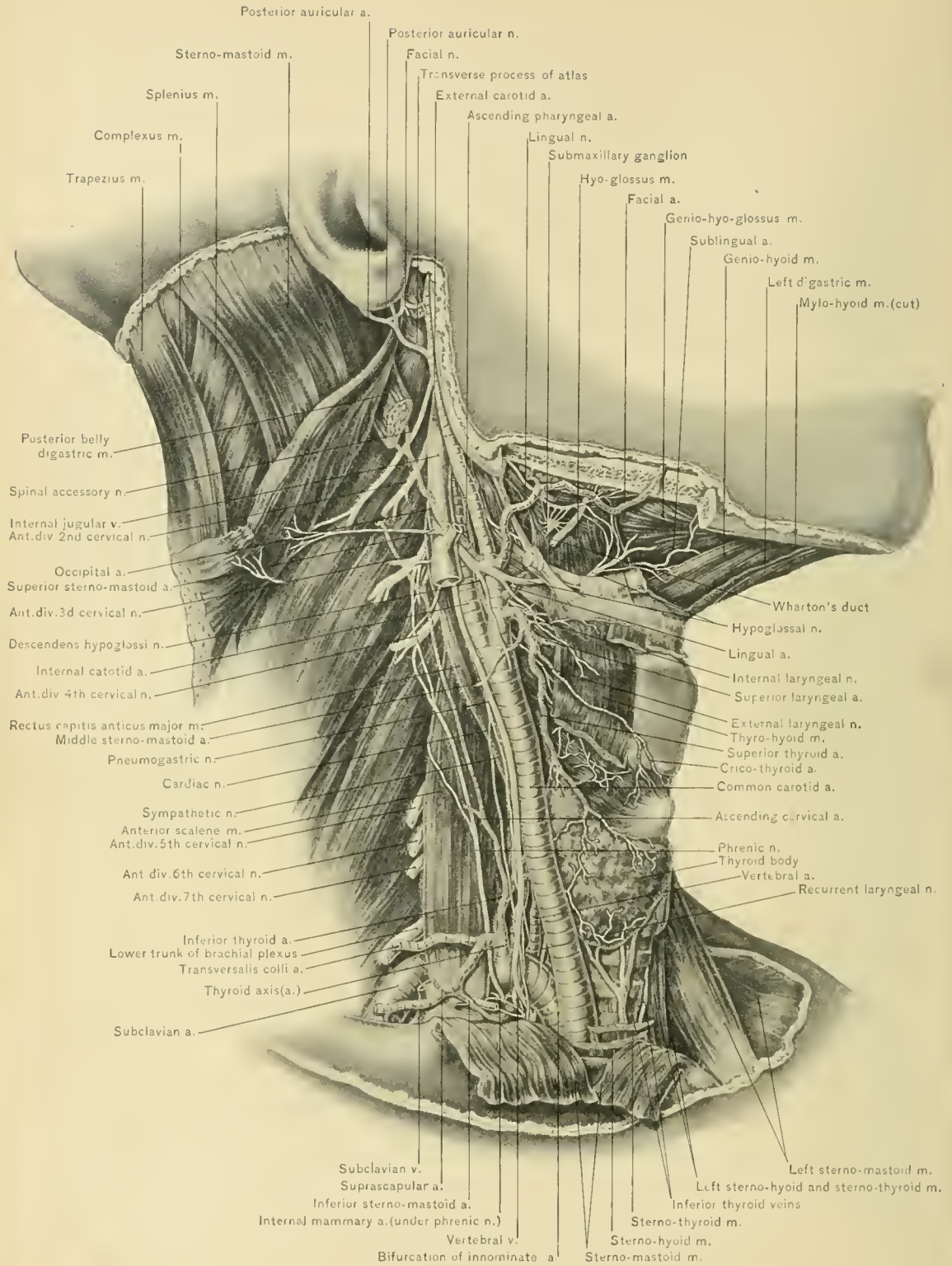
Ligation of the common carotid artery.—In wounds or aneurysm of this artery or one of its branches, it may require a ligature. It is tied, preferably, in the superior carotid triangle, opposite the cricoid cartilage and immediately above the point where the omo-hyoid muscle crosses its sheath. The incision is made along the anterior border of the sterno-mastoid muscle, cutting through the skin, superficial fascia, platysma myoides muscle, and superficial layer of the deep fascia; the sterno-mastoid muscle is then displaced outward, and the sheath with the descendens hypoglossi nerve upon it exposed. As the internal jugular vein slightly

overlaps the outer side of the artery, a small incision should be made in the inner side of the sheath, and the needle passed from without inward, avoiding the internal jugular vein and the pneumogastric nerve. The opening in the sheath should be small, so that the vasa vasorum and the nutrition of the vessel will not be unnecessarily disturbed. In exposing the carotid sheath, the superior or middle thyroid vein and the middle sterno-mastoid artery may be severed. In the inferior carotid triangle the artery is ligatured with more difficulty and danger, because it is deeper and covered by three layers of muscles: the sterno-thyroid, sterno-hyoid, and sterno-mastoid; and, on the left side, the internal jugular vein turns forward in front of the artery at the root of the neck to join the subclavian vein.

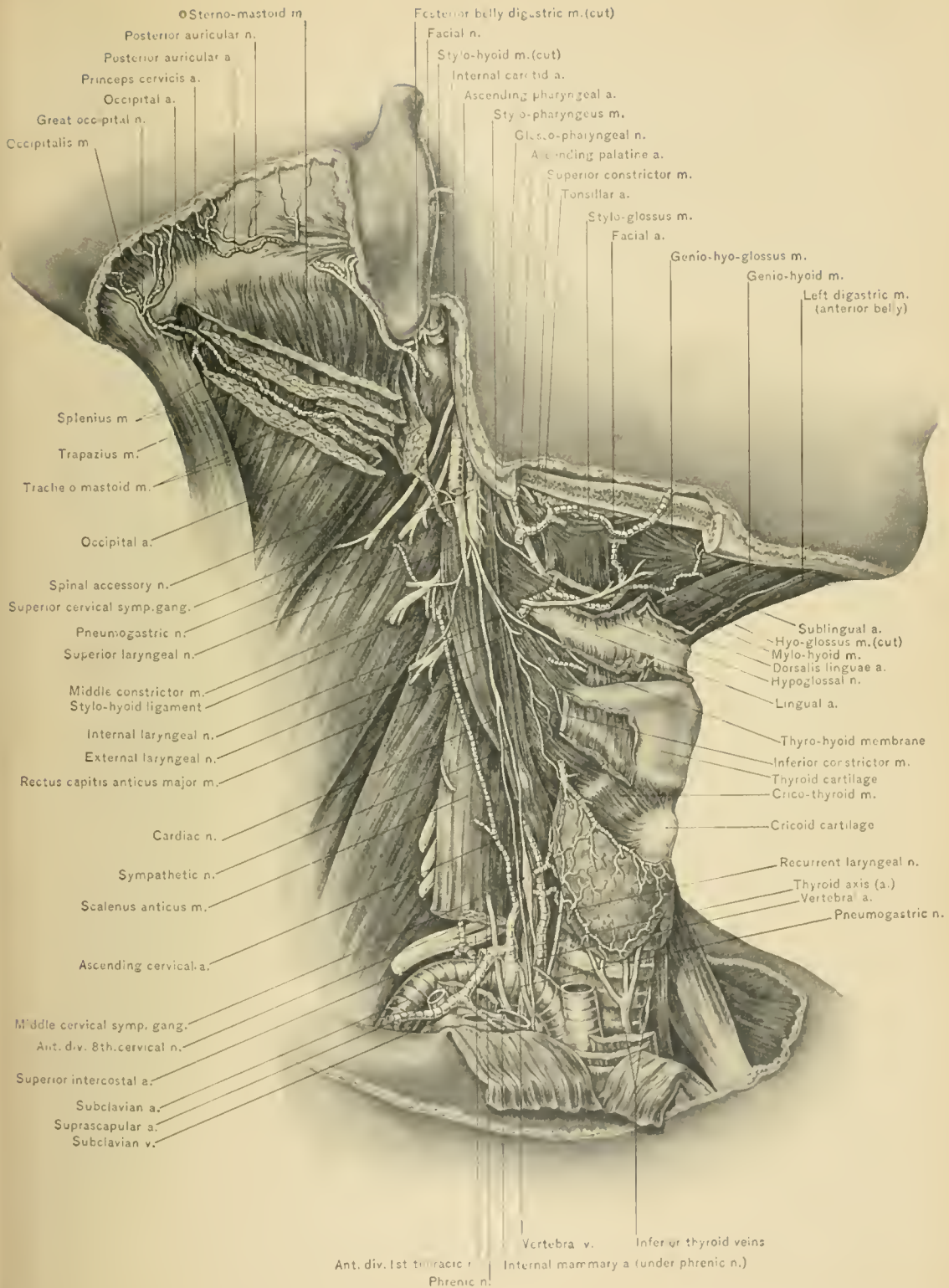
Intercarotid body or ganglion.—This small, oval, reddish-brown body is situated in the interval between the external and internal carotid arteries, behind the bifurcation of the common carotid artery. It receives filaments from the sympathetic nerve, and resembles the coccygeal body or Luschka's gland.

The Pneumogastric or Vagus Nerve.—The pneumogastric nerve, the tenth and longest of the cranial nerves, has an extensive area of distribution. It supplies branches to the dura mater, external ear, pharynx, larynx, esophagus, trachea, bronchi, lungs, stomach, spleen, liver, and to the sympathetic system of nerves in the cervical, thoracic, and abdominal regions. It leaves the cranial cavity at the jugular foramen, inclosed within the same sheath of the dura mater as the spinal accessory nerve. It runs downward between the internal jugular vein and the internal carotid artery, passing next between the internal jugular vein and the common carotid artery, lying behind and between them in the posterior compartment of their sheath. It enters the chest at its superior opening. On the right side it passes between the first portion of the subclavian artery and the subclavian vein, while on the left side it runs between the first portion of the subclavian artery and the common carotid artery, beneath the left innominate vein. Its course in the chest will be included in the description of that part of the body. The pneumogastric nerve, owing to its position between the internal jugular vein and the internal carotid artery, is closely associated with the glosso-pharyngeal, spinal accessory, and hypo-glossal nerves. These nerves accompany the internal carotid artery but a short distance, the glosso-pharyngeal nerve curving forward between the external and internal carotid arteries, the spinal accessory nerve turning backward beneath the internal jugular vein, and the hypo-glossal nerve curving forward over the internal and external carotid arteries and the root of the occipital artery.

There are two ganglia on the pneumogastric nerve: the *ganglion of the root*, and the *ganglion of the trunk*. The ganglion of the root is a small, rounded swelling seen upon the nerve as it lies in the jugular foramen. The ganglion of the trunk



DEEP STRUCTURES OF NECK,—CAROTID ARTERIES AND PNEUMOGASTRIC NERVE.



SYMPATHETIC NERVE AND LARYNGEAL NERVES.

is a long, fusiform enlargement, situated upon the nerve about one-half of an inch below the jugular foramen. It is closely associated with the hypo-glossal nerve, which winds around its outer side; below this ganglion the vagus receives some fibers from the accessory portion of the spinal accessory nerve.

BRANCHES OF THE PNEUMOGASTRIC NERVE.—These may be classified as *communicating branches* and *branches of distribution*. The communicating branches connect it with the facial, glosso-pharyngeal, spinal accessory, hypo-glossal, sympathetic, and first two cervical nerves. The branches of distribution are: in the jugular foramen, the meningeal and the auricular nerve; in the neck, the pharyngeal, superior laryngeal, recurrent laryngeal, and cervical cardiac nerves; in the chest, the thoracic cardiac, anterior and posterior pulmonary, and esophageal nerves; in the abdomen, gastric branches.

The **meningeal or recurrent branch** is a small twig which runs upward from the ganglion of the root, through the jugular foramen, to the dura mater near the lateral sinus.

The **auricular (Arnold's) nerve** has its origin from the ganglion of the root of the vagus, receives a branch from the petrous ganglion of the glosso-pharyngeal nerve, and passes over the bulb of the internal jugular vein to reach an aperture in the outer wall of the jugular fossa. It next passes through the temporal bone near the facial canal, communicating with the facial nerve, and emerging from the bone between the mastoid process and the external auditory meatus. Turning outward, it supplies the back of the pinna and part of the external auditory canal, one of its branches communicating with the posterior auricular branch of the facial nerve. Irritation of this nerve by a foreign body in the external auditory meatus may induce cough, which is not relieved until the foreign body is removed. This *ear cough* is explained by reference of the irritation to the mucous membrane of the larynx through the auricular and superior laryngeal branches of the pneumogastric nerve.

The **pharyngeal branch**, the chief motor nerve of the pharynx, arises from the ganglion of the trunk and receives part of the accessory portion of the spinal accessory nerve. It runs behind or in front of the internal carotid artery to the back of the pharynx, to the upper border of the middle constrictor muscle, where it assists in forming the *pharyngeal plexus*. This plexus is formed by branches of the glosso-pharyngeal nerve, pneumogastric nerve, and superior cervical sympathetic ganglion. The pharyngeal muscles and mucous membrane and the azygos uvulæ and levator palati muscles are supplied by filaments from this plexus.

The **superior laryngeal nerve** is the sensory nerve of the larynx. It arises from the ganglion of the trunk of the pneumogastric nerve, curving downward and forward behind the internal and external carotid arteries, and dividing

into the external and internal laryngeal branches. The *internal branch*, together with the superior laryngeal artery, enters the larynx through the thyro-hyoid membrane, supplying the laryngeal mucous membrane and the arytenoid muscle, and communicating with the recurrent laryngeal nerve. Irritation of this branch, as by a crumb of bread or a drop of water entering the larynx, causes a momentary cessation of respiration, cough, and expulsion of the intruding substance. The *external branch*, which is smaller than the internal, descends along the side of the pharynx under the sterno-thyroid muscle; it supplies the crico-thyroid muscle and crico-thyroid membrane, the inferior constrictor muscle of the pharynx, and the thyroid gland; it also sends filaments to the pharyngeal plexus, and gives off, behind the common carotid artery, a branch to the superior cardiac nerve of the sympathetic.

Paralysis of the superior laryngeal nerve may be due to pressure of an aneurysm of the external or the internal carotid artery, or to enlarged lymphatic glands or tumors. The external laryngeal division may also be compressed by aneurysm of the upper part of the common carotid artery. Anesthesia of the laryngeal mucous membrane would permit foreign bodies to enter the larynx, and cause inflammation or obstruction. The vocal cords can not be stretched, owing to paralysis of the crico-thyroid muscle, and the voice is, in consequence, hoarse and of low pitch.

Irritation of the superior laryngeal nerve, as by aneurysm of the internal or external carotid artery, or by an enlarged thyroid gland or lymphatic glands, causes peculiar, ringing cough, without expectoration.

The **recurrent or inferior laryngeal nerves** are the motor nerves of the larynx, supplying all of the intrinsic muscles of that organ except the crico-thyroid muscles, these being supplied by the external laryngeal branches of the superior laryngeal nerves. The *right recurrent laryngeal nerve* is shorter than the left, arising from the pneumogastric nerve as it crosses the first portion of the right subclavian artery. It then winds behind the first portion of the right subclavian artery, ascending obliquely inward in front of the apex of the right pleural sac, and behind the root of the right common carotid artery and the terminal portion of the inferior thyroid artery to reach the groove between the trachea and esophagus. While in this groove it passes behind and internal to the right lateral lobe of the thyroid body, and leaves the groove to reach the intrinsic muscles of the larynx by passing behind the inferior cornu of the thyroid cartilage.

Pressure upon this nerve may be caused by aneurysm of the first portion of the right subclavian artery or lowermost portion of the right common carotid artery, by enlargement of the thyroid body, cicatrices of the apex of the right pleura, as in phthisis, or by malignant disease of the esophagus.

The *left recurrent laryngeal nerve* arises from the pneumogastric nerve in front of the transverse portion of the arch of the aorta, and winds behind that portion of the arch below and to the left side of the obliterated ductus arteriosus. It next ascends behind the root of the left common carotid artery to the groove between the trachea and esophagus, continuing upward to the larynx, and passing behind and internal to the left lateral lobe of the thyroid body, in a course similar to that of the right recurrent laryngeal nerve. Both nerves communicate with the superior laryngeal nerve of the same side, and with the sympathetic nerve.

Pressure upon the left recurrent laryngeal nerve may be produced by aneurysm of the arch of the aorta or of the lowermost portion of the left common carotid artery, by tumors of the posterior mediastinum, by enlargement of the thyroid body, or by malignant disease of the esophagus. Moderate pressure causes spasm of the muscles of the same side of the larynx, dyspnea, and change of voice. Greater pressure causes paralysis and alteration of the voice. Both nerves may be involved in labio-glosso-pharyngeal paralysis or disseminated sclerosis of the pons, medulla oblongata, and spinal cord, or by pressure from an enlarged thyroid body, or carcinoma of the esophagus. When both nerves are paralyzed the vocal cords are immovable, phonation is imperfect, and the rima glottidis is in the relaxed attitude assumed in quiet breathing.

The **cervical cardiac branches of the pneumogastric nerve** are given off in the upper and lower part of the neck. The *superior cervical cardiac branches* join the cardiac branches of the sympathetic and terminate in the deep cardiac plexus. The *left inferior cervical cardiac branch* passes between the pleura and the left side of the transverse portion of the aortic arch, entering the superficial cardiac plexus with the left superior cervical cardiac branch of the sympathetic nerve. The *right inferior cervical cardiac branch* passes on the trachea to the deep cardiac plexus.

The **thoracic and abdominal branches of the pneumogastric nerve** are described with the thorax and abdomen.

The Sympathetic.—The sympathetic nervous system consists of a series of ganglia, one ganglion being joined to another by connecting nerve cords; it is also composed of gangliated plexuses, visceral ganglia, and many nerve fibers. Some of the ganglia—as, for instance, the cardiac ganglia—possess automatic action. The nerve fibers of the sympathetic system are chiefly non-medullated.

The **cervical portion of the sympathetic nerve** is situated behind the carotid sheath or in its posterior wall, and lies beneath the prevertebral fascia, where it rests upon the rectus capitis anticus major and the longus colli muscle. Three cervical ganglia—the superior, middle, and inferior—lie in each side of the neck.

The **superior cervical ganglion**, the largest of the three, is a long, fusiform body situated opposite the transverse processes of the second and third cervical vertebræ, behind the sheath of the great vessels. It is formed probably by the fusion of four ganglia, as it communicates with four spinal nerves. It gives off an ascending and a descending branch, branches to cranial and cervical nerves, branches which follow the external carotid artery and its branches, pharyngeal branches, laryngeal branches, and the superior cardiac nerve.

The *ascending branch* passes upward through the carotid canal, with the internal carotid artery. It divides into an external and an internal branch. Its external branch forms the carotid plexus, while its internal branch forms the cavernous plexus.

The *descending branch* passes downward to the middle cervical ganglion.

The *branches to the cranial nerves* communicate with the ganglia of the root and trunk of the pneumogastric nerve, the petrous ganglion of the glosso-pharyngeal nerve, and the hypo-glossal nerve. No branches pass to the spinal accessory nerve. The branches to the spinal nerves pass outward over the rectus capitis anticus major muscle to join the upper four cervical nerves.

The branches which ramify upon the external carotid artery and its branches (*nervi molles*) proceed from the upper part of the ganglion. The *nervi molles* upon the external carotid artery supply branches to the intercarotid body; the *nervi molles* of the facial artery, branches to the submaxillary ganglion (the sympathetic root); those upon the middle meningeal artery, the sympathetic root to the otic ganglion, and the external *superficial petrosal nerve*, which is the sympathetic root of the geniculate ganglion of the facial nerve.

The *pharyngeal branches* pass inward behind the internal and external carotid arteries, and assists in forming the pharyngeal plexus.

The *laryngeal branches* join the superior laryngeal nerve.

The *superior cervical sympathetic cardiac nerve* arises from the lower part of the superior cervical sympathetic ganglion, or from the cord which runs to the middle cervical ganglion. It runs downward behind the carotid sheath, communicating with the superior cardiac branch of the pneumogastric, the external laryngeal, and the recurrent laryngeal nerve. In the chest the two nerves take different courses. The right superior cervical sympathetic cardiac nerve passes in front of or behind the first portion of the subclavian artery, following the innominate artery, and terminating in the deep cardiac plexus. On the left side the nerve passes between the left common carotid and the left subclavian artery, and over the left side of the arch of the aorta, to the left of the left pneumogastric nerve, terminating in the superficial cardiac plexus.

The **middle cervical or thyroid ganglion**, the smallest of the three ganglia,

appears as a swelling upon the sympathetic cord. It may, however, be absent. It rests upon or beneath the inferior thyroid artery, opposite the transverse process of the sixth cervical vertebra, and is formed probably by the fusion of two ganglia, as it communicates with two spinal nerves. It gives off communicating branches to the superior and inferior cervical ganglia, and to the fifth and sixth cervical nerves, thyroid branches, and the middle cardiac nerve.

The *communicating branch to the superior ganglion* is the cord of the sympathetic nerve.

The *communicating branches to the inferior ganglion* are the main sympathetic cord, which passes behind the first portion of the subclavian artery, and one or two nerves which form a loop (*ansa Vieussenii*) in front of and below the artery.

The *thyroid branches* accompany the inferior thyroid artery to the thyroid body.

The *middle cardiac nerve*, the largest of the three cervical sympathetic cardiac nerves, arises from the middle ganglion or the sympathetic cord just below it. It communicates with the superior cardiac and the recurrent laryngeal nerve, and passes in front of or behind the first portion of the subclavian artery, entering the deep cardiac plexus.

The **inferior cervical ganglion** is intermediate in size between the middle and superior ganglia. It is deeply situated between the transverse process of the seventh cervical vertebra and the neck of the first rib, and lies to the inner side of the superior intercostal artery, behind the vertebral artery. It is formed probably by the fusion of two ganglia, as it communicates with two spinal nerves, the seventh and eighth cervical. It is joined to the first thoracic ganglion by two large nerves, and may be fused with that ganglion. The sympathetic cord and the *ansa Vieussenii* connect it with the middle cervical ganglion. It gives off the inferior cardiac nerve and branches which form a plexus on the vertebral artery.

The *inferior cervical sympathetic cardiac nerve* arises from the inferior cervical ganglion, or occasionally from the first thoracic ganglion. It passes behind the subclavian artery, communicating with the recurrent laryngeal and the middle cardiac nerve, and descending upon the trachea to enter the deep cardiac plexus.

The branches forming a plexus (*vertebral plexus*) upon the vertebral artery accompany that vessel into the cranial cavity, after which they follow the basilar and cerebral arteries. It is through this plexus of nerves that contraction of the pupil of the same side results after ligation of the vertebral artery.

The **External Carotid Artery**, so called because it supplies the tissues on the outside of the cranium, is the smaller of the two terminal divisions of the common carotid artery. It arises opposite the upper border of the thyroid cartilage,

ascends, and enters the parotid gland, where it lies beneath the temporo-maxillary vein and facial nerve. Opposite the neck of the lower jaw it divides into its two terminal branches, the temporal and internal maxillary arteries. At first it lies to the inner side of the internal carotid artery, but later becomes superficial to that vessel.

RELATIONS.—It is covered by the skin, superficial fascia, platysma myoides muscle, superficial layer of the deep cervical fascia, anterior border of the sternomastoid muscle, and a portion of the parotid gland, the temporo-maxillary vein, and the facial nerve. It is crossed by the hypo-glossal nerve, the facial and lingual veins, the posterior belly of the digastric muscle and the stylo-hyoid muscle, and enters the parotid gland. Along the inner side of the vessel, from below upward, are the wall of the pharynx, the hyoid bone, the ramus of the lower jaw, and the stylo-maxillary ligament, from which it is separated by a portion of the parotid gland. Beneath it, near its origin, is the superior laryngeal nerve; higher in the neck the stylo-glossus and stylo-pharyngeus muscles, the stylo-hyoid ligament, the glosso-pharyngeal nerve, the pharyngeal branch of the pneumogastric nerve, and part of the parotid gland separate it from the internal carotid artery. On its outer side, at its origin, is the internal carotid artery. The external carotid artery differs from most of the arteries in not having a companion vein, but a vein formed by the union of the temporal and internal maxillary veins does occasionally accompany it.

A *line* drawn from the junction of the sternum with the clavicle, to a point midway between the angle of the lower jaw and the mastoid process represents the course of the common and external carotid arteries.

BRANCHES OF THE EXTERNAL CAROTID ARTERY.—These are the superior thyroid, lingual, facial, occipital, posterior auricular, ascending pharyngeal, superficial temporal, and internal maxillary arteries. They may be divided into four sets: an anterior, a posterior, an ascending, and a terminal. The anterior set comprises the superior thyroid, lingual, and facial; the posterior, the occipital, and posterior auricular; the ascending, the ascending pharyngeal; and the terminal, the superficial temporal, and internal maxillary.

The **superior thyroid artery**, the first branch given off from the external carotid, arises just below the greater cornu of the hyoid bone. Throughout the greater part of its course it occupies the superior carotid triangle. It passes forward and then downward and inward behind the omo-hyoid, sterno-thyroid, and sterno-hyoid muscles to the upper and front part of the thyroid body, in which it terminates. Its branches are the hyoid, middle sterno-mastoid, superior laryngeal, and crico-thyroid arteries.

The *hyoid (infra-hyoid) artery* is very small. It runs inward along the lower

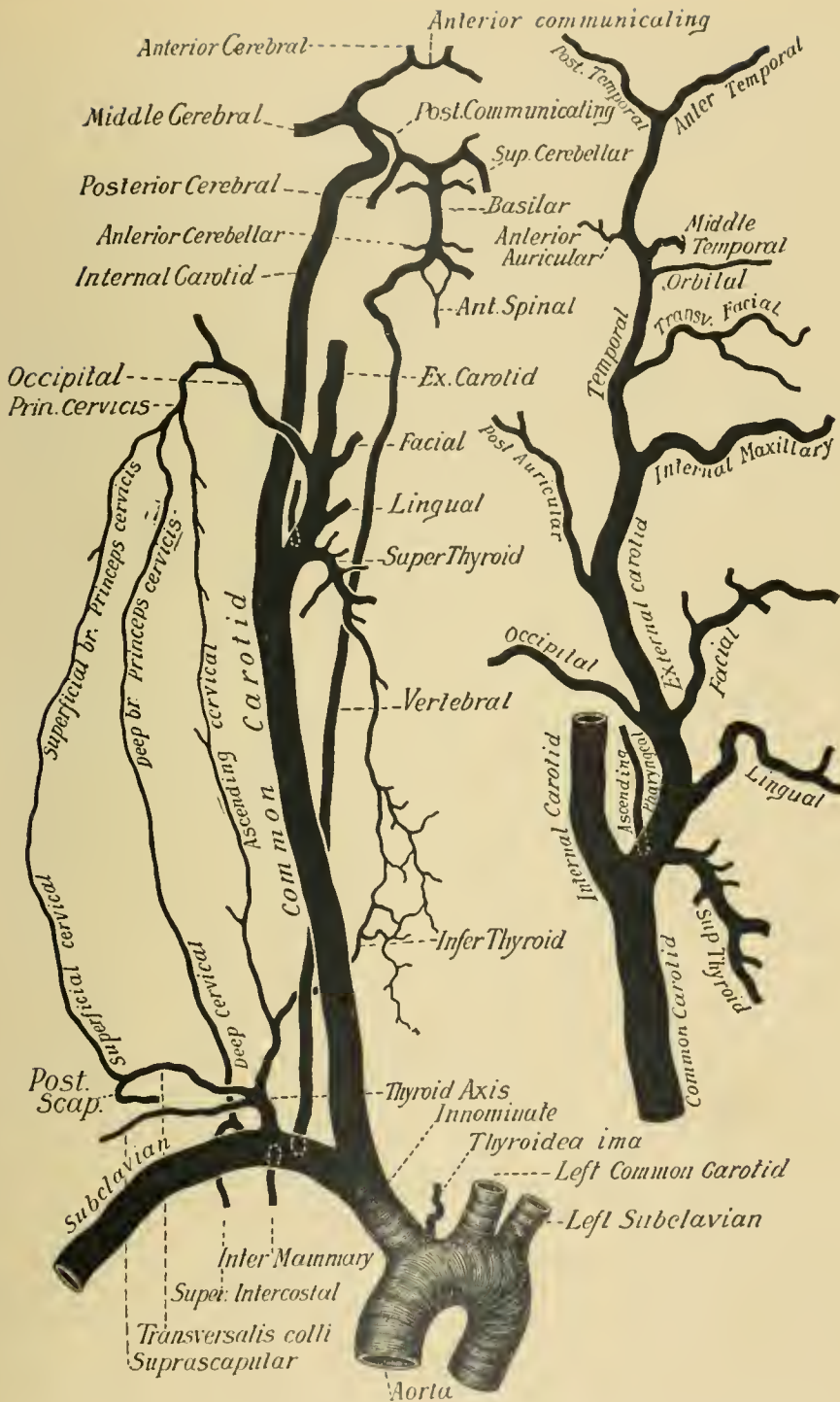
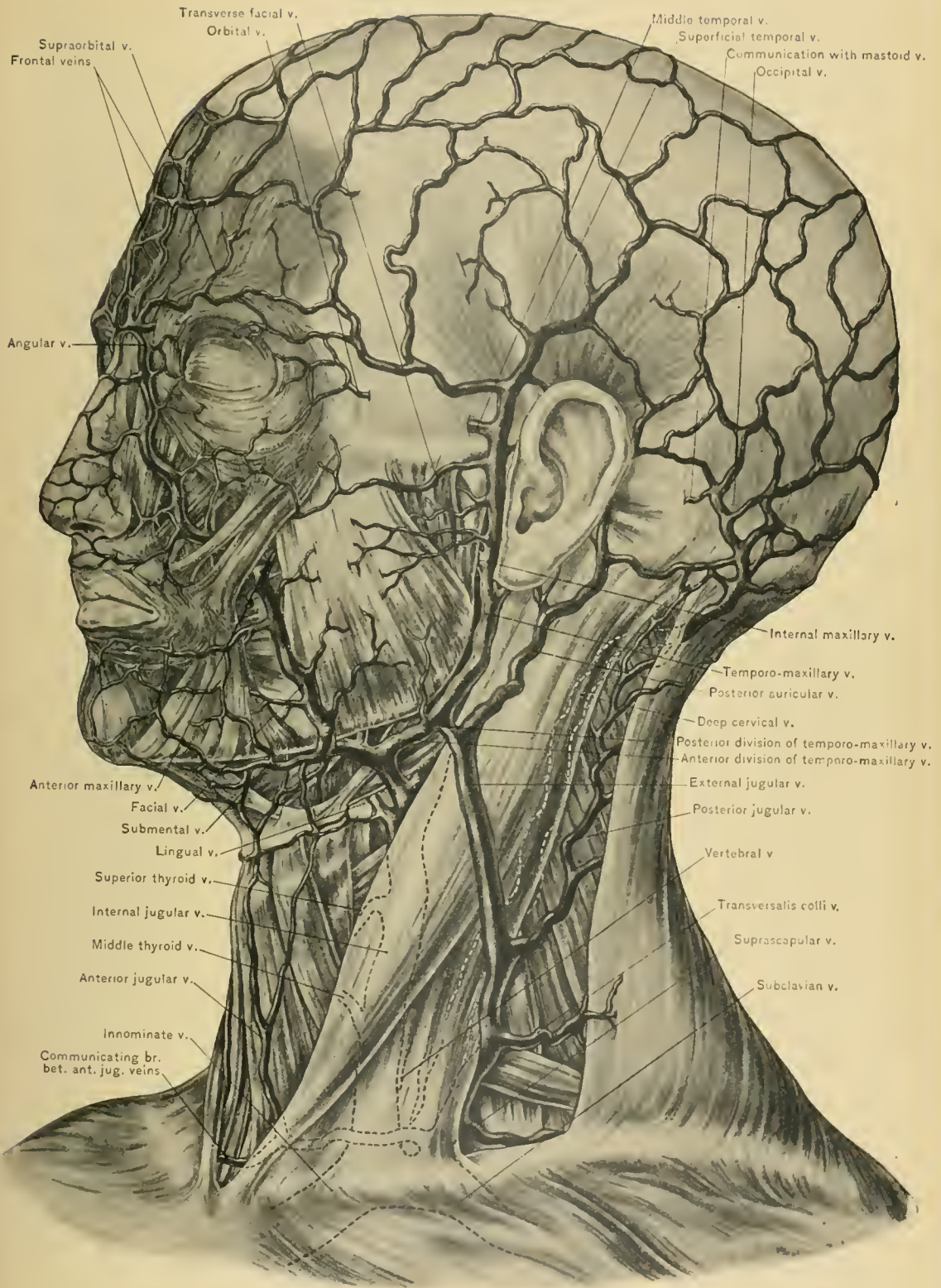


DIAGRAM OF SUBCLAVIAN AND CAROTID ARTERIES AND THEIR BRANCHES



VEINS OF SCALP, FACE, AND NECK.

border of the hyoid bone, beneath the thyro-hyoid muscle, supplying the infra-hyoid bursa and the thyro-hyoid muscle, and communicates with the infra-hyoid artery of the opposite side and with the supra-hyoid branch of the lingual artery.

The *middle sterno-mastoid artery* passes downward and outward over the sheath of the common carotid artery in the superior carotid triangle, the triangle of election; it is chiefly distributed to the middle portion of the sterno-mastoid muscle, supplying also the thyro-hyoid, sterno-thyroid, sterno-hyoid, omio-hyoid, and platysma myoides muscles, and the overlying skin. The author has observed cases in which this vessel was unusually large, running into the occipital triangle, and giving rise to fatal hemorrhage following the opening of an abscess.

The *superior laryngeal artery*, larger than either of the two preceding branches, is accompanied by the internal branch of the superior laryngeal nerve; it passes beneath the thyro-hyoid muscle and pierces the thyro-hyoid membrane, supplying the muscles and mucous membrane of the larynx, and anastomosing with the superior laryngeal artery of the opposite side and the inferior laryngeal branch of the inferior thyroid artery. At times it enters the larynx through a foramen in the thyroid cartilage.

The *erico-thyroid artery* runs across the erico-thyroid membrane, just below the lower border of the thyroid cartilage, and is continuous with the erico-thyroid artery of the opposite side. A small branch usually passes through the erico-thyroid membrane to the interior of the larynx. The operation of laryngotomy is performed by carrying a transverse incision through the erico-thyroid membrane, close to the ericoid cartilage, and it is therefore important to keep in mind the relation which the erico-thyroid artery bears to the membrane, and the necessity, when time is at command, for exposing the membrane by careful dissection.

The **superior thyroid vein**, the accompanying vessel of the superior thyroid artery, crosses the terminal part of the common carotid artery, and empties into the internal jugular vein; it may, at times, enter the facial or lingual vein. It emerges from the upper part of the lateral lobe of the thyroid body, accompanying the superior thyroid artery for a short distance, and then crossing the common carotid artery to empty into the internal jugular vein. A branch of the vein, or one which arises separately in the thyroid body, usually passes upward and anterior to the common carotid and the external carotid artery, and empties into the lingual vein.

The **lingual artery**, the second branch of the external carotid, arises opposite the greater cornu of the hyoid bone between the superior thyroid and facial arteries, occasionally arising as a common trunk with the latter. It consists of three portions: the *first* or oblique, which lies between its origin and the outer border of the hyo-glossus muscle; the *second* or horizontal portion, beneath the hyo-glossus

muscle and parallel with the greater cornu of the hyoid bone; and the *third* or ascending portion, between the hyo-glossus and the genio-hyo-glossus muscle. The *first* or oblique portion lies in the superior carotid triangle, and runs upward and inward to the upper border of the greater cornu of the hyoid bone, resting upon the middle constrictor muscle of the pharynx and the internal laryngeal branch of the superior laryngeal nerve. Thence it passes beneath the hyo-glossus, the posterior belly of the digastric, and the stylo-hyoid muscle, emerging from the superior carotid triangle and entering the submaxillary triangle. This portion of the vessel is crossed by the hypo-glossal nerve and lingual vein, and gives off the supra-hyoid branch. The *second* or horizontal portion runs beneath the hyo-glossus muscle. (See description of submaxillary triangle.) The *third* or ascending portion runs beneath the anterior border of the hyo-glossus on the outer aspect of the genio-hyo-glossus muscle, and runs forward to the tip of the tongue, terminating as the *ranine artery*; the terminal portion of the lingual artery is separated from the cavity of the mouth by the mucous membrane which lines it. (See description of submaxillary triangle.)

The *lingual vein* is seen crossing the first portion of the lingual artery with the hypo-glossal nerve. It runs over the external carotid artery and opposite the greater cornu of the hyoid bone empties into the internal jugular vein separately, or by a common trunk with the facial vein and a branch of the superior thyroid vein. These veins and their common trunk may cause some difficulty in ligation of the common carotid or first portion of the lingual artery.

The **facial artery** (external maxillary) arises from the external carotid above the lingual artery, passes upward beneath the posterior belly of the digastric and the stylo-hyoid muscle and the submaxillary gland, being embedded in a groove on the under surface of the latter; it then curves upward over the body of the lower jaw, reaching the face at the anterior inferior angle of the masseter muscle, where the artery can be compressed and its pulsations readily felt. It consists of two portions, a cervical and a facial.

The BRANCHES given off from the cervical portion of the facial artery are the ascending or inferior palatine, the tonsillar, the submaxillary, the submental, and the muscular.

The *ascending or inferior palatine artery* occasionally arises separately from the external carotid artery. It ascends between the internal and external carotid arteries, then runs between the stylo-glossus and stylo-pharyngeus muscles, and finally between the internal pterygoid muscle and the superior constrictor muscle of the pharynx. Reaching the levator palati muscle, it divides into two branches: one, the palatine, follows the course of the levator palati muscle to supply the soft palate, and anastomoses with the ascending palatine artery of the opposite side, the

descending palatine branch of the internal maxillary artery, and the ascending pharyngeal artery; the other branch, the tonsillar, perforates the superior constrictor muscle of the pharynx, and supplies the tonsil and the Eustachian tube, anastomoses with the tonsillar branches of the ascending pharyngeal and facial arteries, and with the descending or posterior palatine branch of the internal maxillary artery.

The *tonsillar artery*, smaller than the ascending palatine artery, passes upward between the internal pterygoid and the stylo-glossus muscle. It perforates the superior constrictor muscle of the pharynx opposite the tonsil, and supplies branches to the tonsil and root of the tongue. It anastomoses with the tonsillar branch of the ascending palatine and the other tonsillar arteries.

The *glandular (submaxillary) branches*, three or four in number, supply the submaxillary gland, and are derived from the portion of the artery in contact with the gland; some twigs usually run to Wharton's duct.

The *submental artery* is the largest of the branches given off from the cervical portion of the facial artery. It arises from this vessel, beneath the submaxillary gland. It next runs forward upon the mylo-hyoid muscle, under the lower border of the lower jaw, and beneath the anterior belly of the digastric muscle, to the symphysis of the lower jaw, where it divides into a superficial and a deep branch. The superficial branch winds over the lower jaw and runs in the superficial fascia of the chin, anastomosing with the inferior labial artery. The deep branch runs beneath the depressor labii inferioris muscle, and anastomoses with the inferior labial and mental arteries. Its branches are *muscular*, which supply the adjacent muscles; *perforating*, which pierce the mylo-hyoid muscle to anastomose with the sublingual artery; and *cutaneous*, to the overlying skin.

The *muscular branches* supply the posterior belly of the digastric, the stylo-hyoid, the stylo-glossus, the mylo-hyoid, and the internal pterygoid muscle.

The **facial vein** leaves the face at the anterior inferior angle of the masseter muscle. It passes over the submaxillary gland, the stylo-hyoid and posterior belly of the digastric muscle, which separate it from the facial artery. It receives the anterior division of the temporo-maxillary vein, crosses the external carotid artery, and empties into the internal jugular vein opposite the greater cornu of the hyoid bone. It may be injured in opening abscesses situated where it passes over the submaxillary gland.

The **occipital artery**, quite a large vessel, is one of the posterior branches of the external carotid artery. It arises opposite the facial artery, near the lower border of the posterior belly of the digastric muscle, along which it runs to the interval between the mastoid process of the temporal bone and the transverse

process of the atlas, to reach the groove on the under surface of the mastoid portion of the temporal bone. At its origin it is crossed by the hypo-glossal nerve. On its way to the mastoid process it crosses the internal carotid artery, the internal jugular vein, the pneumogastric, hypo-glossal, and spinal accessory nerves, and passes beneath the lower portion of the parotid gland. It runs horizontally backward through the occipital groove of the temporal bone, covered by all the muscles attached to the mastoid process,—the sterno-mastoid, splenius capitis, trachelo-mastoid, and posterior belly of the digastric muscle,—and lies upon the superior oblique and complexus muscles. Reaching the back of the head, the artery pierces the trapezius muscle close to the superior curved line of the occipital bone, ascends, and divides into branches, as described under the Dissection of the Scalp. As it pierces the trapezius muscle and ramifies in the superficial fascia of the scalp, it is accompanied by the great occipital nerve. This vessel is conveniently divided by the sterno-mastoid muscle into three parts,—a first, a second, and a third portion,—situated respectively internal to, beneath, and external to that muscle. The *first portion* is covered only by skin and fasciæ, except where it is overlapped by the posterior belly of the digastric muscle, the parotid gland, and the temporo-maxillary vein. It is crossed by the hypo-glossal nerve. Behind it successively lie the internal carotid artery, the hypo-glossal and the pneumogastric nerve, the internal jugular vein, and the spinal accessory nerve. The first portion of the artery is the *place of election* for ligation. An *incision* is carried along the anterior border of the upper part of the sterno-mastoid muscle while the neck is well extended. The skin, superficial fascia, platysma myoides muscle, and the superficial layer of the deep fascia are divided, and the artery is seen running parallel with or beneath the lower border of the digastric muscle. The hypo-glossal nerve will be seen curving around the artery at its origin. The *second portion* dips deeply under the digastric muscle between the mastoid process of the temporal bone and the transverse process of the atlas, being covered, as previously stated, by the muscles attached to the mastoid process, and lying successively against the rectus capitis lateralis, which separates it from the vertebral artery, the mastoid portion of the temporal bone while passing through the occipital groove, and finally against the insertion of the superior oblique muscle. The *third portion* emerges from beneath the posterior border of the sterno-mastoid and splenius muscles, lying upon the complexus in the triangular interval between the sterno-mastoid and the trapezius, and piercing the trapezius muscle about midway between the mastoid process and the external occipital protuberance, to become subcutaneous and pass upward in the superficial fascia of the scalp. It is accompanied by the great occipital nerve.

The BRANCHES given off from the occipital artery are the muscular, superior

sterno-mastoid, auricular, posterior meningeal, mastoid, princeps cervicis, communicating, and terminal.

The *muscular branches* supply the digastric, stylo-hyoid, splenius, trachelo-mastoid, trapezius, recti, superior and inferior oblique, and the occipitalis muscles.

The *superior sterno-mastoid artery* enters the sterno-mastoid muscle with the spinal accessory nerve. It arises from the first portion of the occipital artery, and passes downward and backward over the hypo-glossal nerve to enter the sterno-mastoid muscle.

The *auricular branch* supplies the back of the pinna. At times it is large and takes the place of the posterior auricular artery; it may send a branch to the dura mater through the mastoid foramen.

The *posterior meningeal branches* ascend along the internal jugular vein, and enter the cranial cavity through the jugular foramen to supply the dura mater of the posterior cranial fossa.

The *mastoid branch* is a small vessel which traverses the mastoid foramen to supply the diploë, the walls of the lateral sinus, the dura mater, and the mastoid air cells.

The *princeps cervicis artery* is the largest branch of the occipital artery. It runs down the back of the neck between the splenius and the complexus muscle, and divides into a superficial and a deep branch. The *superficial branch* pierces the splenius and runs between it and the trapezius, supplying these muscles and anastomosing with the superficial cervical artery, one of the terminal branches of the transversalis colli; the *deep branch* descends between the complexus and semi-spinalis colli, supplies these muscles, and anastomoses with branches of the vertebral and with the deep cervical branch of the superior intercostal artery. The anastomoses between the occipital, vertebral, and superior intercostal arteries play an important part in the formation of the collateral circulation after ligation of the common carotid or the subclavian artery.

Communicating branches run between the recti and the superior and inferior oblique muscles to anastomose with branches of the vertebral artery.

The *terminal branches* pass laterally and mesially upward in the superficial fascia of the occipital region of the scalp to supply the scalp and pericranium, and are known as external and internal. They anastomose with the occipital artery of the opposite side, the posterior auricular and the superficial temporal artery.

The **occipital vein** accompanies the third portion of the occipital artery; it communicates with the lateral sinus through the mastoid foramen, and with the diploic veins, piercing the trapezius muscle with the occipital artery. It enters the occipital triangle and terminates in the deep cervical vein, or it may bifurcate, one subdivision emptying into the posterior jugular vein, and the other

into the deep cervical vein. The *deep cervical vein* accompanies the deep branch of the princeps cervicis artery, then the profunda cervicis, passes between the transverse process of the seventh cervical vertebra and the neck of the first rib, and empties into the innominate or vertebral vein.

The **posterior auricular artery**, the remaining posterior branch of the external carotid, is smaller than the occipital artery, and arises just above the posterior belly of the digastric muscle. It ascends obliquely upward and backward in the parotid gland, to the furrow between the pinna of the ear and the mastoid process of the temporal bone, passing below the facial nerve and over the spinal accessory nerve. Immediately above the mastoid process it divides into two branches—an anterior, which passes forward and anastomoses with the posterior division of the temporal artery, and a posterior, which anastomoses with the occipital artery.

The BRANCHES of the posterior auricular artery are the parotid, muscular, stylo-mastoid, auricular, and mastoid.

The *parotid branches* supply the lower end of the parotid gland, anastomosing with other arteries distributed to the gland.

The *muscular branches* supply the digastric, stylo-hyoid, sterno-mastoid, and retrahens aurem muscles.

The *stylo-mastoid branch* enters the stylo-mastoid foramen of the temporal bone, and supplies the tympanum, the mastoid cells, and the semicircular canals. In the fetus a branch of the stylo-mastoid artery forms, with the tympanic branch from the internal maxillary artery, a vascular circle around the circumference of the tympanic membrane; from this circle smaller vessels are given off, which ramify upon the membrane. From the aqueduct of Fallopius it sends branches to the external auditory meatus (*meatal*); to the mastoid cells and mastoid antrum (*mastoid*); to the stapedius muscle (*stapedic*); to the tympanum, forming the anastomotic circle in the fetus (*tympanic*); to the vestibule and semicircular canals (*vestibular*); and a final twig (*terminal*), which accompanies the great superficial petrosal nerve through the hiatus Fallopii and anastomoses with the petrosal branch of the middle meningeal artery.

The *auricular branch* (anterior terminal) supplies the back part of the auricle, and anastomoses with the posterior temporal and auricular branch of the superficial temporal artery; some of its branches perforate the cartilage of the pinna to supply its anterior surface.

The *mastoid branch* (occipital branch) crosses the insertion of the sterno-mastoid muscle, supplies the structures over the mastoid process, and anastomoses with the occipital artery.

The **posterior auricular vein**, which is of considerable size, accompanies the

terminal portion of the posterior auricular artery and joins the posterior division of the temporo-maxillary vein to form the external jugular vein.

The posterior auricular nerve.—Running close to the posterior auricular artery is the posterior auricular nerve, the first branch given off from the facial after its exit from the stylo-mastoid foramen. It ascends in front of the mastoid process, where it communicates with the great auricular nerve and the auricular branch of the pneumogastric nerve. Between the mastoid process and the external auditory meatus it divides into two branches: an anterior, which supplies the *retrahens aurem* and the small muscles on the back of the pinna, and a posterior occipital, the larger, which passes along the superior curved line of the occipital bone, supplying the occipitalis muscle and communicating with the small occipital nerve.

The ascending pharyngeal artery, a long, slender branch, the smallest given off from the external carotid artery, arises from the back part of that artery, about one-half of an inch above the bifurcation of the common carotid artery. At times, however, it arises from the common carotid artery. It is situated deep in the neck, in relation with the internal carotid artery, and lies upon the *rectus capitis anticus major* muscle. It ascends between the internal carotid artery and the side of the pharynx, and beneath the stylo-pharyngeus muscle and the glosso-pharyngeal nerve, to the base of the skull: here it enters the pharynx above the superior constrictor muscle, to end in the soft palate. It gives off prevertebral, pharyngeal, meningeal, palatine, and tympanic branches.

The *prevertebral branches* are small vessels which pass outward to supply the *rectus capitis anticus major* and minor muscles, the sympathetic, pneumogastric, and hypo-glossal nerves, and the deep cervical chain of lymphatic glands. They anastomose with the ascending cervical artery.

The *pharyngeal branches*, three or four in number, supply the upper and middle constrictor muscles, the mucous membrane of the pharynx, and the stylo-pharyngeus muscle. The largest of these branches, the *palatine*, enters the pharynx above the superior constrictor muscle, and terminates in the soft palate, the Eustachian tube, and the tonsil; it takes the place of the ascending palatine branch of the facial artery when this vessel is small.

The *meningeal branches*, three in number, enter the cranial cavity through the jugular foramen, in company with the internal jugular vein, through the anterior condyloid and middle lacerated foramina, to supply the dura mater.

The *tympanic branch* traverses the tympanic canaliculus, together with the tympanic branch of the glosso-pharyngeal nerve, enters the tympanum, anastomoses with the other tympanic arteries, and supplies the adjacent structures.

The descending pharyngeal vein arises in a minute plexus at the back part

and side of the pharynx. After receiving meningeal branches, the veins from the soft palate and Eustachian tube, and the Vidian vein, it terminates in the internal jugular vein. It occasionally empties into the facial vein.

Internal maxillary and temporal arteries.—The description of the internal maxillary artery is given under the Dissection of the Pterygo-maxillary Region. The temporal artery is described under the Dissection of the Face.

The **Submaxillary Triangle** (continued).—

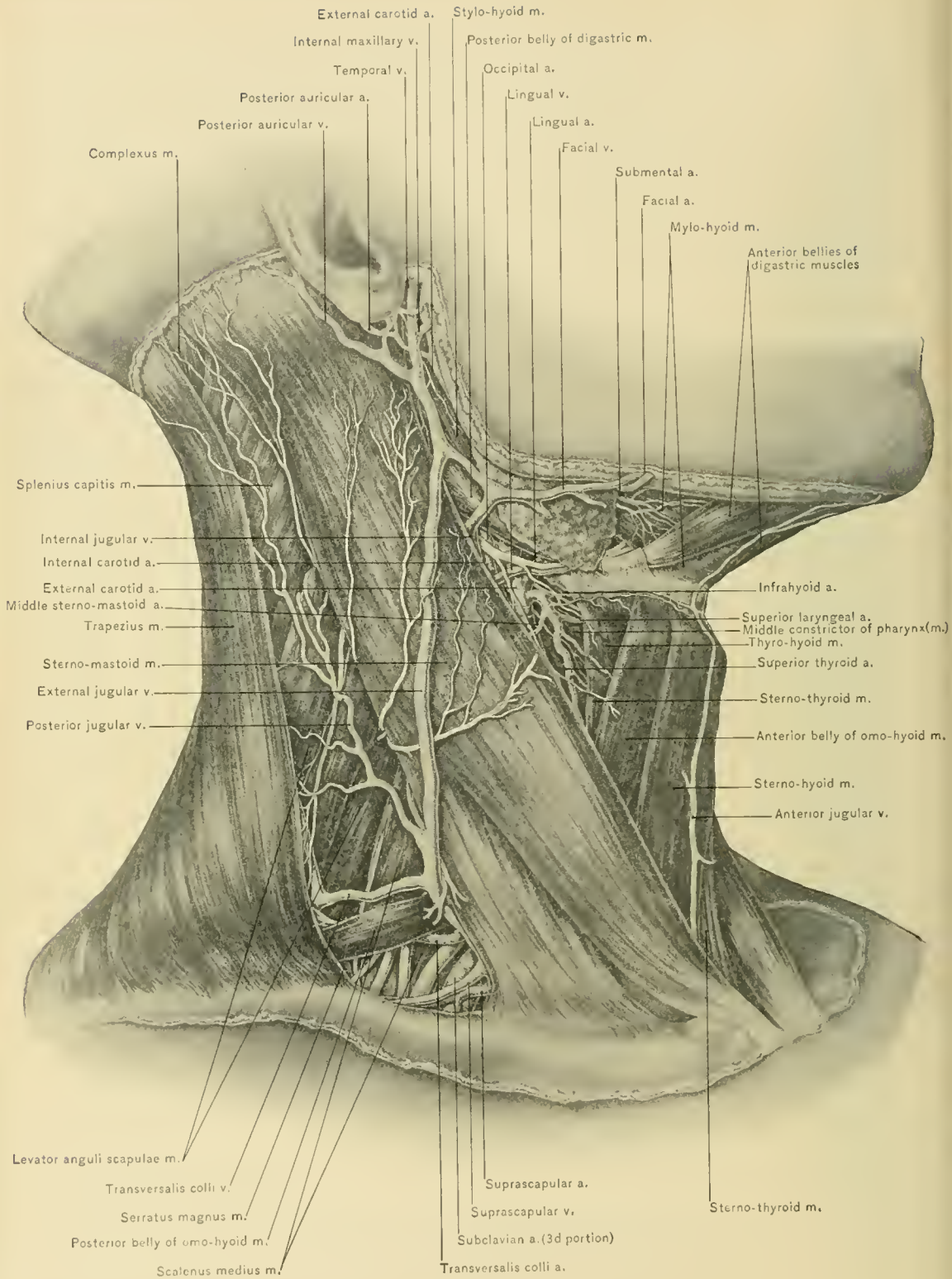
The **digastric muscle** consists of two muscular bellies, an anterior and a posterior, united by an intervening tendon. The posterior belly, the larger of the two, arises from the digastric groove, which lies to the inner side of the base of the mastoid process of the temporal bone; the anterior belly, the shorter of the two, arises from the depression on the deep surface of the lower jaw at the side of the symphysis. The fibers of the posterior belly are directed downward, forward, and inward: those of the anterior, downward and backward to the intervening tendon, which pierces the stylo-hyoid muscle, and is connected to the side of the body of the hyoid bone by a process of the deep cervical fascia lined with a synovial membrane. A broad aponeurotic expansion—the *supra-hyoid aponeurosis*—is given off on each side from the tendon of the digastric muscle, and is attached to the body and greater cornu of the hyoid bone and to aponeurotic expansion of the opposite side, so that the interval between the anterior bellies of the digastric muscles is occupied by this expansion. The posterior belly passes over the sheath of the carotid vessels, the hypo-glossal and spinal accessory nerves, and beneath the sterno-mastoid and trachelo-mastoid muscles. The occipital artery passes upward and backward along the lower border of the posterior belly. The anterior belly may be absent and the posterior belly may be double. At times accessory slips join the posterior belly from the styloid process or pharynx.

NERVE SUPPLY.—The posterior belly of the digastric muscle is supplied by a branch from the facial nerve; the anterior belly, by the mylo-hyoid, a branch of the inferior dental nerve.

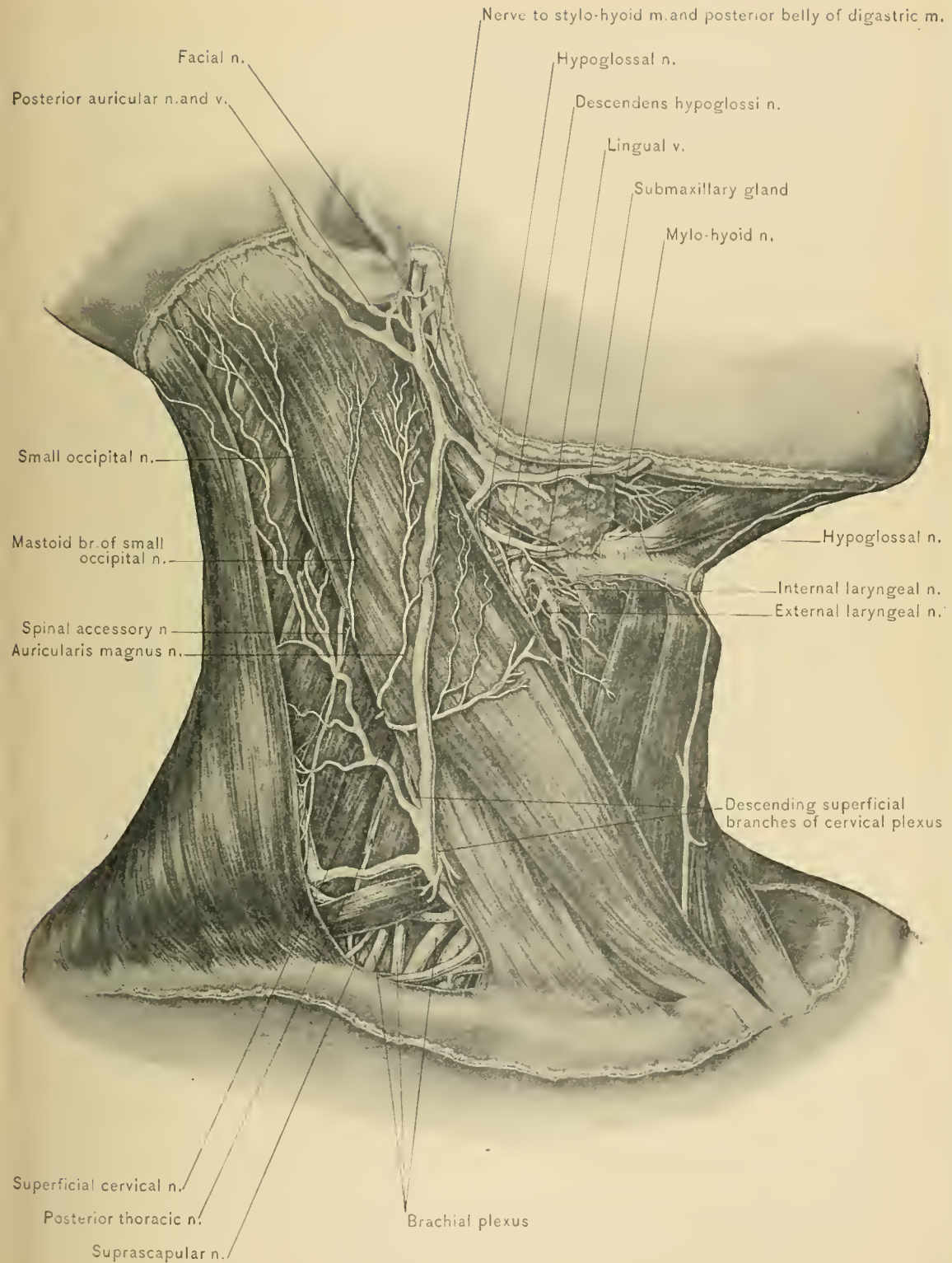
BLOOD SUPPLY.—From muscular branches of the facial, occipital, and posterior auricular arteries.

ACTION.—It depresses the lower jaw and assists in opening the mouth. If the lower jaw be fixed, the two bellies acting together would raise the hyoid bone, as in deglutition.

The **stylo-hyoid muscle** is slender, has about the same position as the poste-



SUPERFICIAL STRUCTURES OF NECK.



SUPERFICIAL STRUCTURES OF NECK.



rior belly of the digastric, and lies in contact with the upper border of the posterior belly of the digastric muscle. It arises from the middle of the outer surface of the styloid process of the temporal bone, whence it passes downward and forward to be inserted into the outer surface of the hyoid bone where the greater cornu joins the body. It lies above the posterior belly of the digastric muscle, and is pierced near its insertion by the tendon of the digastric. In some cadavers the stylo-hyoid muscle is absent.

NERVE SUPPLY.—From the facial nerve.

BLOOD SUPPLY.—From the muscular twigs of the facial, occipital, and posterior auricular arteries.

ACTION.—It raises and draws the hyoid bone backward, thus preventing the return of food into the pharynx during deglutition.

The **submaxillary gland**, one of the three salivary glands, is situated in the submaxillary triangle and extends upward under the body of the lower jaw as far as the attachment of the mylo-hyoid muscle. It weighs about two drams. It consists of a larger superficial portion and a smaller deep portion. The superficial portion of the gland is covered by the skin, superficial fascia, platysma myoides muscle, infra-maxillary branches of the facial nerve, superficial layer of the deep fascia, facial vein, some lymphatic glands, and the body of the lower jaw; it rests upon the mylo-hyoid, hyo-glossus, and stylo-glossus muscles, the facial artery, submental artery, mylo-hyoid artery and nerve, and the hypo-glossal nerve and lingual vein; in front of it lies the anterior belly of the digastric muscle; behind it is the stylo-maxillary ligament, which separates it from the parotid gland. Its deep surface contains a groove for the facial artery. The deep portion and duct of the gland (Wharton's duct), which dip under the posterior border of the mylo-hyoid muscle, will be described.

BLOOD SUPPLY.—From branches of the facial and lingual arteries.

NERVE SUPPLY.—From branches of the submaxillary ganglion, through which it receives filaments from the gustatory and chorda tympani nerves. It also receives branches from the mylo-hyoid nerve and from the sympathetic plexus around the facial artery.

DISSECTION.—Reflect the submaxillary gland upward without dividing the facial vein, which runs over the gland, or the facial and submental arteries, which are beneath it. The submaxillary branches of the facial artery which supply the gland must be divided. This exposes a portion of the facial artery and its infra-maxillary branches, the mylo-hyoid artery and nerve, a part of the hypo-glossal nerve and lingual vein, the mylo-hyoid, hyo-glossus, and stylo-glossus muscles.

The cervical portion of the facial artery and its submaxillary, submental, ascending palatine, and tonsillar branches have been described.

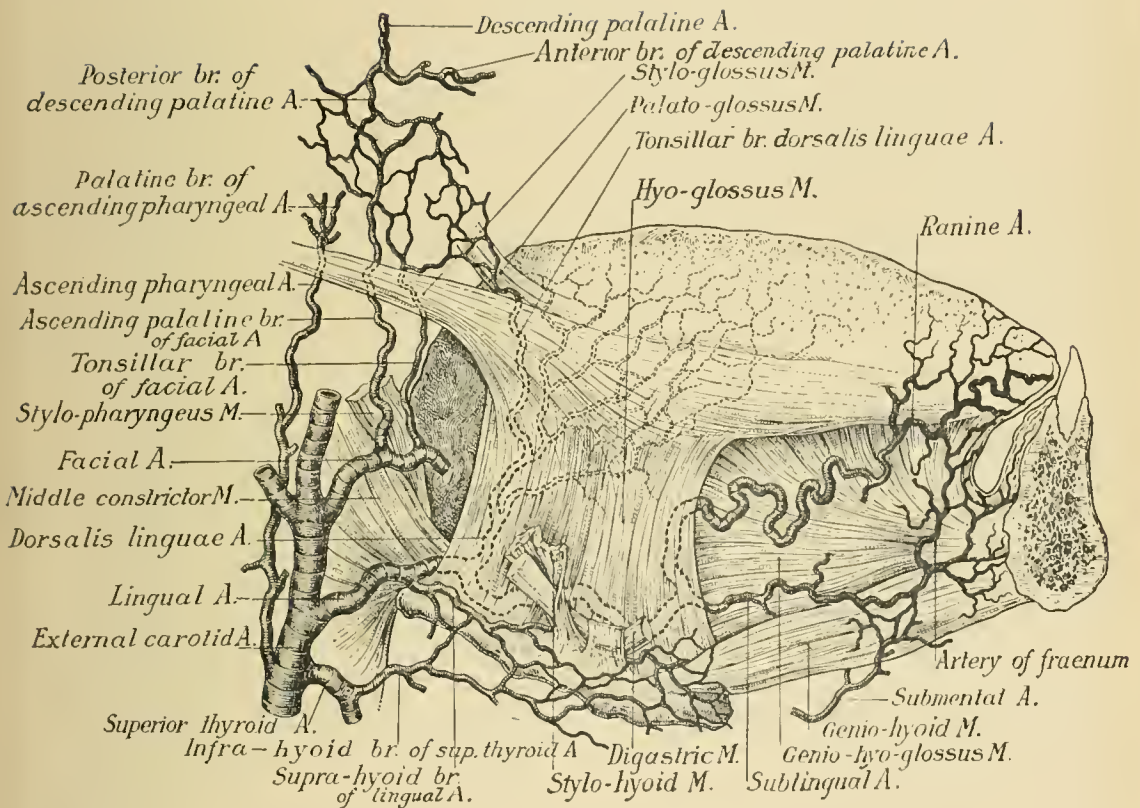
The **mylo-hyoid nerve**, a branch of the inferior dental nerve, may be seen emerging from between the lower jaw and the internal pterygoid muscle. It runs forward with the submental artery upon the mylo-hyoid muscle, to terminate in the anterior belly of the digastric muscle, supplying the mylo-hyoid and the anterior belly of the digastric muscle.

The **mylo-hyoid artery** accompanies the mylo-hyoid nerve between the internal pterygoid muscle and lower jaw, and anastomoses with the submental and dorsalis linguae arteries.

The **hypo-glossal nerve**, the motor nerve of the tongue, is the twelfth or last of the cranial nerves. It leaves the cranial cavity at the anterior condyloid foramen, and descends almost vertically toward the angle of the lower jaw, lying at first deeply beneath the internal jugular vein and internal carotid artery, and is intimately connected with the lower ganglion (ganglion of the trunk) of the pneumogastric nerve. It then passes forward between the internal jugular vein and the internal carotid artery, and beneath the posterior belly of the digastric muscle, at the lower border of which it becomes more superficial and enters the superior carotid triangle. It next passes over the internal carotid and curves around the occipital artery, at its origin from the external carotid artery; thence it continues forward over the external carotid and facial arteries, and near the greater cornu of the hyoid bone, over the superior laryngeal nerve, the middle constrictor muscle of the pharynx, and the hyo-glossus muscle, forming a loop the convexity of which is directed downward and outward. At the anterior border of the hyo-glossus muscle it communicates with the gustatory or lingual nerve. It passes beneath the tendon of the digastric, the stylo-hyoid, and the mylo-hyoid muscle. After running beneath the stylo-hyoid and the posterior part of the tendon of the digastric muscle, it lies in the submaxillary triangle upon the hyo-glossus muscle, and beneath the submaxillary gland. Here it forms the base of the lingual triangle, and lies above the lingual vein. It supplies all of the extrinsic muscles of the tongue, the thyro-hyoid, and through the descendens hypoglossi nerve assists in supplying the omo-hyoid, sterno-hyoid, and sterno-thyroid muscles. The branch to the thyro-hyoid muscle is given off near the tip of the greater cornu of the hyoid bone, and passes obliquely downward and forward to reach the superficial surface of that muscle.

Paralysis of one hypo-glossal nerve causes wasting and flabbiness of the corresponding half of the tongue; when the tongue is protruded, the tip of the organ is carried toward the paralyzed side.

DISSECTION.—In completing the dissection of the submaxillary triangle, the anterior belly of the digastric muscle should be detached from the lower jaw and displaced downward, when the mylo-hyoid, the muscle forming the greater part



of the floor of the triangle, as well as the greater part of the floor of the mouth, will be completely exposed.

The **mylo-hyoid** is a triangularly shaped muscle, with its base at the lower jaw and its apex at the hyoid bone; it unites along the middle line with the mylo-hyoid muscle of the opposite side. It is sometimes termed the diaphragm of the mouth, or the upper diaphragm. It arises from the mylo-hyoid ridge (internal oblique line) of the lower jaw, its origin extending from the symphysis as far backward as the last molar tooth. The posterior fibers are inserted into the body of the hyoid bone; the middle and anterior fibers into the median fibrous raphé, where they join the fibers of the opposite muscle. Its lower or cutaneous surface has the anterior belly of the digastric muscle, the supra-hyoid aponeurosis, the mylo-hyoid nerve and artery, the submental vessels, and the submaxillary glands in relation with it. The duct of the submaxillary gland winds around its free posterior border. In relation with its deep or buccal surface are the genio-hyoid muscle, part of the hyo-glossus and stylo-glossus muscles, the deep part of the submaxillary gland, Wharton's duct, the hypo-glossal and gustatory nerves, the submaxillary ganglion, the sublingual gland, the ranine and sublingual arteries, and the mucous membrane of the mouth.

NERVE SUPPLY.—From the mylo-hyoid branch of the inferior dental nerve.

BLOOD SUPPLY. From the submental branch of the facial artery.

ACTION.—When both muscles act conjointly from their point of origin they elevate the hyoid bone, the larynx, and the floor of the mouth, preparatory to swallowing; when acting from their hyoid attachment they assist in depressing the jaw and in opening the mouth.

DISSECTION.—Divide the facial vessels immediately below the lower jaw, and displace them upward with the superficial part of the submaxillary gland, leaving *in situ* the deep part of the gland which turns beneath the mylo-hyoid muscle and has the submaxillary ganglion in contact with it. Divide the small vessels and nerves on the cutaneous surface of the mylo-hyoid muscle, detaching it from the lower jaw and the mylo-hyoid muscle of the opposite side, and displace it downward. This exposes the structures in relation with the upper surface of the mylo-hyoid muscle.

The **genio-hyoid** is a slender muscle which arises from the lower of the two lateral (genial) tubercles on the inner aspect of the symphysis of the lower jaw, and is inserted into the middle of the front of the body of the hyoid bone. It is covered by the mylo-hyoid muscle, rests upon the genio-hyo-glossus muscle, and mesially against the genio-hyoid muscle of the opposite side.

NERVE SUPPLY.—From the hypo-glossal nerve.

BLOOD SUPPLY.—From the lingual artery.

ACTION.—It raises and advances the hyoid bone; when the mouth is closed, acting in the reverse direction, it assists in depressing the lower jaw and in opening the mouth. It may be inseparable from the genio-hyoid muscle of the other side.

DISSECTION.—The lower jaw should be sawed through at two points—viz., immediately in advance of the angle and at the symphysis; the intervening portion, carrying with it the mucous membrane of the mouth, should be displaced upward, and fastened with hooks or with a stitch. The tongue should next be drawn out of the mouth, with its tip fastened to the nose, and the hyoid bone drawn downward and also fixed by means of hooks, thus putting the muscular fibers of the tongue on the stretch. All the fat and connective tissue having been removed, the following structures should be carefully examined: The hyo-glossus, stylo-glossus, and genio-hyo-glossus muscles, the lingual vein, the hypo-glossal nerve, the gustatory or lingual nerve, the submaxillary ganglion, Wharton's duct, the deep portion of the submaxillary gland, the sublingual gland, the ranine and sublingual arteries.

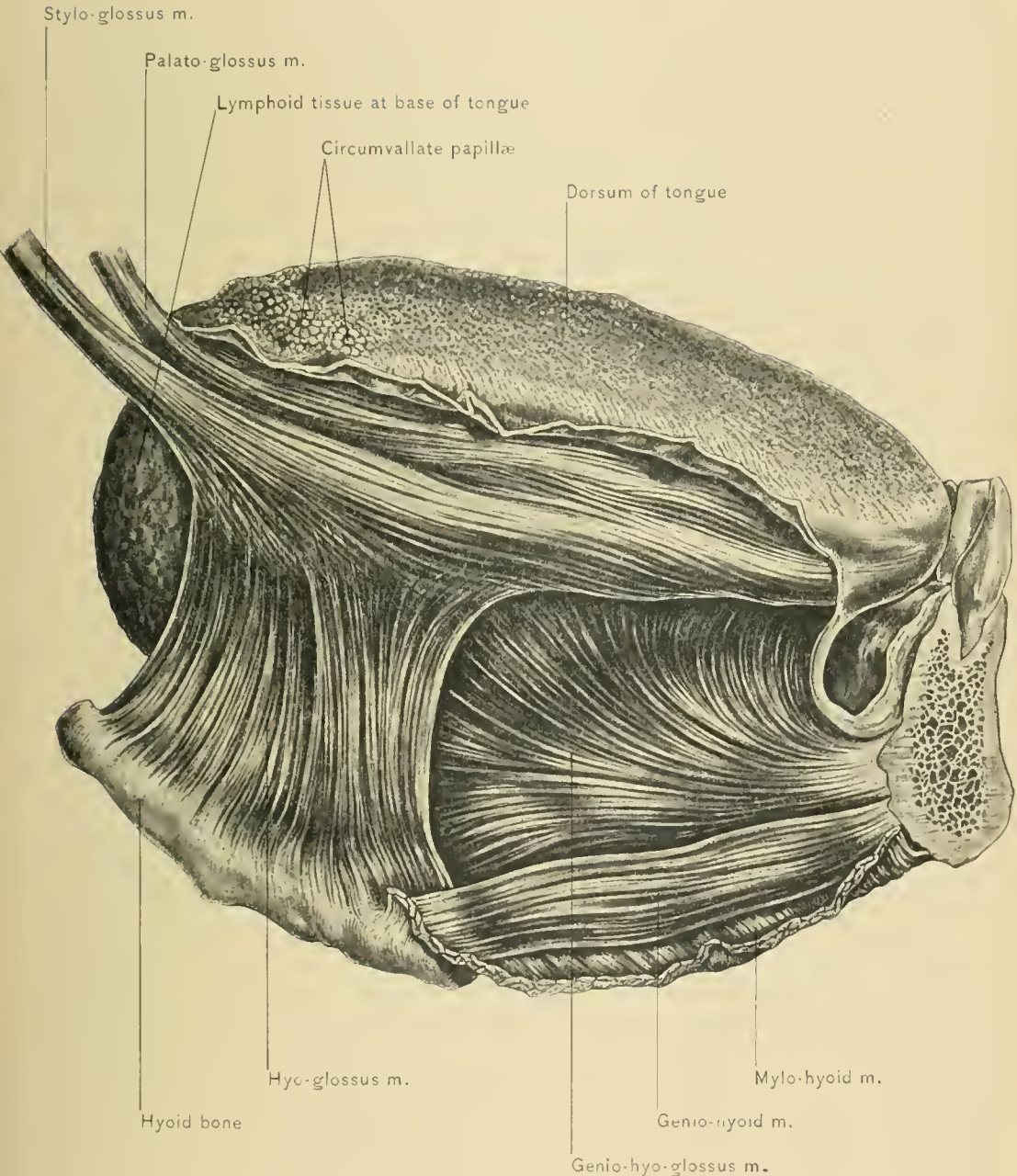
The **hyo-glossus** is a thin, flat, square-shaped muscle, arising from the side of the body of the hyoid bone and from its greater and lesser cornua. It is inserted into the posterior half of the side of the tongue between the stylo-glossus and lingualis muscles. Its fibers ascend almost perpendicularly from their origin to their insertion, and mingle with the fibers of the palato-glossus and stylo-glossus muscles. The fibers arising from the body of the hyoid bone, termed the *basio-glossus*, pass upward and backward, and overlap those which arise from the greater cornu, termed the *kerato-glossus*, which are directed obliquely forward. Those fibers which arise from the lesser cornu are termed the *chondro-glossus*, and are separated from the remainder of the muscle by a few fibers of the genio-hyo-glossus muscle; they are covered by the fibers arising from the body of the hyoid bone.

NERVE SUPPLY.—From the hypo-glossal nerve.

BLOOD SUPPLY.—From the lingual artery.

ACTION.—It draws the side of the tongue downward, and when the tongue is protruded it draws it back into the mouth.

RELATIONS OF THE HYO-GLOSSUS MUSCLE.—Upon the outer surface of the muscle are the hypo-glossal nerve and the small branch which ascends to the stylo-glossus muscle, the gustatory or lingual nerve, the loop of communication between the gustatory and hypo-glossal nerves, the submaxillary ganglion, the submaxillary gland, Wharton's duct, the hyoid branch of the lingual artery, the lingual vein, the sublingual gland, the posterior belly of the digastric, the stylo-hyoid, stylo-glossus, and myo-hyoid muscles. Its deep surface is in contact with the genio-hyo-glossus, lingualis, middle constrictor muscle of the pharynx, part of the origin of the superior constrictor muscle, the lingual artery, the glosso-pharyngeal nerve, and the



EXTRINSIC MUSCLES OF TONGUE.

stylo-hyoid ligament. At the posterior border of the hyo-glossus muscle may be seen the lingual artery, the glosso-pharyngeal nerve, and the stylo-hyoid ligament passing beneath the muscle. At the anterior border may be seen the loop of communication between the gustatory and hypo-glossal nerves, the branches of which can be traced to the under surface of the tongue; and the ranine artery, emerging from beneath the anterior border of the hyo-glossus muscle.

The **stylo-glossus muscle**—the smallest of the three muscles which arise from the styloid process—has its origin from the front and outer side of that process near its apex and from the stylo-maxillary ligament. Its fibers pass downward and forward, and then run almost horizontally to be inserted along the side of the tongue, superficial to the hyo-glossus muscle and as far forward as the tip of that organ; they blend with the fibers of the lingualis muscle. Beneath the lower jaw the stylo-glossus muscle is crossed by the gustatory or lingual nerve.

NERVE SUPPLY.—From the hypo-glossal nerve.

BLOOD SUPPLY.—From the muscular branches of the facial artery.

ACTION.—When both muscles act together they raise the back of the tongue toward the roof of the mouth. When the tongue is protruded, they draw it back into the mouth. They also draw the sides of the tongue upward, thus helping to make it transversely concave.

The **genio-hyo-glossus muscle**, the largest of the muscles of the tongue, is triangular in shape, with its apex attached to the lower jaw, and its base to the tongue and the hyoid bone. It arises from the upper genial tubercle on the inner aspect of the symphysis of the lower jaw, immediately above the genio-hyoid muscle. The fibers diverge from their origin, the inferior fibers passing downward to be inserted into the body of the hyoid bone, the middle fibers into the side of the pharynx, and the superior fibers into the tongue from the root to the tip. In relation with the external surface of the muscle are the stylo-glossus, hyo-glossus, and lingualis muscles, the lingual artery, the hypo-glossal and gustatory nerves, the sublingual gland, and the submaxillary or Wharton's duct. It is separated from the genio-hyo-glossus muscle of the opposite side by the fibrous septum,—the *septum linguae*,—which extends through the middle of the tongue. Below it is the genio-hyoid muscle.

NERVE SUPPLY.—From the hypo-glossal nerve.

BLOOD SUPPLY.—From the lingual artery.

ACTION.—By the simultaneous action of all the fibers of the muscle attached to the tongue that organ is depressed and its upper surface grooved. The fibers inserted near the base of the tongue protrude it, while those attached near the tip retract it after it has been protruded. The inferior fibers aid the genio-hyoid and anterior belly of the digastric muscle in pulling the hyoid bone upward and

forward; acting from below, they tend to depress the chin. Contraction of this muscle in epileptic convulsions causes the tongue to protrude from the mouth, and it may thus be bitten. In certain fractures of the lower jaw, as well as in some operations about the tongue and floor of the mouth in which the origin of this muscle is detached, the tongue has a tendency to fall backward over the superior aperture of the larynx, and respiration may be embarrassed. During anesthetization the base of the tongue at times falls backward, and breathing becomes labored; by carrying the angles of the lower jaw forward, the genio-hyo-glossus muscles are made to pull the tongue forward, and thus to relieve the difficulty. If the genio-hyo-glossus muscle of one side is paralyzed and the patient is asked to protrude the tongue, the sound muscle pulls its own side of the base of the tongue forward, whereas the other side is not acted upon; the tip of the organ will consequently protrude toward the paralyzed side.

The **lingual vein** arises near the tip of the tongue, where it is also known as the ranine vein. It receives a branch of the superior thyroid vein and the venæ comites of the lingual artery, the tributaries of which correspond to the branches of the lingual artery. It accompanies the hypo-glossal nerve over the outer surface of the hyo-glossus muscle, which separates it from the lingual artery. It passes beneath the stylo-hyoid and posterior belly of the digastric muscle, and empties into the internal jugular or facial vein. When the lingual vein empties into the internal jugular vein, it crosses the external carotid artery at about the level of the greater cornu of the hyoid bone.

The hypo-glossal nerve.—Its course as far as the point where it passes beneath the posterior border of the mylo-hyoid muscle has been described. In the submaxillary triangle it lies on the hyo-glossus muscle, accompanied by the lingual vein, and communicates with the gustatory or lingual nerve at the anterior border of that muscle, from which point it continues forward to the tip of the tongue in the substance of the genio-hyo-glossus muscle.

The **gustatory or lingual nerve** is a branch of the inferior maxillary division of the fifth nerve, and for some little distance from its origin it lies in the pterygo-maxillary region. This portion of the nerve has been described under the Dissection of the Pterygo-maxillary Region. Passing between the ramus of the lower jaw and the internal pterygoid muscle it leaves the pterygo-maxillary region, inclines forward along the side of the tongue, and runs upon the superior constrictor muscle of the pharynx and between the stylo-glossus muscle and the deep portion of the submaxillary gland. It next crosses the upper part of the hyo-glossus muscle and Wharton's duct, whence it passes between the mylo-hyoid muscle and the mucous membrane of the floor of the mouth along the side of the tongue to its tip. Two or more branches connect the gustatory nerve with the submaxillary

ganglion near the root of the tongue, while near the anterior border of the hyo-glossus muscle it forms a loop with the hypo-glossal nerve.

It supplies the mucous membrane of the mouth, the lower gums, and the sublingual and submaxillary glands, and gives off branches which ascend through the muscular substance of the tongue to the filiform and fungiform papillæ. The branches to the sublingual and submaxillary glands contain secreto-motor fibers, which, when stimulated, increase the secretion of these glands. The lingual is the common sensory nerve of the tongue, and contains taste fibers for the anterior two-thirds of that organ.

The **submaxillary ganglion** is small, and is situated upon the hyo-glossus muscle, between the gustatory nerve and the deep portion of the submaxillary gland and beneath the posterior border of the mylo-hyoid muscle. Like the other ganglia of the head, it is connected with the branches of the trifacial nerve and receives filaments of communication of three kinds—viz., motor, sensory, and sympathetic. Its motor root arises from the facial nerve through the chorda tympani; the sensory branches are derived from the gustatory or lingual nerve; its connection with the sympathetic nerve is through a branch which comes from the *nervi molles* around the facial artery. Its branches of distribution, five or six in number, supply the mucous membrane of the floor of the mouth, and the submaxillary gland and its duct.

Wharton's duct, the duct of the submaxillary gland, is about two inches long, and has its origin in the deep portion of the gland. It winds around the posterior or free border of the mylo-hyoid muscle, then lies on the hyo-glossus muscle, between the hypo-glossal and gustatory nerves, under cover of the mylo-hyoid muscle; thence it passes forward over the genio-hyo-glossus muscle, and beneath the gustatory nerve and sublingual gland, terminating in a constricted opening, situated on a small papilla in the floor of the mouth at the side of the lingual frenum. Near its termination it is joined by one of the ducts of the sublingual gland—the duct of Bartholin.

The submaxillary gland.—The deep portion of the submaxillary gland turns forward around the posterior or free border of the mylo-hyoid muscle, lying between it and the hyo-glossus muscle.

The sublingual gland, the smallest of the three salivary glands, lies upon the mylo-hyoid muscle beneath the mucous membrane of the floor of the mouth at the side of the lingual frenum, where it produces an oblong prominence. It is in contact, on its inner side, with the hyo-glossus, genio-hyo-glossus, and stylo-glossus muscles, the gustatory nerve, and the duct of the submaxillary gland. On its outer side it is in relation with the sublingual fossa in the body of the lower jaw and with the mylo-hyoid muscle; behind, with the deep portion of the submaxil-

lary gland, touching the other sublingual gland in the mesial plane. It measures about one and one-half inches in its long diameter, and weighs about one dram. Its ducts—*ducti Rivini*—are from ten to twenty in number, and open separately on the ridge at each side of the lingual frenum, with the exception of two or more which join to form the *duct of Bartholin*, which opens either near or into Wharton's duct.

BLOOD SUPPLY.—From the lingual and submental arteries.

NERVE SUPPLY.—From the gustatory, chorda tympani, and sympathetic nerves.

Obstruction of the salivary ducts.—The duct of the submaxillary gland may become obstructed by a calculus, and give rise to a hard and painful swelling over the site of the duct, perceptible through the submaxillary triangle and through the floor of the mouth. Obstruction and dilatation of one of the several ducts opening at the side of the lingual frenum will occasion a cystic swelling known as *ranula*; this condition may also be due to an obstructed mucous follicle.

DISSECTION.—Detach the hyo-glossus muscle from the hyoid bone and lift it up, when the structures in relation with the deep surface may be seen; these are the horizontal portion, and the commencement of the ascending portion, of the lingual artery, part of the genio-hyo-glossus muscle, the lingualis muscle, the origin of the middle constrictor muscle of the pharynx, the glosso-pharyngeal nerve, and the stylo-hyoid ligament.

The **horizontal or second portion of the lingual artery** rests upon the middle constrictor of the pharynx and the genio-hyo-glossus muscle, below the level of the glosso-pharyngeal nerve, and is covered by the tendon of the digastric, the stylo-hyoid, and the hyo-glossus muscle. From this portion the *dorsalis linguæ artery* is given off, which ascends to the base of the tongue to supply the mucous membrane back of the circumvallate papillæ, the tonsil, and the soft palate. It anastomoses with the *dorsalis linguæ* of the opposite side, but this anastomosis is so fine that but slight bleeding follows severance of the tongue accurately in the median line.

The **ascending or third portion of the lingual artery** commences beneath the hyo-glossus muscle. It rests upon the genio-hyo-glossus, and passes tortuously between the genio-hyo-glossus and the lingualis muscle to the tip of the tongue, being covered only by the mucous membrane of the under surface of this organ. This portion gives off the sublingual artery and continues as the ranine.

The **ranine artery**, the continuation of the lingual artery, passes to the tip of the tongue along the outer side of the genio-hyo-glossus muscle, running between it and the lingualis muscle, and is accompanied by the ranine vein and the terminal portion of the gustatory nerve. Near the tip of the tongue it anastomoses

with the ranine artery of the opposite side, and on its way supplies the adjacent muscles and mucous membrane.

The **sublingual artery**, smaller than the ranine, arises near the anterior border of the hyo-glossus muscle, and runs outward and forward over the oral surface of the mylo-hyoid muscle to reach the sublingual gland. It supplies the sublingual gland, the mylo-hyoid muscle, the mucous membrane of the floor of the mouth, and the gums. It anastomoses with the opposite sublingual artery, and with the submental branch of the facial artery, after having perforated the mylo-hyoid muscle.

The **artery of the frenum** is usually a branch of the sublingual artery. It is sometimes wounded in operating for "tongue tie." The best way to divide the lingual frenum so as to avoid wounding the vessel is to place the child upon its back in the mother's lap, and, with the head held tightly between the knees of the operator, to engage the frenum in the slot of a grooved director, by means of which the point of the tongue can be held up. The frenum is thus made tense, and at its attachment to the lower jaw is then simply nicked with a pair of blunt scissors, after which any additional separation which may be required can be done with the finger nail.

The **stylo-pharyngeus muscle**, long and slender, arises from the inner side of the base of the styloid process, and is the longest of the three muscles arising therefrom. It passes downward and forward, and disappears between the middle and superior constrictor muscles of the pharynx. Some of its fibers join the palato-pharyngeus muscle, to be inserted into the posterior border of the thyroid cartilage. The remaining fibers become connected with the fibers of the constrictor muscles of the pharynx. Running along its outer side is the glosso-pharyngeal nerve. In order to reach the tongue, to which it is partly distributed, the nerve passes over the muscle, supplying it with twigs.

The **stylo-hyoid ligament** is a fibrous cord which passes from the tip of the styloid process to the lesser cornu of the hyoid bone. It may be seen lying near the anterior border of the stylo-pharyngeus muscle, and passing beneath the hyo-glossus muscle to the lesser cornu of the hyoid bone. It is the continuation of the styloid process; it may contain nodules of cartilage, and may be largely ossified, forming an unusually long styloid process.

DISSECTION.—Cut off the styloid process at its base, and reflect it downward with the attached muscles and the stylo-hyoid ligament.

The **glosso-pharyngeal nerve**.—Running along the posterior border of the stylo-pharyngeus muscle, and crossing in front of it, is the glosso-pharyngeal nerve. It curves upon the side of the neck, the convexity being directed downward and backward; it resembles in this respect the hypo-glossal and superior laryngeal

nerves. The principal landmark for finding this nerve is the stylo-pharyngeus muscle, around which it curves. Beyond the stylo-pharyngeus muscle the glosso-pharyngeal nerve lies on the middle constrictor muscle of the pharynx. The terminal portion of the nerve lies beneath the hyo-glossus muscle, where it divides into two terminal lingual branches, one supplying the mucous membrane covering the posterior third of the dorsum of the tongue, and the other the mucous membrane of the side of the tongue, inosculating with the lingual nerve. The glosso-pharyngeal is a nerve of motion, sensation, and special sense (taste): of *motion*, to the muscles of the pharynx; of *sensation*, to the mucous membrane of the fauces, tonsil, and pharynx; and of *taste*, to the base of the tongue and the fauces.

It leaves the cranial cavity by way of the middle compartment of the jugular foramen, clothed by a separate sheath of the dura mater, and lying in advance of, and a little internal to, the pneumogastric and spinal accessory nerves. Having made its exit from the foramen, it descends between the internal jugular vein and the internal carotid artery, crosses over the latter vessel obliquely, and passes beneath the styloid process and the muscles arising therefrom, to reach the posterior border of the stylo-pharyngeus muscle, as previously described.

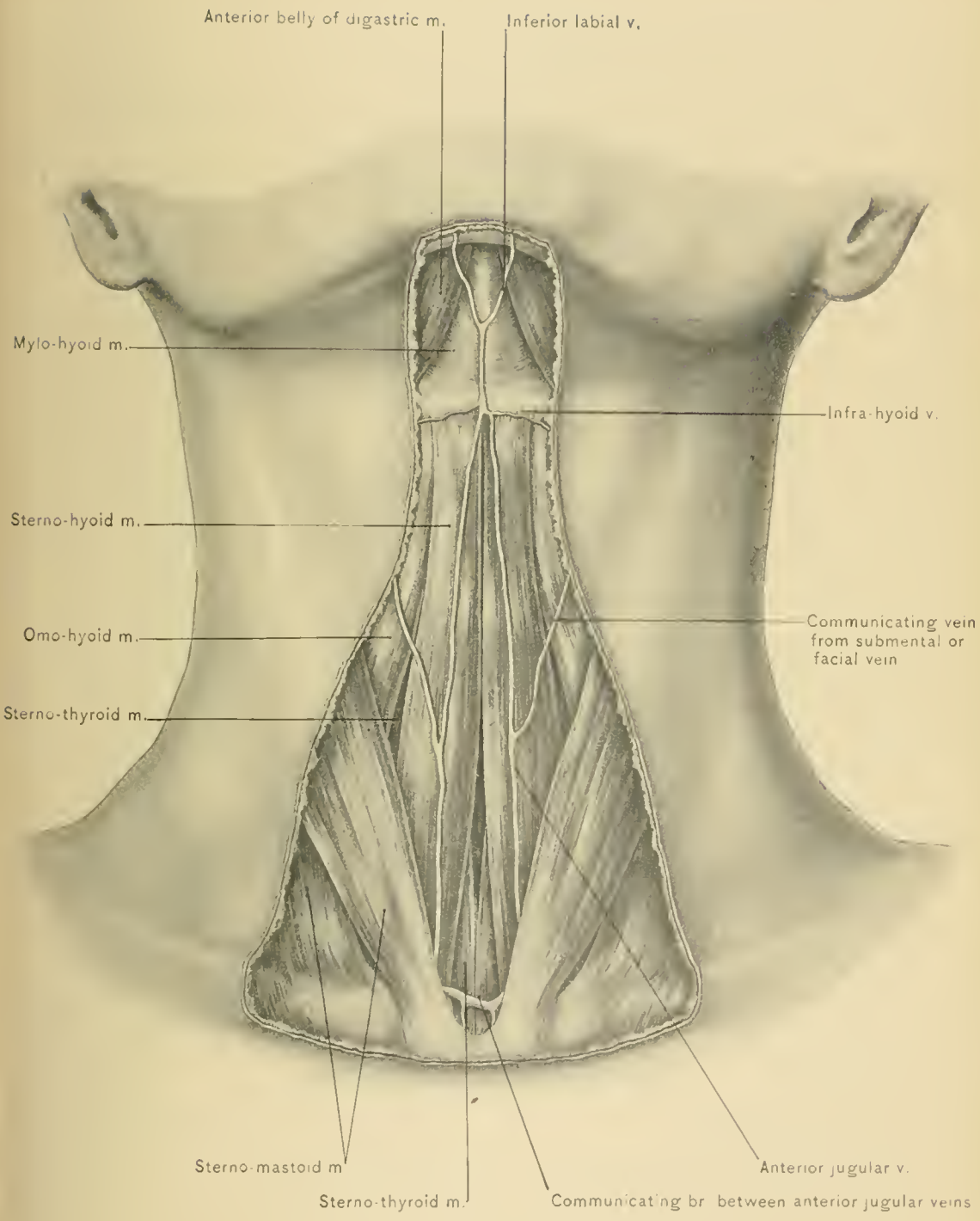
Upon the trunk of the nerve in the jugular foramen are two ganglia: an upper, the *jugular*, and a lower, the *petrous*. The former is inconstant, and both are considered analogous to the ganglia on the posterior roots of the spinal nerves. At the petrous ganglion (ganglion of Andersch), the glosso-pharyngeal nerve is connected with the pneumogastric and sympathetic nerves by communicating branches. The branches of the glosso-pharyngeal nerve, other than the terminal lingual and the communicating, are the meningeal, tympanic, carotid, pharyngeal, muscular, and tonsillar.

The *meningeal branches* arise within the cranial cavity, and are distributed to the pia mater and arachnoid.

The *tympanic branch* (*Jacobson's nerve*) arises from the petrous ganglion, and passes to the inner wall of the tympanum through a bony canal (the tympanic canaliculus) the orifice of which is situated upon the ridge of bone between the carotid canal and the jugular fossa. It ramifies upon the promontory of the tympanum, forming the tympanic plexus, which supplies branches to the round and oval windows, and to the Eustachian tube, and communicates with the carotid plexus and with the great and small superficial petrosal nerves.

The *carotid branches* surround the cervical portion of the internal carotid artery, and communicate with the pneumogastric and sympathetic nerves.

The *pharyngeal branches*, three or four in number, join branches from the pneumogastric, superior laryngeal, and sympathetic nerves, and from the *pharyngeal plexus*, which supplies the pharynx.



SUPERFICIAL STRUCTURES NEAR MEDIAN LINE OF NECK.

The *muscular branch* supplies the stylo-pharyngeus muscle.

The *tonsillar branches* arise under the hyo-glossus muscle, and are distributed to and around the tonsils, forming a plexus from which branches to the fauces and soft palate are derived.

The *communicating branches* arise from the petrous ganglion, as stated, and run to the superior cervical ganglion; to the auricular branch of the pneumogastric, forming a loop; an inconstant branch to the ganglion of the root of the pneumogastric nerve; and one from the nerve just below the ganglion, to join the lingual branch of the facial nerve.

The *lingual branches* proceed from the end of the glosso-pharyngeal nerve, and are, therefore, its terminal filaments. They are distributed mainly to the circumvallate papillæ, while some filaments supply the follicular glands of the tongue and the front of the epiglottis. Others inosculate around the foramen cæcum with those of the same nerve of the opposite side.

The **Internal Carotid Artery**, the larger of the two terminal divisions of the common carotid, ascends perpendicularly by the side of the pharynx to the base of the skull, where it enters the carotid canal, in the petrous portion of the temporal bone. It lies at first on the outer side of the external carotid artery, and then behind it. At its origin it is more superficial than elsewhere, and lies in the superior carotid triangle; but as it ascends it lies more deeply, passing beneath the parotid gland, the posterior belly of the digastric muscle, styloid process, stylo-pharyngeus and stylo-hyoid muscles. It is crossed by the hypo-glossal and glosso-pharyngeal nerves, and the occipital and posterior auricular arteries. Externally it is in close relation with the internal jugular vein and the pneumogastric nerve, and near the base of the skull with the glosso-pharyngeal, hypo-glossal, and spinal accessory nerves; behind, with the rectus capitis anticus major muscle, the superior ganglion of the sympathetic nerve, and the superior laryngeal nerve; internally, with the pharynx, the tonsil, and the ascending pharyngeal artery; in front it is covered by the skin, fasciæ, parotid gland, and the structures which pass between it and the external carotid artery—the stylo-glossus and stylo-pharyngeus muscles, the glosso-pharyngeal nerve, and the stylo-hyoid ligament.

DISSECTION.—The deep fascia upon each side of the median line of the neck having been removed, the anterior belly of the omo-hyoid, the sterno-hyoid, sterno-thyroid, and thyro-hyoid muscles will be exposed.

The **omo-hyoid muscle** consists of two bellies, an anterior and a posterior, connected by an intervening tendon. The anterior belly, which is exposed in this dissection, commences at the tendon intervening between the two bellies of the muscle beneath the sterno-mastoid muscle and in front of the carotid sheath, on a level with the cricoid cartilage. It passes upward along the outer border of

the sterno-hyoid and over the sterno-thyroid and thyro-hyoid muscles, to be inserted into the lower border of the body of the hyoid bone external to the sterno-hyoid muscle. It lies beneath the superficial layer of the deep fascia and sterno-mastoid muscle, and in front of the thyro-hyoid and sterno-thyroid muscles and the carotid sheath. It may be absent or double, or may blend with the adjacent sterno-hyoid muscle; occasionally it receives an accessory slip from the manubrium sterni, or sends one to the lower jaw.

The posterior belly of the muscle has already been seen crossing the posterior triangle just above the clavicle, and dividing it into the occipital and subclavian triangles. It arises from the upper border of the scapula, behind the supra-scapular notch, and from the transverse ligament, and may have an additional origin from the upper surface of the middle third of the clavicle. It terminates in the tendon of the omo-hyoid muscle which crosses the carotid sheath. It is covered by the superficial layer of the deep fascia, trapezius muscle, clavicle, subclavius muscle, sterno-mastoid muscle, external jugular vein, and the descending superficial branches of the cervical plexus of nerves. It passes over the first digitation of the serratus magnus muscle and third part of the subclavian artery, the transversalis colli and supra-scapular arteries, the supra-scapular nerve, the cervical trunks of the brachial plexus, the scaleni muscles, the prevertebral fascia, and the carotid sheath. The intervening tendon is bound down by a process of the deep fascia, attached to the clavicle and first rib.

ACTION.—It draws the hyoid bone downward and assists in making tense the lower portion of the deep cervical fascia, thus diminishing the atmospheric pressure upon the large veins at the root of the neck and favoring the return circulation.

NERVE SUPPLY.—It is supplied by the descendens hypoglossi and the communicantes hypoglossi nerves.

The **sterno-hyoid muscle** arises from the posterior surface of the upper part of the manubrium sterni, the posterior sterno-clavicular ligament, and the posterior surface of the inner extremity of the clavicle. Its fibers pass upward and inward to be inserted into the lower border of the body of the hyoid bone. It has, at times, a tendinous intersection in its lower part. It lies beneath the skin and fascia, anterior jugular vein, sterno-mastoid muscle, sterno-clavicular joint, and the manubrium sterni; in front of the sterno-thyroid, thyro-hyoid, and crico-thyroid muscles, the thyroid and cricoid cartilages, the thyro-hyoid and crico-thyroid membranes, the pretracheal fascia, trachea, isthmus of the thyroid body, and inferior thyroid veins.

NERVE SUPPLY.—From the loop between the descendens and communicantes hypoglossi nerves.

BLOOD SUPPLY.—From branches of the superior thyroid artery.

ACTION.—It draws the hyoid bone downward, as after swallowing. In labored respiration it will act as an elevator of the sternum, being an accessory muscle of respiration.

The **sterno-thyroid muscle** is wider and shorter than the sterno-hyoid muscle, beneath which it lies. It arises from the posterior surface of the upper part of the manubrium sterni and the cartilage of the first rib, below, and internal to the sterno-hyoid muscle. Its fibers pass upward and outward, and are inserted into the oblique line on the side of the thyroid cartilage, where it is continuous with the thyro-hyoid muscle. In the inferior carotid triangle the outer border of the muscle partly overlaps the sheath of the common carotid artery. It lies beneath the skin and fasciæ, the manubrium sterni, anterior jugular vein, sterno-mastoid, sterno-hyoid, and anterior belly of the omo-hyoid muscle, and in front of the thyroid and cricoid cartilages, the crico-thyroid muscle, the inferior constrictor muscle of the pharynx, thyroid gland, inferior thyroid veins, pretracheal fascia, trachea, common carotid artery, and left innominate vein. This muscle may be absent or double.

NERVE SUPPLY.—From the ansa hypoglossi.

ACTION.—It draws the thyroid cartilage downward, as after swallowing, and assists the crico-thyroid muscle in making tense the vocal cords, by drawing the thyroid cartilage downward and forward. It is an accessory muscle of respiration.

The *interspace* between the internal borders of the sterno-hyoid muscles is wider at the sternum than at the hyoid bone, while the interspace between the inner margins of the sterno-thyroid muscles is wider above than at the sternum; a lozenge-shaped intermuscular space is thus formed.

The **thyro-hyoid muscle**, apparently an extension of the sterno-thyroid muscle, arises from the oblique line on the side of the thyroid cartilage. Its fibers ascend and are inserted into the lower border of the body and the inner half of the greater cornu of the hyoid bone. The sterno-mastoid, sterno-hyoid, and the anterior belly of the omo-hyoid muscle pass over the outer surface of the thyro-hyoid muscle; the superior laryngeal vessels and nerve, the thyro-hyoid membrane, bursa, and the thyroid cartilage lie beneath it.

NERVE SUPPLY.—From the hypo-glossal nerve.

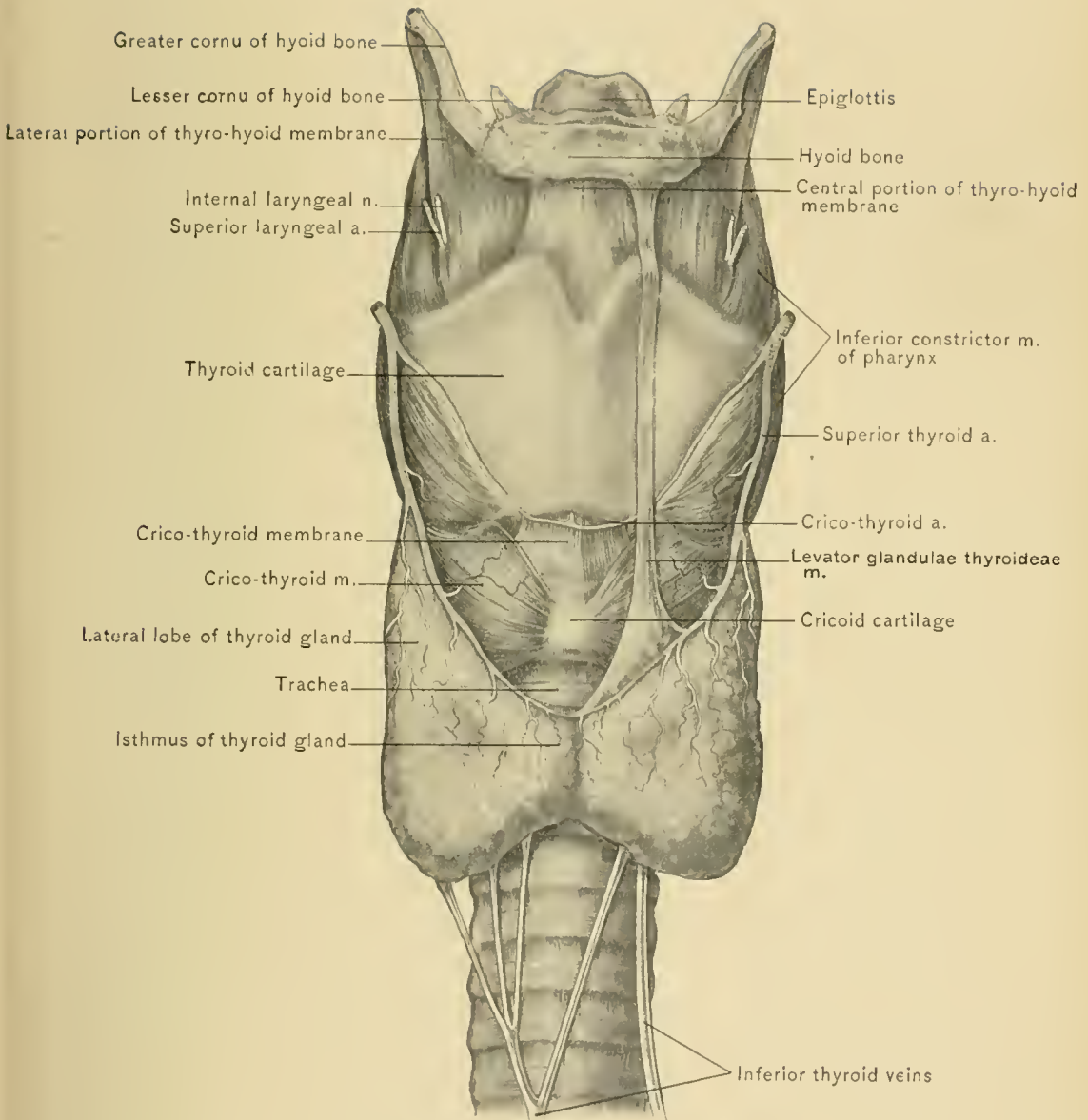
BLOOD SUPPLY.—From the hyoid, the sterno-mastoid, and the crico-thyroid branches of the superior thyroid artery, and the hyoid branch of the lingual artery.

ACTION.—It raises the thyroid cartilage toward the hyoid bone preparatory to swallowing, and in conjunction with the sterno-thyroid muscle it depresses the hyoid bone and larynx.

DISSECTION.—Divide the sterno-hyoid and sterno-thyroid muscles at their

middle, and reflect them upward and downward. This exposes, from above downward, the thyro-hyoid membrane, pierced upon each side by the internal branch of the superior laryngeal nerve and the superior laryngeal artery; the thyroid cartilage; the crico-thyroid membrane, upon which are the crico-thyroid arteries; the cricoid cartilage, partly concealed by the crico-thyroid muscles; the first, and at times the second, ring of the trachea; the thyroid gland, its middle portion, or isthmus connecting the two lateral lobes; the trachea, covered by a plexus of veins formed by the anastomoses of the inferior thyroid veins; the middle thyroid artery, when present, and the pretracheal fascia.

The **Thyroid Gland or Body**, a ductless and very vascular structure, is situated on the front and sides of the upper part of the trachea, and the sides of the lower part of the larynx. It consists of two lateral lobes and a middle lobe, or isthmus, and weighs from one to two ounces. Each lateral lobe is about two inches in length, one and one-fourth inches in breadth, and three-fourths of an inch in thickness. Each lateral lobe is pyriform or cone-shaped, the apex directed upward; it extends from the fifth or sixth ring of the trachea to the middle of the side of the thyroid cartilage. It is convex anteriorly, and is situated between the trachea and the sheath of the common carotid artery, and is covered anteriorly by the sterno-hyoid, the sterno-thyroid, and the anterior belly of the omo-hyoid muscle. Its deep surface is concave, and in contact with the trachea, larynx, pharynx, esophagus, inferior thyroid artery, and recurrent laryngeal nerve. From its upper part, and most commonly from the left lobe, a conic piece, called the *pyramid*, at times ascends toward the hyoid bone, to which it is attached by a fibrous band in front of the thyro-hyoid membrane; this part is at times attached to the hyoid bone by a slip of muscle, the *levator glandule thyroideæ of Soemmering*. The middle lobe, or isthmus, is about one-half of an inch in depth, and rests upon the second and third rings of the trachea. The isthmus varies much in its dimensions, and is sometimes absent. There is a space between the upper border of the middle lobe, or isthmus, and the cricoid cartilage, where the trachea is not covered by the gland; this portion of the trachea is opened in the high operation of tracheotomy. To perform this operation when the space is covered by the middle lobe, it is necessary either to displace the lobe downward or pass two ligatures around it and divide it between them. In some instances, however, the width of the middle lobe, or isthmus, is so great that it covers the trachea almost to the sternum. The low operation of tracheotomy is performed below the isthmus of the gland. That this operation is the more difficult of the two will be seen at a glance in the dissected neck; this is due to the increasing depth of the trachea as it approaches the sternum, and the presence of the thyroid plexus of veins in front of this part of the trachea. An abnormally high position of the large vessels at the root of the neck



THYROID BODY.

would add to the difficulty and danger of the low operation. The thyroid gland is closely attached by areolar tissue to the sides of the trachea and the cricoid and thyroid cartilages. During deglutition it rises and falls with the larynx—a fact of the utmost value in the differential diagnosis between cervical tumors and enlargement of this gland. It varies in size in different individuals and at different periods of life, being relatively larger in children and in females. It often enlarges during menstruation, owing to increased distention of the blood vessels. The right lobe is larger than the left. In old age the gland decreases in size, becomes firmer, and at times contains calcareous substances. When enlarged, it may displace and compress the trachea, especially if the enlargement take place rapidly, the body of the gland being held down by the sterno-thyroid and omohyoid muscles; or it may displace the great vessels of the neck laterally, so that the common carotid artery may be felt pulsating at the outer border of the sternomastoid muscle. Venous engorgement may also ensue, and the recurrent laryngeal nerve may suffer from the pressure of an enlarged thyroid gland. Bonnett has practised subcutaneous section of the muscles in some cases of dyspnea caused by a rapidly growing bronchocele (enlarged thyroid gland). Sir Duncan Gibb, on the other hand, because of the fact that the isthmus, or middle lobe, binds together the enlarging lateral lobes of a bronchocele, proposed to divide the isthmus in cases where dyspnea resulted. He performed this operation several times, great relief to the patient ensuing. As the lateral borders of the thyroid gland are in contact with the sheath of the common carotid artery, it follows that the gland, when enlarged, may readily receive transmitted pulsations from that vessel. An error is occasionally made by mistaking a pulsating goiter for aneurysm of the common carotid artery.

The median lobe of the thyroid gland is developed as a downgrowth of the epithelium from the posterior part of the tongue; the site from which this starts is indicated in the adult by the foramen cæcum of the tongue. The canal thus formed is known as the *thyro-glossal duct*, or *canal of His*. Its walls normally disappear, but remains of them are frequently found in the pyramidal process of the thyroid gland. Accessory thyroid glands, occurring near the median line of the neck, in the vicinity of the hyoid bone, and elsewhere in the neck, are regarded as being formed by division of the pyramidal process. Furthermore, certain cystic tumors at the base of the tongue and in the median line of the neck, as well as the rare cases of median cervical fistula, result from incomplete obliteration of the thyro-glossal duct.

The deep surface of the thyroid gland being in relation with the lower part of the pharynx and the upper part of the esophagus, the difficulty in swallowing often observed in bronchocele is explained by the direct pressure, and the interference

with the movements of the larynx. Enlargement of the left lobe of the gland is more likely to occasion difficulty in swallowing than a similar condition on the right side, owing to the inclination of the esophagus toward the left. In a case mentioned by Allan Burns, the isthmus was located between the trachea and the esophagus. It is very evident that enlargement of this portion of the gland holding such abnormal relation would occasion great difficulty in swallowing. The author has seen a case of goiter in which the esophagus was so nearly occluded that the patient, an old woman, was no longer able to swallow liquids. Atrophy of the thyroid gland, or its destruction by disease, is apt to be followed by the condition known as myxedema. Absence of the thyroid gland in children causes cretinism and idiocy.

The **arteries of the thyroid gland**—two on each side—are the superior and inferior thyroid. The superior thyroid, a branch of the external carotid artery, ramifies chiefly upon the anterior aspect of the gland, while the inferior thyroid, a branch of the thyroid axis, enters the under and inner surface of the lateral lobe of the gland. A very free anastomosis is established between these vessels, which form a complete network around the acini in the substance of the gland. Occasionally there is a middle thyroid artery (*thyroideæ ima*), a branch of the innominate artery or arch of the aorta, which ascends in front of the trachea and enters the isthmus of the gland.

The thyroid gland is surrounded by a thin, dense, fibrous capsule, which is derived from the pretracheal fascia and sends processes into the interior which separate the substance into lobules of varying form and size. The vesicles composing these lobules are lined by a single layer of columnar epithelium and contain a colloid substance. Increase of this colloid substance constitutes a form of goiter.

The **nerves of the thyroid gland** are derived from the middle and lower cervical sympathetic ganglia, and accompany the inferior thyroid artery.

The **thyroid veins**, three on each side, are the superior, the middle, and the inferior thyroid. The superior and middle thyroid veins cross in front of the common carotid artery, emptying into the internal jugular vein. The inferior thyroid veins descend on the trachea, form a plexus in front of the pretracheal fascia, and behind the sterno-thyroid muscles, and empty into the left innominate vein. The numerous and large lymphatics pass to the lymph trunks at the root of the neck. In some cases these lymphatics have been found to contain colloid substance, giving rise to the supposition that they act as ducts of the gland.

Thyroidectomy.—In the operation of removal of half of the thyroid gland in either bilateral or unilateral goiter (*bronchocele*) the incision may be made parallel with the anterior border of the sterno-mastoid muscle, or a transverse curved incision, concave upward, may be carried over the most prominent portion

of the tumor. The gland being exposed, the superior and inferior thyroid arteries should be carefully freed, and then secured and divided between ligatures. In exposing the inferior thyroid artery preparatory to severing it, and in freeing the lower end of the lateral lobe of the gland behind, care must be exercised to avoid injuring the recurrent laryngeal nerve. After attempts to cure a unilateral goiter by the injection of tincture of iodine or by electro-puncture have failed, the inflammation consequent upon either form of treatment may result in binding the gland tightly to the carotid sheath, or perhaps to the wall of the internal jugular vein. Under these circumstances dissecting it loose, in attempted removal of the goiter, will be attended by risk of tearing the vein. Where much periglandular inflammation has occurred, the recurrent laryngeal nerve may be involved in the deposit of exudate, this condition giving rise to aphonia, which is likely to be permanent whether the goiter be removed or not.

The **recurrent laryngeal nerve**, which has been described with the pneumogastric nerve, should now be observed passing upward in the groove between the trachea and esophagus and behind and internal to the lateral lobe of the thyroid gland to enter the larynx.

The Subclavian Artery.—The origin, course, and relations of the subclavian arteries differ upon the two sides. The right subclavian is a branch of the innominate artery, and the left of the arch of the aorta. The anterior scalene muscle passes in front of the subclavian artery and divides it into three portions. The *first portion* is situated between its origin and the inner border of the anterior scalene muscle, the *second portion* behind the muscle, and the *third portion* between the outer border of the muscle and the lower border of the first rib. The first portion of the artery is the one which differs in course and relations on the two sides; it will, therefore, be described separately.

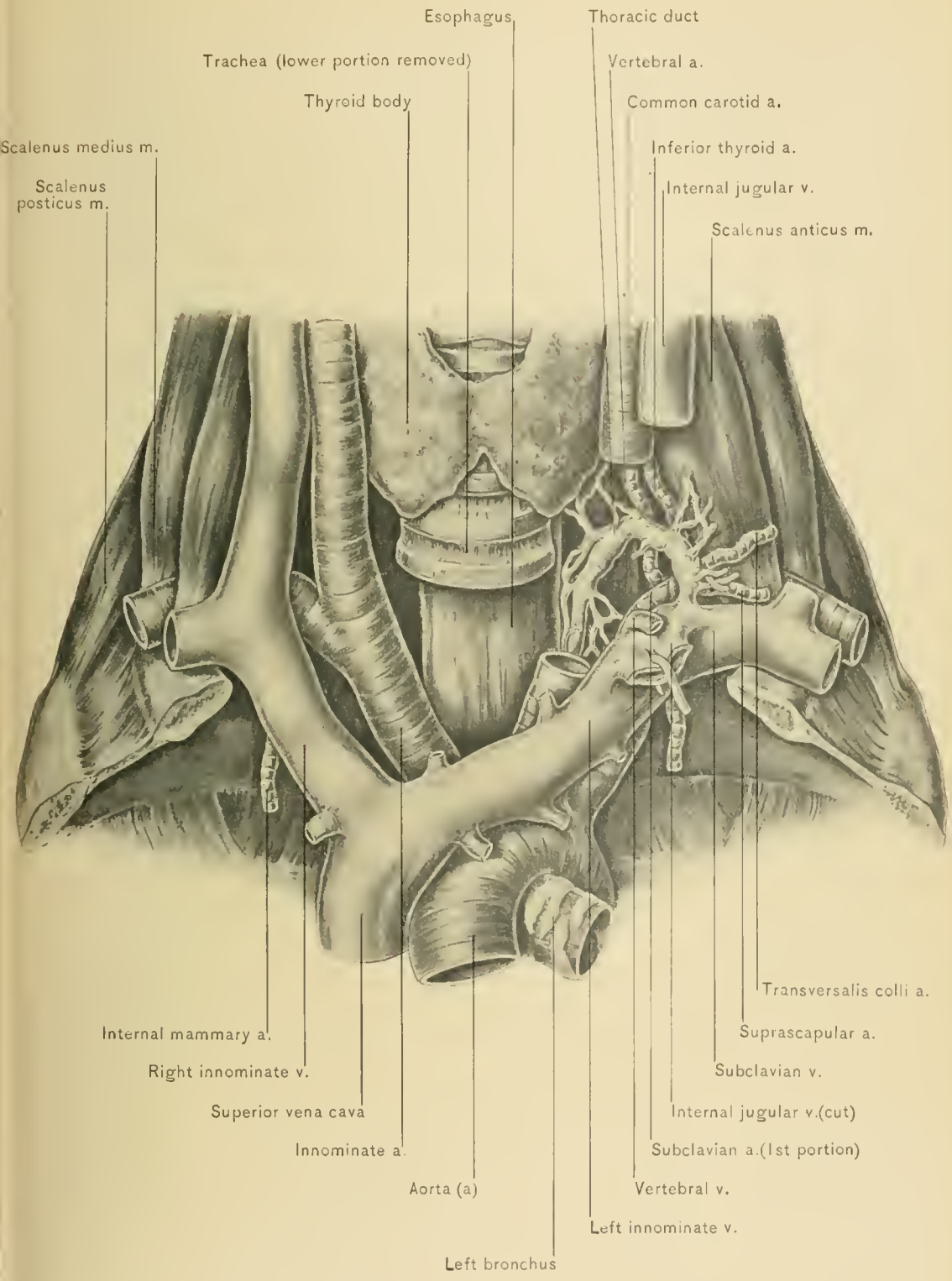
The **right subclavian artery** is the shorter of the two. It arises as one of the two terminal divisions of the innominate artery behind the upper border of the right sterno-clavicular articulation. The first portion of the artery lies deep in the neck, and ascends upward and outward to the inner border of the anterior scalene muscle. It is covered in front by the skin, the superficial fascia, the platysma myoides muscle, the superficial layer of the deep fascia, the sternal end of the clavicle, the sterno-mastoid muscle, the anterior jugular vein, the sterno-hyoid and sterno-thyroid muscles, and the posterior process of the deep fascia (prevertebral fascia) continued forward from in front of the scaleni muscles. It is crossed by the internal jugular and vertebral veins, the pneumogastric nerve, the superior cardiac nerves and a loop of the sympathetic nerve (*ansa Vieussenii*), and the phrenic nerve. Below the artery are the pleura, the recurrent laryngeal nerve,

and the subclavian vein ; behind it are the recurrent laryngeal nerve, the cord of the sympathetic nerve with its middle and inferior cardiac branches, the longus colli muscle, the transverse process of the seventh cervical or first thoracic vertebra, from which it is separated by a small quantity of cellular tissue and fat, and the apex of the lung, covered with pleura.

The **left subclavian**, the longer of the two arteries, arises from the transverse portion of the arch of the aorta opposite the third thoracic vertebra. Its first portion ascends almost vertically to the inner margin of the first rib and the inner border of the insertion of the anterior scalene muscle. Only the relations of the cervical part of this portion of the artery will be described here. The cervical part of the first portion is covered by the skin, the superficial fascia, the platysma myoides muscle, the superficial layer of the deep fascia, the sterno-mastoid muscle, the anterior jugular vein, the sterno-hyoid and sterno-thyroid muscles, the posterior process of the deep fascia, continued forward from in front of the scaleni muscles, the sternal end of the clavicle, the left internal jugular vein, the vertebral and subclavian veins, the apex of the left lung and its pleura, the phrenic nerve, and the cardiac branches of the sympathetic nerve, which lie parallel with the artery, the left common carotid artery, and the thoracic duct. On its outer side are the apex of the lung and pleura ; on its inner side are the trachea, the recurrent laryngeal nerve, the esophagus, and the thoracic duct ; behind it are the pleura and the apex of the left lung, while behind and internal to it are the thoracic duct, the esophagus, the inferior cervical ganglion of the sympathetic nerve, the sympathetic cord, the longus colli muscle, and the spinal column.

Differences Between the Right and Left Subclavian Arteries in Their First Portion.—The first portion of the left subclavian artery differs from the first portion of the right in the following respects: The left subclavian arises directly from the arch of the aorta, while the right arises from the innominate artery ; it lies deeper, is longer and more vertical ; it is in relation with the esophagus and the thoracic duct, while the right is not ; it is crossed by the left innominate or brachio-cephalic vein, the phrenic and pneumogastric nerves, and the cardiac branches of the sympathetic nerve running almost parallel with it ; on the right side the phrenic and pneumogastric nerves and some of the cardiac branches of the sympathetic nerve pass in front of the right subclavian artery, at nearly a right angle. The left subclavian artery is not in so close a relation with the recurrent laryngeal nerve as is the right subclavian, the nerve winding around below the latter. In the following description of the course of the thoracic duct it will be seen to be in relation with the first portion of the left subclavian artery at two points ; it holds, of course, no relation to the right subclavian artery.

The **thoracic duct** passes upward and out of the chest to the left of the



Scalenus medius m.
Scalenus posticus m.

Trachea (lower portion removed)
Thyroid body

Esophagus.

Thoracic duct

Vertebral a.
Common carotid a.
Inferior thyroid a.
Internal jugular v.
Scalenus anticus m.

Internal mammary a.
Right innominate v.
Superior vena cava
Innominate a.

Aorta (a)
Left bronchus

Transversalis colli a.
Suprascapular a.
Subclavian v.
Internal jugular v.(cut)
Subclavian a.(1st portion)
Vertebral v.
Left innominate v.

THORACIC DUCT.

esophagus and behind the first portion of the subclavian artery and the apex of the left lung. Behind the left internal jugular vein and common carotid artery, and opposite the seventh cervical vertebra, the duct forms an arch above the subclavian artery and anterior to the vertebral artery and vein, and descends in front of the anterior scalene muscle to empty into the left subclavian vein at its junction with the internal jugular vein.

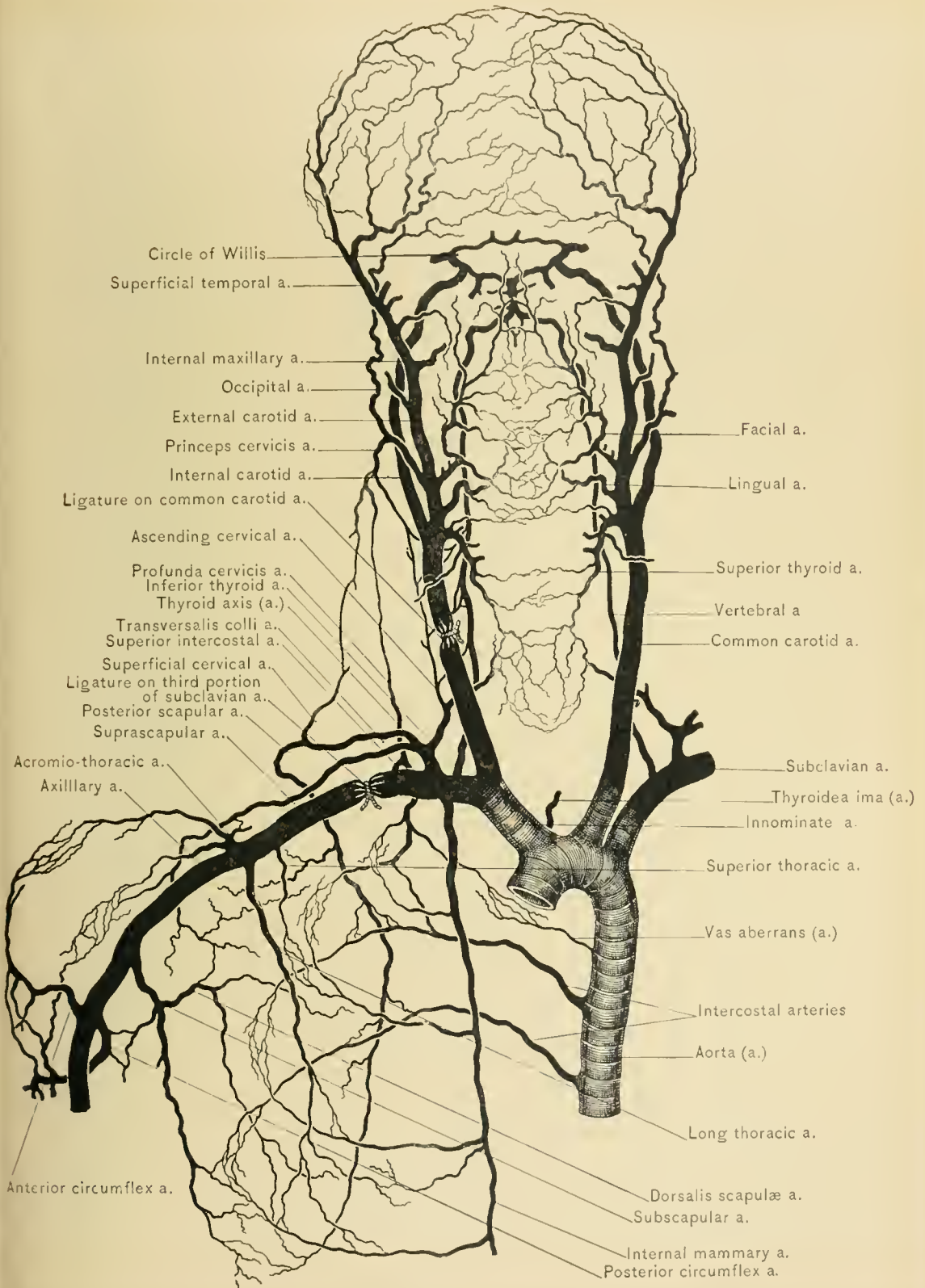
The Second Portion of the Subclavian Artery.—The relations of the subclavian artery in its second and third portions are alike on its two sides. In its second portion the artery lies behind the scalenus anticus and in front of the scalenus medius muscle; at this point it rises highest above the clavicle, usually about three-fourths of an inch. It is covered by the skin, the superficial fascia, the platysma myoides muscle, the superficial layer of the deep fascia, the clavicular origin of the sterno-mastoid muscle, the posterior process of the deep fascia, the phrenic nerve, and the anterior scalene muscle, the latter separating it from the subclavian vein. Above it lies the lower of the three cervical trunks of the axillary or brachial plexus of nerves. Behind it are the middle scalene muscle and the apex of the lung and pleura. Below it lies the pleura, while below and in front of it is the subclavian vein. This portion gives off but one branch, the superior intercostal artery.

The Third Portion of the Subclavian Artery.—In the third part of its course the artery passes downward and outward from the external margin of the anterior scalene muscle to the lower border of the first rib, occupying the subclavian triangle, where it is nearer the surface than in either the first or second portion of its course. It is covered by the skin, the superficial fascia, the platysma myoides muscle, the superficial layer and the posterior of the two processes of the deep fascia, and near its termination by the clavicle and subclavius muscle. Running in front of this portion are the supra-scapular artery and vein, while crossing it are the clavicular branches of the cervical plexus, the nerve to the subclavius muscle, and the external jugular vein. The transversalis colli, supra-scapular, posterior jugular, and jugulo-cephalic veins, which frequently form a plexus in front of the artery, and should be borne in mind in ligating the third portion of the subclavian artery, empty into the external jugular vein. The relation between the supra-scapular artery and the third portion of the subclavian artery at its point of election can be compared, surgically, to the relation held between the middle sterno-mastoid and the common carotid artery at its point of election. The anatomic difference is, however, that the middle sterno-mastoid artery passes across the sheath of the common carotid, and is frequently severed in the ligation of the latter, while the supra-scapular passes in front of, and almost parallel with, the subclavian artery, and can be displaced when the main vessel is ligatured. The subclavian

vein lies below the artery, and on a plane anterior to it. Above and to the outer side of this portion of the artery are the three cervical trunks of the axillary or brachial plexus of nerves and the omo-hyoid muscle. The upper trunk runs so close to and so nearly parallel with the artery that it may be mistaken for it and tied, the surgeon being misled by the pulsation communicated to the nerve. Behind the artery are the middle scalene muscle and the lower cervical trunk of the brachial plexus. Below this portion of the artery is the first rib. The third portion of the subclavian artery, as a rule, gives off no branches, but occasionally gives origin to the posterior scapular artery.

Variations of the subclavian artery.—The right subclavian artery may arise as a separate trunk from the arch of the aorta. It may pass in front of or through the fibers of the anterior scalene muscle, and ascend as high as one and one-half inches above the clavicle. In some cases the subclavian vein passes with the artery behind the anterior scalene muscle.

Ligation of the third portion of the subclavian artery.—The third portion is the point of election for ligation of the subclavian artery; in this portion it is most superficial, is covered by fewer important structures, and, as a rule, gives off no branches; the posterior scapular artery occasionally arises from it. When performing this ligation the patient should be placed in the supine position, with a pillow beneath the upper part of the back, and the shoulder depressed. The incision is made parallel with the upper border of the clavicle, should be three or four inches in length, and commence at the outer border of the clavicular origin of the sterno-mastoid muscle. The vessel is brought nearer the surface by carrying the arm to the side and depressing the shoulder, thus diminishing the depth of the triangle through which the artery passes. The relation of the supra-scapular vessels to the third portion of the subclavian artery is so changed when the arm is well drawn down that it is not endangered in the ligation. The following structures are divided: the skin, the superficial fascia, the platysma myoides muscle, some of the clavicular branches of the cervical plexus of nerves, the superficial layer of the deep fascia, and the posterior of its two processes (prevertebral fascia). The external jugular vein, with the veins emptying into it, which frequently form a plexus above and in front of the subclavian artery between the two layers of the deep fascia (superficial and prevertebral), should be pushed aside; if this is not feasible, they may be tied and severed between ligatures. The posterior belly of the omo-hyoid muscle should next be exposed by dividing the connective tissue at the bottom of the wound; the operator then searches for the upper cervical trunk of the axillary or brachial plexus of nerves and the outer border of the anterior scalene muscle, along which the finger is passed until the tubercle on the first rib is reached, provided the vessel is not felt pulsating before the finger reaches



COLLATERAL CIRCULATION AFTER LIGATION OF SUBCLAVIAN AND COMMON CAROTID ARTERIES.

the rib. If the pulsations of the artery be felt, its sheath should be opened and the aneurysm needle, carrying the ligature, passed from before backward, away from the vein, and then from below upward, care being taken to avoid including the lowest of the three cervical trunks of the axillary or brachial plexus, which runs behind and nearly parallel with the third portion of the subclavian artery. In very muscular subjects, in addition to the above structures, it may be necessary to divide a portion of the clavicular head of the sterno-mastoid and the anterior border of the trapezius muscle.

After this ligation the *collateral circulation* is carried on by the anastomosis of the supra-scapular and posterior scapular arteries with the dorsalis scapulae and the terminal portion of the subscapular artery, the supra-scapular above, with the acromio-thoracic and posterior circumflex arteries below, and by the anastomosis of the superior thoracic, thoracic branches of the acromio-thoracic, the long thoracic, and the subscapular artery, with the aortic intercostal arteries, the internal mammary, and the superior intercostal artery.


Ligation of the second portion of the subclavian artery is very rarely performed. The vessel is exposed by an incision along the clavicle, as in the foregoing ligation; in addition, the clavicular head of the sterno-mastoid muscle is divided, the connective tissue is cleared away, and any veins which may be found overlying the prevertebral fascia covering the anterior scalene muscle are tied. The prevertebral fascia is divided, the phrenic nerve carried inward, and the anterior scalene muscle severed near its attachment to the first rib, care being taken not to injure the anterior jugular, external jugular, internal jugular, and subclavian veins or the pleura. The needle should be carried from before backward and below upward to avoid injuring the vein, as in ligating the third portion of the artery.

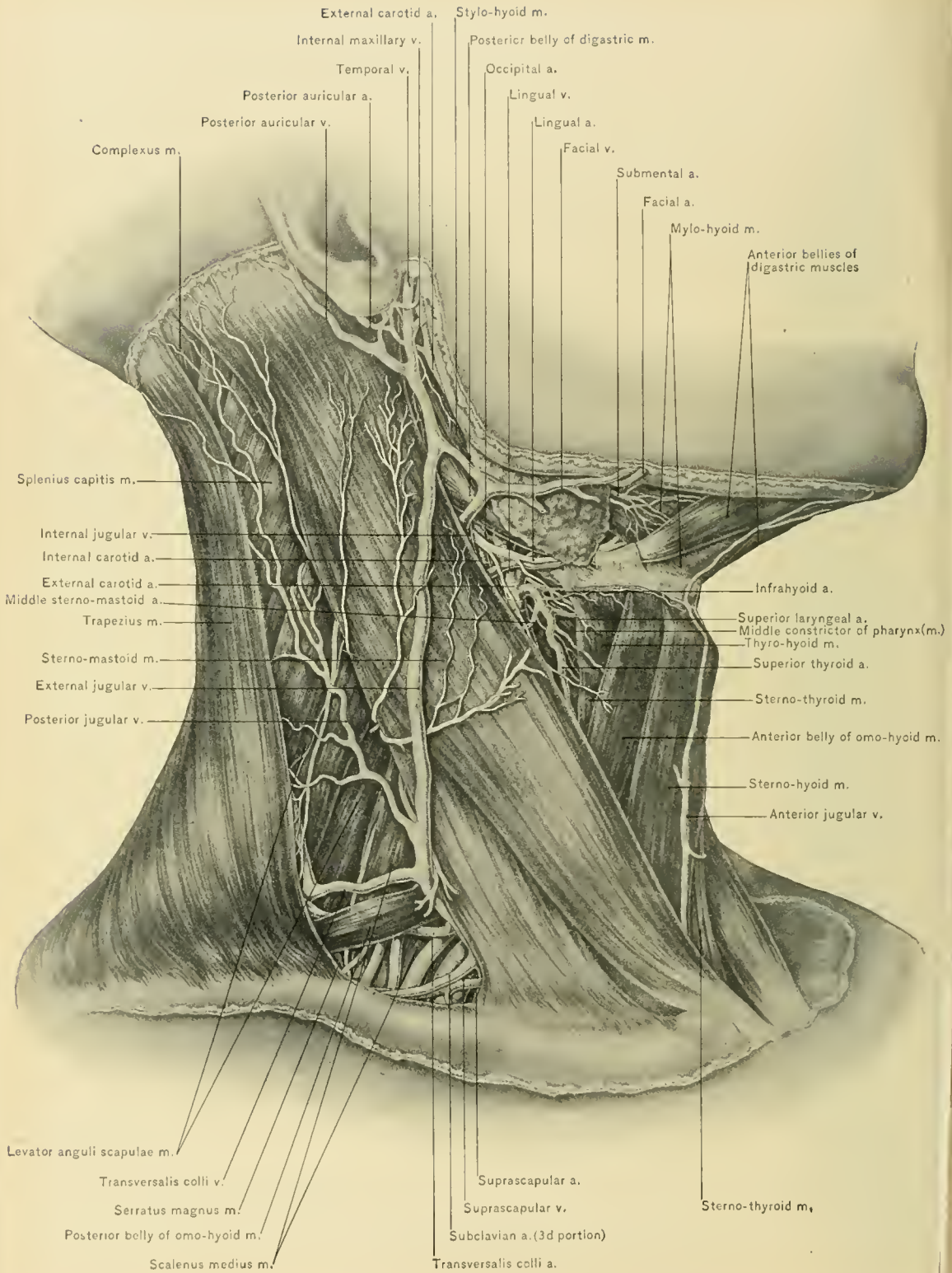
Ligation of the first portion of the subclavian artery is the most difficult of the three ligations, especially of the left subclavian artery. This portion of the vessel lies deeper than the other two portions, is surrounded more intimately by important structures, and gives off three branches. (See description of the relations of the first portion.) To expose this portion of the vessel on the right side make a triangular flap, like that made in tying the innominate artery, by carrying an incision along the inner border of the sterno-mastoid muscle and one along the upper border of the clavicle. The skin, superficial fascia, platysma myoides muscle, superficial layer of the deep fascia, and the anterior jugular vein are divided. The sternal head of the sterno-mastoid muscle, and, if necessary, the clavicular head, as well as the sterno-hyoid and sterno-thyroid muscles at their origin, are divided. The inferior thyroid veins, now seen at the bottom of the wound, should be held aside or divided between ligatures, and the root of the com-

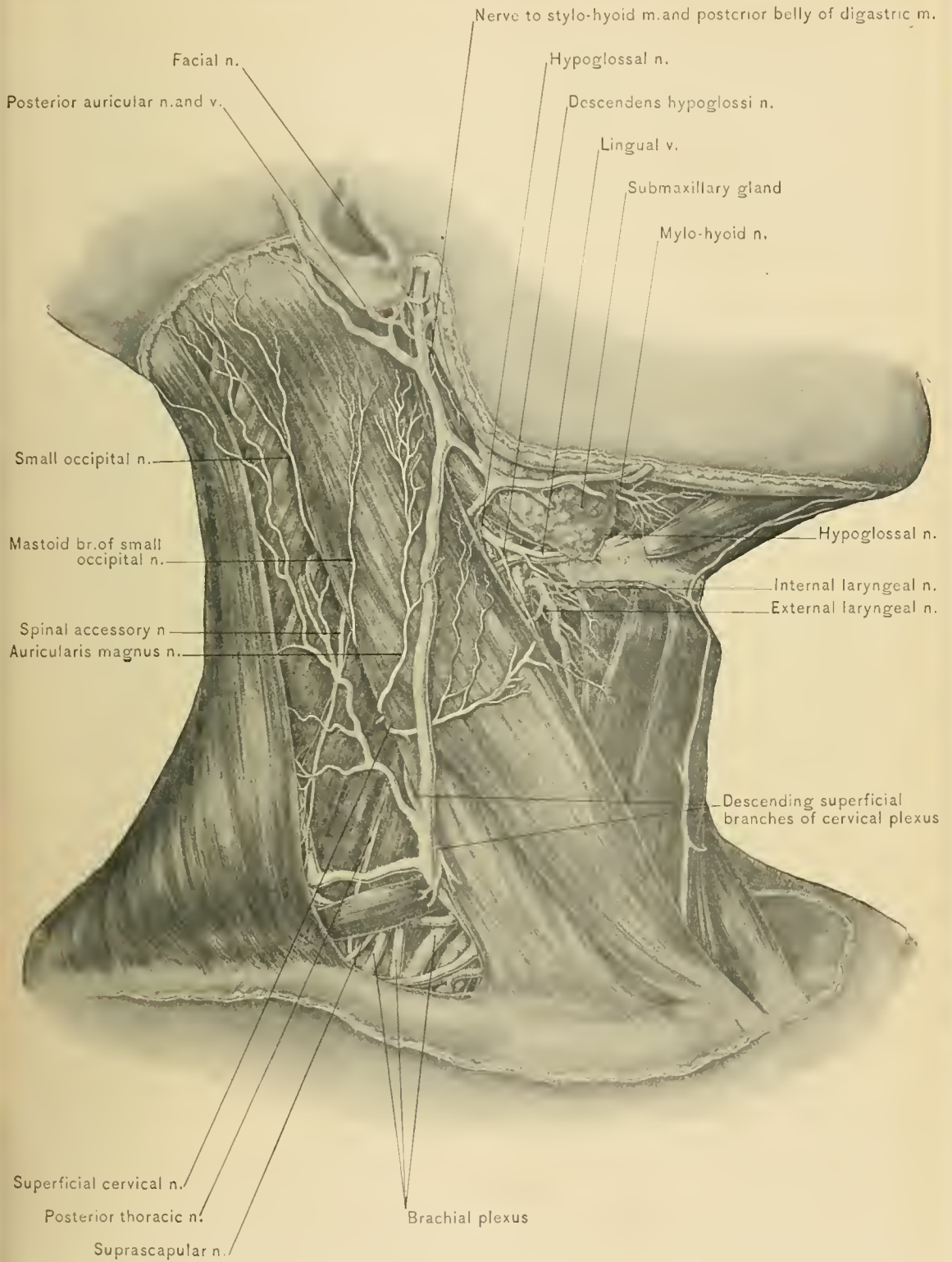
mon carotid artery exposed; this artery is then followed downward to the innominate, thus reaching the first part of the subclavian artery. To expose the first portion of the left subclavian artery a flap similar to that described in exposing the same portion of the right should be made. The sterno-mastoid, the sterno-hyoid, and the sterno-thyroid muscle are divided, and the apex of the left lung, with the structures running parallel to and in front of the artery (see description of the relations of the first portion of the left subclavian artery), should be drawn forward, the vertebral and internal jugular veins avoided, and the aneurysm needle passed from below upward. In carrying the needle behind the artery, unless great care be exercised, the thoracic duct and pleura may be wounded.

BRANCHES OF THE SUBCLAVIAN ARTERY.—These consist of the vertebral, the thyroid axis, the internal mammary, and the superior intercostal artery. The first three branches arise from the first portion of the artery; the fourth branch arises from the second portion. In the majority of cases the third portion gives off no branches, but the posterior scapular artery frequently arises from it.

The **vertebral artery**, the first and largest branch, arises from the upper and back part of the first portion of the subclavian artery. It ascends in the interval between the scalenus anticus and longus colli muscles, entering the foramen in the transverse process of the sixth cervical vertebra, just below the level of the lower border of the cricoid cartilage. It continues upward through the foramina in the transverse processes of the remaining cervical vertebræ to the skull. Having passed through the foramen in the transverse process of the axis, it makes an S-shaped curve upward and outward, which prevents its being stretched when the head is rotated. It then passes through the foramen in the transverse process of the atlas, curving backward behind the articular process in a deep groove on the upper surface of the posterior arch of the atlas. Here it lies in the suboccipital triangle, and pierces the posterior occipito-atloid ligament and dura mater of the spinal cord to traverse the foramen magnum and become intra-cranial. It unites with the vertebral artery of the opposite side near the lower border of the pons Varolii to form the basilar artery. The first or *cervical portion* of the vertebral artery lies behind the internal jugular vein, the inferior thyroid artery, and the vertebral vein, while near the transverse process of the sixth cervical vertebra it lies between the scalenus anticus and longus colli muscles; the thoracic duct lies in front of the left vertebral artery. The second or *vertebral portion* lies within the canal formed by the foramina of the transverse processes of the upper six cervical vertebræ, and is accompanied by the vertebral veins and the vertebral plexus of nerves derived from the inferior cervical sympathetic ganglion; it lies between the vertebral vein in front, and the cervical nerves, which pass out of the spinal canal through the intervertebral foramina, behind. It is in contact with the







MUSCLES AND NERVES OF NECK.



intertransverse muscles. Its third or *occipital portion* lies in the groove on the posterior arch of the atlas, where it rests upon the suboccipital nerve, and is within the suboccipital triangle formed by the rectus capitis posterior major muscle upon the inner side, the obliquus capitis superior above and the obliquus capitis inferior muscle below; it is covered by the complexus muscle. The relation which the fourth or *intra-cranial portion* holds within the cranial cavity is described under the Dissection of the Brain.

THE BRANCHES OF THE VERTEBRAL ARTERY.—These consist of two sets: those given off in the neck and those given off within the cranial cavity. The branches given off in the neck are the lateral spinal and the muscular.

The *lateral spinal arteries* pass through the intervertebral foramina, and each divides into two branches for the supply of the spinal cord, its membranes, and the bodies of the vertebrae.

The *muscular branches* are given off immediately before the vertebral artery pierces the occipito-atloid ligament; they supply the deep muscles of the neck, and anastomose with the ascending cervical, occipital, and deep cervical arteries.

The *vertebral vein* is formed in the suboccipital triangle from a plexus of veins composed of numerous small branches from the deep muscles. It enters the foramen in the transverse process of the atlas, and forms a plexus around the vertebral artery. At the lower part of the neck the plexus unites to form the vertebral vein, which emerges at the foramen in the transverse process of the sixth cervical vertebra, whence it passes downward in front of the vertebral artery and behind the internal jugular vein and terminates in the innominate vein near its origin, passing in front of the first portion of the subclavian artery. Its orifice is guarded by a pair of valves. It receives as tributaries the veins from the neighboring muscles; the dorsi spinalis veins, the veins from the spinal canal (the meningo-rachidian veins), the deep cervical, and, at times, the first pair of intercostal veins. In cases where the posterior condyloid foramen is present, the vertebral vein communicates with the lateral sinus by a branch which passes through the foramen.

Ligation of the vertebral artery is performed through an incision carried along the lower part of the posterior border of the sterno-mastoid muscle, which corresponds to the outer border of the anterior scalene muscle. The skin, superficial fascia, platysma myoides muscle, and the superficial layer of the deep fascia are divided, the external jugular vein being displaced outward. The sterno-mastoid muscle is drawn toward the median line, and the connective tissue divided or pushed aside with the handle of the scalpel, thus exposing the pre-vertebral fascia or posterior process of the deep cervical fascia which covers the anterior scalene muscle and the phrenic nerve. The posterior process of the deep

cervical fascia (prevertebral fascia) is divided on a line with the inner border of the anterior scalene muscle: the vertebral artery with its companion vein, which partly covers it, will be found occupying the interval between the anterior scalene and the longus colli muscle. The inferior thyroid artery, which lies in front of the vertebral artery, must not be mistaken for it. The dissection necessary to expose the vessel must be done cautiously, otherwise there is danger of wounding the phrenic nerve and the internal jugular vein, or of opening the pleural sac. The inexperienced operator may be led to believe he has opened the pleural sac, by the crackling sound occasioned by air infiltrating the connective tissue occupying this position. The vertebral vein must be slightly displaced before passing the aneurysm needle, which should be carried from without inward to avoid injuring the vertebral vein, the internal jugular vein being protected with the tip of the finger. On the left side the thoracic duct should be avoided. Contraction of the pupil of the eye of the corresponding side, caused by the disturbance of the sympathetic filaments in relation with the artery, is evidence that the ligature has included the vertebral artery. The author has found this a reliable sign. The carotid tubercle, which is at the upper extremity of the groove between the scalenus anticus and longus colli muscles, is the deep guide to the artery.

The **thyroid axis**, a short thick trunk, arises from the subclavian artery near the inner border of the anterior scalene muscle. It lies beneath the internal jugular vein and prevertebral fascia and between the phrenic nerve and vertebral vein, and divides into three BRANCHES: the inferior thyroid, supra-scapular, and transversalis colli arteries.

The **inferior thyroid artery**, the largest branch of the thyroid axis, passes obliquely upward and inward behind the internal jugular vein, and in front of the vertebral artery and inward behind the sheath of the common carotid artery and the sympathetic nerve to the deep surface of the lateral lobe of the thyroid gland, which gland it supplies and within which it anastomoses with the superior thyroid artery and the inferior thyroid artery of the opposite side. It turns inward just below the carotid tubercle (anterior tubercle of the sixth cervical transverse process), and crosses behind the sheath of the vessels at about the level of the tendon of the omo-hyoid muscle. The middle cervical or thyroid ganglion of the sympathetic nerve rests upon the inferior thyroid artery. It gives off the following BRANCHES: ascending cervical, laryngeal, tracheal, esophageal, and muscular.

The *ascending cervical artery* arises from the inferior thyroid behind the internal jugular vein, and runs up the neck close to the tips of the transverse processes of the cervical vertebrae in the groove between the anterior scalene and the rectus capitis anticus major muscle, and to the inner side of the phrenic nerve.

Its branches to the muscles of the neck communicate with the muscular branches of the vertebral artery, while others enter the intervertebral foramina to reach the bodies of the vertebrae and the spinal cord and its meninges. It anastomoses with the vertebral, ascending pharyngeal, and branches of the occipital artery. It sends a branch to the phrenic nerve.

The *inferior laryngeal artery* accompanies the recurrent laryngeal nerve, supplies the muscles and mucous membrane of the larynx, and anastomoses with the superior laryngeal artery.

The *tracheal branches* ramify upon the trachea, the lower ones anastomosing with the bronchial arteries.

The *esophageal branches* supply the esophagus. One of these is often large, runs parallel with the continuation of the inferior thyroid artery, and may be mistaken for it.

The *muscular branches* supply the muscles of the lower anterior part of the neck.

The inferior thyroid artery is not accompanied by the corresponding **vein**, which lies at the side of the median line of the neck. (See Dissection of Front of Neck.)

Ligation of the inferior thyroid artery.—This is performed either where the artery lies between the internal jugular vein and the inner border of the anterior scalene muscle, or to the inner side of the carotid sheath as it passes to the deep surface of the lateral lobe of the thyroid gland just below the level of the cricoid cartilage. To secure the inferior thyroid artery along the inner border of the anterior scalene muscle make an incision similar to that made in ligation of the vertebral artery, carrying the aneurysm needle from within outward away from the vertebral vein. To secure the inferior thyroid artery on the inner side of the carotid sheath make an incision along the anterior border of the sterno-mastoid muscle.

The **supra-scapular artery** (*transversalis humeri*), smaller than the *transversalis colli* artery, coarses outward across the lower part of the neck. It first passes beneath the sterno-mastoid muscle and over the phrenic nerve and lower part of the anterior scalene muscle; then it runs behind the clavicle and subclavius muscle, crosses the third part of the subclavian artery, and passes beneath the posterior belly of the omo-hyoid and the anterior border of the trapezius muscle, to the superior border of the scapula, where it passes over the transverse ligament of that bone to reach the supra-spinous fossa. The supra-scapular nerve, which joins the artery just before it dips under the omo-hyoid muscle, passes beneath the transverse ligament, and through the supra-scapular notch. In the supra-spinous fossa the artery lies close to the bone, and supplies the supra-spinatus muscle; at

the neck of the scapula it turns around the base of the spine to the infra-spinous fossa, where it anastomoses with the dorsalis scapulae, a branch of the subscapular artery, and with the posterior scapular artery. The chief BRANCHES of the supra-scapular artery are the inferior sterno-mastoid, supra-acromial, and articular. Other branches supply the subclavius muscle, the skin over the manubrium sterni (supra-sternal), and the clavicle.

The *inferior sterno-mastoid artery* supplies the clavicular portion of the sterno-mastoid muscle, behind which it is given off.

The *supra-acromial branch* pierces the trapezius muscle, passes over the acromion process, and anastomoses with the acromio-thoracic and posterior circum-flex arteries.

The *articular branches* supply the acromio-clavicular joint and the shoulder-joint.

The **transversalis colli artery**, or transverse cervical, usually larger than the supra-scapular artery, passes outward across the side of the neck, higher than the supra-scapular, over the scalene muscles and phrenic nerve, and over or between the cervical trunks of the axillary or brachial plexus to the anterior border of the trapezius, beneath which, and at the outer border of the levator anguli scapulae muscle, it divides into its two terminal branches, the superficial cervical and the posterior scapular.

The *superficial cervical artery* passes upward beneath the anterior border of the trapezius and over the levator anguli scapulae and splenius muscles. It supplies these muscles and the posterior chain of lymphatic glands in the neck, and anastomoses with the superficial branch of the arteria princeps cervicis, which descends from the occipital artery between the splenius and complexus muscles.

The *posterior scapular artery*, the larger of the two terminal branches, passes beneath the trapezius and the levator anguli scapulae muscle to the superior angle of the scapula, whence it descends along the vertebral border or base of the scapula to the inferior angle. It runs between the insertions of the serratus magnus muscle in front and the rhomboidei and levator anguli scapulae muscles behind, which, with the latissimus dorsi and trapezius, it supplies. It anastomoses with the supra-scapular and subscapular arteries, and with the posterior branches of the intercostal arteries. It frequently arises from the third portion of the sub-clavian artery, and in such cases the superficial cervical artery usually arises from the thyroid axis.

The **veins** corresponding to the branches of the thyroid axis empty into the external jugular vein, except the inferior thyroid vein, which goes to the innominate vein.

The **Internal Mammary Artery** arises from the lower margin of the first

part of the subclavian artery opposite the thyroid axis. It passes downward beneath the clavicle, the subclavius muscle, and the subclavian vein, and enters the chest between the cartilage of the first rib and the pleura. At its origin it is crossed from without inward by the phrenic nerve. Its further course is described under the Dissection of the Thorax. The accompanying **veins** of the internal mammary artery, two in number, unite to form a common trunk which empties into the innominate vein.

The **Superior Intercostal Artery** arises from the upper margin of the second portion of the subclavian artery, and occasionally arises from the first portion upon the left side. It arches backward and a little upward over the pleura, and then descends behind it, giving off the profunda cervicis artery; it then passes in front of the neck of the first, and sometimes of the second, rib, giving off the arteries of the first, and at times of the second, intercostal space, and a posterior branch, which is distributed to the muscles of the back and to the spinal cord and its membranes. In front of the neck of the first rib it lies between the first thoracic sympathetic ganglion on the inner side, and the anterior branch of the first thoracic nerve on the outer side. Its **BRANCHES** are the deep cervical, the first intercostal, and the arteria aberrans.

The **deep cervical artery** (profunda cervicis) passes backward between the seventh and eighth cervical nerves, and then between the transverse process of the last cervical vertebra and the neck of the first rib, internal to the middle and posterior scalene muscles; thence it passes up the back of the neck between the complexus and semi-spinalis colli muscles, which it supplies, and anastomoses with the arteria princeps cervicis and branches of the ascending cervical and vertebral arteries.

The **deep cervical vein** begins in the suboccipital triangle, usually receives the occipital vein, accompanies the arteria princeps cervicis, and then the profunda cervicis artery, and empties into the vertebral or innominate vein.

The **first intercostal artery** has a distribution in the first intercostal space corresponding with that of the arteries in the other intercostal spaces.

The **arteria aberrans**, inconstant, arises from the inner side of the right superior intercostal artery, and passes downward behind the esophagus, supplying adjacent structures and sometimes joining a small ascending branch of the aorta, opposite the third thoracic vertebra.

The *anastomosis* between the superior intercostal and the occipital artery performs an important part in the development of the collateral circulation after ligation of the common carotid artery.

The **veins** which correspond to the superior intercostal arteries are the right

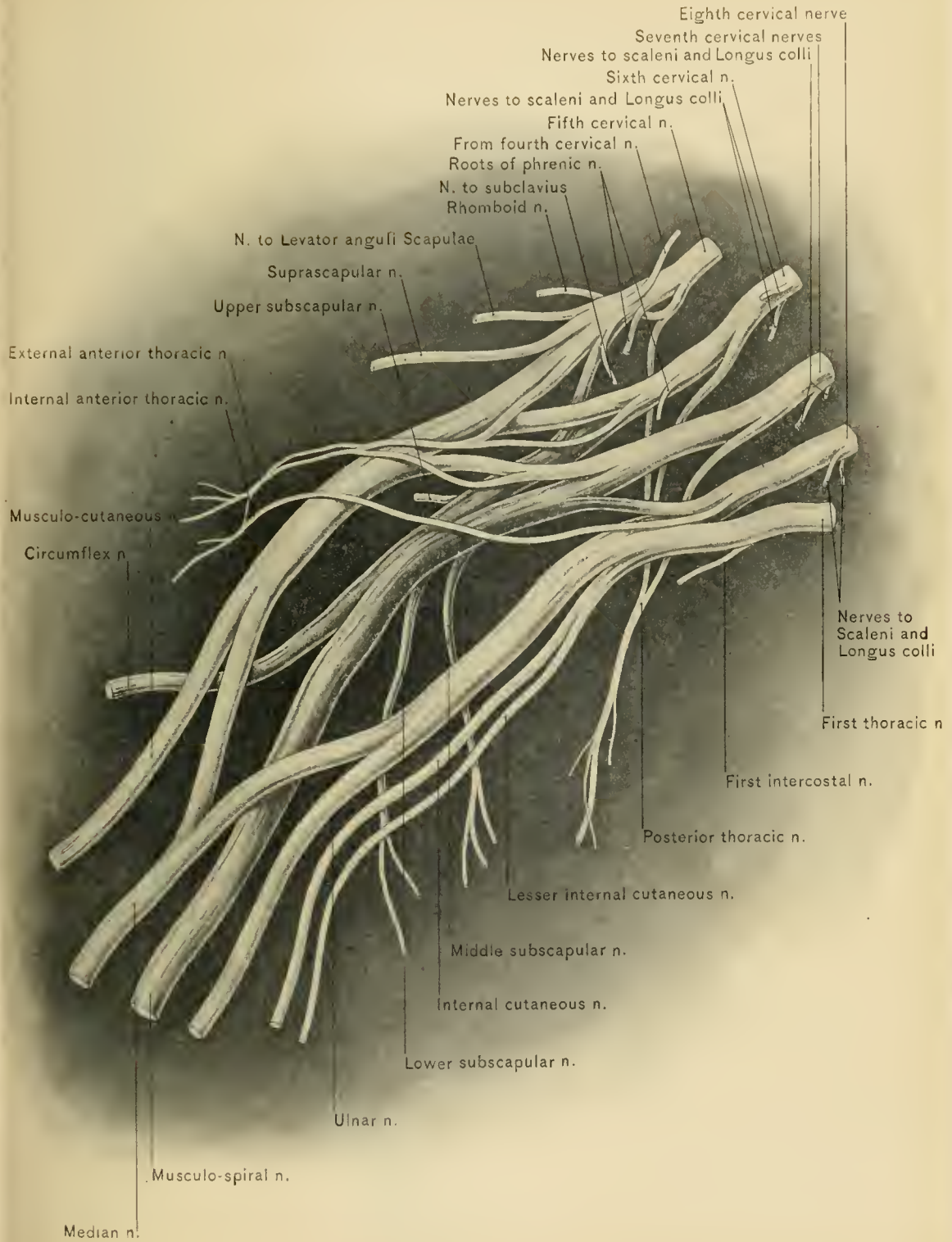
and left superior intercostal veins. The left superior intercostal vein empties into the left innominate vein, and the right into the vena azygos major or the right innominate vein.

The Axillary or Brachial Plexus.—The axillary or brachial plexus of nerves will be seen at the side of the neck, emerging from between the anterior and middle scalene muscles; it is formed by the union of the anterior branches of the lower four cervical nerves and by the greater portion of the anterior branch of the first thoracic nerve. A small branch from the anterior division of the fourth cervical and another from the second thoracic nerve usually enter the plexus. These branches form the cords of the plexus, from which are given off the branches that supply the upper extremity. The nerves in the neck are arranged as follows: the anterior branches of the fifth and sixth cervical nerves unite beyond the outer border of the anterior scalene muscle to form an upper trunk; the anterior branch of the seventh cervical nerve remains distinct as the middle trunk; the anterior branches of the eighth cervical and first thoracic nerves unite between the scalenus anticus and scalenus medius muscles to form the lower trunk. The upper and middle trunks run above and parallel with the subclavian artery, but on a posterior plane, while the lower trunk passes behind the artery. The three trunks accompany the artery between the clavicle and first rib on their way to the axilla. These three trunks separate into anterior and posterior divisions, the anterior divisions of the upper and middle trunks forming the outer cord, that of the lower trunk continuing as the inner cord, and all the posterior divisions uniting to form the posterior cord. (For a description of the plexus within the axilla see Dissection of Axilla.)

The **branches of the axillary or brachial plexus** are divided into two sets: those given off above the clavicle and those arising below that bone. The branches arising above the clavicle are the nerves to the subclavius, rhomboidei, scaleni, and longus colli muscles, the posterior or long thoracic nerve (the external respiratory nerve of Bell), communicating, and supra-scapular nerves.

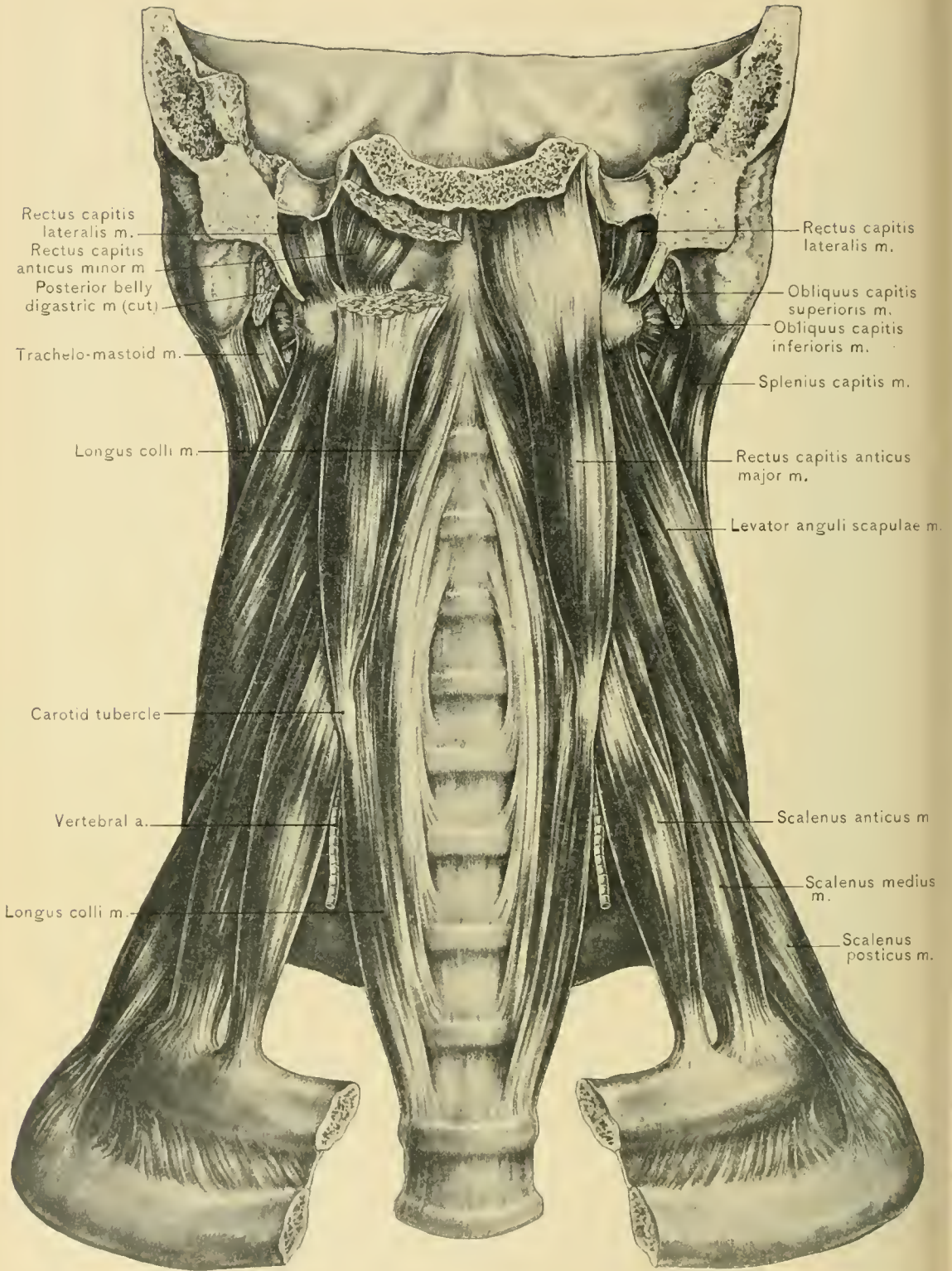
The **nerve to the subclavius muscle** arises from the trunk formed by the fifth and sixth cervical nerves, and passes downward over the third portion of the subclavian artery to the under surface of the subclavius muscle. It is frequently connected with the phrenic nerve at the lower part of the neck by a filament which passes in front of the subclavian vein.

The **nerve to the rhomboidei muscles** arises from the fifth cervical nerve,



AXILLARY OF BRACHIAL PLEXUS OF NERVES.





pierces the middle scalene muscle, and passes backward beneath the levator anguli scapulae muscle to the under surface of the rhomboidei muscles, which, with the levator anguli scapulae muscle, it supplies. It accompanies the posterior scapular artery.

The **nerves to the scaleni and longus colli muscles** arise from the lower three cervical nerves near the intervertebral foramina.

The **posterior or long thoracic nerve** (external respiratory nerve of Bell) arises within the substance of the scalenus medius muscle from the fifth, sixth, and seventh cervical nerves. The first two roots pierce the scalenus medius muscle below the nerve to the rhomboidei muscles, and the last root passes in front of the scalenus medius muscle. The long thoracic nerve passes downward behind the trunks of the axillary plexus and the subclavian vessels, and enters the axilla by way of the apex. Here it lies upon the serratus magnus muscle, which it supplies.

Communicating.—Usually a branch from the fifth cervical nerve joins the phrenic nerve on the anterior scalene muscle.

The **supra-scapular nerve**, the largest of the branches given off above the clavicle, arises from the upper cervical trunk near the nerve to the subclavius muscle. It passes downward and outward beneath the trapezius and the posterior belly of the omo-hyoid muscle to the upper border of the scapula, where it is in relation with the supra-scapular artery. It passes through the supra-scapular notch, being separated from the artery by the transverse ligament, and enters the supra-spinous fossa. It supplies the supra-spinatus muscle, winds around the base of the spine of the scapula, and sends articular branches to the shoulder-joint, after which it terminates in the infra-spinatus muscle.

The scalene muscles.—The scalene muscles are three in number: the anterior, the middle, and the posterior.

The **anterior scalene muscle** arises from the anterior tubercles of the transverse processes of the third, fourth, fifth, and sixth cervical vertebrae, and is inserted into the tubercle on the inner border and upper surface of the first rib in front of the groove for the subclavian artery. It is most deeply situated below. In relation with its anterior surface are the phrenic and pneumogastric nerves, the transversalis colli, supra-scapular, and ascending cervical arteries, the internal jugular and subclavian veins, the subclavius and omo-hyoid muscles, and the clavicular head of the sterno-mastoid muscle. On the left side the thoracic duct crosses in front of the muscle. Along the inner border of the muscle, above, lies the rectus capitis anticus major muscle: the vertebral artery and vein, the inferior thyroid artery and sympathetic nerves, which separate it from the longus colli muscle, lie along the inner side of the lower part of the muscle.

Behind the anterior scalene muscle are the pleura, the subclavian and superior intercostal arteries, the nerves forming the axillary plexus of nerves, and the middle scalene muscle.

NERVE SUPPLY.—From the anterior primary branches of the fourth, fifth, and sixth cervical nerves.

ACTION.—The anterior scalene muscle, when acting from its points of origin, will raise the first rib; but if the rib be fixed, the muscle acting from below will flex the lower cervical vertebræ, at the same time slightly rotating these vertebræ.

The **middle scalene muscle**, the largest, as well as the longest, of the three scalene muscles, arises from the posterior tubercles of the transverse processes of the lower six cervical vertebræ, and is inserted into the upper surface of the first rib, behind the groove for the subclavian artery. It is separated from the anterior scalene muscle by the subclavian artery and the nerves forming the axillary plexus. Passing through its substance is the posterior or long thoracic nerve (the external respiratory nerve of Bell). It is in relation, in front, with the cervical and brachial plexuses of nerves, the subclavian artery, the anterior scalene, omo-hyoid, and sterno-mastoid muscles, and the clavicle; along its outer border, with the levator anguli scapulæ and posterior scalene muscles; behind, with a part of the posterior scalene and the deep lateral muscles of the back of the neck.

NERVE SUPPLY.—From the posterior primary branches of the cervical nerves.

ACTION.—When acting from above, the middle scalene muscle elevates the first rib; with the rib fixed, it laterally flexes the cervical portion of the spinal column.

The **posterior scalene muscle**, the smallest and deepest of the three scaleni, arises from the posterior tubercles of the transverse processes of the lower two or three cervical vertebræ, and is inserted into the outer surface of the second rib behind the origin of the serratus magnus muscle. It is sometimes blended with the middle scalene muscle.

NERVE SUPPLY.—From the lower three cervical nerves.

ACTION.—It produces lateral cervical flexion when acting from below, and raises the second rib when acting from above.

The scaleni are accessory muscles of respiration; this can be demonstrated by placing the fingers over them while taking a full breath, when they will be felt contracting.

The **scalene tubercle**, or the tubercle on the first rib, to which the anterior scalene muscle is attached, is an important guide in locating the outer edge of the muscle and the third portion of the subclavian artery. Immediately to the outer side of the tubercle the subclavian artery can be compressed against the first rib. The position of the phrenic nerve on the anterior scalene muscle, and the relation which the clavicular head of the sterno-mastoid muscle holds to the

phrenic nerve and anterior scalene muscle must be borne in mind in operations upon the lower part of the side of the neck.

To *faradize the diaphragm* in suspended respiration, one pole of the battery should be placed over the anterior scalene muscle to stimulate the phrenic nerve. The head should be turned to the opposite side, so that the posterior border of the sterno-mastoid muscle will not extend so far beyond the phrenic nerve. The author doubts if this procedure is of any value.

DISSECTION.—Divide the trachea, esophagus, common carotid artery, internal jugular vein, the pneumogastric, sympathetic, and recurrent laryngeal nerves at the lower part of the neck. Separate these structures from the prevertebral muscles with the fingers. In order to study the prevertebral muscles and the pharynx, it is necessary to divide the skull so as to leave its posterior portion attached to the prevertebral muscles and its anterior portion attached to the pharynx. Draw the pharynx well forward; while an assistant holds a weight or block against the upper surface of the basilar process of the occipital bone, divide that process between the attachments of the pharynx and the rectus capitis anticus major muscle with a chisel and a mallet. The chisel should be directed upward and backward. Next saw through the sides of the skull, so as to leave the jugular foramina and carotid canals in the anterior segment. With a chisel separate the petrous portion of the temporal bone from the basilar process. The two portions of the skull can now be separated with a knife; the two segments can also be separated by sawing from above downward just in front of the foramen magnum. The anterior portion of the skull, with the pharynx and larynx, should be kept moist while the prevertebral muscles are dissected.

DISSECTION.—The remainder of the prevertebral fascia should now be removed.

The **prevertebral muscles** are the longus colli, rectus capitis anticus major, rectus capitis anticus minor, and rectus capitis lateralis.

The **longus colli muscle** consists of three sets of fibers: a longitudinal, a superior oblique, and an inferior oblique set. The *longitudinal set* arises from the bodies of the first, second, and third thoracic, and of the sixth and seventh cervical vertebræ, and passes upward to be inserted into the bodies of the second, third, and fourth cervical vertebræ. The *superior oblique set* arises from the anterior tubercles of the transverse processes of the third, fourth, and fifth cervical vertebræ, and passes upward and inward to be inserted into the anterior tubercle of the atlas. The *inferior oblique set* arises from the bodies of the first, second, and third thoracic vertebræ, and passes upward and outward to be inserted into the anterior tubercles of the transverse processes of the fifth and sixth cervical vertebræ.

Lying in front of the longus colli muscle are the prevertebral fascia, the pharynx, the esophagus, the sympathetic nerve, the inferior thyroid artery, the

recurrent laryngeal nerve, and the carotid sheath, containing the pneumogastric nerve, common carotid artery, and internal jugular vein. Behind the muscle are the cervical and upper thoracic vertebræ and the vertebral artery. Below, the vertebral artery lies along the outer border of the muscle, in the groove between it and the scalenus anticus muscle.

NERVE SUPPLY.—From the anterior branches of the lower cervical nerves.

ACTION.—It flexes the cervical portion of the spinal column, slightly flexes it laterally, and rotates it.

The **rectus capitis anticus major muscle** arises from the anterior tubercles of the third, fourth, fifth, and sixth cervical vertebræ by four tendinous slips; these slips pass upward and inward to the belly of the muscle, which is inserted into the basilar process of the occipital bone by a short tendon.

In front of the muscle are the prevertebral fascia, the common and internal carotid arteries, the internal jugular vein, the pneumogastric and sympathetic nerves, and a portion of the pharynx. Behind it are the rectus capitis anticus minor and part of the longus colli muscle, and the upper cervical vertebræ.

NERVE SUPPLY.—From the first and second cervical nerves.

ACTION.—It flexes the head and rotates the face to the same side.

DISSECTION.—Divide the rectus capitis anticus major muscle near the basilar process and reflect it downward to expose the rectus capitis anticus minor muscle.

The **rectus capitis anticus minor muscle** arises from the anterior part of the lateral mass and the root of the transverse process of the atlas. Its fibers pass upward and inward to be inserted into the basilar process of the occipital bone, between the foramen magnum and the insertion of the rectus capitis anticus major muscle, which lies in front of it. Behind it is the occipito-atlantal joint.

NERVE SUPPLY.—From the first cervical nerve.

ACTION.—It flexes the head.

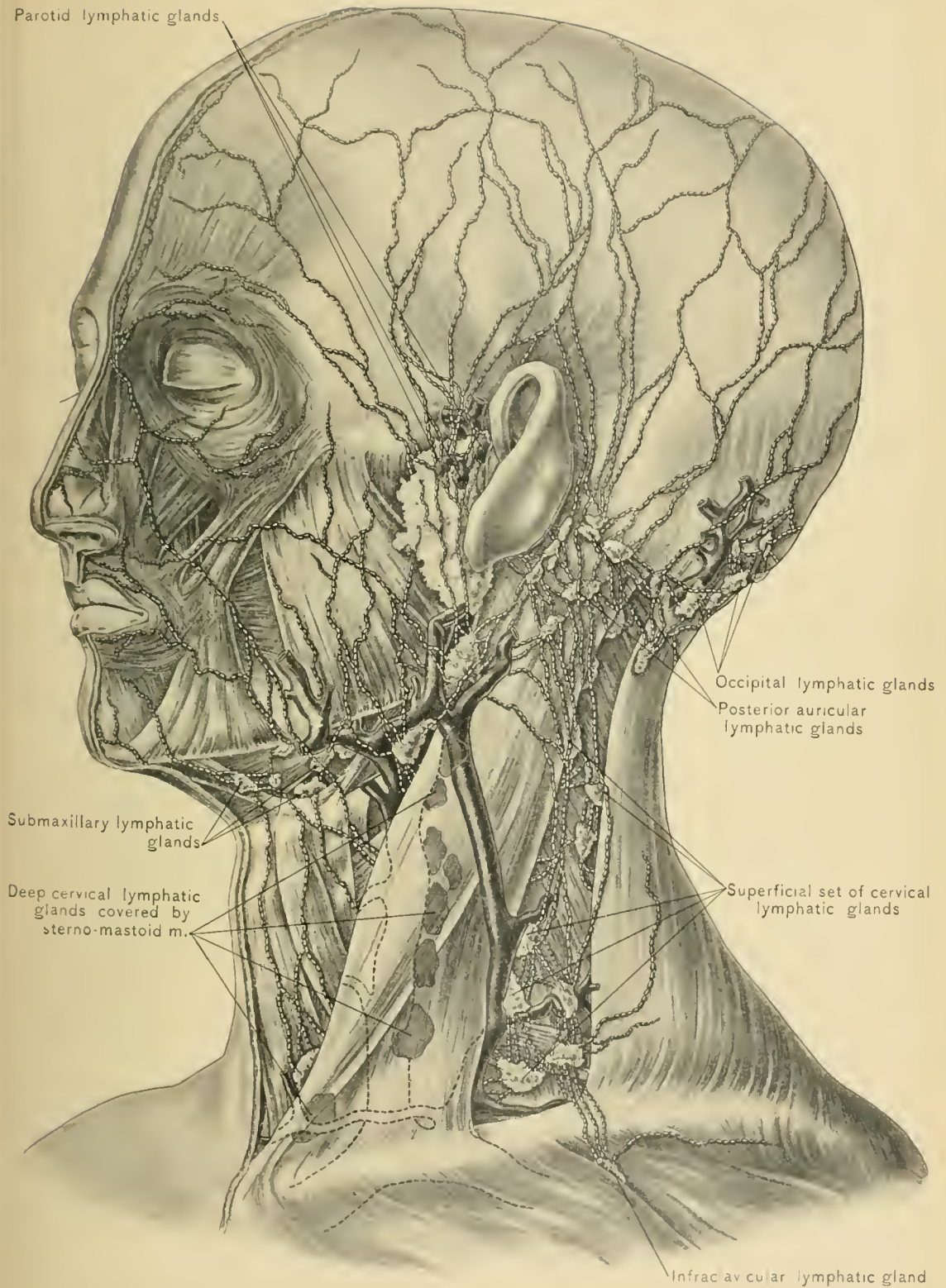
The **rectus capitis lateralis muscle** is seen to the outer side of, and slightly posterior to, the rectus capitis anticus minor muscle. It arises from the upper surface of the transverse process of the atlas, and is inserted into the jugular process of the occipital bone.

In front of it are the internal jugular vein and the anterior branch of the first cervical nerve, and behind it are the trachelo-mastoid muscle and the vertebral artery. The occipital artery lies on its outer side.


NERVE SUPPLY.—From the anterior branch of the first cervical nerve.

ACTION.—It flexes the head laterally.

There are three **bursæ** in the neck: one in front of the upper part of the thyroid cartilage, or *pomum Adami*; another between the upper margin of the thyroid cartilage and the posterior surface of the hyoid bone; a third is also situ-



LYMPHATIC GLANDS AND LYMPHATIC VESSELS.



ated near the median line, between the genio-hyoid and genio-hyo-glossus muscles. These bursæ may become enlarged; that beneath the genio-hyoid muscle, when distended, may simulate a ranula. Like goiters and cysts of the thyroid gland, they move with the larynx in deglutition, differing in this respect from sebaceous and dermoid cysts, aneurysms of the carotid arteries, and growths of the lymphatic glands.

LYMPHATIC GLANDS OF THE NECK.

The lymphatic glands of the neck are classified as superficial and deep.

The **Superficial Lymphatic Glands** of the neck are most numerous along the course of the external jugular vein and posterior jugular vein. This set, the **superficial cervical chain**, is composed of from four to six glands, and lies beneath the superficial layer of the deep cervical fascia in the posterior triangle. The glands of this set are most numerous at the lower part of this triangle. Other small superficial lymphatic glands are seen in the median line of the neck: one below the symphysis of the lower jaw, two above the body of the hyoid bone, one near the cricoid cartilage, one above the sternum, and some resting upon the trapezius muscle. The superficial cervical chain receives the efferent vessels from the suboccipital and posterior auricular lymphatic glands and some from the parotid and submaxillary lymphatic glands, and the lymphatic vessels from the external ear and skin of the neck. Their efferent vessels empty into the inferior deep cervical glands. The lowest of the superficial cervical lymphatic glands also receive lymphatic vessels from the infraclavicular glands which are situated in the upper part of the delto-pectoral sulcus. In secondary syphilis the superficial cervical lymphatic glands along the posterior border of the sterno-mastoid muscle are enlarged early and can readily be felt.

The **Deep Lymphatic Glands** of the neck number from twenty to thirty, and are situated along the internal jugular and subclavian veins. They are divided into a superior and an inferior set. The **superior set** is situated along the internal jugular vein, between the base of the skull and the bifurcation of the common carotid artery. These glands receive the efferent vessels from the internal maxillary lymphatic glands, and some from the submaxillary lymphatic glands, the lymphatic vessels from the cranial cavity, the deep muscles of the upper part of the neck, the posterior part of the tongue, the middle portion of the pharynx, the upper part of the larynx, and the upper part of the thyroid body. Their efferent vessels empty into the glands of the inferior set. The **inferior set** is situated along the internal jugular vein, below the bifurcation of the common carotid artery, and extends outward into the subclavian triangle along the subclavian vein. These glands receive the efferent vessels from the superior deep cervical

and the superficial cervical glands; the lymphatic vessels from the lower part of the thyroid body, lower part of the larynx, lower part of the pharynx, upper part of the trachea and esophagus, and lower part of the neck; and some of the lymphatic vessels from the axillary and infra-clavicular glands. Their efferent vessels unite to form the jugular lymphatic trunk, which empties into the right lymphatic duct on the right side, and into the thoracic duct on the left side.

The deep cervical lymphatic glands are more important surgically than the superficial glands. These deep glands hold so close a relation to the great vessels of the neck that an attempt to remove them when they are much enlarged may lead the operator into dangerous locations.

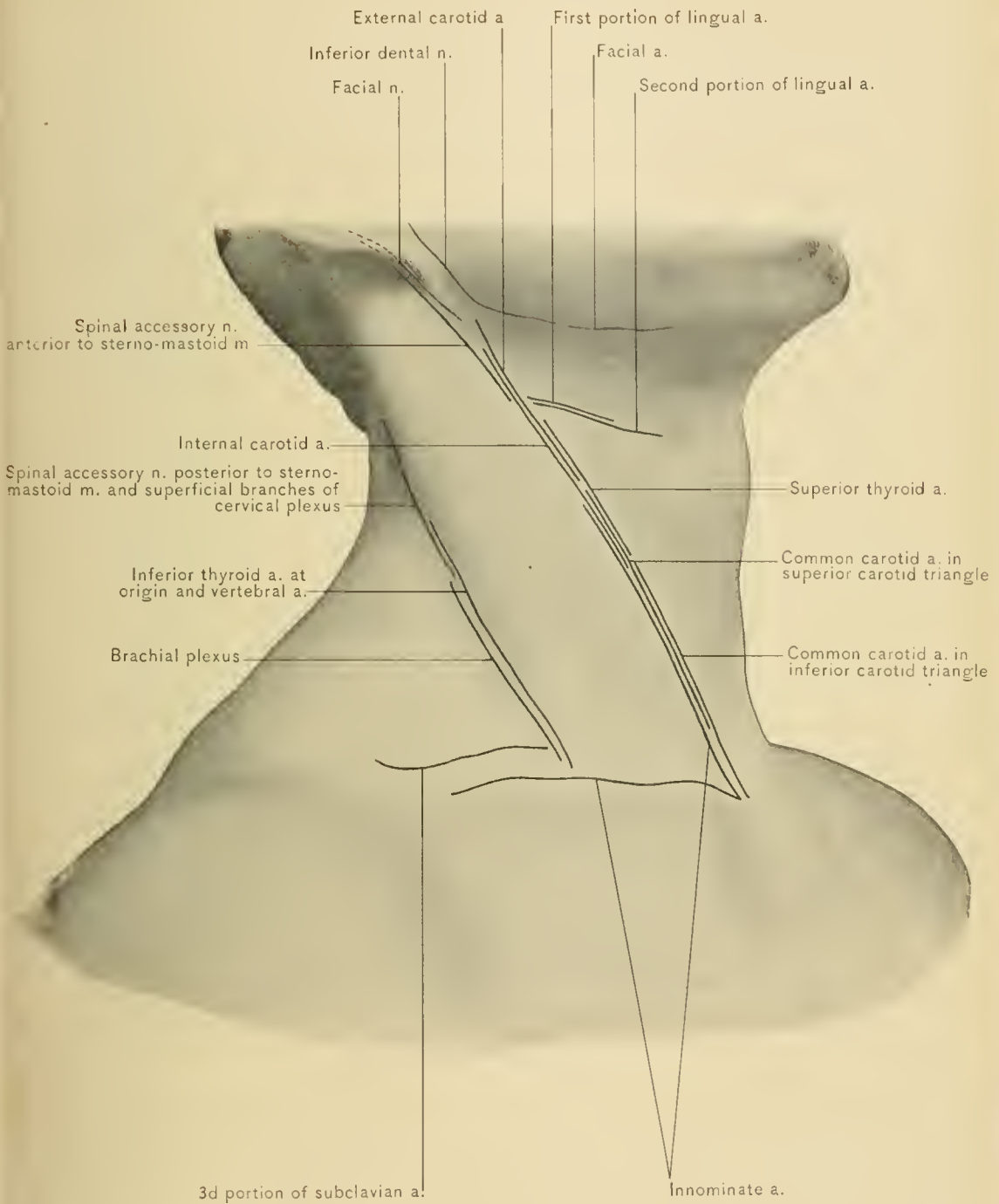
In the most radical operation for excision of the mammary gland for carcinoma the lymphatic glands in the subclavian triangle are removed so that there will be less likelihood of recurrence of the disease.

The *right lymphatic duct* is a short trunk about one-half of an inch in length. It receives the lymphatic vessels from the right side of the neck, right upper extremity, right side of the thorax, and upper surface of the liver. It empties into the subclavian vein or the internal jugular vein at the junction of these veins. Its orifice is guarded by a double valve.

The *thoracic duct*, which is described with the contents of the thorax, receives the lymphatic vessels from about three-fourths of the body—from the left side of the head, neck, and thorax, left upper extremity, abdomen, and lower extremities. It is found only on the left side in the neck. It emerges from the upper opening of the thorax behind and internal to the apex of the left pleural sac, curves forward and outward above the first portion of the left subclavian artery and in front of the left vertebral artery, and empties into the left subclavian vein or the left internal jugular vein near the angle of junction of these veins. The thoracic duct near its termination may subdivide into two or more ducts, and it rarely empties into the right subclavian vein.

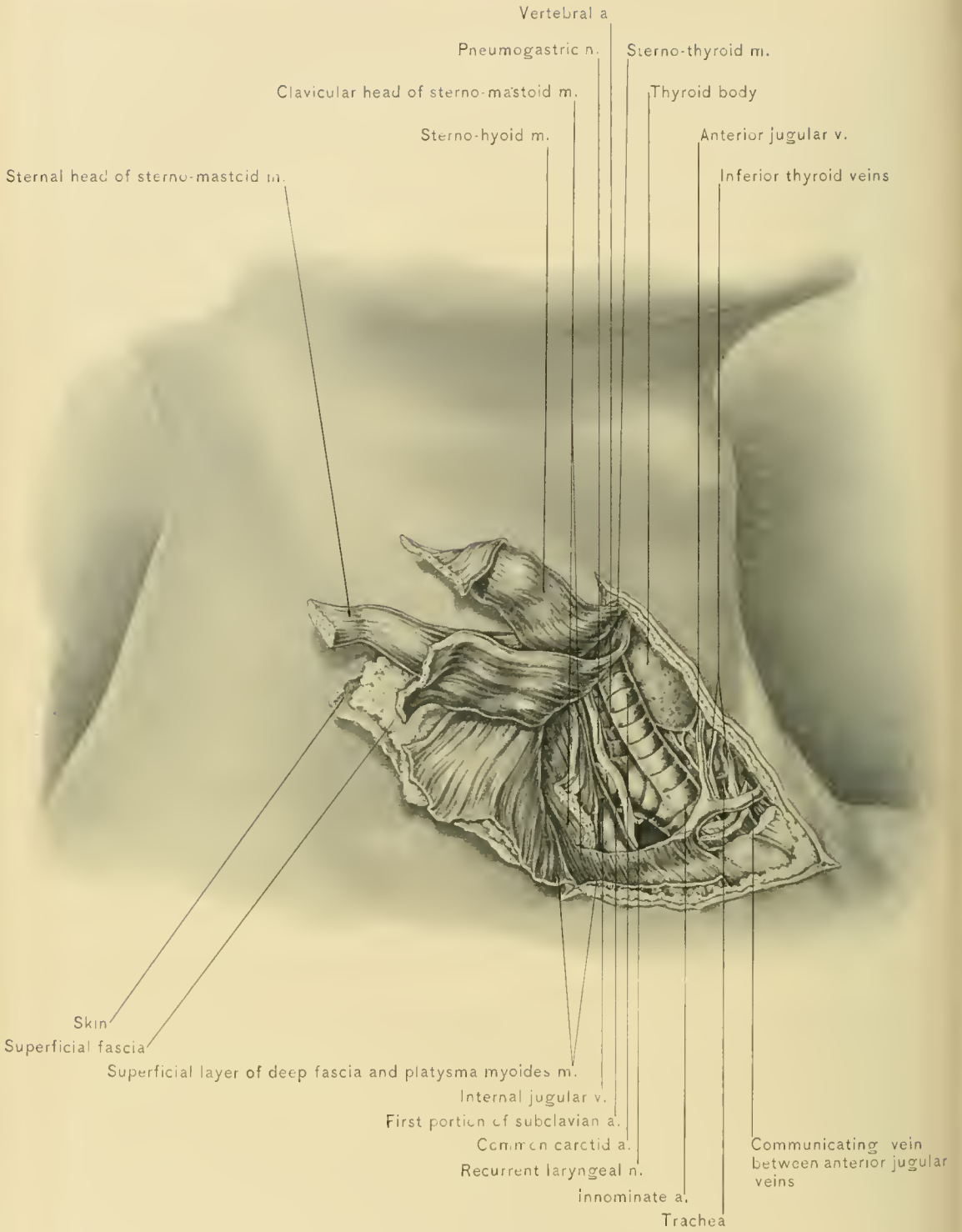
LIGATION OF ARTERIES OF HEAD AND NECK.

The **innominate artery** has been ligatured twenty-four times, with but two recoveries (Ashhurst). The operation is, for this reason, rarely performed. Ligation was indicated in these cases by aneurysms of the right subclavian or common carotid artery. Death was caused by secondary hemorrhage occurring on the distal side of the ligature. To avoid this sequel, ligatures should be placed at the same time upon the common carotid and vertebral arteries and not upon the



LINES OF INCISIONS FOR OPERATIONS ON NERVES AND ARTERIES OF HEAD AND NECK.





EXPOSURE OF INNOMINATE ARTERY.

innominate artery. In front of the innominate artery are the sternum, right sterno-clavicular joint, sterno-hyoid and sterno-thyroid muscles, and the remains of the thymus gland. The left innominate vein crosses it at its origin, and the right inferior thyroid vein descends obliquely over its lower and inner part. Behind it are the trachea and right pleura. To its right side are the right innominate vein, right pneumogastric nerve, and pleura. To its left side are the inferior thyroid veins, left common carotid artery, remains of the thymus gland, and, at its upper end, the trachea. The innominate artery divides most frequently at the upper border of the right sterno-clavicular articulation; it occasionally divides lower, but seldom higher. Its depth and relation to important and delicate structures render the operation of ligation a difficult one. The incision should be carried along the anterior border of the right sterno-mastoid muscle to the upper margin of the sternum, and thence along the right clavicle. An angular incision is thus made, each part of which should be about three inches in length. The superficial incision divides the skin, superficial fascia, platysma myoides muscle, and supra-sternal and supra-clavicular branches of the cervical plexus. The triangular flap of skin, superficial fascia, and platysma myoides muscle should next be turned upward. The superficial layer of the deep fascia, sterno-hyoid, sterno-thyroid, and inner part of the sterno-mastoid muscle are next divided. The anterior jugular vein, which may require division between ligatures, runs transversely under the lower end of the sterno-mastoid muscle. The sheath of the common carotid artery should be opened and the artery traced downward to the innominate artery. The aneurysm needle, directed slightly downward, should be carefully passed around the artery, from without inward. In doing this, the dangers to be guarded against are punctures of the innominate vein and pleura.

COLLATERAL CIRCULATION.—The collateral circulation is established by the following anastomoses :

PROXIMAL.		DISTAL.
Aortic intercostal arteries	with	{ Superior intercostal artery. Internal mammary artery. Superior thoracic artery. Long thoracic artery. Subscapular artery. Posterior scapular artery.
Phrenic artery } Deep epigastric artery }	with	Internal mammary artery.
Thyroidea ima artery	with	{ Superior thyroid artery. Inferior thyroid artery.

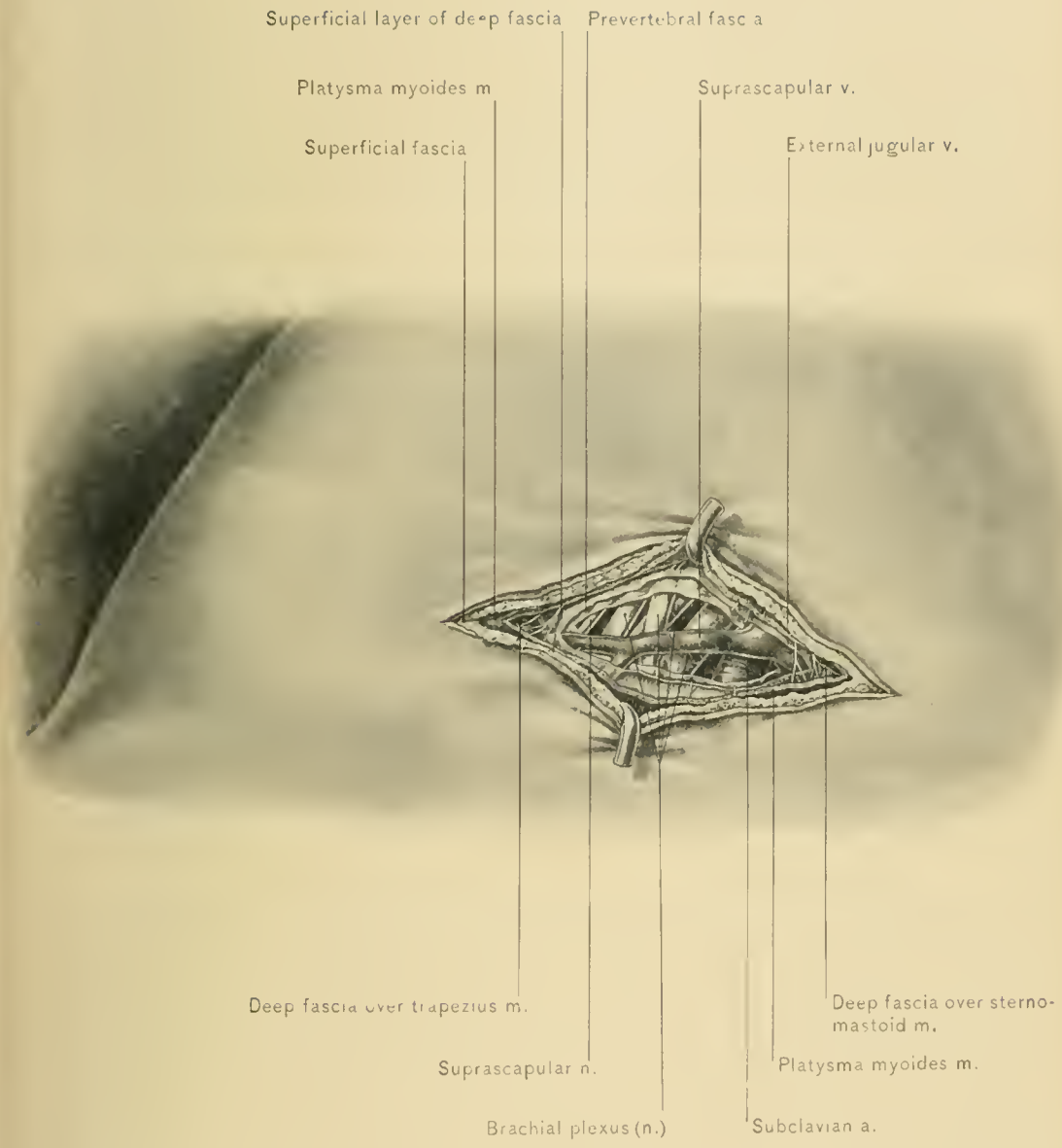
Arteries of one side of the head and neck anastomose with corresponding arteries of the opposite side, as the two external carotid, two internal carotid, two vertebral, two inferior thyroid arteries, etc.

IRREGULAR FORMS.—The innominate artery may bifurcate higher or lower than the upper margin of the right sterno-clavicular articulation; it may give off the thyroidea ima, vertebral, or internal mammary artery, a thymic, tracheal, bronchial, or pericardiac branch, and it may arise as the third branch of the transverse portion of the arch of the aorta. When the innominate artery bifurcates at an unusually high level, it may be tied more readily, and may overlie the trachea for an inch above the sternum and be endangered in the low operation for tracheotomy; if it divide at a lower level, it is tied with greater difficulty. When the innominate artery is the last branch of the transverse portion of the arch of the aorta, it may pass behind the trachea and esophagus. An innominate artery rarely exists on the left side, or the innominate artery may be absent and the right common carotid and the right subclavian artery may arise from the arch of the aorta.

GUIDES.—The guides to the innominate artery are the right sterno-clavicular articulation, the right common carotid artery, and the angle between the roots of the right common carotid and the right subclavian artery.

The **subclavian artery** is usually tied at its third portion, which is to the outer side of the anterior scalene muscle, and is the place of election. Ligature of the *first portion* of the artery is attended by great risk, this portion being deeply placed, and having closely associated with it the pneumogastric and sympathetic nerves and their cardiac branches; the pleura is behind and the commencement of the innominate vein or the termination of the internal jugular vein in front of the first portion. The *second portion* is seldom tied, the artery being here covered by the anterior scalene muscle, which underlies the phrenic nerve; this portion is closely related to the pleura.

The *third portion* of the subclavian artery is more accessible, being more superficial, and not so closely associated with important structures. It is ligatured for aneurysm of the arch of the aorta, the innominate, and the axillary artery; also previous to excision of the scapula, amputation at the shoulder-joint, and removal of large growths from the axilla. It is covered by the skin, superficial fascia, platysma myoides muscle, supra-clavicular branches of the cervical plexus, superficial layer of the deep cervical fascia, areolar tissue and fat, which here contains the terminations of the external jugular vein and supra-scapular vein, and, at times, the posterior external jugular, transversalis colli, and jugulo-cephalic veins. When all of these veins are present in this location, they form a plexus over the artery and increase the difficulty of reaching the vessel. The third



EXPOSURE OF THIRD PORTION OF SUBCLAVIAN ARTERY.



portion of the artery is also covered by the prevertebral fascia or posterior process of the deep cervical fascia, and is crossed by the nerve to the subclavius muscle. The supra-scapular artery and vein cross this portion of the artery from within outward, and usually lie near the level of the upper border of the clavicle. In this respect the supra-scapular artery bears the same relation to the subclavian artery at the point of election as the middle sterno-mastoid artery does to the common carotid artery at its point of election. Behind this part of the artery are the middle scalene muscle, the first rib, and the lower cervical trunk of the brachial plexus, which is formed by the eighth cervical and the first thoracic nerve. Above it are the upper and middle trunks of the brachial plexus and the posterior belly of the omo-hyoid muscle. The upper cervical trunk of the brachial plexus, which lies just above the artery and in an anterior plane, may be mistaken for the subclavian artery. Below, it rests against the upper surface of the first rib. The subclavian vein lies below the subclavian artery, but on an anterior plane, and is usually behind the clavicle.

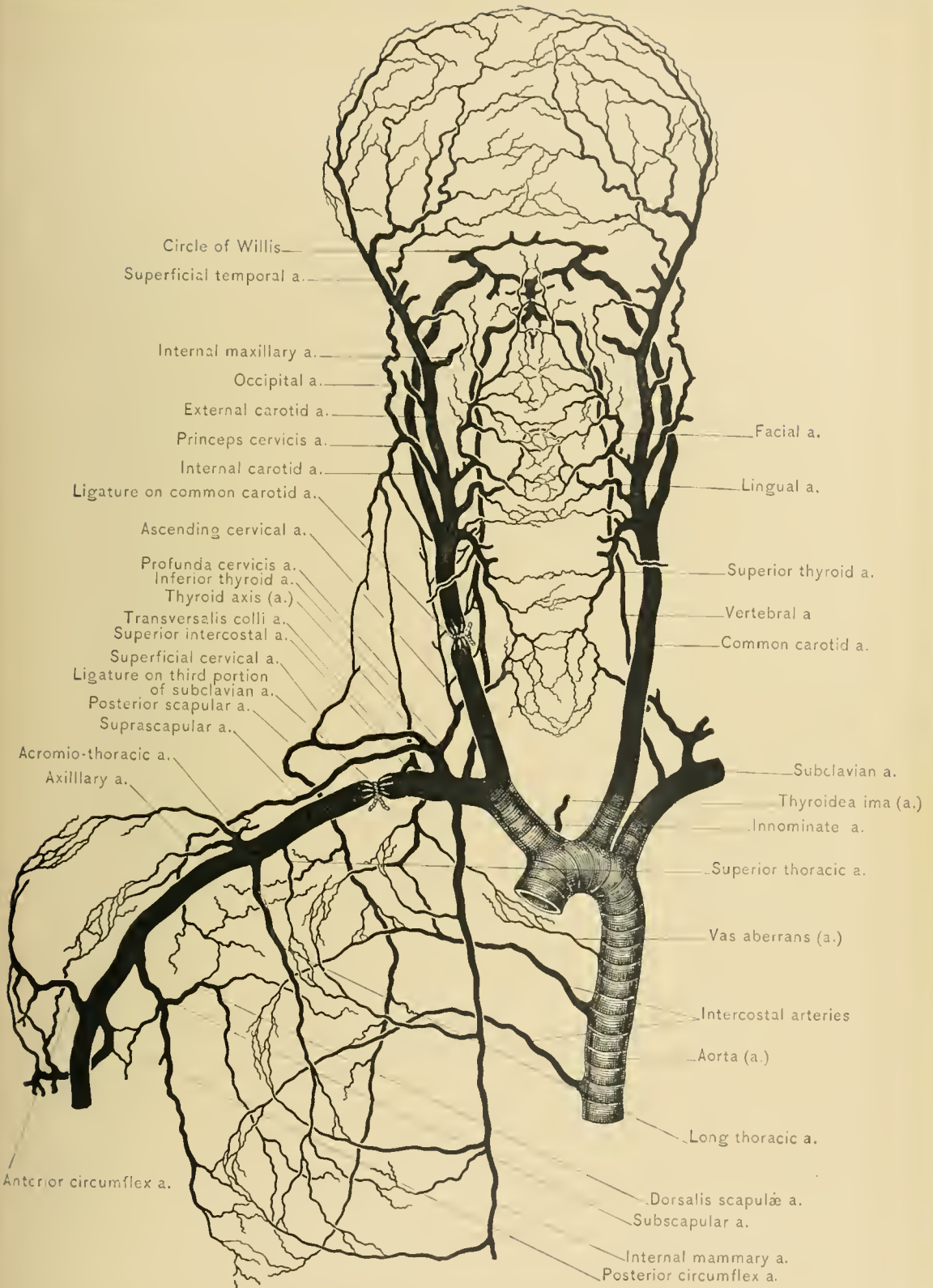
In ligating the third portion of the subclavian artery the upper part of the thorax should be elevated by placing a pillow beneath the shoulders; the neck should be extended, and the head turned toward the opposite side. The shoulder is next depressed, to make the subclavian triangle shallow, and to bring the artery nearer to the surface. The skin should be drawn downward over the clavicle, and a transverse incision, three inches long, should be carried along that bone, so that when the skin is allowed to retract, the incision will be about one-half of an inch above the clavicle. This method of dividing the skin obviates the danger of injuring the external jugular vein, which crosses the artery close to or under the posterior border of the sterno-mastoid muscle. The incision should extend from the trapezius to the sterno-mastoid muscle. It divides the skin, superficial fascia, platysma myoides muscle, supra-clavicular branches of the cervical plexus, some small arteries, and the jugulo-cephalic vein, if present. The superficial layer of the deep fascia is next divided. If a plexus of veins be present, the veins should be divided between ligatures, and the posterior process of the deep fascia (prevertebral fascia) carefully incised. The posterior belly of the omo-hyoid muscle is located, and the posterior border of the anterior scalene muscle is found, and traced downward to the scalene tubercle of the first rib. The artery may be felt pulsating just external to the tubercle, and is exposed, together with the cervical trunks of the brachial plexus, by a slight dissection. The sheath of the artery being opened, the aneurysm needle is passed around the artery from before backward and below upward, to avoid the subclavian vein, which lies below, but in an anterior plane. The needle should be held close to the artery, to avoid inclusion of the lowest trunk of the brachial plexus, which lies behind the artery.

The transversalis colli artery is rarely seen, owing to its high position, while the supra-scapular artery crosses the subclavian artery just behind the clavicle. If either artery is seen, it should be displaced, and not divided; if the external jugular vein causes much difficulty, it should be divided between ligatures. In very muscular subjects it may be necessary to cut through the posterior part of the clavicular origin of the sterno-mastoid muscle. The variations in the position of this portion of the artery should be borne in mind. It usually emerges from beneath the anterior scalene muscle, about one-half of an inch above the clavicle, and descends abruptly; it may, however, lie almost entirely under the clavicle, or it may ascend as high as one and one-half inches above the clavicle. It occasionally gives origin to the posterior scapular artery. That the ligature has been applied to the subclavian artery instead of to a trunk of the brachial plexus is proved by the absence of the pulse beyond the ligature.

The COLLATERAL CIRCULATION is established by the anastomoses of the—

ABOVE.		BELOW.
Supra-scapular and Posterior scapular arteries	with	Acromio-thoracic, posterior circum- flex, and subscapular arteries.
Internal mammary artery Superior intercostal artery Aortic intercostal artery	with	Superior thoracic, long thoracic, and subscapular arteries.

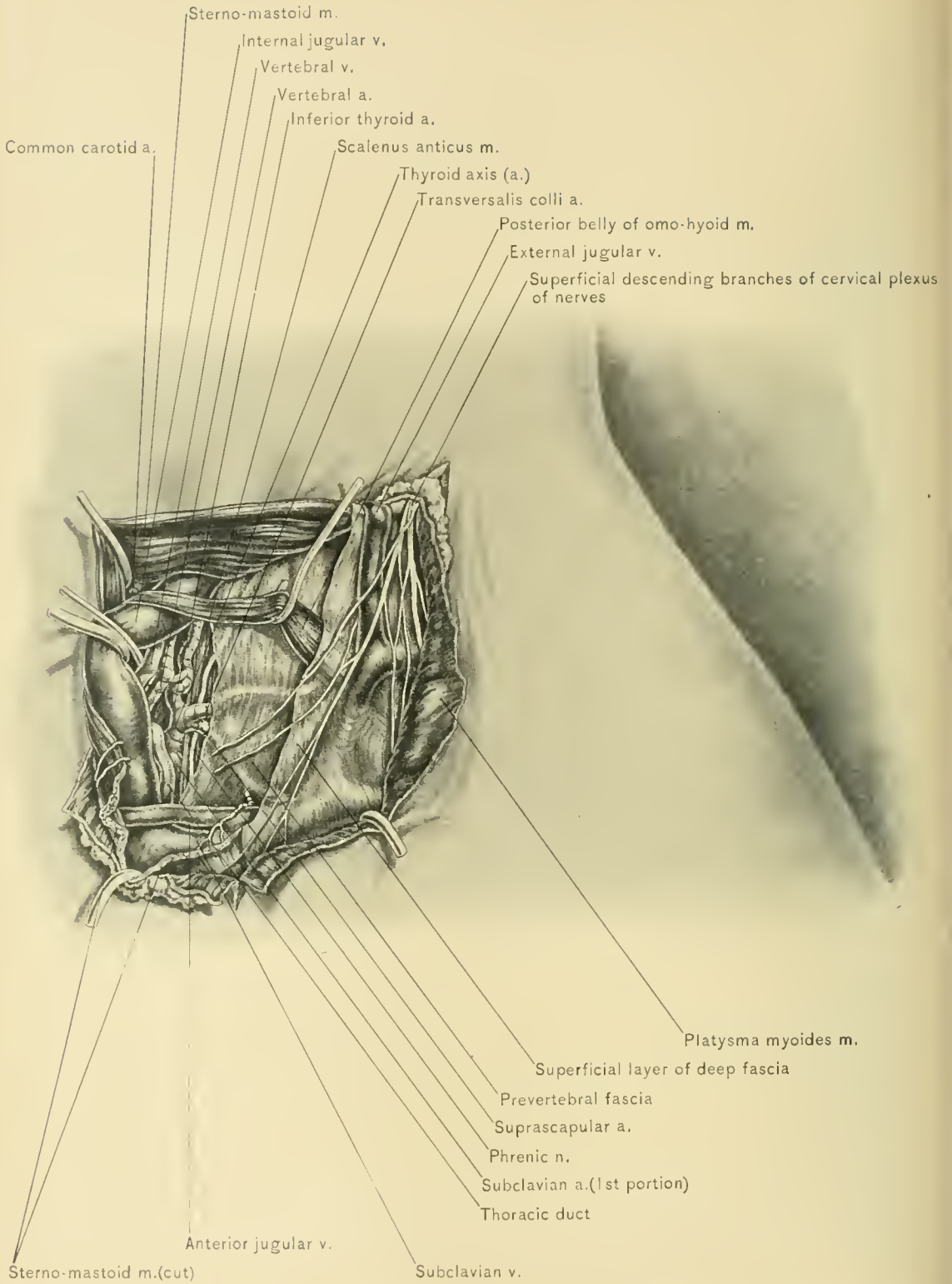
IRREGULAR FORMS.—The *right subclavian artery* arises at times higher or lower than normally, or may spring directly from the transverse portion of the arch of the aorta as the first, second, third, or fourth branch. When it is the first branch, the first portion takes the course of the innominate artery and is more deeply situated than normally; when it is the second or third branch, it usually passes under the common carotid artery; and when it is the fourth branch, it may pass under the trachea and esophagus, or between the trachea and esophagus, and has been seen arising from the descending portion of the aorta as low as the fourth thoracic vertebra. The *left subclavian artery* may arise from a short trunk common to it and the left common carotid artery. On each side the subclavian artery may pass in front of or pierce the scalenus anticus muscle; the subclavian vein may accompany the second portion of the subclavian artery through or under the scalenus anticus muscle. The second portion may lie under the clavicle, or may rise one and one-half inches above the clavicle. The third portion of the subclavian artery frequently gives origin to the posterior scapular artery, and occasionally to the supra-scapular artery, and in muscular persons may be covered by the sterno-mastoid and trapezius muscles. A clavicular origin of the posterior belly of the omo-hyoid muscle may lie in front of this portion, and this belly of the



COLLATERAL CIRCULATION AFTER LIGATION OF SUBCLAVIAN AND COMMON CAROTID ARTERIES.







EXPOSURE OF VERTEBRAL ARTERY AND INFERIOR THYROID ARTERY AT ORIGIN—LEFT SIDE OF NECK.

omo-hyoid may lie close to the clavicle in front of the subclavian artery. The external jugular vein may cross the artery at some distance external to the posterior border of the sterno-mastoid muscle.

GUIDES.—The guides to the third portion of the subclavian artery (the place of election) are the most prominent part of the clavicle behind which it lies, the posterior border of the sterno-mastoid muscle, the outer border of the insertion of the scalenus anticus muscle into the scalene tubercle of the first rib, and the pulsations of the artery.

The **vertebral artery** may be ligatured for wounds, traumatic aneurysm, and aneurysm of the innominate artery and arch of the aorta. Its only accessible portion is deeply situated in the lower part of the neck, where it lies in the groove between the scalenus anticus and longus colli muscles. This portion of the artery is in relation, in front, with the vertebral and internal jugular veins, and is crossed on both sides by the inferior thyroid artery and by the thoracic duct on the left side. The vertebral vein crosses in front of the artery just below the transverse process of the sixth cervical vertebra; it then lies in front and to the outer side of the artery as it passes downward to the innominate vein. The relation of this vein to the artery is variable, as the vein may be found on either side of the artery. Behind the artery are the sympathetic nerve cord, the inferior cervical sympathetic ganglion, and the transverse process of the seventh cervical vertebra. To its inner side is the longus colli muscle, and to its outer side the anterior scalene muscle. It is surrounded by the vertebral sympathetic plexus.

In the operation for ligation of the vertebral artery the patient lies in the same position as in ligation of the third portion of the subclavian artery—*i. e.*, with the shoulder elevated, the neck extended, and the face turned to the opposite side. The incision should commence at the clavicle, and be carried for three inches upward along the posterior border of the sterno-mastoid muscle.

Care is required here to avoid injuring the external jugular vein, which runs under the platysma myoides muscle obliquely across the sterno-mastoid muscle to its posterior border, then along that border, piercing the superficial layer of the deep fascia one-half of an inch above the clavicle. The incision divides the skin, superficial fascia, platysma myoides muscle, and descending branches of the cervical plexus. The external jugular vein is exposed and drawn outward, and the superficial layer of the deep fascia divided. It may be necessary to sever part of the clavicular head of the sterno-mastoid muscle at its origin. The anterior scalene muscle is located, and the surgeon carries his finger inward through the interval between the prevertebral fascia and the superficial layer of the deep fascia. The positions of the internal jugular vein, common carotid artery, and transverse process of the sixth cervical vertebra are ascertained. The anterior

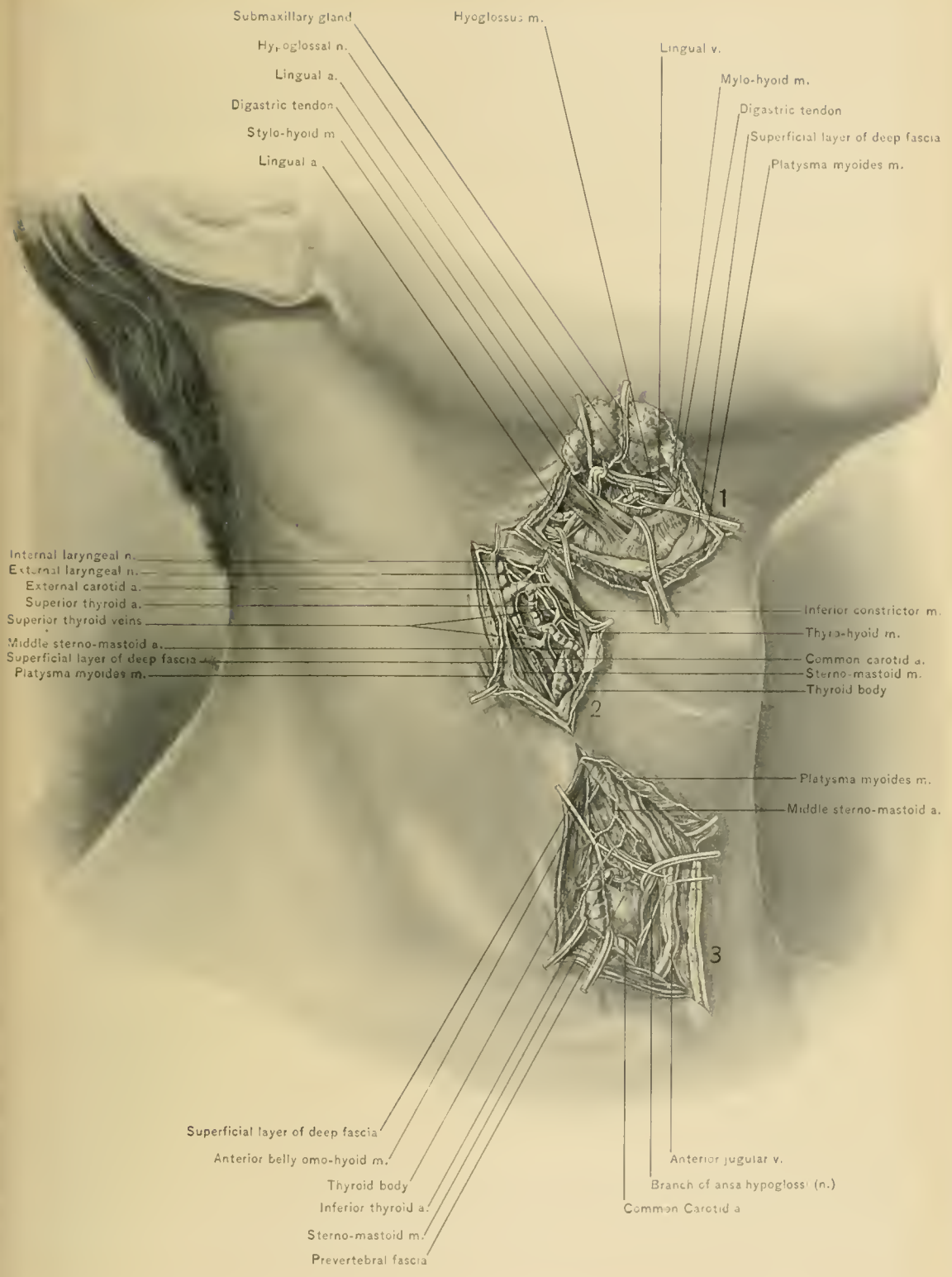
tubercle of the transverse process of the sixth cervical vertebra (carotid tubercle) is the guide to the vertebral artery, for the reason that it is usually the first transverse process which is entered by the artery. Just below this tubercle the groove between the scalenus anticus and longus colli muscles can be felt, and the prevertebral fascia is divided along the inner border of the scalenus anticus muscle. Along the inner border of the scalenus anticus muscle the inferior thyroid artery can be recognized by its pulsations; the vertebral artery is detected in the same manner, deep in the groove previously mentioned. The vertebral vein and inferior thyroid artery should then be drawn outward, and the needle be passed from without inward. Care is necessary to avoid injuring the internal jugular vein, inferior thyroid artery, vertebral vein, pleura, the right lymphatic duct, and, on the left side, the thoracic duct. The phrenic nerve is not endangered, because it lies beneath the prevertebral fascia on the scalenus anticus muscle. Immediately after the artery is tied contraction of the pupil of the same side occurs, due to disturbance of the vertebral plexus of the sympathetic nerve. This condition is evidence that the inferior thyroid artery or its ascending cervical branch has not been ligatured instead of the vertebral artery.

IRREGULAR FORMS.—The left vertebral artery may arise from the subclavian artery at a point unusually near either to the origin or the termination of the first portion of the left subclavian artery. It may arise from the arch of the aorta or the left common carotid artery.

The right vertebral artery occasionally arises nearer to the bifurcation of the innominate artery or to the inner margin of the scalenus anticus muscle. When the right subclavian artery arises from the aortic arch, the right vertebral artery may arise from the right common carotid artery or from the arch of the aorta. When it arises from the left side of the aortic arch, it may pass behind the esophagus.

Either vertebral artery may arise from the subclavian as two branches, which later unite, or the vertebral artery may divide while passing upward in the transverse processes, one branch entering the spinal canal with the second cervical nerve, and the other pursuing the normal course of the vertebral artery. On each side the vertebral artery frequently enters the passageway in the cervical transverse processes, at some other than at the sixth cervical transverse process. It may first enter any of the cervical transverse processes from the second to the seventh inclusive. When the artery first enters the seventh cervical transverse process its ligation is difficult, and when it enters above the sixth, the artery lies nearer to the esophagus than normally. The vertebral artery rarely gives origin to the inferior thyroid, superior intercostal, profunda cervicis, or occipital artery. One vertebral artery may be larger than the artery of the opposite side.

GUIDES.—The guides to the vertebral artery are the posterior border of the



LIGATION OF (1) FIRST AND SECOND PORTIONS OF LINGUAL ARTERY, (2) SUPERIOR THYROID ARTERY; (3) INFERIOR THYROID ARTERY.



sterno-mastoid muscle and the carotid tubercle or anterior tubercle of the sixth cervical transverse process, which lies at the upper extremity of the groove between the scalenus anticus and longus colli muscles.

The **inferior thyroid artery** may be ligatured to arrest the growth of the thyroid body in goiter, and for wounds of this body. It is more commonly ligatured in the removal of one-half of the thyroid body (thyroidectomy). It may be tied near its origin, where it lies along the inner border of the anterior scalene muscle,—*i. e.*, between that muscle and the internal jugular vein, or to the inner side of the carotid sheath as it enters the thyroid gland. It is seldom ligatured near its origin, where it may be secured through an incision similar to that made in ligature of the vertebral artery. To reach it just before it enters the thyroid body, where it lies on or slightly below the level of the cricoid cartilage of the larynx, the shoulders should be elevated and the neck extended, and an incision three inches long be made along the lower portion of the anterior border of the sterno-mastoid muscle. The skin, superficial fascia, and platysma myoides muscle are divided, avoiding the anterior external jugular vein; the superficial layer of the deep fascia is also divided. The sterno-mastoid muscle and carotid sheath with its contents should be drawn outward, and the sterno-hyoid and sterno-thyroid muscles and thyroid body drawn inward. Locate the carotid tubercle behind the carotid sheath, and the artery will be felt pulsating just below and internal to it. Next divide the prevertebral fascia. The artery should then be tied near the carotid sheath, thus avoiding injury of the recurrent laryngeal nerve; this nerve, however, is not in much danger, as in this location it lies behind and internal to the lateral lobe of the thyroid body. The inferior thyroid artery frequently divides behind the carotid sheath into two terminal branches of about equal size, which are separated by an interval of about one-fourth of an inch.

IRREGULARITIES.—The inferior thyroid artery occasionally arises directly from the first portion of the subclavian artery; it may, however, arise from the third portion near the outer border of the scalenus anticus muscle, or from the vertebral or common carotid artery. It may subdivide before it reaches the thyroid body, or it may arise as two separate arteries, one branch of it passing in front of and the other behind the carotid sheath. The artery may be small or absent.

The **common carotid artery** is tied for aneurysm or wounds of the internal or external carotid artery or their branches, to check malignant growths, and preparatory to the removal of tumors. It may be tied in any part of its course in the neck, which is indicated by a line drawn from the sterno-clavicular articulation to a point midway between the angle of the lower jaw and the mastoid process of the temporal bone, the portion of this line below the level of the upper border of the thyroid cartilage indicating the course of the common carotid artery. On the

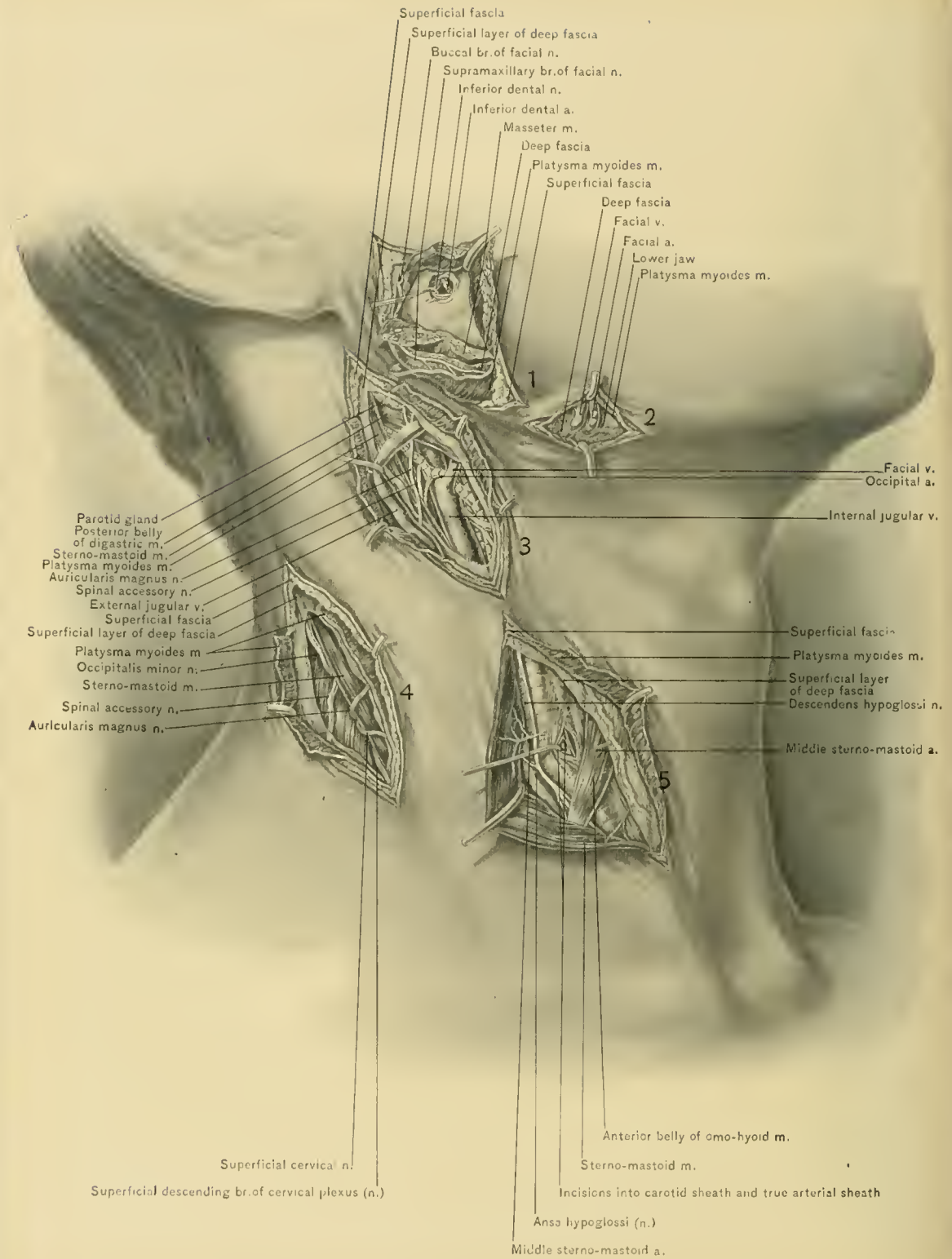
right side the common carotid artery arises as one of the two terminal branches of the innominate artery, which divides behind the upper border of the right sterno-clavicular articulation; on the left side, however, it arises within the chest from the arch of the aorta. On both sides the common carotid artery terminates opposite the upper border of the thyroid cartilage, where it divides into the external and internal carotid arteries.

In front of the artery are the skin, superficial fascia, platysma myoides muscle, superficial layer of the deep fascia, inner border of the sterno-mastoid muscle, anterior jugular vein, sterno-hyoid muscle, sterno-thyroid muscle, lateral lobe of the thyroid gland, superior and middle thyroid veins, middle sterno-mastoid artery, omo-hyoid muscle, descendens hypoglossi nerve, ansa hypoglossi, and anterior wall of the sheath. To its outer side are the internal jugular vein and the pneumogastric nerve. On the right side the internal jugular vein at the root of the neck passes outward away from the artery, while on the left side it overlaps the artery and curves forward to empty into the left innominate vein. Behind and to its outer side is the pneumogastric nerve, and behind it are the posterior wall of its sheath, the sympathetic nerve, inferior thyroid artery, recurrent laryngeal nerve, and the longus colli and rectus capitis anticus major muscles. To its inner side are the inner wall of its sheath, the trachea, esophagus, recurrent laryngeal nerve, lateral lobe of the thyroid gland, cricoid cartilage, thyroid cartilage, pharynx, superior thyroid artery, and external laryngeal branch of the superior laryngeal nerve.

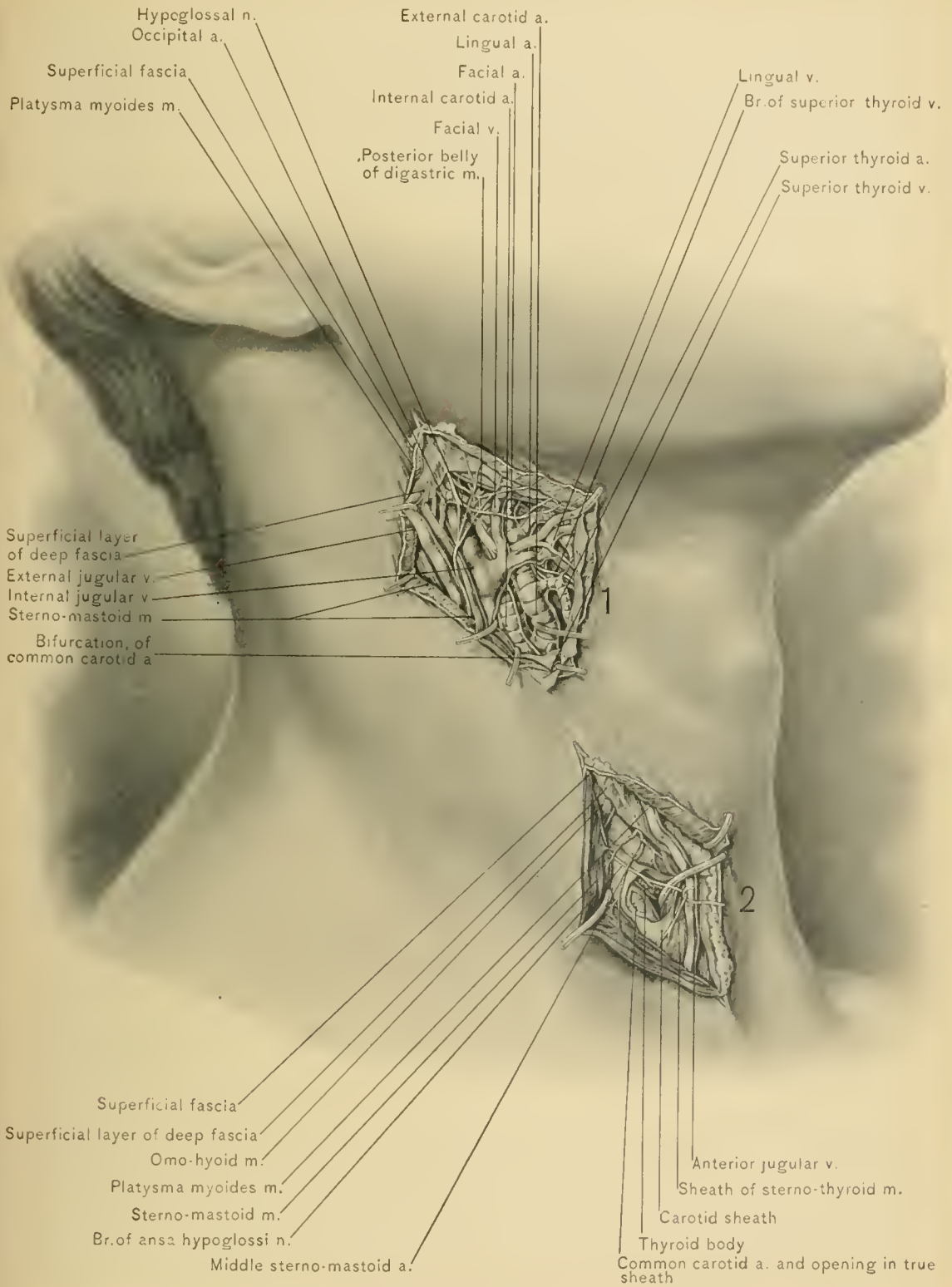
It is usually tied in the superior carotid triangle,—above the anterior belly of the omo-hyoid muscle,—where it is more superficial. In the inferior carotid triangle—below the anterior belly of the omo-hyoid muscle—the artery is deeper, being in this location covered by additional structures, the sterno-hyoid and sterno-thyroid muscles, and overlapped by the lateral lobe of the thyroid gland. The omo-hyoid muscle crosses the artery at the level of the cricoid cartilage, the middle thyroid vein crosses just above that muscle, and the superior thyroid vein and middle sterno-mastoid artery cross the artery higher in the superior carotid triangle.

In the operation through the *superior carotid triangle* the patient should rest upon the back, with the shoulders elevated, the neck extended, and the face turned slightly to the opposite side. The superficial veins should be located, especially the vein which connects the submental veins with the anterior jugular vein and runs beneath the platysma myoides muscle parallel to and along the inner side of the anterior border of the sterno-mastoid muscle. An incision three inches long should be made in the line of the artery, so that the center of the incision will be on a level with the cricoid cartilage. Skin, superficial fascia, platysma myoides muscle, superficial vessels and nerves, and the superficial layer of the deep fascia are divided, the communicating branch between the anterior jugular and sub-





EXPOSURE OF (1) INFERIOR DENTAL NERVE; (2) FACIAL ARTERY; (3, 4) SPINAL ACCESSORY NERVE AND SUPERFICIAL BRANCHES OF CERVICAL PLEXUS; AND (5) COMMON CAROTID ARTERY IN SUPERIOR CAROTID TRIANGLE.



(1) EXPOSURE OF EXTERNAL CAROTID AND INTERNAL CAROTID, AND OF THE SUPERIOR THYROID, LINGUAL, FACIAL, AND OCCIPITAL AT THEIR ORIGIN; AND (?) EXPOSURE OF COMMON CAROTID IN INFERIOR CAROTID TRIANGLE.



mental veins being avoided. The sterno-mastoid muscle should be displaced outward and the omo-hyoid muscle downward, and the pulsations of the artery are felt. The middle sterno-mastoid artery and the superior and middle thyroid veins should be avoided, if possible, and the internal jugular vein and descendens hypoglossi nerve should be avoided by opening the inner wall of the carotid sheath. By holding up first one edge of the opening in the sheath and then the other, the sheath can be gently separated from the artery with an aneurysm needle. The needle should be passed from without inward, threaded, and withdrawn.

To tie the common carotid artery in the *inferior carotid triangle*, the patient should be placed in the same position as for the higher ligation. The incision, which is about three inches in length, should be made along the anterior border of the sterno-mastoid muscle, beginning at the level of the cricoid cartilage, and extending almost to the sterno-clavicular articulation. Skin, superficial fascia, platysma myoides muscle, and superficial vessels and nerves are divided. The anterior jugular vein and the vein which connects it with the facial or submental vein should be avoided. The superficial layer of the deep fascia is divided, and the sterno-mastoid muscle drawn outward, the sterno-hyoid and sterno-thyroid muscles inward. The sheath is opened on the inner side, and the needle passed from without inward. The structures which are to be avoided in the operation are the anterior jugular vein; its tributary, which runs beneath the platysma myoides muscle parallel with the anterior border of the sterno-mastoid muscle; the nerves from the ansa hypoglossi to the sterno-hyoid and sterno-thyroid muscles, the internal jugular vein, the inferior thyroid veins, the inferior thyroid artery, and the recurrent laryngeal nerve. On the left side the internal jugular vein overlaps the artery at the lower part of the neck and renders the operation more difficult.

COLLATERAL CIRCULATION.—The collateral circulation, after ligation of the common carotid artery, is established by the anastomoses of the following arteries:

PROXIMAL SIDE.		DISTAL SIDE.
Branches of the external carotid artery of the opposite side	with	Branches of the external carotid artery of the same side.
Vertebral artery of same side and opposite internal carotid artery and vertebral artery	with	Internal carotid artery of the same side through circle of Willis.
Inferior thyroid artery, thyroidea ima artery (if present)	with	Superior thyroid artery.
Ascending cervical artery		
Superficial cervical artery	with	Princeps cervicis artery.
Deep cervical artery		
Ascending cervical artery	with	Ascending pharyngeal artery.
Vertebral artery	with	Occipital artery.

The tissues supplied by the external carotid artery are chiefly nourished through the anastomoses between the opposite branches of the two external carotid arteries, and the portion of the brain previously nourished by the internal carotid artery receives its blood supply through the two vertebral arteries and the opposite internal carotid artery.

IRREGULARITIES.—The *right common carotid artery*, when the innominate artery is absent, may arise from the arch of the aorta separately or from a trunk common to the two common carotid arteries. When it arises from a trunk common to it and the left common carotid artery, it may cross in front of the trachea above the sternum. Owing to the variability in the level at which the innominate artery bifurcates, the right common carotid artery may arise higher or lower than the upper margin of the right sterno-clavicular joint; its origin is more frequently below that level than above it.

The *left common carotid artery* varies chiefly in its origin from the arch of the aorta. Its place of origin may extend into that of the innominate artery. When the right common carotid artery arises from the arch of the aorta, the two carotid arteries may arise from a common trunk. The left common carotid artery occasionally arises from a left innominate artery.

Either of the common carotid arteries may bifurcate higher or lower than the upper border of the thyroid cartilage. The artery may bifurcate above the level of the hyoid bone, giving off some of the branches which should arise from the external carotid artery. It may not bifurcate, the external carotid or internal carotid artery being absent. The point of bifurcation may be as low as the root of the neck. The common carotid artery may be absent, the external carotid and internal carotid arteries arising from the innominate artery or the arch of the aorta.

The common carotid artery may give origin to the thyroidea ima, vertebral, inferior thyroid, or some of the branches of the external carotid artery. The pneumogastric nerve may lie in front of the common carotid artery.

The **external carotid artery** is ligatured after injury to this vessel or its branches, to check malignant growths, in cirroid aneurysm of its branches, before removal of the parotid gland, and in various other conditions. The artery is usually tied between the points of origin of the lingual and superior thyroid arteries and in the superior carotid triangle, as it is more superficial here, and the distance from the bifurcation of the common carotid artery is sufficient to favor the formation of a clot. Its course is represented by that portion of the line of the common carotid artery which is above the level of the upper border of the thyroid cartilage. In the superior carotid triangle below the posterior belly of the digastric muscle the external carotid artery is covered by skin, super-

ficial fascia, platysma myoides muscle, superficial layer of the deep fascia, anterior border of the sterno-mastoid muscle, and the sheath of the vessels; it is crossed by the hypo-glossal nerve and lingual and facial veins. Higher in its course it is crossed by the stylo-hyoid and posterior belly of the digastric muscle, and enters the parotid gland. To its inner side are the hyoid bone, the pharynx, the superior laryngeal and glosso-pharyngeal nerves, part of the parotid gland, and the ramus of the lower jaw. To its outer side, at its origin, is the internal carotid artery. Behind it are the internal carotid artery, from which it is separated above by the stylo-glossus and stylo-pharyngeus muscles, the glosso-pharyngeal nerve, the pharyngeal branch of the pneumogastric nerve, the stylo-hyoid ligament, and part of the parotid gland. The superior laryngeal nerve is also behind the artery.

The position of the patient should be the same as in ligation of the common carotid artery, the shoulders being elevated, the neck extended, and the face turned slightly to the opposite side. The incision should extend from the angle of the lower jaw downward along the anterior border of the sterno-mastoid muscle for about two and one-half inches, so that the greater cornu of the hyoid bone will be just above the center of the incision. The skin, superficial fascia, platysma myoides muscle, some cutaneous vessels and nerves, and the superficial layer of the deep fascia are divided. The sterno-mastoid muscle is drawn outward, and the greater cornu of the hyoid bone, the hypo-glossal nerve, and lingual and facial veins located. The sheath is opened, and the needle is passed from without inward. The needle should be kept close to the artery, thus avoiding the superior laryngeal nerve, which passes beneath the artery.

COLLATERAL CIRCULATION.—The collateral circulation, after ligation of the external carotid artery, is established by the anastomoses between the branches of this artery and the corresponding branches of the opposite external carotid artery.

IRREGULARITIES.—The external carotid artery may be absent, the branches of that artery arising from the common carotid artery, which continues upward as the internal carotid artery. It may be a short trunk or arise at a higher or lower level than normally. Two or more of its branches—as the superior thyroid, lingual and facial arteries—may arise from it by a common trunk. Some of its lower branches may arise from the common carotid artery. Occasionally it gives origin to additional branches—viz., the superior laryngeal and middle sterno-mastoid branches of the superior thyroid artery, the ascending palatine and tonsillar branches of the facial artery, the superior sterno-mastoid branch of the occipital artery, and the transverse facial branch of the superficial temporal artery.

The **superior thyroid artery** is tied preparatory to removal of one-half of the thyroid body, and may be ligatured to arrest the growth of a goiter. It arises from the external carotid artery just below the greater cornu of the hyoid bone, and runs

forward and then downward and forward along the inner side of the carotid sheath. Its upper portion is superficial, its lower portion being more deeply situated between the larynx and the carotid sheath. The superior laryngeal nerve lies beneath the upper portion of the artery, and its external laryngeal branch runs parallel with the lower part of the vessel. The artery may be tied near its origin and above its hyoid branch, but is preferably ligatured between the origins of the superior laryngeal and middle sterno-mastoid branches.

The patient is placed in the same position as for ligature of the external carotid artery, and an incision two inches long should be made along the anterior border of the sterno-mastoid muscle. The center of the incision should be on a level with the upper border of the thyroid cartilage. Skin, superficial fascia, platysma myoides muscle, and superficial layer of the deep fascia are divided. The sterno-mastoid muscle is drawn outward, and the superior thyroid artery seen running downward along the inner side of the carotid sheath. The artery should be traced from its origin and tied above the origin of the middle sterno-mastoid artery, avoiding the superior thyroid vein. The vein which connects the facial or submental vein with the anterior jugular vein and runs beneath the platysma myoides muscle parallel with the anterior margin of the sterno-mastoid muscle should also be avoided. The needle is preferably passed away from the superior thyroid vein, which usually runs on the lower side of the artery and may form a plexus.

IRREGULARITIES of the superior thyroid artery and of the other branches of the external carotid artery are not of much surgical importance. The superior thyroid artery may be double, or it may be unusually small, the other thyroid arteries being larger than normal. It may arise from the common carotid artery or a trunk common to it and the lingual artery, or a trunk common to the superior thyroid, lingual, and facial arteries. The hyoid, superior laryngeal, and middle sterno-mastoid branches may arise from the external carotid artery. The superior laryngeal artery may be unusually large, occasionally passing through a foramen in the thyroid cartilage, or it may pass along the thyroid cartilage and turn inward under the lower margin of that cartilage. The crico-thyroid artery may be unusually large, and may send a branch downward over the crico-thyroid membrane to the isthmus of the thyroid body. Such an abnormal branch would be divided in laryngotomy and perhaps in high tracheotomy. For this reason it is advisable to thoroughly expose the crico-thyroid membrane before incising it, as the entrance of blood into the larynx might cause broncho-pneumonia.

The **lingual artery** is most frequently ligatured preparatory to removal of the tongue. It is also tied to control hemorrhage from it or its branches in injuries and advanced carcinoma of the tongue, to check the growth of advanced carcinoma of the tongue, and in macroglossia. It arises from the external carotid

artery, opposite the greater cornu of the hyoid bone, and its course, as elsewhere described, is divided into three portions :

The *first portion* extends from the origin of the artery to the outer border of the hyo-glossus muscle. It ascends to reach the upper border of the greater cornu of the hyoid bone, and then runs just above and parallel with that cornu. This is the most superficial portion of the artery. It is covered by skin, superficial fascia, platysma myoides muscle, and superficial layer of the deep fascia, and is crossed by the hypo-glossal nerve, lingual vein, and digastric and stylo-hyoid muscles. This portion of the vessel rests upon the middle constrictor muscle of the pharynx and the superior laryngeal nerve.

The *second portion* runs along the upper border of the hyoid bone beneath the hyo-glossus muscle, lingual vein, hypo-glossal nerve, digastric and stylo-hyoid muscles, submaxillary gland, superficial layer of the deep fascia, platysma myoides muscle, and superficial fascia and skin.

It rests here upon the middle constrictor muscles of the pharynx and the genio-hyo-glossus muscle. This portion is the point of election in ligation of the artery.

The *third portion* ascends between the hyo-glossus and genio-hyo-glossus muscles, pierces the latter muscle, and runs between it and the lingualis muscle in the under surface of the tongue as far as the tip of that organ.

To ligature the lingual artery in its second portion, or point of election, the patient should be placed in the same position as for ligature of the common and external carotid arteries, and the lower jaw drawn upward. The incision extends from the anterior border of the sterno-mastoid muscle forward along the upper border of the greater cornu of the hyoid bone. The skin, superficial fascia, platysma myoides muscle, branches of the facial and anterior jugular veins, and the superficial layer of the deep fascia are divided. The submaxillary gland is displaced and held well upward on the lower jaw, and the process of deep fascia beneath the gland divided. The tendon and bellies of the digastric muscle, the stylo-hyoid muscle, the hypo-glossal nerve, the lingual vein (which is just below the nerve), the mylo-hyoid and the hyo-glossus muscle, will be exposed. The stylo-hyoid muscle and the tendon of the digastric muscle are drawn downward, the lingual vein and hypo-glossal nerve upward, and an incision one-half of an inch long should be carefully made through the hyo-glossus muscle just above the hyoid bone. If the incision through the hyo-glossus muscle is accurately made, the artery will project into the wound. The aneurysm needle is passed around the artery, and may include the venæ comites. The submaxillary gland should not be injured, as this accident would probably give rise to a salivary fistula. To avoid the danger of opening the pharynx when incising the hyo-

glossus muscle care is required. Instead of dividing the hyo-glossus muscle, the artery may be ligatured immediately before it passes under the outer border of that muscle.

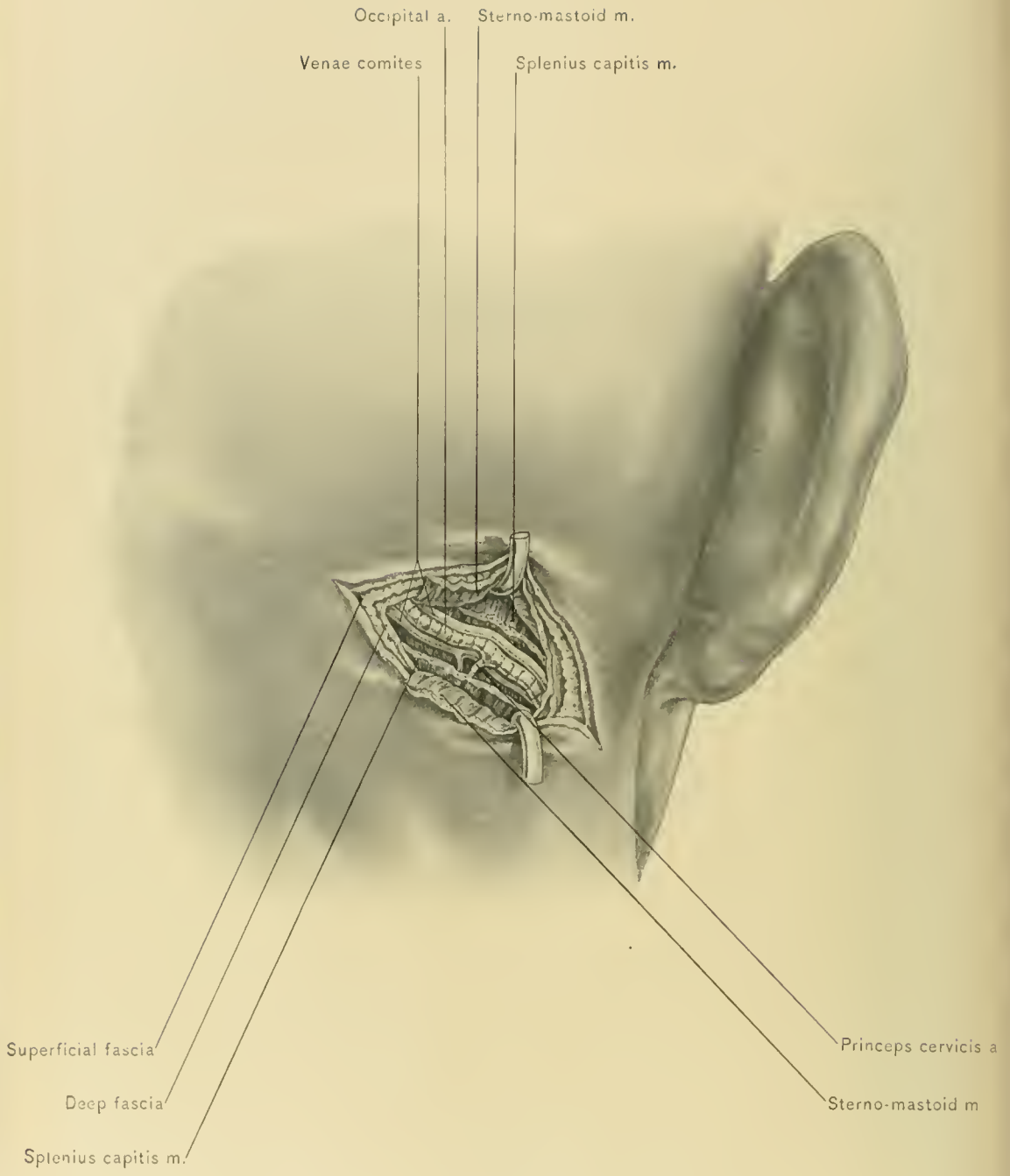
The *first portion* of the lingual artery is reached through an incision one inch long, carried from the sterno-mastoid muscle forward along the upper border of the greater cornu of the hyoid bone. The position of the patient should be the same as that for the foregoing operation. Skin, superficial fascia, platysma myoides muscle, and superficial layer of the deep fascia are divided. The submaxillary gland is displaced upward, and the process of deep fascia beneath the gland divided. The lingual vein and hypo-glossal nerve are exposed and drawn upward, and the artery secured as it passes under the posterior margin of the hyo-glossus muscle. This operation is more difficult than ligature of the second portion of the vessel; this is due to the fact that the lingual vein, hypo-glossal nerve, stylo-hyoid muscle, and posterior belly of the digastric muscle lie in front of the artery. This portion of the artery may be secured at its origin through an incision two inches long, made along the anterior border of the sterno-mastoid muscle. The center of the incision should be opposite the greater cornu of the hyoid bone. The location of the external carotid artery is ascertained, as described under ligature of that vessel, and the origin of the lingual artery located opposite the greater cornu of the hyoid bone. The hypo-glossal nerve and lingual and facial veins must be avoided.

IRREGULARITIES.—The most common irregularities of the lingual artery are the following: It may arise from a trunk common to it and the facial artery, or from a trunk common to the superior thyroid, lingual, and facial arteries. It may pierce the hyo-glossus muscle. Occasionally it is given off as a branch of the facial or internal maxillary artery. Its sublingual branch may arise from the facial artery, and the hyoid branch may be absent.

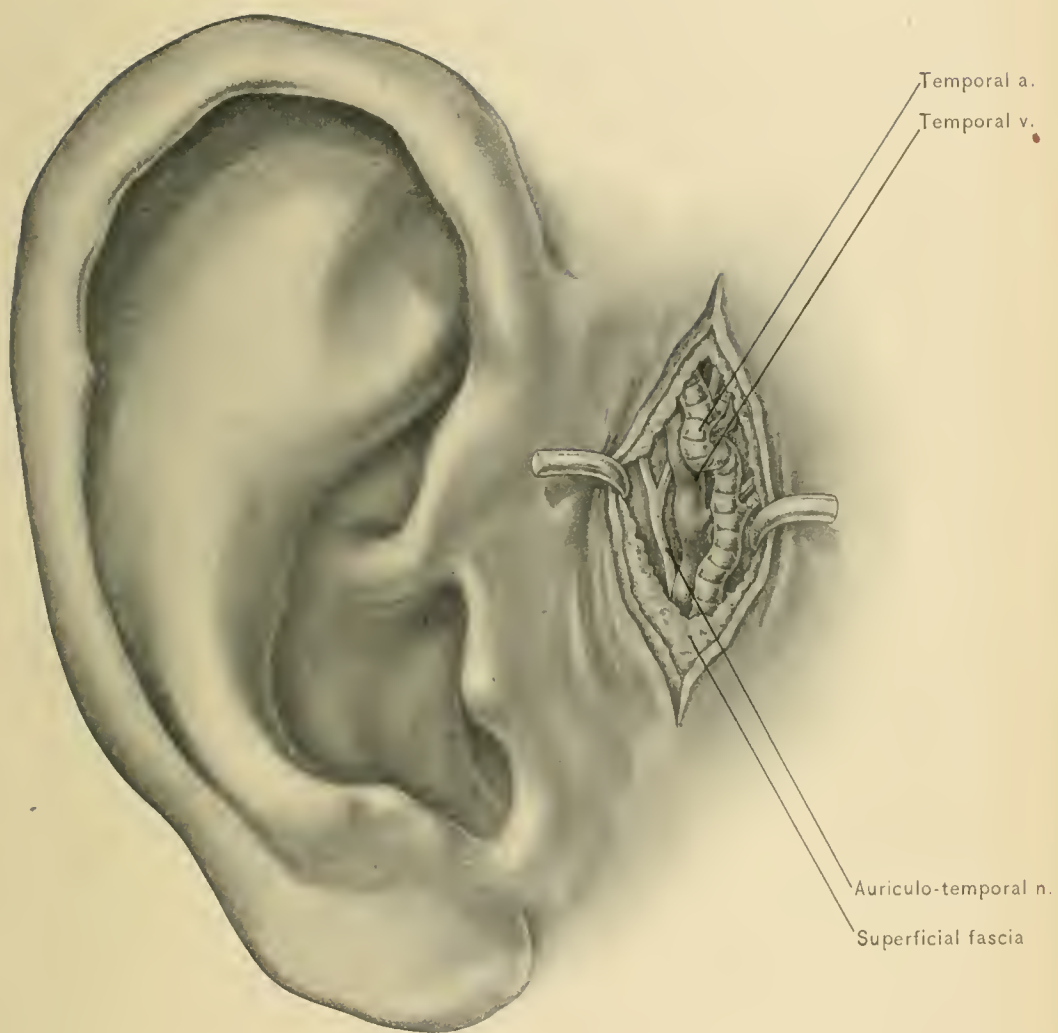
The **facial artery** may be secured at its origin or as it passes over the lower border of the lower jaw at the anterior inferior angle of the masseter muscle. To ligature the facial artery at its origin, which is just above that of the lingual artery, an incision should be made similar to that for ligation of the external carotid artery, except that the center of the incision should be just above the greater cornu of the hyoid bone. The facial and lingual veins, anterior division of the temporo-maxillary vein, and hypo-glossal nerve should be avoided. To tie the artery as it turns over the lower border of the lower jaw, an incision one inch long should be made below and parallel with this border of the jaw, so that the resulting scar will not be prominent. The skin, superficial fascia, platysma myoides muscle, and superficial layer of the deep fascia are divided. As the facial vein is behind the artery, the needle should be passed from behind forward.

IRREGULARITY.—The irregularity of the facial artery which is of importance





EXPOSURE OF OCCIPITAL ARTERY FOR LIGATION.



EXPOSURE OF AURICULO-TEMPORAL NERVE AND TEMPORAL ARTERY.

is the following: It may terminate as the submental artery, its area of distribution in the face being supplied by the nasal branch of the ophthalmic, the transverse facial, or the internal maxillary artery.

The **occipital artery** is ligatured for circoid aneurysm. It may be tied at its origin, or as it passes through the occipital region. To tie it at its origin the shoulders should be elevated, the neck well extended, and an incision made along the upper part of the anterior border of the sterno-mastoid muscle. The origin of the artery will be found by tracing backward over the external carotid artery the hypo-glossal nerve, which winds from behind forward over that portion of the vessel. In the occipital region the artery may be secured through an incision carried obliquely backward and slightly upward from the tip of the mastoid process. The structures divided in the occipital region are the skin, superficial fascia, superficial nerves and vessels, superficial layer of the deep fascia, a portion of the sterno-mastoid muscle, posterior process of the deep fascia (prevertebral fascia), and the splenius capitis muscle. The artery may be readily found in this region, at a point midway between the mastoid process and the external occipital protuberance.

IRREGULARITIES.—The irregularities of the occipital artery which are of importance are the following: It may arise from the internal carotid artery or the ascending cervical branch of the inferior thyroid artery; it may cross over, instead of under, the upper portion of the sterno-mastoid muscle; it may give origin to the posterior auricular or ascending pharyngeal artery.

IRREGULARITIES of the ascending pharyngeal, posterior auricular, superficial temporal, and internal maxillary arteries are not of much surgical importance.

The **superficial temporal artery**, like the occipital, is ligatured in injuries and circoid aneurysm. The artery usually bifurcates into the anterior and posterior temporal one and one-half to two inches above the zygoma, but it frequently divides at a lower level. The artery may be felt pulsating just in front of the pinna of the ear, where it crosses the posterior root of the zygoma; this is the point at which it should be tied. The incision should be vertical, about one inch in length, and be made over the vessel in front of the pinna. The structures divided are the skin, superficial fascia, and deep fascia. The superficial temporal vein lies behind the artery and overlaps it, and the auriculo-temporal nerve emerges from beneath the artery and vein, and then runs behind the vein. The temporal branches of the facial nerve cross the artery and vein in the parotid gland. The needle should be passed from behind forward.

The **internal carotid artery** is rarely ligatured, but may be tied after injury of the vessel and for traumatic aneurysm. The line for this vessel is the same as that for the common carotid artery. Its only accessible and superficial portion

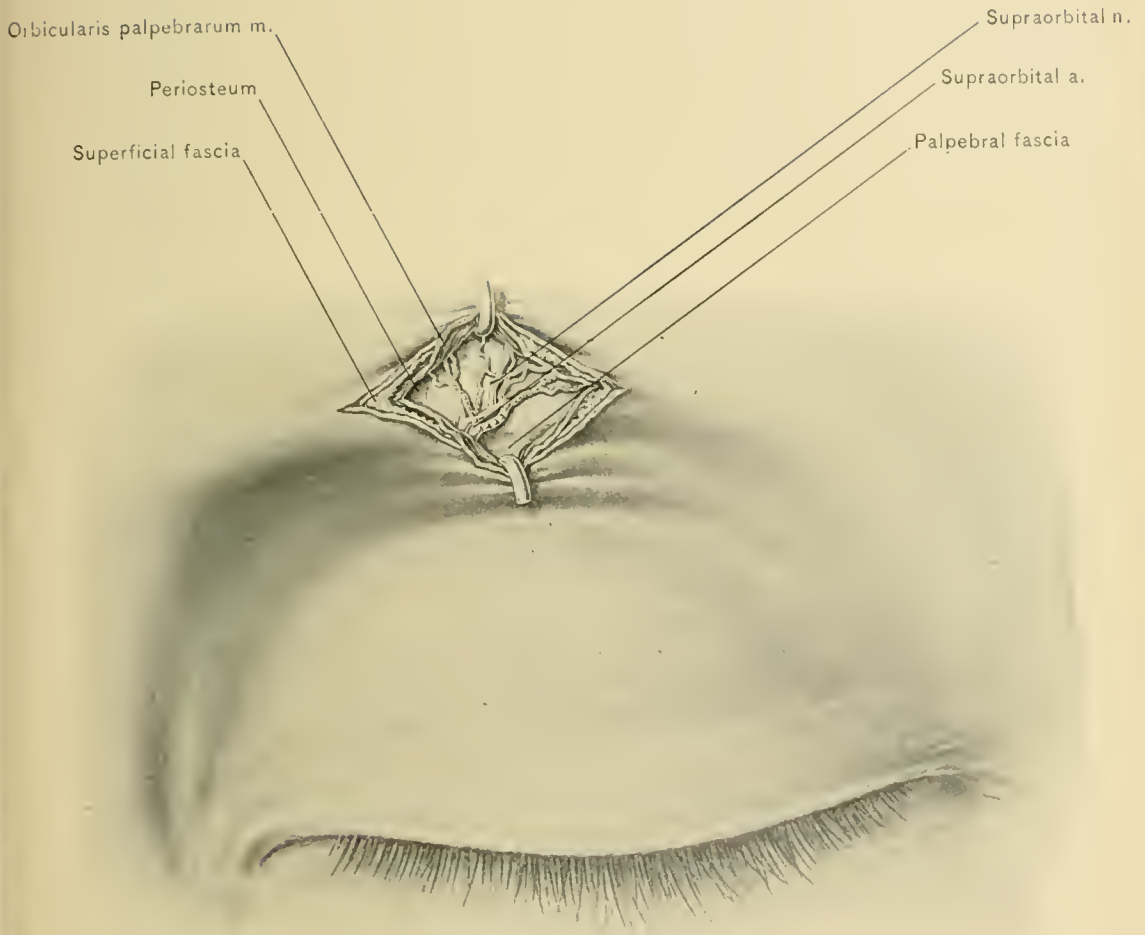
is at its origin, and is about one inch in length. The internal carotid artery begins at the bifurcation of the common carotid artery, which is opposite the upper border of the thyroid cartilage. At first it lies external to and on the same plane as the external carotid artery, but it gradually passes beneath the latter vessel. In front of it in this location are the skin, superficial fascia, platysma myoides muscle, superficial layer of the deep fascia, anterior border of the sterno-mastoid muscle, and the wall of the carotid sheath; behind it are the pneumogastric nerve, prevertebral fascia, superior sympathetic ganglion, and rectus capitis anticus major muscle; to the outer side are the pneumogastric nerve and internal jugular vein; and to the inner side are the external carotid artery, ascending pharyngeal artery, and pharynx. The patient should be placed in the same position as for ligation of the common carotid artery. An incision three inches long is made over the anterior border of the sterno-mastoid muscle, the center of the incision being slightly above the level of the upper border of the thyroid cartilage. Skin, superficial fascia, platysma myoides muscle, and superficial layer of the deep fascia are divided. The sterno-mastoid muscle is drawn outward, the posterior belly of the digastric muscle upward, the external carotid artery inward, and the internal carotid artery outward. The anterior wall of the sheath of the artery should be carefully opened, and the needle passed from without inward, away from the internal jugular vein and pneumogastric nerve. In many cases the facial and lingual veins cross the internal carotid artery to empty into the internal jugular vein.

COLLATERAL CIRCULATION.—The collateral circulation is established by the anastomosis of the vertebral arteries and opposite internal carotid with the ligatured artery through the circle of Willis.

IRREGULARITIES.—The irregularities of the internal carotid artery which are of importance are the following: It may arise from the arch of the aorta or the innominate artery; its cervical portion may be tortuous; it may give origin to the occipital artery.

OPERATIONS UPON NERVES OF HEAD AND NECK.

The **supra-orbital nerve** is exposed at the supra-orbital notch or foramen, which is located at the junction of the middle one-third with the inner one-third of the supra-orbital margin. The eyelid is drawn downward and the eyebrow held steady while a transverse incision is made along the supra-orbital margin. The incision is one-half to three-fourths of an inch in length and divides skin, superficial fascia, and orbicularis palpebrarum muscle. The nerve is now



EXPOSURE OF SUPRAORBITAL ARTERY AND NERVE.

exposed, the supra-orbital vessels being on its outer side. The palpebral fascia is divided, the orbital fat depressed, and the nerve traced into the orbit as far as possible, so that the frontal nerve may be reached and divided just before it bifurcates into the supra-orbital and supra-trochlear nerves. About an inch of the supra-orbital nerve is resected. The supra-orbital vessels may be injured. The supra-orbital artery may be ligated through the same incision. •

The **infra-orbital nerve** may be resected through an incision three-fourths of an inch long, made about one-fourth to three-eighths of an inch below, and parallel with, the infra-orbital margin, so that its center will lie over the infra-orbital foramen, which is situated in a line drawn from the supra-orbital notch to the second bicuspid tooth of the upper jaw, and between one-fourth and three-eighths of an inch below the infra-orbital margin. The skin, superficial fascia, orbicularis palpebrarum muscle, and levator labii superioris muscle are divided, the nerve is drawn out of the foramen, and as much as possible resected.

The **superior maxillary nerve** is resected in the sphenomaxillary fossa by way of the antrum of Highmore, or through an incision at the side of the face. These operations are described in volume 1, page 563.

The **Gasserian ganglion** is removed through an osteo-plastic resection of the temporal region, or by way of the pterygo-maxillary region. (See Vol. 1, page 595.)

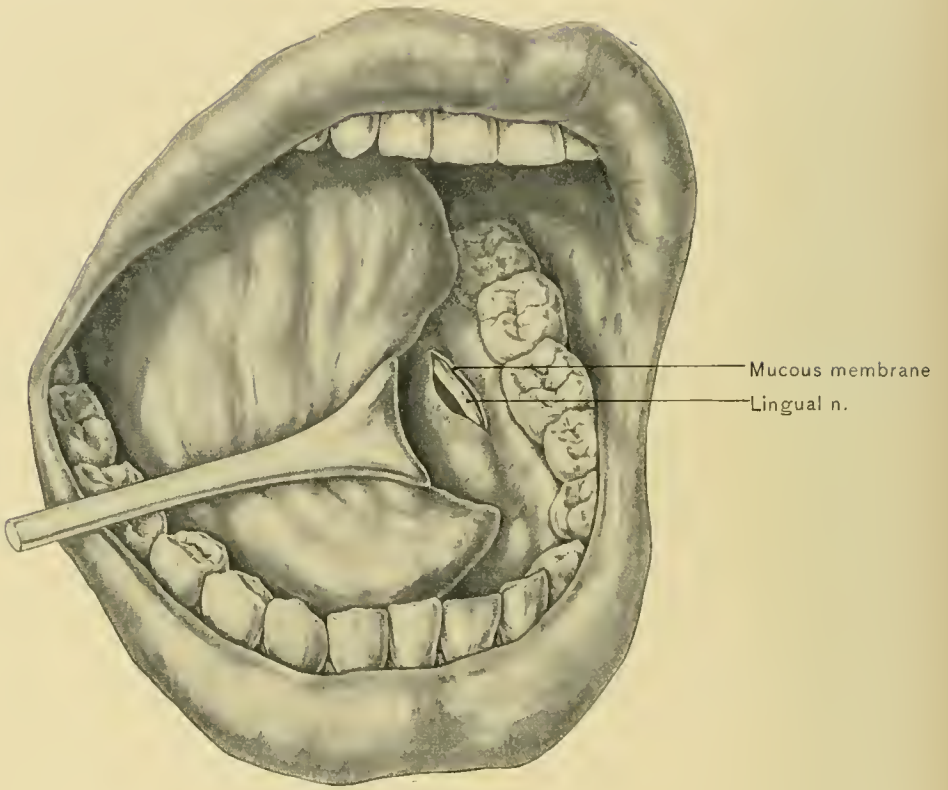
The **inferior maxillary nerve** is exposed at its exit from the foramen ovale. The reflected flap is square, its attached margin being below. Two vertical incisions are made, parallel with the margins of the ramus of the lower jaw, and extend from the level of the upper margin of the zygoma to half way down the ramus; the upper extremities of the incisions are connected by a transverse incision. The skin and superficial fascia are divided, the zygoma is sawed at each end, the temporal fascia and the masseteric fascia are divided, the zygoma and the masseter muscle are displaced downward, and the masseteric vessels and nerve are severed. Care is required to avoid injuring Stenson's duct and some of the large branches of the facial nerve which are at the attached margin of the flap. The coronoid process of the lower jaw is divided and reflected upward with the temporal muscle; and the upper head of the external pterygoid muscle is separated from the pterygoid ridge of the sphenoid bone and displaced downward. The nerve can then be exposed at the foramen ovale and divided with scissors. The small meningeal artery is necessarily divided with the nerve. The foramen ovale is situated about one-fourth of an inch in front of the spine of the sphenoid bone, just behind the base of the external pterygoid plate, and in a transverse line passing through the eminentia articularis of the temporal bone. This operation is hardly justifiable on account of the number of important tissues injured, the resulting paralysis of the muscles of mastication and of the mylo-hyoid muscle

and anterior belly of the digastric muscle, the partial loss of power in moving the lower jaw, and the dangers of infection and suppuration in so inaccessible a region as the pterygo-maxillary space.

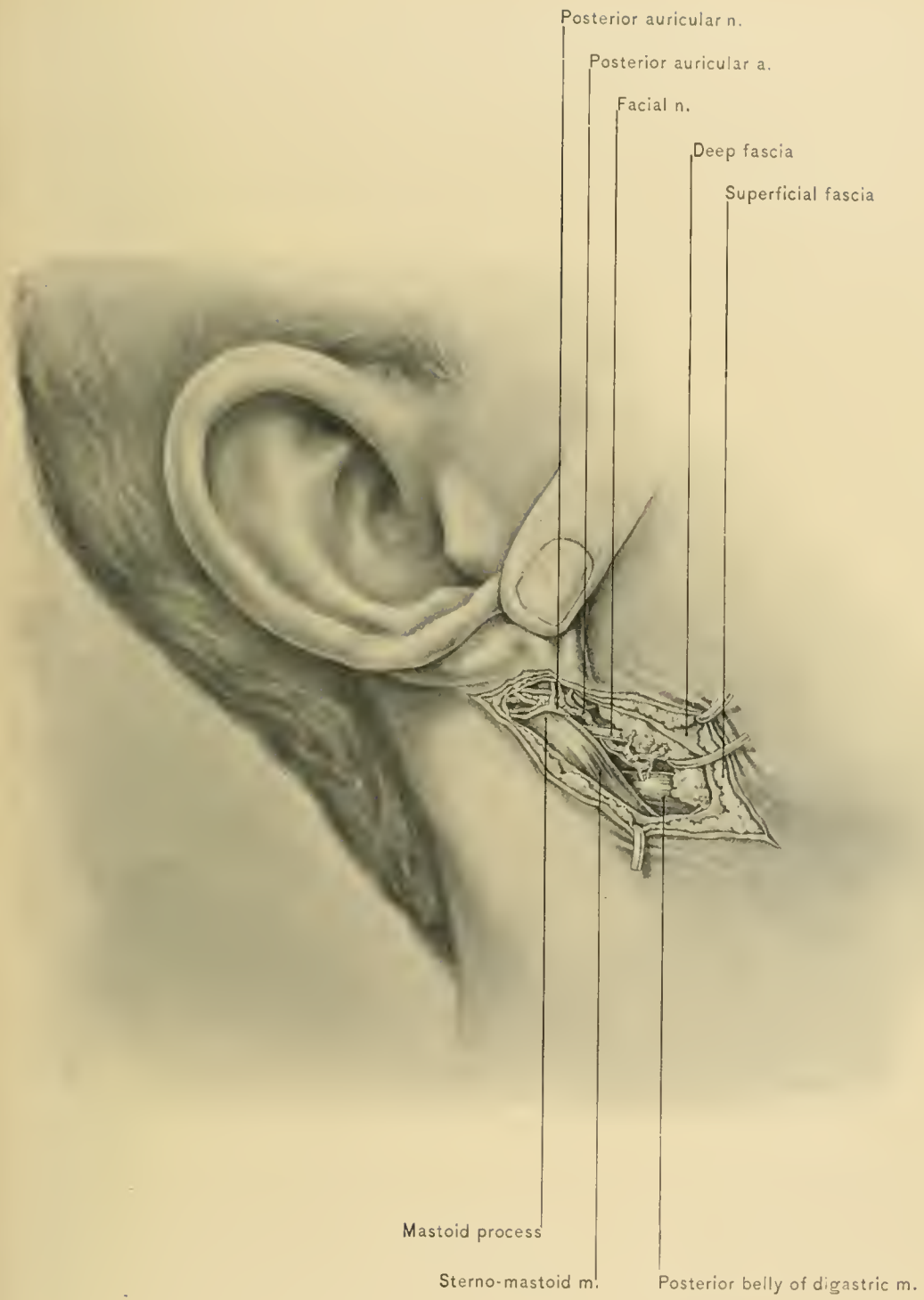The **inferior dental nerve** may be resected at the mental foramen, in the inferior dental canal, or before it enters that canal. It is preferably resected before it enters the inferior dental canal, in order that all the dental and gingival fibers of the nerve can be included. This portion of the nerve can be reached by an incision through the cheek or through the mucous membrane of the mouth. The external incision is preferable because asepsis is an impossibility in wounds of the mouth, the external method is more easily performed, and the incision can be so located that the scar will not be prominent. The incision in the external method is angular and made along the posterior border of the ramus to the angle of the lower jaw, and thence forward along the lower border of the lower jaw, each limb of the incision being about one inch in length. Only the skin and superficial fascia are divided in the first stage of the operation. Next divide the masseteric fascia and the platysma myoides muscle, exercising care to avoid injuring the buccal and supra-maxillary branches of the facial nerve and the parotid gland. The lower limb of the incision should not extend far enough forward to divide the facial artery or vein. The lower portion of the masseter muscle is separated from the ramus of the lower jaw with the periosteal elevator and the knife, and displaced upward. A small trephine is applied to the ramus midway between its anterior and posterior borders, and just above the level of the alveolar margin of the lower jaw. The trephine first divides the upper and thinner portion of the circle of bone; the remainder of the incision through the bone must be completed with the chisel and elevator, so that the inferior dental vessels will not be injured. The inferior dental vessels and nerve are detected lying upon the internal lateral ligament of the lower jaw. The nerve is separated from the vessels, drawn out with a blunt hook, and as much of it as possible resected.

In *neurectomy of the inferior dental nerve* through the mouth, the upper teeth are widely separated from the lower with a gag, and a vertical incision about an inch long is made through the mucous membrane along the inner margin of the anterior border of the ramus of the lower jaw. The anterior margin of the ramus is exposed, and the mucous membrane is separated from the ramus with a small periosteal elevator. The lingual nerve is seen, the separation is extended a short distance further backward, and the spine of bone (spine of Spix) just below the inferior dental foramen is located with the finger. This spine gives attachment to the internal lateral ligament of the lower jaw; this ligament hides from view the inferior dental vessels and nerve which lie between it and the ramus of the lower jaw. The internal lateral ligament is cautiously divided with long, slender scis-





EXPOSURE OF LINGUAL NERVE.



EXPOSURE OF FACIAL NERVE.



sors, and the inferior dental vessels and nerve are exposed at their entrance into the inferior dental canal. The nerve and vessels are gently drawn forward with a small blunt hook and traced upward for about a half inch above their point of entrance into the inferior dental canal. Here the nerve and vessels are not in so close contact and can be separated. The nerve is isolated from the vessels, and about one-fourth or one-half of an inch removed, the upper end of the segment being divided first because of the fact that the upper part of the nerve retracts after being divided. If the nerve and vessels are traced too high, the internal maxillary artery is endangered. The wound in the mucous membrane is not closed.

The **lingual (gustatory) nerve** is divided or a portion of it excised for painful conditions of the tongue, as advanced cancer of that organ. The nerve may be exposed by merely cutting through the mucous membrane of the floor of the mouth near the side of the tongue, and opposite the second molar tooth. The nerve may also be exposed by dividing the mucous membrane about one-half of an inch below and behind the last molar tooth, where the nerve can readily be felt.

The **auriculo-temporal nerve** is exposed where it first lies in relation with the superficial temporal vessels over the posterior root of the zygoma and in front of the pinna of the ear. The incision is the same as that made for ligation of the superficial temporal artery. The nerve is found just to the outer side of the superficial temporal vessels.

The **facial nerve** is stretched for twitching of the muscles of expression, associated with more or less pain (*tic convulsif*). The nerve is secured near the stylo-mastoid foramen, as it lies superficial to the styloid process and above the posterior belly of the digastric muscle.

In this location the trunk of the nerve is found before it gives off the stylohyoid and digastric branches, and before it bifurcates into its two divisions. The posterior auricular nerve arises from it close to the stylo-mastoid foramen. The incision begins behind the pinna of the ear, opposite the external auditory meatus, and is carried behind the lobule of the ear downward and forward to the angle of the lower jaw. A transverse incision may also be made behind the lobule. The skin, superficial fascia, superficial layer of the deep fascia, and branches of the auricularis magnus nerve are divided. The flaps which have been made are now dissected from the parotid gland, sterno-mastoid muscle, and mastoid process, the posterior auricular nerve, vein, and artery being avoided. The parotid gland is separated from the mastoid process, and the trunk of the nerve is found above the posterior belly of the digastric muscle, lying upon the styloid process. The nerve is stretched by lifting it with a blunt hook.

The **spinal accessory nerve** is stretched or divided for spasmodic wryneck. Division or excision of a portion of the nerve offers better results. The nerve is

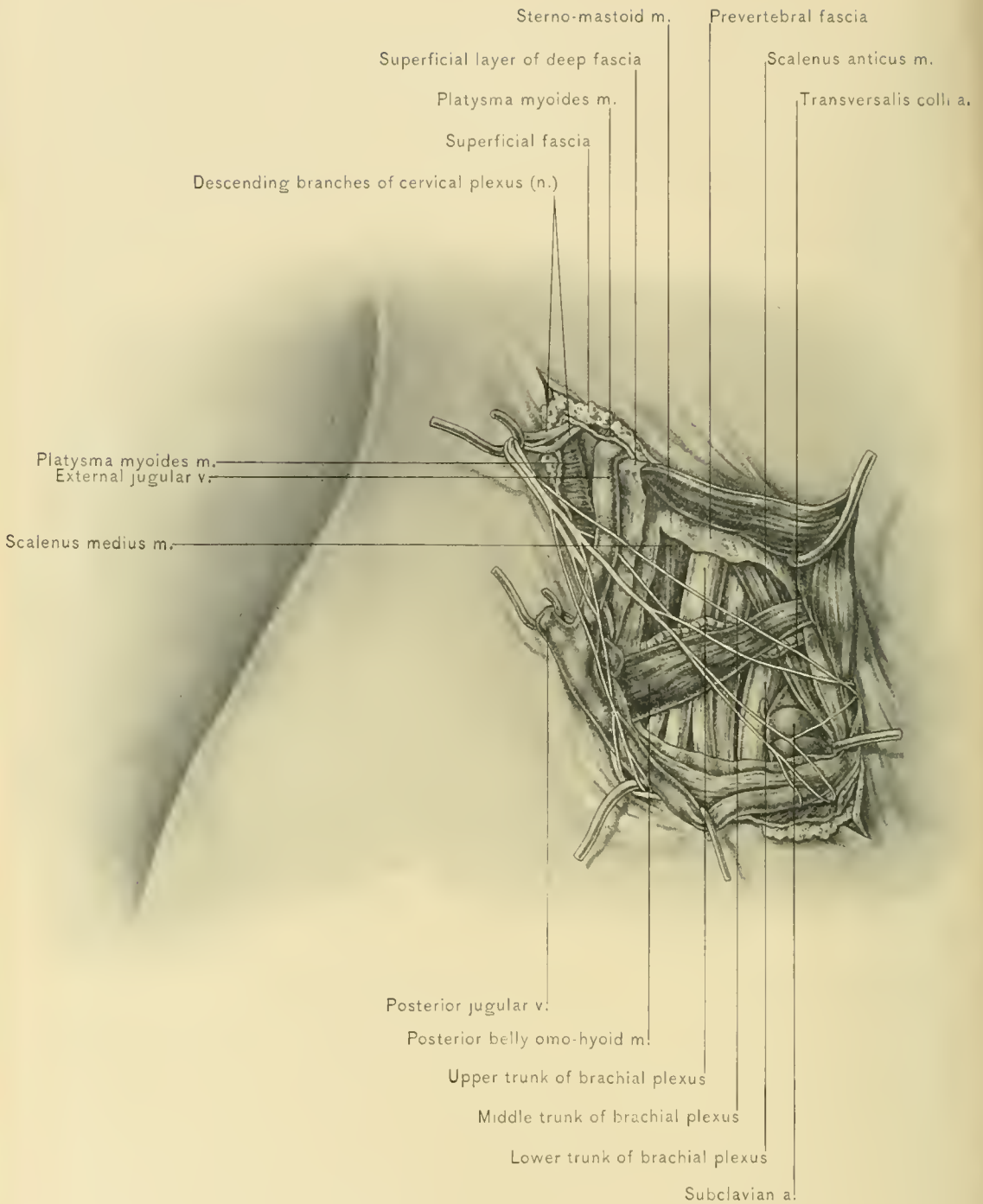
secured at the anterior or at the posterior border of the sterno-mastoid muscle. When it is exposed behind the sterno-mastoid muscle, it should be traced upward and divided above its sterno-mastoid branches. In its course downward from the jugular foramen the nerve runs beneath the internal jugular vein, the occipital artery and posterior belly of the digastric muscle, and enters the under surface of the sterno-mastoid muscle about midway between its two borders and about two inches from the tip of the mastoid process. It emerges from the muscle at about the middle of its posterior border. Between the posterior belly of the digastric muscle and the point where it enters the sterno-mastoid muscle it is accompanied by the superior sterno-mastoid artery.

Before exposing the nerve at the anterior border of the sterno-mastoid muscle the patient is placed on his back, with the shoulders raised and the neck extended. The incision begins at the anterior border of the mastoid process, and is carried downward for two and one-half or three inches along the anterior margin of the sterno-mastoid muscle. The skin, superficial fascia, platysma myoides muscle, a branch of the auricularis magnus nerve, and the deep fascia are divided, the external jugular vein being avoided. The sterno-mastoid muscle is drawn outward, and the nerve, with its accompanying sterno-mastoid artery, can be felt just below the prominent transverse process of the atlas, lying upon the levator anguli scapulæ muscle.

Before exposing the spinal accessory nerve at the posterior border of the sterno-mastoid muscle the shoulders are elevated, the face is turned to the opposite side, and the neck is flexed laterally toward the opposite shoulder. The incision is made along the posterior border of the sterno-mastoid muscle, is two inches in length, and its center is at the middle of that border of the muscle. The skin, superficial fascia, platysma myoides muscle, and the superficial layer of the deep fascia are divided. The small occipital nerve is easily found as it runs along the upper one-half of the posterior border of the sterno-mastoid muscle. This nerve is traced downward to the spinal accessory nerve, with which it forms a loop. The spinal accessory nerve is then traced beneath or through the deeper portion of the sterno-mastoid muscle and divided.

The **superficial branches of the cervical plexus** may be exposed through the same incision as that made at the posterior border of the sterno-mastoid muscle for the spinal accessory nerve. The *auricularis magnus nerve* runs from the middle of the posterior border of the sterno-mastoid muscle toward the pinna. The *occipitalis minor nerve* lies between the superficial layer of the deep fascia and its posterior process (prevertebral fascia), and just behind the upper one-half of the posterior margin of the sterno-mastoid muscle. The *superficial cervical nerve* emerges from under the sterno-mastoid muscle at the middle of its posterior





EXPOSURE OF BRACHIAL PLEXUS OF NERVES.

border, turns downward along that margin for a short distance, and then runs transversely forward. The *descending superficial branch of the cervical plexus*, which divides into the supra-sternal, supra-clavicular, and supra-acromial nerves, is found running along the posterior border of the sterno-mastoid muscle just below the middle of that margin, and usually passes between the sterno-mastoid muscle and the external jugular vein.

The **brachial plexus** may be stretched in the neck external to the scalenus anticus muscle. It emerges from between the scalenus anticus and scalenus medius muscles, and converges toward the apex of the axilla. The patient is placed on the back, with the shoulders elevated, the neck extended, and the face turned to the opposite side. The incision begins about one-half of an inch above the middle of the clavicle. It is carried directly upward for about three inches, and parallel with the posterior margin of the sterno-mastoid muscle. The skin, superficial fascia, and platysma myoides muscle are divided. The external jugular vein, which lies to the inner side of the incision, should be located, and it may be necessary to divide the posterior external jugular or transverse cervical and supra-scapular veins between ligatures. The superficial layer of the deep fascia is next divided. The posterior belly of the omo-hyoid muscle is drawn upward, the transversalis colli artery and the cords of the plexus and the position of the outer border of the scalenus anticus muscle are located with the finger. The posterior process of the deep fascia (pre-vertebral fascia) is divided a short distance external to the scalenus anticus muscle, avoiding the nerve to the subclavius muscle, which runs along the outer border of the scalenus anticus muscle, and the transversalis colli artery, which runs across the upper part of the plexus. The prevertebral fascia is reflected outward. The upper and middle cervical trunks of the plexus are found above the subclavian artery, whereas the lower trunk is overlapped by the upper margin of that artery.

THE MOUTH.

The student should now examine the mouth, the pharynx, the larynx, and the nose. These are attached to the anterior portion of the skull which has been divided previous to the dissection of the prevertebral muscles.

The **mouth** is situated at the commencement of the alimentary canal. It contains the organs of mastication, those of the sense of taste, some of the organs of speech, and it acts as a resonating cavity. The buccal cavity (cavity of the

mouth) is divided into two parts by the teeth and alveolar processes—viz., the vestibule and the mouth proper.

The **Vestibule** is situated between the lips and cheeks externally, and the teeth and gums internally. The walls of the vestibule, except when it is distended, are in contact. In front it opens upon the face at the buccal orifice, and behind the last molar teeth it communicates with the mouth proper, even when the teeth are in contact, so that in tetanus or during treatment of fractures of the lower jaw a patient may be fed liquids through a tube passed from the back part of the vestibule into the mouth proper. Under these circumstances a preferable method of feeding may be through a catheter introduced through the nose.

The **Lips** are composed of the skin, superficial fascia, orbicularis oris muscle and the muscles inserted around it, areolar tissue, and mucous membrane. The first three layers of the lips—skin, superficial fascia, and muscular tissue—have been described with the face. The margins of the lips are covered with dry, red mucous membrane, which is continuous with the skin, and contains numerous vascular papillæ and touch corpuscles. Internally, the mucous membrane is reflected from the upper and lower lips upon the gums, and in the median line forms two folds—the frænum labii superioris and frænum labii inferioris. Along the line of junction of the skin and mucous membrane “fever blister,” or herpes labialis, is very common. Through cicatricial contraction after burns of the lips and cheeks the buccal orifice may be much distorted. The deformity can be lessened, if not corrected, by plastic operation. The areolar tissue, or submucous layer, contains the coronary vessels, branches of the infra-orbital and mental nerves, and the labial glands. The coronary vessels completely encircle the buccal orifice near the free margin of the lips, lying immediately superficial to the mucous membrane in the submucous layer.

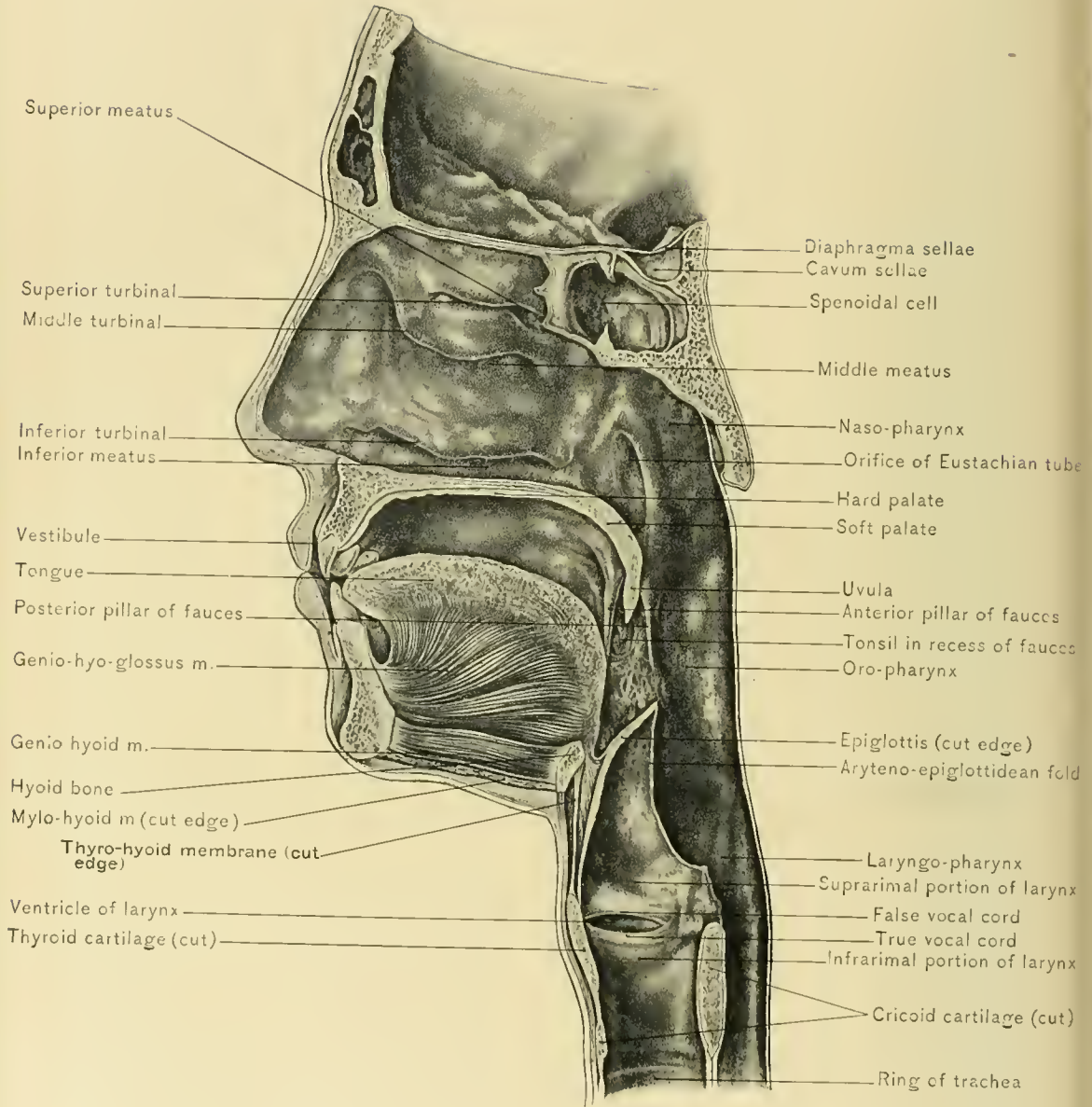
The **labial glands** are situated around the orifice of the mouth, in the submucous layer of the lips. They are small lobulated bodies, about the size of a small pea, and their ducts open into the mouth. They secrete a mucous fluid. When the ducts of these glands become occluded, mucous retention cysts develop.

Between the lips is the **buccal orifice**, which extends between the **angles of the mouth**.

In harelip operations and after excision of a large segment of the lip in removing an epithelioma, the mobility and elasticity of the lips, particularly of the lower lip, allow approximation of the edges of the wound.

The **lymphatics** from the median portion of the lower lip pass to a lymphatic gland situated just above the body of the hyoid bone; those from the lateral portions pass to the submaxillary lymphatic glands, into which the lymphatics of the upper lip also empty.





VERTICAL SECTION OF MOUTH, PHARYNX, LARYNX, AND NOSE.

The operation which is frequently performed upon the upper lip is for correction of **harelip** which occurs upon one side, opposite the interval between the canine and lateral incisor teeth and not in the median line, because the central portion of the lip with the premaxillary bone is formed by the fronto-nasal process of the fetus, whereas each lateral portion of the upper lip develops from the maxillary process of the superior visceral arch. The lower lip is rarely operated upon except for extirpation of epitheliomata. These operations leave a V-shaped wound, which is closed by pins or sutures. The arteries divided are the superior coronary or inferior coronary arteries. During the operation hemorrhage may be checked by an assistant grasping the lip at the angles of the mouth, between the thumbs and index fingers. In closing the wound the arteries are occluded by pressure of one of the pins or sutures. The pin or suture is carried through the tissues of the lip to the mucous membrane and under the artery, then under the artery at the opposite side of the wound, and outward through the tissues of the lip. The lower lip is occasionally the site of nevus or hypertrophy. Neurotic edema of the lower lip, a condition seldom seen, and for which operation is of no avail, must not be mistaken for hypertrophy of the lower lip.

The **Cheeks** are composed of five layers: the skin, the superficial fascia (which contains the facial vessels and some branches of the facial and trifacial nerves), the bucco-pharyngeal fascia, the buccinator muscle, the submucous areolar tissues, and the mucous membrane.

The **bucco-pharyngeal fascia** covers the buccinator muscle, and is continued backward over the constrictor muscles of the pharynx. The submucous areolar tissue contains the **buccal glands**, which resemble the labial glands. Two or three glands larger than the others are situated between the buccinator muscle and its fascial covering. They are called **molar glands**, and their ducts open into the vestibule of the mouth opposite the last molar tooth. Opposite the crown of the second molar tooth of the upper jaw is the papilla, which marks the orifice of Stenson's duct.

The **Mouth Proper** is bounded in front and at the sides by the teeth and gums. Its roof is formed by the hard and the soft palate, and its floor by the mucous membrane of the mouth, a large portion of the tongue, and the mylo-hyoid and genio-hyoid muscles. Behind, it opens into the pharynx at the **isthmus of the fauces**. When the mouth is closed, the tongue lies in contact with the palate and almost fills the mouth proper.

The **Teeth** in the human subject appear as two sets: The *first or temporary set* is present in children, and numbers ten in each jaw—viz., four incisors, two canines, and four molars. The central incisors are the first to pierce the gum, and make their appearance at the seventh month. The lateral incisors soon follow, the last

of the set to appear being the posterior molars, the eruption of which should occur in the third year or the latter half of the second year. The *second or permanent set* are sixteen in number in each jaw—viz., four incisors, two canines, four bicuspids or premolars, and six molars. The first molars appear in the seventh year; the middle incisors and then the lateral incisors soon follow. The third molars, or wisdom teeth, are the last to pierce the gums, usually at the seventeenth or eighteenth year. When a child is affected by congenital syphilis, faulty nutrition affects the development of the permanent teeth, so that they are not perfectly formed. These syphilitic teeth are uneven, and have a contracted and a crescentically notched cutting edge. The central incisors are the most typical, and are the “test teeth of Hutcheson.”

When the mouth is wide open, a ridge produced by the pterygo-maxillary ligament may be seen ascending from just behind the last molar tooth to the hamular process of the internal pterygoid plate of the sphenoid bone. The hamular process may be felt as a resisting prominence a short distance behind and slightly internal to the upper last molar tooth. It is the guide in division of the tensor palati and levator palati muscles.

The **Gums** cover the alveolar processes of the jaws and firmly surround the necks of the teeth. They are composed of dense vascular connective tissue, covered by mucous membrane. The periosteum of the alveolar processes is continued into the alveoli, forming the lining membrane of these cavities. Pus at the root of a tooth may work its way into the gum, producing a “gum boil.”

In chronic lead poisoning a blue line appears upon the dental margin of the gums, and is produced by lead sulphid, which is formed by chemic combination between lead in the tissues and hydrogen sulphid derived from decomposing food.

Swelling of the gums and tenderness of the teeth during the administration of mercury indicate that the physiologic limit for that remedy has been reached, and that the dose should be decreased or the drug temporarily withdrawn.

The swollen and readily bleeding gums in scurvy assist in the diagnosis of that disease.

The **Hard Palate** is composed of the palate or horizontal processes of the superior maxillary and palate bones, clothed on their inferior surface by a dense, tough muco-periosteum. In the operation for cleft palate the toughness and density of the muco-periosteum render its manipulation more difficult. The muco-periosteum contains a median raphe, which marks the line of junction of the two halves. When these two halves fail to unite, cleft palate results. This malformation is often associated with harelip.

BLOOD SUPPLY.—The hard palate is supplied by the naso-palatine and posterior palatine vessels.

The posterior or descending palatine arteries furnish nearly all the nutrition of the hard palate, and lie in the mucéo-periosteum near the alveolar processes. The incision into the mucéo-periosteum in the operation for cleft of the hard palate should be made near and parallel with the alveolar processes, so that the descending palatine arteries need not be divided and may be retained in the flaps to provide for their nutrition. In dissecting up the flaps the operator should follow the bone closely, as these arteries run nearer to the bone than to the free surface of the mucéo-periosteum. Bleeding from the posterior palatine artery may be checked by plugging the posterior palatine canal, which can be located to the inner side of the last molar tooth with a sharp probe.

NERVE SUPPLY.—From the naso-palatine and great or anterior palatine nerves.

Cleft palate, as previously stated, occurs only in the median line. The cleft may affect only the uvula and soft palate, or it may extend forward through the hard palate to the anterior palatine foramen. If the cleft extend forward beyond this foramen, it leaves the median line and follows the line of the suture at the side of the premaxillary bone, the anterior extremity of the cleft being between the lateral incisor and the canine tooth. If the cleft follow one suture, single harelip is usually present, and if it traverse both sutures, double harelip usually exists and the premaxillary bone is suspended by the vomer. In the operation for the correction of double harelip with projection of the premaxillary bone, the author advises that the attachments of this bone be loosened and the bone be pushed back in place and not removed.

The **Soft Palate** is described with the pharynx.

The **Mucous Membrane** in the floor of the mouth covers the tongue, a small area on each side of that organ, and the triangular area beneath its tip or free end. In the median line, as the mucous membrane is reflected upon the under surface of the tongue, it forms a fold—the **frænum linguæ**. In some infants the frænum linguæ is so short that it interferes with sucking, and later prevents distinct articulation. To relieve these cases it is necessary to divide the frenum by snipping its free margin with blunt scissors close to the floor of the mouth and then tearing it. This method is adopted to avoid division of the artery of the frenum, with consequent annoying hemorrhage. On each side of the frenum are the small papillæ, which contain the orifices of Wharton's ducts. The rounded elevation on each side of the lingual frenum is produced by the sublingual glands, which lie immediately beneath the mucous membrane. The orifices of the ducts of Rivini are situated upon these elevations. In the floor of the mouth, opposite the second molar tooth, the lingual nerve may be felt and divided to relieve pain in the tongue; when the tongue is drawn out of the mouth

and toward the opposite side, a ridge in the mucous membrane of the floor of the mouth, produced by this nerve, is seen extending forward from the inner side of the last molar tooth.

A cystic tumor in the floor of the mouth due to occlusion of the orifice of Wharton's duct, one of the ducts of Rivini, or the duct of a mucous follicle, is called a *ranula*.

The *sublingual bursa*, according to Tillaux, is found immediately beneath the mucous membrane of the anterior part of the floor of the mouth, where the mucous membrane is reflected upon the posterior surface of the lower jaw. This bursa is affected in acute ranula.

The **Tongue** is a freely movable, muscular organ, covered with mucous membrane. It contains the organs of the special sense of taste, and is an important accessory in the functions of mastication, deglutition, and speech.

The mucous membrane covers all the free surface of the tongue—*i. e.*, the dorsum, sides, and less than the anterior one-third of the under surface of the organ.

The tongue has a tip, a base, a dorsum, and two sides.

The **tip or apex of the tongue** is its most movable portion, and is covered on both its upper and lower surface by mucous membrane. Its range of motion is influenced by the length of the frænum linguae. A short frenum causes tongue-tie, and a long one allows the tongue to fall backward.

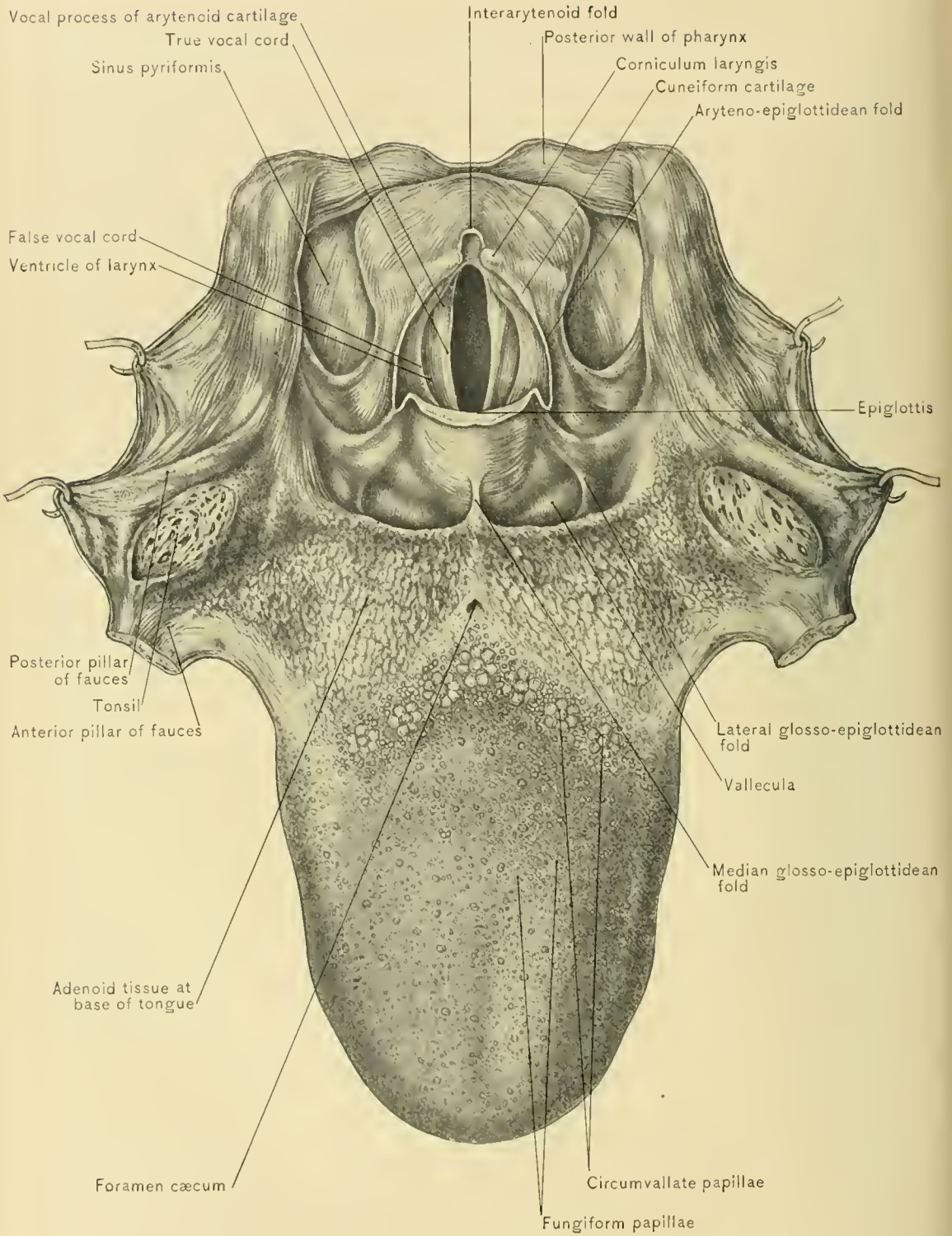
The **base or root of the tongue** is its least movable portion. It is attached to the hyoid bone by muscular tissue and by a fibrous membrane (*hypo-glossal membrane*); to the anterior portion of the lower jaw, at the side of the symphysis, by the genio-hyo-glossus muscle; and to the epiglottis, by the three glosso-epiglottidean folds of mucous membrane.

The **median glosso-epiglottidean fold** is sharply outlined, and has been called the **frænum epiglottidis**. The **lateral glosso-epiglottidean folds** are rounded and indistinct. Between the median and the lateral folds are the **glosso-epiglottidean pouches or valleculæ**, in which small foreign bodies may lodge and cause much discomfort.

The **dorsum of the tongue** is convex and grooved in the median line, forming a raphe from which a septum dips down between the muscles of the two sides. The raphe terminates behind at the **foramen cæcum**, which is the orifice of the obliterated thyro-glossal duct. In the fetus the **thyro-glossal duct** extends from the middle lobe of the thyroid gland to the tongue. It can seldom be traced in the adult. The posterior one-third of the dorsum of the tongue dips downward in front of the pharynx almost to the level of the hyoid bone, and overhangs the epiglottis. It presents no papillæ, but has a somewhat uneven surface, produced



PLATE XLIX.



SUPERIOR APERTURE OF LARYNX AND DORSUM OF TONGUE.

by the irregular collection of lymphoid tissue, known as the *lingual tonsil*. When the lingual tonsil is much enlarged, it may depress the epiglottis and cause difficult respiration. On the anterior two-thirds of the dorsum of the tongue the mucous membrane contains numerous papillæ, which are of three varieties: filiform, fungiform, and circumvallate.

The **filiform papillæ** are the smallest and most numerous. They are long, slender, conic, and branched at their free ends. Fur on the tongue, or coated tongue, is due to increase in the thickness of the epithelium upon these papillæ. Fur on the tongue is present in indigestion, constipation, high fever, contagious and infectious diseases, when large abscesses are present, or in the various forms of ptomain poisoning.

The **fungiform papillæ** are more numerous than the circumvallate papillæ. They resemble small knobs, and are the red spots best observed on the sides and anterior portion of the dorsum of the tongue.

The **circumvallate papillæ**, numbering from eight to twelve, are situated at the junction of the posterior with the middle one-third of the dorsum of the tongue. They form a letter V, its apex being directed backward toward the foramen cæcum. They are surrounded by an elevated margin or *vallum*, so that the papillæ rest in pits. They contain the special taste organs.

On the **sides of the tongue** the mucous membrane is smooth, except at the posterior part, just in front of the attachment of the anterior pillars of the fauces, where there are several parallel folds, known as the papillæ foliata. The **papillæ foliata** are best developed in some of the lower animals, and contain taste organs.

The **under surface of the tongue**, behind, receives the insertion of its extrinsic muscles, but in front it is free and covered by smooth, thin mucous membrane, through which the commencement of the lingual vein can be seen on each side of the median line. These veins are so superficial that they may be injured in division of the lingual frenum for tongue-tie.

The **glands of the tongue** are found in the mucous membrane of the posterior third of the dorsum and at the sides of the organ. They are most numerous around the circumvallate papillæ. Those in relation with the taste buds secrete a serous, and the others a mucous, fluid. Embedded in the substance of the lower surface of the tongue, near the tip of the organ, is a collection of mucous glands, about the size of a pea; this is the so-called gland of Nuhn or Blandin; occlusion of the duct of these glands may cause the formation of a retention cyst.

DISSECTION.—To study the arrangement of the muscles of the tongue it is necessary to remove the mucous membrane from one side of it.

The **muscles of the tongue** compose the greater part of its mass, and are divided into an extrinsic and an intrinsic group. The *extrinsic muscles* are the

stylo-glossus, hyo-glossus, a small portion of the superior constrictor muscle of the pharynx, palato-glossus, and genio-hyo-glossus.

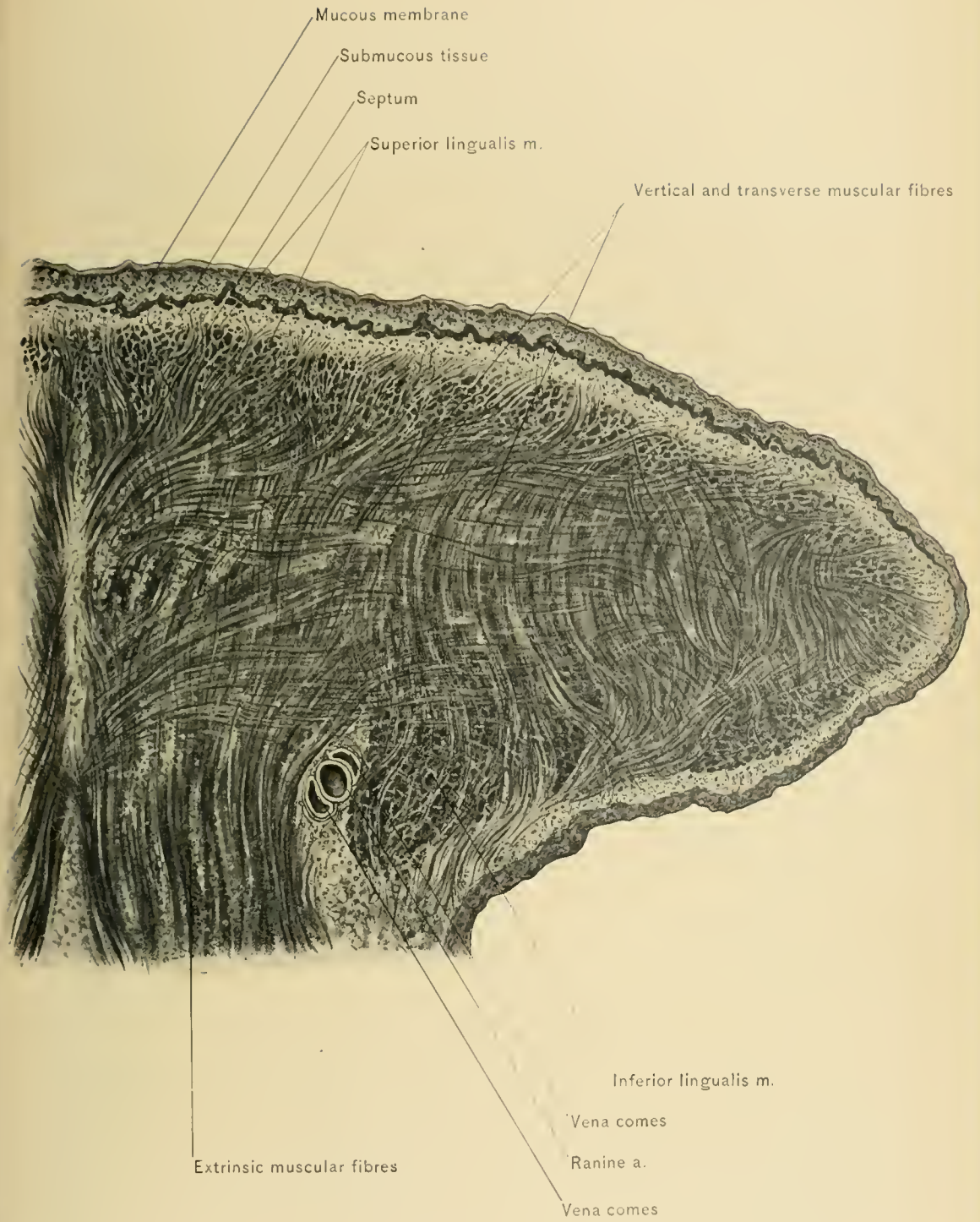
The stylo-glossus muscle runs along the side of the tongue to its tip. The hyo-glossus muscle is inserted internal to the stylo-glossus muscle. The superior constrictor muscle of the pharynx is seen arising from the side of the base of the tongue. The palato-glossus muscle is continuous with the transverse fibers of the intrinsic muscular tissue of the tongue. The genio-hyo-glossus muscle is next to the median line, and is separated from the genio-hyo-glossus of the opposite side by the septum linguæ and hypo-glossal membrane.

The *intrinsic or lingualis muscle* contains longitudinal, transverse, and vertical fibers. The longitudinal fibers are composed of two separate bundles on each side, a superior and an inferior. The *superior lingualis muscle* lies beneath the mucous membrane of the dorsum, and extends from the base to the apex of the tongue. It is separated from the superior lingualis of the opposite side by the septum linguæ. The *inferior lingualis muscle* is found on the under surface of the tongue, beneath the transverse fibers. It is attached behind to the hyoid bone, and extends from the base of the tongue to its apex. Behind, it lies between the hyo-glossus and the genio-hyo-glossus muscle, and in front, between the stylo-glossus and the genio-hyo-glossus muscle. The *transverse fibers* form a thick layer beneath the superior lingualis muscle, and extend from the septum linguæ to the side of the tongue. The *vertical fibers* decussate with the transverse fibers, and pass in curved lines from the dorsum to the inferior aspect of the tongue. As the tongue is almost entirely composed of muscular tissue and contains little areolar tissue, it does not become much swollen when inflamed.

Many of the muscular fibers of the tongue are attached to the mucous membrane; hence, when the mucosa is destroyed, as in ulcerative processes, the surface of the ulcer presents an uneven, ragged appearance, due, in part, to retraction of the muscular fibers.

The **septum linguæ** is a fibrous membrane which extends vertically downward from the median raphe between the halves of the tongue, and separates the two lingualis and the two genio-hyo-glossus muscles. Its lower portion is strong, attaches the base of the tongue to the hyoid bone, and is called the **hypo-glossal membrane**.

Paralysis and atrophy of one-half of the tongue may be produced by a central lesion of the hypo-glossal nerve, as by a hemorrhage affecting the center of that nerve in the medulla oblongata, or by a peripheral lesion, as disease or fracture of the occipital bone at the anterior condyloid foramen or by pressure from an aneurysm of the external carotid or internal carotid artery.



TRANSVERSE SECTION OF ONE-HALF OF TONGUE.



Macroglossia, or large tongue, is usually due to increased development of the lymphoid tissue of the tongue.

BLOOD SUPPLY.—The nutrition of the tongue is derived from the lingual, facial, and ascending pharyngeal arteries.

NERVE SUPPLY.—From the glosso-pharyngeal, hypo-glossal, lingual, and chorda tympani nerves. The glosso-pharyngeal is the nerve of the special sense of taste, and supplies special sensory and common sensory fibers to the mucous membrane at the posterior third of the tongue, and to the circumvallate papillae. The hypo-glossal is the motor nerve, and supplies the extrinsic muscles and the lingualis muscle, the latter being also supplied by the chorda tympani nerve. The lingual, or gustatory, is the common sensory nerve of the tongue, and supplies the front and sides of that organ. Small branches of the superior laryngeal nerve are distributed to the base of the tongue in the region of the epiglottis.

Irritation of the lingual nerve, as by an ulcer or a carcinoma of the tongue, may cause reflected disturbance in the tissues supplied by other branches of the inferior maxillary nerve—through the auriculo-temporal nerve, pain in the pinna, external auditory meatus, and temporal region; through the inferior dental nerve, pain in the lower teeth, lower gums, and chin; and through the motor branches of the inferior maxillary nerve, spasm of the muscles of mastication, excepting the buccinator muscle.

In **profound anesthesia** relaxation of the tissues allows the tongue to fall backward, depress the epiglottis, and obstruct respiration. To relieve this condition the anesthetizer carries the lower jaw forward by placing his fingers behind the angles of that bone. This procedure makes tension upon the genio-hyo-glossus, genio-hyoid, and mylo-hyoid muscles, the hypo-glossal membrane, the glosso-epiglottidean folds, and the hyo-epiglottidean ligament; draws the tongue, epiglottis, and hyoid bone forward; and opens the superior aperture of the larynx.

The **lymphatic vessels of the lips** pass with the superficial lymphatic vessels of the front of the face into the submaxillary and superior deep cervical lymphatic glands.

The **lymphatics of the roof of the mouth and deeper portion of the cheek** terminate in the internal maxillary lymphatic glands.

The **lymphatics of the floor of the mouth and anterior part of the tongue** pierce the mylo-hyoid muscle and join the submaxillary lymphatic glands.

The **lymphatics of the tongue**, excepting those of the most anterior portion, accompany the lingual vein, pass through the lingual lymphatic glands on the hyo-glossus muscle, and terminate in the superior deep cervical glands.

In **excision of the tongue** for carcinoma it is advisable to remove the superior

deep cervical, submaxillary, and lingual lymphatic glands, so that the involved glands may not be the source of a secondary growth. Occasionally the submaxillary salivary gland, which contains two or more lymphatic glands, should also be removed.

The **isthmus of the fauces** is the large orifice of communication between the mouth and the pharynx. It is bounded above by the soft palate, below by the base of the tongue, and on each side by the pillars of the fauces.

The under surface of the **Soft Palate**, which is seen through the mouth, is concave, and its mucous membrane is continuous with that of the hard palate. It presents a median raphe which marks the line of union of the halves.

The **Uvula** is the conic process which is suspended in the isthmus of the fauces from the middle of the free border of the soft palate.

The **pillars of the fauces**, or **pillars of the soft palate**, are ridges in the mucous membrane which extend outward and downward from the uvula. There are two pillars on each side—an anterior and a posterior pillar. The anterior pillars extend downward, outward, and forward to the sides of the base of the tongue. They contain the palato-glossus muscles. The posterior pillars are directed downward, outward, and backward, and fade away upon the lateral wall of the pharynx. They are produced by the palato-pharyngeus muscles. A triangular depression exists on each side between the anterior and the posterior pillar, and is termed the **recess of the fauces**, or **tonsillar recess**.

The **Tonsils** are two oblong rounded bodies, situated in the recesses of the fauces. They vary in size in different individuals, but should not project beyond the anterior pillars of the fauces. The internal surface of the tonsil is covered by the oral mucous membrane, and presents from ten to fifteen puncture-like orifices, which lead into recesses called *crypts*. The crypts are lined by extensions of the oral mucous membrane. The tonsils are compound follicular glands—*i. e.*, they contain a number of aggregations of lymphoid tissue similar to that of the solitary glands of the intestines. They are enveloped by a fibrous capsule. The secretion of the tonsil is derived from the mucous glands in the mucous membrane lining the crypts, and contains numerous epithelial and lymphoid cells.

Inspissation of the mucous secretion in the crypts of the hypertrophied tonsils gives rise to the formation of cheesy plugs, which contain decomposing epithelium, emit a foul odor, and produce fetid breath.

It is quite probable that germs in the stagnant secretion in the crypts of the tonsils enter the lymphatic vessels, and cause many of the cases of inflammation and tuberculosis of the deep cervical chain of lymphatic glands.

BLOOD SUPPLY.—From the ascending pharyngeal branch of the external

carotid, the tonsillar, and ascending palatine branches of the facial artery, the dorsalis lingue branch of the lingual artery, and the descending palatine branch of the internal maxillary artery.

NERVE SUPPLY.—From the glosso-pharyngeal nerve and branches of Meckel's ganglion.

The **veins** of the tonsils empty into the tonsillar plexus, which lies on the outer surface of the gland and is drained by the pharyngeal veins.

The **lymphatics** of the tonsil, which are numerous, empty into the lymphatic glands near the angle of the lower jaw, and into the superior deep cervical lymphatic glands.

RELATIONS.—Externally, the tonsil is in relation with the superior constrictor muscle of the pharynx and the pharyngeal aponeurosis, which separate it from the internal carotid and the ascending pharyngeal artery; internally, with the mucous membrane of the mouth and pharynx.

Tonsillitis.—The tonsils are frequently affected by inflammation. In follicular tonsillitis the crypts especially are involved, and their secretion is inspissated, forming yellowish-white plugs which resemble diphtheric false membrane, and give the throat the appearance of "ulcerated sore throat." In phlegmonous or purulent tonsillitis (quinsy), when the affection is bilateral, the tonsils may almost meet in the median line. These tonsillar abscesses should be incised with a bistoury, guarded to avoid injuring the tongue. The knife should be directed backward and inward, and the incision be made toward the median line to avoid injuring the internal carotid artery, which lies just external to the gland.

Hypertrophied tonsils can not be felt externally below the angles of the lower jaw, for the reason that the pharyngeal aponeurosis and the superior constrictor muscles of the pharynx prevent the tonsils from projecting outward. The masses present in these locations are enlarged lymphatic glands which receive lymphatic vessels from the tonsils. Hypertrophied tonsils project beyond the pillars of the fauces, and cause considerable annoyance through their interference with respiration and with the resonance of the voice. Hypertrophied tonsils should be amputated with a tonsillotome, or removed by dissection. Exaggerated prominence of the anterior pillars of the fauces may render these operations quite difficult. The relation which the tonsil bears to the internal carotid and ascending pharyngeal arteries should be borne in mind in either of these operations.

The ascending pharyngeal artery runs upon the external surface of the superior constrictor muscle of the pharynx, opposite the tonsil, and in operations upon the tonsil or in wounds of that organ is in more danger of being injured than is the internal carotid artery, which is placed further back.

Malignant growths of the tonsil are not infrequent, and are best removed through an incision made along the anterior border of the sterno-mastoid muscle and not through the mouth, because the involved lymphatic glands can not be satisfactorily reached by the latter route.

The **Bucco-pharyngeal Fascia** is a thin layer of deep fascia which covers the buccinator muscle and the constrictor muscle of the pharynx. It is continuous below with the delicate fibrous investment of the esophagus.

DISSECTION.—Stuff the pharynx and esophagus with cotton, and carefully remove the fascia covering the esophagus, trachea, and the constrictor muscles of the pharynx. The ascending pharyngeal artery, which is in relation with the superior constrictor muscle of the pharynx, and the recurrent laryngeal nerve, which lies in the groove between the esophagus and trachea, are the structures most likely to be destroyed.

The **Esophagus** is the narrow continuation of the pharynx. It begins at the lower, contracted end of the pharynx, opposite the sixth cervical vertebra and the lower border of the cricoid cartilage. It passes downward behind the trachea, to enter the posterior mediastinum of the chest. At its beginning it lies in the median line, but at the lower part of the neck it inclines to the left side. Its muscular coat is seen to be continuous with the inferior constrictor muscle of the pharynx.

RELATIONS.—In front of the esophagus, in the neck, are the trachea, left recurrent laryngeal nerve, and the posterior surface of the left lobe of the thyroid gland. Behind it are the prevertebral fascia, the bodies of the vertebrae, and the longus coli muscles. On its right side are the right carotid sheath and its contents, the right recurrent laryngeal nerve, and the right lobe of the thyroid gland. On its left side are the left carotid sheath, the left common carotid and subclavian arteries, the left recurrent laryngeal nerve, the thoracic duct, and the left lobe of the thyroid gland.

The narrowest point in the esophagus is behind the lower border of the cricoid cartilage and in front of the sixth cervical vertebra. This is the point at which a large foreign body, such as a set of false teeth, would be likely to lodge. If a foreign body can not be withdrawn through the mouth or pushed into the stomach, it becomes necessary to perform an esophagotomy. This is done as follows: An incision is made along the anterior border of the left sterno-mastoid muscle, cutting skin, superficial fascia, platysma myoides muscle, some superficial vessels and nerves, superficial layer of the deep fascia, omo-hyoid muscle if necessary, pre-tracheal fascia, and esophagus. The carotid sheath and its contents must be displaced outward; the trachea, thyroid gland, and sterno-thyroid and sterno-hyoid muscles should be displaced inward. The superior and middle thyroid veins must

be avoided or divided between ligatures, and the recurrent laryngeal nerve and inferior thyroid artery must not be injured.

The thoracic portion of the esophagus will be described with the chest.

THE PHARYNX.

The **pharynx**, the second portion of the alimentary tract, is situated behind the nasal cavities, the mouth, and the larynx; it is subdivided into the naso-pharynx, oro-pharynx, and laryngo-pharynx, and is a conic, musculo-membranous tube. The **naso-pharynx** and **oro-pharynx** bridge the gap in the respiratory tract between the larynx and nasal cavities, and assist in giving resonance to the voice; the **oro-pharynx** and **laryngo-pharynx** connect the mouth with the esophagus, and carry the food from the former to the latter. The pharynx is about four and one-half inches in length, and extends from the base of the skull to the upper border of the sixth cervical vertebra, opposite the lower border of the cricoid cartilage, where it becomes the esophagus. The base of the cone is in contact with the under surface of the body of the sphenoid bone and the basilar process of the occipital bone, and its apex blends with the esophagus. The pharynx is compressed from before backward, the transverse diameter being greater than the antero-posterior. Its widest point is opposite the greater cornua of the hyoid bone, where it is about two inches in width; its narrowest point is at its junction with the esophagus, opposite the lower border of the cricoid cartilage, where it is about three-fourths of an inch wide.

Although, owing to the dilatibility of the pharynx, large foreign bodies may be retained in it for a long time without producing much discomfort, they more frequently give rise to alarming symptoms. They usually lodge at the lower end, which is the narrowest portion of that canal. Here they lie behind the larynx, causing dyspnea and obstructing deglutition. In attempting removal of these bodies it is important to remember that the pharyngo-esophageal junction is about six inches from the teeth.

Foreign bodies in the pharynx may cause suffocation by occlusion of the superior aperture of the larynx, or by producing spasm of the muscles of the larynx. In either condition sudden death may occur during eating. As the mass of food can be reached if it rests upon the superior aperture of the larynx, the proper course of procedure is to remove it with the finger used as a hook.

The pharynx has a muscular, a fibrous, and a mucous coat.

The **Muscular Coat of the Pharynx** is composed of three muscles—viz., the

inferior, middle, and superior constrictor muscles,—with a few fibers from the stylo-pharyngeus and palato-pharyngeus muscles.

The **constrictor muscles of the pharynx** are flat, and are inserted into the median raphe on the posterior aspect of the organ. This raphe is formed by the interlacing, tendinous fibers of the muscles of the opposite sides, and extends downward from the pharyngeal spine on the basilar process of the occipital bone. The constrictor muscles are arranged so that the inferior overlaps the middle, and the middle overlaps the superior.

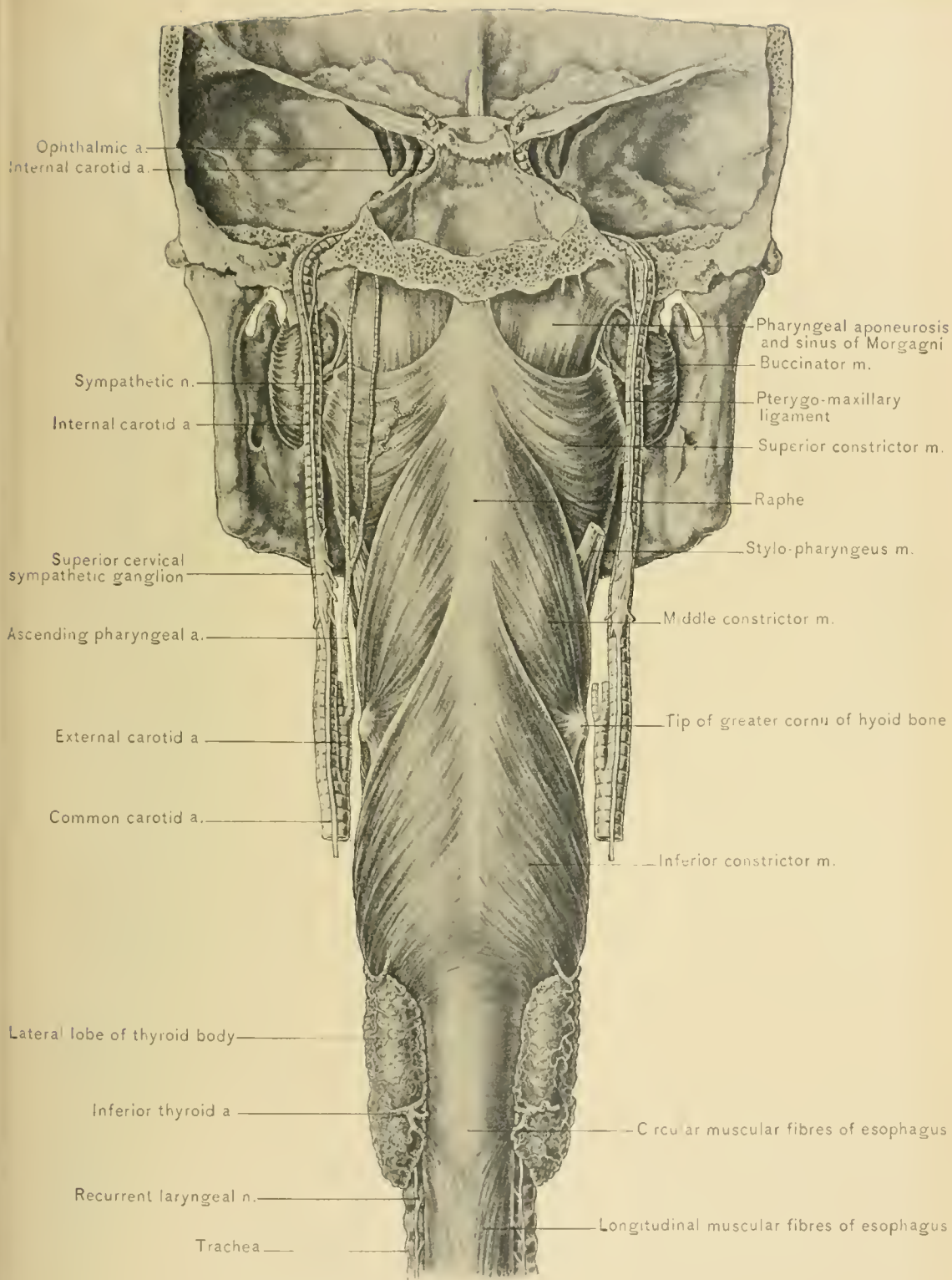
The *inferior constrictor muscle of the pharynx* arises from the posterior part of the side of the cricoid cartilage behind the crico-thyroid muscle, from the inferior cornu, the oblique line, and the superior border of the ala of the thyroid cartilage. Its fibers diverge as they pass backward around the pharynx, to be inserted into the median raphe. The lower fibers are almost horizontal, and are continuous with the muscular coat of the esophagus. The upper fibers ascend obliquely over the lower portion of the middle constrictor muscle, to be inserted into the raphe higher up. Passing beneath or through the lower border of the inferior constrictor muscle at its origin are the recurrent laryngeal nerve and the inferior laryngeal branch of the inferior thyroid artery on their way to the larynx.

The *middle constrictor muscle of the pharynx* has a narrow origin from the stylo-hyoid ligament, the lesser cornu of the hyoid bone, and the entire length of the upper surface of the greater cornu of the hyoid bone. Its fibers diverge as they pass to the back of the pharynx, to reach the median raphe. The lower fibers are almost horizontal, and pass beneath the upper part of the inferior constrictor muscle. The upper fibers pass obliquely upward over the lower part of the superior constrictor muscle, to reach the raphe near the base of the skull. Some of its tendinous fibers continue upward to the pharyngeal spine on the basilar process of the occipital bone.

In the interval between the origins of the middle and inferior constrictor muscles, the *internal laryngeal branch of the superior laryngeal nerve* and the *superior laryngeal artery* pierce the thyro-hyoid membrane. Near the upper margin of the middle constrictor muscle runs the glosso-pharyngeal nerve, and passing beneath that margin is the stylo-pharyngeus muscle. Its origin is covered by the hyo-glossus muscle and the lingual artery, which lies between the hyo-glossus and the middle constrictor muscle.

DISSECTION.—To expose the origin of the superior constrictor muscle it is necessary to remove the internal pterygoid muscle. In removing the origin of that muscle from the pterygoid fossa preserve the tensor palati muscle, which lies between the internal pterygoid muscle and the internal pterygoid plate.

The *superior constrictor muscle* is a thin, pale, quadrilateral muscle. It arises



CONSTRICOR MUSCLES OF PHARYNX.

from the lower one-third of the posterior border of the internal pterygoid plate, from the hamular process of that plate, the pterygo-maxillary ligament, the posterior part of the mylo-hyoid ridge of the lower jaw, and the side of the base of the tongue. Its fibers pass backward to be inserted into the median raphe. The lower fibers are overlapped by the middle constrictor muscle. The upper fibers curve upward, and have a tendinous attachment to the pharyngeal spine on the basilar process of the occipital bone. The upper margin is crescentic, and situated some distance from the base of the skull, leaving a semilunar interval—the sinus of Morgagni. The floor of the *sinus of Morgagni* is formed by the pharyngeal aponeurosis. The upper border of the superior constrictor muscle of the pharynx is in relation with the levator palati muscle and the Eustachian tube. The superior constrictor muscle with the pharyngeal aponeurosis separate the ascending pharyngeal and internal carotid arteries from the tonsil.

NERVE SUPPLY.—The constrictor muscles of the pharynx derive their nerve supply from the pharyngeal plexus. The inferior constrictor muscle receives additional branches from the external and recurrent laryngeal nerves.

Tetanus often presents its first symptom as spasm of those muscles of mastication which elevate the lower jaw,—viz., the masseter, temporal and internal pterygoid muscles,—and of the constrictor muscles of the pharynx. Consequently, the patient can not open the mouth, and deglutition, or swallowing, is difficult or causes choking sensations. Spasm of the constrictor muscles of the pharynx and difficult deglutition are also prominent symptoms of hydrophobia.

The **Pharyngeal Plexus of Nerves** is found chiefly upon the middle constrictor muscle. It is formed by the pharyngeal branches of the pneumogastric, external laryngeal, and glosso-pharyngeal nerves, and of the superior cervical sympathetic ganglion. It supplies the muscular and other coats of the pharynx.

The **Pterygo-maxillary Ligament** is a fibrous raphe between the buccinator and superior constrictor muscles, and extends from the lower extremity of the internal pterygoid plate to the posterior end of the mylo-hyoid ridge or internal oblique line of the lower jaw.

The **Pharyngeal Aponeurosis**, the fibrous coat of the pharynx, is dense and strong where the muscular coat is absent,—viz., at the sinuses of Morgagni and in the triangular intervals between the origins of the constrictor muscles,—and becomes delicate and fades away below. It holds the pharynx open by means of its attachment to the basilar process of the occipital bone, the cartilages in the middle lacerated foramina, the apices of the petrous portions of the temporal bones, the posterior borders of the internal pterygoid plates, the greater cornua of the hyoid bone, and the posterior borders of the ake of the thyroid cartilage.

The **Mucous Coat**, or mucous membrane, lining the pharynx is continuous with that of the Eustachian tubes, nasal cavities, mouth, larynx, and esophagus. It contains racemose mucous glands and scattered lymphoid follicles. Because of its vascularity, **inflammation of this membrane**, which is known as pharyngitis or sore throat, frequently occurs. Through the continuity of the mucous membrane of the nose and larynx the catarrhal process may extend to the mucous membrane of those cavities.

DISSECTION.—Divide the posterior wall of the pharynx in the median line, and detach it from the base of the skull as far as the lateral wall. Then turn the two flaps outward, to study the interior of the pharynx.

Beneath the petrous portion of the temporal bone the cavity of the pharynx extends outward, forming a pouch—the *pharyngeal recess*.

The **Pharyngeal Tonsil of Luschka** is a collection of lymphoid tissue in the posterior wall of the pharynx, near its junction with the roof.

The **Pharyngeal Bursa** is a small diverticulum in the posterior wall of the pharynx, below the occipital bone; it is most conspicuous in the fetus and in infants.

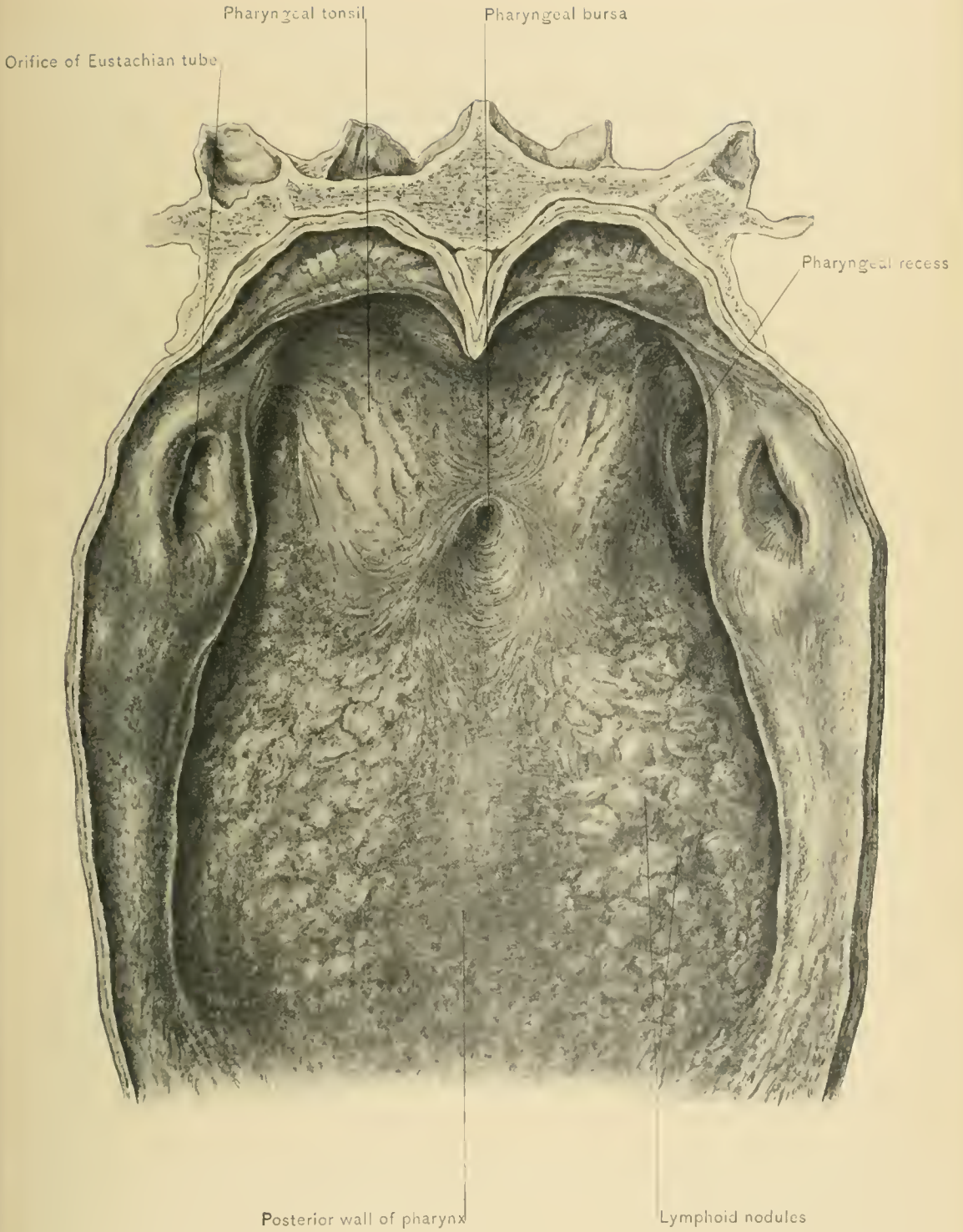
Hypertrophy of the Pharyngeal Tonsil is the source of adenoid growths in the naso-pharynx. Obstruction of the posterior nares, loss of nasal resonance in the voice, and mouth breathing result. Extension of the hypertrophic process into the Eustachian tubes causes obstruction of those tubes, tinnitus aurium, or peculiar sounds in the ears, and deafness.

Post-pharyngeal Abscess, usually resulting from caries of the upper cervical vertebræ or suppuration of the post-pharyngeal lymphatic gland, may bulge into the pharynx and cause difficulty in deglutition or respiration. Post-pharyngeal abscesses, and those arising in the pterygo-maxillary region and temporal fossa, may rupture into the pharynx.

There are seven **Openings** into the pharynx: The two posterior nares, two Eustachian tubes, mouth, larynx, and esophagus.

The two **posterior nares** (choanæ) are at the highest point of the anterior wall of the pharynx. They are separated from each other by the posterior margin of the septum of the nose. Through them can be seen the middle and inferior turbinated bones. When a mirror is placed immediately behind the soft palate, the superior turbinated bones can also be seen.

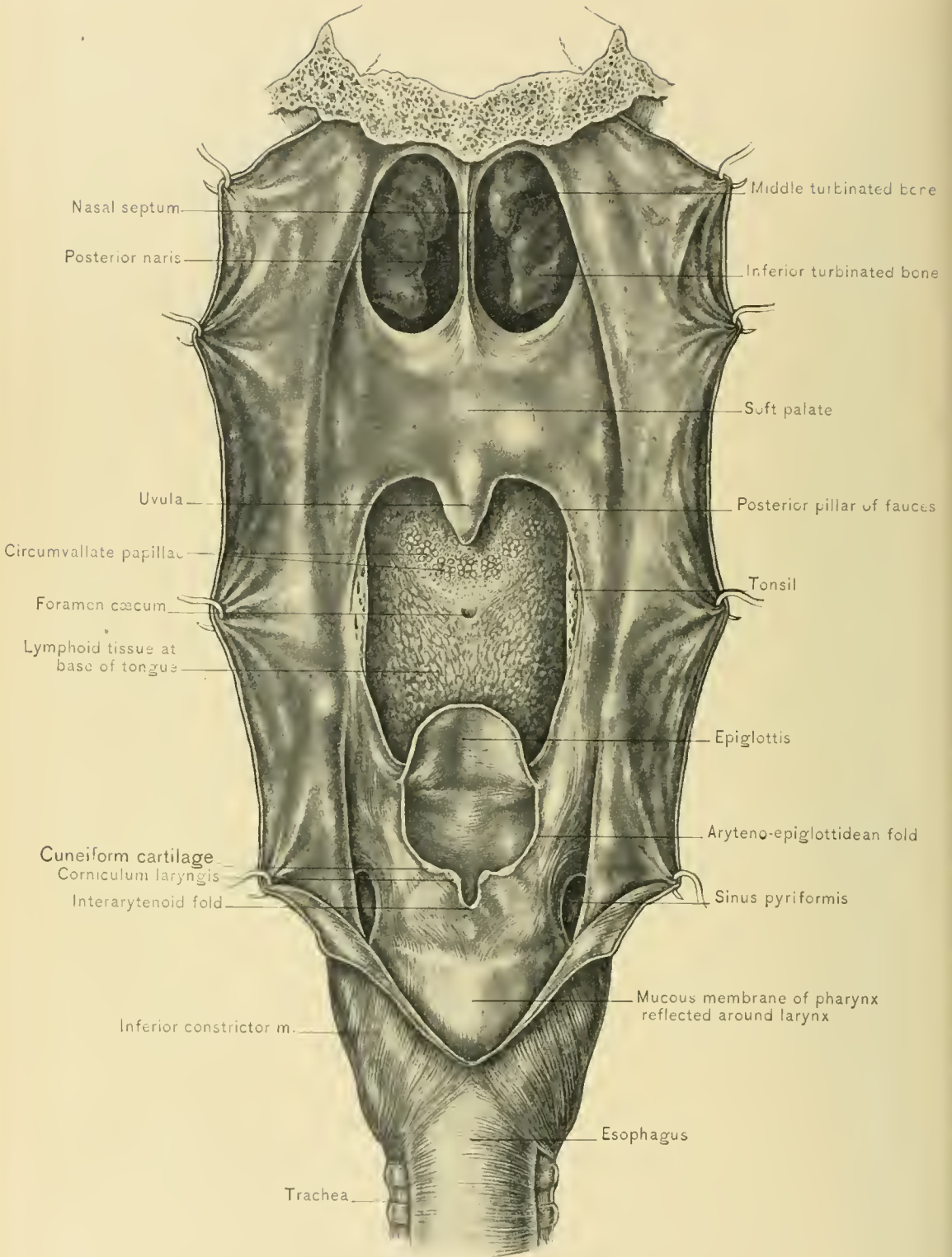
The trumpet-shaped orifices of the **Eustachian tubes** are in the lateral walls of the pharynx, at about the level of the inferior turbinated bones. It should be noticed that a Eustachian catheter carried through the inferior meatus to the posterior wall of the pharynx, rotated outward, and drawn forward along the lateral wall of the pharynx until it passes over the elevation at the posterior mar-



PHARYNGEAL TONSIL AND BURSA.







gin of the Eustachian orifice, will readily slip into the Eustachian tube when pushed backward again. From their orifices the Eustachian tubes are directed backward, outward, and slightly upward, opening into the tympanic cavity at its anterior wall. The inner portion of the Eustachian tube is cartilaginous on the upper and inner sides, and fibrous below. The outer portion of the Eustachian tube has bony walls, and begins in the receding angle between the squamous and petrous portions of the temporal bone.

The **isthmus of the fauces**, or posterior opening of the mouth, is situated immediately below the posterior nares and soft palate. Through the isthmus some of the structures of the mouth can be examined from behind. The pillars of the fauces, the tonsils, situated in the recesses of the fauces, and the base of the tongue are more satisfactorily seen through the isthmus of the fauces than through the buccal orifice. The base of the tongue holds a vertical position, and overhangs the epiglottis. Between the tongue and the epiglottis are the three glosso-epiglottidean folds and the two glosso-epiglottidean pouches.

The **superior aperture of the larynx** is situated below the base of the tongue. It is a large, triangular-shaped opening, its wider portion being directed forward. It slopes obliquely downward and backward from the upper extremity of the epiglottis. It is bounded in front by the epiglottis, behind by the interarytenoid fold of mucous membrane, and on each side by the aryteno-epiglottidean fold and the tips of the arytenoid cartilages. On each side of its posterior portion there is a deep depression, the *sinus pyriformis*, in which foreign bodies may lodge.

The **esophageal opening of the pharynx** is the narrowest portion of the pharynx, and is located behind the lower border of the cricoid cartilage.

RELATIONS OF THE PHARYNX.—In front of the pharynx are the posterior nares, the soft palate, the isthmus of the fauces, the base of the tongue, the hyoid bone, and the larynx. Behind it are the prevertebral fascia, the post-pharyngeal lymphatic gland, the rectus capitis anticus major and longus colli muscles, and the bodies of the upper vertebrae. Laterally, its upper portion is in relation with the Eustachian tube, the inferior maxillary nerve, the styloid process of the temporal bone, the muscles arising from that process, the internal pterygoid muscles, the parotid gland, the glosso-pharyngeal, pneumogastric, spinal accessory, hypo-glossal, and sympathetic nerves, ascending pharyngeal, and internal carotid arteries, and internal jugular vein; its lower portion is in relation laterally with the carotid sheath and its contents, the lower part of the external carotid artery, the commencement of the superior thyroid, lingual, and facial arteries, the lateral lobe of the thyroid body, the sterno-thyroid muscle, and the deep cervical chain of lymphatic glands. Above the pharynx is that portion of the base of the skull formed by the body of

the sphenoid bone and the basilar process of the occipital bone. Below, it leads into the esophagus.

While studying the relations of the pharynx, it is well to observe some important facts associated therewith. The body of the sphenoid bone and the basilar process of the occipital bone and the upper three cervical vertebræ can be palpated with the finger inserted into the pharynx. The anterior arch of the atlas is in the same transverse plane as the hard palate; the body of the axis is in the same transverse plane as the cutting edges of the upper teeth; and the body of the third cervical vertebra is just below that of the axis. In *necrosis* of the body of the sphenoid bone, basilar process of the occipital bone, anterior arch of the atlas, and bodies of the upper cervical vertebræ, pus and pieces of bone may be discharged through the pharynx and mouth. *Sharp foreign bodies* which have perforated the wall of the pharynx may wound one of the carotid arteries or the internal jugular vein.

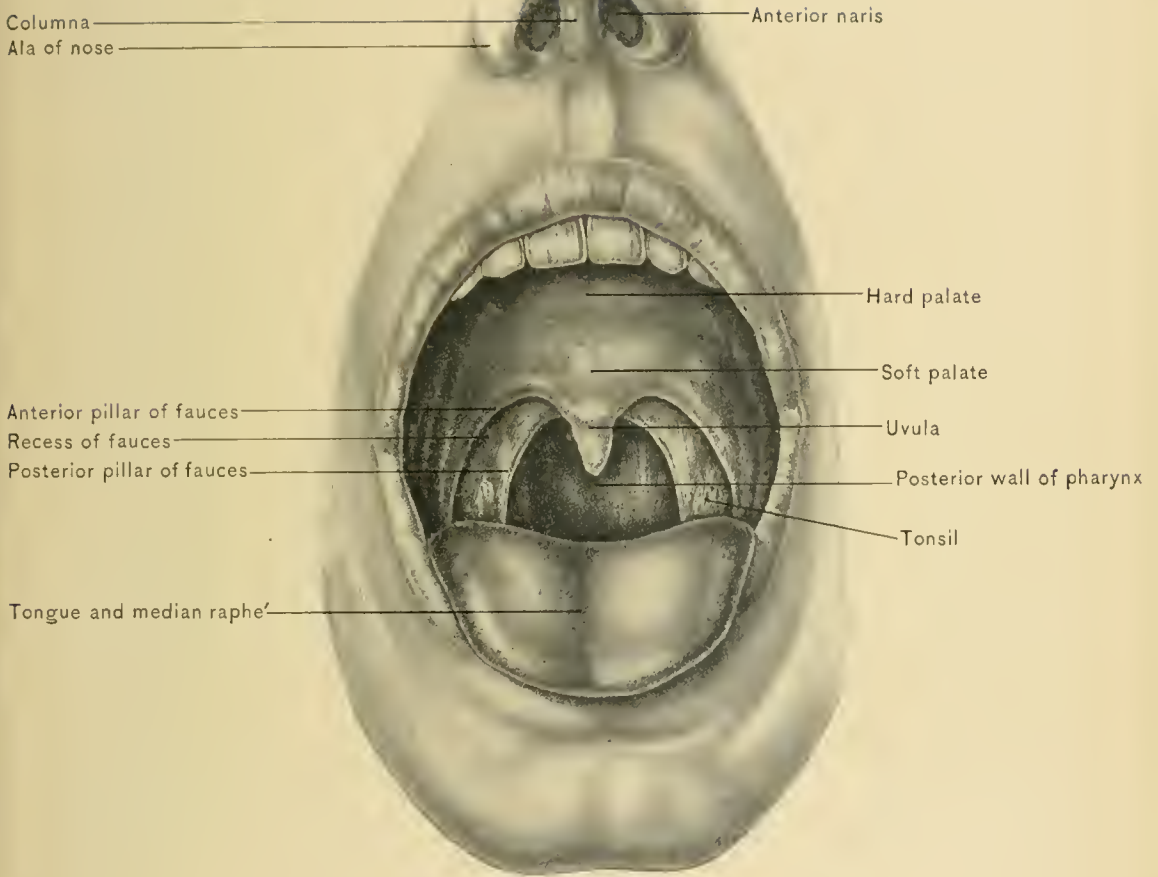
BLOOD SUPPLY.—From the ascending pharyngeal artery, the tonsillar and ascending palatine branches of the facial artery, the superior laryngeal branch of the superior thyroid artery, and the inferior laryngeal branch of the inferior thyroid artery.

NERVE SUPPLY.—From the pharyngeal plexus of nerves.

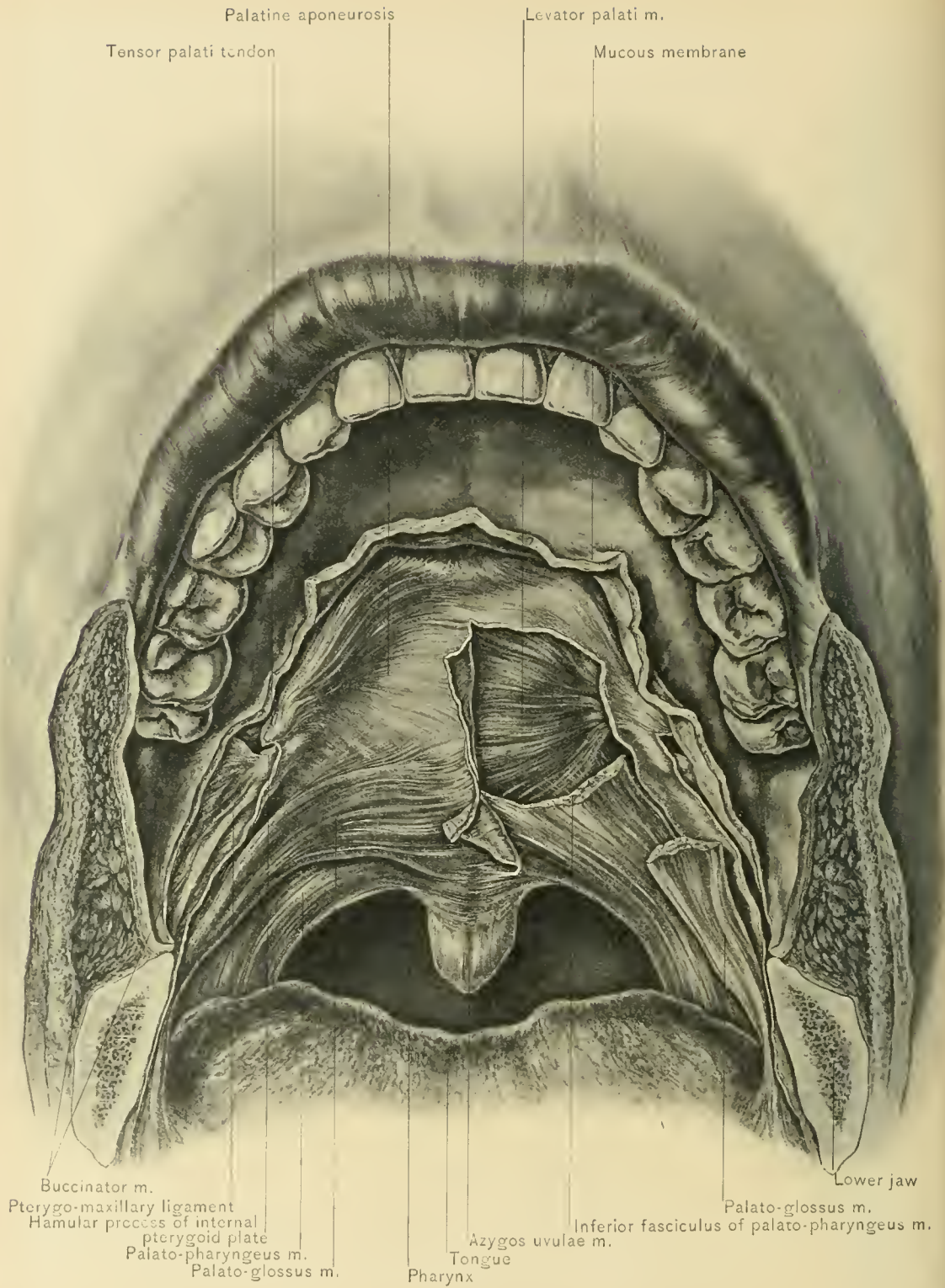
The **Veins of the Pharynx** are arranged as a plexus which is situated between the constrictor muscles and the prevertebral fascia. This plexus communicates above with the pterygoid plexus of veins, and empties into the terminal portion of the facial vein or into the internal jugular vein.

The **Lymphatic Vessels of the Upper Portion of the Pharynx** terminate in the post-pharyngeal gland; those of the middle portion, in the superior deep cervical glands; and those of the lower portion, in the inferior deep cervical lymphatic glands.

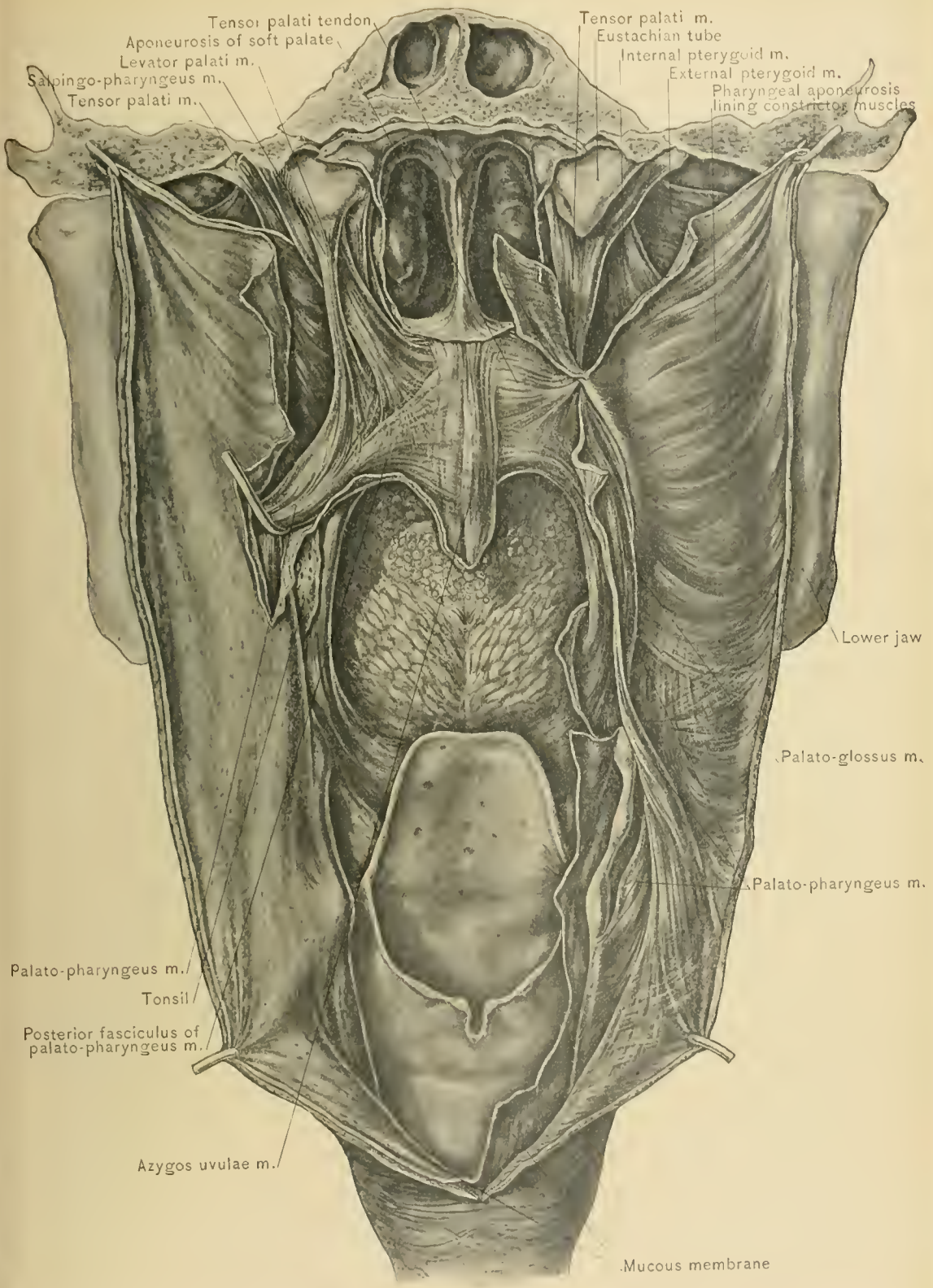
The **Soft Palate** is a musculo-membranous and freely movable curtain. Its anterior margin is attached to the posterior border of the hard palate; its posterior margin is free, and forms the upper boundary of the isthmus of the fauces. From the center of this curved margin the **uvula** is suspended. The lateral margins are attached to the side of the pharynx. Its upper surface is convex; its lower, concave. The mucous membrane on the upper surface is continuous with that of the floor of the nasal cavities, and the mucous membrane of its lower surface with that of the roof of the mouth. Between its two layers of mucous membrane are the two levatores palati, two tensores palati, the palato-pharyngeus, palato-glossus, and azygos uvulæ muscles, an aponeurosis, glandular tissue, vessels, and nerves. The under surface of the soft palate contains a prominence a short distance behind the last molar tooth. This elevation is produced by the hamular process of the in-



ANTERIOR VIEW OF MOUTH.



MUSCLES OF SOFT PALATE—ANTERIOR VIEW.



MUSCLES OF SOFT PALATE.

ternal pterygoid plate of the sphenoid bone, which is the guide in dividing the aponeuroses of the tensor palati and levator palati muscles.

DISSECTION.—Make the tissues tense by means of hooks, and reflect the mucous membrane from both surfaces of the soft palate and from the pillars of the fauces. Remove the mucous membrane and pharyngeal aponeurosis from the upper portion of the side of the pharynx, in order to fully expose the levatores and tensores palati muscles, which have been seen during the dissection of the superior constrictor muscle of the pharynx.

The **Levator Palati Muscle** arises from the under surface of the petrous portion of the temporal bone, in front of the carotid canal and from the under and inner surfaces of the cartilaginous portion of the Eustachian tube. It passes internal to the upper margin of the superior constrictor muscle of the pharynx, to reach the inner surface of that muscle, and is inserted into the palatine aponeurosis and into its fellow of the opposite side, in front of the azygos uvulae muscle.

ACTION.—It elevates the soft palate and brings it into contact with the posterior wall of the pharynx, so as to separate the naso-pharynx from the oro-pharynx and prevent regurgitation of food from the oro-pharynx into the naso-pharynx and nasal cavities.

The **Tensor Palati Muscle** arises from the scaphoid fossa, which is situated behind the base of the internal pterygoid plate, from the spine of the sphenoid bone, and the outer side of the cartilaginous portion of the Eustachian tube. It is a flat muscle, which lies on the outer surface of the internal pterygoid plate and terminates in a tendon which winds around the hamular process of that plate. The tendon forms almost a right angle with the muscle, and is inserted into the palatine aponeurosis, with which it is continuous, and into the transverse ridge on the under surface of the horizontal plate of the palate bone. A bursa facilitates the movement of the tendon over the hamular process.

ACTION.—It renders the soft palate tense and opens the Eustachian tube during deglutition.

The **Palato-pharyngeus Muscle** is situated in the posterior pillar of the fauces. It arises from the soft palate by two slips, which are separated by the levator palati and azygos uvulae muscles and are continuous with the corresponding slips of the opposite muscle, and also has an origin from the cartilage of the Eustachian tube (salpingo-pharyngeus). It passes to the side of the pharynx and joins the stylo-pharyngeus muscle, to be inserted into the posterior border of the thyroid cartilage below the base of the superior cornu, and by an expansion into the pharyngeal aponeurosis.

ACTION.—It elevates the pharynx and larynx and approximates the posterior pillars of the fauces.

The **Palato-glossus Muscle** is found in the anterior pillar of the fauces. It arises from the under surface of the palatine aponeurosis, and is partly continuous with the palato-glossus muscle of the opposite side in front of the azygos uvulae muscle. It is inserted into the side of the tongue, and is partly continuous with the transverse muscular fibers of that organ.

ACTION.—It draws the side of the soft palate downward, and elevates the sides and back part of the tongue, thus constricting the isthmus of the fauces to prevent the morsel of food from being driven back into the mouth in deglutition.

The **Azygos Uvulae Muscle** is a double muscle, and arises from the palatine aponeurosis and the posterior nasal spine on the horizontal plate of the palate bone, and is inserted into the mucous membrane of the uvula.

ACTION.—It elevates and shortens the uvula.

The **Palatine Aponeurosis** is a thin but dense fibrous membrane, which is attached to the posterior margin of the hard palate and gradually disappears as it approaches the posterior or free border of the soft palate. Laterally, it is continuous with the pharyngeal aponeurosis. It receives the tendinous expansion of the tensor palati muscle, and gives form to the soft palate.

The glandular tissue of the soft palate is most abundant in its upper surface, although there is some adenoid tissue in its under surface.

BLOOD SUPPLY.—From the dorsalis linguae and the ascending pharyngeal artery, the ascending palatine branch of the facial artery, and the posterior palatine branch of the internal maxillary artery.

The *veins* correspond to the arteries. The *lymphatics* empty into the glands at the angle of the jaw.

NERVE SUPPLY.—From Meckel's ganglion, the glosso-pharyngeal nerve, the pharyngeal plexus of nerves, and the otic ganglion. The tensor palati muscle is supplied by a branch from the otic ganglion. The levator palati, palato-glossus, palato-pharyngeus, and azygos uvulae muscles are probably supplied by branches from the pharyngeal plexus, which are derived from the spinal accessory nerve.

Clefts of the Soft Palate may exist independently of clefts of the hard palate. They are widened by the tensor palati, levator palati, palato-glossus, and palato-pharyngeus muscles. These clefts give rise to difficulty in deglutition, because they allow food to pass into the naso-pharynx and nose. Before closing the cleft, the aponeuroses of these muscles are divided to prevent them from causing tension upon the sutures. The aponeuroses of the tensor palati and levator palati muscles may be divided by one incision. A slender bistoury, with its cutting edge directed forward and upward, is inserted into the soft palate slightly in front of and close to the inner side of the hamular process of the internal pterygoid plate of the sphenoid bone, until it projects through the superior surface

of the soft palate. As the knife is pushed upward it cuts the tensor palati aponeurosis. The bistoury is then carried upward, forward, and inward, cutting the superior surface of the soft palate for a distance sufficient to allow severance of the levator palati aponeurosis. The palato-glossus and palato-pharyngeus muscles can be divided by a shallow incision across each of the pillars of the fauces. The attachment of the palatine aponeurosis to the posterior margin of the hard palate may also cause difficulty in approximating the freshened margins of the cleft, and should be divided as far as necessary. The success of the operation depends chiefly upon the relief of tension upon the sutures.

Paralysis of the Muscles of the Soft Palate and Pharynx may occur during convalescence from diphtheria. As a result, there is difficulty in swallowing and regurgitation of food through the nose.

THE LARYNX.

The **larynx** is a membrano-cartilaginous, box-like organ. It is the organ of voice, assists in protecting the respiratory tract from the entrance of foreign bodies during deglutition, and closes the respiratory tract, so that the chest can be made firm during great muscular effort. It is situated at the upper portion of the respiratory tract, above the trachea and in front of the lower portion of the pharynx. Anteriorly, it is covered by skin, superficial and deep fasciæ, two thin layers of muscular tissue, and, occasionally, a process of the middle lobe of the thyroid gland. The superficial stratum of muscular tissue is composed of the sterno-hyoid and omo-hyoid muscles; the deep stratum, of the sterno-thyroid and thyro-hyoid muscles. The great vessels lie on each side of the larynx in the groove between the larynx and the sterno-mastoid muscle. It is suspended from the skull by the stylo-hyoid ligament, the muscles attached to the superior surface of the hyoid bone, and the stylo-pharyngeus and palato-pharyngeus muscles, which are inserted into the posterior borders of the alæ of the thyroid cartilage. It is lined internally by mucous membrane which is continuous above with that lining the pharynx, and below with that of the trachea. It consists of three single cartilages and three pairs of cartilages united by membranes, ligaments, and muscles. The three single cartilages are the thyroid, cricoid, and epiglottis; the paired ones are the arytenoid, cornicula laryngis, and cuneiform. The larynx is larger in all its dimensions in the male than in the female.

The **Superior Aperture of the Larynx** inclines obliquely downward and backward. It is bounded in front by the epiglottis; behind, by the interarytenoid

fold of mucous membrane; and at the sides, by the aryteno-epiglottidean folds and the tips of the arytenoid cartilages.

The **aryteno-epiglottidean folds** extend from the sides of the epiglottis to the summits of the arytenoid cartilages. They are composed of two layers of mucous membrane, between which are a supporting layer of connective tissue; the cornicula laryngis, which rest upon the summits of the arytenoid cartilages; the cuneiform cartilages, which lie in front of the arytenoid cartilages; and the aryteno-epiglottidean muscles. In viewing the larynx from above, the corniculum laryngis and cuneiform cartilage appear as two small swellings in the aryteno-epiglottidean fold. In these folds there is much loose submucous tissue, which is the chief site of the swelling in edema of the larynx. This swelling may be so extensive as to interfere seriously with the entrance of air into the larynx, and laryngotomy, tracheotomy, or intubation may become necessary.

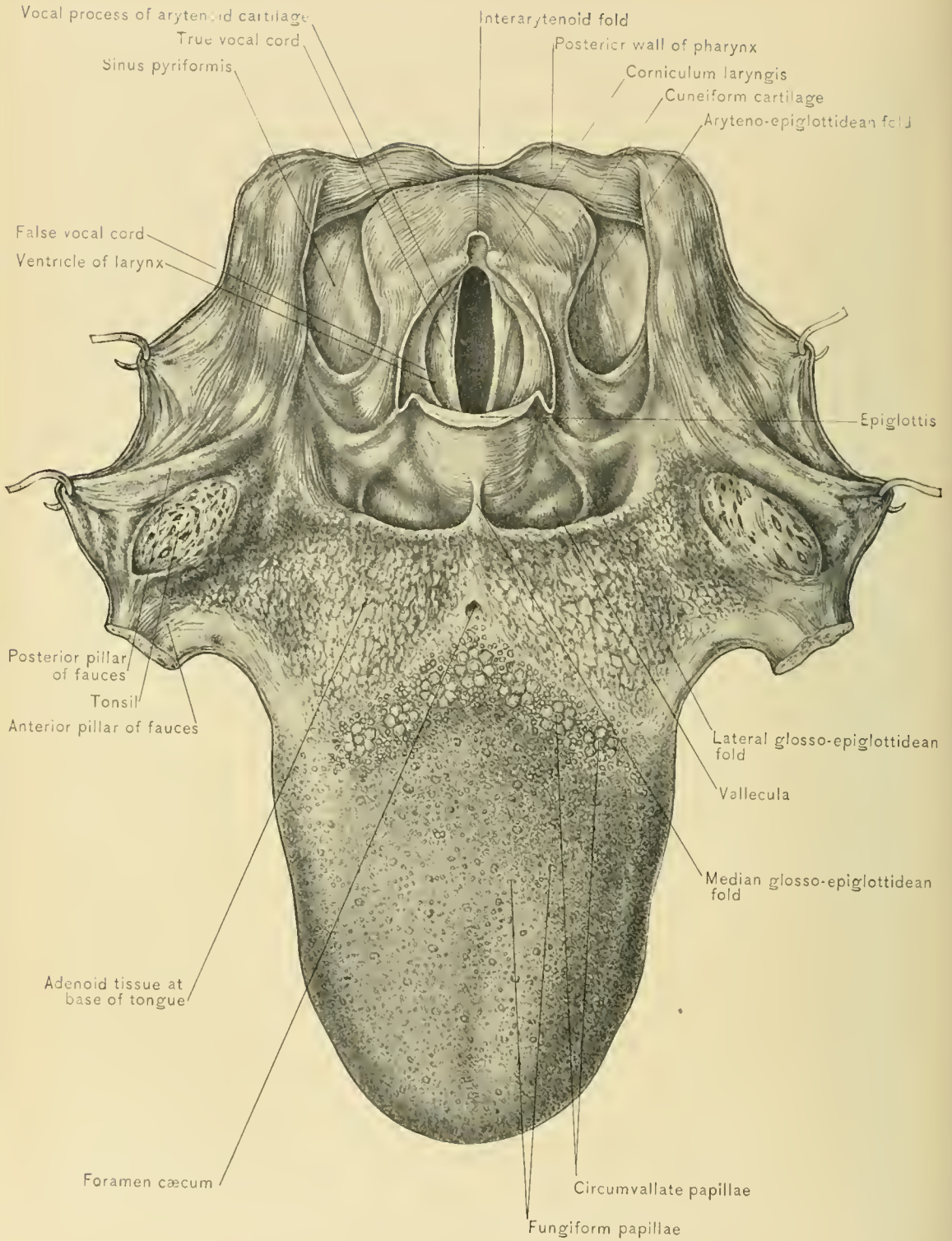
The **sinus pyriformis**, which is between the aryteno-epiglottidean fold and the ala of the thyroid cartilage, the **three glosso-epiglottidean folds**, and the **valleculæ**, between the epiglottis and the base of the tongue, have been previously described.

Two pairs of folds may be seen stretching across the cavity of the larynx. The upper pair is formed by the **false vocal cords**, and the lower pair by the **true cords**, which are more closely approximated. A depression—the **ventricle** of the larynx—exists between the true and false cords. The interval between the true vocal cords is the chink of the glottis, or **rima glottidis**. The true vocal cords divide the larynx into a supra-rimal and an infra-rimal portion.

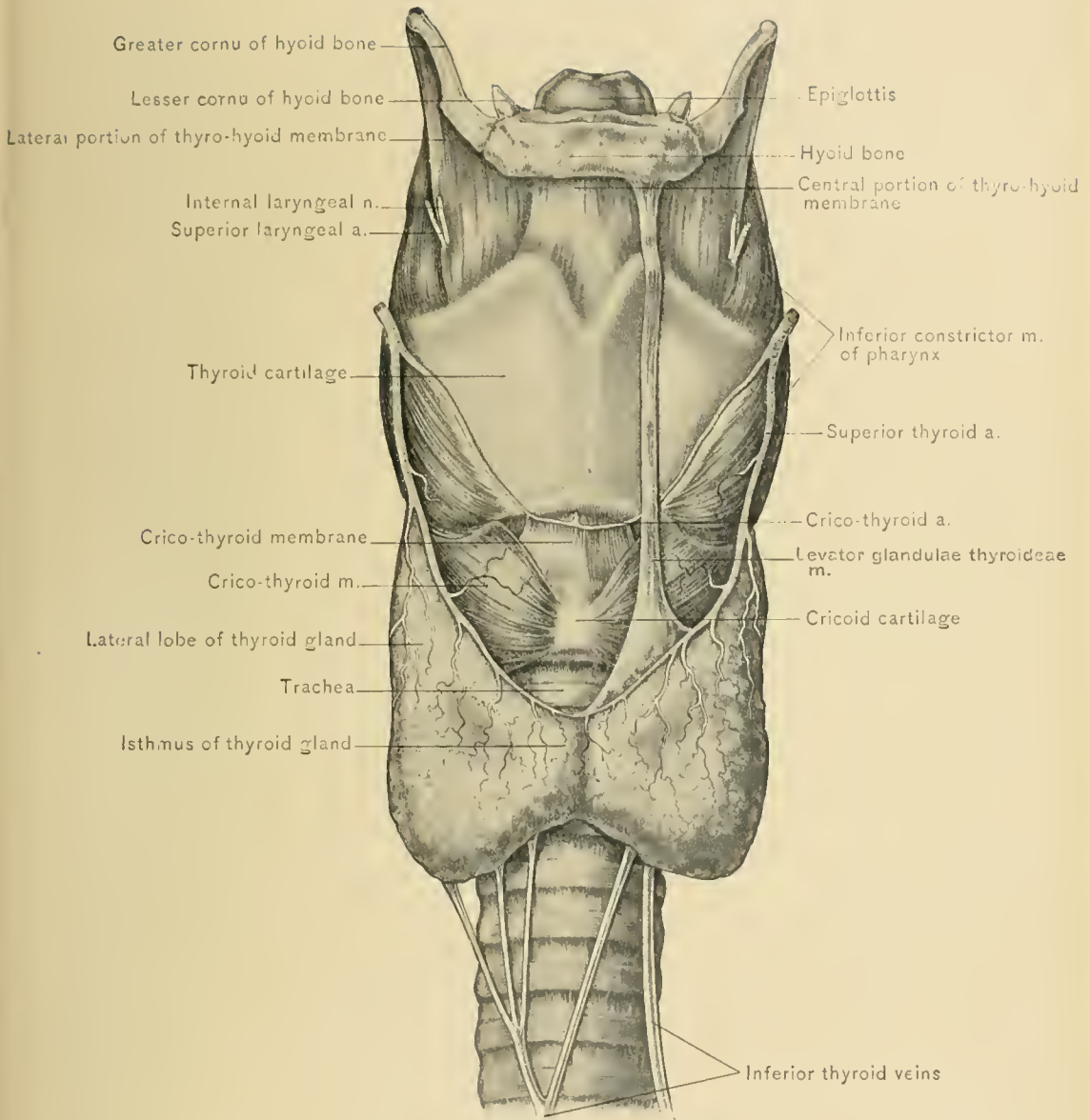
The **Supra-rimal Portion** of the larynx extends from the superior aperture to the true vocal cords. It is wide and triangular above, and becomes narrow below.

The **Infra-rimal Portion** is compressed laterally above, and becomes circular below, where it is surrounded by the cricoid cartilage and leads into the trachea. In laryngotomy the knife enters this portion of the larynx and is directed downward and backward to avoid the vocal cords.

DISSECTION.—Clean the anterior portion of the external surface of the larynx, entirely removing the attachments of the sterno-hyoid, omo-hyoid, and thyro-hyoid muscles from the hyoid bone, those of the thyro-hyoid and sterno-thyroid muscles from the thyroid cartilage, and the attachments of the inferior constrictor muscles of the pharynx from the thyroid and cricoid cartilages. Avoid injuring the superior laryngeal artery and the internal branch of the superior laryngeal nerve, which pierce the thyro-hyoid membrane; the external laryngeal nerve, which supplies the inferior constrictor and the crico-thyroid muscle; the crico-thyroid artery, which crosses the crico-thyroid membrane; and the recurrent laryngeal nerve and inferior laryngeal artery, which pass to the larynx behind

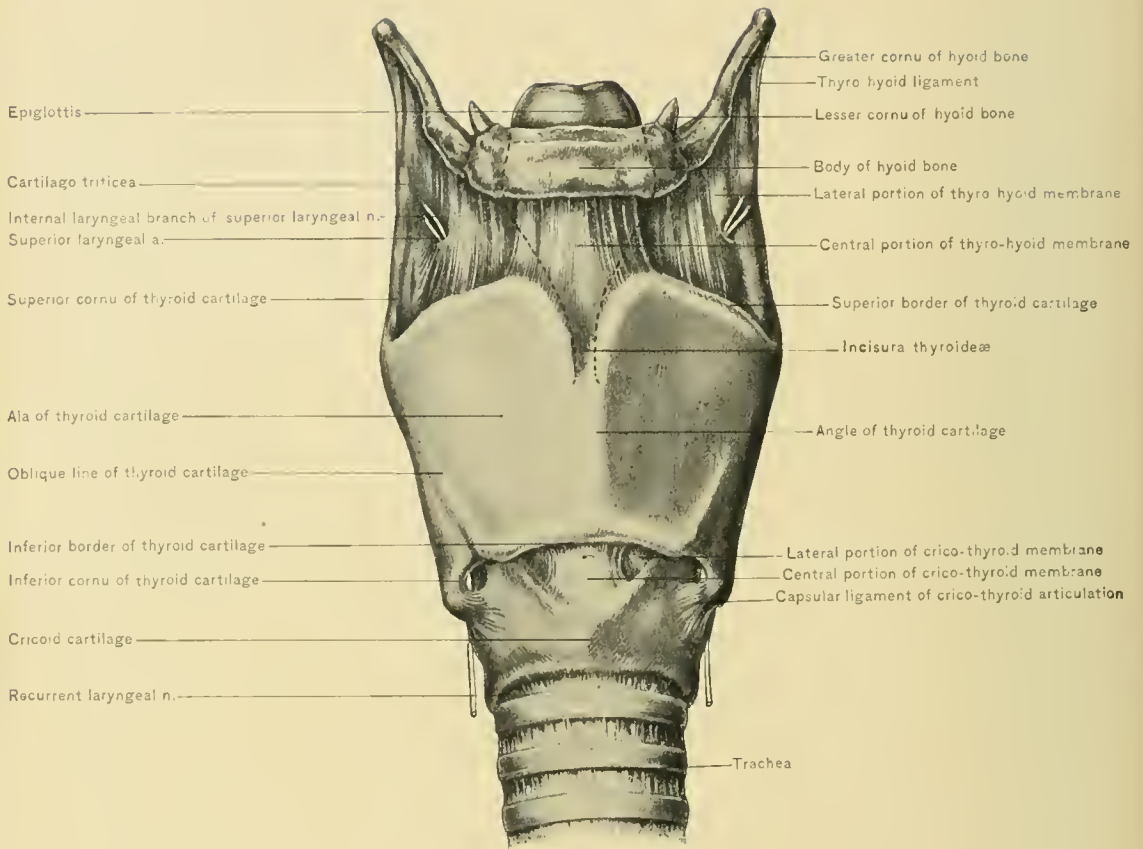


SUPERIOR APERTURE OF LARYNX.



LARYNX AND CRICO-THYROID MUSCLE.





ANTERIOR VIEW OF LARYNX, INCLUDING CRICO-THYROID MEMBRANES.

the crico-thyroid articulation. This dissection more thoroughly exposes the thyro-hyoid membrane, thyroid cartilage, crico-thyroid muscles, crico-thyroid membrane, and cricoid cartilage.

The **Thyro-hyoid Membrane**, which is largely composed of elastic fibers, extends from the upper border of the thyroid cartilage to the posterior superior border of the hyoid bone. Its central portion is thick and strong, and its lateral portions are thin and pierced by the superior laryngeal arteries and internal laryngeal nerves on their way to the interior of the larynx. The *thyro-hyoid bursa* intervenes between the thyro-hyoid membrane and the posterior surface of the hyoid bone, and may be enlarged and produce a cystic tumor and swelling in the median line of the neck. Laterally, the thyro-hyoid membrane is continuous with the thyro-hyoid ligaments. Behind the thyro-hyoid membrane lies the epiglottis, from which it is separated by a small amount of loose areolar tissue.

The **Thyro-hyoid Ligaments** are elastic bands connecting the superior cornua of the thyroid cartilage with the tips of the greater cornua of the hyoid bone. They frequently contain a nodule of cartilage (*cartilago triticea*), which may be ossified.

The **thyroid and cricoid cartilages** will be described later.

The **Crico-thyroid Muscle** arises from the anterior portion of the side of the cricoid cartilage, and is inserted into the anterior border of the inferior cornu and the outer surface of the lower border of the ala of the thyroid cartilage. Its upper fibers pass obliquely upward and backward, and its lower fibers horizontally backward. At its insertion it blends with the origin of the inferior constrictor muscle of the pharynx. It rests upon the cricoid cartilage and lateral portion of the crico-thyroid membrane. In the interval between the two crico-thyroid muscles the central portion of the crico-thyroid membrane is seen.

NERVE SUPPLY.—From the external laryngeal branch of the superior laryngeal nerve.

ACTION.—It depresses the anterior portion of the thyroid cartilage, thus making the vocal cords tense.

DISSECTION.—Remove the crico-thyroid muscle on one side, in order to more fully expose the crico-thyroid membrane.

The **Crico-thyroid Membrane** is chiefly composed of elastic fibers. It is divided into a central and two lateral portions, which are lined by the mucous membrane of the larynx. The **central portion** is thicker and stronger than the lateral portions, and extends from the middle of the upper border of the anterior portion of the cricoid cartilage to the corresponding portion of the lower border of the thyroid cartilage. Near the lower border of the thyroid cartilage it is crossed by the anastomosing crico-thyroid branches of the superior thyroid arteries, and is

pierced by one or two branches of the arch formed by the crico-thyroid arteries. It lies immediately beneath the interval between the two sterno-hyoid muscles and between the two sterno-thyroid muscles, and may be seen in the triangular interval between the inner margins of the crico-thyroid muscles. Laryngotomy is performed through the lower border of this portion of the membrane.

The **lateral portions** of the membrane are thin, and pass upward from the inner margin of the upper border of the cricoid cartilage to become continuous with the true vocal cords. The lateral portions of the crico-thyroid membrane are covered by the crico-thyroid, lateral crico-arytenoid, and thyro-arytenoid muscles.

DISSECTION.—Place the larynx, with the anterior aspect down, upon a board, and fasten it in that position with pins or tacks. Carefully remove the pharyngeal mucous membrane from its posterior aspect, preserving the recurrent laryngeal nerve and the inferior laryngeal artery, which is a branch of the inferior thyroid artery. Then remove the mucous membrane from the external surface of the aryteno-epiglottidean fold and the portion of the thyroid cartilage bounding the sinus pyriformis. Next cut through the crico-thyroid articulation on one side, and divide the ala of the thyroid cartilage about one-fourth of an inch to the same side of the angle of that cartilage. This dissection requires care to avoid injuring the underlying muscles, vocal cords, lateral portion of the crico-thyroid membrane, the superior laryngeal artery, the internal laryngeal nerve, and the terminal portion of the recurrent laryngeal nerve and inferior laryngeal artery.

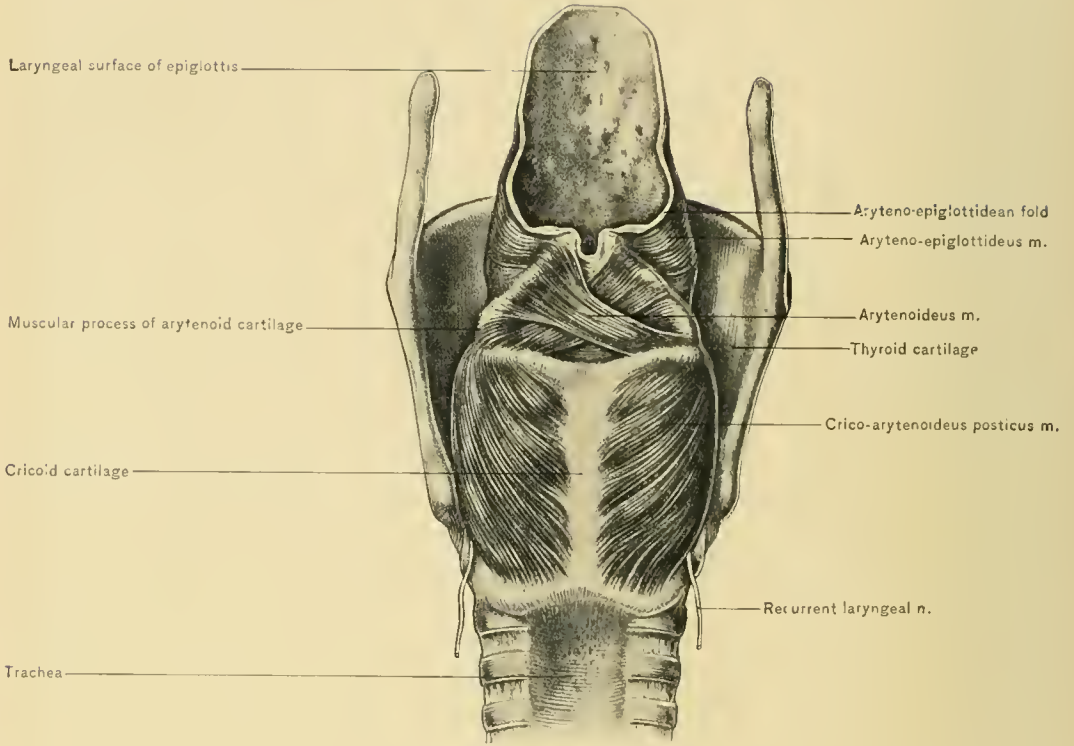
The **Crico-arytenoideus Posticus Muscle** arises from the surface at the side of the posterior median ridge of the cricoid cartilage. It is inserted into the posterior portion of the external angle (muscular process) of the arytenoid cartilage. Its upper fibers pass transversely outward; its middle fibers, obliquely upward and outward, and its lower fibers, vertically upward.

NERVE SUPPLY.—From the recurrent laryngeal nerve.

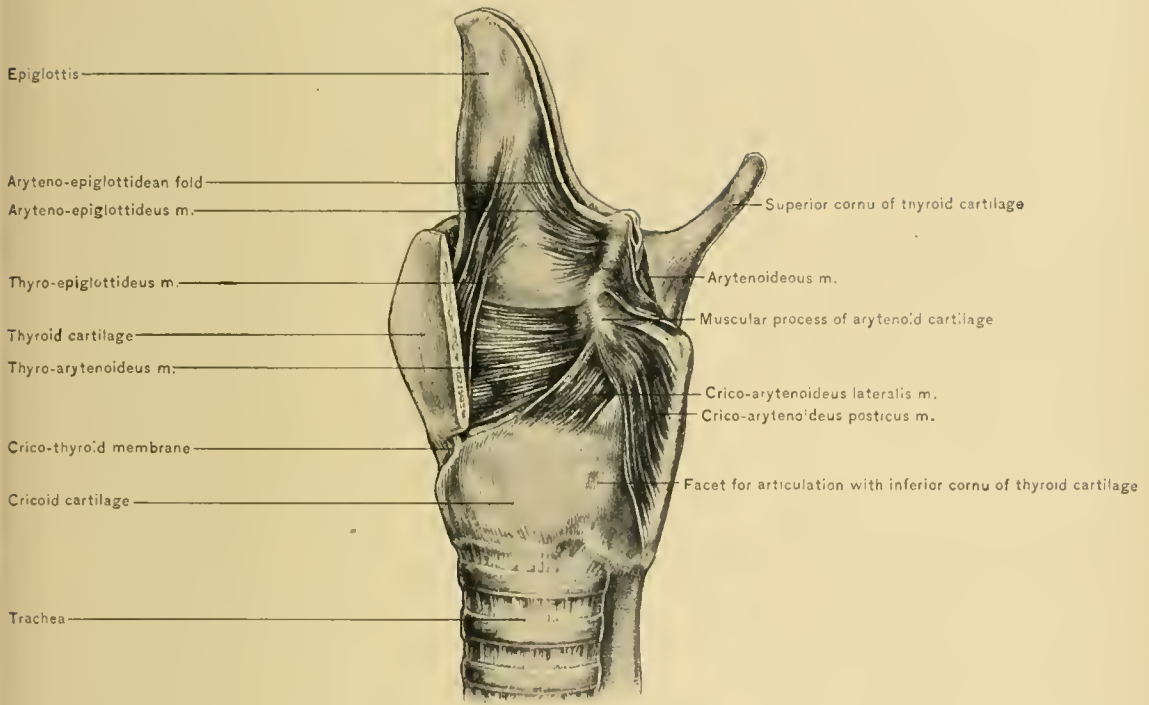
ACTION.—It rotates the arytenoid cartilage, and opens the rima glottidis, and its vertical fibers produce the gliding motion of that cartilage.

The **arytenoideus muscle** is a single muscle, situated between the arytenoid cartilages. It consists of superficial oblique fibers and a transverse portion. The oblique fibers arise from the external angle of one arytenoid cartilage, and pass upward and outward to the summit of the opposite arytenoid cartilage, crossing the oblique fibers from the other side in the form of the letter X. Some of these fibers pass around the apex of the arytenoid cartilage, and join the aryteno-epiglottideus muscle to form a sphincter for the superior aperture of the larynx. The transverse portion is thicker, and connects the posterior concave surfaces of the arytenoid cartilages.

NERVE SUPPLY.—From the recurrent and superior laryngeal nerves.



MUSCLES OF LARYNX—POSTERIOR VIEW.



MUSCLES OF LARYNX—LATERAL VIEW.

ACTION.—The arytenoideus muscle draws the arytenoid cartilages together and approximates the vocal cords.

The **Crico-arytenoideus Lateralis Muscle** arises from the upper border of the cricoid cartilage, in front of the crico-arytenoid articulation. It is inserted into the anterior and inferior aspects of the external angle of the arytenoid cartilage. It is covered by the thyroid cartilage and the crico-thyroid muscle, and rests upon the lateral portion of the crico-thyroid membrane. Its upper border, near its termination, blends with the thyro-arytenoid muscle.

NERVE SUPPLY.—From the recurrent laryngeal nerve.

ACTION.—It pulls the arytenoid cartilage forward, relaxing the vocal cords, and rotates that cartilage inward, approximating the cords and closing the rima glottidis.

The **Thyro-arytenoideus Muscle** is a quadrilateral band of muscular fibers which is divided into a superior and an inferior portion. The **superior portion** is broad and thin, and is situated above the level of the vocal cords, external to the ventricle of the larynx and the laryngeal pouch. It arises from the lower two-thirds of the inner surface of the ala, near the angle of the thyroid cartilage, and is inserted into the anterior surface and external angle of the arytenoid cartilage. The **inferior portion** is closely attached to the true vocal cord. It arises from the ala, near the angle of the thyroid cartilage, external to the attachment of the true vocal cord, and is inserted into the anterior angle (vocal process) and the adjacent portion of the anterior surface of the arytenoid cartilage. Some of its deeper fibers (*ary-vocalis* of Ludwig) are attached to the vocal cord at several points.

NERVE SUPPLY.—From the recurrent laryngeal nerve.

ACTION.—The thyro-arytenoid muscles relax the true vocal cords by drawing the arytenoid cartilages forward, and approximate them by drawing the vocal processes downward and inward. The ary-vocalis can make a portion of the true cord tense while the remainder is relaxed.

The **Thyro-epiglottideus Muscle** is composed of a few of the uppermost fibers of the thyro-arytenoideus muscle, which turn upward, external to the laryngeal pouch, to be attached to the side of the epiglottis.

NERVE SUPPLY.—From the recurrent laryngeal nerve.

ACTION.—It depresses the epiglottis.

The **Aryteno-epiglottideus Muscle** is situated in the aryteno-epiglottidean fold. It arises from the apex and anterior border of the arytenoid cartilage, above the false vocal cord. Its upper fibers are inserted into the mucous membrane at the margin of the aryteno-epiglottidean fold, and its lower fibers are inserted into the side of the epiglottis. It is joined by some of the fibers of the oblique portion of the arytenoideus muscle, which pass around the apex of the arytenoid cartilage.

NERVE SUPPLY.—From the recurrent laryngeal nerve.

ACTION.—It pulls the epiglottis backward and compresses the laryngeal pouch, and with the assistance of the arytenoideus muscle acts as a sphincter of the superior aperture of the larynx.

The muscles just described—viz., the two crico-thyroidei, two crico-arytenoidei postici, one arytenoideus, two crico-arytenoidei laterales, two thyro-arytenoidei, two thyro-epiglottidei, and two aryteno-epiglottidei—are the **intrinsic muscles of the larynx**.

The **extrinsic muscles of the larynx**—viz., the sterno-thyroid, thyro-hyoid, stylo-pharyngei, and palato-pharyngei—have been described with the neck and pharynx. These muscles are assisted by all the muscles which elevate or depress the hyoid bone and larynx or hold the hyoid bone firm.

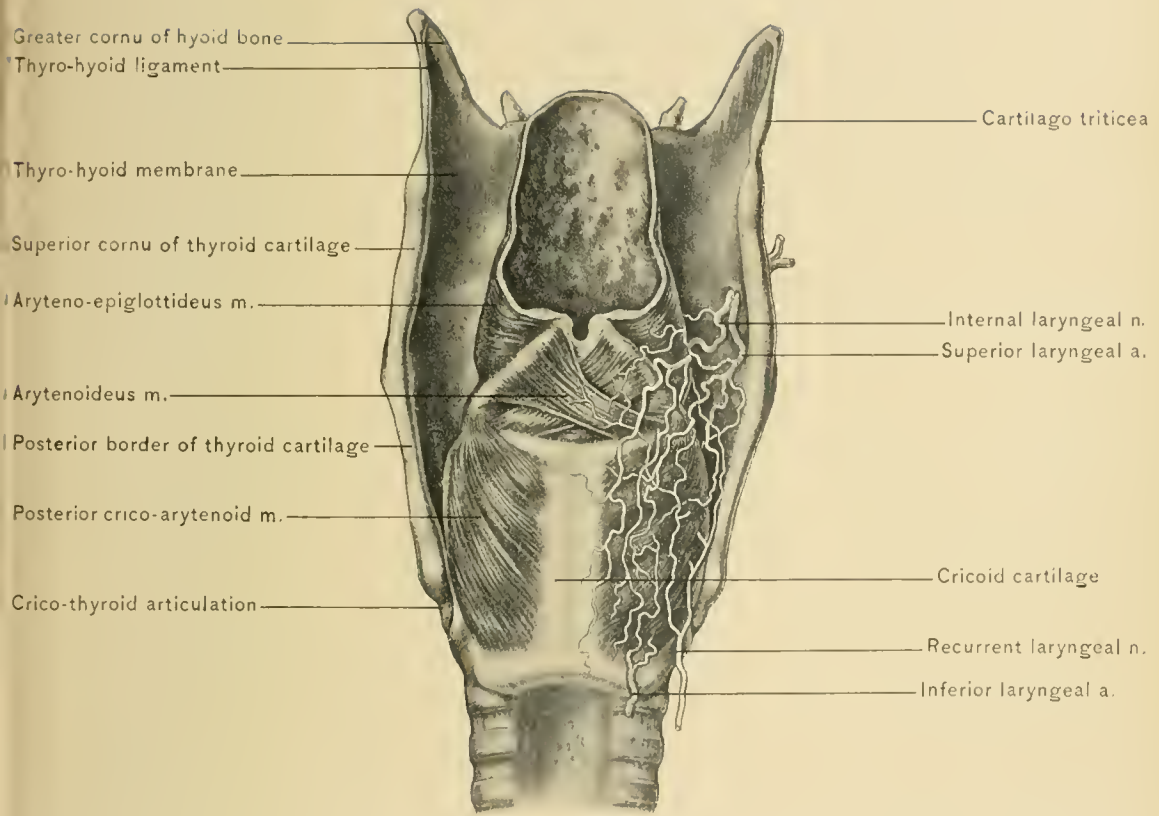
In **Laryngismus Stridulus**, or laryngeal asthma, there occurs spasm of the muscles of the larynx. This condition occurs most frequently in children, is usually due to reflected irritation, as after eating indigestible food, and may be caused by irritation of the nerve centers in the medulla oblongata. In adults it may be caused by pressure upon the recurrent laryngeal nerve by aneurysms, malignant growths of the esophagus or posterior mediastinal glands, or enlargement of the thyroid body. It may also be produced by irritation from foreign bodies in the larynx or lower part of the pharynx.

NERVE SUPPLY OF THE LARYNX.—From the superior laryngeal and recurrent laryngeal branches of the pneumogastric nerve.

The **Superior Laryngeal Nerve** divides into the external and internal laryngeal nerves. The **external laryngeal nerve** passes downward with the superior thyroid artery, and supplies the crico-thyroid muscle. The **internal laryngeal nerve** pierces the thyro-hyoid membrane with the superior laryngeal artery, passes downward and backward, ramifies upon the intrinsic muscles in the lateral wall of the larynx, and supplies the mucous membrane, sending a branch to the arytenoideus muscle. The internal laryngeal nerve is the *sensory nerve* of the larynx.

The **Recurrent Laryngeal Nerve** is the *motor nerve* of the larynx, and reaches it behind the crico-thyroid articulation, where it divides into an anterior and a posterior branch. The posterior branch supplies the arytenoideus muscle and the crico-arytenoideus posticus muscle, and communicates with the internal laryngeal branch of the superior laryngeal nerve; the anterior branch supplies all the other intrinsic muscles except the crico-thyroid muscle.

Paralysis of the Right Side of the Larynx may be caused by pressure upon the right recurrent laryngeal nerve, produced by aneurysm of the first portion of the right subclavian artery or lower portion of the right common carotid artery,



NERVES AND ARTERIES OF LARYNX.

enlargement of the thyroid body, malignant disease of the esophagus, and cicatrices at the apex of the right pleura, as in phthisis.

Paralysis of the Left Side of the Larynx may be caused by pressure upon the left recurrent laryngeal nerve, produced by aneurysm of the arch of the aorta and lower portion of the left common carotid artery, malignant disease of the esophagus, and enlargement of the thyroid body. The left side of the larynx is more frequently paralyzed than the right; this is explained by the longer course of the left recurrent laryngeal nerve, and by its relation with the arch of the aorta, which is more commonly affected by aneurysm than the first portion of the right subclavian artery. Moderate pressure upon one of the recurrent laryngeal nerves causes spasm of the muscles of one side of the larynx, dyspnea, and change of voice; greater pressure causes paralysis and change of voice. Both nerves may be paralyzed by a lesion of the medulla oblongata, as in labio-glosso-pharyngeal paralysis or disseminated sclerosis, or by pressure from a goiter or malignant growth of the esophagus. In bilateral paralysis the true vocal cords are immovable, and the rima glottidis is in the position assumed in quiet breathing.

BLOOD SUPPLY OF THE LARYNX.—From the superior laryngeal and inferior laryngeal arteries, and some twigs from the dorsalis linguæ artery, which supply the epiglottis.

The **Superior Laryngeal Artery** is a branch of the superior thyroid artery, and pierces the thyro-hyoid membrane with the internal laryngeal nerve. It runs downward and backward with that nerve to anastomose with the inferior laryngeal artery.

The **Inferior Laryngeal Artery** is derived from the inferior thyroid artery, and accompanies the terminal portion of the recurrent laryngeal nerve.

The Veins of the Larynx.—The superior laryngeal veins empty into the superior thyroid veins, and the inferior laryngeal veins into the inferior thyroid veins.

The **Lymphatic Vessels of the Larynx** terminate in the deep cervical chain of lymphatic glands. The lymphatics from the upper or supra-rimal portion of the larynx pass through the thyro-hyoid membrane with the superior laryngeal vessels, and join the superior set of deep cervical glands near the bifurcation of the common carotid artery. The lymphatics from the lower or infra-rimal portion of the larynx pierce the crico-thyroid membrane, join the prelaryngeal gland situated upon that membrane, and pass thence to some lateral laryngeal glands situated between the lower portion of the larynx and the lateral lobes of the thyroid body. The efferent vessels from the lateral or inferior laryngeal glands terminate in the inferior set of deep cervical glands.

DISSECTION.—Remove the muscles from one side of the larynx—viz., the

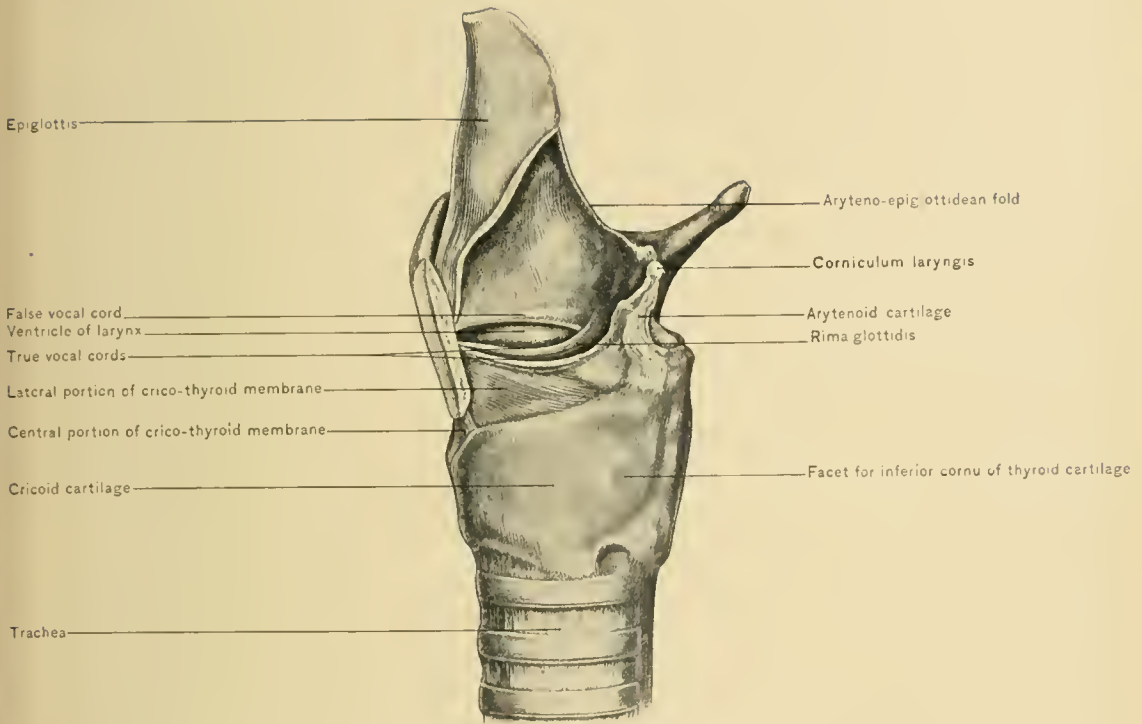
lateral crico-thyroid, thyro-arytenoid, thyro-epiglottideus, and aryteno-epiglottideus muscles. Next cut away the mucous membrane and connective tissue from the same side, from the upper border of the true vocal cord to the upper margin of the aryteno-epiglottidean fold, preserving intact the cuneiform cartilage which lies in that fold. The lateral portion of the crico-thyroid membrane, both true vocal cords, and one side of the interior of the larynx are exposed by this procedure.

The **True or Inferior Vocal Cords**, or inferior thyro-arytenoid ligaments, are two pearly white, fibro-elastic bands stretching between the anterior angles (vocal processes) of the arytenoid cartilages and the retiring angle of the thyroid cartilage on each side of the median line. They are continuous with the lateral portions of the crico-thyroid membrane, and on transverse section are prismatic in form. The free border is directed upward and inward, and vibrates to produce the voice. They are covered internally by a very thin layer of mucous membrane, through which they appear as white bands in laryngoscopic examination. They are longer in the adult male than in women and children.

The **Rima Glottidis**, or chink of the glottis, is bounded in its anterior portion on each side by the true vocal cords, and in its posterior portion on each side by the internal surfaces of the arytenoid cartilages. According to Krause, its length, in the male, varies from nineteen to twenty-five millimeters, and in the female, from fourteen to seventeen millimeters. The portion of the chink between the true cords is called the **glottis vocalis**, for it is closely related to phonation; the portion between the bases of the arytenoid cartilages is called the **glottis respiratoria**, because it is closed in phonation, and affords additional space for passage of air in respiration. In ordinary respiration the rima glottidis is almost triangular in shape, but is more nearly of a lanceolate form, as there is a slight angle at the junction of the true cord with the arytenoid cartilage. The apex of the triangle or point of the lance is directed forward, and is situated at the retiring angle of the thyroid cartilage, the base lying between the arytenoid cartilages. During phonation the rima glottidis is closed, and air is forced through the narrow slit thus formed, causing vibration of the thin free borders of the true cords.

The **False or Superior Vocal Cords** are not concerned in phonation. They are two rounded folds of mucous membrane which cover two elastic bands, the **superior thyro-arytenoid ligaments**. Below they present a free, arched border, which bounds the ventricle of the larynx above. They are situated above the true cords upon each side of the larynx, but as they are more widely separated, the true cords are seen between them in a laryngoscopic examination. The space between them is called the **false glottis**.

The **Ventricles or Sinuses of the Larynx**, one on each side, are the depressions between the true and false cords. They permit free vibration of the true



LATERAL VIEW OF INTERIOR OF LARYNX.

cords. They partially undermine the false cords, and a probe or grooved director passed into one of them will enter a diverticulum which passes beneath the anterior portion of the false cord, and which usually projects upward as high as the upper border of the ala of the thyroid cartilage. This diverticulum is the **laryngeal pouch or sac**. The ventricles of the larynx may retain small foreign bodies which have entered the larynx. Through irritation these bodies may cause spasm of the muscles of the larynx and asphyxia.

The **Fossa Innominata** is a depression situated behind the margin of the epiglottis, on the lateral wall of the larynx, and between the aryteno-epiglottidean fold and the false vocal cord. It is indistinct except during phonation.

The **Mucous Membrane of the Larynx** is thin and closely adherent over the true cords, but is thicker, more vascular, and, excepting over the epiglottis, loosely adherent elsewhere. It is continuous above with the mucous membrane of the pharynx, and below with that of the trachea, so that an inflammation of the mucous membrane may spread, by continuity, from the pharynx to the larynx to the trachea. This course is frequently observed in diphtheria. Irritation of this membrane, as by a foreign body or mucus in laryngitis, causes cough, or spasm of the muscles of the larynx, as in croup or laryngismus stridulus.

Edema of the mucous membrane of the larynx or **edema of the glottis** is frequently associated with severe attacks of acute laryngitis, as after swallowing hot or irritating liquids or the inhalation of irritating vapors. Unless the submucous effusion of serum is allowed to escape by scarification, death may result from asphyxia. Intubation of the larynx, laryngotomy, or tracheotomy may be required to prevent suffocation. As the submucous tissue is more plentiful at the superior aperture of the larynx, and especially upon the epiglottis, the swelling is most extensive in this location.

The **Mucous Glands of the Larynx** are found in the mucous membrane of all portions of the larynx except over the true cords. They are especially numerous in the aryteno-epiglottidean folds, in front of the arytenoid cartilages, in the laryngeal sacs, and upon the posterior surface of the epiglottis, in which they are lodged in pits. These glands keep the larynx moist, and those in the laryngeal sacs are especially active in lubricating the true vocal cords during phonation. After long-continued speaking, especially if in the open air, these glands are unable to preserve the moist condition of the true vocal cords, and the voice becomes husky. These same conditions are likely to cause a determination of blood to the larynx and produce an acute laryngitis. When the ducts of these glands become occluded, cystic tumors appear in the mucous membrane of the larynx.

DISSECTION.—Clean the cartilages of the larynx, preserving the slender liga-

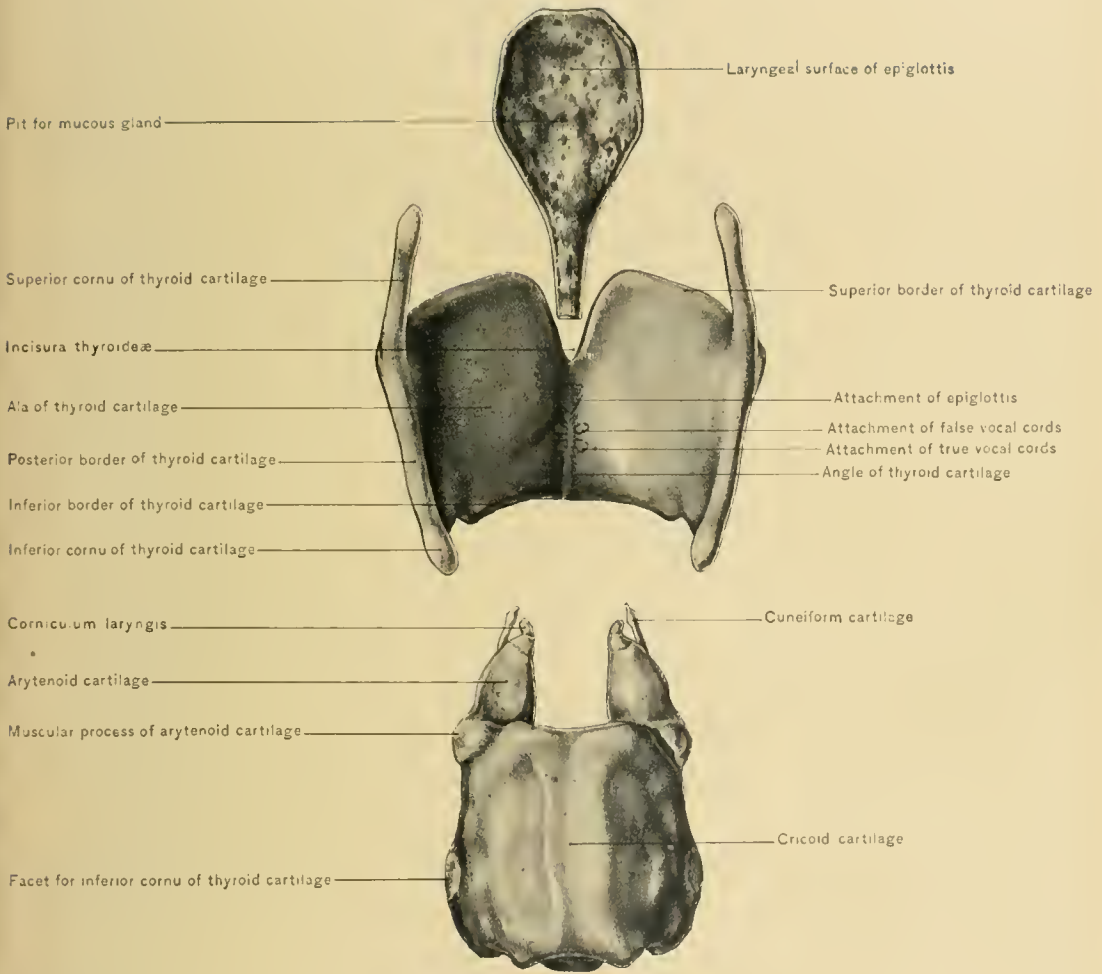
ment connecting the cornicula laryngis with the cricoid cartilage (*ligamentum jugale*), the superior thyro-arytenoid ligaments, which are located in the false cords, the inferior thyro-arytenoid ligaments or true vocal cords, and the glosso-epiglottidean and hyo-epiglottidean ligaments.

The **Cartilages of the Larynx** are nine in number—viz., the epiglottis, thyroid, and cricoid, which are unpaired, and two arytenoid, two cornicula laryngis, and two cuneiform cartilages.

The **epiglottis** is composed of yellow elastic cartilage. It is leaf-like in form, its stalk being directed downward and attached to the internal surface of the angle of the thyroid cartilage by an elastic band—the *thyro-epiglottidean ligament*. Its uppermost portion is free, and is situated behind the lowermost portion of the base of the tongue, the greater part of which holds a vertical position above it. Its *postero-inferior surface* is covered by mucous membrane. It is concave from side to side, looks toward the larynx, and contains numerous pits, which are occupied by mucous glands. About its center this surface projects backward and forms a low eminence, the cushion or *tubercle of the epiglottis*. Its *antero-superior surface*, except in its uppermost portion, is not covered by mucous membrane. It is convex from side to side and looks toward the thyro-hyoid membrane, hyoid bone, and a small portion of the base of the tongue. This surface is attached to the thyro-hyoid membrane by intervening fat and loose, cellular, elastic tissue, called the *periglottis*. It is attached to the hyoid bone by the *hyo-epiglottidean ligament* or hypoglossal membrane, which is composed of elastic tissue; and to the base of the tongue by the three *glosso-epiglottidean folds*, which contain three delicate elastic *glosso-epiglottidean ligaments*. The *lateral margins* are curved backward; and for nearly their whole extent are attached to the aryteno-epiglottidean folds. Into these margins the aryteno-epiglottidean and thyro-epiglottidean muscles are inserted. Its upper border is free and curls forward.

The epiglottis is the door which guards the superior aperture of the larynx. It lies in a vertical position during respiration and phonation, and, dropping backward, closes the superior aperture of the larynx during deglutition. It is drawn forward into the vertical position by muscles which are attached to the tongue and hyoid bone—*i. e.*, the genio-hyo-glossus, genio-hyoid, and mylo-hyoid muscles. The epiglottis is depressed by the aryteno-epiglottideus and thyro-epiglottideus muscles; they are small and have but slight power. Occlusion of the superior aperture of the larynx is produced by elevation of that organ; by this means the larynx approaches the base of the tongue, and the epiglottis is brought against the margins of the superior aperture of the larynx.

After the epiglottis has been destroyed by ulceration, food and liquids may enter the larynx during deglutition; to prevent such a disaster the patient should



CARTILAGES OF LARYNX.



be fed through a stomach tube; or he may successfully feed himself by leaning his body far forward and sucking liquid food through a tube. After a time the muscles of the larynx may act as a sphincter, thus preventing food from entering the larynx.

The **thyroid cartilage** is of the hyaline variety, and forms the greater part of the anterior and lateral walls of the larynx. It is composed of two wings, or *alæ*, connected in the median line, forming almost a right angle.

The *alæ* are irregularly quadrilateral in form. Their *upper borders*, where they meet in the median line, dip downward, leaving a deep thyroid notch or *incisura thyroideæ*. Behind they terminate in the anterior margins of the superior cornua. Anterior to the superior cornua each *alæ* presents a tubercle, which is placed at the upper end of the oblique line. To the upper border of the *alæ* is attached the thyro-hyoid membrane.

The *lower border of the cartilage* is not so sinuous as the upper border; it terminates, behind, in the anterior margins of the inferior cornua; and presents a tubercle, which is located at the lower end of the oblique line. It gives attachment to the central portion of the crico-thyroid membrane and to the crico-thyroid muscles.

The *posterior border* is continuous with the posterior borders of the superior and inferior cornua. It gives attachment to the stylo-pharyngeus and palato-pharyngeus muscles, and to the pharyngeal aponeurosis.

The *external surface of the alæ* presents an oblique line, which inclines downward and slightly forward. The oblique line gives attachment to the sterno-thyroid and thyro-hyoid muscles. The surface behind the oblique line is covered by the inferior constrictor muscle of the pharynx, which arises just behind the line.

The *inner surface of the alæ* is slightly concave. It is in relation with the mucous membrane of the sinus pyriformis, with the thyro-hyoid and lateral crico-arytenoid muscles, and with the lateral portion of the crico-thyroid membrane.

The *superior cornua* are longer than the inferior, and extend upward, inward, and backward. They are attached to the greater cornua of the hyoid bone by the thyro-hyoid ligaments.

The *inferior cornua* are short, and directed downward, forward, and inward. On their inner surfaces they have concave facets for articulation with the cricoid cartilage. They give attachment to the inferior constrictor and crico-thyroid muscles, and to the capsular ligaments of the crico-thyroid articulations.

The *angle* is at the line of junction of the *alæ*, is more prominent above, where it is called the *pomum Adami*, and lies beneath the interval between the sterno-hyoid muscles. Internally it gives attachment, on each side of the median line, to the true and the false vocal cords. For the purpose of making the interior

of the larynx accessible, the thyroid cartilage is sometimes split longitudinally, from the notch in the upper border to the lower border. In this operation it is important to divide the cartilage exactly in the median line, so as not to injure the attachments of the vocal cords. When the cartilage has been divided, the two halves are turned aside, thus exposing the interior of the larynx and enabling the operator to remove a small tumor or foreign body.

Fractures of the thyroid cartilage are rare, but are more common than in the other cartilages of the larynx. They are usually produced by external direct violence, as choking or throttling, and the line of fracture is usually in the median line, at the angle. There are pain, swelling, and tenderness in and around the larynx, with increased pain on swallowing, coughing, or talking. The moist crepitus which can be produced by forcibly moving a normal thyroid cartilage laterally must not be mistaken for that present as a result of fracture.

Ossification of the thyroid cartilage frequently occurs, and may commence at the age of twenty years.

The **cricoid cartilage** is the strongest of the cartilages of the larynx; it is a firm base which supports the other portions of the larynx, and rests upon the upper end of the trachea. It is hyaline in structure, completely encircles the lower portion of the cavity of the larynx, and, like a signet ring, is broader behind than in front.

Its *external surface* gives origin, in front, to the crico-thyroid muscle, and, at the side, to the inferior constrictor muscle of the pharynx. Where its lateral aspect joins the posterior there is a facet for articulation with the inferior cornu of the thyroid cartilage. The posterior portion of this surface presents a median ridge, which gives origin to the longitudinal muscular fibers of the esophagus, and a depression on each side of the ridge, which gives origin to the posterior crico-arytenoid muscles.

The *upper border* is horizontal for a short distance, but is soon directed obliquely downward and forward. Where the oblique portion begins there is a facet upon which the base of the arytenoid cartilage rests. The anterior and lateral portions of the upper border give attachment to the crico-thyroid membrane and the lateral crico-thyroid muscle.

The *inferior border* is horizontal. It is attached to the first ring of the trachea by fibrous membrane like that between the tracheal rings. The internal surface is covered by the mucous membrane of the larynx.

Ossification is not uncommon in the cricoid cartilage, but in the smaller cartilages of the larynx that stage of development is seldom attained.

The **cuneiform cartilages**, or cartilages of Wrisberg, should next be studied. They are two small conic masses of yellow elastic cartilage situated in the aryteno-

epiglottidean folds, just anterior to the cornicula laryngis. Sometimes they are long and club-shaped; occasionally they are absent.

The **cornicula laryngis**, or cartilages of Santorini, are two pyramidal masses of yellow elastic cartilage situated upon the summits of the arytenoid cartilages in the aryteno-epiglottidean folds. They are directed inward. There may be a joint between them and the arytenoid cartilages, or they may be directly continuous with those cartilages. Their summits are attached to the upper border of the posterior portion of the cricoid cartilage by the *ligamentum jugale*. The *ligamentum jugale* is Y-shaped, the stem of the Y being attached to the cricoid cartilage and the two limbs to the summits of the cornicula laryngis.

The cornicula laryngis and cuneiform cartilages, on laryngoscopic examination, appear as two whitish swellings in the posterior extremity of each aryteno-epiglottidean fold.

The **arytenoid cartilages** are two irregularly pyramidal bodies, which rest upon the upper border of the posterior portion of the cricoid cartilage. Their greater portion is composed of hyaline cartilage; the remainder, their apices, being yellow elastic cartilage. Each has an apex, a base, three sides, three borders, and three angles. The *apex* is directed upward, backward, and inward, and supports the corniculum laryngis. The *base* is concave, and presents on its inner side a facet for articulation with the cricoid cartilage. The three sides are an internal, a posterior, and an antero-external or anterior surface.

The *internal surface* is directed toward the corresponding surface of the opposite arytenoid cartilage, and is covered by mucous membrane.

The *posterior surface* is concave, and gives attachment to the arytenoideus muscle.

The *antero-external or anterior surface* is rough and irregular. It gives attachment to the thyro-arytenoideus muscle and the superior thyro-arytenoid ligament, which supports the mucous membrane of the false vocal cord.

The three borders are the internal, external, and anterior.

The *internal border* is directed inward and backward; the *external border* slopes downward and outward to the external angle; the *anterior border* slopes downward and forward to the anterior angle. The three angles are the internal, external, and anterior. The *internal angle* is situated at the postero-internal angle of the base. It gives attachment to the transverse or crico-arytenoid ligament. The *external angle* or muscular process is located at the external angle of the base. It gives attachment anteriorly to the lateral crico-arytenoid muscle, and posteriorly to the posterior crico-arytenoid muscle. The *anterior angle* or vocal process, situated at the anterior angle of the base, is long and pointed, and gives attachment to the true vocal cord or inferior thyro-arytenoid ligament.

The **hyaline cartilages of the larynx**—namely, the thyroid, cricoid, arytenoid, and cartilago triticea—frequently undergo ossification.

When any of the cartilages of the larynx are fractured, the patient should be placed on his back, prohibited from talking, and fed through the rectum; it may be necessary to practise intubation, laryngotomy, or tracheotomy.

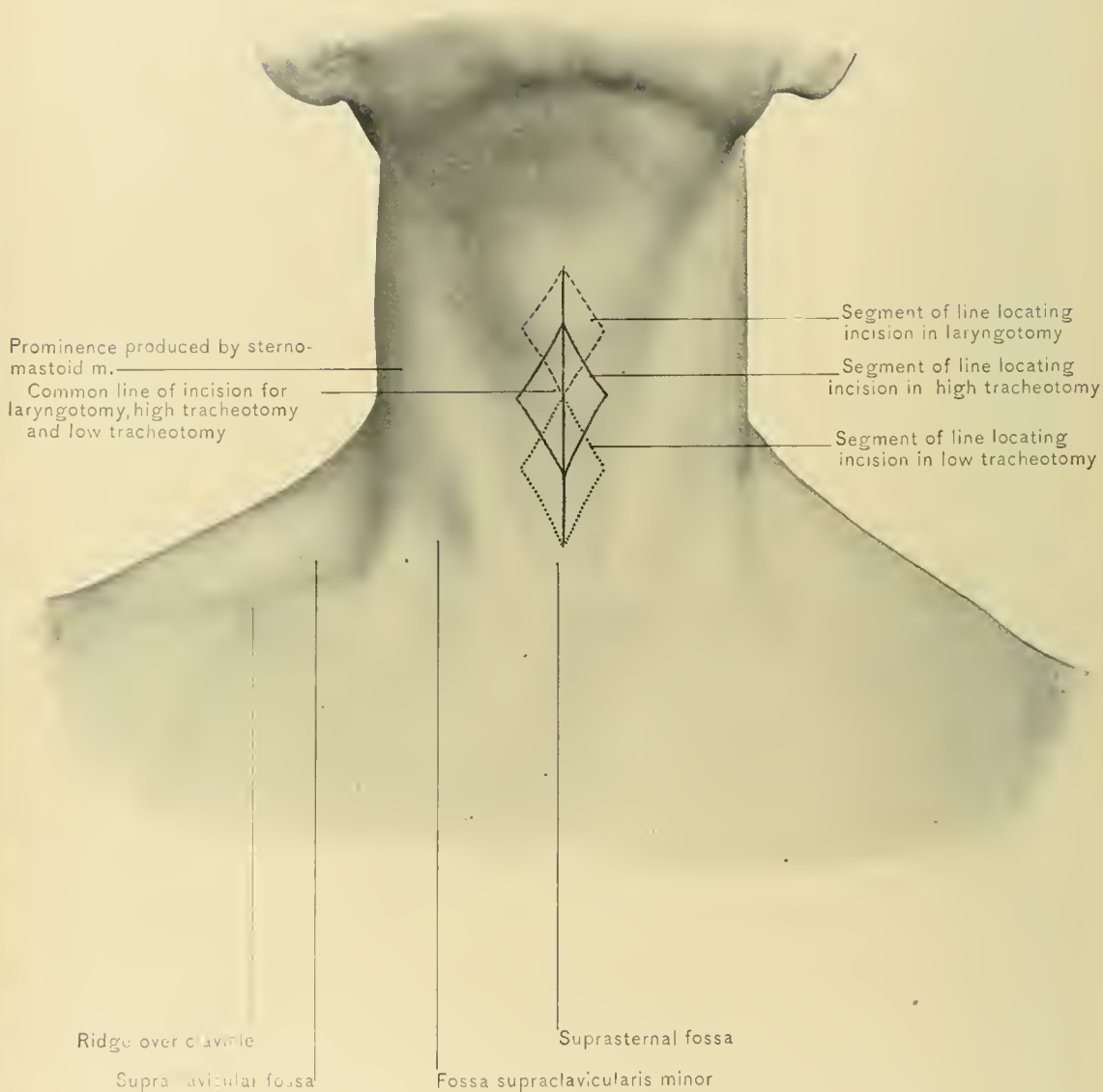
The **Joints of the Larynx** are the crico-thyroid and crico-arytenoid.

The **crico-thyroid joints** are formed by the articulation of the inferior cornua of the thyroid cartilage with the cricoid cartilage. They are lined by synovial membrane, and have capsular ligaments which are stronger posteriorly. Their movements are gliding of the cricoid cartilage upward and backward, and rotatory around a transverse axis.

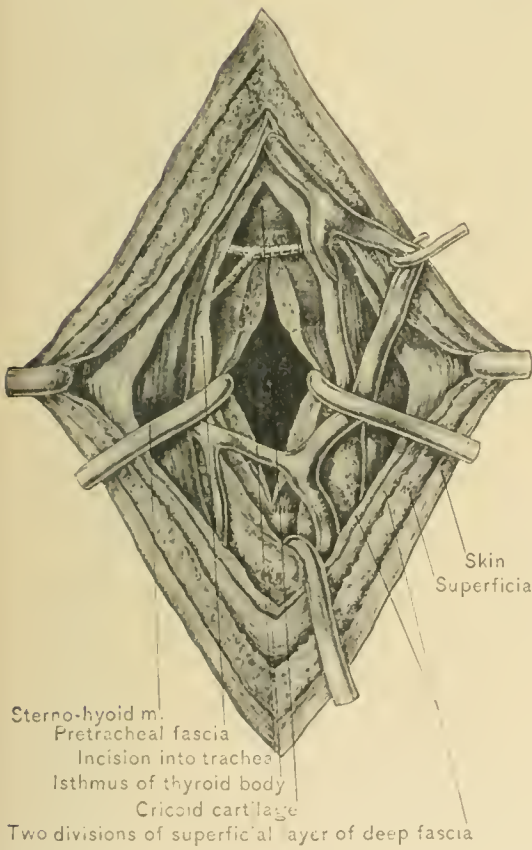
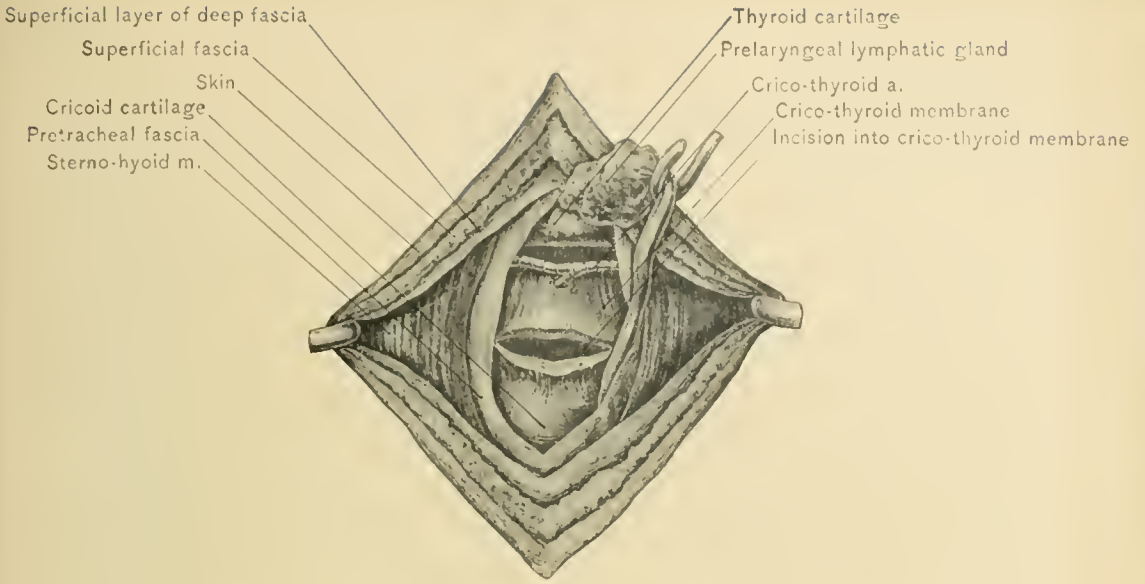
The **crico-arytenoid joints** are formed by the articulation of the cricoid cartilage with the bases of the arytenoid cartilages. They have a capsular, a posterior crico-arytenoid, and a transverse or crico-arytenoid ligament; and each has a synovial membrane. The capsular ligament is loose and allows free movement. The posterior crico-arytenoid ligament arrests the forward movement of the arytenoid cartilage. The transverse or crico-arytenoid ligament connects the upper border of the cricoid cartilage with the internal angles of the arytenoid cartilages. The crico-arytenoid joints permit of the arytenoid cartilages gliding inward or outward or rotating around a vertical axis. These movements permit the vocal processes to rotate inward and the arytenoid cartilages to be drawn together, closing the rima glottidis, as in phonation; or they allow the vocal processes to rotate outward and the arytenoid cartilages to be separated, thus opening the rima glottidis as in respiration.

The **Ligaments of the Larynx** not associated with the joints are the thyrohyoid and crico-thyroid membranes; the thyrohyoid ligaments, which have been described; the superior thyro-arytenoid ligaments, described with the false vocal cords; and the inferior thyro-arytenoid ligaments, described as the true vocal cords.

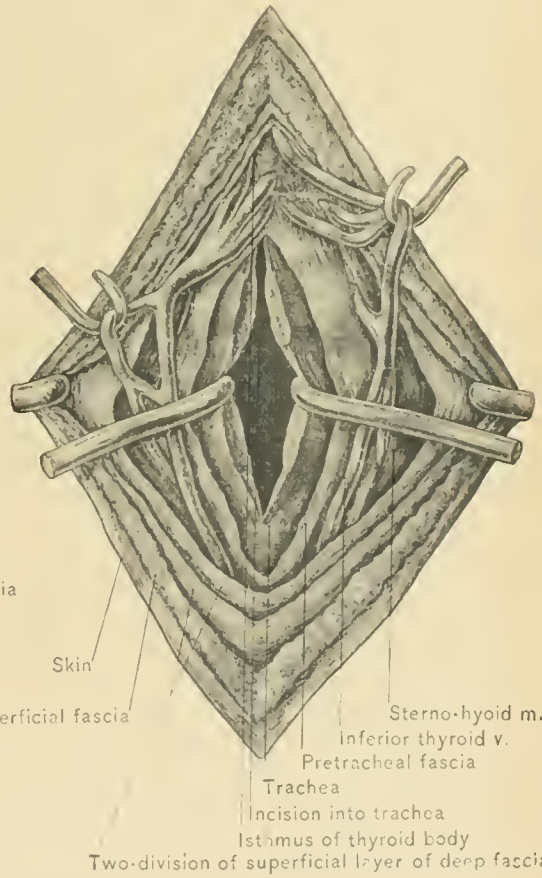
In **Laryngoscopic Examination** the patient should sit at a higher level than the physician; his tongue should be drawn forward so that the base of that organ will not hang backward over the epiglottis and superior aperture of the larynx; his head should be thrown backward so that the reflection of the interior of the larynx, instead of the image of the base of the tongue, will be seen. When the mirror has been introduced into the oro-pharynx, its handle must usually be depressed. The epiglottis will be seen in its upper part; the arytenoid cartilages, cartilages of Santorini and Wrisberg, in its lower part; the false vocal cords, ventricles, and true vocal cords, on their corresponding sides; and the anterior wall of the trachea and, occasionally, its bifurcation may be seen. The true vocal cords



SURFACE MARKS OF NECK AND LINES OF INCISIONS FOR LARYNGOTOMY AND TRACHEOTOMY.



HIGH TRACHEOTOMY.



LOW TRACHEOTOMY.

appear as white bands more nearly approximated than the false cords. In acute laryngitis the true vocal cords are of a pinkish color, and the remainder of the larynx is red and swollen. This swelling, or edema, of the glottis is produced by a serous infiltration into the submucous areolar tissue; and if present to a marked degree, is best treated by scarification; it may, however, necessitate intubation, laryngotomy, or tracheotomy.

The **Hyoid Bone** is an important adjunct to the larynx. It prevents collapse of the pharynx over the superior aperture of the larynx, and from it the larynx is suspended by the thyro-hyoid membrane and thyro-hyoid ligaments. The greater cornua of this bone are important guides. The tip of the greater cornu is opposite the origin of the lingual artery, just above the level of that of the superior thyroid artery, and just below the level of the origin of the facial artery. In the operation for ligation of the lingual artery in the lingual triangle the incision is made just above and parallel with the greater cornu of the hyoid bone. This bone is sometimes fractured by external violence, as in choking or throttling, and has been broken by muscular action. The body of the bone is rarely fractured, one of the greater cornua usually being fractured.

The **Movements of the Larynx en masse** are in but two directions—upward and downward. The most marked movements are performed during deglutition, prior to which the larynx, as well as the pharynx, is drawn upward. By this means closure of the superior aperture of the larynx is facilitated, and elevation of the pharynx aids the constrictor muscles of the pharynx to grasp the morsel of food. The larynx is elevated by the following muscles: The digastric, the stylo-hyoid, the mylo-hyoid, the genio-hyoid, the lower portion of the genio-hyo-glossus, the stylo-pharyngeus, and the palato-pharyngeus. It is depressed by the sterno-hyoid, the sterno-thyroid, and the omo-hyoid muscles.

Laryngotomy is performed through the crico-thyroid membrane. The shoulders are elevated by a pillow, the head and neck are extended, a firm support is placed under the neck, and the face is made to look directly forward so that the relations of the structures in the median line of the neck may not be distorted. The thyroid and cricoid cartilages and the crico-thyroid space are outlined, the larynx is gently steadied with the thumb and fingers of one hand, and an incision one and one-half inches long is made in the median line over the lower part of the thyroid cartilage, the crico-thyroid membrane, and the cricoid cartilage. The skin, the superficial fascia, and the superficial layer of the deep fascia are divided; the sterno-hyoid and sterno-thyroid muscles are separated from the corresponding muscles of the opposite side; the pretracheal fascia is divided; and the central portion of the crico-thyroid membrane is divided transversely along the upper border of the cricoid cartilage. By dividing the lowest portion of the membrane the

erico-thyroid arteries and the true vocal cords are avoided, and if the knife is directed downward and backward, the vocal cords are in less danger.

Excision of the Larynx is sometimes performed for removal of malignant disease of that organ; but the results of the operation are so discouraging that a palliative tracheotomy is usually preferred.

The **Trachea** is directly continuous with the lower portion of the larynx, so that the larynx appears to be the upper extremity of the trachea modified for the performance of certain special functions. The trachea varies between four and one-half and five inches in length and three-fourths of an inch and one inch in width. On transverse section it is shaped like a bar horseshoe, the indentation being posteriorly for the accommodation of the esophagus. The trachea is composed of cartilaginous rings, which are connected by fibrous membrane. The rings are horseshoe-shaped, with the open end posteriorly; this interval is filled by the fibro-elastic membrane, which yields to pressure of bodies passing through the esophagus, thus providing additional space during deglutition. The trachea contains from sixteen to twenty of these rings, seven or eight of which are above the upper margin of the sternum. When the head and neck are in the long axis of the body, about two inches of the trachea are above the sternum, and by full extension of the head and neck this distance may be increased to three inches. The trachea is quite superficial at its upper extremity, but rapidly becomes deeply situated as it descends; this is one of the reasons for preferring high tracheotomy.

RELATIONS OF THE CERVICAL PORTION OF THE TRACHEA.—In front are the skin; the superficial fascia; the superficial layer of the deep fascia, which is here composed of two layers; a communicating branch between the anterior jugular veins, situated just above the sternum; the sterno-hyoid and sterno-thyroid muscles; the isthmus of the thyroid body; the inferior thyroid veins or thyroid plexus of veins; occasionally, the thymus gland or the remains of that gland; the pre-tracheal fascia, and the thyroidea ima artery when present. Occasionally, a high innominate artery or left innominate vein may be in front of the trachea at the root of the neck. Behind the cervical portion of the trachea is the esophagus. On each side of it are the lateral lobes of the thyroid body, the recurrent laryngeal nerves, the terminal portions of the inferior thyroid arteries, and the carotid sheaths inclosing the common carotid arteries, internal jugular veins, and pneumogastric nerves. The trachea will be more completely described under the section on the Chest.

Tracheotomy.—The windpipe may be opened either above or below the isthmus of the thyroid gland; the former procedure being known as high, the latter as low, tracheotomy. High tracheotomy is the easier of the two operations, because the first part of the trachea is less deeply placed and is somewhat larger

and less mobile, being, therefore, more accessible than the part just above the sternum. Furthermore, the inferior thyroid veins, lying upon the trachea below the isthmus, the occasional presence of a thyroidea ima artery, and in infants the upper part of the thymus gland, add to the difficulties of the low operation. It is also to be remembered that the innominate artery or the left innominate vein may cross the trachea higher than usual and might be encountered in the low operation.

For the performance of the operation the head is well extended and so held by an assistant that the median line of the face will be in line with the median line of the neck. A firm cylindric cushion or a large bottle is so placed under the back of the neck as to render its anterior region prominent. The parts are steadied with the fingers and thumb of one hand. The various landmarks, such as the pomum Adami and the cricoid cartilage, are recognized by palpation. The incision extends from about the lower border of the thyroid cartilage downward for two and a half inches in the median line. It is made from below upward, and divides skin and superficial fascia. The anterior jugular veins, which lie alongside of the median line, may now appear, and should be avoided by cutting between them and drawing them aside. The two layers of the superficial layer of the deep cervical fascia are then divided either upon a director or with the free hand. The interval between the flat pretracheal muscles is recognized, and the wound deepened by "blunt dissection"; the director or the handle of the knife being used to slit down the soft parts in the median line until the pretracheal fascia is reached. The pretracheal fascia is incised and the tracheal rings are fully exposed, the director or handle of the knife being again used in order to avoid hemorrhage. The isthmus of the thyroid gland is depressed, if need be, to gain additional space.

Hemorrhage having been checked and the tracheal rings fully exposed, the trachea is held steady with a tenaculum and a sharp narrow-bladed knife, with its cutting edge directed upward, is thrust into the windpipe and two or three rings divided from below upward. The edges of the tracheal wound are then held apart with a dilator, hooks, or a loop of silk passed through each side. False membrane, if present, is withdrawn, and the tracheal tube is inserted.

After opening the windpipe it will usually be noticed that respiration is much slower, owing to the fact that plenty of air is admitted; whereas prior to the operation the breathing was hurried, on account of the obstruction.

It is important during the operation that the trachea be kept exactly in the median line, otherwise it may be opened on one side, or, from being carelessly drawn to one side by the assistant, it may be missed altogether, and the operator, as has occurred, may expose the vertebral column before the error is recognized.

It is also essential to thoroughly expose the rings of the trachea by clearing away the pretracheal fascia; such exposure prevents the mistake of introducing the tracheal tube under that fascia, instead of into the windpipe, thereby increasing the respiratory difficulty.

In children the cricoid cartilage is sometimes divided in addition to the tracheal rings, thus converting the operation into a laryngo-tracheotomy.

In the low operation the same general rules are observed as in the high operation; the incision extends from the top of the sternum to the cricoid cartilage. After division of the skin and fascia, the wound is deepened by blunt dissection, for there is here, of course, more danger of hemorrhage than in the previously described operation. The inferior thyroid veins, or thyroid plexus of veins, which lie upon the pretracheal fascia, should be displaced, and the trachea thoroughly exposed, the forefinger being passed into the wound from time to time as the wound is deepened, in order to ascertain the relations of the tissues, recognize abnormal vessels, and feel the tracheal rings.

THE NOSE.

The **Nose** is the uppermost portion of the respiratory tract. It contains the special organs of the sense of smell, and removes particles of dust from and warms and moistens the inhaled air; therefore, when the nasal passages are occluded, disease of the lower portion of the respiratory tract is more likely to occur. It may be divided into the **nose** proper and the **nasal cavities** or **fossæ**.

The **Nose** proper resembles a pyramid with three sides, the posterior of which is wanting and directed toward the nasal cavities. The two lateral surfaces are triangular, covered by skin, and form a part of the face. The apex of the pyramid—the root of the nose—joins the forehead. Below its root it broadens into the **bridge** or **dorsum** of the nose. Sinking of the bridge of the nose occurs in children who are affected by congenital syphilis, and who suffer from syphilitic coryza or “snuffles.” The severe nasal catarrh modifies the nutrition of the surrounding structures, and causes imperfect development of the adjacent bones. The two lateral borders of the nose are continuous with the face. The anterior border is free, and terminates below in the **lobule** or **tip** of the nose. The lateral surfaces, below, slope outward into the **alæ** or **wings** of the nose, which form the lower borders of those surfaces.

The **base** of the nose presents two apertures, the **anterior nares**, or nostrils, which are separated by a median pillar or **columna**. The anterior nares are

guarded internally by short stiff hairs, or vibrissæ, which sift small bodies out of the inhaled air. The anterior nares open into the **vestibule** of the nose, which is the portion of the nasal cavities within the cartilaginous portion of the nose proper. As the base of the nose is in a slightly lower plane than the floor of the nasal fossæ, the base of the nose should be elevated with the speculum in making an examination of the nasal cavities.

The **walls** of the nose proper are formed above by the nasal bones, the nasal spine of the frontal bone, and the nasal processes of the superior maxillary bones; and, below, by the lateral cartilages of the nose.

The **skin** is loosely adherent to the upper part of the nose, but is closely attached over the alæ and lobule. It contains sebaceous glands, which are especially numerous at the lower part of the nose. Therefore, acne and comedones are common in this location. *Acne*, or pimples, and other inflammatory affections upon the alæ and lobule of the nose are painful on account of the density of the tissues, which prevents swelling and causes increased pressure on the nerves. The skin of the nose is also commonly affected by acne rosaceâ and lupus, especially lupus erythematosus, which develops upon the nose, ears, and face more frequently than on other portions of the body. *Rodent ulcer*, another affection which has a predilection for the nose, frequently commences in the crease between the cheek and the ala of the nose. This is a not uncommon site for *epithelioma*.

BLOOD SUPPLY.—The nose proper is supplied by the nasal, angular, infra-orbital, lateral nasal, and superior coronary arteries. The numerous and freely anastomosing vessels of the exterior of the nose communicate with those in the mucous membrane; hence it happens that in many cases of inflammatory disease of the nasal mucosa there is congestion of the cutaneous vessels.

On account of its free blood supply, the skin of the nose offers a good field for plastic operations. Restoration of the nose by a plastic operation is known as *rhinoplasty*. The flap may be derived from the forehead, as in the Indian method, or from the inside of the arm, as in the Tagliacotian method. The flaps may also be taken from the cheeks, or the flaps from the cheeks may be placed with their cutaneous surface inward and covered with a flap from the forehead. In the nose, as in the scalp, the free blood supply prevents sloughing of portions of the organ almost cut away and then repositied, and small scars are formed in the repair of wounds.

NERVE SUPPLY.—The nose proper is supplied by the nasal, infra-trochlear, and infra-orbital nerves. The muscles of the nose proper, which have been considered with the description of the face, are supplied by the facial nerve.

The **veins** of the nose proper empty into the ophthalmic and facial veins. There is a network of rather large anastomosing veins in the tip of the nose.

The **lymphatics** of the nose proper pass to the submaxillary lymphatic glands.

Because of their exposed position and the absence of subcutaneous fat which protects underlying vessels, the lobule and ala of the nose, like the pinna of the ear, are frequently frozen and may be the site of gangrene resulting therefrom.

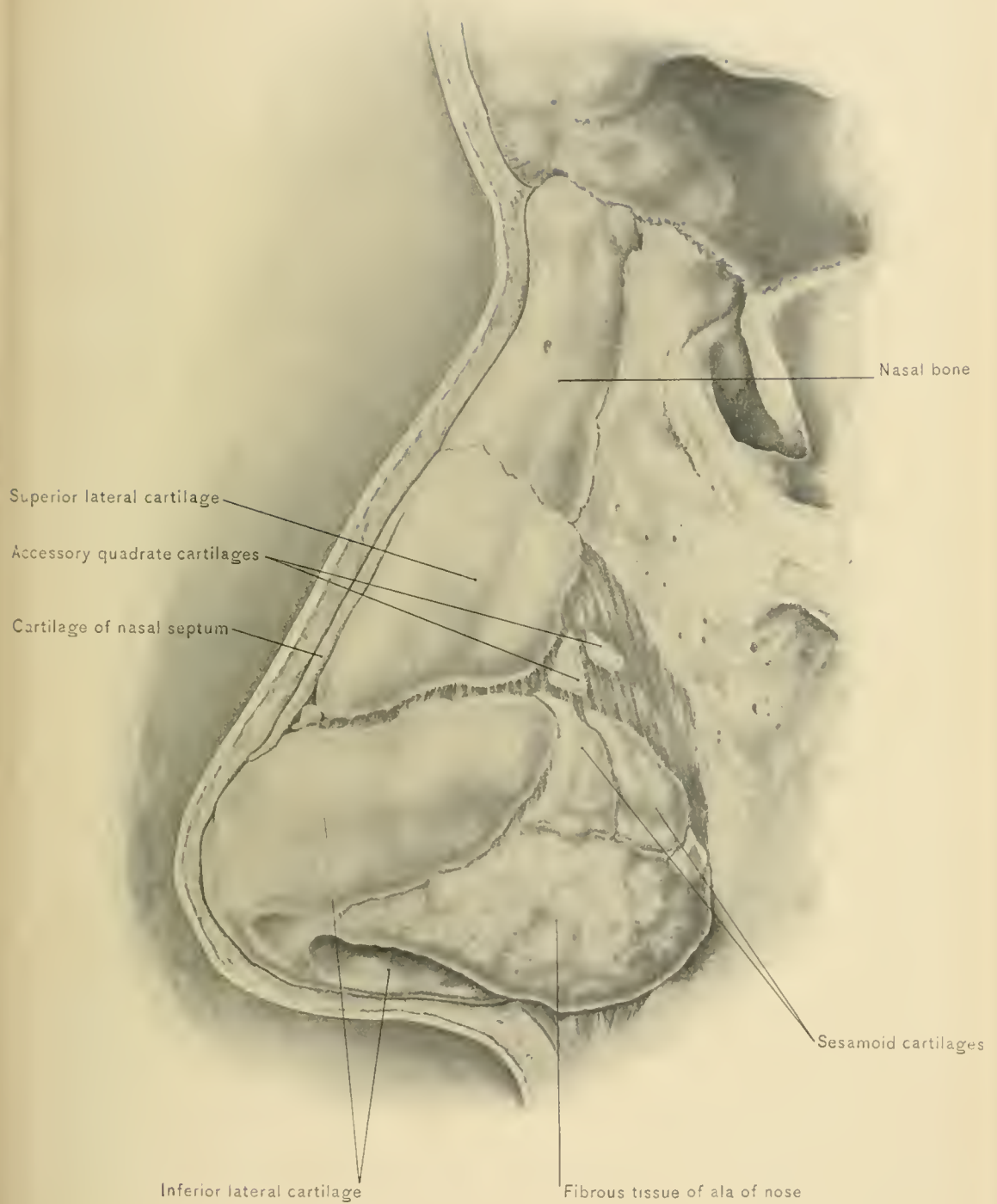
DISSECTION.—Remove the tissues covering the nasal bones and lateral cartilages of the nose.

The **nasal bones** are thick and narrow at their upper extremities, and thin, broad, and much exposed to injury at their lower portion; consequently these bones are more frequently fractured near their lower margins. A blow at the root of the nose is far more likely to break the cribriform plate of the ethmoid bone and the anterior walls of the frontal sinuses than the nasal bones. Fractures of the nasal bones may be reduced by manipulation of the fragments between the fingers externally and a grooved director introduced into the nasal fosse. Owing to their vascularity, the nasal bones unite quickly. In congenital syphilis destruction of the bones, especially of those of the septum, causes the bridge of the nose to sink. Congenital protrusions of the membranes of the brain or the brain itself may occur at the root of the nose. They are known as sincipital meningoceles and encephalocelles, and appear because of incomplete union of the frontal bone with the cribriform plate of the ethmoid bone and with the nasal bones. The skin over these tumors may be highly vascular and present some resemblance to that over a nevus.

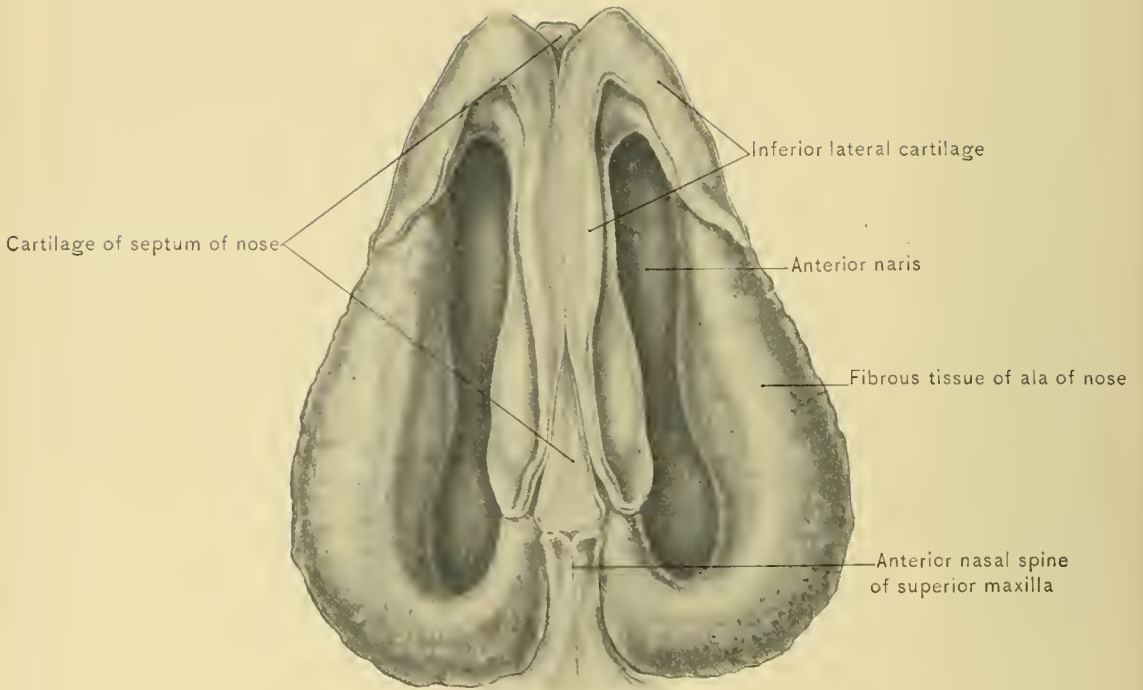
The **cartilages** in the framework of the nose consist of a superior and an inferior lateral cartilage and sesamoid cartilages on each side, and the cartilage of the septum.

The *superior lateral cartilages* are triangular. Their anterior margins are partly continuous with the anterior border of the cartilage of the septum, to which they are closely applied. Their posterior margins are closely united to the superior maxillæ and the lower border of the nasal bones. Their inferior borders are attached to the inferior lateral cartilages. Their outer surfaces are covered by the skin and the muscular and fibrous tissue of the nose; and their inner surfaces by the nasal mucous membrane. When the superior lateral cartilage is detached from the nasal bone by traumatism, considerable pain in the nose is produced by injury of the nasal nerve, which emerges between this cartilage and the nasal bone.

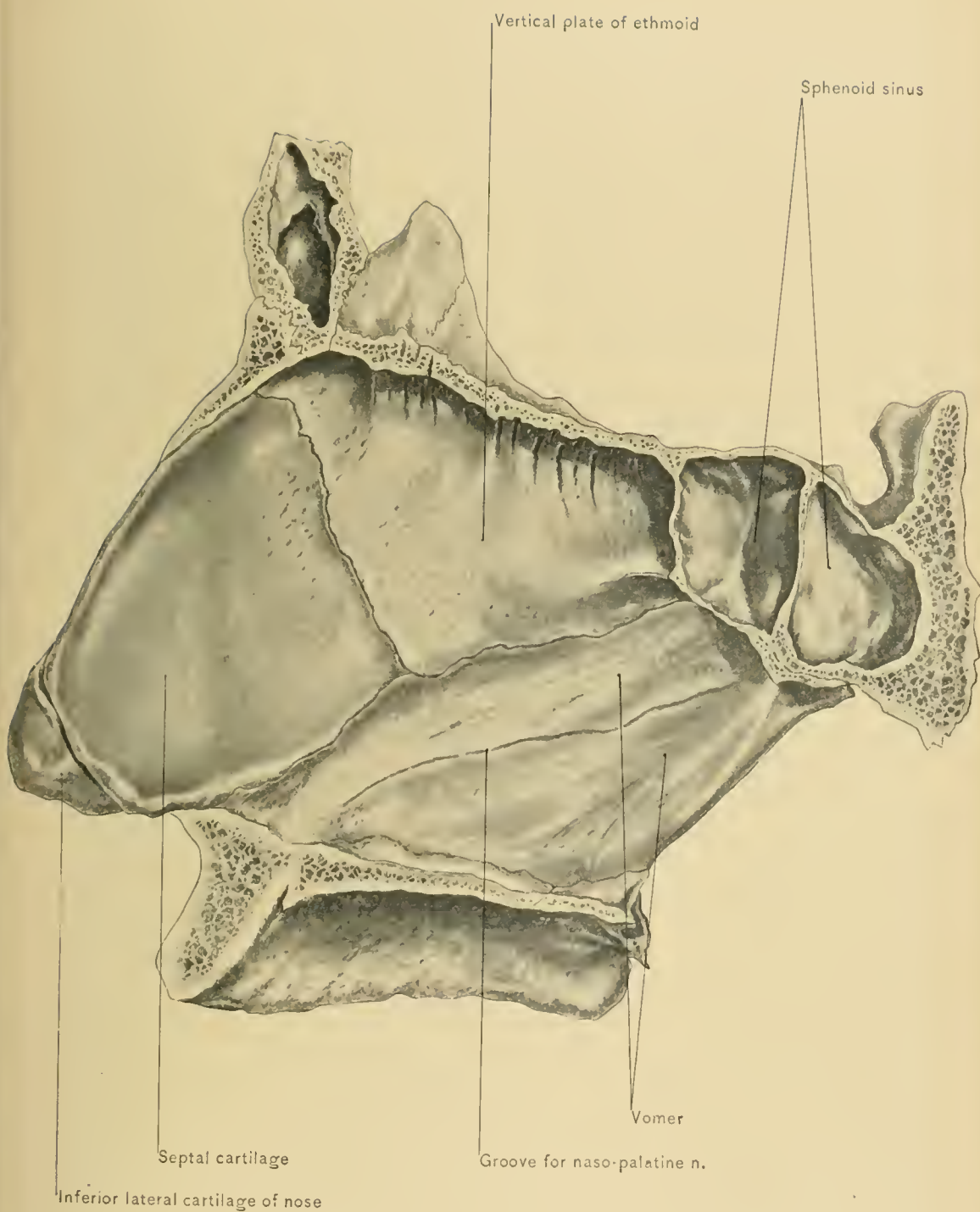
The *inferior lateral cartilages* are sharply bent around in front of the anterior nares, so that they are composed of an inner and an outer portion. The inner portion lies in contact with the corresponding portion of the opposite inferior lateral cartilage on the inner side of the anterior nares, forming part of the columna. The outer portion is oval and curves backward in the ala of the nose. It



LATERAL CARTILAGES OF NOSE.



CARTILAGES AT BASE OF NOSE.



is attached to the superior lateral cartilage and the superior maxilla by dense fibrous tissue, in which the sesamoid cartilages are found. The margin of the alæ of the nose is not formed by the inferior lateral cartilage, but by the dense fibrous tissue which forms the framework of the nose proper where the bones and cartilages are absent.

The *sesamoid or accessory cartilages* are usually four in number in each lateral wall of the nose proper. Two of these cartilages are situated in the fibrous tissue which connects the inferior lateral cartilage with the nasal process of the superior maxilla. Just above these are the other two, which are called the *accessory quadrate cartilages*. Additional sesamoid cartilages may be found in the fibrous tissue which completes the framework of the nose proper, but the four previously mentioned are the only constant sesamoid cartilages.

The *septal cartilage* is placed in the antero-inferior portion of the septum, filling the angular interval between the vertical plate of the ethmoid bone and the vomer. It is quadrilateral in form. Its posterior superior border is in contact with the vertical plate of the ethmoid bone, which is sometimes grooved to receive it. Its posterior inferior border joins the anterior nasal spine of the superior maxilla, and the vomer, which may be grooved for its reception. The upper portion of its anterior superior border is attached to the crest on the under surface of the junction of the nasal bones, and below the nasal bones the sides of this border are continuous with the superior lateral cartilages; it terminates just above the tip of the nose between the inner plates of the two inferior lateral cartilages. The anterior inferior border is short, and extends backward and downward, above the columna, to the anterior nasal spine, which it embraces.

The cartilages and other soft tissues of the cartilaginous portion of the nose may be destroyed by *lupus vulgaris*, the bones not being involved. The nose may be repaired by one of the methods of plastic operation (rhinoplasty) previously mentioned.

Dilating specula introduced into the anterior nares should not be inserted beyond the cartilaginous portion of the nose, on account of the pain produced by pressure upon resisting bony structures.

DISSECTION.—Hold the anterior segment of the skull so that the light enters the nasal cavities through the anterior nares, or pass a probe or a grooved director into the nasal cavities to determine to which side the nasal septum is deflected. Then cut through the tissues of the upper lip and through the lateral cartilages, close to that side of the septum which does not bulge. With the hard palate facing upward saw through the skull, close to the flat or concave side of the septum. The superior turbinated bone on one side may be broken, in which case it may be studied on the other side after removing the septum.

The **Nasal Cavities**, or **Fossæ**, two in number, are located between the base of the skull and the hard palate. They are wide below and become quite narrow above, where the middle and superior turbinated bones lie near the septum, and at times in contact with it. The vertical diameter of each nasal fossa is greater than the transverse diameter; and, therefore, forceps inserted into the fossæ should be opened vertically. The nasal cavities open upon the face by means of the vestibule and anterior nares, and into the naso-pharynx by means of the posterior nares. They are separated by the nasal septum.

The **nasal septum** is formed by the crest at the junction of the nasal bones, the nasal spine of the frontal bone, the vertical plate of the ethmoid bone, the cartilage of the septum, the vomer, the crest of the sphenoid bone, and by the crest situated at the line of junction of the two palatal processes of the two superior maxillæ and of the two horizontal plates of the palate bones. In children up to the seventh year and in primitive races the septum is straight in eighty per cent. of cases; but in the adult in seventy-six per cent. of persons it is deflected to one side, and more frequently to the left. This deflection should not be mistaken for a bony growth of the septum.

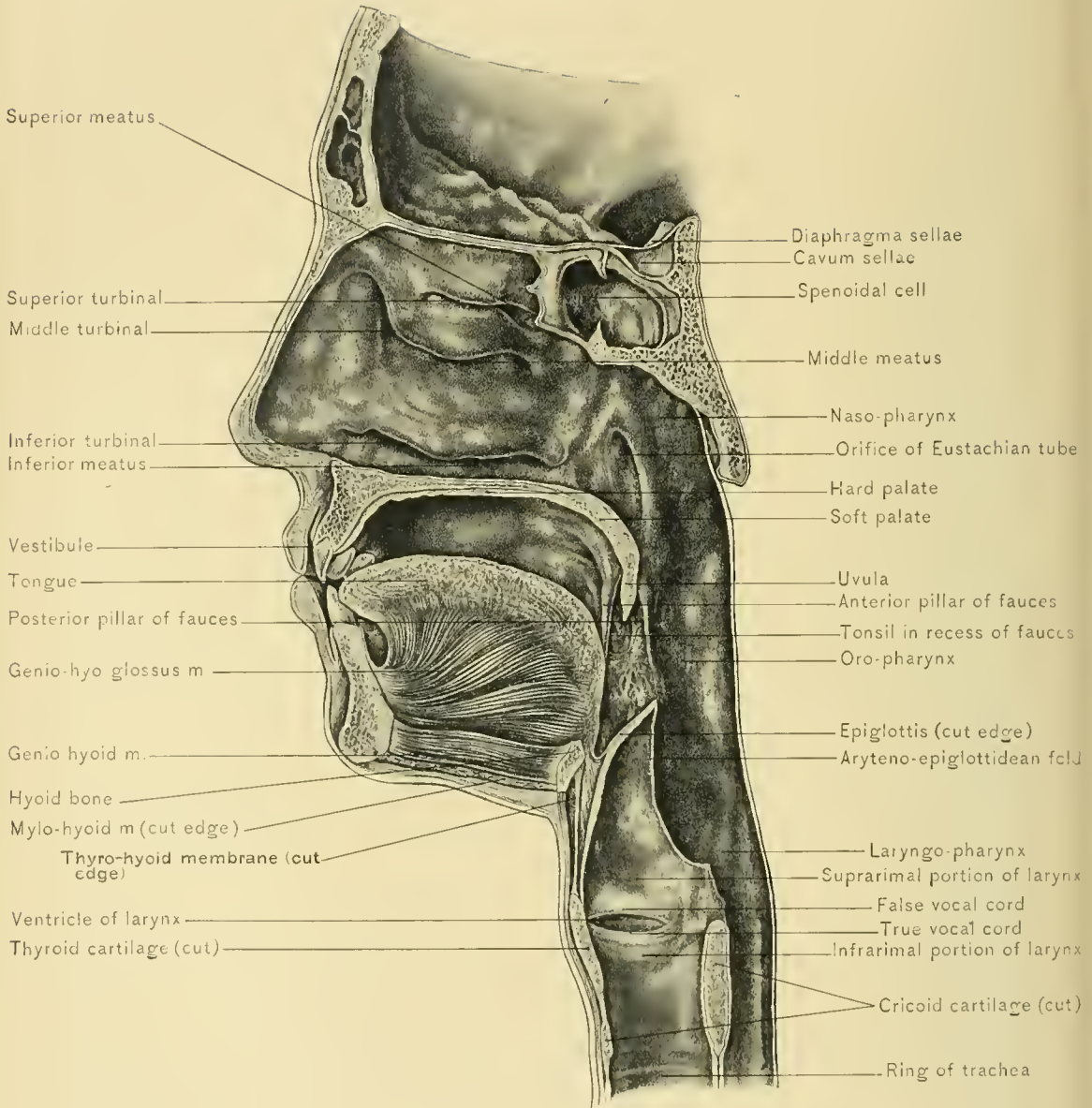
The frequency of deviation of the nasal septum is supposed to be due to the practice of always blowing the nose with the same hand. This condition, by obstructing one nasal fossa, retards breathing and impairs the resonance of the voice, which should be perfect in those who sing.

Perforation of the nasal septum may occur in persons exposed to the vapor of chromic acid in the manufacture of potassium bichromate, in syphilitic individuals, and in scrofulous persons, or may be a congenital condition.

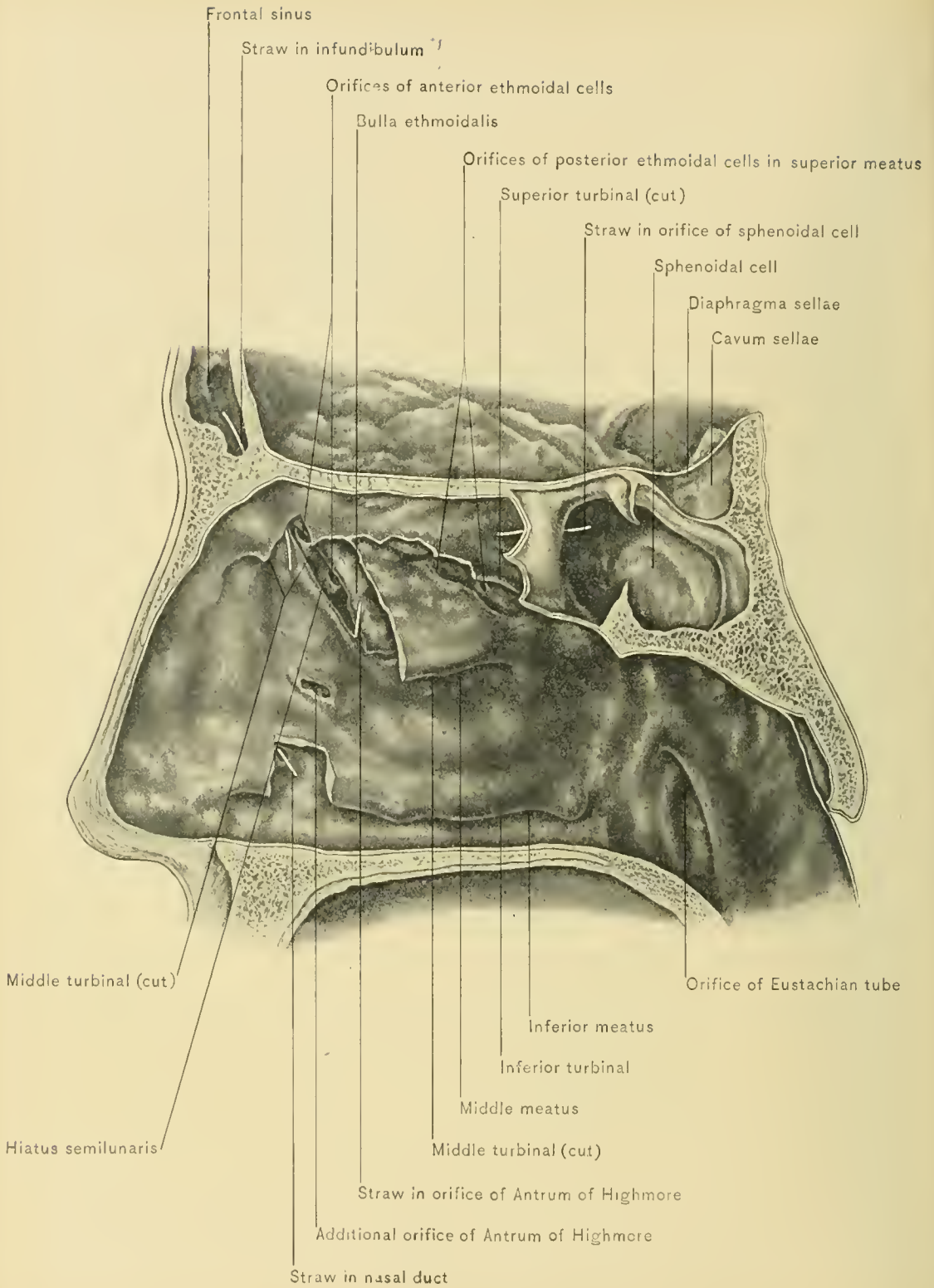
The **roof** of the nasal cavities is formed by the nasal bones, nasal spine of the frontal bone, cribriform plate of the ethmoid bone, sphenoid turbinated bones, body of the sphenoid bone, alve of the vomer, and sphenoid processes of the palate bones. The middle portion of the roof, formed by the cribriform plate of the ethmoid bone, is horizontal, its anterior portion slopes downward and forward, and its posterior portion downward and backward. A meningocele projecting through the roof of the nasal fossa into the nasal cavity has been mistaken for a polypus and removed, with a fatal result. In fracture of this portion of the base of the skull blood or cerebro-spinal fluid may escape through the nose.

The middle portion of the roof of the nose is so thin that it may easily be punctured and the cranial cavity entered by slender instruments or foreign bodies introduced in the nose, either intentionally or accidentally.

The **floor** of the nose is wider than the roof, being slightly more or less than one-half of an inch wide. It is formed by the palatal processes of the superior



MEATUSES OF NOSE AND TURBINATED BONES—LATERAL VIEW.



ORIFICES OF ACCESSORY AIR-CHAMBERS OF NOSE.

maxilla and the horizontal plates of the ethmoid bones. It is somewhat concave from side to side, and slopes slightly downward and backward.

The **outer wall** of the nasal fossa is formed by the nasal process and internal surface of the superior maxilla, the inferior turbinate bone, the lacrymal bone, the lateral mass of the ethmoid bone, the vertical plate of the palate bone, and the internal pterygoid plate of the sphenoid bone. The outer wall is made irregular by projection of the superior, middle, and inferior turbinate bones into the nasal cavity.

The **superior turbinate bone** is situated on the upper part of the outer wall in the posterior one-third of the cavity, its anterior and highest portion being about opposite the tendo oculi. The **middle turbinate bone** extends along the posterior two-thirds and the **inferior turbinate bone** along nearly the whole length of the outer wall of the nasal fossa. The recesses beneath the turbinate bones are called meatuses. Of these there are three—viz., the superior, middle, and inferior meatuses, each situated beneath the corresponding turbinate bone. The **superior meatus** is closed in front and opens downward and backward. It contains the orifices of the sphenoid cells or sinuses and of the posterior ethmoid cells. The orifice of the sphenoid cells is really in the roof of the nasal fossa at the level of the superior turbinate bone, and when that bone is divided into two plates, the orifice is opposite the space between them, known as the **fourth meatus** or **spheno-ethmoid recess of Meyer**. The **middle meatus** is open in front, behind, and below. In front it opens into a broad portion of the nasal cavity, called the *atrium* of the *middle meatus*. The atrium opens widely anteriorly into the vestibule, allowing most of the inhaled air to pass through the middle meatus. On the lateral or external wall of the middle meatus is a groove known as the **hiatus semilunaris**, which begins at the lower extremity of the infundibulum and curves from above backward and downward. The orifices leading to the antrum of Highmore and to the anterior ethmoid air cells are in this groove. The **bulla ethmoidalis** is the rounded upper boundary of the hiatus semilunaris. The orifice of the antrum of Highmore is about an inch above the floor of the nose. The **inferior meatus** opens chiefly downward and backward, so that more exhaled than inhaled air passes through it. It presents the inferior orifice of the lacrymo-nasal (nasal or lacrymal) duct, which carries the tears from the lacrymal sac to the nose. The opening of the nasal duct is at the under surface of the attached margin of the inferior turbinate bone, about an inch behind the anterior nares, and three-fourths of an inch above the floor of the nose. Instruments to be introduced into the inferior meatus must be directed toward the floor of the nose, or the anterior end of the inferior turbinate bone will guide them into the middle meatus, which is more widely open. Foreign bodies are most frequently

found in the inferior meatus. If these bodies are retained for a long time, concretions of calcareous matter adhere to them and thus *rhinoliths* are formed.

The turbinated bones or other portions of the walls of the nasal cavities may be the site of *necrosis*, which causes a purulent discharge usually from one nostril. The carious bone should be removed, and when the disease is situated high up, Rouge's operation offers a good exposure of the nasal cavities. In this operation the upper lip is everted, and the tissues of the lip and nose are detached from the external surface of the superior maxilla.

A *chronic purulent discharge* from one nostril is usually caused by the presence of a foreign body or carious bone in the nasal fossa or one of its accessory cavities; and from both nostrils by constitutional disease, as syphilis.

The nasal cavities are divided, according to function, into the **olfactory portion**, which includes the superior meatus, middle turbinated bone, and upper two-thirds of the septum of the nose, and the **respiratory portion**, which includes the middle meatus, inferior turbinated bone, inferior meatus, and lower one-third of the septum.

The nasal cavities are lined by a **mucous membrane** (Schneiderian or pituitary membrane) which is continuous with that of the pharynx, sphenoid and ethmoid cells, frontal sinuses, antra of Highmore or maxillary sinuses, lacrymo-nasal ducts, and lacrymal sacs. This continuity with the adjacent mucous membrane and with the lining of the accessory cavities of the nose, as the various air sinuses are called, is very important to remember, for there is a marked interrelation existing between the diseases of these various parts. Empyema of the frontal and ethmoid air sinuses, for instance, and of the antrum of Highmore is usually dependent upon disease of the nasal mucosa. In the olfactory portion the mucosa is of a yellowish color, which gradually fades below, making no marked line between the mucous membrane of the two portions. Over the nasal septum it is rather firmly adherent to the underlying periosteum; at times submucous hematoma of the septum are seen after injury of the nose. On the anterior inferior portion of the septum the mucous membrane presents a little diverticulum, which is the remains of Jacobson's organ. This organ is more highly developed in the lower animals. At the upper two-thirds of the septum and outer wall (in the olfactory portion) the mucous membrane is delicate and thin, and contains the branches of the olfactory nerve. In the lower or respiratory portion of the nasal fossa the mucous membrane is thicker, more vascular, and pale red in color. This is especially noticeable over the lower borders and posterior extremities of the middle and inferior turbinated bones, where it is soft and boggy and projects beyond the bones. This condition is due to the presence of a large number of veins in the submucous layer of the mucous membrane of the middle and inferior

turbinated bones, and to the presence of cavernous spaces of erectile tissue in that of the inferior turbinated bone. In chronic nasal catarrh these cavernous spaces are distended with blood, the nasal cavity is occluded, and the individual is unable to breathe through the nose. The mucous membrane of the anterior extremity of the inferior turbinated bone, when distended, resembles a polypoid growth.

Instruments, such as specula or tubes of atomizers, introduced through the anterior nares should be directed slightly outward to avoid striking the septum, which causes pain, and to prevent injury to the mucous membrane, which often bleeds after slight traumatism.

Mucous polypi are frequently developed in the nose, and usually from the mucous membrane of the superior or middle turbinated bone or near the hiatus semilunaris. They occlude the nasal cavity, may broaden the nose, compressing the nasal ducts, and may project through the anterior or posterior nares. They should be removed, and if they continue to recur, a portion of the adjacent bone should be removed, exercising sufficient care to avoid fracturing the cribriform plate of the ethmoid bone. Fibrous or sarcomatous polypi arise from the periosteum and more frequently from the roof of the nose.

Bleeding from the nose (**epistaxis**) is one of the prodromal symptoms of typhoid fever, but it is more commonly due to other causes, such as engorged vessels, as in plethoric individuals, or ulceration into an artery, and may be a symptom of fracture of the base of the skull, purpura hemorrhagica, hemophilia, scurvy, or ptomain poisoning, as from large abscesses. Hemorrhage from the nose is checked by the laity by pressure on the upper lip, which occludes the artery of the septum; by plugging the anterior nares; by raising the arm and increasing the expansion of the chest, which lessens the pressure in the veins; and by dropping a cold key down the back, or applying cold water to the back of the neck, and thus stimulating the vasomotor nerves. If the source of a serious hemorrhage can not be found, the bleeding can be checked by plugging both the anterior and posterior nares, which is done by introducing a strong thread, stiffened by soaking in gum and drying, into the nose and pharynx, and bringing it out through the mouth and attaching a plug of cotton to it; or a soft catheter may be threaded and carried through the nose into the pharynx. One end of the thread is brought out through the mouth with forceps, and the other through the nose in withdrawing the catheter. A plug of cotton the size of a walnut is then attached to the string, the two ends of which are tied together so that the plug can be pulled against the posterior nares, or withdrawn and reapplied if necessary. The instrument specially designed for plugging the posterior nares is Bellocq's cannula.

Ozena is the name given to any affection of the nasal fossæ giving rise to a foul discharge from the nose. A fetid purulent discharge from both nostrils may

be a symptom of atrophic rhinitis, syphilis, carcinoma, glanders, or occasionally necrosis; and from one nostril a symptom of rhinoliths (incrusted foreign bodies), necrosis, or empyema of one of the accessory cavities of the nose.

The **vestibule** of the nose is that portion of the nasal fossa within the cartilaginous portion of the nose, and is lined with skin which blends with the mucous membrane of the nose.

The **mucous glands** are most numerous over the posterior portion of the outer wall and septum of the nose. The position of these glands and the backward and downward slope of the nasal floor accounts for the gravitation of the mucus to the pharynx. Occlusion of the duct of a mucous gland causes the formation of a retention cyst.

Some lymphoid tissue is also found in the nasal mucous membrane.

NERVE SUPPLY.—The nerve supply of the nasal mucous membrane is derived from the olfactory, nasal, and naso-palatine nerves, branches from Meckel's ganglion and the Vidian nerve, branches from the anterior superior dental nerve, and branches from the anterior palatine nerve.

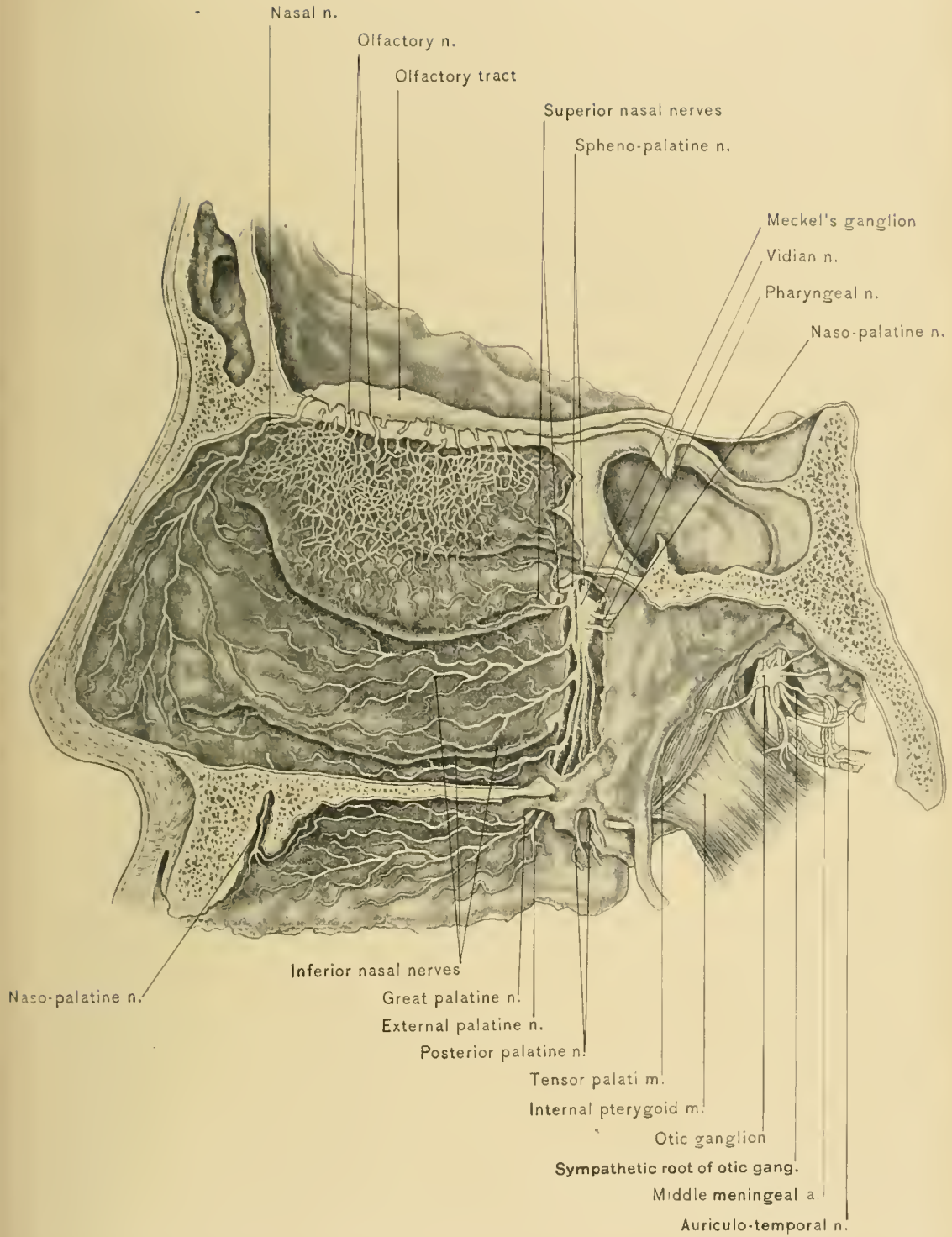
The **olfactory nerves**, which arise from the olfactory bulb, enter the nasal fossa by piercing the cribriform plate of the ethmoid bone as numerous branches. The internal or mesial branches ramify upon the upper one-third of the septum, and the external branches upon the superior turbinated bones and the surface of the ethmoid above and in front of these bones. They form plexuses in and beneath the mucous membrane. *Anosmia*, or loss of the sense of smell, after a severe blow upon the head is supposed to be due to rupture of the olfactory nerves where they pass through the cribriform plate.

The **nasal nerve** is a branch of the ophthalmic division of the fifth cranial nerve. It reaches the nasal fossa by passing through the slit at the side of the crista galli, runs downward in the groove on the internal surface of the nasal bone, and passes forward between the nasal bone and the upper lateral cartilage to supply the tip of the nose. It supplies branches to the anterior portion of both the outer wall and the septum of the nose.

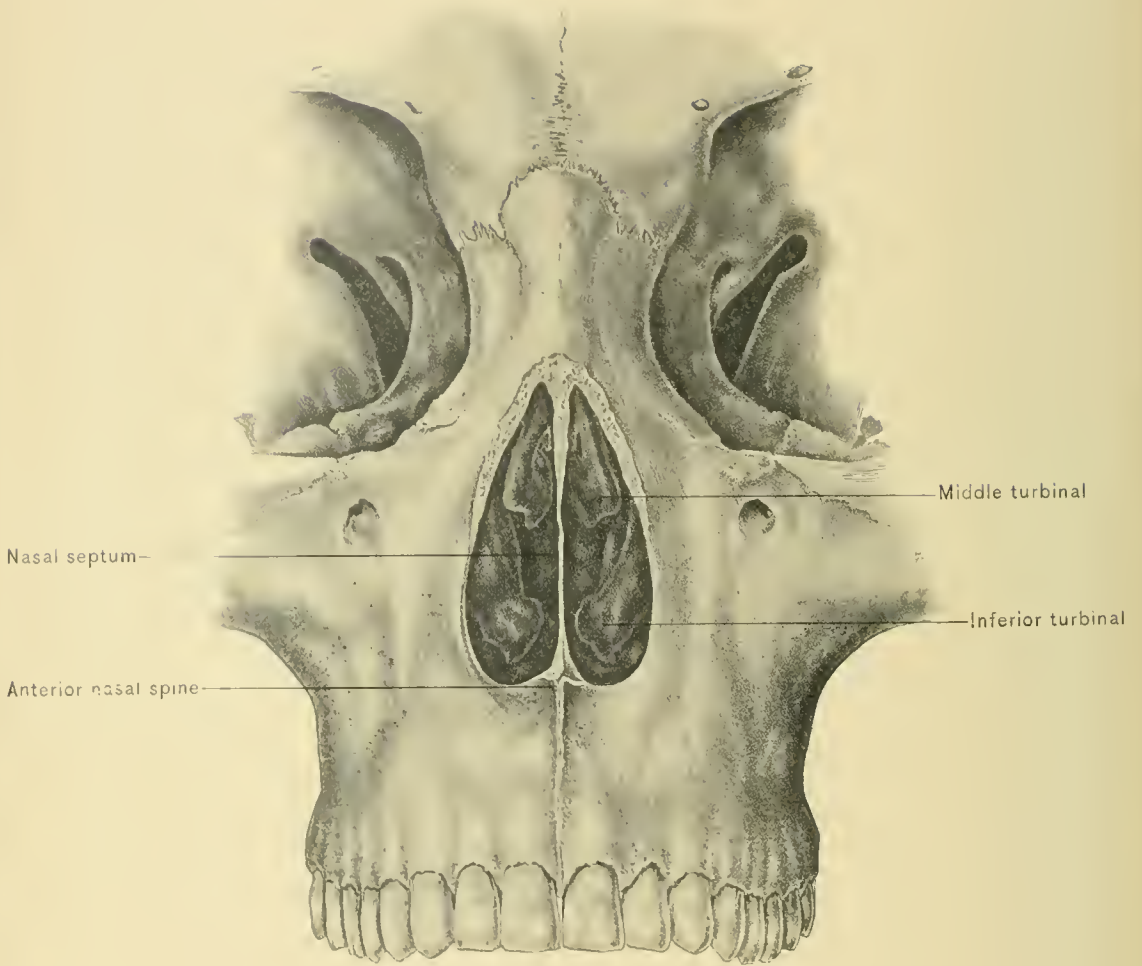
The **naso-palatine nerve** is a branch of Meckel's ganglion, and enters the nasal fossa with the naso-palatine artery at the sphenopalatine foramen. It crosses on the body of the sphenoid bone to the septum, upon which it runs downward and forward, supplying its middle portion.

The branches from the **Vidian nerve** and the anterior branches of **Meckel's ganglion** are small. They supply the upper and back part of the septum and the superior turbinated bone. They can seldom be traced.

The branches of the **anterior superior dental branch of the superior maxillary nerve** supply the inferior turbinated bone and the inferior meatus. The



OLFACTORY NERVES.



ANTERIOR VIEW OF NASAL FOSSÆ.

branches from the anterior palatine nerve (inferior nasal nerves) run forward upon the middle and inferior turbinated bones.

BLOOD SUPPLY.—The blood supply of the nasal cavities is derived from the sphenopalatine, descending palatine, anterior and posterior ethmoid arteries, and the artery of the septum.

The **spheno-palatine artery**, a branch of the internal maxillary, is the principal artery of the nasal fossa. It enters it at the sphenopalatine foramen with the naso-palatine nerve. Its internal branch, the naso-palatine, accompanies the naso-palatine nerve downward and forward upon the septum toward the anterior palatine foramen. Its external branches supply the outer wall of the cavity, the ethmoid cells, frontal sinus, and antrum of Highmore.

The **descending palatine artery** is also a branch of the internal maxillary artery. It gives off a few small branches to the posterior portion of the outer wall of the nasal fossa.

The **anterior and posterior ethmoid arteries** are branches of the ophthalmic artery. They supply the roof, upper portion of the septum, and outer wall of the nasal fossa, ethmoid cells, and frontal sinuses.

The **artery of the septum** is derived from the superior coronary branch of the facial artery. It supplies the columna and the lower portion of the septum.

The **veins of the nasal cavities** form a plexus under the mucous membrane. The plexus is drained by the veins which accompany the sphenopalatine artery and empty into the pterygoid plexus; those which follow the ethmoid arteries and empty into the ophthalmic vein; some which pass through the foramina in the nasal bone and nasal process of the superior maxilla to empty into the facial vein; and others which pass through the foramen cæcum to join the superior longitudinal sinus and through the cribriform plate of the ethmoid bone to join the intra-cranial veins.

The **lymphatic vessels** of the muco-periosteal lining and walls of the nasal fosse terminate in the post-pharyngeal lymphatic gland, the internal maxillary lymphatic glands, the parotid lymphatic glands, and the superior deep cervical lymphatic glands. Through the cribriform plate of the ethmoid bone these vessels communicate with the intra-cranial lymphatics and the subdural space, affording a channel through which meningitis may be produced by caries of the upper portion of the wall of the nose. Involvement of the post-pharyngeal, internal maxillary, parotid, and superior deep cervical lymphatic glands may also result from disease of the nasal fosse.

In **anterior rhinoscopy**, or examination of the nasal fossa through the anterior naris, the following structures can be observed: The septum, which should occupy a vertical position, and, if it deviates toward the fossa under examination, it

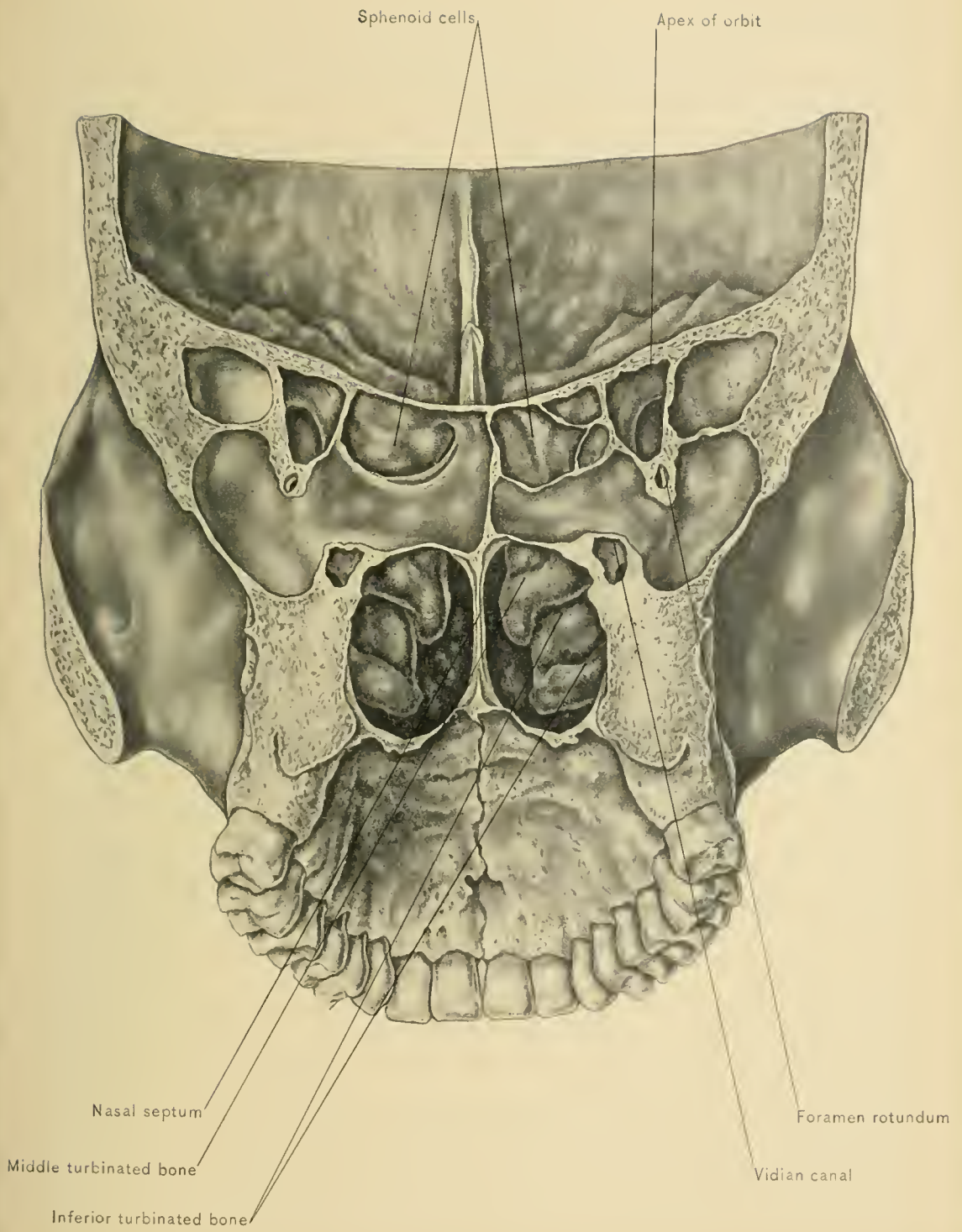
should not be mistaken for a tumor; the floor of the nose; the inferior turbinated bone, which extends backward along the outer wall of the fossa; the middle meatus; the middle turbinated bone; and high up the superior meatus and the anterior extremity of the superior turbinated bone.

Posterior rhinoscopy, or examination of the nasal fossæ through the posterior nares is quite difficult, and can be performed only after some practice. A small mirror, similar to a laryngoscopic mirror, is inserted behind the soft palate, while the patient breathes through the nose and the tongue is depressed by the examiner. By means of light reflected through the mouth the following structures can be seen: The posterior nares, separated by the posterior margin of the nasal septum; the upper or attached portion of the inferior turbinated bone; the middle meatus; the middle turbinated bone; the superior meatus; the superior turbinated bone; the roof of the naso-pharynx; the upper part of the posterior wall of the naso-pharynx; the pharyngeal tonsil; the upper part of the lateral wall of the naso-pharynx; the pharyngeal recess; and the profile of the trumpet-shaped orifice of the Eustachian tube.

Nasal douche.—In nasal catarrh the nasal fossæ are frequently cleansed by spraying or douching with an alkaline solution. In using the nasal douche the solution flows in one anterior naris and out through the other, elevation of the soft palate against the posterior wall of the pharynx preventing the solution from passing into the oro-pharynx. The bottom of the vessel containing the solution should not be placed above the level of the eyebrows, and the head should be inclined slightly forward so that the solution will not enter the Eustachian tubes, the orifices of which are on a level with the posterior extremities of the inferior turbinated bones. If the solution should enter the middle ear through the Eustachian tube, otitis media and deafness might result.

DISSECTION.—The student should now turn the superior turbinated bone upward, and with a probe search for the orifices of the sphenoid sinus and posterior ethmoid cells; remove the anterior portion of the middle turbinated bone, to find the orifices of the antrum of Highmore, anterior ethmoid cells, and the infundibulum, and cut away the anterior portion of the inferior turbinated bone to see the inferior opening of the lacrymo-nasal duct. The frontal and sphenoid sinuses have been opened in sawing through the skull, so they can be satisfactorily studied.

The **frontal sinuses** are situated between the inner and outer tables of the frontal bones, at the position of the superciliary eminences and glabella. They are absent before the seventh year, when they originate as extensions of the anterior ethmoid cells, and reach their full development at about the twentieth year. The anterior or external bony wall of the sinuses is the thicker of the two, and, upon careful examination, it can usually be seen to consist of two laminae, between



POSTERIOR VIEW OF NASAL FOSSÆ.



which there is a thin diploic layer. The weakest and thinnest portion of this external wall is just above the inner angle of the orbit, and when a collection of pus in the frontal sinus bursts externally, it is usually at this point that the opening occurs. Such a fistulous opening may be mistaken by the careless observer for a fistula lachrymalis.

The frontal sinuses are extremely variable in size and form. A thin osseous partition usually separates one sinus from the other; this septum may, however, be incomplete. In many cases these sinuses extend backward for a considerable distance over the roof of the orbit. Additional septa may divide the cavity into subcompartments, and, furthermore, one or two of the ethmoid cells may bulge into the sinus. In women they are comparatively small. In some individuals they are quite small, or even absent, and this is said to be the common condition in skulls which have a midfrontal suture. They open into the middle meatuses of the nasal fossæ by means of the infundibula. They are lined by mucous membrane, which is an extension of that of the nose and is supplied by filaments of the nasal nerve.

Congestion of the mucous membrane of the frontal sinuses, which is likely to be associated with acute coryza, or "cold in the head," produces the dull ache over the glabella and superciliary eminences in that affection. When drainage from the sinuses is insufficient, mucus becomes inspissated within them.

Empyema, or a purulent collection *in the frontal sinus*, is often associated with occlusion of the infundibulum, and, because of the unyielding character of the walls of the sinus, causes much pain. If the infundibulum is patulous, the pus appears in the middle meatus of the nose. For the proper treatment of this affection it is necessary to trephine the anterior wall of the sinus, reestablish the communication with the nose, and institute drainage by means of a tube passed into the nasal fossa. The incision is made just below the supra-orbital margin, and extends from the root of the nose outward for about an inch. A small trephine or a drill is applied just above the inner angle of the orbit, where the bone is thin.

The *external table of the skull may be fractured* and depressed at the position of the frontal sinuses without injuring the inner table or affecting the cranial contents, and the inspissated mucus escaping from the sinus may be mistaken for brain matter. These fractures are often accompanied by emphysema, in which case the air is derived from the nose by way of the infundibulum.

Living foreign bodies, such as centipedes, maggots, and insects, may enter the frontal sinuses by passing up the infundibulum.

A *polypus* is sometimes found in one of the frontal sinuses. It may originate in the sinus or in the nose, and enter the sinus by way of the infundibulum. If it

continues to enlarge, it may bulge the anterior wall or orbital wall of the sinus and displace the eyeball. It can be removed by trephining the anterior wall of the sinus.

DISSECTION.—The antrum of Highmore, or maxillary sinus, should be opened by sawing away part of its external wall.

The **antrum of Highmore, or maxillary sinus**, is an accessory air chamber of the nose, and is situated in the superior maxillary bone. It is irregularly pyramidal in shape, the base of the pyramid being directed toward the nose, and the apex toward the malar process of the superior maxilla. The base is formed by the external wall of the nasal fossa—*i. e.*, by the nasal surface of the superior maxilla, the maxillary process of the inferior turbinated bone, the uncinatè process of the ethmoid bone, the vertical plate of the palate bone, and the lacrymal bone. In the upper and posterior part of this surface is the orifice of the sinus, which is so situated that drainage from the antrum is defective. Consequently, mucus or pus may be retained in the cavity, forming a mucocele or empyema of the antrum. The roof of the antrum is formed by the orbital plate of the superior maxilla, the floor by the alveolar process of the superior maxilla, the anterior or external wall by the facial surface of the superior maxilla, and the posterior wall by the zygomatic surface of the superior maxilla.

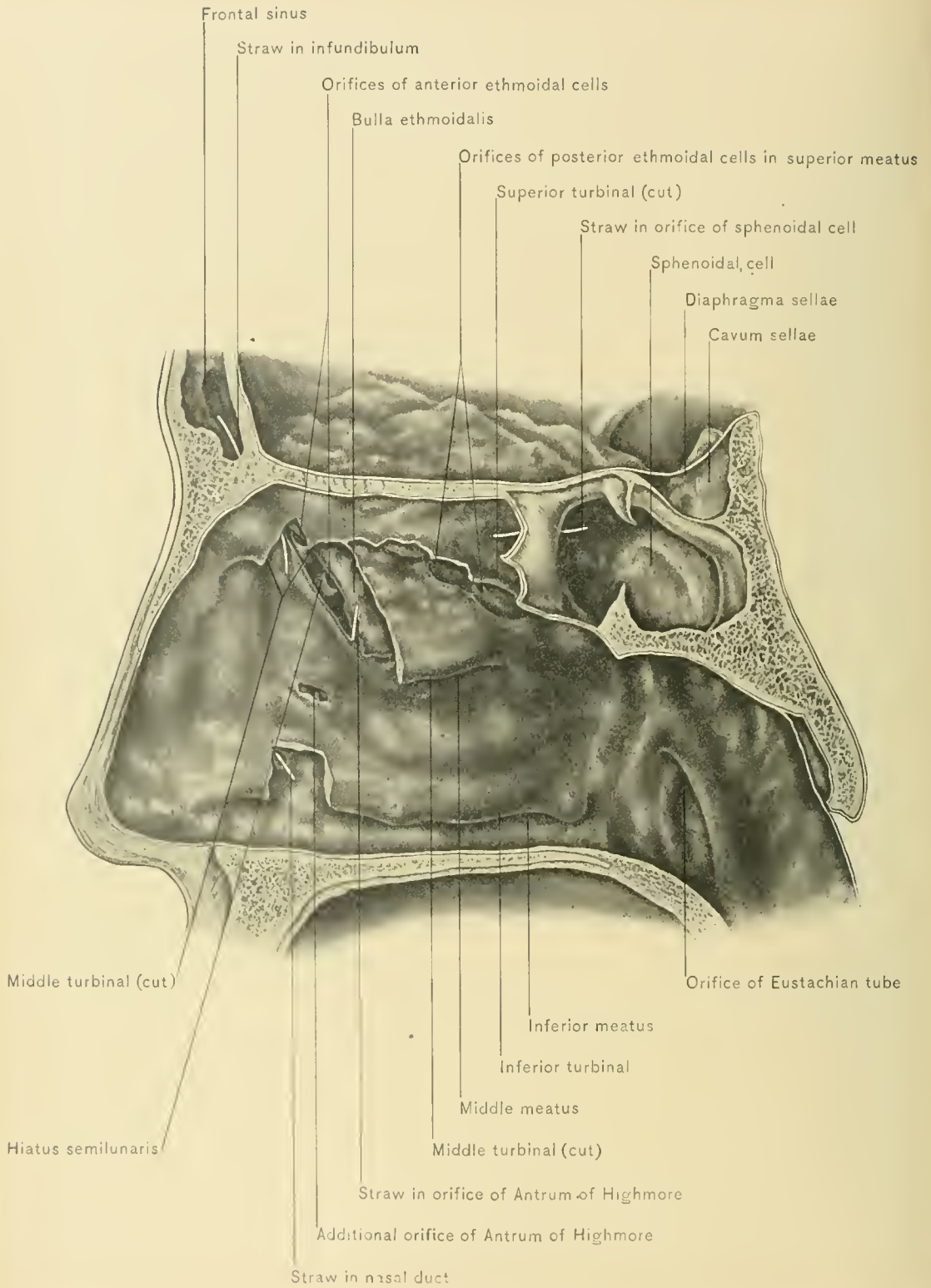
The antrum is usually larger in the male than in the female. In young subjects the antrum is small and its walls are quite thick; absorptive processes in old age may cause a defect in the anterior bony wall. The two antra are frequently asymmetric in size and shape. The roots of the first and second molar teeth often, and those of the premolars and canine teeth occasionally, form prominences in the floor of the cavity. It is evident that caries of these teeth and their fangs may lead to antral disease.

The *mucous membrane* of the maxillary sinus is thinner and less vascular than that of the nasal fossa.

The *orifice* of the antrum opens into the lower part of the hiatus semilunaris and the middle meatus of the nose. The orifice is small and rounded or elliptic. In empyema and mucocele of the antrum the orifice is usually closed by thickening of the mucous membrane of the nose in rhinitis. There may be one or more additional orifices leading into the nasal fossa.

The *tumors* which originate in the antrum may be either malignant or benign. By pressure upon the walls of the sinus they encroach upon the orbital and nasal fosse, lacrymal duct, pterygo-maxillary region, and mouth, and cause bulging of the cheek. The malignant tumors are removed by excising the superior maxilla.

Empyema, or abscess of the antrum, may be caused by extension of catarrh from the nose to the antrum, with occlusion of the antral orifice, retention of



ORIFICES OF NASAL DUCT AND ACCESSORY AIR-CHAMBERS OF NOSE.

mucus, and formation of pus; by diseased fangs of teeth projecting into the cavity; by fevers, as scarlet fever; and by injury. If the orifice of the antrum is not occluded, the pus may escape into the middle meatus by overflowing, which is favored by lying upon a horizontal surface with the opposite side of the face resting upon that surface. If the orifice is closed, it will be necessary to drain the antrum by extracting a carious bicuspid or molar tooth which may cause the abscess, and forcing a trocar through the alveolus into the antrum. If the teeth are not diseased, the sinus may be opened by everting the upper lip and drilling or trephining the canine fossa just above the second bicuspid tooth, or by drilling the nasal wall of the cavity in the middle or inferior meatus of the nose.

In *dropsy of the antrum*, or hydrods antri, a glairy or thin serous fluid occupies the maxillary sinus. It arises from cystic degeneration of the mucous membrane.

Dentigerous cysts of the antrum arise through abnormal development of a tooth, which may be caused by failure to lose one of the temporary teeth.

The **ethmoid sinuses** or **cells** are situated in the lateral masses of the ethmoid bone. On each side they are divided into two sets—an anterior and a posterior. The anterior set forms a rounded eminence, the *bullæ ethmoidalis*, situated in the outer wall of the nasal fossa just above the hiatus semilunaris, into which many of the cells open. The remaining anterior ethmoid cells open directly into the middle meatus of the nose. The posterior ethmoid cells open into the superior meatus of the nose. The ethmoid cells are lined by muco-periosteum continuous with that of the nasal fossa, and may be affected by catarrhal inflammation extending from the nose, by necrosis, mucocele, or malignant or benign growths.

The **sphenoid sinuses** or **cells** are located in the body of the sphenoid bone. They are usually two in number, being separated by a delicate septum. They are lined by muco-periosteum continuous with that of the nose and roof of the pharynx. Their orifices are situated in the posterior part of the roof of the nose, opposite the posterior extremity of the superior turbinated bone, and are said to open into the superior meatus of the nose. They may be the site of catarrh and malignant or benign growths.

DISSECTION.—The student should now remove the mucous membrane from the septum and the outer wall of the nose, and trace the vessels and nerves previously described. If the otic ganglion has not been destroyed and the part is in good condition, the ganglion may be seen by carefully removing the cartilaginous portion of the Eustachian tube and tracing upward the nerve to the internal pterygoid muscle. The ganglion will be found on the inner side of the inferior maxillary nerve, below the foramen ovale. For description of the otic ganglion, see volume 1, page 555.

THE ORBIT.

The **Orbits** are two irregularly conic or pyramidal cavities which contain the eyeballs and their accessory structures—muscles, vessels, nerves, and fat. The walls of each orbit are lined with a loosely attached periosteum or periorbita. The orbit has an apex, a base, and four walls.

The **apex of the orbit** is directed backward, and is situated at the optic foramen, through which the optic nerve and ophthalmic artery enter the orbit.

The **base of the orbit** is directed outward and forward, and is the only wall of this cavity which is absent or not filled by bone. The margins of the base are : above, the supra-orbital margin ; below, the infra-orbital margin. They project beyond the eyeball and protect it from injury by blows from large objects. The orbital margins are formed above by the frontal bone ; externally, by the malar bone ; internally, by the nasal process of the superior maxilla ; below, by the malar bone and the body of the superior maxilla. The supra-orbital margin contains the supra-orbital notch—a landmark in operations upon the supra-orbital and infra-orbital nerves. This notch is situated at the junction of the inner one-third with the outer two-thirds of that margin, and transmits the supra-orbital vessels and nerves.

The **roof of the orbit** is formed by the orbital plate of the frontal bone and the lesser wing of the sphenoid bone. The frontal sinuses frequently project backward into that part of the orbital roof formed by the frontal bone ; consequently tumors or an empyema of the frontal sinus may encroach upon the orbit and cause displacement of the eyeball and double vision—diplopia. At the outer side, near the base of the orbit, the roof presents a large depression—the lacrymal fossa—for the lacrymal gland ; and at the inner side, near the base of the orbit, the small depression to which the pulley of the superior oblique muscle is attached. On account of the relation between the orbit and the cranial cavity and the tenuity of the intervening bony wall, a foreign body with a sharp point, such as a foil or stick, may enter the orbit, pierce the roof of that cavity, and penetrate the brain without producing an apparently grave external injury.

The **floor of the orbit** is formed by the superior maxilla, the malar bone, and the orbital plate of the palate bone. Beneath the greater portion of the floor is the antrum of Highmore, tumors of which may encroach upon the orbit, displace the eyeball, and cause diplopia.

The **outer wall of the orbit** inclines obliquely forward and outward, and is formed by the malar bone, the external angular process of the frontal bone, and the greater wing of the sphenoid bone. When dividing the optic nerve in excision of the eyeball, the scissors is more readily introduced on the outer side,

because of the greater space between the eyeball and the outer wall and the outward slope of that wall, which makes a larger angle with the optic nerve than does the inner wall.

The **inner wall of the orbit** is formed by the nasal process of the superior maxilla, the internal angular process of the frontal bone, the lacrymal bone, the os planum of the ethmoid bone, and the body of the sphenoid bone. Near the base of the orbit the inner wall presents a large depression—the lacrymal groove—which lodges the lacrymal sac and below leads into the lacrymal canal, which is lined by the muco-periosteal wall of the lacrymo-nasal duct. In the inner wall of the orbit, and separated from that cavity by a thin bony partition, are the ethmoid cells and the sphenoid cell or sinus. Tumors, empyema, or mucocele of these cells may encroach upon the orbit, displace the eyeball, and cause diplopia.

Measurements.—The antero-posterior diameter of the orbit is about one and three-fourth inches. At the base the vertical diameter is about one and one-fourth inches, and the transverse diameter about one and one-half inches.

The orbit is widely open anteriorly, and posteriorly it is in communication with the cranial cavity through the optic foramen and the sphenoid fissure, and with the pterygo-maxillary region and spheno-maxillary fossa through the spheno-maxillary fissure.

Blood may be extravasated into the orbit after fracture of one of the walls of that cavity, more commonly the roof. Tumors, blood, or pus may enter the orbit from the pterygo-maxillary region through the spheno-maxillary fissure, and from the cranial cavity through the sphenoid fissure. Blood extravasated into the orbit produces subconjunctival ecchymosis.

DISSECTION.—According to the level at which the calvaria has been removed, there will be found remaining more or less of the vertical plate of the frontal bone, covered in front by the soft parts. The soft tissues should be turned down after making two incisions down to the bone, one running vertically upward from the nasion and the other running parallel to the vertical incision, and starting from the external angular process of the frontal bone. Should there be much of the vertical plate of the frontal bone remaining, it should be removed with hammer and chisel almost as far down as the supra-orbital arch. The roof of the orbit should now be removed, either entirely or all of it except the supra-orbital margin, as suggested by Cunningham. In the former method two cuts, converging at the optic foramen, are made with a saw, leaving the bone around the optic foramen undisturbed, and then, by a firm tap with a mallet, breaking away the orbital roof, and turning it forward. In Cunningham's method the thin plate of bone covering the orbit is removed with a chisel and mallet, leaving intact the

ring of bone around the optic foramen and that constituting the supra-orbital margin. Care should be taken to avoid injuring two structures—the pulley of the superior oblique muscle and the orbital periosteum.

If at the time the dissection of this portion of the body is begun the eyeball has collapsed, it should be inflated. After the periosteum has been opened, carry a ligature loosely around the optic nerve by means of an aneurysm needle; then insert a blowpipe between the optic nerve and its sheath, thrusting it almost, if not quite, into the eyeball. Inflate until the ball is tense; then, while an assistant is slowly withdrawing the blowpipe, draw the ligature tight.

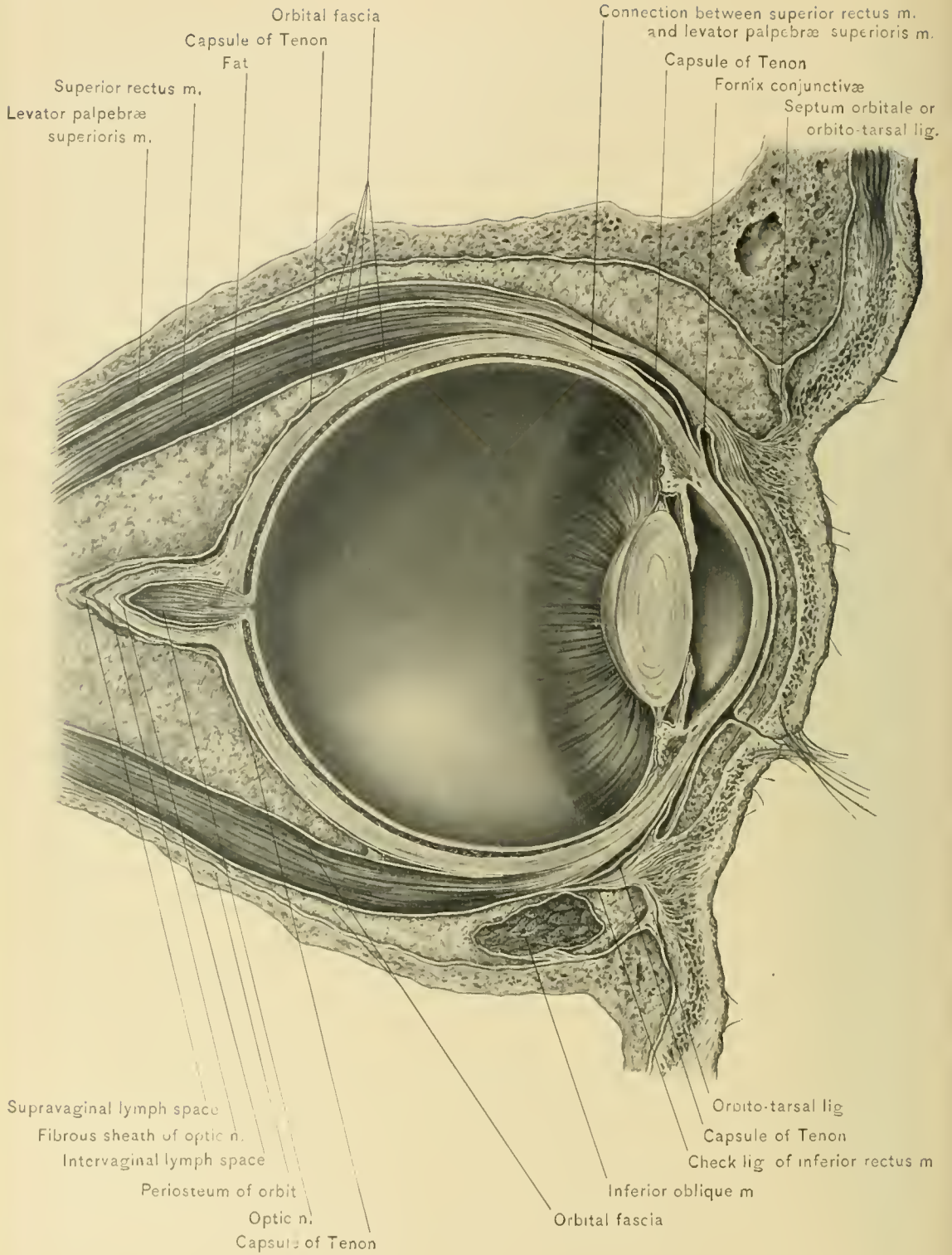The eyeball is preferably inflated from the front, this procedure being less difficult, more successful, and allowing reinflation when necessary. In this method a sharp needle is introduced obliquely at the sclero-corneal junction. The blowpipe is then inserted through the puncture, and, after the eyeball is distended, withdrawn. The valvular character of the incision is sufficient to prevent rapid escape of the air.

Orbital Periosteum or Periorbita.—The orbital roof having been removed, the periosteum comes into view. It incloses the structures which fill the orbit, and is but loosely attached to the bony walls. It is continuous posteriorly with the endosteal layer of the dura mater through the optic foramen and the sphenoid fissure. Anteriorly the periorbita divides at the orbital margins into two lamellæ—one is continuous with the periosteum on the facial surface of the bones which form those margins, and the other blends with the palpebral fascia of the eyelids.

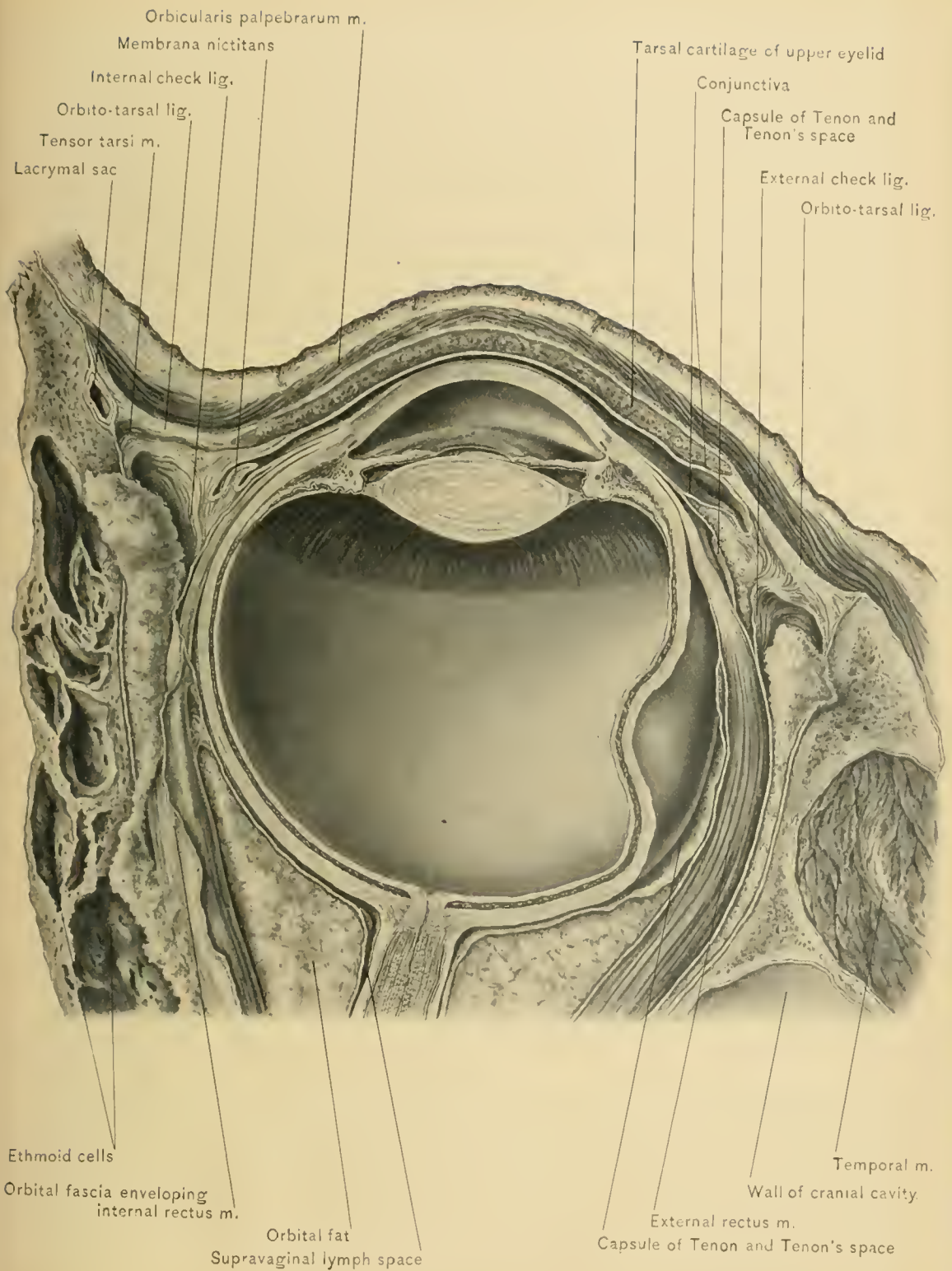
DISSECTION.—Two incisions are now made through the periosteum. One is transverse, and runs parallel to the supra-orbital ridge; the other is longitudinal, and runs antero-posteriorly from the optic foramen to the middle of the first incision. Either a very sharp knife must be used, or else a nick should be made in the periosteum and the rest of the cutting done with scissors or with a knife in the trough of a small grooved director. The two flaps thus formed should be carefully turned aside, gently separating them from the underlying structures. Further dissection is much facilitated by drawing forward the eyeball and retaining it in position with a suture or hooks, taking care not to puncture the eyeball, and allow the escape of its contained air.

Structures Exposed by Removal of the Periosteum.—The orbital fat, orbital fascia, and frontal nerve are exposed as soon as the flaps of periosteum are reflected. Careful removal of some of the orbital fat will demonstrate a number of structures.

In the median line the frontal nerve is readily demonstrable without dissection. It lies upon the levator palpebræ superioris muscle, and its anterior portion is accompanied by the supra-orbital artery.



ORBITAL FASCIA AND CAPSULE OF TENON—SAGITTAL SECTION.



ORBITAL FASCIA AND CAPSULE OF TENON—TRANSVERSE SECTION.

Running along the outer wall of the orbit, and just above the external rectus muscle, will be seen the lacrymal nerve and artery.

At the front and outer part of the orbit the lacrymal gland appears resting against the lacrymal fossa in the under surface of the horizontal plate of the frontal bone.

Along the inner wall will be seen the superior oblique muscle. At its anterior portion the fibrous ring or pulley through which its tendon works can be demonstrated; and, well back in its course, the fourth or pathetic nerve will be seen entering its fleshy portion.

The orbital fat.—The posterior half of the orbit contains a large mass of stringy, coherent fat, which forms a soft pad or cushion for the support of the eyeball, and fills the interstices between the muscles, vessels, and nerves. The sinking in of the eyeball, coincident with the emaciation of disease or age, is due to partial absorption of this fat.

Orbital abscesses are situated in the orbital fat and may develop therein; they may arise from ocular inflammation, periostitis, injuries, or result from extension from adjacent cavities, as the ethmoid or sphenoid cells, antrum of Highmore, pterygo-maxillary region, or cranial cavity. If the abscess attains a large size, it displaces the eyeball forward, retards its movements, and, through pressure upon the ophthalmic vein and its tributaries, causes congestion of the conjunctiva and swelling of the eyelids.

Foreign bodies may lodge in the orbital fat for a long time without causing much disturbance.

Emphysema of the orbit, or air in the orbital fat, results from rupture of the orbital periosteum and fracture of the wall intervening between the orbit and one of the accessory air-chambers of the nose—viz., the frontal sinuses, ethmoid cells, sphenoid cells, and antrum of Highmore.

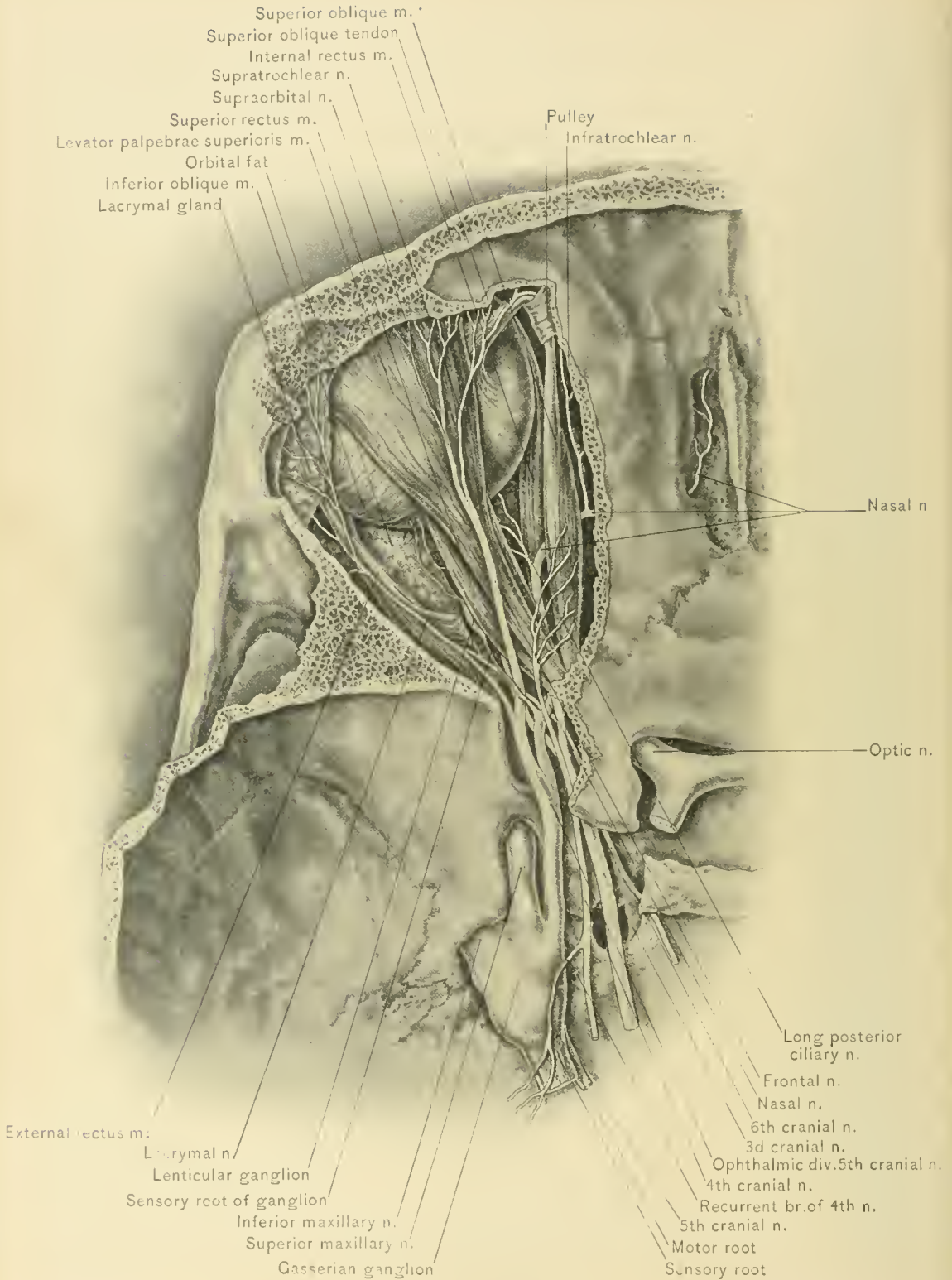
The **orbital fascia** resembles the deep fascia of other locations. It envelops and forms sheaths for the muscles, vessels, and nerves of the orbit, and sends partitions or septa into the orbital fat which separate it into lobules. Posteriorly, or at the apex of the orbit, the orbital fascia is continuous with the orbital periosteum around the origins of the muscles. It passes forward as a single layer between the muscles, and where each of the muscles is located it exists as two layers which envelop the muscle. Near the apex of the orbit it is thin and lax, but as it passes forward it becomes much stronger and more adherent to the muscles. About opposite the equator of the eyeball it divides into two laminae—the anterior and the posterior. The anterior lamina of the orbital fascia passes forward to blend with the orbital periosteum at the orbital margin and to the deep surface of the palpebral fascia in the eyelids, thus forming a funnel-shaped parti-

tion which supports the fornix of the conjunctiva. The posterior lamina turns backward behind the posterior one-third of the eyeball, and loosely envelops the optic nerve and its sheath.

The anterior lamina is a strong membrane throughout its extent, and that portion of it beneath the eyeball has been called the *suspensory ligament of the eyeball* because, after excision of the superior maxilla, the lower portion of the anterior lamina forms a hammock-like sling which supports the eyeball and prevents it from sinking downward. This ligament is attached externally to the malar bone, and internally to the crest of the lacrymal bone. Where the four rectus muscles are located the anterior lamina is stronger and forms *check ligaments*—the external and internal check ligaments being the stronger. The *external check ligament* passes outward and forward from the tendon of the external rectus muscle and under the lacrymal gland to be attached to the malar bone just behind the external palpebral ligament. The *internal check ligament* passes inward from the internal rectus muscle to be attached to the upper part of the crest of the lacrymal bone behind the tensor tarsi muscle. The check ligaments of the rectus muscles prevent extreme action of these muscles, and after the external or internal rectus muscle is divided, prevent the belly of the muscle from retreating far back into the orbit.

The *capsule of Tenon* is the membrane which envelops the posterior two-thirds of the eyeball. It is a thin, translucent, fibrous membrane formed by the posterior lamina and part of the anterior lamina of the orbital fascia, and extends from the insertions of the rectus muscles backward over the sclerotic coat of the eyeball almost to the place of entrance of the optic nerve. Here it is reflected backward over the sheath of the optic nerve to the apex of the orbit. The capsule approaches the sheath of the optic nerve in passing toward the apex of the orbit, but does not blend with it. The space between the sheath of the optic nerve and the capsule of Tenon is the *supra-vaginal lymph-space*, and that between the sclerotic coat and the capsule is *Tenon's space*. These are both lymph-spaces and are in communication. The capsule of Tenon is attached to the sclerotic coat and the sheath of the optic nerve by loose areolar tissue which permits free movement of the eyeball. The orbital surface of the capsule is in relation with the orbital fat. The capsule first comes into contact with the rectus muscles near the equator of the eyeball, where the capsule is pierced by the tendons of these muscles. The anterior margin of the capsule of Tenon forms a circular line connecting the insertion of the rectus muscles.

The posterior two-thirds of the eyeball and the capsule of Tenon might be said to form a ball-and-socket joint, permitting the various rotatory and gliding movements of the eyeball. The socket of the joint, or the capsule of Tenon, is



NERVES AND MUSCLES OF ORBIT.

held in position by the attachments of orbital fascia, and the globe is held in the socket chiefly by the rectus muscles.

After excision of the eyeball the muscles of the orbit are able to move the stump through their attachments to the capsule of Tenon.

The frontal nerve.—Of the three branches of the ophthalmic division of the fifth nerve, the lacrymal, the nasal, and the frontal, the last mentioned is by far the largest, and can be regarded as the continuation of the main trunk. It gains entrance to the orbit by way of the sphenoid fissure, lying external and on a plane slightly inferior to the fourth nerve. It then passes forward upon the levator palpebræ superioris muscle, between it and the orbital periosteum. At a point about midway between the sphenoid fissure and the supra-orbital notch it divides into its terminal branches—the supra-orbital and the supra-trochlear.

The **supra-orbital nerve** continues forward in the line of the frontal nerve, and with the supra-orbital artery leaves the orbit by way of the supra-orbital foramen or notch. It then turns upward on the forehead, and, dividing into an internal and an external branch, supplies the scalp as far back as the lambdoid suture. At the supra-orbital foramen it gives off a few filaments to the upper eyelid.

The **supra-trochlear nerve** runs toward the inner side of the orbit, and, as its name implies, passes over the pulley of the superior oblique muscle. There it gives off a twig which communicates with the infra-trochlear branch of the nasal nerve. It then passes out of the orbit accompanied by the frontal artery, gives a few twigs to the inner part of the upper eyelid, supplies the structures around the inner canthus of the eye and root of the nose, and sends a few filaments to the lining membrane of the frontal sinus.

The **lacrymal nerve** is the smallest branch of the ophthalmic division. It enters the orbit through the sphenoid fissure external to and slightly below the frontal nerve. It then courses along the outer wall of the orbit above the upper margin of the external rectus muscle accompanied by the lacrymal artery. Just behind the lacrymal gland it forms a loop of communication with the temporal branch of the orbital or temporo-malar nerve. From this loop and the immediate portion of the nerve, twigs are given off which enter the lacrymal gland. The remainder of the nerve continues forward, pierces the palpebral fascia, and supplies the skin and conjunctiva around the outer canthus of the eyelids.

The **fourth, pathetic, or trochlear nerve** enters the orbit through the inner end of the sphenoid fissure, occupying the highest position of all the structures which traverse it, and lying above and to the inner side of the frontal nerve. It is the smallest of all the cranial nerves. It passes over the origin of the levator palpebræ superioris muscle, lies to the inner side of the frontal nerve, and enters

the orbital surface of the superior oblique muscle, to which alone it is distributed.

The **lacrymal gland** is a distinctly lobulated structure, which lies in the outer part of the orbit under the external angular process of the frontal bone. It is composed of two portions of unequal size, which are separated by the aponeurotic expansion of the levator palpebræ superioris muscle. The separation is not perfect, there being gaps which allow of communication between the portions of the gland. Of the two portions, the upper is by far the larger, and is called the superior or orbital portion, or superior lacrymal gland; the lower and smaller part is called the inferior or palpebral portion, or inferior lacrymal gland.

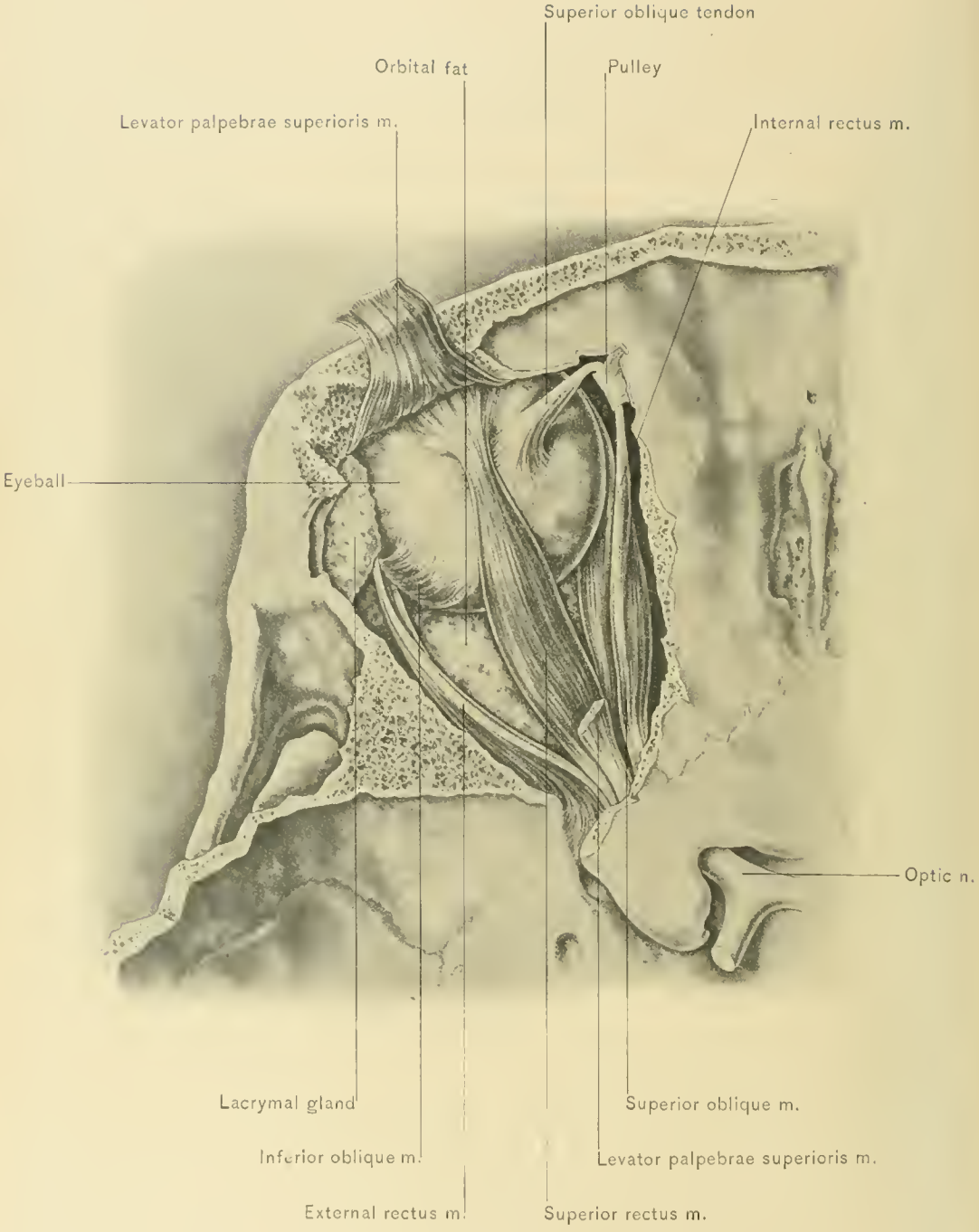
The *superior lacrymal gland*, as stated, comprises the main part of the gland. It is about the size of a small almond. Its upper surface is convex, and its lower surface concave. It is inclosed by a capsule, from which run fibrous trabeculæ to be inserted into the posterior border of the orbital margin. These bands are called the *suspensory ligaments of the lacrymal gland*.

The *inferior lacrymal gland* is looser in texture. It extends into the outer one-third of the upper eyelid, and can be readily seen in this position when the eyelid is everted.

The lacrymal gland secretes the tears, which flow through ten to fifteen ducts into the outer part of the superior conjunctival fornix about four millimeters above the upper margin of the tarsal cartilage. The tears flow thence inward over the ocular conjunctiva to the puncta lachrymalia, and pass through the lacrymal canaliculi, lacrymal sac, and lacrymo-nasal duct into the inferior meatus of the nose.

The **Muscles of the Orbit** are the levator palpebræ superioris, superior oblique, superior rectus, external rectus, internal rectus, inferior rectus, and inferior oblique. With one exception—the inferior oblique—they arise from the margin of the optic foramen and diverge as they pass forward to their insertion.

The **levator palpebræ superioris muscle** pursues a forward course between the orbital periosteum and the superior rectus muscle, which lies immediately below it. It arises from the orbital roof, above and in front of the optic foramen, and passes forward, gradually widening. It expands into a broad aponeurosis, passes between the two portions of the lacrymal gland, and splits into three lamellæ. The uppermost lamella blends with the superior orbito-tarsal ligament; the middle lamella, the most easily demonstrable, is inserted into the anterior surface of the upper border of the tarsal cartilage; the lower lamella is attached to the conjunctival fornix. The margins of the tendon are attached to the margin of the orbit, and thus any excessive action of the muscle is prevented.



ACTION.—It raises the upper eyelid and retains it in that position. The muscle relaxes, and the eyelid falls as one becomes sleepy.

NERVE SUPPLY.—From the superior division of the motor oculi nerve, a branch which pierces the superior rectus muscle.

The **superior oblique muscle** takes its origin from the orbital roof at the upper and inner margins of the optic foramen. It extends as a fleshy belly along the upper and inner part of the orbital wall above the internal rectus muscle. It then narrows into a shining, slender tendon, which enters the ring-like pulley attached to the frontal bone. Leaving the pulley, the tendon changes its course to an outward and a backward direction. It then passes under the superior rectus muscle, and expands to be inserted into the sclera midway between the entrance of the optic nerve and the margin of the cornea, and between the superior rectus and external rectus muscles.

The *pulley or trochlea of the superior oblique muscle* is a fibro-cartilaginous ring, which is attached by a fibrous plate to the trochlear fossa in the under surface of the orbital plate of the frontal bone. The ring is lined by a synovial sheath, and this sheath is continued over its contained tendon. Chronic serous effusion into this synovial sheath sometimes exists in persons past middle life, and causes a cystic swelling at the upper and inner portion of the upper eyelid.

ACTION.—It rotates the eyeball inward, and as the muscle is inserted into the posterior portion of the globe, it draws the cornea downward and slightly abducts it. It counteracts the tendency of the inferior rectus muscle to rotate the cornea outward, and the tendency of the superior and inferior recti muscles to adduct the cornea.

NERVE SUPPLY.—From the pathetic or fourth cranial nerve.

DISSECTION.—Divide the frontal nerve and levator palpebræ superioris muscle, and dissect the latter free from the underlying structures. While dissecting up the levator palpebræ superioris muscle, a nerve filament should be observed which passes through the underlying muscle—the superior rectus—and enters the under surface of the posterior portion of the levator palpebræ superioris muscle. This is the branch of the oculo-motor nerve, which supplies that muscle.

The **superior rectus muscle** is now fully exposed. It arises from the upper portion of the anterior margin of the optic foramen, and becomes broader as it passes forward between the levator palpebræ superioris muscle and the optic nerve. It is inserted by a thin, expanded tendon into the sclera, about one-fourth to one-third of an inch behind the upper margin of the sclero-corneal junction.

ACTION.—It rotates the eyeball upward, in addition to adducting and rotating the cornea inward—*i. e.*, it carries the cornea upward, adducts it, and slightly rotates it inward.

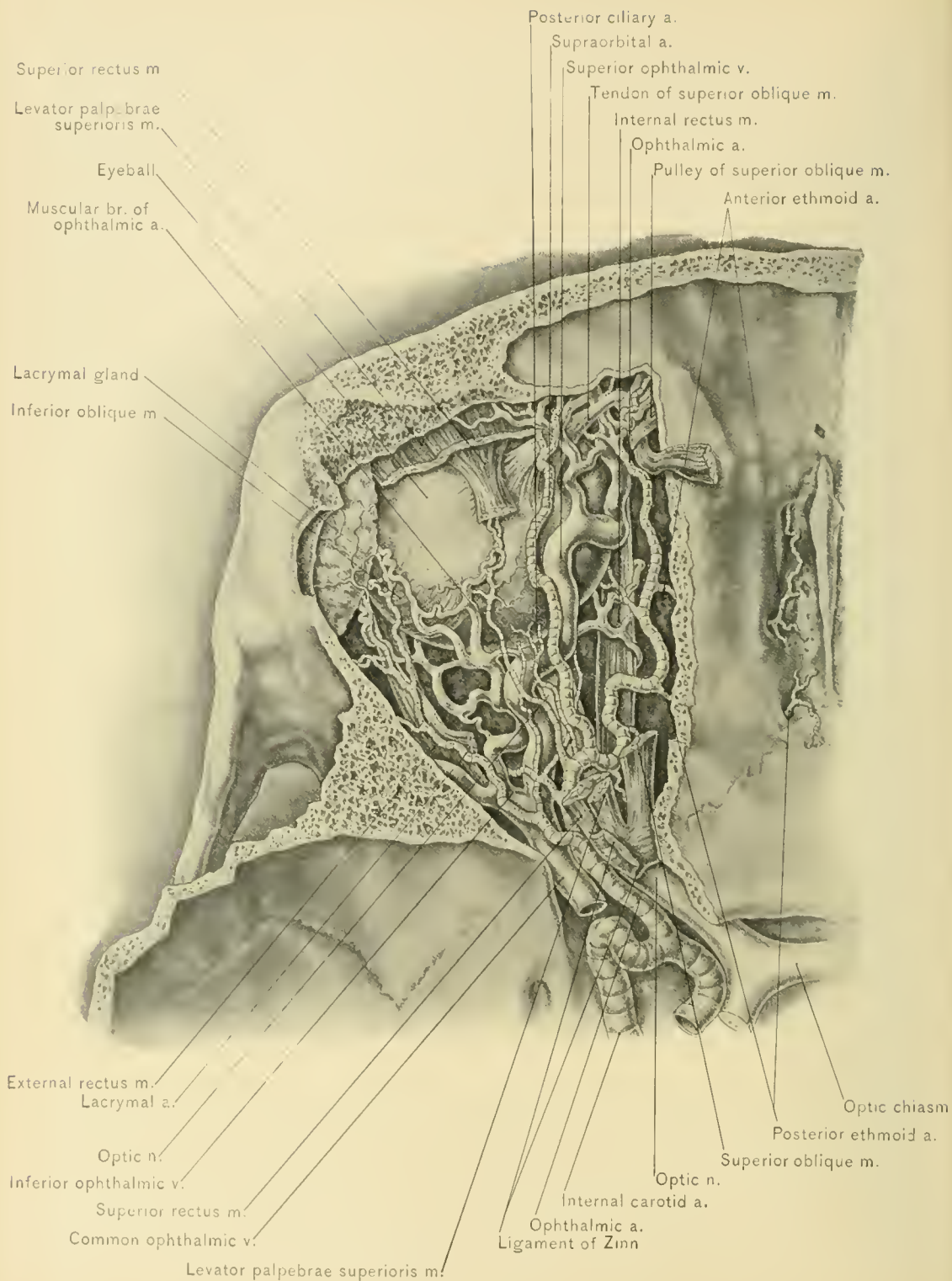
NERVE SUPPLY.—From the superior division of the motor oculi nerve.

DISSECTION.—This is a very important stage of the dissection, and if care is not exercised, some of the important structures will be destroyed. Divide the superior rectus muscle and reflect it. While dissecting this muscle free from the underlying structures, observe a nerve filament entering the under surface of the posterior portion of the divided muscle. This nerve is the superior division of the oculo-motor nerve, and, as previously stated, sends a perforating branch through the superior rectus muscle to supply the levator palpebræ superioris muscle. Remove a quantity of loose fat, and when working on the outer side of the optic nerve, take especial care not to injure the lenticular ganglion or its connections. The optic nerve, as well as numerous structures above and upon each side of it, will now be exposed. These are the nasal nerve, the ophthalmic artery and vein, and the long ciliary branches of the nasal nerve, all of which cross the optic nerve. There may also be found the short ciliary nerves. These are more numerous than the long ciliary nerves, and one of the largest should be selected and followed backward until its source of origin, the lenticular ganglion, is reached. By careful work the roots of this ganglion can be worked out by tracing them backward from the ganglion. They will lead to the nasal nerve, the inferior division of the oculo-motor nerve, and the cavernous plexus of the sympathetic nerve.

In the posterior portion of the orbit the third nerve, the nasal branch of the ophthalmic nerve, the sixth nerve, and the ophthalmic vein can be seen passing between the heads of the external rectus muscle.

In the anterior portion of the orbit the reflected tendon of the superior oblique muscle can now be more readily seen, for reflection of the superior rectus muscle has exposed its terminal portion.

The **Nasal Nerve** is a branch of the ophthalmic division of the fifth nerve. It gains access to the orbit through the sphenoid fissure, and passes between the two heads of the external rectus muscle and between the divisions of the oculo-motor nerve. It then crosses to the inner wall of the orbit, passing over the optic nerve and immediately under the superior rectus muscle, taking a position between the superior oblique muscle and the internal rectus muscle. After giving off the infra-trochlear branch, it leaves the orbit through the anterior ethmoid foramen. It then takes the following course: Having passed through the anterior ethmoid foramen, it again becomes an occupant of the cranial cavity, lying between the dura mater and the cribriform plate of the ethmoid bone. Here it leaves the cranial cavity through the ethmoid fissure, or nasal slit at the side of the crista galli, and becomes an occupant of the nasal fossa. It has thus traversed in succession the cranial cavity, the orbit, the cranial cavity again, and, finally, the



ARTERIES AND VEINS OF ORBIT.

nasal cavity. It then gives off an internal and an external branch, and continues as the anterior or terminal branch.

The *internal or septal branch* supplies the anterior part of the septum.

The *external branch* supplies the anterior portion of the middle and inferior turbinated bones and the mucous membrane of the outer nasal wall.

The *anterior or terminal branch* runs downward in the groove on the under surface of the nasal bone, passes between the lower edge of the nasal bone and the superior lateral nasal cartilage, and supplies the sides and tip of the nose.

The **branches of the nasal nerve** in the orbit are four in number: the long root to the lenticular ganglion, the two long ciliary nerves, and the infra-trochlear nerve.

The *branch to the lenticular ganglion*, known as the long, upper, or sensory root of that ganglion, arises from the nasal nerve as it passes between the two heads of the external rectus muscle. It is very slender, and measures about one-half of an inch in length. It passes along the outer side of the optic nerve, and enters the posterior superior angle of the lenticular ganglion.

The *long ciliary nerves* are usually two in number. They arise from the nasal nerve as it crosses the optic nerve, and run along the inner side of the optic nerve to enter the eyeball by piercing the sclera. One of these nerves usually unites with one of the short ciliary nerves. Their course between the sclera and choroid is described with the eyeball.

The *infra-trochlear nerve* arises from the nasal nerve just before that nerve enters the anterior ethmoid foramen. It traverses the inner orbital wall below the superior oblique muscle and its pulley. It forms a loop of communication with the supra-trochlear nerve at times behind, but usually in front of, the pulley of the superior oblique muscle. It supplies the region around the inner canthus of the eyelids, including the lacrymal sac and the lacrymal caruncle.

The **Ophthalmic Artery** is a branch of the cavernous portion of the internal carotid artery. It enters the orbit by passing through the optic foramen in company with the optic nerve, holding a position to the outer side of, and a little below, the nerve. The ophthalmic artery, like arteries in other parts of the body in which the tissues must be freely movable,—*e. g.*, the facial and splenic arteries,—is very tortuous, to allow of its elongation. At first it lies to the outer side of the optic nerve, soon crossing over that nerve and running along and near the internal orbital wall, between the superior rectus and the internal rectus muscle. At the inner canthus of the eyelids it terminates by dividing into the nasal and frontal arteries.

The **branches of the ophthalmic artery** are the lacrymal, ethmoid, supra-orbital, retinal, ciliary, muscular, palpebral, nasal, and frontal.

The **lacrymal artery** is given off from the ophthalmic artery, between the superior rectus and the external rectus muscle, soon after the ophthalmic artery has entered the orbit. It accompanies the lacrymal nerve to the lacrymal gland, which it supplies, finally terminating in the conjunctiva and eyelids. It sends off twigs as follows: (1) A *recurrent branch*, which passes backward through the sphenoid fissure to anastomose with the middle meningeal artery; (2) *muscular branches* to the external rectus muscle; (3) *malar branches*, which traverse the malar bone to enter the temporal fossa, one anastomosing with the deep temporal arteries and middle temporal artery, and the other with the transverse facial artery; (4) *palpebral branches*, which form an arch in each eyelid with the palpebral branches of the ophthalmic artery; and (5) some *anterior ciliary branches*.

The **supra-orbital artery** arises from the ophthalmic artery as that vessel crosses the optic nerve. It accompanies the frontal nerve upon the levator palpebræ superioris muscle, emerging upon the forehead through the supra-orbital foramen. Having reached the forehead, it divides into a superficial and a deep branch, the former ramifying in the superficial fascia, and the latter in the areolar tissue layer of the scalp. It anastomoses with the anterior temporal artery, the angular artery, and the supra-orbital artery of the opposite side. Its branches are: (1) *Periosteal*, to the roof of the orbit; (2) *muscular*, to the adjacent muscles; (3) *diploic*, to the diploë and frontal sinus; (4) *trochlear*, to the pulley of the superior oblique muscle; and (5) *palpebral*, to the upper eyelid.

The **central artery of the retina** arises from the ophthalmic artery just anterior to the optic foramen. It enters the optic nerve obliquely, about one-half of an inch behind the eyeball, and traverses the nerve to reach the interior of the eyeball and supply the retina.

Ciliary arteries.—Of these there are three sets—short posterior, long posterior, and anterior.

The *short posterior ciliary arteries* are about twelve in number, and arise from the ophthalmic artery. They run tortuously forward and pierce the sclerotic coat in a ring around the optic nerve, to be distributed to the choroid coat of the eyeball.

The *long posterior ciliary arteries* are two in number, and, arising from the ophthalmic artery, pass forward on each side of the optic nerve to pierce the sclerotic coat of the eyeball. They then run between the choroid and sclerotic coats as far forward as the ciliary body and iris.

The *anterior ciliary arteries* are branches of the muscular and lacrymal arteries, and are about eight in number. They pass forward in company with the tendons of the rectus muscles, and run beneath the conjunctiva. They then pierce the

sclera, about one-fourth of an inch behind the sclero-corneal junction, and terminate in the great arterial circle around the iris and in the ciliary processes.

The **ethmoid arteries** are two in number—posterior and anterior.

The *posterior ethmoid artery* passes outward between the internal rectus muscle and the superior oblique muscle, and enters the posterior ethmoid foramen. Having reached the posterior ethmoid cells, it gives off branches which nourish their walls and the lining mucous membrane. It then enters the cranial cavity, and gives off branches to a small area of dura mater and nasal branches which pass downward through the cribriform plate of the ethmoid bone, to supply the mucous membrane of the roof of the nose.

The *anterior ethmoid artery* is larger than the posterior ethmoid artery, and traverses the anterior ethmoid foramen in company with the nasal nerve. It accompanies the nerve in the cranial cavity, and out of that cavity through the ethmoid fissure into the nose. Its branches are the following: (1) *Ethmoid*, to the walls and mucous membrane of the anterior ethmoid cells; (2) *meningeal*, to the dura mater in the anterior cranial fossa; (3) *nasal*, to the outer and anterior part of the mucous membrane of the nose; (4) *frontal*, to the frontal sinus; and (5) *terminal*, which accompanies the terminal branch of the nasal nerve to the skin of the nose.

The **muscular branches of the ophthalmic artery** are variable in number and origin, and are distributed to the muscles of the orbit. They give off the greatest number of the anterior ciliary arteries.

The **palpebral arteries** are two in number—superior and inferior. They arise from the ophthalmic artery, either separately or by a common trunk, almost opposite the pulley of the superior oblique muscle. They pass one above and the other below the tendo oculi, run between the tarsal cartilage and the orbicularis palpebrarum muscle, near the edge of the eyelid, and anastomose with the palpebral branches of the lacrymal artery, thus forming a vascular arch in each eyelid. They also supply the lacrymal duct and caruncle and the adjacent conjunctiva.

The **nasal artery** is the lower terminal branch of the ophthalmic artery. It leaves the orbit by piercing the orbito-tarsal ligament or palpebral fascia above the tendo oculi. It then passes down the side of the nose, and anastomoses with the angular or lateral nasal branches of the facial artery.

The **frontal artery** is the upper of the terminal branches of the ophthalmic artery. It leaves the orbit at the inner canthus of the eyelids by piercing the palpebral fascia, and passes upward on the forehead, anastomosing with the supra-orbital artery, the anterior temporal artery, and the frontal artery of the opposite side.

The **Ophthalmic Veins** are three in number. They are the common ophthalmic vein, superior ophthalmic vein, and inferior ophthalmic vein. Neither

these veins nor their tributaries have valves. Their anastomosis is fairly free, the communications being with veins corresponding to the arteries with which the branches of the ophthalmic artery anastomose.

The **common ophthalmic vein**, formed by the union of the superior and inferior ophthalmic veins, is short and thick. It passes between the heads of the external rectus muscle, through the sphenoid fissure, and enters the cavernous sinus.

The **superior ophthalmic vein** is considerably larger than the inferior ophthalmic vein. It commences at the inner portion of the upper eyelid by a free anastomosis with the frontal, supra-orbital, and angular veins, and, following a straighter course than the ophthalmic artery, crosses over the optic nerve to reach the inner end of the sphenoid fissure, where it joins the inferior ophthalmic vein to form the common ophthalmic vein.

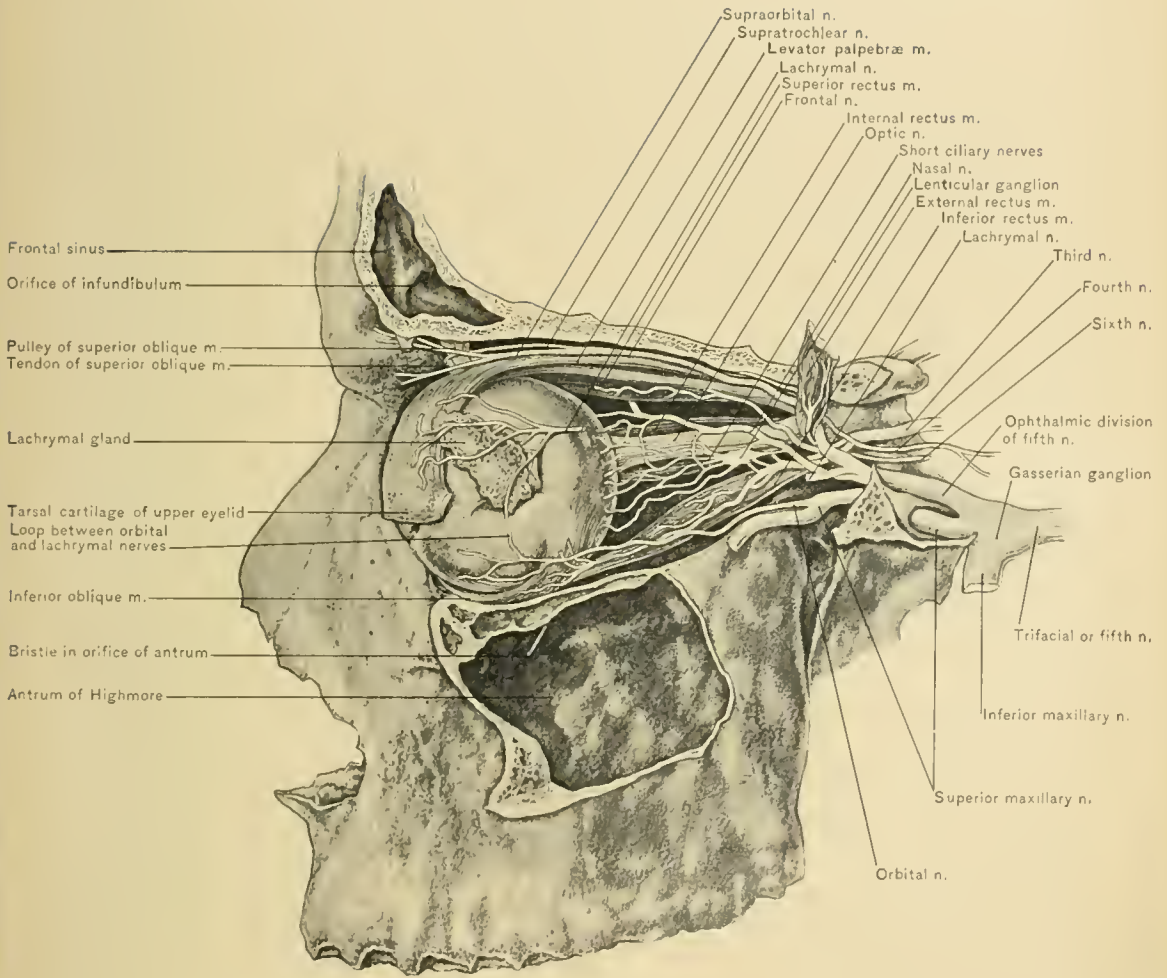
The **inferior ophthalmic vein** is formed by the union of the inferior muscular and posterior ciliary veins in the lower external portion of the orbit. It lies below the plane of the optic nerve, and communicates with the pterygoid plexus of veins by a twig which passes through the sphenomaxillary fissure. It then runs backward to the rear of the orbit, and joins the superior ophthalmic vein, as previously described. The inferior ophthalmic vein, as well as the superior, empties at times directly into the cavernous sinus.

Phlebitis of the ophthalmic veins may extend to the cavernous sinus and cause fatal thrombosis.

Pulsation of the ophthalmic vein and of the orbit may be produced by an arterio-venous aneurysm between the internal carotid artery and the cavernous sinus. Pulsation of the orbit may also be caused by traumatic aneurysm of one of the arteries of the orbit, or pulsation transmitted to the terminal portion of the ophthalmic vein from an aneurysm of the internal carotid artery.

The **Lenticular, Ophthalmic, or Ciliary Ganglion** is a small, reddish body, slightly larger than the head of an ordinary pin. It is of quadrilateral outline, and both its surfaces are slightly convex. It lies about one-fourth of an inch in front of the sphenoid fissure, and between the optic nerve on the inner side and the external rectus muscle on the outer side. It is usually situated at the outer side of the ophthalmic artery, to which it is, at times, closely adherent. Like all the sporadic ganglia connected with the fifth nerve, it has afferent and efferent filaments. The afferent filaments are three in number, and are termed its roots; the efferent filaments are the branches of distribution.

The **roots** are motor, sensory, and sympathetic. The motor, or short root, is derived from that branch of the oculo-motor nerve which runs to the inferior oblique muscle. It enters the posterior inferior angle of the ganglion. The



sensory or long root springs from the nasal branch of the ophthalmic division of the fifth nerve. It passes along the outer side of the optic nerve, and enters the posterior superior angle of the ganglion. The sympathetic root has its origin in the cavernous plexus, and is somewhat difficult to dissect satisfactorily. It enters the back portion of the ganglion in one of three ways: most commonly in company with the sensory root, more rarely alone, in the form of a bunch of fine filaments, and least frequently in company with the motor root.

BRANCHES.—From the anterior border of the ganglion about six delicate filaments are given off, which run forward to the eyeball and, by subdividing, number twenty when they reach the globe. They are termed the short ciliary nerves. They surround the optic nerve and pierce the sclerotic coat in a circle around the entrance of that nerve. Having penetrated the sclerotic coat, they are joined by the long ciliary nerves. They are ordinary sensory and trophic nerves to the eyeball, and motor nerves to the radiating fibers of the iris, the ciliary muscle, and the sphincter iridis. The motor oculi filaments supply the circular muscular fibers of the iris; and the sympathetic fibers supply the radiating muscular fibers of the iris.

The **Third, Motor Oculi**, or **Oculo-motor Nerve** lies in the outer wall of the cavernous sinus, holding the highest position of all the nerves situated there. It passes to the sphenoid fissure, and here divides into a superior and an inferior division. These divisions then pass through the sphenoid fissure and between the heads of the external rectus muscle, separated from each other by the nasal branch of the ophthalmic nerve.

The superior division, the smaller of the two, has already been traced. It supplies the superior rectus muscle and the levator palpebræ superioris muscle.

The inferior division very soon breaks up into three branches. Two of these are comparatively short, and enter the ocular surface of the two muscles to which they are distributed,—the inferior and internal recti muscles,—the branch to the internal rectus muscle passing under the optic nerve. The third branch pursues a longer course, and runs along the floor of the orbit to supply the inferior oblique muscle. It occupies the interval between the inferior and external rectus muscles and enters the inferior oblique muscle at its posterior border. It gives off, near its origin, the motor root to the lenticular ganglion.

The oculo-motor nerve supplies the lenticular ganglion and the muscles of the orbit, with the exception of the external rectus and superior oblique muscles. Through the lenticular ganglion it supplies the ciliary muscle and the sphincter ^{relator} iridis.

The **Sixth**, or **Abducent Nerve**, passes forward in the inner wall of the cavernous sinus, lying on the outer side of, and slightly posterior to, the internal carotid artery. It enters the orbit through the inner part of the sphenoid fissure,

between the inferior division of the oculo-motor nerve and the ophthalmic vein. It then passes between the heads of the external rectus muscle, to terminate in the ocular surface of that muscle and supply it.

Arrangement of the Nerves of the Orbit, in the walls of the cavernous sinus and in the sphenoid fissure, is as follows: In the *outer wall of the cavernous sinus* there are, from above downward, the third nerve, the fourth nerve, and the ophthalmic division of the fifth nerve; in the inner wall is the sixth nerve, in relation with the outer side of the internal carotid artery. These nerves are separated from the cavity of the sinus by its endothelial lining. In the *sphenoid fissure* the lacrymal, frontal, and pathetic or fourth nerve occupy a higher plane than the other nerves, and are found in the order named from without inward. They pass above the origin of the muscles, while the other nerves and the ophthalmic vein are lower down and enter the orbit between the two heads of the external rectus muscle. The nerves lying on a lower plane in the sphenoid fissure are, from without inward, the superior division of the oculo-motor nerve, the nasal nerve, the inferior division of the oculo-motor nerve, and the abducent or sixth nerve. The ophthalmic vein lies to the inner side of the sixth nerve.

The **optic nerve** enters the orbit through the optic foramen, in company with the ophthalmic artery, and passes into the eyeball about one-tenth of an inch, or 2.5 millimeters, internal to the posterior pole of that organ. It is invested by a sheath of dura mater and arachnoid, and is surrounded by an extension of the capsule of Tenon, the orbital fat and vessels, and the rectus muscles. It is pierced and traversed by the vena centralis retinae and arteria centralis retinae.

The **External Rectus Muscle** is seen along the outer wall of the orbit. It has two heads of origin: the upper head arises from the outer margin of the optic foramen, beneath the superior rectus muscle, and the lower head, partly from the ligament or tendon of Zinn and partly from a small spine of bone situated on the lower margin of the sphenoid fissure. Between these two heads pass the third nerve, the nasal nerve, the sixth nerve, and the ophthalmic vein. The external rectus muscle is inserted by an expanded tendon into the sclerotic coat of the eyeball about one-fourth to one-third of an inch behind the outer margin of the cornea.

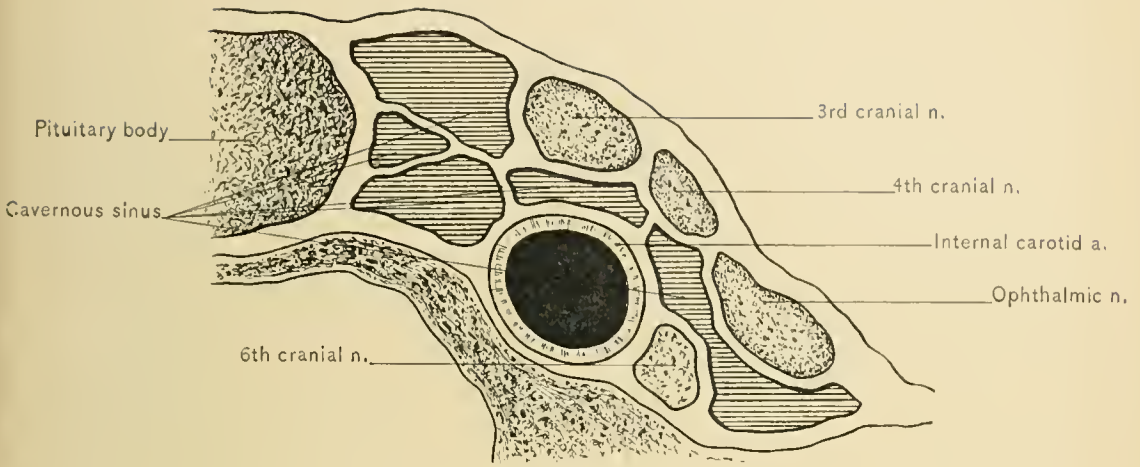
ACTION.—It abducts the cornea.

NERVE SUPPLY.—From the abducent or sixth cranial nerve.

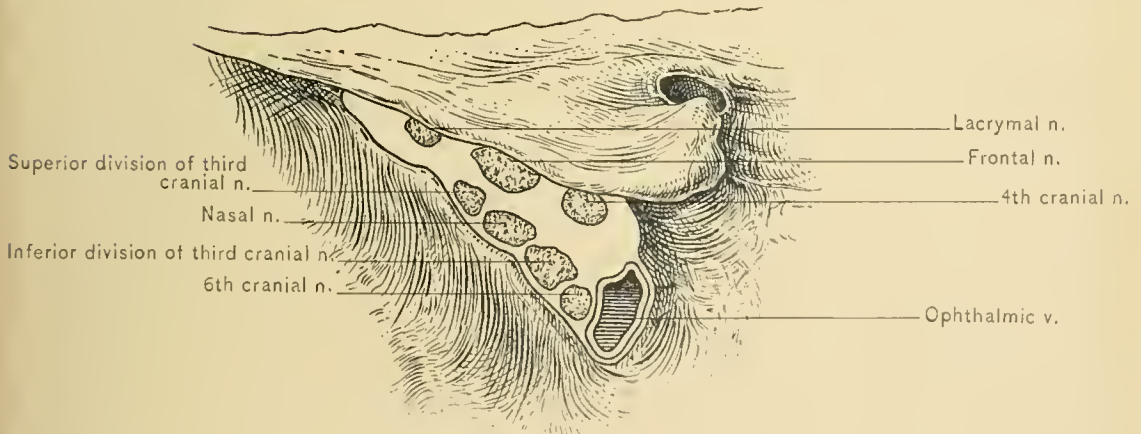
The **Internal Rectus Muscle** lies along the inner wall of the orbit, below the superior oblique muscle, ophthalmic artery, and nasal nerve. It arises through the ligament or tendon of Zinn from the inner margin of the optic foramen, and is inserted into the sclerotic coat of the eyeball about one-fourth to one-third of an inch behind the inner margin of the cornea.

ACTION.—It abducts the cornea.

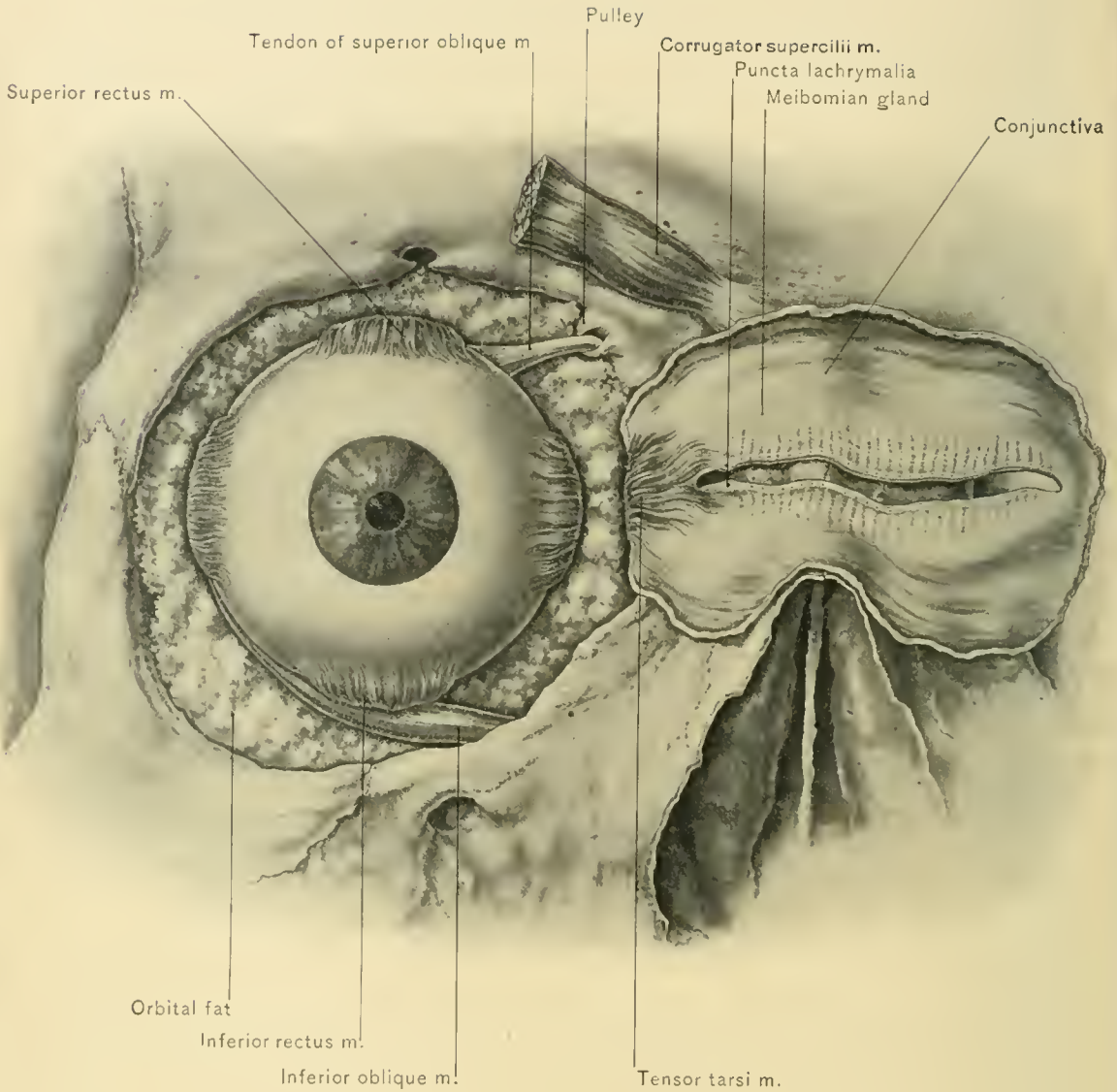
NERVE SUPPLY.—From the inferior division of the third cranial nerve.



SECTION OF CAVERNOUS SINUS.



STRUCTURES TRAVERSING SPHENOID FISSURE.



TENSOR TARSII AND CORRUGATOR SUPERCILII MUSCLES.

The **Inferior Rectus Muscle** arises from the lower margin of the optic foramen through the ligament or tendon of Zinn. It passes forward along the floor of the orbit and below the optic nerve, and is inserted into the sclerotic coat of the eyeball about one-fourth to one-third of an inch from the lower margin of the cornea.

ACTION.—It depresses the cornea, adducts it, and rotates it outward.

NERVE SUPPLY.—From the inferior division of the motor oculi or third cranial nerve.

The inferior rectus muscle can be better studied after the dissection of the vessels, the nerves, and the other muscles has been completed, and those structures have been removed.

Ligament of Zinn.—By observation of the ocular surfaces of the origin of the *four rectus muscles*, it will be seen that these muscles arise from a common tendinous ring which is attached around the optic foramen. This common tendon may be divided into a superior and an inferior common tendon. The *superior common tendon* is attached to the upper margin and the upper outer part of the margin of the optic foramen, and gives origin to the superior rectus muscle, part of the internal rectus muscle, and the upper head of the external rectus muscle.

The inferior common tendon, or *ligament of Zinn*, is attached to the lower part of the inner margin, the lower margin and the lower part of the outer margin of the optic foramen, and gives origin to the inferior rectus muscle and part of the internal rectus muscle, and the lower head of the external rectus muscle.

DISSECTION.—The inferior oblique muscle is next exposed. Its position and relations differ much from those of the other orbital muscles, and it can best be seen after the following dissection: Release the eyeball from any position in which it may be held. Evert the lower eyelid, and remove the conjunctiva from it at the inferior fornix. Remove the fat lying in the floor of the anterior portion of the orbit, and clean the exposed muscle. In doing this be careful not to cut the nerve which enters the posterior border of the inferior oblique muscle.

The **Inferior Oblique Muscle** arises by a flat tendon from the orbital plate of the superior maxilla to the outer side of the orbital orifice of the lacrymal duct. It passes outward and backward under the inferior rectus muscle, and then upward between the globe and the external rectus muscle. It ends in a membranous tendon which is inserted into the sclera on the upper and outer side of the globe, below and external to the insertion of the superior oblique muscle.

ACTION.—It rotates the eyeball outward, and elevates and abducts the cornea. In abducting the cornea it counteracts the tendency of the superior rectus muscle and inferior rectus muscle to adduct the cornea.

NERVE SUPPLY.—From the longest branch of the inferior division of the oculo-motor nerve, which enters the muscle at its posterior margin.

DISSECTION.—The ocular conjunctiva should now be removed from the sclerotic coat of the eyeball as far forward as the margin of the cornea, so that the positions of the attachments of the four rectus muscles can be observed.

The rectus muscles are inserted by thin, flat, slightly expanded tendons into the sclerotic coat of the eyeball, one-fourth to one-third of an inch from the margin of the cornea.

ACTION.—The actions of the rectus and oblique muscles of the orbit are somewhat complex, as almost every movement of the eyeball is performed by two or more muscles. In considering the movements of the eyeball it must be remembered that the globe can not be moved away from its position, in which it is closely retained by the capsule of Tenon and the attachments of the orbital fascia, forward movement being prevented by the rectus muscles. The only movements of the eyeball are rotation around any axis of the globe, limited by the attachments of the orbital fascia existing between the muscles and the adjacent structures, as the orbital periosteum and the palpebral fascia. These movements are more easily understood if only the motion of the cornea is considered.

Adduction of the cornea is performed by the internal rectus muscle, and abduction of the cornea by the external rectus muscle and the two oblique muscles.

Elevation of the cornea, as in looking directly upward, is performed by the superior rectus muscle, the inferior oblique muscle preventing adduction of the cornea and rotation of the cornea inward. Rotation of the cornea inward is movement of the uppermost portion of the cornea inward and downward.

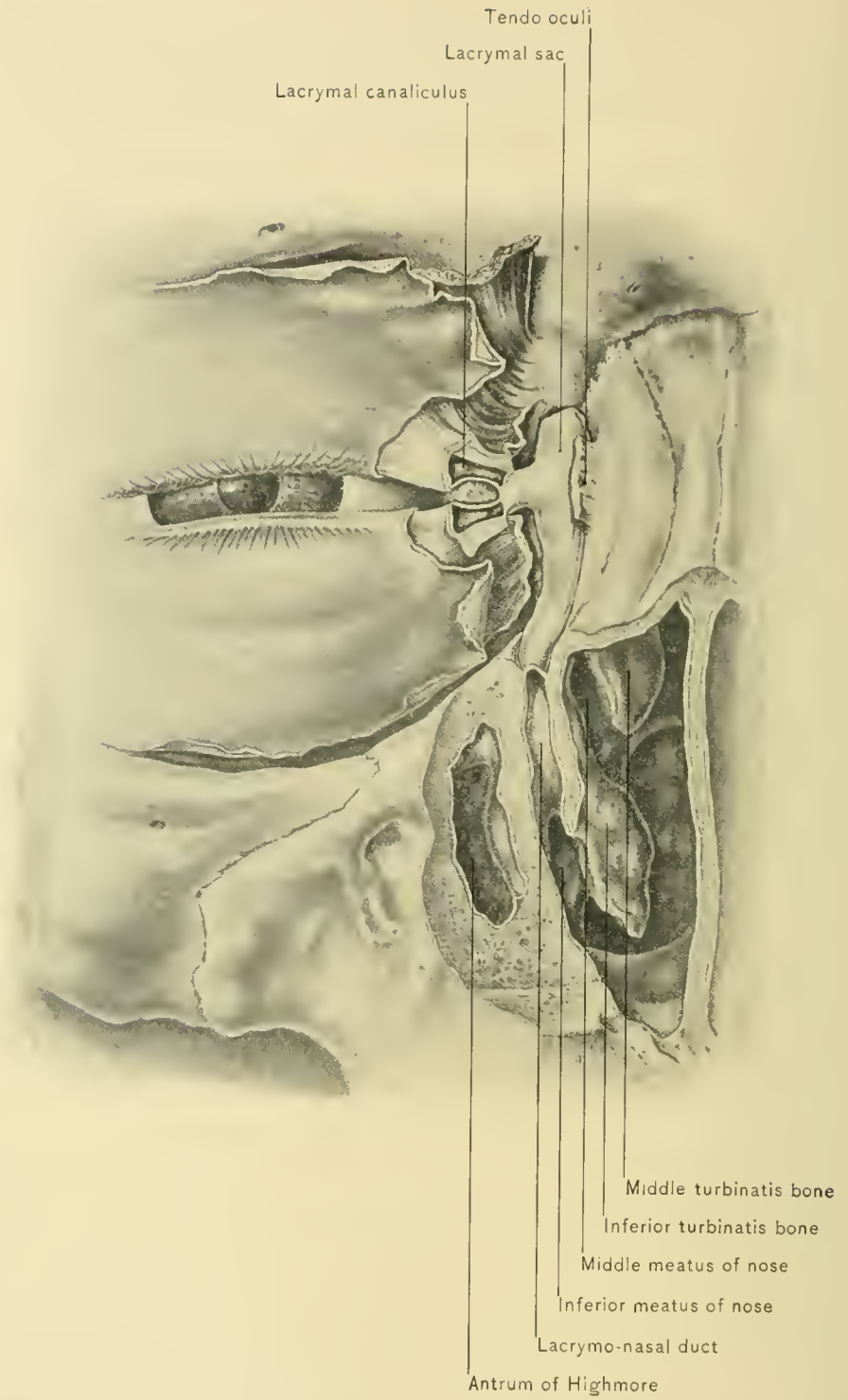
Depression of the cornea is performed by the inferior rectus muscle, the superior oblique muscle preventing adduction of the cornea and rotation of the cornea outward.

Rotation of the cornea inward is performed by the superior rectus muscle and the superior oblique muscle, and rotation of the cornea outward by the inferior rectus muscle and the inferior oblique muscle. Rotation of the cornea is not a common movement, and it occurs when the head is inclined to one side.

Movement of the cornea in an oblique direction is performed chiefly by two of the rectus muscles, as upward and outward by the superior rectus and external rectus muscles.

Excessive action of the various muscles is prevented by the attachments of the anterior lamella of the orbital fascia.

Strabismus, or deviation of the sagittal axis of one eyeball from its normal position, occurs when one or more muscles are excessively active or the opposing



LACRYMAL APPARATUS.

muscles are insufficiently active. This condition is more commonly caused by defective refraction in the affected eye or unequal refraction in the two eyes. The first requisite is to correct the defect in refraction, and as a last resort the tendon or tendons of the hyperactive muscle or muscles may be divided. After division of the tendon, extreme retraction of the muscle is prevented by the anterior lamella of the orbital fascia.

DISSECTION.—The temporo-malar nerve is the last structure to be dissected. The orbital contents must be removed completely, and the nerve will be found in a pad of fat in the retiring angle between the inferior and external orbital walls.

The **Temporo-malar** or **Orbital Nerve** arises from the superior maxillary nerve in the spheno-maxillary fossa, and reaches the orbit by passing through the spheno-maxillary fissure. It then divides into two branches—temporal and malar.

The **temporal branch** forms a loop of communication with the lacrymal nerve, and then runs beneath the orbital periosteum to reach the spheno-malar foramen. Having traversed this foramen and entered the temporal fossa, it pierces the deep layer of the temporal fascia. It runs upward between the two layers of the temporal fascia for a short distance, and pierces the superficial layer of that fascia. It communicates with the temporal branch of the facial nerve, and is distributed to the skin of the anterior temporal region.

The **malar branch** runs forward in the orbital fat, and leaves the orbit by passing through the malar foramen. It communicates with the malar branch of the facial nerve and supplies the skin of the cheek.

The **Lymphatics of the Orbit** pass through the spheno-maxillary fissure to the internal maxillary and deep parotid lymphatic glands.

THE LACRYMAL APPARATUS.

DISSECTION.—Insert slender probes into the puncta lachrymalia and lacrymal canaliculi, and open the latter as far as the lacrymal sac.

The **Lacrymal Canaliculi** are two narrow canals, one in each eyelid, extending from the lacrymal punctum to the lacrymal sac. For a short distance from the lacrymal punctum the course of each canaliculus is vertically away from the margin of the lid, then, turning abruptly, it forms a right angle, passes inward, and pierces the inner division of the tendo oculi to reach the lacrymal sac. Before entering the lacrymal sac the lacrymal canaliculi of the upper and lower lids

frequently join and open into the sac by a common orifice. In passing a probe into the lacrymal canaliculi their angular course should be remembered.

DISSECTION.—Next make a vertical section through the upper and the lower eyelid, to demonstrate their several layers of tissue.

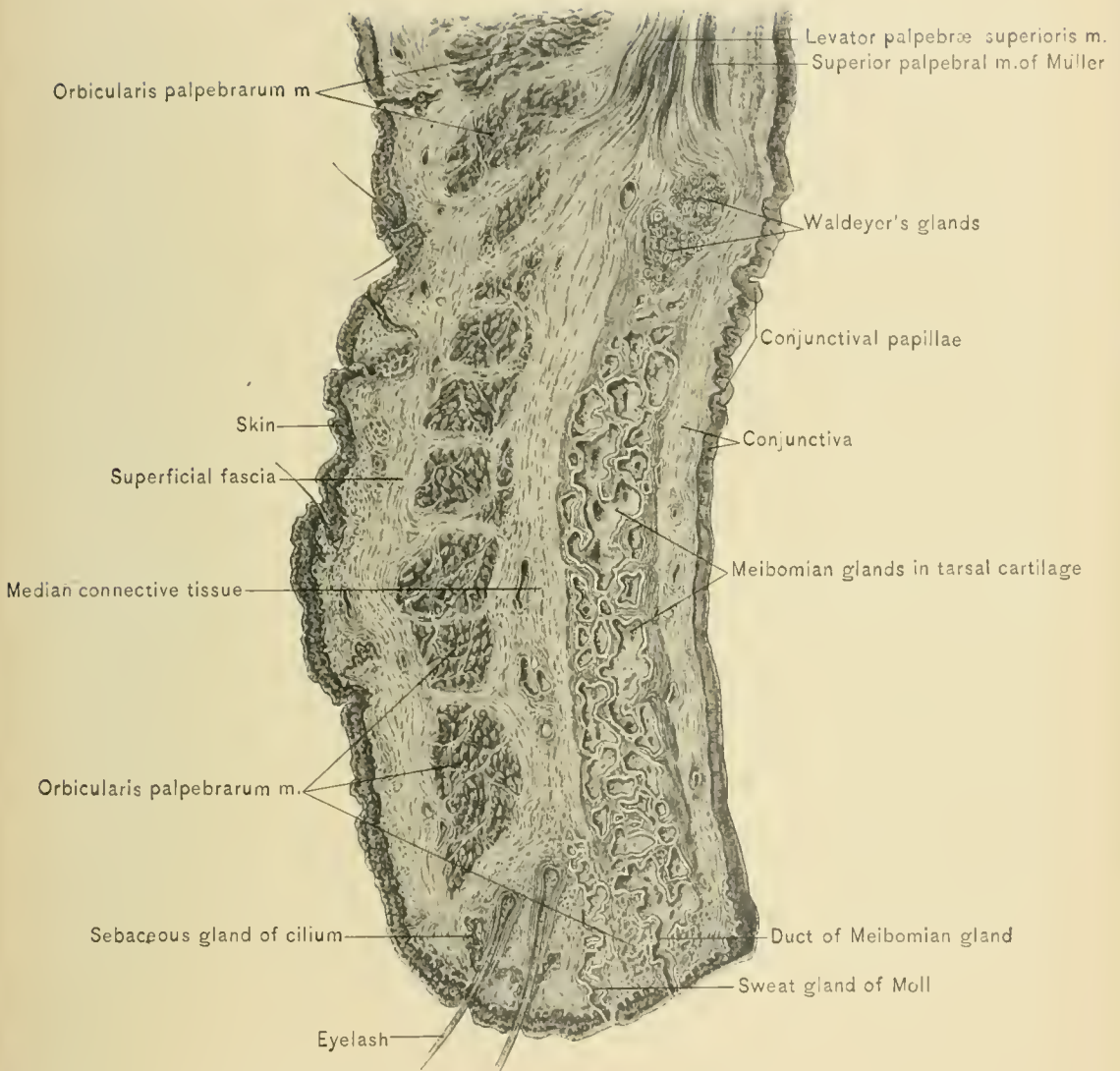
The **Eyelids** are composed of skin, superficial fascia, orbicularis palpebrarum muscle, areolar tissue, palpebral ligaments, orbito-tarsal ligaments, tarsal cartilages, Meibomian glands, conjunctiva, vessels, nerves, and lymphatic vessels. The upper eyelid also contains the aponeurosis of the levator palpebræ superioris muscle. The most superficial layer is the skin; the second layer is the superficial fascia, which contains no fat in this location; the third layer is composed of delicate areolar tissue; in the fourth layer are the tarsal cartilage, the orbito-tarsal ligament, the palpebral ligaments, the Meibomian glands, and in the upper lid the aponeurosis of the levator palpebræ superioris muscle; the fifth layer is composed of conjunctiva and subconjunctival tissue. The eyelids are described in volume I, pages 512–520.

DISSECTION.—Open the lacrymal sac, and, after passing a probe through the lacrymo-nasal duct, saw away the anterior wall of that duct.

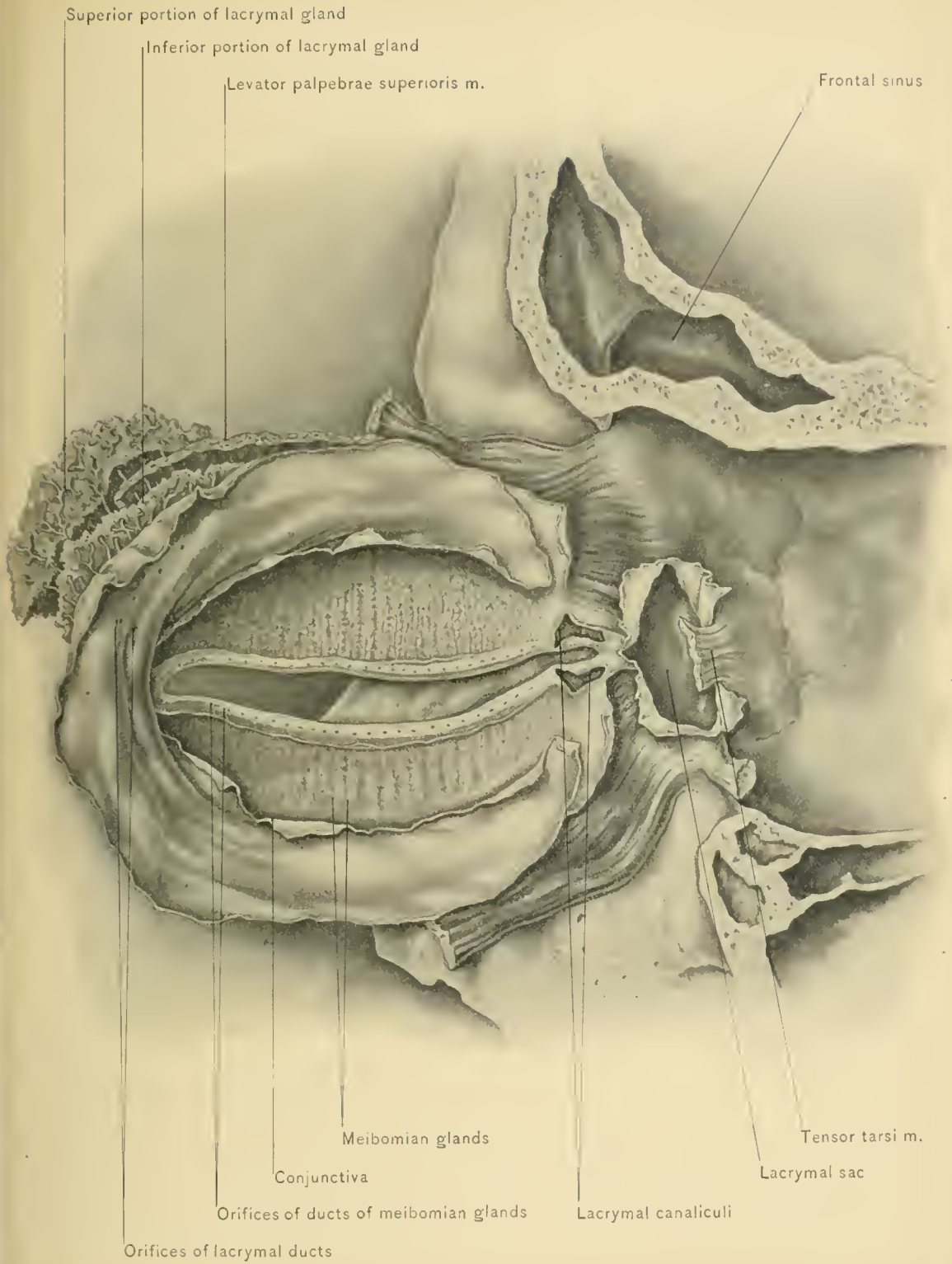
The **Lacrymal Sac** is the upper, dilated end of the lacrymo-nasal duct, and rests in the lacrymal groove, which is a depression in the lower anterior portion of the inner wall of the orbit. The lacrymal sac is invested by a fibrous capsule, which is attached to the margins of the lacrymal groove, and is continuous with the orbital periosteum. It is lined with mucous membrane, which is continuous with that of the lacrymal canaliculi and lacrymo-nasal duct. Loose submucous tissue attaches mucous membrane to the fibrous capsule.

The **Lacrymo-nasal, Nasal, or Lacrymal Duct** extends from the lacrymal sac to the uppermost part of the anterior portion of the inferior meatus of the nose. It is directed downward and slightly backward and outward. Its walls are formed by the superior maxillary, lacrymal, and inferior turbinated bones, and are lined by mucous membrane continuous with that of the nose and lacrymal sac, the sac and the duct forming the **Lacrymal Canal**. The nasal orifice of the duct is guarded by a valvular flap of mucous membrane.

The **Course of the Tears** is from the lacrymal gland at the outer part of the upper fornix of the conjunctiva and the accessory lacrymal glands in the eyelids, inward over the conjunctiva to the lacrymal puncta, and thence successively through the lacrymal canaliculi, lacrymal sac, lacrymal duct, and inferior meatus of the nose. If the lower eyelid is everted or inverted so that the tears do not enter the lacrymal punctum, or there is an obstruction in the lacrymal canaliculi or nasal duct, or the tears are secreted too rapidly for the capacity of the puncta, as in weeping, the tears flow over the cheek.



SAGITTAL SECTION OF UPPER EYELID.



MEIBOMIAN GLANDS AND LACRYMAL APPARATUS.

THE EYEBALL.

The **eyeball** is a globular body, so situated in the orbital fossa as to be protected by the orbital margins from injury by large objects. It is freely movable around its axes, in order that objects may be seen without appreciable muscular effort.

The **mobility of the eyeball** is permitted by the relation existing between the globe and the capsule of Tenon, which has been described with the orbit. The eyeball and capsule of Tenon form a ball-and-socket joint. Backward, lateral, vertical, and oblique movements of the eyeball *en masse* are prevented by the attachments of the orbital fascia to the orbital margins and palpebral fascia, and forward movement of the organ is checked by the rectus muscles; therefore the only movements of the eyeball are those of rotation around its axes. Excessive rotation is prevented by the attachments of the anterior lamella of the orbital fascia and its thickened portions, designated check ligaments.

Exophthalmos, or protrusion of the eyeball from the orbit, may be caused by tumors or foreign bodies in the orbit, myopia, and enlargement of the eyeball by disease. It sometimes exists slightly after tenotomy of one of the rectus muscles, and may be a sign of exophthalmic goiter.

Sinking of the eyeball occurs after partial absorption of the orbital fat in wasting diseases, and is associated with general emaciation.

Being a globular body, the eyeball has an **anterior pole**, located at the center of the cornea; and a **posterior pole**, at the center of the posterior segment of the eye, which is the portion covered by the sclera. It also has an **equator**, midway between the two poles; an **axis**, or **sagittal diameter**, connecting the two poles; a **vertical** and a **transverse diameter** at the equator. It is not quite spheric, because the cornea is a segment of a smaller sphere, and projects forward like a watch-glass, increasing the sagittal diameter or axis; the transverse is slightly greater than the vertical diameter. The axis, or sagittal diameter, measures about 24.5 millimeters; the transverse equatorial diameter, about 23.9 millimeters; and the vertical equatorial diameter, about 23.5 millimeters. From these measurements it will be seen that the eyeball is slightly elongated from behind forward, and compressed from above downward. The axes of the two eyeballs are parallel with each other, although the axes of the two orbits are divergent anteriorly.

DISSECTION.—By the time the orbit has been dissected, the human eyeball will be so far decomposed that it can not be easily nor profitably dissected. Fortunately, an adequate substitute is found in the eye of a pig, a sheep, or a bullock. Of these, the pig's eye corresponds more nearly in size to the human

eye; but the bullock's eye, on account of its comparative grossness, is more easily dissected. At least a half dozen bullocks' eyes should be procured before the dissection is commenced. The globe must be thoroughly cleaned down to the sclerotic. Perhaps the best way to accomplish this is as follows: With scissors and forceps make a circular incision through the conjunctiva close to and parallel with the margin of the cornea. The conjunctiva, capsule of Tenon, fat, fascia, and muscles are then gradually worked free from the sclera from before backward, as far as the point of entrance of the optic nerve. When about half way back, the venæ vorticosæ will be seen emerging; and when near the optic nerve, the circle around it, formed by the posterior ciliary arteries and ciliary nerves, will be noticed.

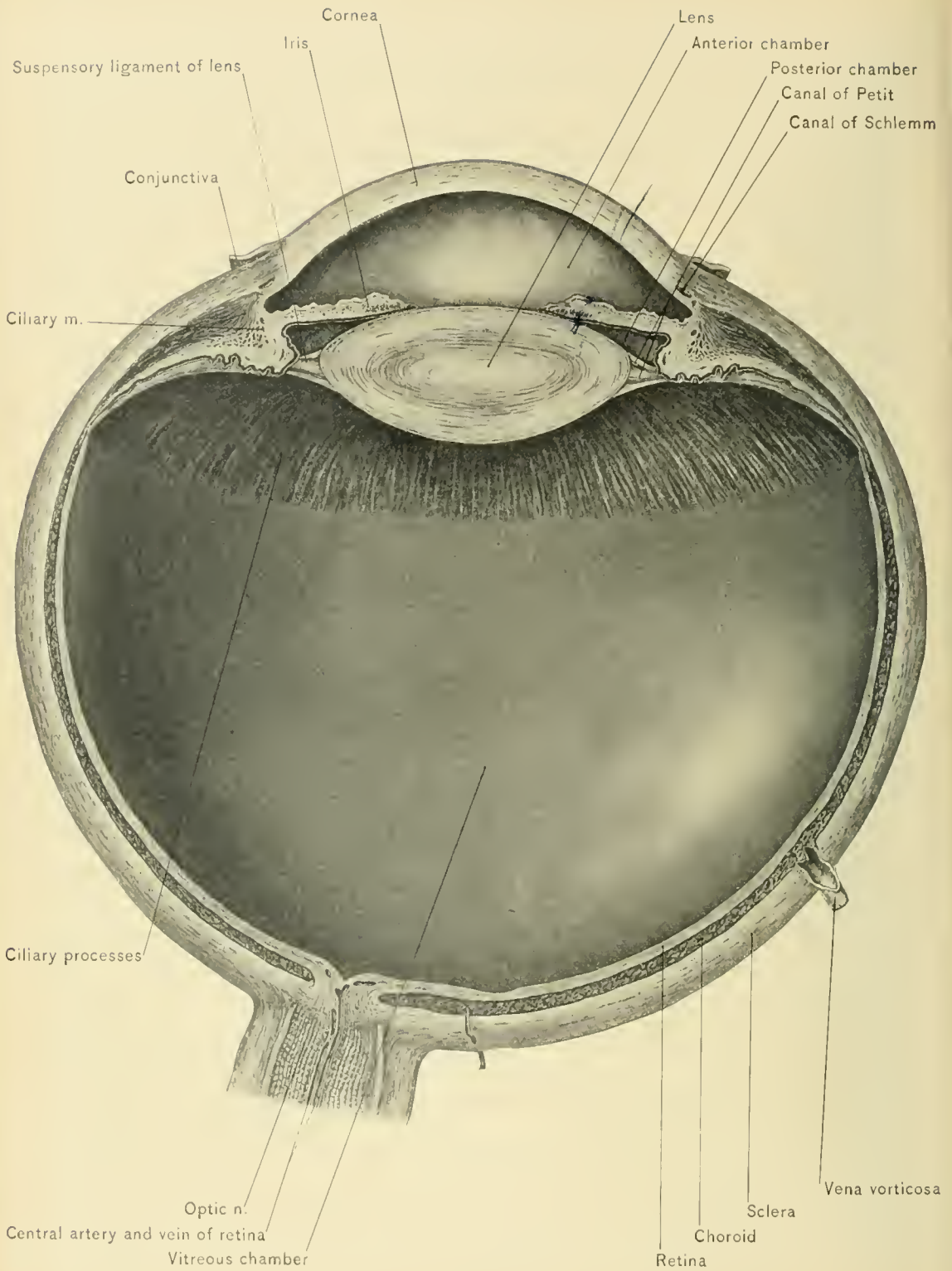
The **Conjunctiva** is a mucous membrane covering the anterior surface of the eyeball and the posterior surface of the eyelids. It consists of a parietal layer, the palpebral portion, which lines the eyelids, and of a visceral layer, the ocular portion, which covers the anterior one-third of the eyeball. The visceral layer is subdivided into a sclerotic and a corneal portion.

The **palpebral portion of the conjunctiva** has been described with the eyelids under the Dissection of the Face.

The **sclerotic portion of the conjunctiva** is loosely adherent, except at the margin of the cornea. It contains small blood-vessels, which are derived from the palpebral vessels, branches of the lacrymal, infra-orbital, supra-orbital, and frontal vessels, which will not be perceptible under perfectly normal conditions. Congested conjunctival vessels are distinguished from the anterior ciliary vessels by the fact that the former move with the conjunctiva, while the latter are fixed in the sclerotic and remain stationary. The lax submucous tissue which connects the conjunctiva with the sclera permits the surgeon to slide flaps of conjunctiva. Its laxity accounts for the occurrence of subconjunctival hemorrhages after sudden, severe muscular effort, as in paroxysms of whooping cough. The hemorrhages, if associated with traumatism about the head, should be viewed with suspicion, as they may result from fracture of the anterior fossa of the skull with leakage of blood into the orbit. The blood does not become dark in color, but remains red, because oxygen passes to it through the conjunctiva.

The **corneal portion of the conjunctiva** consists of layers of epithelial cells, and forms the anterior layer of the cornea. It is closely adherent, perfectly transparent, and gives the cornea its mirror-like characteristics. It contains no blood-vessels.

Extensive destruction of the conjunctiva may be produced by caustics accidentally introduced between the eyelids and the eyeball. This more frequently occurs under the lower eyelid, on account of its position. The lid may adhere to



MERIDIONAL SECTION OF EYE.

the globe, causing **symblepharon**; or cicatricial contraction may produce inversion of the eyelid and eyelashes (**entropion**). Adherence of the two raw surfaces may be prevented by sliding a bridge of conjunctiva from above the cornea, and placing it upon the raw surface below. Entropion may also be caused by cicatricial contraction in chronic conjunctivitis. In purulent conjunctivitis (**purulent ophthalmia**), which is usually due to infection of the conjunctiva by gonorrhœal pus, the great danger lies in involvement of cornea, which may produce permanent blindness.

Coats and Refracting Media of the Eye.—The eyeball contains three superimposed coats, inclosing three refracting media, or so-called humors. The coats, named from without inward, are a fibrous, a vascular, and a nervous coat.

The refracting media, enumerated from before backward, are the aqueous humor, the crystalline lens, and the vitreous humor.

The **Fibrous Coat** is composed of two portions—the sclera and the cornea.

DISSECTION.—To observe all parts of the sclerotic coat clearly, it should be detached from the underlying tissues and removed. To do this it should be incised at the equator—*i. e.*, midway between the center of the cornea (the anterior pole) and the corresponding posterior point (the posterior pole). A sharp knife should be used to make a short cut just deep enough to expose the black, underlying choroid. A pair of scissors with delicate blades and sharp points should then be used to complete the equatorial incision. With the handle of the scalpel the halves of the sclerotic coat should be separated from the subjacent tissues, as one removes the skin of an orange. At only two points will any difficulty be met. One is at the entrance of the optic nerve, where it is necessary to cut off the optic nerve close to the choroid; the other point is anteriorly, where the ciliary body is attached to the sclera. By the use of slight force this attachment can be torn with the forceps, and the anterior moiety, composed of the sclera and the cornea, removed entire. This results in escape of the aqueous humor. The remainder of the globe should be laid aside in diluted alcohol until required for further study.

The **sclera**, or **sclerotic coat**, incloses the posterior five-sixths of the eyeball, the remaining anterior one-sixth of its wall being completed by the cornea. It is incomplete posteriorly at the entrance of the optic nerve, the opening (*foramen sclera*) being partially filled by a layer of sclerotic tissue, called the *lamina cribrosa*. It is white, opaque, and tough, and maintains the normal conformation of the globe. It consists of interlacing bundles of white, fibrous connective tissue. It is thickest posteriorly, and thinnest just behind the insertions of the rectus muscles, about one-fourth to one-third of an inch or six to eight millimeters from the cornea, where it is sometimes ruptured in cases of injury to the eyeball.

Between the cornea and the insertions of the tendons of the rectus muscles it again becomes thicker, on account of its reinforcement by fibers from those tendons. In disease of the eye, such as glaucoma, in which there is increased intra-ocular tension, compression of the ciliary nerves against the unyielding sclerotic coat causes intense pain.

At its anterior margin the sclerotic coat is directly continuous with the cornea, and the slight groove at this point is called the *scleral sulcus*. About one-fourth of an inch, or six millimeters, behind the sclero-corneal junction the sclerotic coat receives the insertions of the rectus muscles. At this point also it receives and transmits the anterior ciliary vessels, which form a ring around the cornea; congestion of these vessels is evident in iritis. In the sclera, just behind the sclero-corneal junction, is a circular blood channel surrounding the margin of the cornea; it is called the *canal of Schlemm*. This canal transmits venous blood, and is in close relation with certain lymph spaces in the pectinate ligament of the iris, called the *spaces of Fontana*. In conjunction with the spaces of Fontana the canal of Schlemm, by absorbing the excess of aqueous humor, is supposed to maintain the normal intra-ocular tension, exaggeration of which results in the grave disease, glaucoma.

The *lamina cribrosa* is in the posterior portion of the sclera, and is the place of entrance of the optic nerve, whose dural and pial investments blend with the sclera. Minute openings which form a circle around the lamina cribrosa transmit the posterior ciliary vessels and nerves. The point of entrance of the optic nerve is not at the posterior pole or in the visual axis of the eye, but lies about one-tenth of an inch, or 2.5 mm., to the nasal side of, and slightly below, it. As this nerve passes through the sclera it is constricted, and instead of passing as a compact bundle, it is broken up into fasciuli which separately pierce the fibrous lamina mentioned—the lamina cribrosa. The lamina has an opening in the center larger than the perforations produced by the individual nerve bundles; this is called the *porus opticus*, and transmits the arteria centralis retinae.

Except at the entrance of the optic nerve and the sclero-corneal junction, the sclerotic is but feebly attached to the subjacent vascular coat. Its innermost layer—which, on account of its deep color, is called the *lamina fusca*—is in relation with the vascular coat, to which it is attached by a layer of loose connective tissue called the *lamina suprachoroidea*.

The **cornea** is the circular anterior window of the eyeball, and comprises about one-sixth of the circumference of the globe. It is perfectly transparent, and is somewhat thinner at its center than at its periphery. Its transparency is lost in interstitial keratitis (inflammation of the corneal tissue), which is frequently caused by syphilis. It is more highly convex than the remainder of the eyeball,

and consequently forms part of a smaller sphere than does the sclera, and hence projects further than does the latter. The student can readily prove this fact by closing his own eye and moving the loose skin of the upper lid over the globe with his finger. The cornea is part of the fibrous coat of the eye, and at its periphery is continuous with the sclera. Owing to the fact that the transition of the sclera into the cornea occurs first on the inner aspect of the former, the sclera seems to overlap the cornea; thus the margin of the cornea becomes beveled on its external aspect and the sclera on its internal aspect. This apparent overlapping being greater above and below than at the sides, the transverse diameter of the cornea slightly exceeds the vertical. It is in front of the aqueous humor, which is interposed between it and the iris and lens.

The cornea being convex, assists in bringing rays of light to a focus upon the retina. If the convexity of the cornea is excessive, the rays are brought to a focus before reaching the retina, and the person suffers from **near-sightedness** or **myopia**. If the cornea is insufficiently convex, the rays reach the retina before being collected to a focus, and the person suffers from **far-sightedness** or **hypermetropia**. When the curvature of the cornea is irregular, the rays of light are not regularly brought to a focus. The error of refraction resulting is known as **astigmatism**, which may also be produced by irregular refraction in the lens.

The cornea consists of five layers: the anterior epithelium, the anterior limiting membrane (membrane of Bowman), the substance proper, the posterior limiting membrane (the membrane of Descemet), and the posterior endothelium.

The *anterior epithelium* and *posterior endothelium* of the cornea serve to prevent absorption of liquid from the tears and from the anterior chamber of the eye. The opacity of the corneal tissue after death is due to imbibition of fluid into the lymph channels of the cornea. If the anterior epithelial layer, composed of the conjunctiva, is broken, and lead lotions are used, lead salts may be deposited and impair the transparency of the cornea.

The *substance proper* (substantia propria) is composed of numerous laminae of modified connective tissue, between which are freely anastomosing lymph channels, through which it is nourished. Like the other layers of the cornea, it contains no blood-vessels. These vessels end in loops at its periphery. In **interstitial keratitis** these laminae are affected, and effusion into the lymph channels causes haziness and loss of transparency of the cornea.

Ulcers and wounds of the cornea, as a rule, heal readily, notwithstanding the absence of blood-vessels. Ulcers may, however, perforate the cornea. Perforating ulcers or wounds of the cornea allow the aqueous humor to escape. With the stream of the escaping aqueous humor the pupillary margin of the iris may be prolapsed through the opening in the cornea. Scars resulting from ulcers or

wounds of the cornea may produce an opacity resembling a small puff of smoke (*nebula*), or a pearly white opacity, which is designated *leukoma*. These opacities, if situated at the center of the cornea, interfere with the passage of light to the most sensitive portion of the retina, making it necessary to form an artificial pupil.

Abscesses of the cornea gravitate between the laminae to the lower part of the cornea, producing a crescentic collection called *onyx*—because of its resemblance to the crescents at the roots of the finger-nails. These abscesses should be evacuated early to avoid perforation, escape of the aqueous humor, and protrusion of the iris.

In elderly persons there is frequently seen an opacity of the corneal tissue near the margin of the cornea; this opacity usually begins at the upper part of the cornea, and then at the lower; subsequently, the extremities of the two hazy crescents meet, and a complete **arcus senilis** results. This condition is due to fatty or hyaline degeneration of the corneal tissue, probably the result of defective vascular supply.

In **pannus** the cornea appears to contain blood-vessels. Through irritation from granular lids or inverted eyelashes blood-vessels grow into the corneal conjunctiva, and later may enter the corneal tissue.

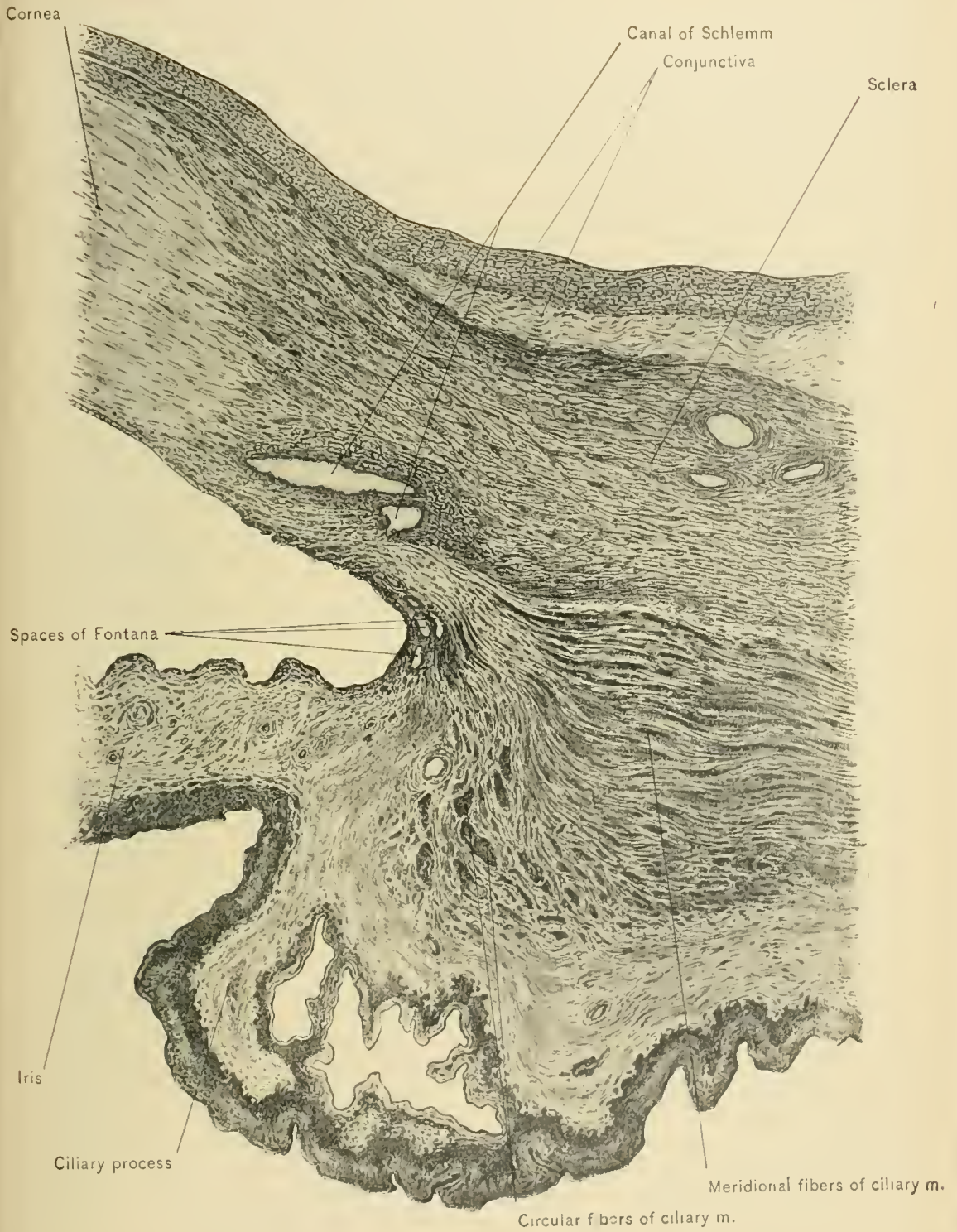
Staphyloma of the cornea is a bulging forward of a corneal scar and adherent iris. It is produced by increased intra-ocular tension pushing forward the iris and even the lens against a weakened cornea, and causing repulsive disfigurement.

A **conic cornea** is thin, protrudes further forward than normally, and retains its transparency. As a result, vision is imperfect.

BLOOD SUPPLY.—The blood supply of the cornea is indirectly derived from the anterior ciliary and long posterior ciliary arteries. No blood-vessels are found in the cornea, nutrition being supplied by imbibition of lymph into the lymph channels of the cornea. The lack of a direct blood supply accounts for the tendency of the cornea to become inflamed in poorly nourished persons.

NERVE SUPPLY.—The cornea receives a rich nerve supply from the ciliary nerves. Its nerves are merely axis cylinders, and, therefore, do not affect its transparency. From pressure on the ciliary nerves in increased intraocular tension, as in glaucoma, the cornea is anesthetized.

The Pectinate Ligament of the Iris.—At the corneal margin the fourth layer of the cornea, the posterior limiting membrane, breaks up into fibrillae, some of which run into the base of the iris. These comprise the pectinate ligament of the iris, and bridge over the angle between the cornea and the base of the iris. This ligament contains lymph spaces, called the *spaces of Fontana*, which communicate,



MERIDIONAL SECTION OF CILIARY REGION OF EYEBALL.

on the one hand, with the anterior chamber of the eye, and, on the other, with the canal of Schlemm.

The **Vascular Coat**, or the uveal tract, is the middle coat of the eye. It has been exposed throughout by the previous dissection. It consists of three portions: the most anterior portion is the iris, the perforated circular curtain which hangs in front of the lens; the next portion is the ciliary body, which lies behind the iris; and the third, posterior and largest, is the choroid.

The **iris**, as previously stated, is the anterior portion of the middle tunic, and is a perforated circular curtain interposed between the lens and the cornea. It is attached only at its margin, where it is joined to the cornea anteriorly by means of the pectinate ligament of the iris, and by the ciliary body posteriorly. These attachments are not very strong; consequently, in injuries of the eye the iris may be torn away from the cornea and ciliary body without damage to either of these two structures. It is contractile and expansile, and floats in the clear aqueous humor, separating the anterior chamber of the eyeball from the posterior chamber, which communicate with each other through the central opening of the iris, called the **pupil**. In the fetus the pupil is closed by the pupillary membrane, which disappears before birth. By change in size of the pupil the iris regulates the amount of light admitted to the interior of the eye. Both contraction and dilatation of the pupil are active processes, the presence of circular and radiating muscle fibers having been demonstrated. Near the pupil the posterior surface of the iris is in contact with the lens, hence in iritis the iris may adhere to the lens, producing **posterior synechia**; when the iris adheres to the cornea, **anterior synechia** results.

The iris receives much support from contact with the lens; consequently, when the lens is dislocated posteriorly or after cataract operations, the iris may be tremulous through lack of support.

The **Argyll Robertson pupil** is one which does not respond to stimulation by light, but retains its power of accommodation for distance. It is a diagnostic sign in locomotor ataxia, and has been observed in cerebral syphilis, general paralysis of the insane, and poisoning by carbon bisulphid.

The **color** of the iris varies in different individuals, and is largely dependent on the amount and position of its pigment. In blue eyes the stroma of the iris is entirely free from pigment, the latter being confined to the posterior pigment layer, from which position it is seen through the superimposed strata of the iris. With the darker eyes the stroma cells of the iris also acquire pigment; in light gray eyes this is small in amount, in brown eyes greater, while in the darkest eyes the colored particles are very numerous, and sometimes appear as almost continuous pigmented areas; in albino eyes, on the other hand, even the retinal portion

of the iris is devoid of pigment (Piersol). The color of the iris may be greatly altered during inflammation of that structure, through effusion into the tissues of the iris. The swelling thus produced causes sluggish movement of the iris, and encroachment upon the pupil.

BLOOD SUPPLY.—This is derived from the ciliary vessels; consequently, iritis is usually associated with choroiditis.

NERVE SUPPLY.—The nerve supply of the iris is derived from the ciliary nerves. The radiating muscle fibers are supplied through the lenticular ganglion by the sympathetic nerve, and the circular fibers through the lenticular ganglion by the third cranial nerve.

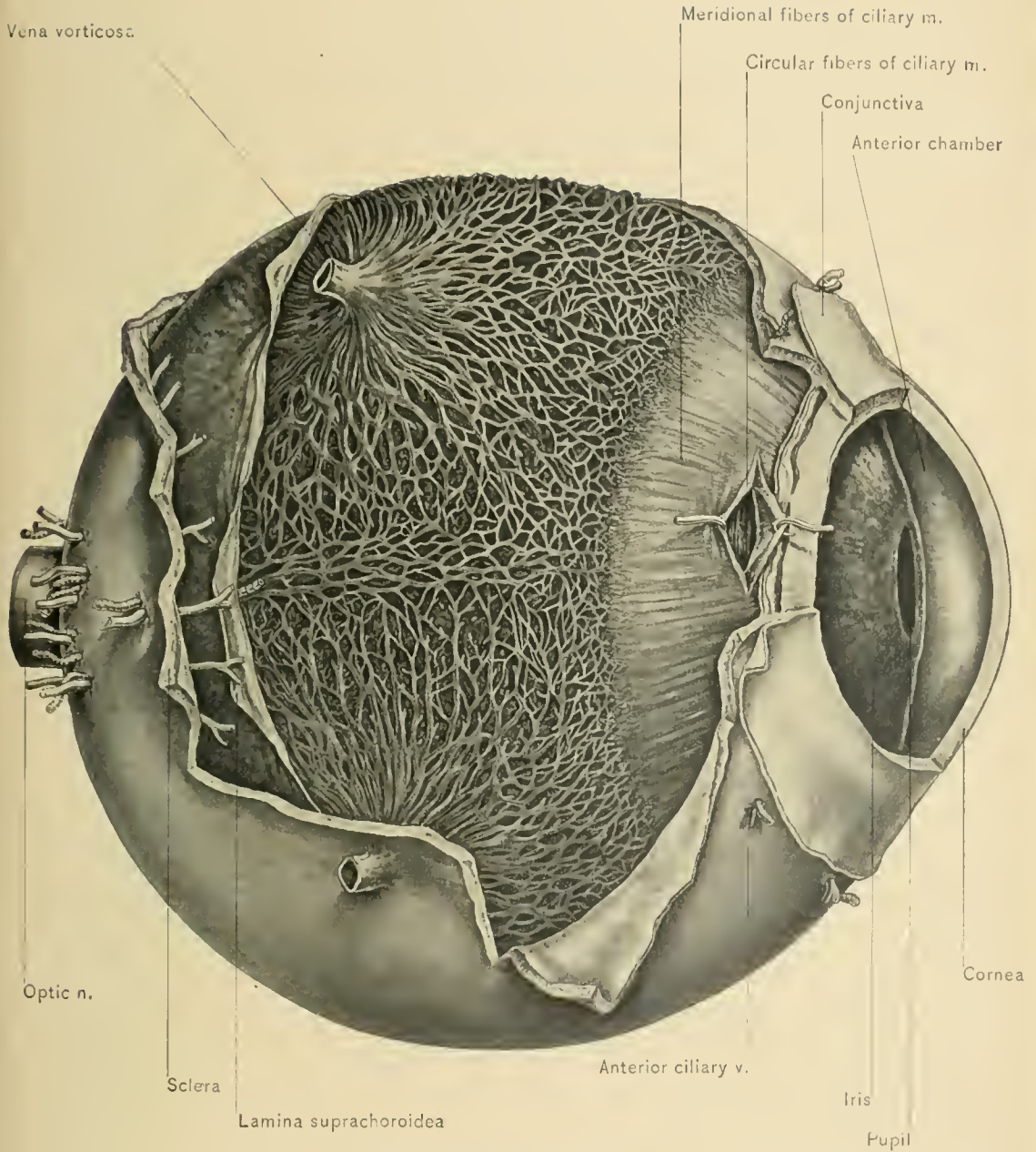
The path for the iris reflex (that is, the contraction and dilatation of the pupil induced by variations in the amount of light falling into the eye) is along the optic nerve and tract to the geniculate body, or perhaps the anterior pair of corpora quadrigemina, thence to the nucleus of the motor oculi, along the latter nerve to the ciliary ganglion, and then through the ciliary nerves to the iris. Interference with this path by lesions in the optic nerves or tracts or in the central nervous system leads to disturbances which the clinician utilizes for diagnostic purposes.

Coloboma, or a cleft of the iris, is the most common congenital defect of the iris; it is usually situated below the pupil, and is due to persistence of the choroid cleft of the embryo.

Aniridia, or absence of the iris, is a rare defect; it is usually bilateral.

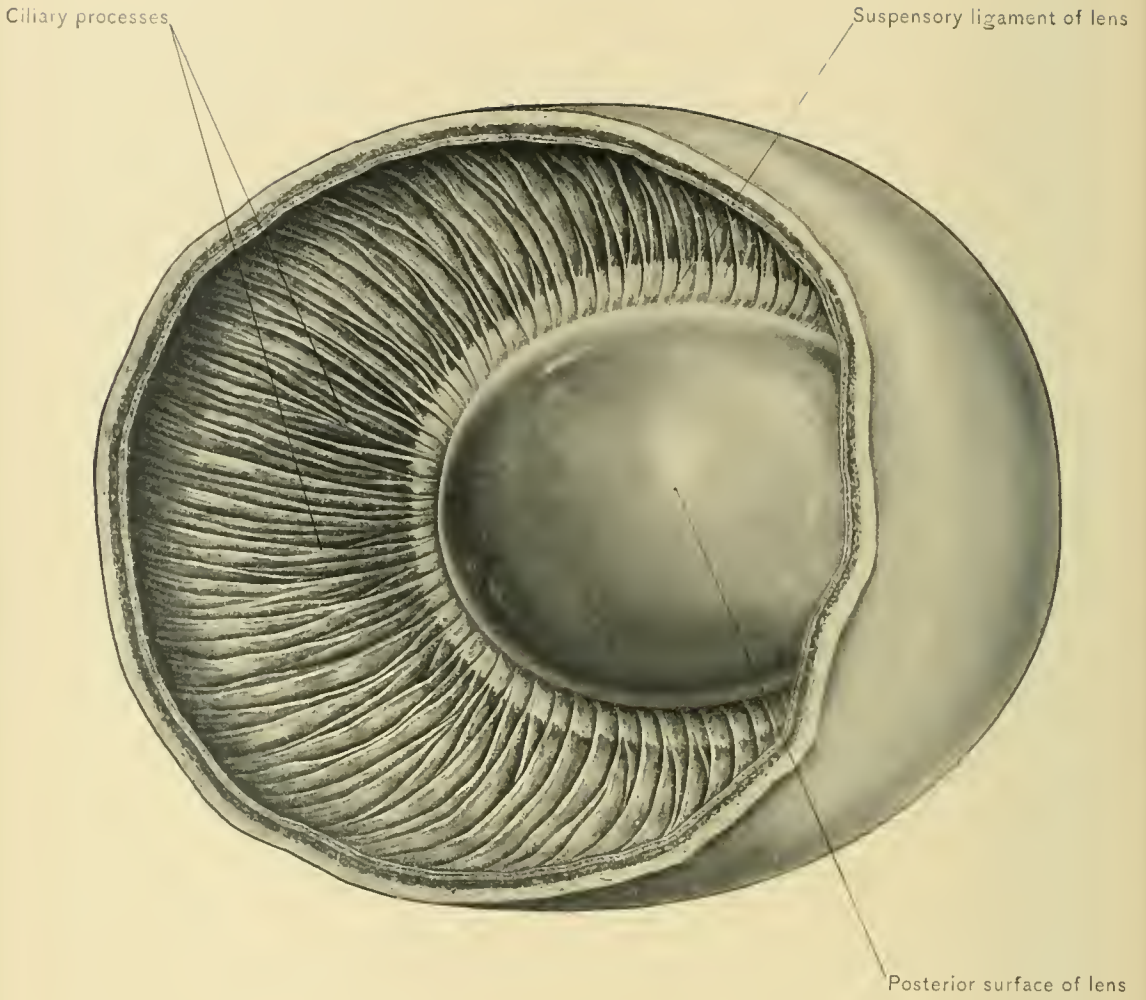
The **ciliary body**, or **cyclon**, the intermediate portion of the middle tunic or uveal tract, is composed of two portions—the ciliary muscle and the choroid portion or ciliary processes. It extends from the posterior, or ciliary, margin of the iris to a point opposite the ora serrata of the retina. In meridional sections of the eyeball it is triangular. The outer side of the triangle is formed by the ciliary muscle, and is in contact with the sclera; the postero-internal side is directed toward the vitreous chamber of the eyeball, and contains the ciliary processes; the anterior side is directed toward the aqueous chamber, and gives attachment to the margin of the iris at about its middle. The ciliary body is well supplied with branches from the ciliary vessels and nerves. Inflammation spreads rapidly from it to the iris, choroid, retina, and cornea. It is called the dangerous area of the eye, because traumatic inflammation of the ciliary body in one eye may be followed by sympathetic ophthalmia beginning in the ciliary body of the other eye. This is supposed by some to be due to the rich nerve supply of that region.

The **ciliary muscle** forms a conspicuous white band between the choroid and the iris, and behind the sclero-corneal junction. It bears on its inner surface the ciliary processes. In cross section of the ciliary body or longitudinal section of the eyeball it appears as a triangular band of muscle fibers. The shorter anterior



EXTERNAL AND MIDDLE COATS OF THE EYEBALL.





CILIARY REGION (FROM LION'S EYE IN MUSEUM OF UNIVERSITY OF PENNSYLVANIA).

side of the triangle extends from the sclero-corneal junction toward the ciliary processes; and at the angle of junction of the other two sides it joins the anterior margin of the choroid. It consists of fasciculi of muscular tissue, the interstices of which are filled with similar strands of connective tissue. The muscular tissue, like all similar structure in the eyeball, is composed of involuntary muscle fibers arranged in two sets—*meridional* and *circular*. The meridional or longitudinal muscle fibers arise from the sclera and the sclero-corneal junction, pass backward, and are inserted into the choroid opposite the ciliary processes. The circular muscle fibers, or ring muscle of Müller, are placed internal to the meridional fibers in the ciliary body, and encircle the attached margin of the iris.

BLOOD SUPPLY.—The ciliary muscle and ciliary body are supplied with blood from the long posterior ciliary and anterior ciliary arteries.

NERVE SUPPLY.—The ciliary body and ciliary muscle depend upon the long and short ciliary nerves for their nerve supply, the ciliary muscle being supplied by fibers of these nerves derived from the third cranial nerve.

ACTION.—The ciliary muscle possesses the function of accommodation, and permits variation in the degree of convexity of the lens to enable the rays of light to reach a focus on the retina. The ciliary muscle pulls upon the ciliary processes and relaxes the suspensory ligament of the lens; lessened tension upon this ligament relaxes the capsule of the lens, and allows the anterior surface of the lens to bulge forward. In the hyperopic or long-sighted eye, in which the antero-posterior axis of the eyeball is too long, the ciliary muscle is overworked in endeavoring to bring the rays of light from near objects to a focus upon the retina; consequently, in hyperopia the ciliary muscle, and especially the ring muscle of Müller, is hypertrophied. After a severe illness, or frequent and long-continued periods of reading, this muscle is unable to perform the required amount of work, and the hypermetropic state ensues, which should be relieved by a convex lens. As the third cranial nerve supplies the internal rectus muscle as well as the ciliary muscle, and does not supply the external rectus muscle, convergent squint is frequently associated with hypermetropia. A properly selected convex lens removes the cause of the spasm of the internal rectus muscle, and the strabismus disappears.

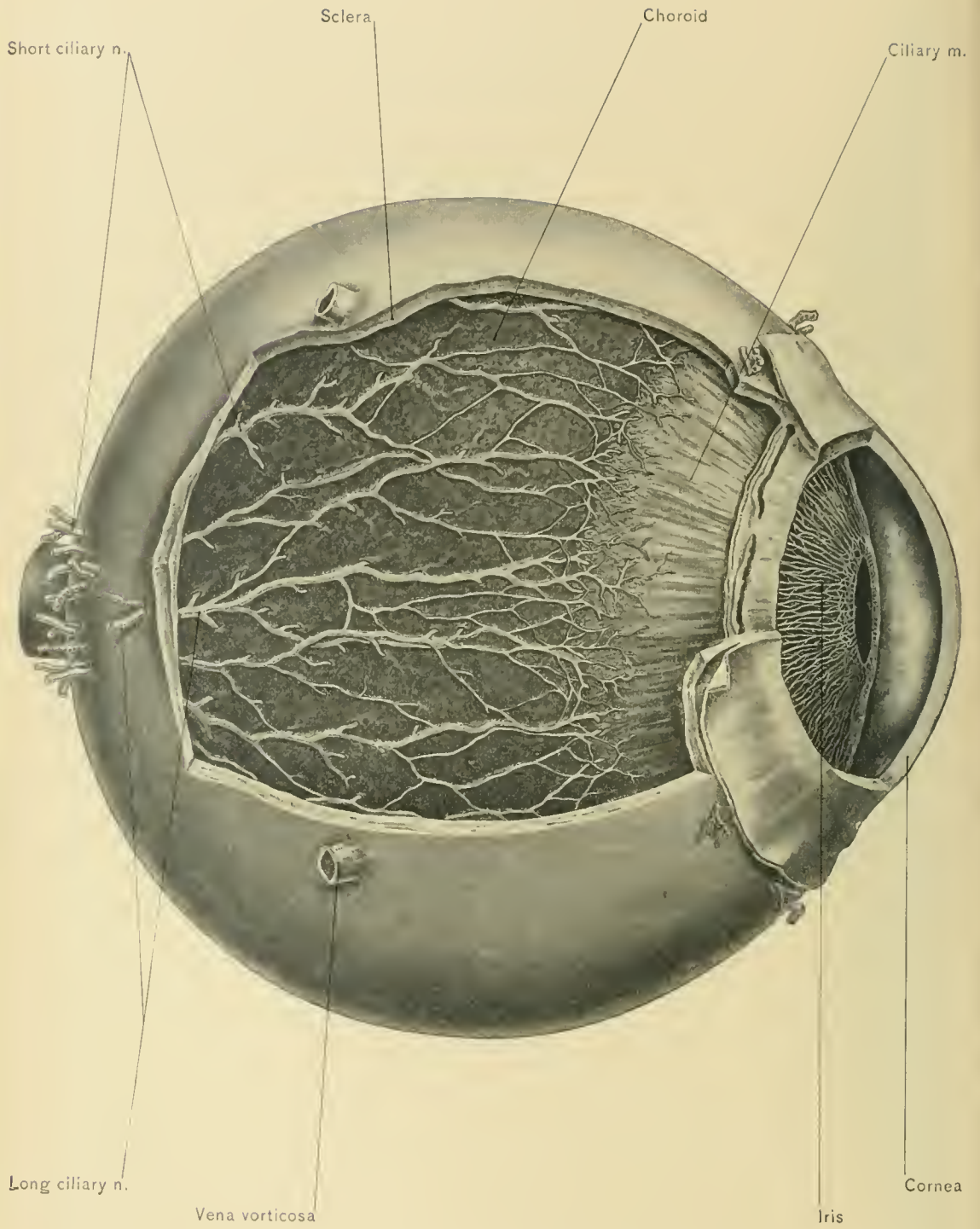
DISSECTION.—Secure a fresh eye, and with a sharp, thin-bladed knife or a pair of scissors cut the globe in half slightly anterior to the equator. Scoop out the jelly-like vitreous, leaving intact the lens and its attachments. Place the bowl-like preparation, thus produced, in a shallow tray containing dilute alcohol, and wash out the pigment with a small camel's-hair pencil. A clear posterior view of the ciliary processes will then be secured. To see them from in front another dissection should be made. The cornea may be removed by making a circular incision just anterior to the sclero-corneal junction. Four meridional incisions

should be made through the sclera and carried backward to about one-quarter of an inch from the posterior pole of the eye. The flaps thus formed should be pinned back, and the whole preparation placed in dilute alcohol held in a wax- or cork-lined tray. With delicate forceps and scissors the iris is then removed, when an anterior view of the ciliary processes may be had.

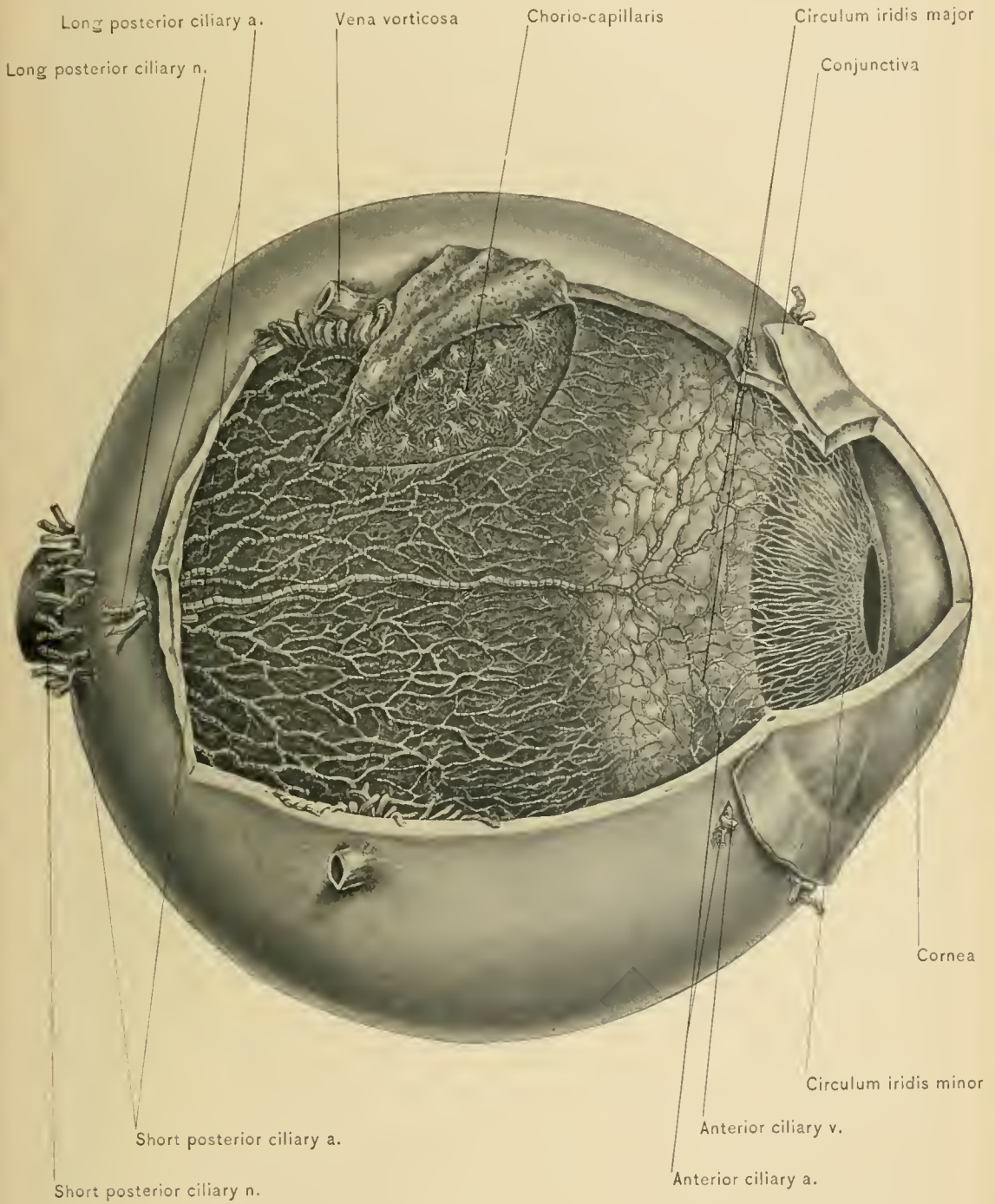
The **ciliary processes** are some seventy or eighty irregular projections from the internal surface of the ciliary body. They are longitudinal folds of the forward continuation of the choroid. Their broader extremities are directed forward and form a circle,—*corona ciliaris*,—which gives attachment to the suspensory ligament of the lens. Toward the posterior part of the ciliary body they become less prominent and subdivide, the inner surface of the ciliary body here being almost smooth and forming the *orbiculus ciliaris*. The ciliary processes are the most vascular portion of the eyeball; like the choroid, they are composed of a connective-tissue stroma, pigment, and numerous blood-vessels. By osmosis from the blood-vessels of the eyeball the aqueous humor is supposed to be replenished. As the iris and the anterior portion of the ciliary body are continuous and their blood-vessels are in free communication, iritis seldom exists without cyclitis; hence the resultant disease is called irido-cyclitis.

The **choroid proper** extends from the posterior termination of the ciliary body to the optic nerve, by which it is pierced. It is found in the posterior portion of the globe, like the sclera, and consists mainly of blood-vessels, areolar tissue, and pigment. Externally, it is in relation with the sclerotic coat, to which it is connected by its outermost layer—the lamina suprachoroidea; internally, it is in contact with the pigment layer of the retina.

It is composed of four layers—viz., the lamina suprachoroidea, the layer containing large vessels, the chorio-capillaris, and the lamina vitrea. Its outer layer, the *lamina suprachoroidea*, is in immediate contact with the sclera, and is composed of loose areolar, nonvascular tissue containing pigment. This layer is so loosely connected with the lamina fusca of the sclera that extensive hemorrhages may occur between the sclera and choroid after traumatism of the eye. The third and fourth layers are vascular in character. The third is the layer of choroid stroma, and contains large blood-vessels. The most conspicuous of these vessels are the four *venæ vorticosæ*, each of which is formed by numbers of veins converging at one point and forming a whorl. They are located at equidistant points along the equator of the eyeball, and to them the small veins converge, returning the blood from the whole uveal tract. The *chorio-capillaris* is the inner vascular layer, and is composed of capillary blood-vessels. The *lamina vitrea*, vitreous or glassy lamina, is the fourth or internal layer. It supports the retinal pigment, which usually adheres to it when the retina is removed.



GILIARY NERVES.



GILIARY ARTERIES.



The choroid contains so much pigment that it is one of the few structures affected by primary **melanotic sarcoma**.

The **ciliary nerves** have two sources of origin—the long ciliary nerves arise from the nasal branch of the ophthalmic nerve, and the short ciliary nerves spring from the lenticular ganglion. They pierce the sclera around the optic nerve, and pass forward between the sclera and the choroid; at the posterior part of the globe they groove the inner surface of the sclera and are intimately attached to it. They pass forward to the ciliary body, where they break up to form a plexus, from which fibers are distributed to the ciliary muscle, the iris, and the cornea. Compression of these nerves against the resisting sclera in increased intra-ocular tension, as in glaucoma, causes intense pain in the eyeball and anesthesia of the cornea.

The **ciliary arteries** consist of the short posterior, long posterior, and anterior. The *short posterior ciliary arteries* are from twelve to twenty in number; they pierce the sclera around the optic nerve, and are distributed to the choroid. The *long posterior ciliary arteries* pierce the sclera just external to the circle formed by the perforations for the short ciliary arteries, and run forward in the choroid. In the ciliary body around the attached margin of the iris they anastomose with the anterior ciliary arteries. These anastomoses form the *circulum iridis major*; branches from this circle enter the iris, and at the outer margin of the sphincter muscle of the iris anastomose and form the *circulum iridis minor*.

The *anterior ciliary arteries* are eight in number, two arising from each of the arteries which supply the rectus muscles. They pierce the sclera near the sclero-corneal junction, and enter into the *circulum iridis major*. The ciliary arteries and nerves are also described with the orbit.

The **veins** which have their origin in the middle coat of the eyeball are the *venæ vorticosæ* and the anterior ciliary veins. The *venæ vorticosæ* have been previously described with the choroid and the orbit. The *anterior ciliary veins* arise from small veins in the ciliary muscle, and pierce the sclera near the margin of the cornea, receiving veins connected with the canal of Schlemm. They also receive conjunctival and episcleral veins, and empty into the veins which accompany the arteries to the rectus muscle.

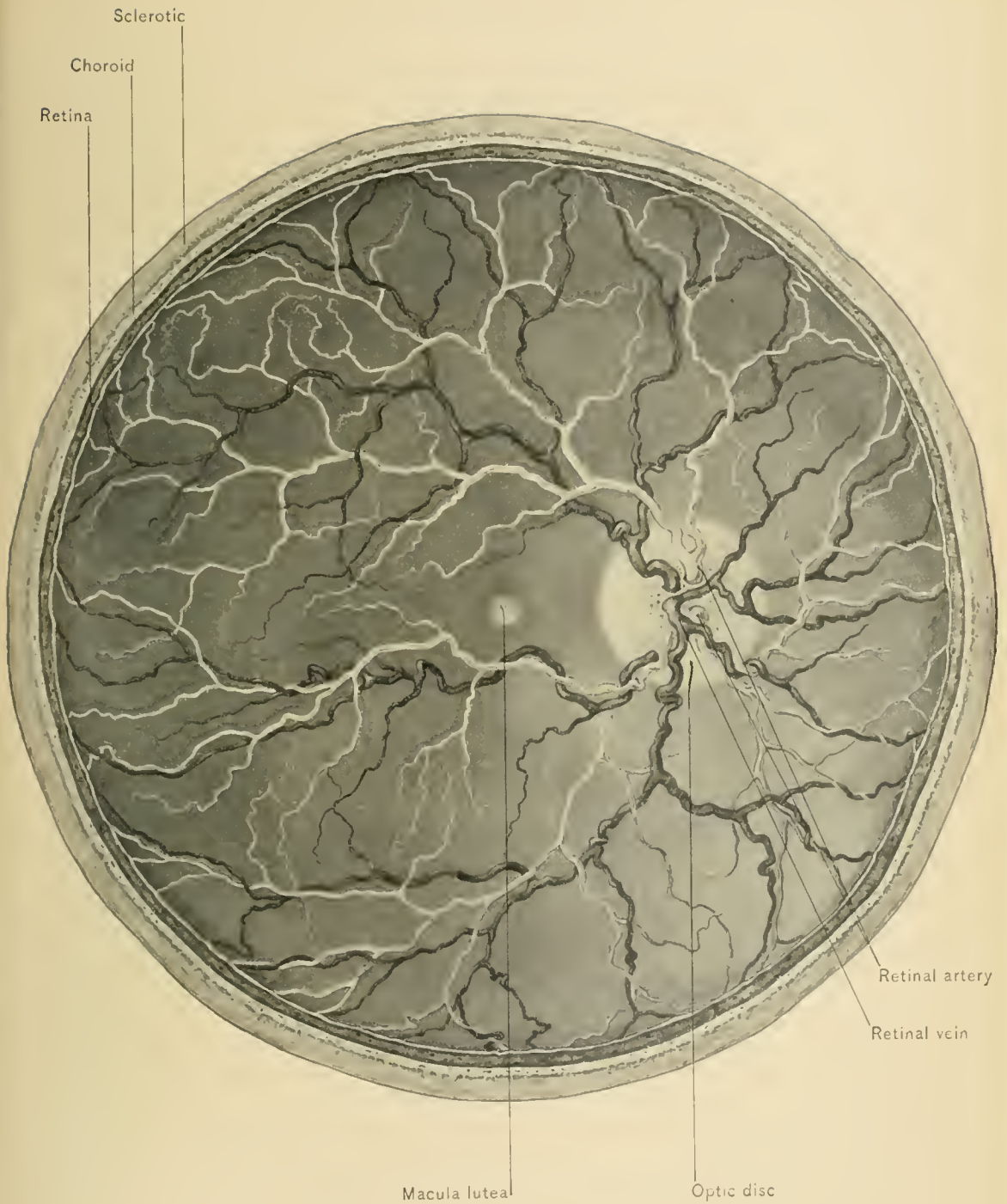
DISSECTION.—The choroid, ciliary body, and iris should be carefully stripped from that eyeball in which they were exposed. This should be done under diluted alcohol, and when completed, the retina will be seen. If a portion of the detached choroid is inspected, on its inner surface irregular black patches will be observed. These are fragments of the pigment layer of the retina which have become detached on account of their firm adhesion to the lamina vitrea of the choroid.

The **Retina**, the third and innermost coat of the eye, is the nervous tunic. It is the end organ of the optic nerve specialized for the function of vision. Morphologically, it extends from the point of entrance of the optic nerve at the foramen scleræ to the free margin of the iris. It consists of three parts: The posterior portion is situated between the choroid and the vitreous body, and extends from the optic nerve entrance to the ciliary body, where the retina suddenly becomes thin along an irregular line, thus forming the **ora serrata**. This posterior portion is called the optic part, or **pars optica retinæ**, and terminates at the ora serrata. The next portion, the ciliary part, or the **pars ciliaris retinæ**, lines the inner surface of the ciliary body, extending as far forward as the insertion of the iris. The anterior portion lines the internal surface of the iris, and is called the **pars iridica retinæ**. The pars optica retinæ is the only part which has much visual function; because the pars ciliaris and pars iridica retinæ are mainly continuations of the pigment layer beyond the ora serrata, at which the highly specialized layers of the retina suddenly diminish in thickness.

When viewed from the interior, a circle is seen at the point of entrance of the optic nerve. This is called the *optic disc*. It is sometimes called the porus opticus, but this name should be applied only to the foramen in the lamina cribrosa traversed by the central artery of the retina. This disc lies one-tenth of an inch or two and one-half millimeters to the inner side of the posterior pole of the eye. As this is the *blind spot* of the retina, it is placed outside of the direct line of vision. Exactly in the center of the retina, at the posterior pole, and in the direct line of vision, a small yellow spot, called the *macula lutea*, is seen in a fresh eye; the depression in the center of the macula lutea is termed the *fovea centralis*. The macula lutea is the point at which vision is most acute. For that reason it is situated in a line with the centers of the lens, pupil, and cornea, so that it receives the rays of light brought to a focus by the lens. Rays from other points, passing through the lens, strike other portions of the pars optica retinæ and produce collateral vision, which is less distinct.

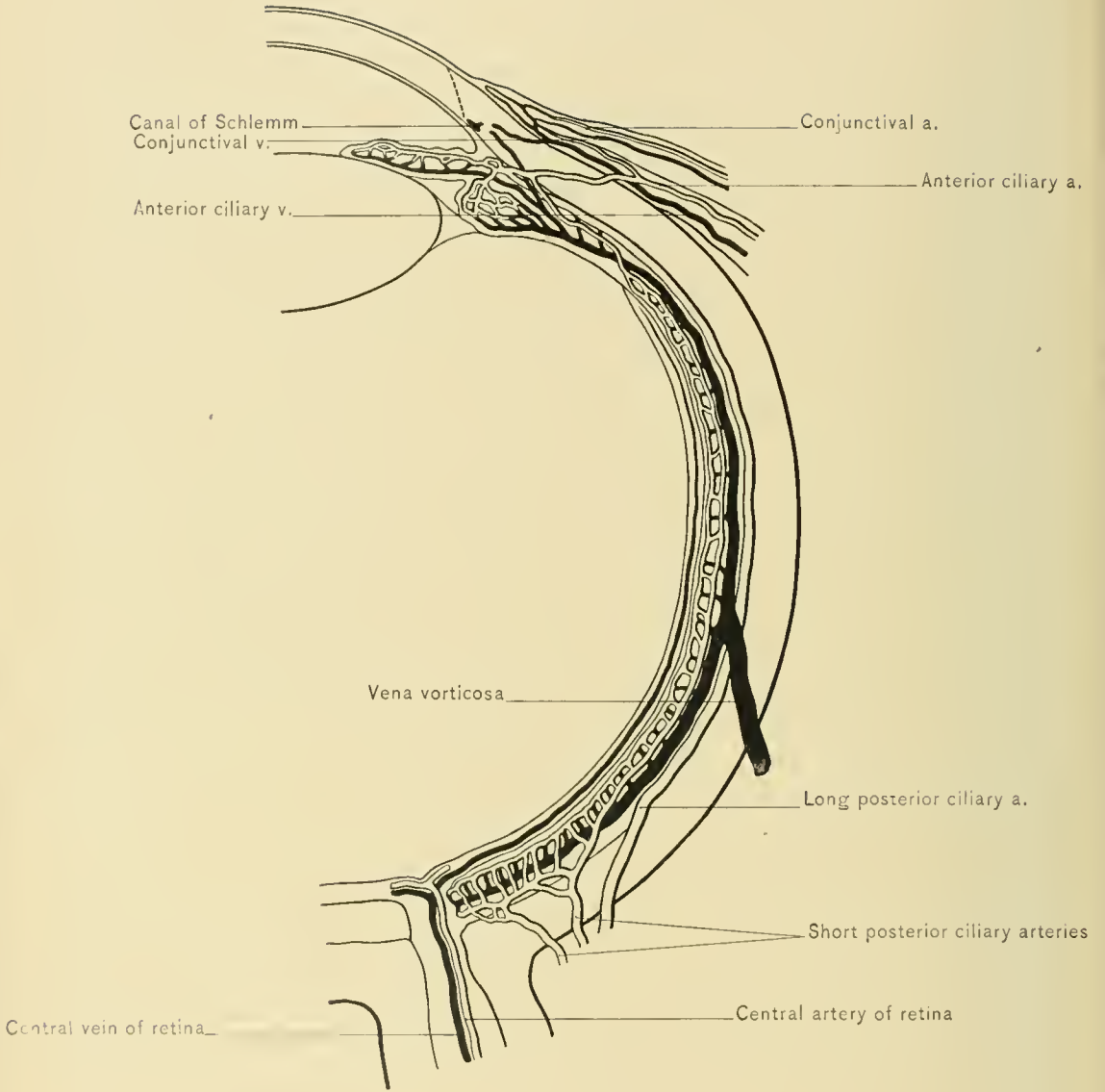
The retina is derived from the two layers of the optic cup, which is an extension of the anterior cerebral vesicle and is, therefore, ectodermic in origin. The outer layer of the cup remains as the pigment layer of the retina, while the inner layer gives rise to the remaining and more specialized portion of it. During life the inner layer is pink and transparent; but after death it becomes hazy and opaque.

BLOOD SUPPLY.—The blood supply of the retina is derived partly from the arteria centralis retinæ, which can be seen entering the eye at the optic disc. It gives off an ascending and a descending branch, each of which has a small nasal



RETINA OF POSTERIOR ONE-HALF OF RIGHT EYEBALL (ENLARGED).





branch. Like the vessels of the brain, lungs, etc., its branches are end arteries, not anastomosing in the substance of the retina with each other or with the ciliary arteries. Probably the greater portion of the nourishment of the retina is derived from the posterior ciliary vessels, through the chorio-capillaris of the choroid.

The **retinal veins** converge to form two vessels which enter the optic nerve at the optic disc, and soon join to form one vena centralis retinae, which pursues a course in the nerve corresponding to that of the artery.

DISSECTION.—The method of Anderson Stuart will be found the most satisfactory for studying the vitreous body and lens. A perfectly fresh eyeball should not be used: it should be kept from one to three days before being utilized, according to the season of the year. The three tunics are divided at the equator and turned back. This is done carefully and over a vessel of diluted alcohol, into which the so-called “eye kernel,” composed of the vitreous body and lens, is allowed to fall. The “eye kernel” is then placed in a strong picrocarmin solution for a few minutes, and when removed, it should be well washed. By this method the hyaloid membrane, the lens capsule, and the zone of Zinn are stained red. If the solution is shaken gently, the coloring matter may enter the hyaloid canal, which may thus be recognized.

The **Vitreous Body** is a soft, gelatinous, perfectly transparent substance, composed of semi-solid connective tissue. It occupies the posterior cavity or vitreous chamber of the globe. The *vitreous chamber* is bounded behind and laterally by the retina, and in front by the lens and the zone of Zinn. The vitreous body consists of the vitreous substance, inclosed by the **hyaloid membrane**, except anteriorly, where the vitreous substance comes into direct contact with the lens capsule, receiving the lens into a depression, the **patellar fossa** of the vitreous body. It has an indistinctly reticulated structure, and may contain small corpuscular bodies which occasionally produce shadows upon the retina, the so-called **muscæ volitantes**. Running from the optic disc to the center of the posterior surface of the lens is a narrow canal, lined by a prolongation of the hyaloid membrane, and called the **hyaloid canal**, **canal of Stilling**, or **canal of Cloquet**. During fetal life this canal transmits an artery to the lens, the hyaloid artery, and in the adult contains the remains of the supporting connective tissue or rarely an atrophied vessel.

The **Zone of Zinn**, **Zonula of Zinn**, or **Suspensory Ligament of the Lens**, is the thickened portion of the hyaloid membrane extending from the ciliary body to the lens. At the ora serrata the hyaloid membrane becomes attached to the ciliary body and remains so attached as far as the peripheral or anterior ends of the ciliary processes. From the apices of the ciliary processes thick bands of the hyaloid membrane pass over to the lens, going to its periphery and

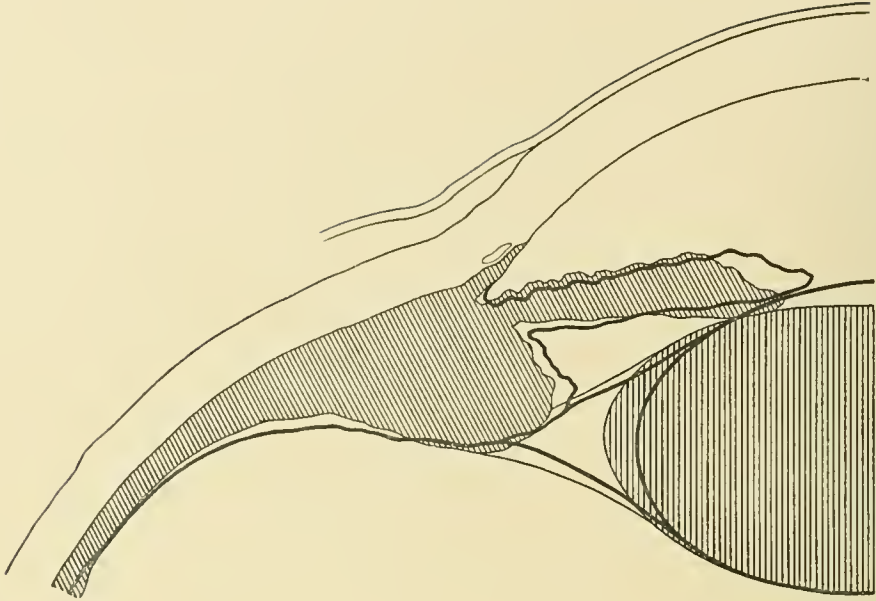
anterior surface. The hyaloid membrane, in this region, is thrown into numerous folds, caused by the plications of the choroid portion of the ciliary body, to which it is so closely apposed. At the ciliary margin of the ligament these folds become converted into stiff fibers, which form two series. One series consists of those fibers which spring from the apices of the ciliary processes; the other, of those which spring from the depressions between the processes. The former are inserted into the periphery and adjacent parts of the posterior portion of the capsule of the lens, and the latter go to the anterior surface of the lens, blending with the superficial layers of the anterior portion of the lens capsule.

The lens is, in this manner, maintained in its position. The tension of the zone of Zinn is varied by contraction of the ciliary muscle; when this muscle contracts, the suspensory ligament is relaxed; thus, the lens is less firmly compressed, and by its own elasticity becomes more convex, and its focal distance is decreased. This function is known as **accommodation**.

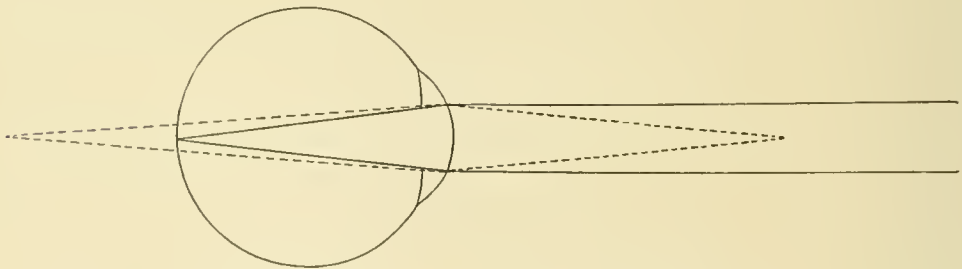
The **Canal of Petit** is a narrow lymphatic channel which encircles the margin of the lens, is triangular on section, and is bounded in front by the anterior lamina of the suspensory ligament of the lens, behind by the hyaloid membrane, and internally by the capsule of the lens. It is subdivided into two portions by the fibers of the posterior lamina of the suspensory ligament of the lens. The lymph in the canal of Petit is derived from the ciliary vessels, and is supposed to supply nutrition to the lens.

DISSECTION.—By carefully inserting a fine blowpipe into the canal of Petit it may be distended by air or a colored fluid. When so dilated, it presents a series of sacculations, due to the undulations in the zone of Zinn produced by the ciliary processes. Remove the lens by cutting through the zone of Zinn with a pair of scissors.

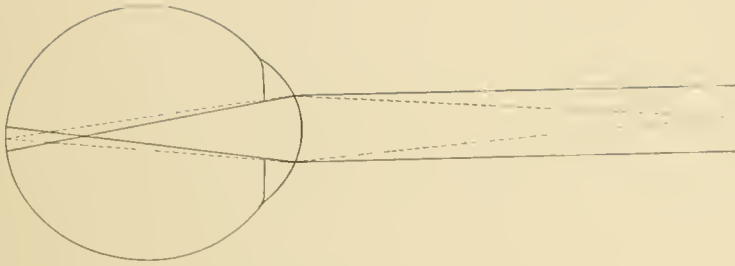
The **Crystalline Lens** is a biconvex, circular body, lying behind the iris and aqueous humor, and in front of the vitreous body. Its rounded margin is a short distance from, and parallel with, the corona ciliaris of the ciliary body, to which it is firmly attached by the suspensory ligament of the lens. The center of the anterior surface of the lens is the anterior pole, and the center of the posterior surface is the posterior pole. The convexity of the anterior surface of the lens is not so great as that of the posterior surface. The central portion of the anterior surface is opposite the pupil, and in contact with the aqueous humor of the anterior chamber. At the margin of this central portion the lens is in contact with the posterior surface of the pupillary margin of the iris; external to this margin the curvature of the lens carries it away from the iris; this interval between the lens and iris is the posterior chamber of the eye, and is filled with part of the aqueous humor. Posteriorly, the lens is received into the patellar fossa of



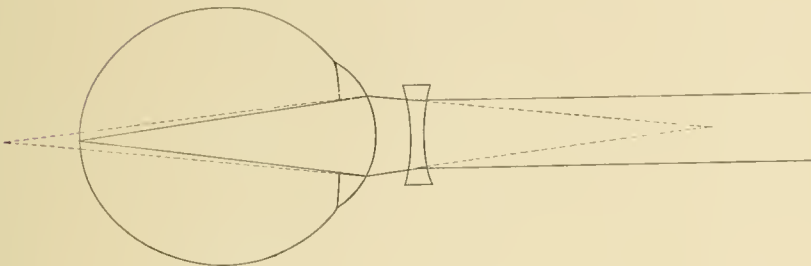
THE DARK AREAS REPRESENT THE LENS, IRIS, AND CILIARY BODY AT REST; AND THE BROAD OUTLINES INDICATE THE CHANGED POSITION OF THOSE STRUCTURES DURING ACCOMMODATION (AFTER FUCHS).



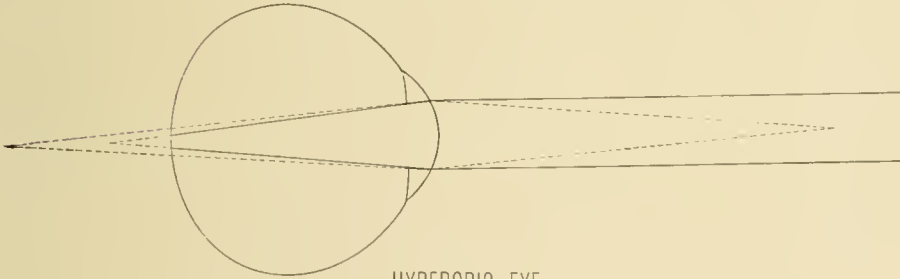
EMMETROPIC EYE.



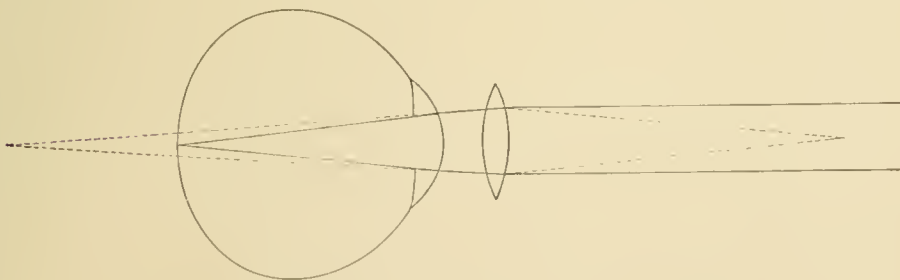
MYOPIC EYE.



MYOPIC EYE WITH CONCAVE LENS.



HYPEROPIC EYE.



HYPEROPIC EYE WITH CONVEX LENS.



the vitreous body. Peripherally, it is in relation with the zone of Zinn and the canal of Petit.

The lens is composed of the lens capsule and the lens substance. The **capsule of the lens** is the strong, elastic, transparent membrane which surrounds the lens substance. The **lens substance** is a transparent, gelatinous material, translucent in the cadaver, and composed of transparent fibers joined by a transparent cement. The **cortex**, or peripheral portion, is soft, and the central portion, or **nucleus**, is firm.

DISSECTION.—With a sharp knife divide the anterior part of the capsule of the lens, and then express the lens substance through the opening as one squeezes the pulp of a grape from its skin; the capsule and lens substance can now be examined.

The capsule of the lens or the suspensory ligament may be ruptured by traumatism, and the lens escape into the vitreous or aqueous humor. If the anterior portion of the capsule is torn, the aqueous humor will enter and produce opacity of the lens. This is done purposely in the treatment of soft cataract, so that the lens substance may be absorbed by the aqueous humor.

In **presbyopia**, or old-age sight, the power of accommodation is diminished through the loss of elasticity of the lens. This occurs between the ages of forty and fifty years. In an emmetropic eye which has become presbyopic parallel rays come to a focus on the retina, and distant objects are easily seen, but, through loss of accommodation, near objects are not discerned so readily. As hyperopic eyes constantly require the function of accommodation, gradual loss of this function causes them to feel the effects of presbyopia at an earlier age than emmetropic or myopic eyes. A myopic eye may never suffer from the effects of presbyopia, because it requires no accommodation.

A **cataract** is a diminution in the transparency of the capsule or substance of the lens. After extraction of the cataractous lens, much of the refractive power of the eyeball is lost; consequently, highly convex glasses are required to bring the rays of light to a focus on the retina.

The **Chambers of the Eyeball** are two in number in addition to the vitreous chamber. Both are in front of the lens; both are lymph spaces and contain aqueous humor, and they are separated from each other by the iris.

The **anterior chamber** of the eye is bounded in front by the cornea and behind by the iris and that portion of the lens which presents at the pupil. It communicates with the posterior chamber through the pupil. At its external angle it is bounded by the pectinate ligament of the iris. This angle, which is formed by the peripheral portions of the cornea and iris, is called the *angle* or *sinus of the anterior chamber*, or the *filtration angle*. Knowledge of the anatomy of

the structures at this angle is most important, for it is here that the excess of the aqueous humor escapes into the spaces of Fontana, and thence by way of the canal of Schlemm into the anterior ciliary veins, thus reducing intra-ocular tension.

Hypopyon is a collection of pus in the anterior chamber of the eye, and arises from suppurative inflammation of the cornea, iris, ciliary body, and choroid. Pus passes from the ciliary body through the pectinate ligament of the iris or the attached margin of the iris to reach the anterior chamber, causing cloudiness of the aqueous humor, and its solid portion gravitates to the most dependent part of the anterior chamber, varying its position with movements of the head. Hypopyon is crescentic in form, like onyx, but the latter is stationary.

The **posterior chamber** of the eye is a circular space, triangular on cross-section, and situated behind the iris. It is bounded in front by the iris; behind, by the lens and zone of Zinn; and externally, by the anterior portion of the ciliary body. It is limited internally by the pupillary margin of the iris.

The **Lymphatic System of the Eyeball** contains no lymphatic vessels except those of the conjunctiva, the lymph being in spaces. These spaces are divided into an anterior and a posterior set.

The **anterior lymph passages** of the eye include the lymph spaces of the cornea and iris, and the anterior and posterior chambers of the eyeball.

The *lymph spaces of the cornea* are situated between the lamellæ of the corneal substance. At the periphery of the cornea the lymph flows into the conjunctival lymphatic vessels.

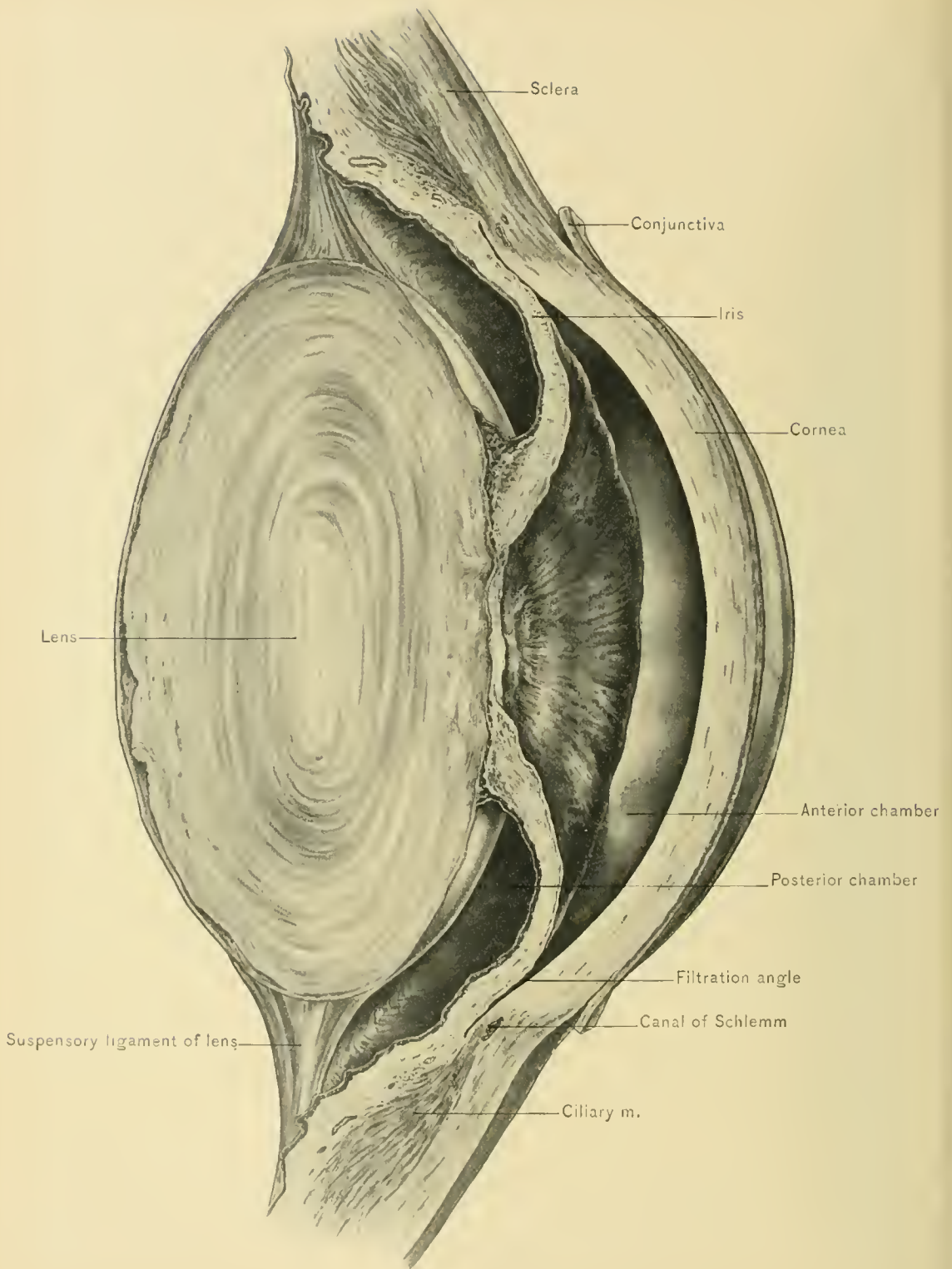
The *lymph spaces* of the iris open into the aqueous humor of the anterior chamber of the eye at small indentations called the *crypts of the iris*, and at the periphery of the iris communicate with the spaces of Fontana.

The *aqueous humor* is composed of lymph situated in the anterior and posterior chambers of the eye. It is secreted in the posterior chamber from the plexus of vessels in the ciliary body, and partly from the vessels in the posterior surface of the iris. The aqueous humor passes from the posterior chamber through the pupil into the anterior chamber of the eye, and escapes by way of the spaces of Fontana, the canal of Schlemm, and the anterior ciliary veins.

The **posterior lymph passages** of the eye include the hyaloid canal, the perichoroid space, Tenon's space, the intervaginal space of the optic nerve, and the supra-vaginal space.

The *hyaloid canal*, or central canal of the vitreous body, extends from the optic disc forward to the posterior pole of the lens. In the embryo it contains the hyaloid artery, which disappears later, although the canal remains as a lymph channel which is drained by the intervaginal space of the optic nerve.

The *perichoroid lymph space*, situated between the choroid and the sclera, is



ANNULAR POSTERIOR SYNECHIA.

continued along the vessels of the choroid and especially along the *venæ vorticosæ*. Its lymph escapes into Tenon's space by perforations in the sclera around the *venæ vorticosæ*.

Tenon's space, situated between the sclera and Tenon's capsule, drains the perichoroid space, and opens into the supra-vaginal space.

The *intereaginal lymph space* is situated between the dural and pial sheaths of the optic nerve, and is subdivided into a subdural and subarachnoid space by the extension of the arachnoid membrane of the brain along the optic nerve. It opens into the subdural and subarachnoid spaces of the brain.

The *supra-vaginal lymph space* is situated between the dural sheath of the optic nerve and the posterior extension of Tenon's capsule.

The greater portion of the lymph of the eyeball escapes by way of the chambers of the aqueous humor, spaces of Fontana, canal of Schlemm, and anterior ciliary veins; consequently, any obstruction in the anterior lymph channels causes increased intra-ocular tension. Such obstruction occurs in **annular posterior synechia**, in which the whole pupillary margin of the iris is adherent to the anterior surface of the capsule of the lens, and prevents the lymph of the posterior chamber, which is derived from the ciliary vessels, from entering the anterior chamber. The pressure thus produced in the posterior chamber causes the peripheral portion of the iris to project forward against the cornea, obliterating the filtration angle, or sinus of the anterior chamber, and preventing escape of lymph from the anterior chamber of the eyeball. In this manner the serious disease of the eye, *glaucoma*, which is characterized by increased intra-ocular tension, is produced. Glaucoma also develops from conditions not so readily demonstrable, as hypersecretion of lymph, and other causes of retention of lymph, in the eyeball.

In **emmetropia**, or normal vision, parallel rays of light or those from distant objects are brought to a focus on the retina when the eye is at rest, and divergent rays or those from near objects do not reach a focus on the retina without some exercise of the function of accommodation. Normal vision occurs in an eye whose axis, or sagittal diameter, is of the normal length, and whose media possess the proper refractive index.

In **hyperopia**, **hypermetropia**, or far-sightedness, the axis, or sagittal diameter of the eye, is usually too short, although hyperopia may be due to absence of the lens, decreased convexity of the refracting surfaces of the eye, or diminished power of refraction in the refractive media of the eye. The result is that when the ciliary muscle is at rest, parallel rays of light or those from distant objects, and divergent rays or those from near objects, come in contact with the retina before being brought to a focus, forming circular diffusion of the light

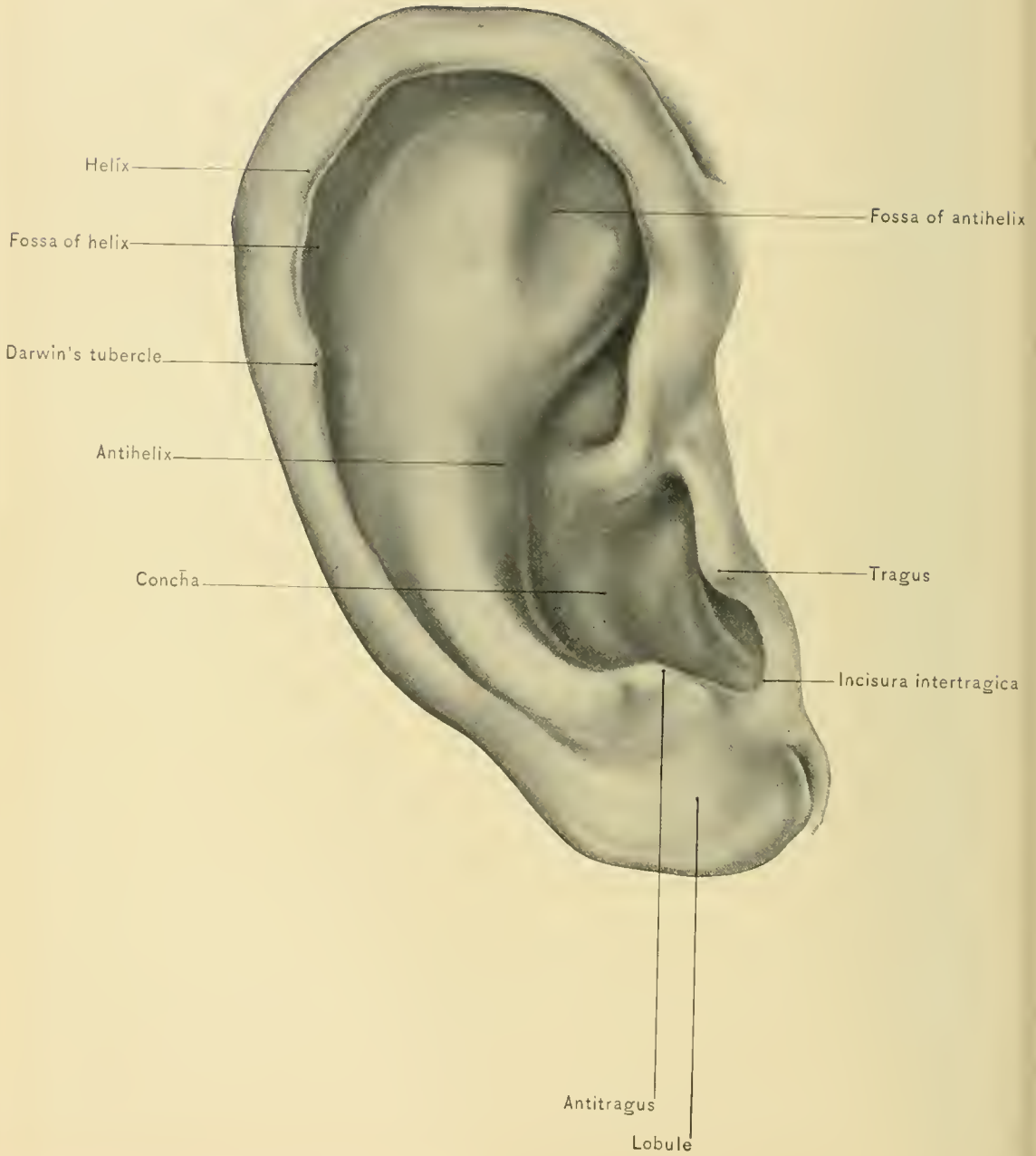
and a blurred image. The ciliary muscle compensates for the defect by contracting and allowing increased convexity of the lens; but the severe strain causes local and remote disorders, and, on account of failure of the muscle to perform the work required, reading becomes difficult. The defect is corrected by converging the rays with convex glasses.

In **myopia**, or near-sightedness, the antero-posterior, or sagittal, diameter is too long, and parallel rays of light are brought to a focus in front of the retina, so that distant objects are indistinct because the image is blurred. Divergent rays or those from near objects at a certain distance are brought to a focus upon the retina. Myopia occasionally results from increased refractive power of the lens; when this occurs in an old person, *second sight* is produced and convex glasses may be discarded. As there is no mechanism in the eye which can compensate for the defect, and the patient can see near objects, continued eye strain may cause more serious disease of the myopic eye. The defect is corrected by concave glasses which cause the rays to diverge.

Exenteration of the orbital contents is performed for malignant disease. The external canthus is split, and the orbital contents, including the periosteum, are all removed except at the apex of the orbit.

Evisceration of the eyeball is performed in staphyloma of the cornea and disfiguring leukoma. The cornea is circumsised at the sclero-corneal margin, and all the contents of the globe and the middle and internal coats of the eyeball are carefully removed, leaving the sclera intact. The opening is enlarged vertically and a glass ball is inserted into the cavity of the eye. The sclera is stitched vertically over the glass ball and the conjunctiva transversely. After the wound heals, an artificial shell may be inserted over the stump.

Enucleation or excision of the eyeball.—The eyelids are separated with a speculum, and the ocular conjunctiva is divided close to and entirely around the cornea. The conjunctiva and capsule of Tenon are pushed backward over the eye. The rectus muscles are grasped with forceps at their insertions and divided back of the forceps. The globe is drawn forward and inward, and the optic nerve and adjoining structures are divided with scissors along the outer side of the eyeball. The eye is then drawn out of its socket, and the remaining adherent tendons and other structures are severed. The cavity is irrigated with cold sterile water, and the stumps of the rectus muscle are sutured together. The wound is cleansed, and a sterilized dressing applied.



THE ORGAN OF HEARING.

The organ of hearing consists of three portions—the external, middle, and internal ear. The **External Ear** comprises the auricle or pinna and the meatus auditorius externus; the former is of but slight importance physiologically; the latter is the canal which leads inward to the tympanic membrane. The **Middle Ear** is composed of the tympanum, the mastoid antrum, and the mastoid cells. The tympanum, an air chamber, communicates with the naso-pharynx by means of the Eustachian tube, and contains a chain of movable bones—the auditory ossicles. The mastoid antrum and mastoid cells are air chambers accessory to the tympanum. The **Internal Ear, or Labyrinth**, is made up of a complex arrangement of cavities; it contains a fluid,—the perilymph,—together with a membranous cast of the bony structures known as the membranous labyrinth; the latter contains the endolymph, and within it are the specialized neuro-epithelial cells and the terminations of the auditory nerve.

THE EXTERNAL EAR.

The **Pinna** consists of a pliable framework of yellow, elastic cartilage covered with integument. The external surface is concave, and conducts the sound waves to the external auditory meatus, yet accidental or intentional amputation of the pinna causes but slight diminution in acuteness of hearing. The outer concave surface presents a number of elevations and depressions. The **helix** is the incurved border of the pinna. At the free border of the helix there is often to be seen a more or less prominent, rather triangular projection, known as the **Darwinian tubercle**; it is analogous to the pointed tip of the ear of quadrupeds. The **fossa of the helix** is the groove formed by the inward curvature of the helix. In front of the helix, and running parallel with it, is a rounded prominence, the **antihelix**, which divides anteriorly and above into two portions inclosing the **fossa of the antihelix** (*fossa scaphoidea*). The antihelix curves around a large concavity,—the **concha**,—which leads to the external auditory meatus. Anterior to the concha is a blunt projection, the **tragus**. This is really a portion of the wall of the external auditory meatus, and to it a number of stiff hairs are often attached. Opposite the tragus is a small projection, the **antitragus**; between the two is a notch, the **incisura intertragica**. The lowest portion of the pinna—the **lobule**—is devoid of cartilage, and is composed of fibro-areolar and adipose tissue. The lobule may gradually be slit in two by heavy ear-rings, and a fibrous or keloid tumor may arise from the scar which forms where the lobule has been pierced.

The pinna is developed in the embryo from six small tubercles which form at the external extremity of the first branchial cleft. As a result of imperfect fusion of these tubules **supernumerary auricles** or **auricular fistulæ** may occur near the external auditory meatus. If the orifice of one of these fistule is closed, a **dermoid cyst** of the pinna forms. Supernumerary pinnæ or auricles may also develop at the external extremity of the other branchial clefts.

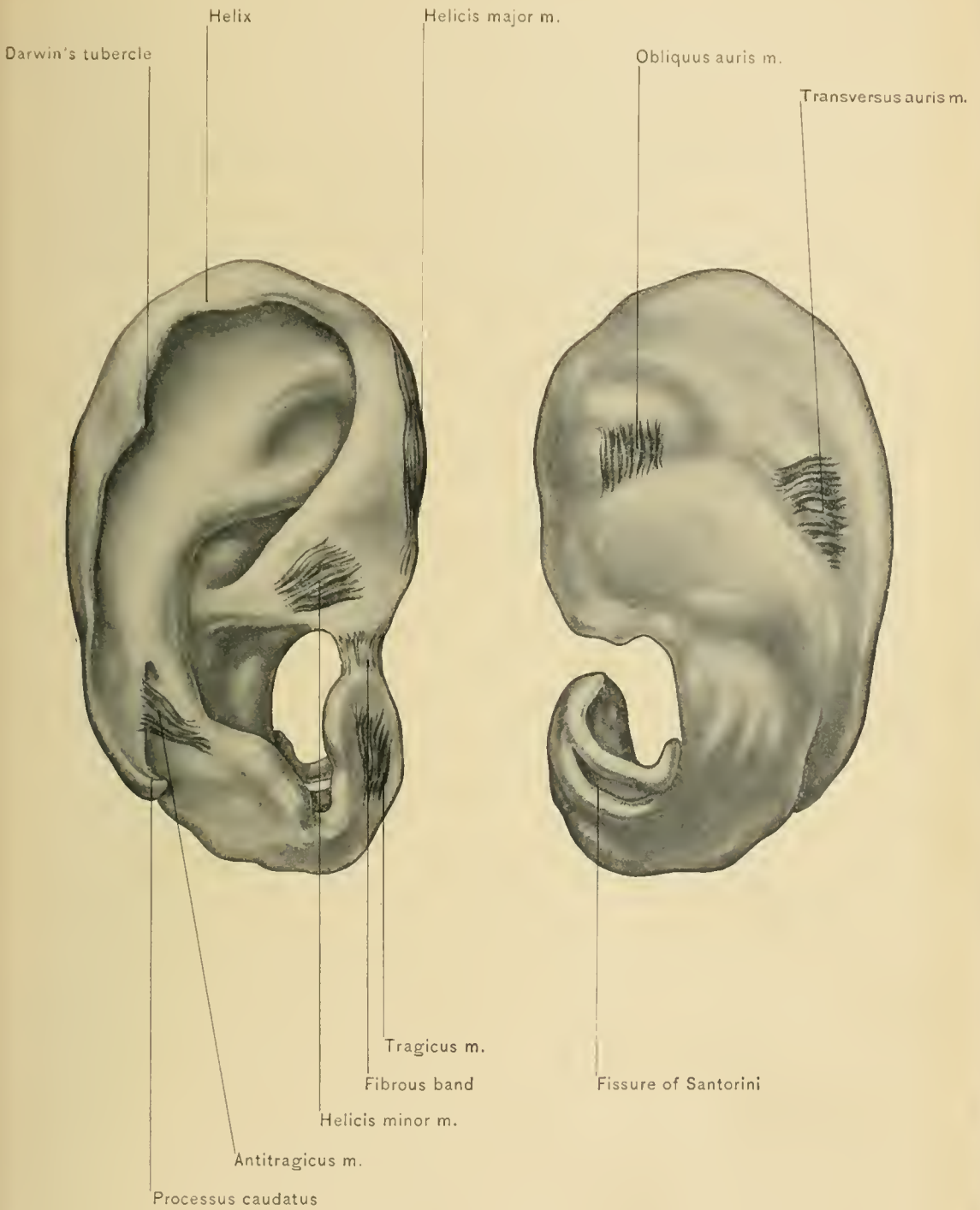
The **integument of the auricle**, which is continuous with that lining the external auditory meatus, is thin, and contains sebaceous glands and, in certain situations, hairs and sudoriferous glands. The sebaceous glands are most abundant in the concha, where their orifices can often be seen, filled with foreign material, in persons who are careless as to cleanliness. *Sebaceous cysts* not infrequently develop in the skin of the pinna. The integument is more firmly attached over the concave surface of the pinna than on the convex or cranial surface. Hemorrhagic effusions beneath the skin or between the cartilage and its perichondrium, as a result of trauma, are not uncommonly seen in pugilists; they are known as *othematomata*. On account of the close union between the skin and the concave surface of the pinna, inflammatory affections are painful in this location. In chronic gout subcutaneous deposits of sodium urate, termed *tophi*, are found in the pinna.

The **subcutaneous tissue of the pinna** forms a thin lamina almost devoid of fat. The lack of subcutaneous fat, which affords protection from cold to the blood-vessels, and the exposed position of the pinna account for the frequency of **frost-bite** in this location, which occasionally causes gangrene of the pinna.

The yellow, elastic **cartilage of the auricle**, which gives form to that structure, presents several fissures and processes; there is a fissure between the origin of the helix and the tragus which is filled with fibrous tissue. The lower end of the antihelix is divided into two parts, one of which terminates in a pointed extremity called the **processus caudatus**. At the anterior portion of the pinna, near the first curve of the helix, there is a projection,—the **spina helieis**,—and behind it is a short cleft—the **fissure of the helix**. Bands of fibrous tissue—the so-called **ligaments of the pinna**—connect this structure with the cranium, and others unite the various parts of the cartilage. Anteriorly a band of fibrous tissue connects the spina helieis with the root of the zygoma, and fibrous tissue attaches the concha to the mastoid process posteriorly.

The **intrinsic muscles of the auricle** are small, rudimentary, and unimportant. The extrinsic muscles have been described with the face.

BLOOD SUPPLY.—The arteries, with which the pinna is well supplied, are derived from the posterior auricular, occipital, and superficial temporal arteries. They are accompanied by corresponding veins.



INTRINSIC MUSCLES OF PINNA.

NERVE SUPPLY.—The sensory nerves of the pinna are derived chiefly from the auriculo-temporal and auricularis magnus, although filaments are contributed by the occipitalis minor and the auricular branch of the vagus nerve; the motor nerves to the muscles of the auricle are derived from the facial nerve. As the back of the pinna is supplied by the auricularis magnus and small occipital nerves and the lobule by the auricularis magnus nerve, pain in the pinna may be caused by irritation of the cervical nerves in caries of the cervical vertebræ or by enlarged cervical lymphatic glands.

The **lymphatics of the pinna** are numerous, and pass to the preauricular or superficial parotid lymphatic glands and to the posterior auricular lymphatic glands.

The **External Auditory Canal** is a slightly curved passage, convex upward, which leads inward and a little forward for a distance of about twenty-four millimeters, or one inch, to the membrana tympani. The highest portion of the canal is about at its middle. Drawing the pinna upward and backward has a tendency to straighten the canal; this is done prior to inspection of the canal or to introduction of instruments. Owing to the obliquity of the tympanic membrane, the anterior and inferior walls of the external auditory meatus are the longer, and the internal extremity of the canal is wedge-shaped, terminating in a narrow recess—the **sinus** of the external auditory meatus. Small **foreign bodies** which have lodged in the sinus of the canal must be removed carefully, as the instruments must approach the membrana tympani closely. The meatus is elliptic at the external orifice, the vertical diameter of the canal being the greater; near the membrana tympani the transverse diameter is the greater. Although the orifice of the external meatus is elliptic, ear specula which are round are more desirable than the elliptic instruments, for they can be rotated while being introduced. The outer one-third of the wall of the external auditory meatus is cartilaginous and continuous with the cartilage of the pinna; this portion is about eight millimeters, or three-eighths of an inch, in length, and the cartilage presents one or two fissures, known as the **incisuræ Santorini**, which are filled with fibrous tissue. The inner or osseous portion is somewhat longer, and measures less in diameter than the cartilaginous portion, its average length being about sixteen millimeters, or five-eighths of an inch. At birth the osseous portion is represented merely by an incomplete bony ring,—the **annulus tympanicus**,—and a mass of epithelial cells and cerumen fills the canal.

The **integument** lining the meatus is thin, and firmly attached to the underlying parts; consequently inflammatory processes, such as furuncles, are accompanied by considerable pain: the cutaneous lining is continued over the tympanic membrane as a delicate covering, forming the outer layer of that structure.

Hairs and sebaceous glands are found in the cartilaginous portion of the meatus, as well as slightly modified sweat glands which secrete the cerumen, or ear wax. When the cerumen, or wax, is secreted too rapidly, the meatus becomes occluded, and deafness and tinnitus aurium result. No hairs or glands are found in the osseous portion of the external auditory meatus.

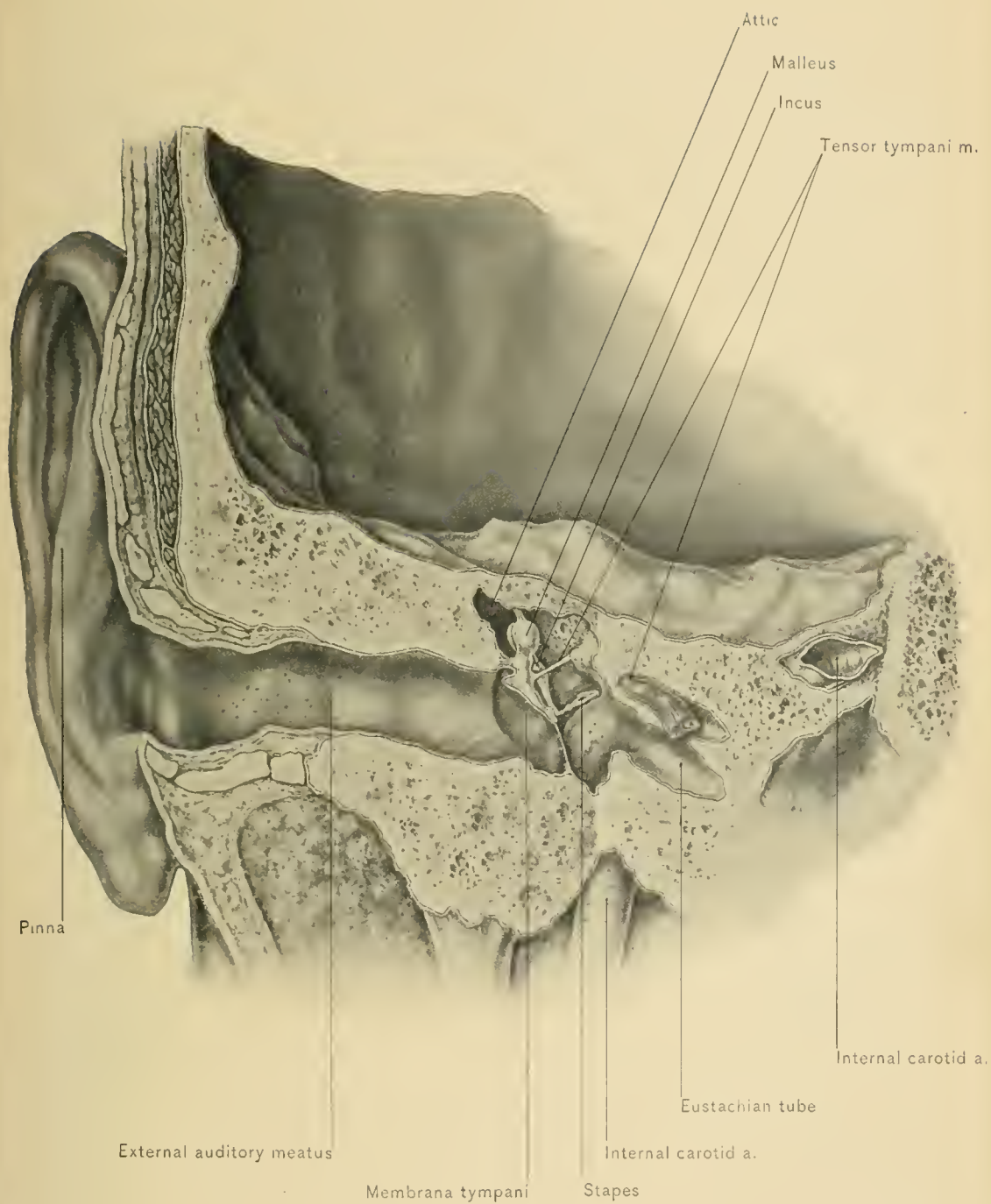
In **otitis externa** the skin of the external auditory meatus is inflamed, and there may be a purulent discharge from that canal.

Occlusion of the external auditory meatus may occur as a congenital defect or from the presence of polypoid growths arising from granulations projecting through a perforation in the membrana tympani in chronic otitis media, from exostoses from the bony wall, from foreign bodies, or from an excessive quantity of cerumen.

Foreign bodies may remain in the external auditory meatus for many years without causing injury or inconvenience, and they may not be discovered until otoscopic examination for some condition in no way connected with the presence of the foreign body. Unskillful attempts at removal have inflicted nearly all the injury following the presence of these foreign bodies. No attempt should be made to remove a foreign body until it is seen in the meatus. Insects or other foreign bodies may be removed by syringing gently with a slender stream of warm water. If this fail, a small hook, which can be made of a hair-pin, should be inserted and kept in view, the canal being well illuminated. If the walls of the canal are swollen, removal of the foreign body should be deferred until the swelling has subsided.

RELATIONS.—A portion of the parotid gland is in relation with the lower and anterior wall of the external auditory meatus; this explains how parotid tumors can cause narrowing of that canal, and how abscesses of the parotid gland might open into it, the fissures in the cartilage affording a favorable situation for perforation. The anterior wall of the meatus is also in relation with the condyle of the lower jaw, so that firm closure of the mouth has a tendency to narrow the lumen of the meatus. When the condyle is driven forcibly backward, as by a blow or a fall on the chin, the bony wall of the meatus may be fractured. The posterior and upper walls of the canal are formed by parts of the mastoid and of the squamous portion of the temporal bone, and often only a thin, osseous partition separates it from the mastoid cells, so that caries of the osseous wall of the external auditory meatus may be followed by mastoid disease.

BLOOD SUPPLY.—The blood supply of the external auditory meatus is derived from branches of the internal maxillary, posterior auricular, and superficial temporal arteries.



EXTERNAL AND MIDDLE EAR.

The *veins* accompany the corresponding arteries and empty into the temporal, internal maxillary, and posterior auricular veins.

NERVE SUPPLY.—The nerve supply of the external auditory meatus is derived from branches of the auriculo-temporal, the auricularis magnus, and the auricular branch of the vagus nerve. Interesting reflex disturbances are at times caused by the presence of foreign bodies, wax, or specula through irritation reflected along the auricular branch of the pneumogastric nerve and referred to the parts supplied by the parent trunk; coughing, faintness, and nausea and vomiting may be induced in this manner. Sneezing is also produced by the presence of foreign bodies or specula in the external auditory meatus. The irritation is reflected probably along the auriculo-temporal nerve to the Gasserian ganglion or other centers of the fifth nerve, and thence referred to the nose through branches of the superior maxillary nerve. Cough produced by irritation reflected from the ear is termed **ear cough**. **Earache** associated with toothache in the upper teeth may be explained in the same manner. Earache frequently is associated with toothache in the lower teeth and disease of the tongue; the pain in the ear is due probably to irritation reflected along the inferior dental nerve and lingual nerve, and referred to the ear through the auriculo-temporal, the other sensory branch of the inferior maxillary nerve.

The **lymphatics of the external auditory meatus** follow the veins, and terminate in the parotid and posterior auricular lymphatic glands.

DISSECTION.—The tympanum is to be opened with a chisel by the removal of its bony roof (tegmen tympani); the opening is made to the outer side of the elevation produced by the superior semicircular canal, and is enlarged carefully, uncovering also the mastoid antrum and the internal auditory meatus.

THE MIDDLE EAR.

The **Middle Ear**, or **Tympanum**, is a small, irregular air chamber, situated in the petrous portion of the temporal bone, and lined with mucous membrane; it is interposed between the external auditory meatus and the internal ear. Its antero-posterior length measures about twelve millimeters, or one-half of an inch; its width is from two millimeters to four millimeters, or from one-twelfth to one-sixth of an inch, and it is narrowest opposite the center or umbilicus of the tympanic membrane which is opposite the promontory; vertically it is about thirteen millimeters, or somewhat more than half an inch, in depth; this last measurement includes the recessus epitympanicus, or attic.

The **attic**, or **recessus epitympanicus**, is the highest portion of the tympanic cavity. It is situated above the level of the membrana tympani,

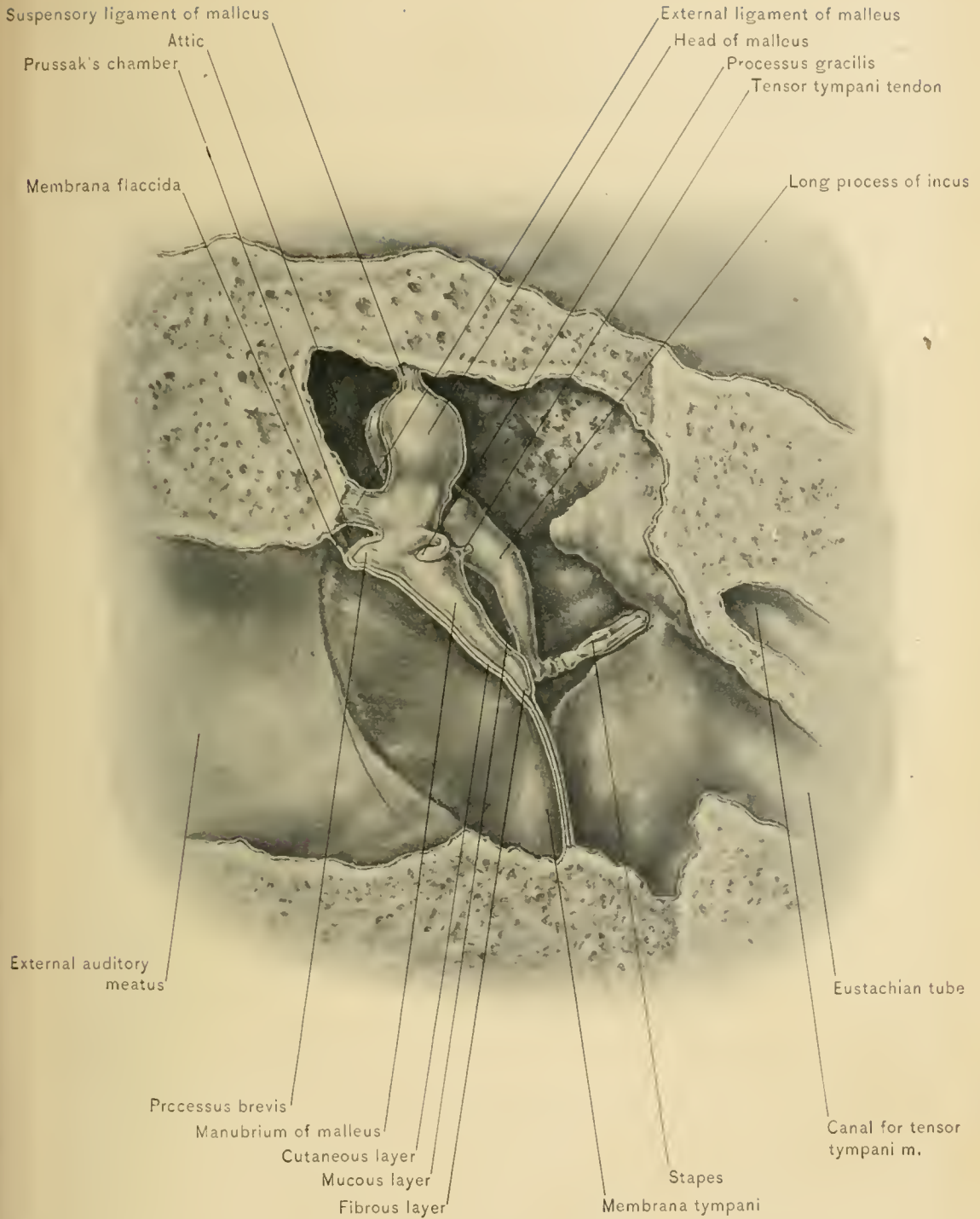
and contains the head of the malleus and part of the incus, and leads into the mastoid antrum.

The **roof of the tympanum** consists of a thin plate of bone—tegmen tympani—which separates the tympanum from the cranial cavity; it forms part of the antero-superior surface of the petrous portion of the temporal bone. Destruction of this osseous lamina or extension through it of the inflammatory process in chronic otitis media may lead to meningeal or cerebral complications, such as extradural abscess, meningitis, abscess of the temporo-sphenoid lobe of the cerebrum, and cerebellar abscess. In children under one year of age the presence of the petro-squamosal suture in the tegmen tympani favors this complication.


The **floor** is formed by a thin, bony plate situated between the tympanum and the jugular fossa. Destruction of this plate of bone by caries in otitis media may cause fatal hemorrhage or septic thrombosis of the internal jugular vein, embolism, and metastatic abscess.

The **anterior wall** is quite narrow, and is deficient superiorly, inasmuch as the Eustachian tube opens into the tympanum in this situation about four millimeters, or one-sixth of an inch, above the floor. Just above the entrance of the tube is the opening of the canal which lodges the tensor tympani muscle. Owing to the position of the tympanic orifice of the Eustachian tube above the level of the floor of the tympanum, fluid which has entered the tympanum by way of the Eustachian tube, through snuffing water in surf-bathing or in using the nasal douche, can not all escape through the tube, and otitis media is likely to result. Below the orifice of the Eustachian tube the anterior wall is composed of a thin, bony lamina, situated between the tympanum and the carotid canal. Caries of this thin plate of bone may occur in otitis media, and ulceration into the internal carotid artery with fatal hemorrhage may follow.

The **Eustachian tube** is the anterior extension of the tympanic cavity which connects the middle ear with the naso-pharynx; it passes inward, downward, and forward from the tympanum, is about thirty-five millimeters, or an inch and a half, in length, and in its several portions varies from two to five millimeters, or from one-twelfth to one-fifth of an inch, in diameter. It consists of an osseous and a cartilaginous portion, the former being about twelve millimeters, or one-half of an inch, long, and the latter about twenty-five millimeters, or one inch, long. The *cartilaginous portion* is somewhat trumpet-shaped, being widest at the *pharyngeal* orifice. It is formed by a cartilaginous plate which is triangular in shape and folded upon itself, thus leaving on the inferior and external aspect of the tube an interval which is filled with fibrous tissue (*fascia salpingo-pharyngea*), and by a part of the tensor palati muscle called the *dilatator tubæ*. (See also description of pharynx.) The *bony portion*, which is smaller than the carti-



ANTERIOR VIEW OF RIGHT TYMPANUM.



laminous portion of the tube, is situated at the junction of the squamous and petrous portions of the temporal bone; the *isthmus tubæ*, its narrowest portion, is situated at the junction of the bony and cartilaginous parts. The Eustachian tube is lined with mucous membrane which is continuous with that of the naso-pharynx and that lining the middle ear. Consequently inflammatory processes of the naso-pharynx, by direct continuity of the tissues, may lead to involvement of the middle ear. The tympanic orifice of the Eustachian tube is situated in the anterior wall of the tympanum, about four millimeters above the floor of that cavity, and the pharyngeal orifice is in the lateral wall of the naso-pharynx, behind the posterior naris, at the level of the posterior extremity of the inferior turbinated bone. Normally the canal is closed, except during swallowing, when it is opened by the tensor palati muscle, levator palati muscle, and the salpingo-pharyngeus, which is the portion of the palato-pharyngeus muscle attached to the Eustachian tube. The action of these muscles during swallowing affords an opportunity to inflate the middle ear by way of the nose, naso-pharynx, and Eustachian tube.

In **Politzer's method of inflation of the middle ear** the patient takes some water in his mouth; the nozzle of a caoutchouc bag which contains air is inserted into one nostril; the nostrils are closed with the fingers of one hand; and as the patient swallows the water the bag is suddenly and forcibly compressed with the other hand. In the **method of Valsalva** the patient closes the mouth and nose firmly and puffs out the cheeks by a forcible effort at expiration. Air is driven through the Eustachian tube, and a sense of pressure and fullness is felt in the middle ear. This method is not altogether safe, on account of the increased tension produced in the blood-vessels and the danger of hemorrhages and apoplexy. The middle ear may also be inflated by the caoutchouc bag and Eustachian catheter; the method for introducing the catheter is described with the pharynx.

The Eustachian tube may be closed by the extension of hypertrophic nasal and naso-pharyngeal catarrh into the tube, or the pharyngeal orifice of the tube may be obstructed mechanically by growths of the nose or naso-pharynx. Occlusion of this tube causes antophony, or loud but muffled sound of the individual's voice, tinnitus aurium, or false sounds in the ears, a sensation of tension or distention in the ears, and more or less deafness.

In the mucous membrane of the Eustachian tube and near the pharyngeal end of the tube there are a few *mucous glands* and a quantity of lymphoid tissue; this latter is sometimes referred to as the *tubal tonsil*.

RELATIONS.—On the outer side of the Eustachian tube are the tensor palati and levator palati muscles, the otic ganglion, the inferior maxillary nerve, and the middle meningeal artery; on the inner side is the wall of the pharynx.

BLOOD SUPPLY.—The blood supply of the Eustachian tube is derived from the ascending pharyngeal, middle meningeal, and Vidian arteries.

NERVE SUPPLY.—The nerve supply of the Eustachian tube is derived from the Vidian nerve and the tympanic plexus.

The **posterior wall of the middle ear** presents at its upper portion a large opening which leads into the mastoid antrum; through this opening the mucous membrane is continuous from one cavity to the other, so that inflammation in the middle ear may lead to involvement of the mastoid air cells. Below the opening into the antrum, near the inner wall of the tympanum and posterior to the fenestra ovalis, is a hollow, cone-shaped projection known as the *pyramid*, at the summit of which there is a perforation for the passage of the tendon of the stapedius muscle. External to the pyramid is the *iter chordæ posterius*, through which the chorda tympani nerve passes.

As the **Mastoid Antrum and Mastoid Cells** communicate with the middle ear, they are cavities accessory to the tympanic cavity.

The **mastoid portion of the temporal bone** contains numerous spaces, some of which are filled with air; these communicate with the middle ear, and are called mastoid cells; other spaces which occupy the tip of the process are filled with marrow. Of the air cavities, the *mastoid antrum* is the largest and most important. Leidy described the mastoid antrum as a part of the tympanum.

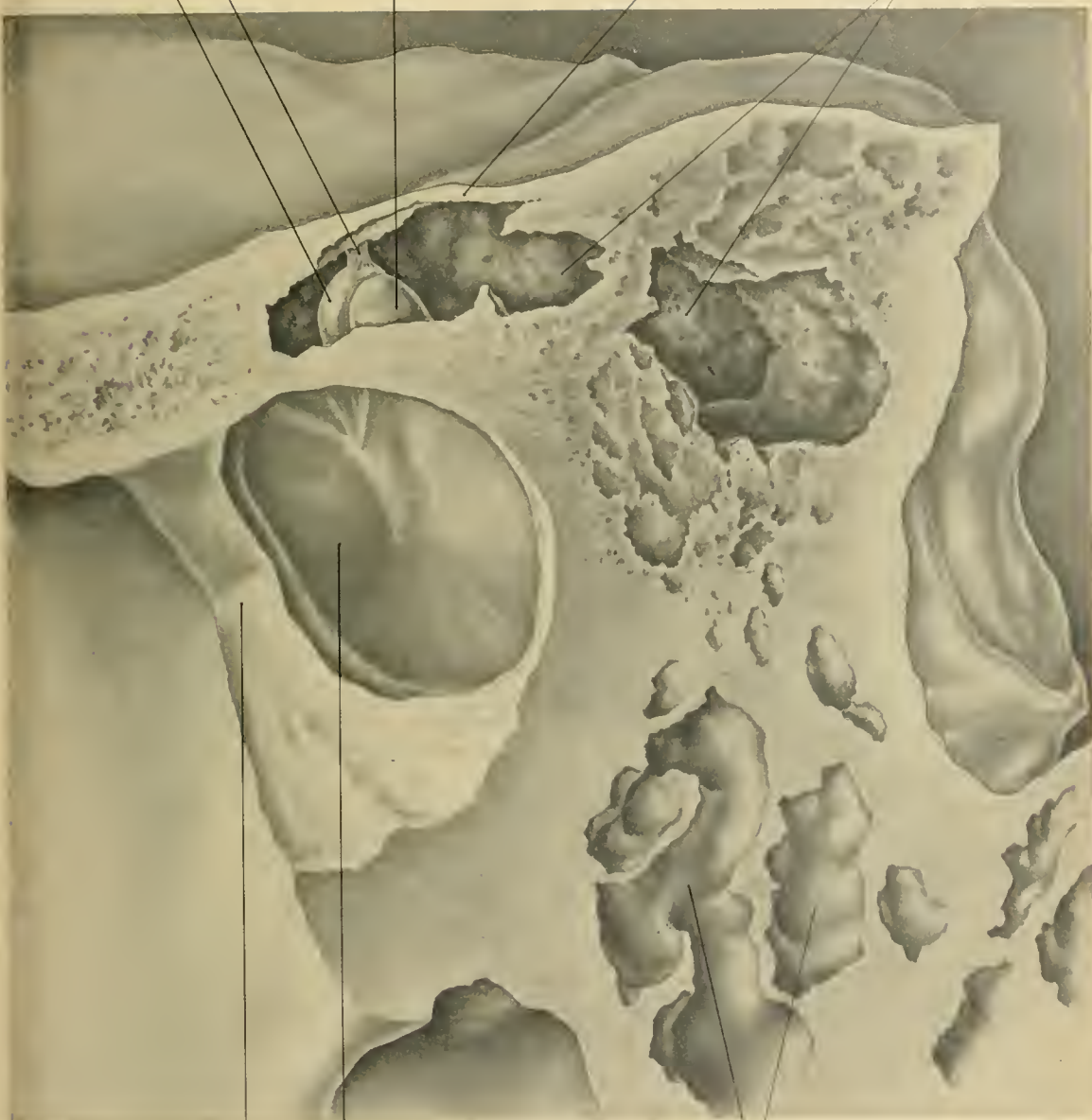The **Mastoid Antrum** is an air cavity of variable size, usually about that of a large pea, or from four to six millimeters in diameter, and is situated posterior to the tympanum, about on a level with the highest part of that cavity. It is lined with mucous membrane or muco-periosteum, which is directly continuous with that of the attic of the tympanum and mastoid cells. The mastoid antrum is present at birth.

The **roof of the mastoid antrum** (*tegmen antri*) is a thin plate of bone about one millimeter in thickness, situated external to the eminence produced by the superior semicircular canal; it separates the mastoid antrum from the cranial cavity, and is perforated by minute veins which empty into the superior petrosal sinus; at times the tegmen is distinctly cribriform, and it may be partly or wholly absorbed in old age.

The **floor of the antrum**, which is not infrequently on a lower level than the communication between the tympanum and antrum, is formed by the substance of the mastoid portion of the temporal bone, and usually contains the orifices of some of the other mastoid cells.

The **anterior wall of the antrum** is thin, and may be perforated; it separates the mastoid antrum from the bony part of the external auditory meatus. Inflammatory processes may extend from the mastoid antrum through this wall to the

Suspensory ligament of malleus.
Head of malleus.
Incus
Roof of tympanic cavity
Mastoid antrum



Anterior portion of membrana tympani
Anterior wall of external auditory meatus chiseled to a deeper plane
Mastoid cells



external auditory meatus, or vice versâ. Through this wall a mastoid abscess may be evacuated by way of the external auditory meatus.

The **posterior wall of the antrum** is a bony lamina of variable thickness, separating the antrum from the groove for the sigmoid sinus; through it small veins pass from the middle ear and mastoid antrum to the sigmoid sinus. By way of these veins septic material due to otitis media or mastoid disease may reach the sigmoid portion of the lateral sinus, and cause septic thrombosis and embolism.

The **inner wall of the mastoid antrum** is from nine-sixteenths to three-fourths of an inch, or fourteen to eighteen millimeters, distant from the base line of the supra-meatal triangle (MacEwen). The facial canal lies in the inner wall of the passage from the mastoid antrum to the tympanum. This canal, which is separated from the tympanum by a thin, osseous lamina, is situated above the oval window of the tympanum; on the inner side of the antro-tympanal passage-way the canal curves and then descends to the stylo-mastoid foramen. The wall of the canal is thin in children, and may be defective in that portion which lies over the oval window; the nerve is therefore more likely to suffer from neuritis in otitis media in children than from the same disease in adults.

The **outer wall of the mastoid antrum** is formed by the descending plate of the squamous portion of the temporal bone; the antrum is from one-half to three-fifths of an inch, or from twelve to fifteen millimeters, distant from the surface of the bone. In an infant the outer wall of the mastoid antrum is about two millimeters in thickness, and in a child nine years of age it is ten millimeters thick (Symington). In the second year this wall rapidly increases in thickness. In infants the descending plate of the squamosal bone is separated from the mastoid process by a suture, the masto-squamosal suture. In adults this suture at times persists wholly or partially. In children, on account of the tenuity of the external wall of the mastoid antrum and the presence of this suture, pus may find its way to the exterior through the middle ear and mastoid antrum, and form a subperiosteal abscess over the mastoid portion of the temporal bone. In some cases this wall has been perforated spontaneously by absorption of the bone. In these cases an air tumor, or **pneumatocele**, which can be inflated through the Eustachian tube may form over the mastoid process.

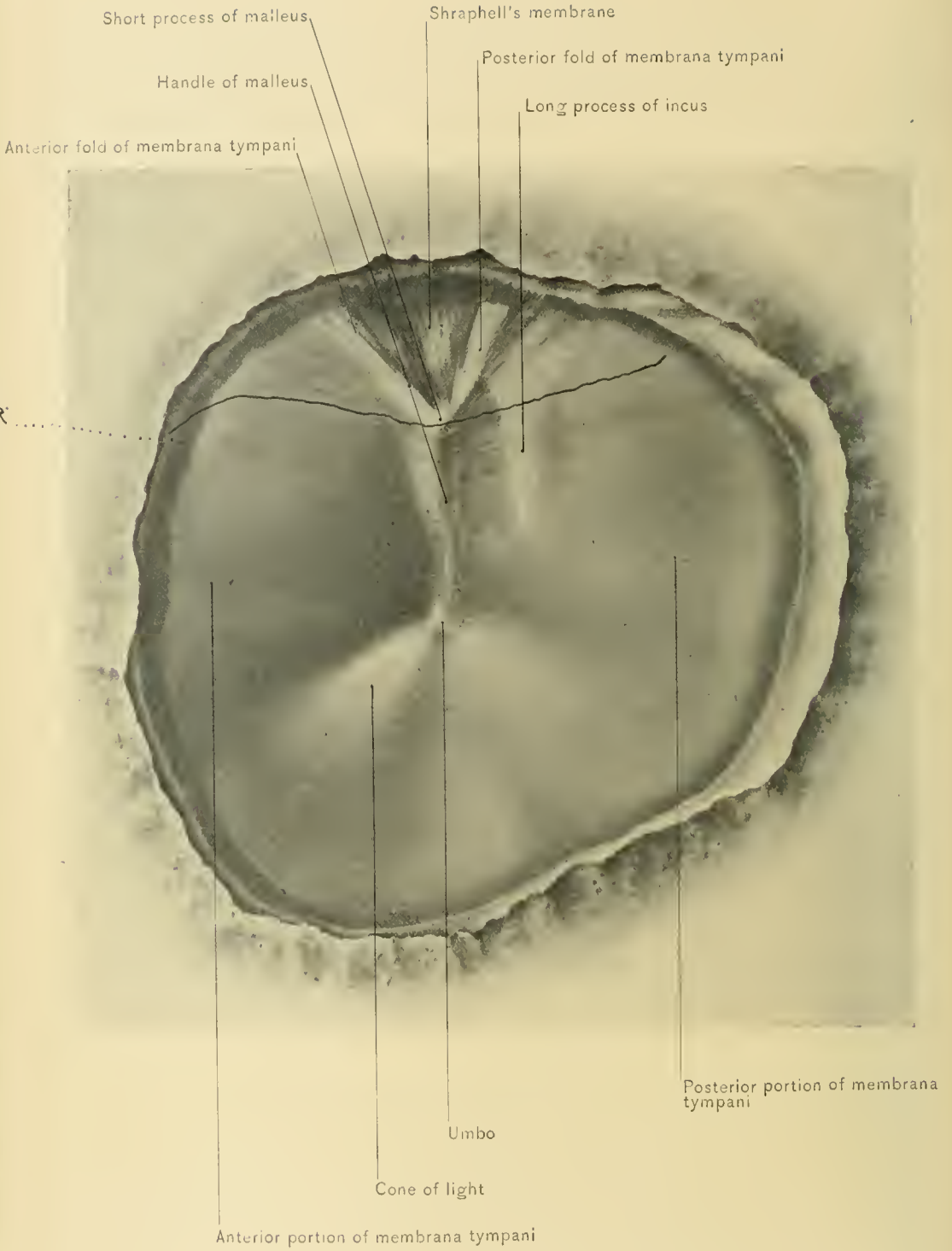
The **Supra-meatal Triangle of MacEwen** is bounded above by the posterior root of the zygoma, which runs nearly horizontally backward; the antero-inferior boundary is formed by the posterior and upper margin of the bony meatus; the posterior boundary is formed by a perpendicular line extending from the most posterior portion of the bony meatus to the posterior root of the zygoma. The apex of this triangular area is directed forward, and the area itself is usually somewhat depressed. Through this triangle the mastoid antrum may be reached

with safety, if the perforation be directed inward and somewhat upward and forward, or parallel with the external auditory meatus. If the mastoid process is opened behind this triangle, the knee of the sigmoid portion of the lateral sinus is in danger of being injured, particularly if the perforation be made directly inward, as that sinus is only from three to six millimeters from the posterior extremity of the mastoid antrum. The posterior root of the zygoma indicates the level of the floor of the cranial cavity; should the operator pierce the bone above this line, the cranial cavity is likely to be opened. As previously stated, the mastoid antrum in the adult is usually from one-half to three-fifths of an inch, or from twelve to fifteen millimeters, from the surface of the bone; for this reason the chisel or gimlet should enter the mastoid antrum at a depth not greater than fifteen millimeters. As the result of long-standing disease, the bone over the mastoid antrum may be thickened and sclerosed. If the inner wall of the antrum is encroached upon, the facial nerve may be injured by the chisel or other instruments used by the operator.

The **Mastoid Cells** vary exceedingly as to number and size. They are absent at birth, and prior to puberty they are few in number. They attain their full development in the young adult, and occupy the greater portion of the mastoid process, opening directly or indirectly into the mastoid antrum. They are lined with muco-periosteum which is continuous with that of the mastoid antrum. Posteriorly they cease abruptly at the occipito-temporal suture. They are separated from the sigmoid portion of the lateral sinus by a thin plate of bone, through which veins pass from these cells to the sinus, affording a ready means of infection and of production of septic thrombosis of the sinus.

The **Outer Wall of the Middle Ear** is formed by the membrana tympani and, to a slight extent, by bone.

The **membrana tympani** is an elliptic or, at times, oval membranous disc, attached to a grooved ridge of bone at the bottom of the external auditory meatus. Its greatest diameter, measured from its posterior and upper portion forward and downward, is ten millimeters in length; the vertical measurement is slightly less; it is one-tenth of a millimeter in thickness. The membrane is situated obliquely, its outer surface being directed outward, downward, and forward. It is directed downward and outward at an angle of about forty-five degrees, and forward and outward at an angle of about ten degrees. In the infant, at birth, this obliquity is greater and the membrane is almost horizontal. Its outer surface is concave, the center being the deepest point of the concavity, for the extremity of the handle of the malleus is here attached, and, as it were, draws the membrane inward. The depressed center is known as the *umbo*. The bony ring to which the tympanic membrane is attached is incomplete above, leaving a notch (*notch of*



EXTERNAL VIEW OF MEMBRANA TYMPANI OF LEFT EAR.

Rivini), which is filled in by a thinner and looser portion of the membrane, known as the *membrana flaccida*, or *Shrapnell's membrane*. The *membrana tympani* consists of three layers: an outer cuticular covering; a middle, fibrous layer; and an inner, mucous lining.

INSPECTION.—When viewed through a speculum during life, the *membrana tympani* is of a pearly gray color, and appears smooth and polished. Extending downward and backward with its apex at the umbo is a *cone of light*, which is of value in the diagnosis of disease of the tympanum and *membrana tympani*. The handle of the malleus and its short process, and, posterior to the handle of the malleus, the long process of the incus, can frequently be seen through the membrane. From the short process of the malleus two folds extend to the margins of the notch of *Rivini*; these are known as the *anterior* and the *posterior fold* of the membrane, and between them is the *membrana flaccida*, so named on account of its laxity. Owing to this laxity perforations of the *membrana flaccida* give rise to but slight loss of hearing. The remainder and major portion of the drum is known as the *membrana tensa*.

Perforation or rupture of the *membrana tympani* is frequently produced by traumatism, as by slender foreign bodies accidentally pushed far into the external auditory canal, or by the escape of pus in otitis media. Perforation of the *membrana flaccida* occurs more commonly when the disease is confined to the attic; perforation of the posterior portion, when the disease is confined to the mastoid antrum; and perforation of the lower portion of the *membrana tensa* is most frequent on account of its low position. Owing to the inelasticity of the membrane, perforations do not gape much. Traumatic perforations heal readily, whereas those associated with suppurative otitis media seldom close. Granulation tissue from the inflamed mucous membrane of the tympanum projecting through the perforation forms *polypoid growths* which conceal the opening, and sometimes hide the tympanic membrane. These growths are associated with copious suppuration.

Paracentesis of the tympanum, or puncture of the tympanic membrane, is frequently practised by the surgeon to relieve tension and allow of the discharge of pus.

The point selected is in the lower or subumbilical portion of the membrane, or wherever the bulging is greatest. Paracentesis of the upper portion of the membrane is attended by danger of injuring the malleus, incus, or chorda tympani nerve, and paracentesis of the lower portion of the membrane must be cautiously performed, for the inner wall of the tympanum is situated only from two millimeters to four millimeters, or from one-twelfth to one-sixth of an inch, internal to the tympanic membrane.

After the *membrana tympani* has been destroyed by ulceration and the malleus and incus have escaped with the pus, a plug of cotton inserted into the tympanum against the stapes will serve as an *artificial membrana tympani*.

BLOOD SUPPLY.—The blood supply of the *membrana tympani* is derived mainly from the tympanic branches of the internal maxillary and internal carotid arteries.

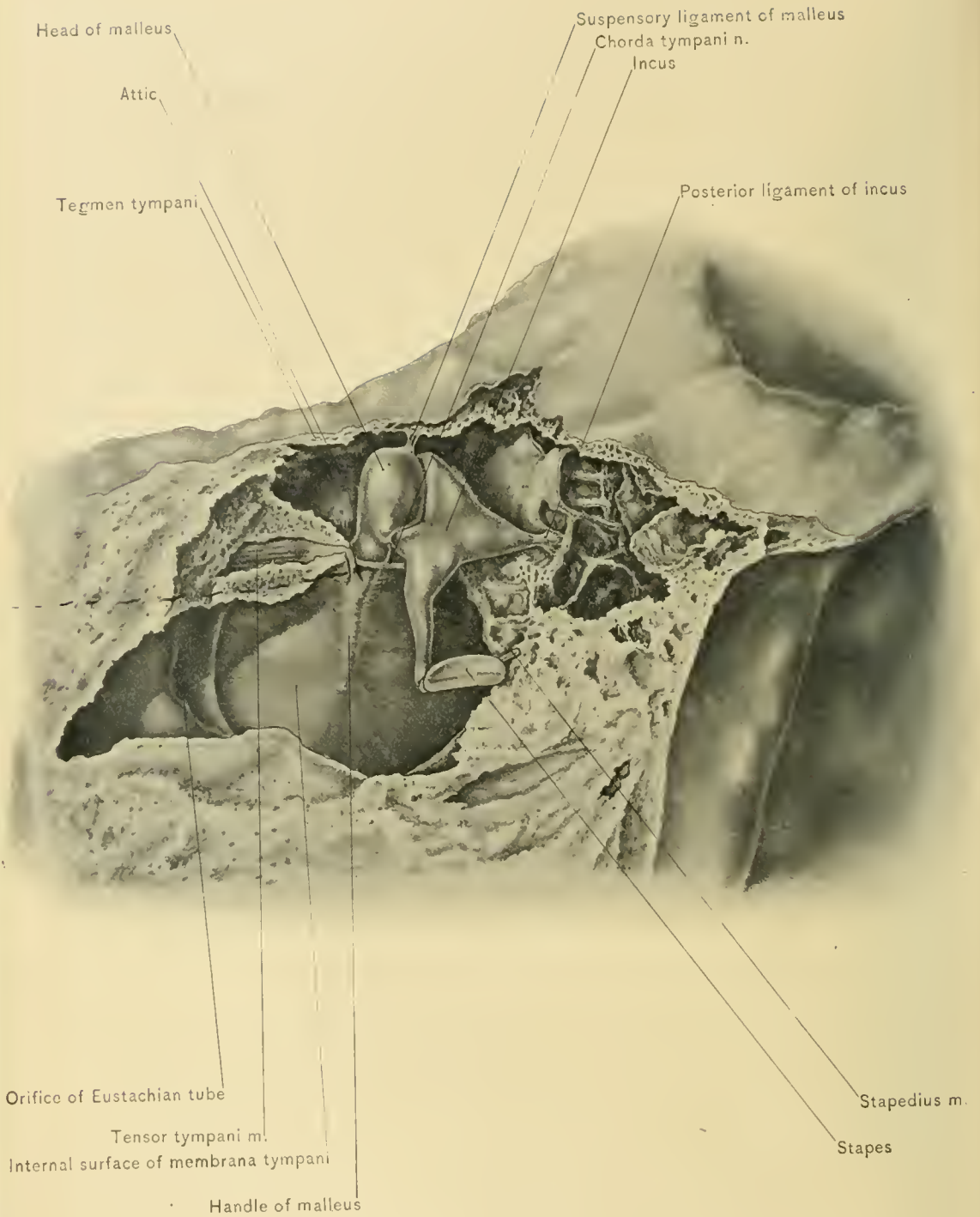
NERVE SUPPLY.—The chief nerve supplying the external surface of the *membrana tympani* is the auriculo-temporal. According to Sappey, Arnold's nerve (the auricular branch of the vagus) supplies the lower portion of this surface of the membrane, and branches from the tympanic plexus supply the inner surface. The membrane is quite sensitive.

The **inner wall of the tympanum** presents several points for examination. A conspicuous rounded elevation, the *promontory* produced by part of the first turn of the cochlea, is seen; on it are faintly marked grooves for the tympanic plexus of nerves. Above the posterior portion of the promontory is a transverse oval foramen,—the *fenestra ovalis*, or oval window,—which leads into the vestibule, and when the ear ossicles are *in situ*, is closed by the base of the stapes. Behind it is the *pyramid*, at the summit of which is an opening for the tendon of the stapedius muscle. Below the promontory is the *fenestra rotunda*, or round window, an opening which leads into the scala tympani of the cochlea, and in the recent state is closed by the *membrana tympani secundaria*. At the junction of the inner wall and roof of the tympanum, above the oval window, is a rounded ridge of bone passing antero-posteriorly; this is produced by the facial canal or aqueductus Fallopii, which lodges the facial nerve. The bony lamina separating this nerve from the cavity of the middle ear is quite thin, especially in children, and in otitis media the facial nerve may become affected by neuritis, leading to paralysis of the muscles of expression upon the corresponding side of the face.

The **mucous membrane of the tympanum** lines the tympanic cavity, and is continuous with the mucous membrane of the Eustachian tube and with that of the mastoid antrum. It forms the inner layer of the tympanic membrane, and is reflected over the ossicles, the tendons which enter the tympanic cavity, and the nerves of the middle ear.

Middle ear disease may be followed by various complications, the most common of which is inflammation of the mastoid antrum and mastoid air cells, resulting in mastoid abscess. As the mucous membrane of the middle ear is directly continuous with that of the mastoid antrum, it will readily be seen how the inflammatory process may extend from the nose to the naso-pharynx, Eustachian tube, tympanum, mastoid antrum, and mastoid cells.

Through carious destruction of the tegmen antri or tegmen tympani or



INTERNAL VIEW OF RIGHT TYMPANUM.

through the perivascular lymphatics and the veins which pierce the tegmen, **extradural abscess, meningitis, thrombosis of the superior petrosal sinus, and cerebral and cerebellar abscess** may result from otitis media and mastoid disease. **Thrombosis of the sigmoid sinus** and consequent septic embolism may occur by extension of the inflammation along the veins from the mastoid antrum, mastoid cells, and tympanum which empty into the sigmoid sinus.

In **otitis media** the pus usually escapes by perforation of the membrana tympani, and may pass out through the Eustachian tube into the pharynx, or through the canal for the tensor tympani muscle. In **mastoid disease** the pus usually escapes through the tympanum and membrana tympani, and may, after destruction of the compact bone on the intracranial surface of the mastoid process, enter the cranial cavity and form an extradural abscess; or it may enter the neck over or under the prevertebral fascia, point on the external surface of the mastoid process, or escape directly into the external auditory meatus.

The **Auditory Ossicles** consist of the malleus, the incus, and the stapes, which form a chain of three small bones that transmit the impulses of sound waves from the membrana tympani to the perilymph and endolymph of the internal ear. The ossicles and the ligaments and tendons attached to them are covered by the mucous membrane of the tympanum.

The **malleus**, or **hammer**, consists of a head, a neck, a handle, or manubrium, the processus brevis, and the processus gracilis. The rounded *head* is situated in the attic, the highest portion of the tympanic cavity, and above the level of the membrana tympani; it is connected with the roof of the cavity by fibrous tissue which forms the so-called *superior ligament of the malleus*. On the posterior aspect of the head of the malleus is a cartilage-covered surface which articulates with the body of the incus. Below the head of the malleus is the *neck*. The *manubrium*, or handle, is connected with the fibrous layer of the tympanic membrane, and is situated between this layer and the mucous lining. The *processus brevis* is a small prominence below the neck, and gives attachment to the tensor tympani muscle. The *processus gracilis* is a long and slender process which passes forward to the Glaserian fissure. In the adult it is often largely represented by fibrous tissue.

The **incus**, or **anvil**, resembles in shape a bicuspid tooth with diverging fangs; it consists of a body and two processes. The *body* presents a concavo-convex articular surface for the head of the malleus; the joint between these bones is surrounded by a capsular ligament and lined by a synovial membrane. The *short process* passes backward, and is connected to the posterior wall of the tympanum by fibrous tissue. The *long process* descends almost parallel with the manubrium of the malleus, but posterior and internal to it. It terminates in a

small, knobbed projection, the so-called *os orbiculare*, which articulates with the head of the stapes.

The **stapes**, or **stirrup**, consists of a head, a neck, two crura or branches, and a foot-piece or base. The *head* articulates with the *os orbiculare* of the incus. This joint has a capsular ligament, and is lined by a synovial membrane. The two *crura* diverge as they leave the neck, are grooved on their concave sides, and are attached to the *foot-piece* or *base*, which fits into the oval window. The base of the stapes is united to the margin of that opening by fibrous tissue.

In otitis media the ligaments associated with the ossicles become indurated and stiffened; through loss of mobility the chain of bones can not transmit impulses to the internal ear, and deafness supervenes. In such cases hearing may be improved by removal of the perforated *membrana tympani*, the malleus and incus, or by massage administered by means of sound. Caries of the malleus and incus not infrequently occurs in otitis media, and they are occasionally discharged with the pus in that disease.

The **Ligaments** situated in the tympanum are associated with the ossicles. They consist of the superior, the anterior, the external, and the internal ligaments of the malleus, the ligament of the incus, and the capsular ligaments.

The **superior** or **suspensory ligament of the malleus** is a slender, fibrous band which is attached to the outer part of the roof of the tympanum and to the highest part of the head of the malleus. It limits downward and outward movement of the head of the malleus and inward rotation of the manubrium of that bone.

The **anterior ligament of the malleus** is a strong, fibrous band which surrounds the *processus gracilis* of the malleus. It is attached to the anterior wall of the tympanum around the Glaserian fissure, and to the anterior aspect of the head and neck of the malleus. It limits movement of any amplitude except in a forward direction. It occasionally contains muscular fibers, and has been described as the *laxator tympani muscle*.

The **external ligament of the malleus** is fan-shaped. Its apex is attached to the neck of the malleus, and its base to the margins of the notch of Rivini. It limits outward rotation of the handle of the malleus.

The **internal ligament of the malleus** is the sheath of the tendon of the tensor tympani muscle, and extends from the tip of the *processus cochleariformis* to the margins of the insertion of the tensor tympani tendon, which is near the root of the handle of the malleus on its inner surface. It limits outward movement of the handle of the malleus.

The **ligament of the incus** is a short, thick band which attaches the extremity of the short process of the incus to the posterior wall of the tympanum near the orifice of the mastoid antrum.

The **capsular ligaments** surround the articulations between the malleus and incus, and the incus and stapes.

The **Muscles of the Tympanum** are the stapedius and the tensor tympani.

The **stapedius muscle** takes its origin from the interior of the pyramid; its tendon passes through an aperture in the apex of the pyramid, and is inserted into the neck of the stapes.

NERVE SUPPLY.—The nerve supply of the stapedius muscle is derived from a branch of the facial nerve.

ACTION.—It draws the head of the stapes backward, thus pressing the posterior part of the base of that bone against the border of the oval window, and regulating the pressure in the vestibular contents or perilymph and endolymph.

The **tensor tympani muscle** is larger than the stapedius muscle, and is situated in a bony canal which lies parallel with the Eustachian tube. It arises from the cartilage of the Eustachian tube, the adjacent surface of the great wing of the sphenoid bone, and the walls of the canal in which it lies. The tendon of the muscle winds around the end of the processus cochleariformis, passes outward in the tympanum, and is inserted into the handle of the malleus near its root.

NERVE SUPPLY.—The nerve supply of the tensor tympani muscle is derived through a branch from the otic ganglion, from the motor root of the trifacial or fifth cranial nerve.

ACTION.—It draws the malleus inward, thus tightening and steadying the membrana tympani and compressing the perilymph of the internal ear. Abnormal action of this muscle is one of the causes of snapping, buzzing, or ringing sounds in the ears.

BLOOD SUPPLY OF THE MIDDLE EAR.—The blood supply of the middle ear is derived from the tympanic branches of the internal maxillary and internal carotid arteries, stylo-mastoid branch of the posterior auricular artery, the petrosal branch of the middle meningeal artery, and a branch of the ascending pharyngeal artery which passes up the Eustachian tube.

The *veins of the middle ear* empty into the temporo-maxillary vein, the superior petrosal sinus, the lateral sinus, the internal jugular vein, and the pharyngeal veins; numerous small venous channels pass through the tegmen tympani, communicating with the veins of the dura mater. These veins afford paths by which inflammatory processes may extend from the tympanum to the venous sinuses, internal jugular vein, meninges, and brain.

The **Lymphatics of the Middle Ear** terminate in the posterior auricular and parotid lymphatic glands.

NERVE SUPPLY OF THE TYMPANUM.—The nerve supply of the tympanum is

derived from numerous sources, for there are several nerves which enter the tympanic plexus of nerves.

The relation of the facial nerve to the tympanum has already been considered.

The **chorda tympani nerve**, a branch of the facial nerve, enters the tympanum through an opening in the posterior wall (*iter chordæ posterioris*), passes through the outer portion of the middle ear near the upper part of the tympanic membrane, crosses the handle of the malleus, and then enters a small, bony canal (*iter chordæ anterioris*) near the Glaserian fissure. In the middle ear it is covered by the tympanic mucous membrane. Involvement of this nerve in otitis media may lead to abnormalities of the sense of taste on one side of the anterior portion of the tongue.

The **tympanic plexus of nerves** ramifies in the grooves on the promontory and inner wall of the tympanum, and supplies the mucous membrane of the tympanum. It is formed by the tympanic branch of the glosso-pharyngeal nerve, a branch of the great superficial petrosal nerve, a branch of the small superficial petrosal nerve, and the small deep petrosal nerve.

The *tympanic branch of the glosso-pharyngeal nerve* arises from the petrous ganglion of the glosso-pharyngeal nerve, and passes into the tympanum through a foramen in the floor near the inner wall of the tympanum.

The *branch of the great superficial petrosal nerve*, which is derived from the facial nerve, passes into the tympanum through a foramen in the inner wall of that cavity just anterior to the oval window.

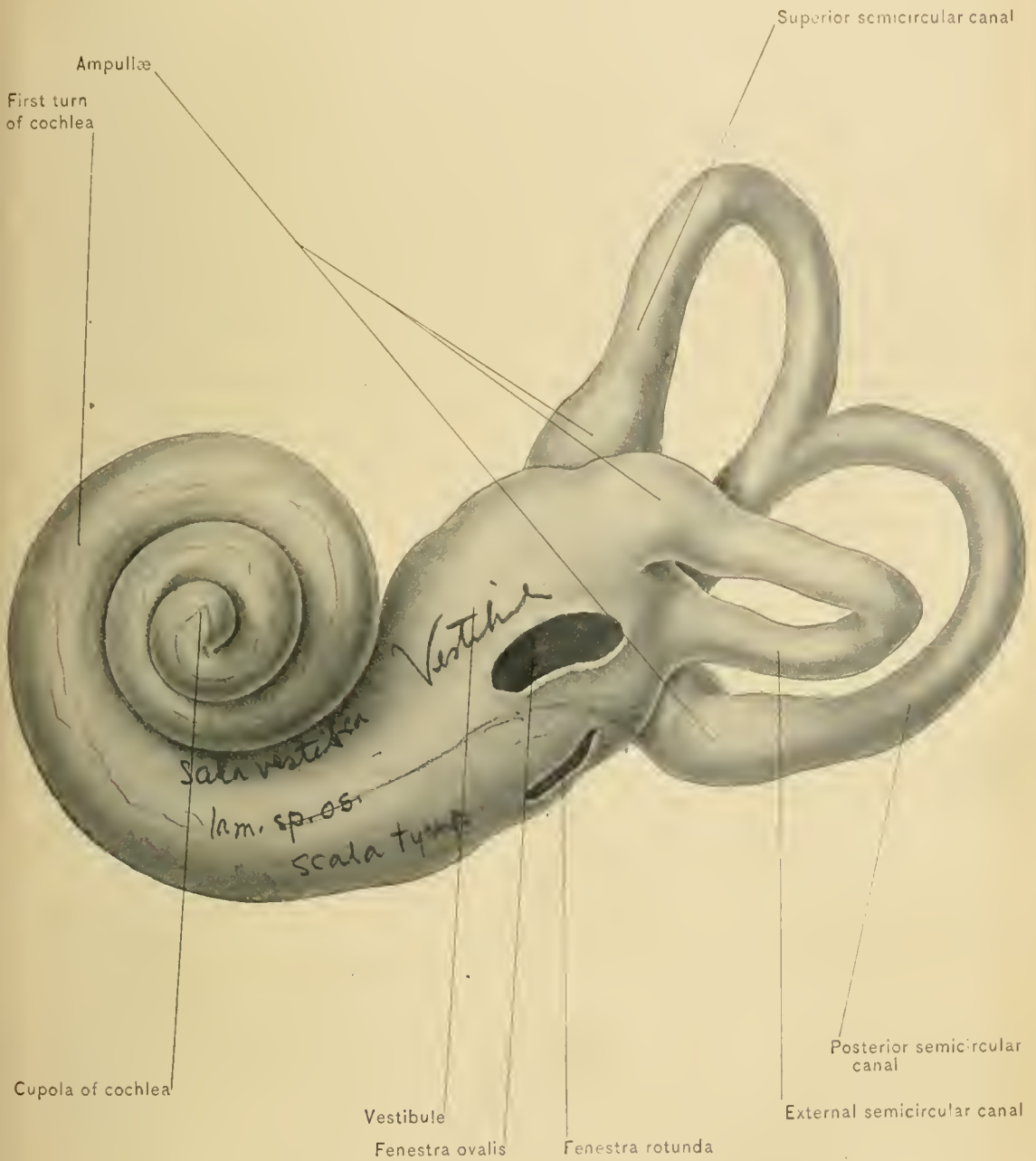
The *branch of the small superficial petrosal nerve*, which is also derived from the facial nerve, enters the tympanum near the canal for the tensor tympani muscle.

The *small deep petrosal nerve*, or tympanic branch of the carotid plexus of the sympathetic nerve, enters the tympanum through the carotico-tympanic canal.

The motor nerves to the tensor tympani and stapedius muscles have already been described.

Otitis media and dentition.—Acute otitis media is frequently associated with eruption of the teeth, and is also believed to result from reflected irritation produced by carious or by artificial teeth. This complication of dentition may be explained by the connection existing between the nerves which supply the tympanum and those supplying the teeth. The great superficial petrosal nerve communicates with the tympanic plexus of nerves and, through the Vidian nerve, joins Meckel's ganglion, which is associated with the superior maxillary nerve. The nerves to the upper teeth are derived from the superior maxillary nerve. The small superficial petrosal nerve communicates with the tympanic plexus

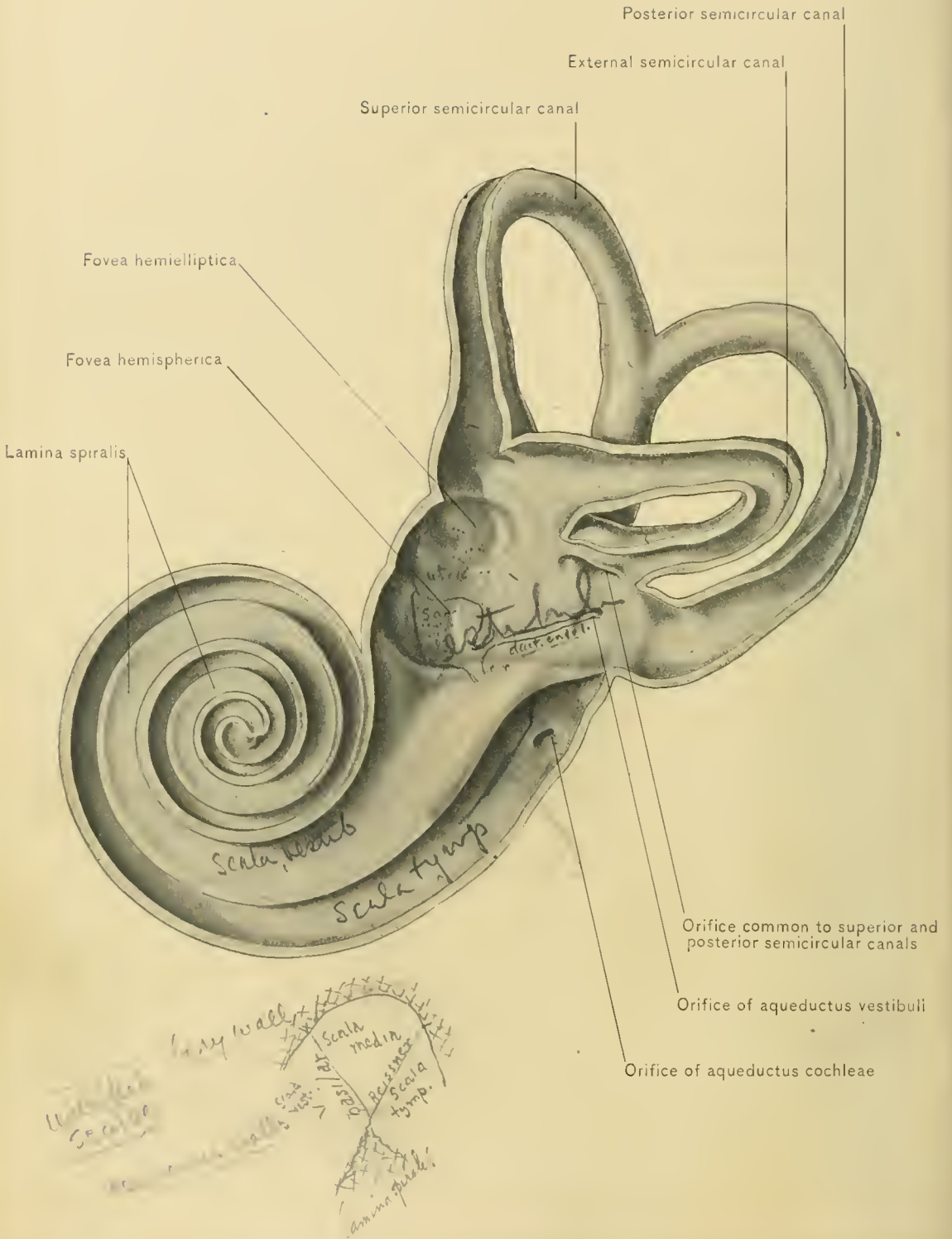
See Fig. p. 418
Fig. p. 422



EXTERNAL VIEW OF BONY LABYRINTH, WITH COCHLEA AND SEMICIRCULAR CANALS.

Lath.





INTERIOR OF OSSEOUS LABYRINTH OF LEFT INTERNAL EAR.

of nerves, and joins the otic ganglion, which is associated with the inferior maxillary nerve. The inferior dental nerve, which supplies the lower teeth, is a branch of the inferior maxillary nerve.

THE INTERNAL EAR.

The **Internal Ear** or **Labyrinth**.—The most important portion of the organ of hearing consists of a series of complex cavities—the bony labyrinth, within which is the membranous labyrinth.

The **Bony Labyrinth** is made up of three intercommunicating cavities,—the vestibule, the cochlea, and the semicircular canals,—which are lined by a delicate periosteum.

The **membranous labyrinth** is a cast of the bony labyrinth, but is considerably smaller than the latter; between the two there is a space lined with endothelium and containing a fluid called the **perilymph**. The parts of the membranous labyrinth are the utricle, the saccule, the membranous semicircular canals, and the duct or canal of the cochlea, all of which are lined with epithelium and contain the **endolymph**.

The **vestibule**, situated between the cochlea and semicircular canals, is an ovoid bony cavity, the antero-posterior diameter of which is about five millimeters, or one-fifth of an inch. On the outer or lateral wall is the *oval window* in communication with the tympanum; as previously stated, this is closed in the natural state by the base of the stapes and the periosteal lining of the vestibule. At the anterior portion of the inner or median wall is a round depression, the *fovea hemispherica*, the bottom of which is pierced by numerous small openings for the transmission of the vestibular branch of the auditory nerve. Posterior to the fovea hemispherica is a vertical crest, the *crista vestibuli*. In the posterior portion of the inner wall is the small opening of the *aqueductus vestibuli*, a canal which extends to the posterior surface of the petrous portion of the temporal bone, and lodges the ductus endolymphaticus and a minute vein. At the lower and anterior portion of the vestibule is the comparatively large opening leading to the *scala vestibuli* of the cochlea. In the posterior portion of the vestibule are the five round openings of the semicircular canals. On the roof of the vestibule is an oval fossa, the *fovea hemielliptica*.

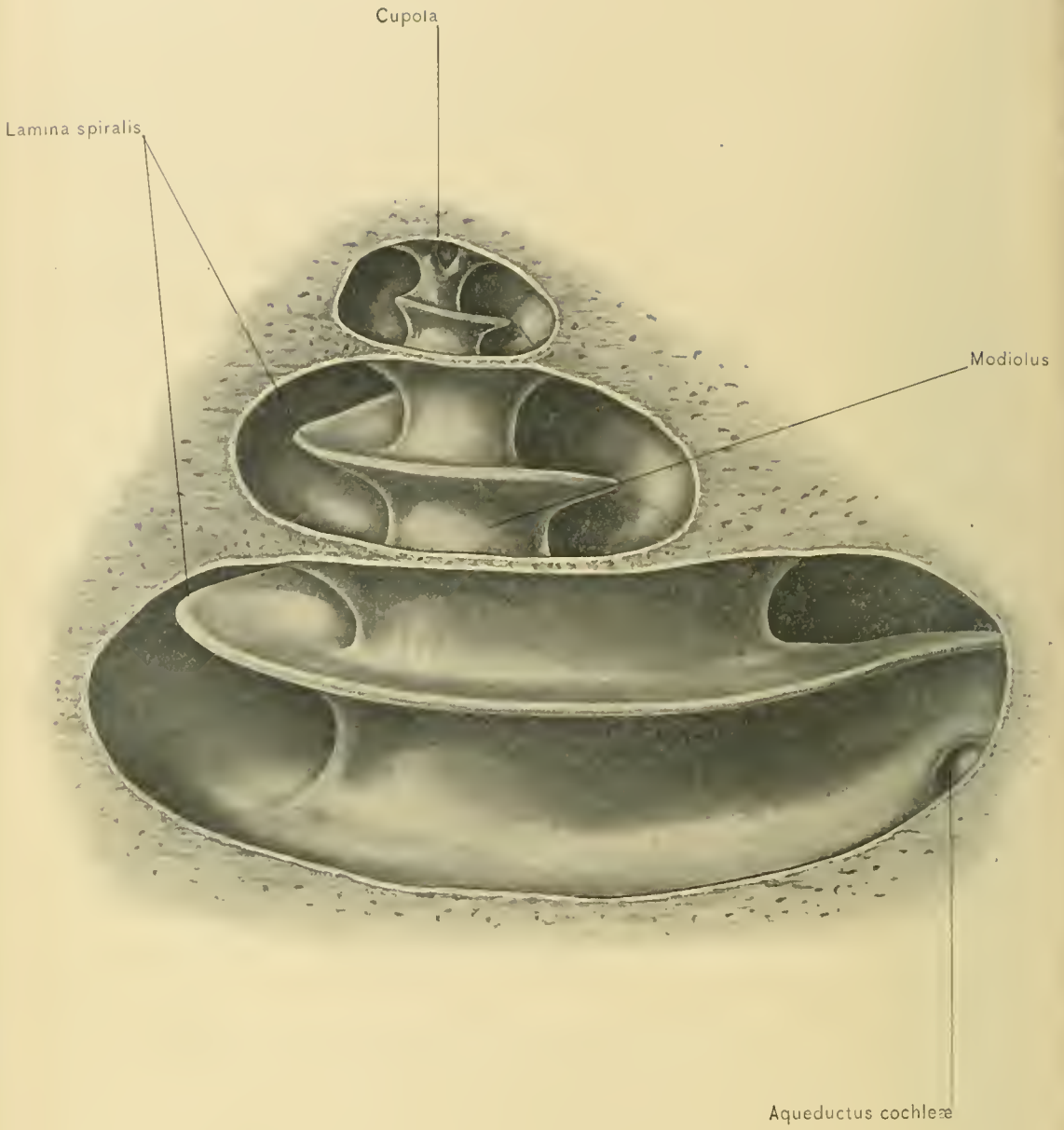
The **semicircular canals**, three bony tubes about one-twentieth of an inch, or one and one-fourth millimeters, in diameter, are situated behind the vestibule. The superior semicircular canal lies nearly in the sagittal plane of the body, the posterior, in the coronal plane, and the external, in a transverse plane; consequently they occupy positions about at right angles to one another. Each forms

more than a semicircle, and upon one extremity of each canal is an enlargement, the *ampulla*. They open by five orifices into the vestibule, as the non-ampullated extremities of the superior and posterior canals join, and have a common orifice. From the positions of these canals in the sagittal, coronal, and transverse planes, it may be inferred that they are in some way associated with the maintenance of equilibrium. The occurrence of vertigo from increased pressure in the perilymph and endolymph increases the probability of this theory.

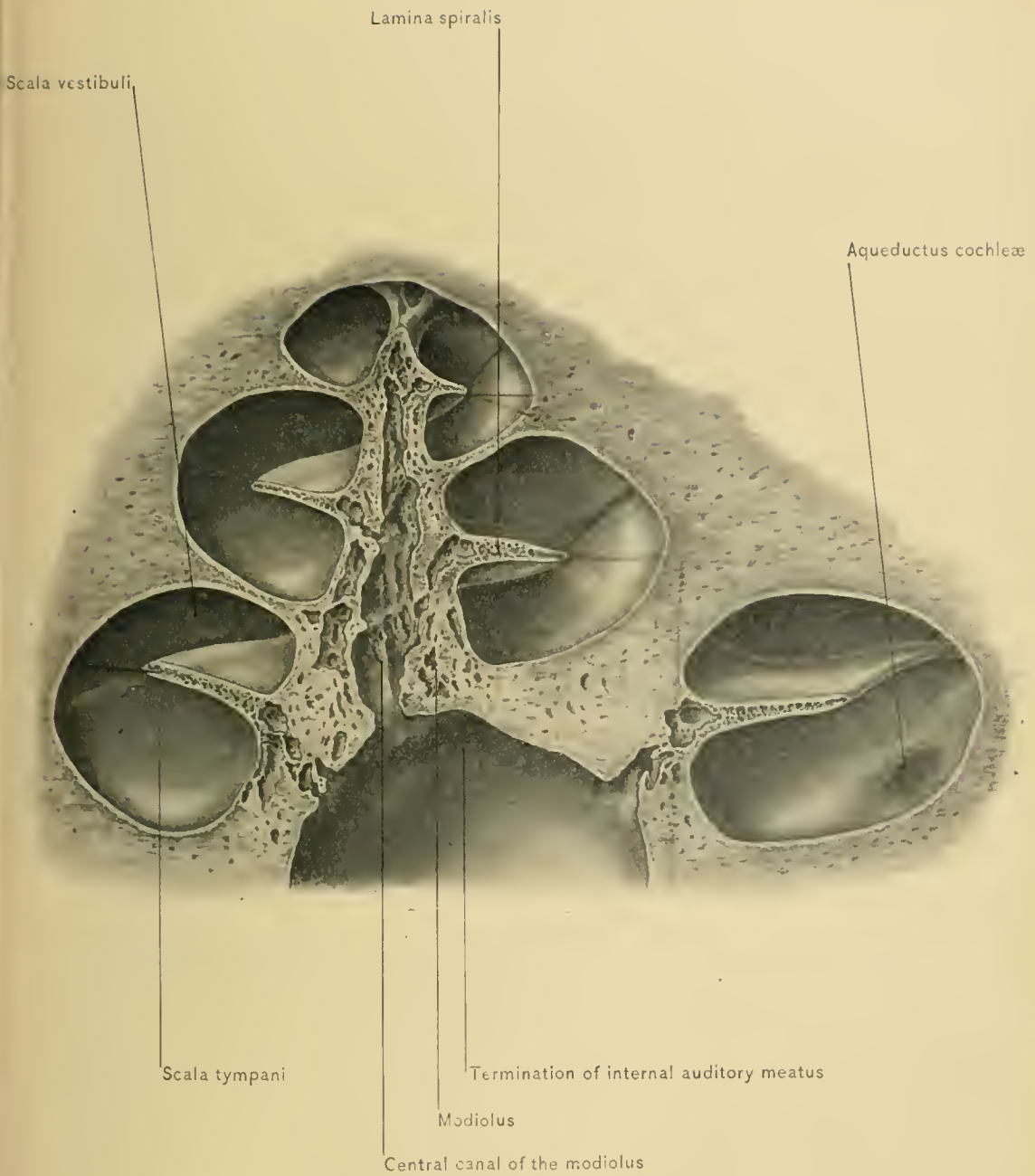
The **cochlea** is situated anterior to the vestibule. When isolated from the investing bony substance it appears as a cone, the apex of which looks outward and somewhat downward and forward. The *base* is perforated by numerous foramina for branches of the auditory nerve, and is directed toward the meatus auditorius internus. The base is nearly two-fifths of an inch, or ten millimeters, in diameter, and the height of the cone is about one-fourth of an inch, or six millimeters. The cochlea consists of a nearly horizontal central axis, the *modiolus* or *columnella*, around which is wound a spiral tube, in a manner similar to the spirals in certain snail shells. The *modiolus* has numerous canals in its interior for branches of the auditory nerve; the largest is the *canalis centralis modioli*. The **spiral canal** diminishes in diameter as it approaches the apex of the cochlea, makes two and one-half turns around the axis, and terminates in a closed extremity, the *cupola*. Projecting into the spiral canal from the modiolus is the bony *lamina spiralis*, which does not reach the outer wall of the cochlea. From the free border of the lamina spiralis or near it two membranes extend, in the natural state, the *membrana basilaris* and the *membrane of Reissner*. These two membranes are connected with the outer wall of the cochlea and inclose between them the *cochlear duct*, or *scala media*; they are, in fact, two parts of the membranous cochlea. By the bony lamina spiralis and the two membranes just alluded to the spiral canal is divided into three parts: the *scala tympani* and the *scala vestibuli*, between which is the *scala media*.

The *scala tympani* is on the basal side of the lamina spiralis, and opens into the tympanum at the fenestra rotunda, though in the natural state this opening is closed by the *membrana tympani secundaria*. The *scala vestibuli* is on the opposite side of the lamina spiralis, and opens into the vestibule. These two scales communicate with each other by an opening at the summit of the cochlea, known as the *helicotrema*; they contain the perilymph. The *perilymph* is in communication with the subarachnoid space of the brain along the sheath of the auditory nerve.

The **Membranous Labyrinth**, the earliest formed and therefore the oldest part of the organ of hearing, lies within the osseous labyrinth, from which it is separated in most places by the perilymph. It contains the **endolymph** and the terminations of the auditory nerve, and it is lined by epithelium.



INTERIOR OF OSSEOUS PORTION OF COCHLEA.



SECTION OF OSSEOUS PORTION OF COCHLEA.



In the vestibule are found two vesicles, the **utricle** and the **sacculæ**, the former lying partly in the fovea hemielliptica, and the latter in the fovea hemispherica. The membranous semicircular canals open into the utricle by ~~five~~^{five} orifices. Filaments of the vestibular branch of the auditory nerve are distributed to a thickened portion of the walls of the utricle which contains calcareous masses, the **otoliths**. The sacculæ, which is smaller than the utricle, receives branches of the auditory nerve through the perforations in the fovea hemispherica; as in the utricle, these nerves are distributed to a thickened portion of the wall of the cavity, which is covered with otoliths. Passing from the sacculæ along the aqueductus vestibuli is a slender tube, the **ductus endolymphaticus**, which expands into the **saccus endolymphaticus**, a blind pouch which lies on the posterior surface of the petrous portion of the temporal bone beneath the dura mater; this canal is joined by a small tube from the utricle, and thus the two portions of the membranous vestibule are brought into direct communication. The sacculæ communicates with the scala media ^{of the} membranous labyrinth of the cochlea by means of a short tube, the **canalis reuniens**.

The **membranous semicircular canals** are about one-fourth the diameter of the osseous canals in which they lie; their extremities are ampullated.

The **membranous cochlea, cochlear duct, or scala media**, lies between the scala tympani and scala vestibuli, as already stated. It follows the windings of the spiral tube of the cochlea, and ends blindly at both extremities, though near its basal end it communicates with the sacculæ by the canalis reuniens. Within the scala media is found the **organ of Corti**, a complex arrangement of modified epithelial cells to which the final ramifications of the cochlear branch of the auditory nerve are distributed. The description of the more minute structure of the internal ear is not within the province of this book, and for these details the reader is referred to works on systematic anatomy and histology.

Aural vertigo is indicated by ringing in the ears or head, dizziness, reeling, and nausea and vomiting in succession. It is produced by abnormal increase of pressure in the membranous labyrinth. Cerumen or instillation of cold liquids into the external auditory meatus may produce this symptom, and it may result from abnormal conditions in the middle ear and reflected irritation in gastric catarrh. Aural vertigo has been termed **Menière's disease**.

BLOOD SUPPLY.—The blood supply of the internal ear is derived from the auditory artery, a branch of the basilar, which enters the internal auditory meatus with the auditory nerve, and divides into branches for the cochlea and vestibule.

The *veins* which drain the internal ear are the vena aqueductus cochlea and vena aqueductus vestibuli. The vena aqueductus cochlea receives the veins of the

cochlea, passes through the aqueductus cochleæ, and empties into the internal jugular vein. The vena aqueductus vestibuli receives the veins from the vestibule and semicircular canals, and empties into the superior petrosal sinus.

The **Lymphatics of the Internal Ear** terminate in the tympanic and intracranial lymphatic vessels.

The **Auditory Nerve** is the nerve of the special sense of hearing. In the internal auditory meatus it divides into two branches, the cochlear and the vestibular; the former is distributed to the cochlea, and the latter to the walls of the membranous vestibule and ampullæ of the semicircular canals.

THE MEMBRANES AND VESSELS OF THE BRAIN.

The dura mater, the meningeal vessels, the sinuses of the dura mater, and the mode of exit of the cranial nerves from the cranial cavity are described in volume I, pages 568 to 599. We now resume the study of the brain, the dissection of which has been facilitated by one of the processes for preserving and hardening that organ.

THE ARACHNOID.

The **Arachnoid**, the second of the three membranes of the brain, is intermediate in position between the dura mater and the pia mater. It envelops the brain, and, like the dura mater, sends processes into the longitudinal and transverse fissures, between the hemispheres of the cerebellum, and, to a slight extent, into the fissure of Sylvius. It also surrounds the nerves, forming tubular sheaths for them as far as their points of exit from the skull. Unlike the pia mater, it does not dip into the sulci or fissures between the convolutions, but passes directly from one convolution to the other, bridging over the sulci. It forms a loose investment for the brain, and is continued downward over the spinal cord. Being a serous membrane, it presents to the naked eye a smooth, polished surface. It is connected by delicate connective tissue with both the dura mater and pia mater, but much more intimately with the latter.

The connection between the arachnoid and the pia mater makes the independent removal of the arachnoid very difficult. The arachnoid and pia mater



DIAGRAM OF MEMBRANOUS LABYRINTH.

W. P. King

can be separated, however, by inflating the subarachnoid space with air by means of a blowpipe.

The Subdural Space.—The arachnoid was formerly described as consisting of two layers—a parietal layer, lining the inner surface of the dura mater, and a visceral layer, reflected over the brain; in this respect it was said to resemble serous membranes elsewhere. It is now regarded as consisting of but one layer. The space between the dura mater and the arachnoid is known as the *subdural space*, and contains a small amount of fluid; this space was formerly styled the cavity of the arachnoid; it does not communicate with the subarachnoid space or with the ventricles.

The Subarachnoid Space.—The space between the arachnoid and the pia mater is known as the subarachnoid space; it is most pronounced at the base of the brain. Here the arachnoid membrane is thicker than elsewhere, and bridges over the interval between the temporo-sphenoid lobes and the space between the hemispheres of the cerebellum, partially occupied by the medulla oblongata. By the intervention of the pons this general subarachnoid space is subdivided into the *anterior* and the *posterior space*. The posterior space communicates with the subarachnoid space of the spinal cord and with the fourth ventricle of the brain through a small opening in the roof of the latter called the *foramen of Magendie*, and through two other apertures—the *foramina of Key and Retzius*—which are located at each lateral recess of the fourth ventricle. This space contains the cerebro-spinal fluid; because of this fact the brain may be said to lie on a water-bed. Projecting into this space are seen the larger blood-vessels on their way toward the brain; the lymphatics of the brain and spinal cord empty into this space, which is in communication with the perilymph of the internal ear and with the lymphatics of the nose.

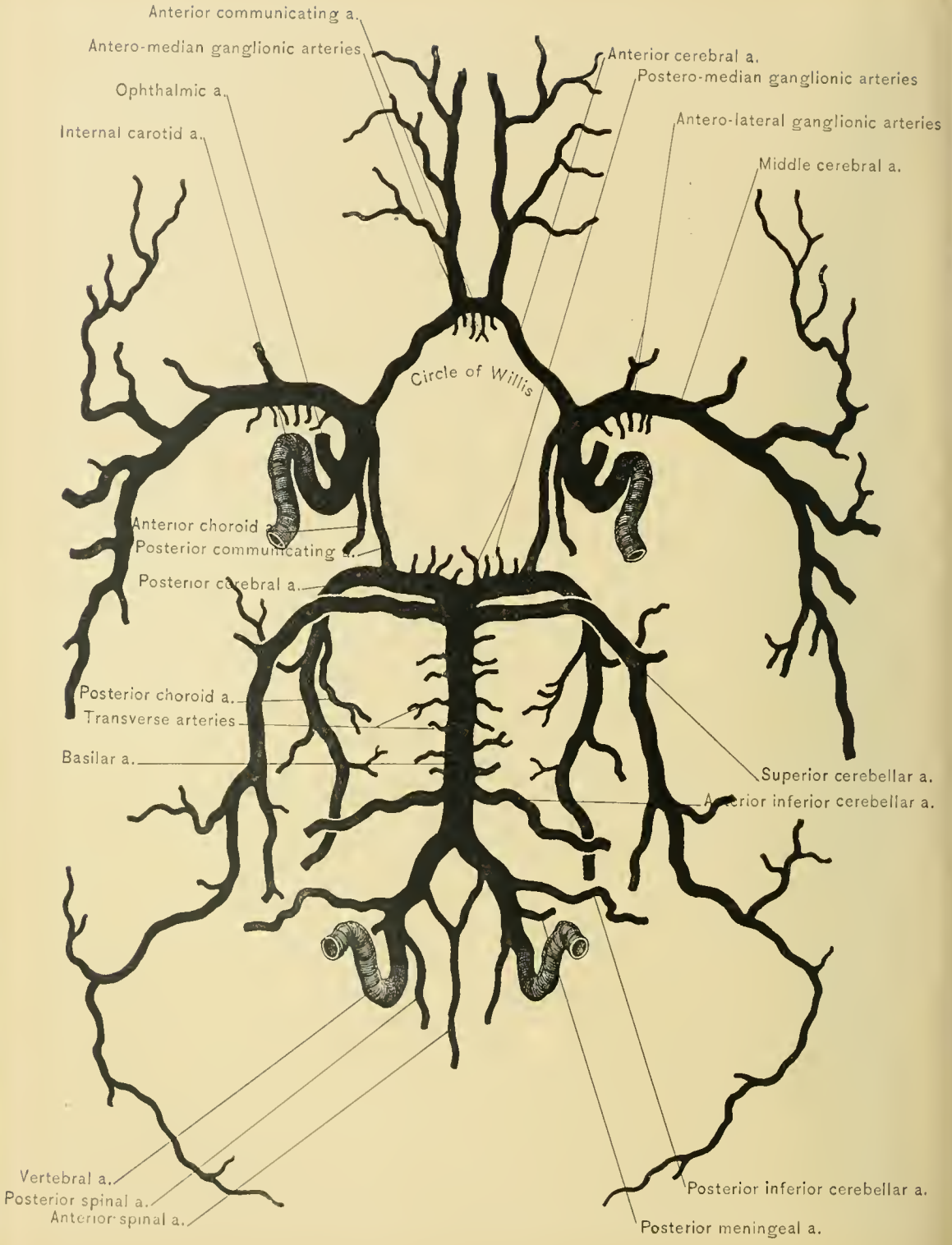
Subarachnoid Cisterns is the name given to the more capacious portions of the subarachnoid space, the largest being the *cisterna magna*, situated between the adjacent surfaces of the medulla oblongata and cerebellum. The cisterna magna is the upward continuation of the posterior portion of the spinal subarachnoid space. The anterior portion of the spinal subarachnoid space is continued upon the anterior surface of the medulla oblongata and pons as the *cisterna pontis*, and communicates freely around the medullo-pontine furrow, or *suleus*, with the cisterna magna, which is situated above and behind the medulla oblongata. The *cisterna basalis* is that part of the subarachnoid space situated between the tips of the temporo-sphenoid lobes and the crura cerebri, and in front of the pons; into it project the circle of Willis and the vessels connected with this circle. Laterally, the cisterna basalis extends into the Sylvian fissures; while anteriorly it extends into a minor space in front of the optic chiasm, and thence further

forward into the great longitudinal fissure. Another large space is found above the corpus callosum; in the pia mater at the bottom of this space are the anterior cerebral arteries. Between the superior vermiform process of the cerebellum and the corpora quadrigemina is an additional space, which contains the veins of Galen. These spaces communicate very freely with one another, and with the fourth ventricle, as stated.

The **Cerebro-spinal Fluid** is a serous fluid, but, unlike ordinary serum, it is not coagulable. This fluid assists in protecting the brain and spinal cord from violent shocks and vibrations. It is secreted by the cells of the ependyma over the fringe-like, vascular processes of the choroid plexus, and slightly by the cells of the arachnoid. However, it is chiefly derived from the choroid plexuses of the lateral ventricles, and to a less extent from the choroid plexuses of the third and fourth ventricles. The fluid passes from the lateral ventricles to the third ventricle through the foramina of Monro, from the third to the fourth ventricle through the aqueduct of Sylvius, and from the fourth ventricle through the foramina of Magendie, Key, and Retzius, to the subarachnoid space of the brain and spinal cord; some of the cerebro-spinal fluid passes directly from the fourth ventricle to the central canal of the spinal cord. This constitutes the course through which the cerebro-spinal fluid circulates, and equalizes the intra-cranio-spinal pressure. By exudation of plastic lymph at the base of the brain, meningitis, especially the tubercular variety, may cause obstruction of the foramina of Magendie, Key, and Retzius, and produce dropsy or hydrocele of the ventricles (*internal hydrocephalus*); hence, tapping of the lateral ventricles, which is sometimes practised in these cases, can give but temporary relief. Aspiration of the subarachnoid space through the anterior fontanel or of the spinal subarachnoid space, for hydrocephalus, is followed by a similar result. The sudden removal of a large quantity of the cerebro-spinal fluid, either by tapping the lateral ventricles or by aspirating through the anterior fontanel, is not without its dangers, and has been followed by severe convulsions. The normal quantity of intra-cranial lymph varies in amount from two drams to two ounces (H. Allen).

The cerebro-spinal fluid is supposed to escape from the subarachnoid space of the brain and spinal cord by way of the prolongations of the arachnoid along the cranial and spinal nerves; these extensions of the subarachnoid space are in communication with the lymphatic vessels in the sheaths of those nerves, and in this manner the fluid reaches the general lymphatic system of the body. It is also supposed that some of the cerebro-spinal fluid escapes by way of the Pacchionian bodies directly into the sinuses of the dura mater.

Choked Disc.—In tubercular or other forms of inflammation of the membranes at the base of the brain with deposit of lymph, or in case of tumor at the



CIRCLE OF WILLIS AND ARTERIES OF BRAIN.

base making pressure, the sheath of the optic nerve becomes distended, causing a congestion of the veins of the optic disc (choked disc), an important diagnostic sign. Pressure, however, does not suffice to explain all cases of "choked disc"; in many cases there is distinct inflammation of the optic papilla, so that the term papillitis would be preferable.

The **Lymphatics** of the brain open into the subarachnoid space.

The **Pacchionian Bodies** are enlargements of the normal villi of the arachnoid; they project from the surface of that membrane, and may perforate the overlying dura mater and cause absorption of the bone in their vicinity.

DISSECTION.—The next step in the dissection consists in removing the arachnoid from the base of the brain. The arteries entering the cranial cavity to supply the brain and the formation of the arterial circle of Willis are then to be carefully examined.

THE ARTERIES OF THE BRAIN.

The **Circle of Willis**, which lies in the pia mater and projects into the subarachnoid space, is formed by branches of the internal carotid and basilar arteries. It forms a heptagonal figure, although it is usually not exactly symmetric. This arrangement serves to equalize the flow of blood derived from the two internal carotid arteries and the basilar artery. Without this or some similar arrangement ligation of the common carotid, internal carotid, or vertebral artery would probably always result in softening of the brain. This circle is formed by the *two posterior cerebral arteries*, which are the terminal divisions of the basilar, the *two internal carotid arteries*, the *two posterior communicating branches* of the internal carotid arteries, which connect the latter with the posterior cerebral arteries, the *two anterior cerebral arteries* (branches of the internal carotid arteries), and the *anterior communicating artery*, a transverse branch which connects the anterior cerebral arteries. This circle is in relation with the several structures which are situated in the interpeduncular space, and form the floor of the third ventricle.

The arteries which enter the cranial cavity for the supply of the brain are the two internal carotid and the two vertebral.

The **Internal Carotid Artery**, one of the two terminal branches of the common carotid, enters the cranial cavity by way of the carotid canal, pierces the cartilage which fills the middle lacerated foramen, and ascends by the side of the body of the sphenoid bone along the inner wall of the cavernous sinus. Upon the inner aspect of the anterior clinoid process it pierces the dura mater, gives off the ophthalmic artery, and passes between the optic and oculo-motor nerves. Having reached the anterior perforated space at the inner extremity of the

fissure of Sylvius, it gives off the posterior communicating and the anterior choroid arteries, and divides into the anterior and middle cerebral arteries.

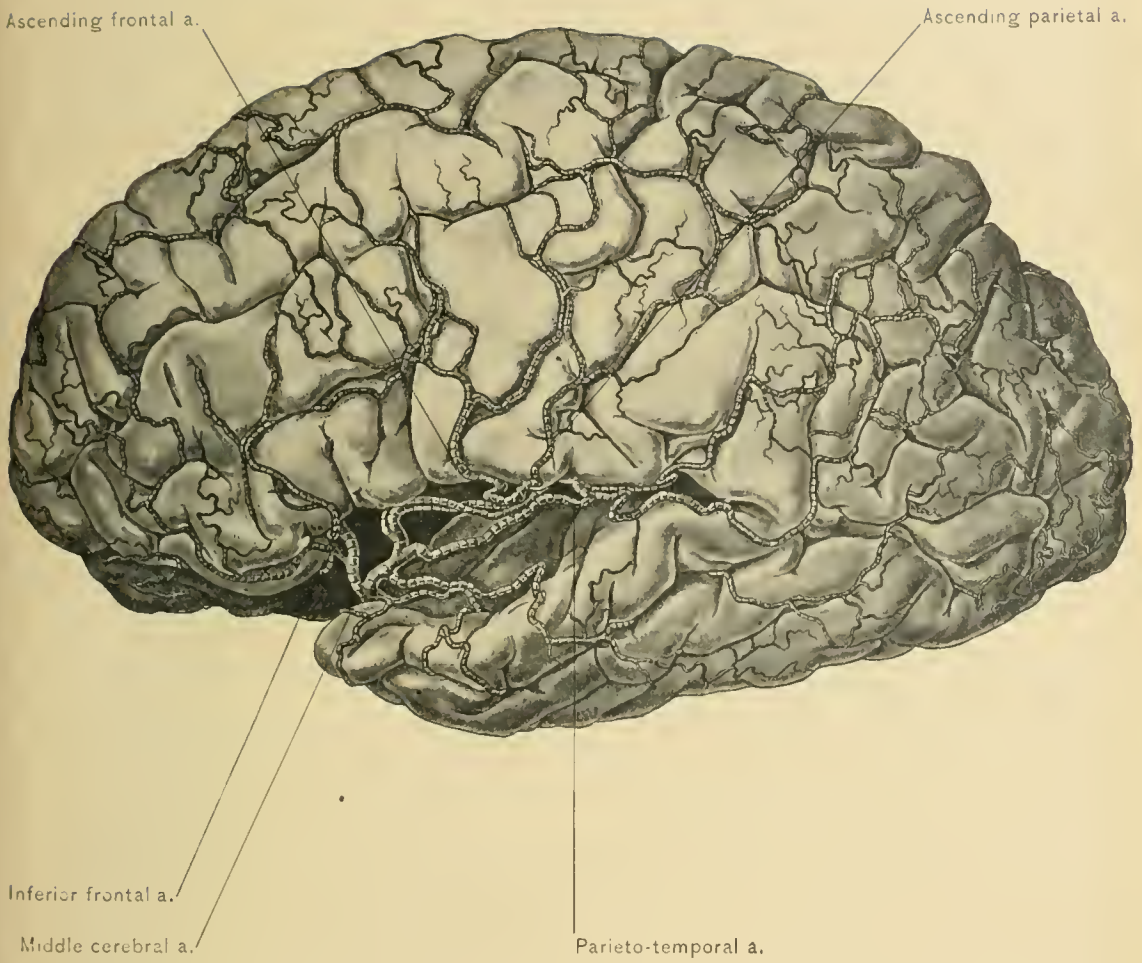
The **Anterior Cerebral Artery** runs forward and inward across the anterior perforated space and the lamina cinerea, and between the optic and olfactory nerves, to reach the longitudinal fissure. Here it is joined to the anterior cerebral artery of the opposite side by a transverse branch, the anterior communicating artery. It now curves around the genu of the corpus callosum, and runs backward along the upper surface of the corpus callosum and at the bottom of the longitudinal fissure of the cerebrum as far as the splenium of the corpus callosum, where it anastomoses with the posterior cerebral artery.

At its commencement the anterior cerebral artery gives off a few antero-median branches to the anterior extremity of the caudate nucleus. At the bottom of the longitudinal fissure it gives off branches to the corpus callosum, the frontal lobe, marginal gyrus, quadrate lobule, and gyrus fornicatus.

The **Anterior Communicating Artery**, the shortest artery in the body, lies on the lamina cinerea in front of the optic commissure, and connects the two anterior cerebral arteries across the longitudinal fissure. It also gives off antero-median ganglionic branches which pierce the lamina cinerea, and a small branch to the anterior extremity of the corpus callosum. Sometimes this vessel is absent, when the two anterior cerebral arteries have no connection, or form a common trunk, and then divide.

The **Middle Cerebral Artery** (Sylvian), the largest branch of the internal carotid, runs outward deeply within the fissure of Sylvius, and supplies the motor area of the brain. It gives off branches which supply the caudate and lenticular nuclei, the internal capsule, the optic thalamus, and the surface of the brain, as follows: Small branches which pass through the bottom of the fissure of Sylvius to the head of the caudate nucleus; antero-lateral branches, which pass through the anterior perforated space and supply the body and tail of the caudate nucleus, the internal capsule, and the optic thalamus; a branch, the lenticulo-striate, which passes through an aperture in the anterior perforated space and supplies the lenticular and caudate nuclei. The lenticulo-striate artery is called by Charcot the *artery of cerebral hemorrhage*, as it has so frequently been found ruptured in this condition. Finally, opposite the island of Reil, the middle cerebral artery gives off cortical branches which supply the operculum and the temporal and parietal lobes, especially the supra-marginal and angular gyri.

The **Posterior Communicating Artery** arises from the posterior surface of the internal carotid, and runs directly backward, parallel to and on the inner side of the oculo-motor nerve, to join the posterior cerebral artery. It varies in size, being sometimes so large as to give the impression that the posterior cerebral artery is its



MIDDLE CEREBRAL ARTERY.

continuation. A great difference in the size of the vessels of the two sides is not infrequently seen. It gives off branches to the uncinate convolution, with which it is in relation, and a branch, the middle thalamic, which passes vertically through the hippocampal sulcus to the optic thalamus.

The **Anterior Choroid Artery** is given off by the internal carotid just beyond the posterior communicating artery. It passes backward and outward under the tip of the temporo-sphenoid lobe of the cerebrum, to enter the descending cornu of the lateral ventricle on its way to supply the hippocampus major, corpus fimbriatum, and choroid plexus.

The **Vertebral Artery**, a branch of the first portion of the subclavian, enters the cranial cavity by way of the foramen magnum, and runs upward around the medulla oblongata, between the hypoglossal nerve and the anterior root of the first cervical or suboccipital nerve. Thence it runs forward along the medulla oblongata to the inner side of the hypoglossal nerve, and joins the vertebral artery of the opposite side at the lower border of the pons, to form a single trunk, the basilar artery. The branches given off from the vertebral artery within the cranial cavity are the posterior meningeal, the anterior and posterior spinal, and the posterior inferior cerebellar artery.

The **Posterior Meningeal Artery** arises from the vertebral artery opposite the foramen magnum, and supplies the bone and dura mater of the occipital fossa.

The **Anterior Spinal Artery** arises from the vertebral artery near its termination in the basilar, and joins the anterior spinal artery of the opposite side about the level of the foramen magnum. The common trunk then runs downward along the anterior median fissure of the spinal cord, in the pia mater. In its course it is reinforced by successive branches at the level of each vertebra; these branches are derived from the vertebral, the ascending cervical, the intercostal, the lumbar, the ilio-lumbar, and the lateral sacral arteries, all of which branches enter the spinal canal by way of the intervertebral foramina, and by their mesial union form a continuous anterior spinal artery which extends along the entire length of the anterior median fissure of the spinal cord.

The **Posterior Spinal Artery**, smaller than the anterior, arises from the vertebral artery at the side of the medulla oblongata, and passes backward to the side of the posterior surface of the spinal cord, where it divides into two branches, one of which descends behind and the other in front of the posterior roots of the spinal nerves. Like the anterior spinal, it is reinforced at the successive vertebral levels by branches derived from the vertebral, the intercostal, the lumbar, the lateral sacral, and the common trunk of the anterior spinal artery by branches which run around the sides of the spinal cord.

The **Posterior Inferior Cerebellar Artery**, the largest branch of the vertebral

artery, arises from that vessel near its termination (sometimes this branch may arise from the basilar artery); it winds backward around the medulla oblongata, between the pneumogastric and spinal accessory nerves; it then runs over the inferior cerebellar peduncle to the under surface of the cerebellum, there to divide into two branches—an outer and an inner; the outer branch traverses the under surface of the hemisphere of the cerebellum, which it supplies, and running along the outer margin of the cerebellum, it anastomoses with the superior cerebellar artery; the inner branch, practically the continuation of the main vessel, runs in the groove between the hemisphere of the cerebellum and the vermiform process, both of which it supplies. The posterior inferior cerebellar artery also sends branches to the fourth ventricle, and anastomoses with the corresponding vessel of the opposite side, and with the superior cerebellar artery.

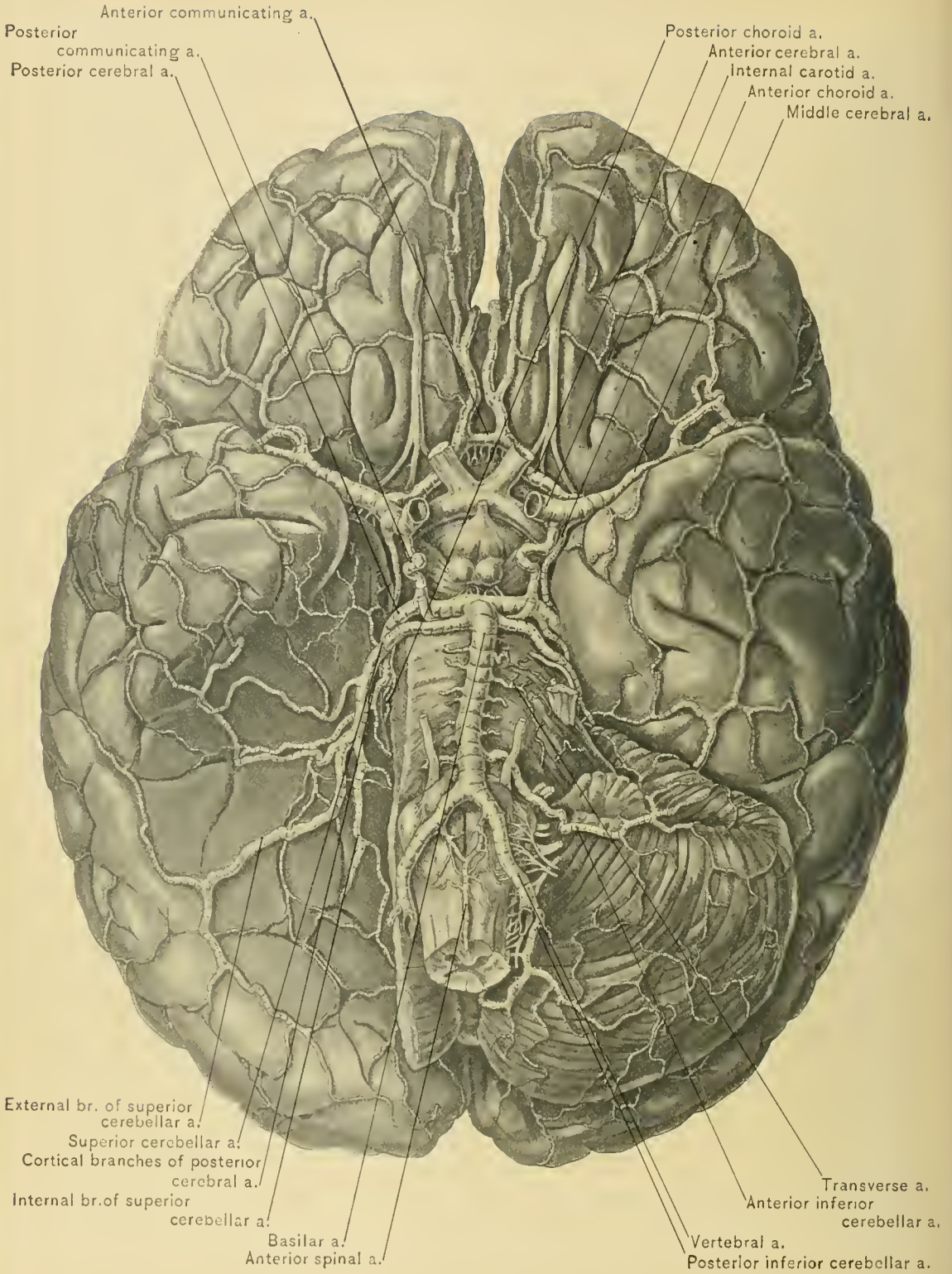
The **Basilar Artery**, formed by the union of the two vertebral arteries at the posterior border of the pons, runs along the median line of the anterior, or lower, surface of the pons as far as its anterior, or upper, border, where it divides into its two terminal branches—the posterior cerebrals. Running on each side of, and almost parallel with, the basilar artery, are the sixth, or abducent, nerves. With the brain *in situ*, the vessel lies on the dorsal surface of the body of the sphenoid bone. Its branches, named from behind forward, are the transverse, the internal auditory, the anterior inferior cerebellar, the superior cerebellar, and the two terminal.

The **Transverse Arteries** are numerous small branches which arise from the basilar upon each side, run in the direction their name indicates, and supply the pons and the adjacent portion of the cerebrum.

The **Internal Auditory Arteries**, one on each side, spring from the basilar artery and may arise from the transverse arteries. Each accompanies the corresponding auditory nerve into the internal auditory meatus, where it runs between the facial and auditory nerves, and, reaching the bottom of the meatus, passes into the internal ear.

The **Anterior Inferior Cerebellar Arteries**, one on each side, arise from the basilar artery near its middle. Each artery passes outward and backward over the pons and the middle crus of the cerebellum. It terminates at the fore part of the under surface of the hemisphere of the cerebellum, to which it is distributed. It anastomoses with the posterior inferior cerebellar artery.

The **Superior Cerebellar Arteries**, one on each side, arise from the basilar so near its bifurcation as to be sometimes mistaken for the posterior cerebral arteries. The superior cerebellar artery is separated from the posterior cerebral artery by the oculo-motor nerve. The superior cerebellar arteries pass outward around the crura cerebri, lying nearly parallel with the pathetic nerves, and reach the



ARTERIES AT BASE OF BRAIN.

upper surface of the cerebellum. Here they divide into branches which anastomose with the corresponding artery of the opposite side and with the inferior cerebellar artery.

The **Posterior Cerebral Arteries**, the two terminal branches of the basilar, wind around the crura cerebri, and, running parallel with the superior cerebellar, from which they are separated by the oculo-motor nerves, reach the inner surface of the posterior part of the cerebrum. As noted, they are joined to the internal carotid arteries by the posterior communicating branches of the latter vessels. They supply the occipital and temporo-sphenoid lobes, and anastomose with the anterior and middle cerebral arteries.

Like the anterior and middle cerebral arteries, the posterior cerebral gives off central and cortical branches. The central branches are as follows: Small branches which pass through the posterior perforated space to supply the optic thalamus and the walls of the third ventricle; the posterior choroid, which passes through the transverse fissure to reach the velum interpositum and the choroid plexus; while others run to the optic thalamus, crus cerebri, and corpora quadrigemina. The cortical branches are distributed to the adjacent parts of the temporal and occipital lobes.

Anastomoses of Cerebral Arteries.—Between the cortical and the central branches of the arteries which supply the brain there is no anastomosis; consequently, these two sets of branches form two independent systems. The cortical branches, however, may and do anastomose with each other, but seldom sufficiently to nourish a portion of the brain from which the blood current through the main artery supplying it has been cut off. In other words, the central vessels differ from the vessels of the upper or lower extremity in not being able to establish a collateral circulation which will perform the office of the principal vessel in the event of its being seriously disabled. In this respect they resemble the vessels of the lungs, kidneys, and retina. The central branches do not anastomose with each other; therefore, obstruction of one of the chief vessels of the brain will result in softening of the region supplied by its central branches, while softening of the region supplied by its cortical branches does not necessarily follow.

Peculiarities of the Arteries to the Brain.—In studying the course of the four large arteries—the two internal carotids and the two vertebrals—which enter the cranial cavity to supply the brain, the dissector will doubtless become aware of the following peculiarities: First, their length and tortuosity; second, that the four arteries anastomose freely by means of the circle of Willis; and, third, that their numerous and small branches run through the third and innermost membrane of the brain,—the pia mater,—by means of duplications of which they reach the interior of the brain. The tortuosity of these arteries diminishes

the force of the current of blood, thus lessening the danger of apoplexy; and, through the circle of Willis, the pressure in the four arteries is equalized.

THE VEINS OF THE BRAIN.

The **Veins of the Brain** empty into the sinuses of the dura mater (see description of the sinuses, vol. I); they do not accompany the corresponding arteries.

The **Veins of the Cerebrum** consist of a superficial or cortical and a deep or central set. The former ramify in the pia mater and empty directly into the sinuses; the latter empty into the sinuses indirectly through the medium of the veins of Galen.

The Cerebellar Veins.—The veins which run over the superior surface of the cerebellum empty into the veins of Galen and the straight sinus, while all of those which traverse the lower surface of the cerebellum empty into the inferior petrosal, lateral, and occipital sinuses.

Absence of Valves.—The veins and sinuses of the brain are destitute of valves. Their absence may be compensated for in the superior longitudinal sinus by the presence of the chordæ Willisii, and by the fact that the veins which empty into this sinus pass from behind forward in a direction opposite to that of the blood current, and that in entering the sinus they pass obliquely through its wall.

THE PIA MATER.

The **Pia Mater**, the innermost of the three membranes which cover the brain, invests it most intimately, and sends processes into all the fissures of the cerebrum and between most of the laminae of the cerebellum. It is the vascular membrane of the brain, and carries the minute branches of the two internal carotids and the two vertebral arteries, and the veins which return the blood conveyed to the brain by these vessels, all of which are associated by delicate connective-tissue fibers. The author would liken the connective-tissue element of the pia mater to a grape arbor, and the vessels running over and through the interstices to the grape vine. Added to the above are numerous minute vessels, given off from the inner surface of the pia mater, which pass perpendicularly into the substance of the brain.

Only two of the processes of the pia mater receive special names—the **velum interpositum** and the **choroid plexuses** of the third and fourth ventricles. The former reaches the interior of the brain by way of the transverse fissure. Both the velum interpositum and the choroid plexus will be described with the ventricles of the brain. The portions of the pia mater which cover the crura cerebri

and the pons have a different appearance from the rest of the membrane, and present a dense fibrous structure which contains but few vessels.

NERVE SUPPLY.—The pia mater is supplied with nerves by branches from the sympathetic, trifacial, and glosso-pharyngeal nerves.

THE BRAIN.

DISSECTION.—If the arachnoid and the pia mater have been allowed to remain in place thus far, they should now be removed, with the exception of that portion of the pia mater which is prolonged inward between the splenium of the corpus callosum above and the pineal gland and the corpora quadrigemina below, to form the velum interpositum which is placed between the corpus callosum and fornix above and the optic thalami, pineal gland, and corpora quadrigemina below. The removal of these membranes exposes the surface of the brain; and in dissecting them from the base of the brain care should be taken not to detach any of the cranial nerves.

Definition and Weight.—The brain, or encephalon, is the intracranial mass of nervous matter, or that portion of the cerebro-spinal axis which is contained within the cavity of the cranium. Its average weight in the adult male is forty-nine and one-half ounces, and in the female forty-four ounces.

Divisions.—The brain is composed of four main portions: The cerebrum (large brain); the cerebellum (small brain), which is second in size; the pons Varolii, which is third in size; and the medulla oblongata, the smallest, yet physiologically the most important.

Position of the Pons.—Of these four portions the pons Varolii is the center around which the three remaining portions are not only grouped, but to which they are connected in the following manner: To the cerebrum by the crura cerebri, the cerebellum by the crura cerebelli (middle peduncles of the cerebellum), and the medulla oblongata by the anterior pyramids and part of the lateral tracts. The pons rests upon the posterior surface of the body of the sphenoid bone and the upper part of the basilar process of the occipital bone.

Position of the Cerebrum.—The cerebrum occupies all the upper part of the cranial cavity, concealing from view the other portions of the brain when one looks from above, and rests upon the floor of the anterior and middle fossæ of the skull, and the tentorium cerebelli. The tentorium cerebelli, in addition to supporting the cerebrum, separates it from the cerebellum and protects the latter from pressure by the cerebrum.

Position of the Cerebellum.—The cerebellum occupies the space between the tentorium cerebelli and the floor of the posterior cranial fossa.

Position of the Medulla Oblongata.—The medulla oblongata is continuous below with the spinal cord, and rests upon the posterior part of the basilar process of the occipital bone.

Contour.—The brain is convex upon its upper and lateral surfaces, and irregular upon the lower or basilar surface, where it conforms to the base of the skull. The form of the surface of the brain is largely that of the interior of the cranium, but not sufficiently so as to make phrenology an exact science.

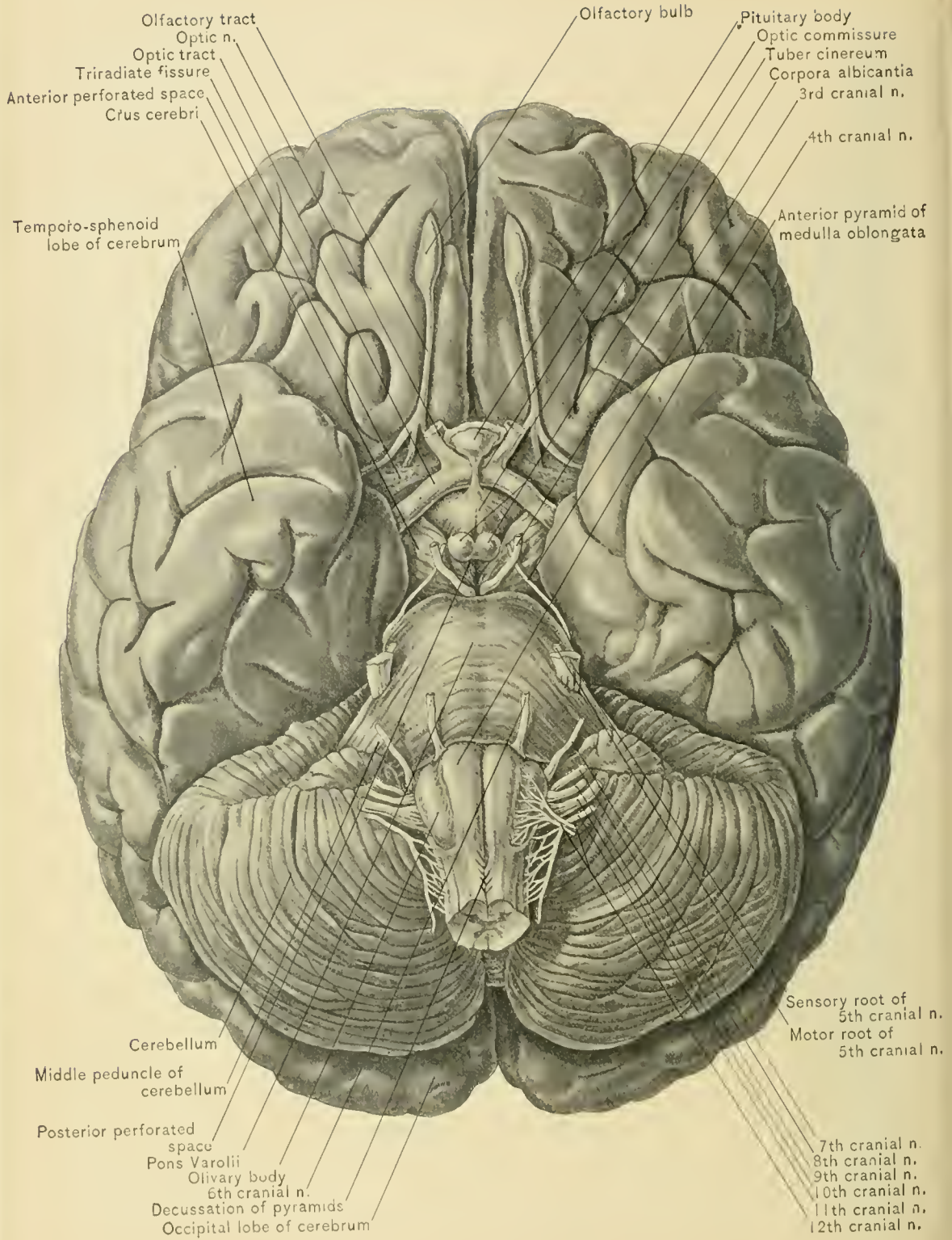
Structures at the Base of the Brain.—In dissecting the brain the most suitable article upon which to place it is an ordinary dinner plate covered with a thick layer of absorbent cotton wet with alcohol. This soft bed will prevent the convolutions from being flattened when the brain is laid on its upper surface to study the structures forming the base. These are the inferior surfaces of the frontal and temporo-sphenoid lobes of the cerebrum, which are irregular and conform to the inequalities of the base of the skull, this relation explaining why contusion of the cerebrum is more common at the basilar surface of these lobes than elsewhere; the fissure of Sylvius, which separates the frontal from the temporo-sphenoid lobe; the olfactory tracts and bulbs; the longitudinal fissure; the corpus callosum and its peduncles; the anterior perforated spaces; the optic commissure and the terminal parts of the optic tracts; the lamina cinerea, the tuber cinereum and a part of the infundibulum—the remaining part, with the pituitary body, having been described; the corpora albicantia, or mammillary eminences; the posterior perforated space; the crura cerebri; the pons Varolii; the middle crura of the cerebellum; the lateral hemispheres of the cerebellum; the medulla oblongata; the posterior extremity of the inferior vermiform process of the cerebellum; and, finally, the roots of the cranial nerves.

Frontal Lobes.—The inferior or orbital surfaces of the frontal lobes are triangular in shape, and separated in front by the longitudinal fissure. Their bases are directed backward, and formed by the fissure of Sylvius. They present two well-pronounced sulci or fissures—the triradiate, or orbital, and the olfactory. These, as will be seen later, divide them into their convolutions.

The **Olfactory Tract and Bulb** are seen occupying the olfactory sulcus.

Temporal Lobes.—The inferior surface of the temporal or temporo-sphenoid lobe, is slightly convex anteriorly and concave posteriorly, and thus accommodates itself in front to the portions of the middle cranial fossa formed by the greater wing of the sphenoid and the anterior surface of the petrous portion of the temporal bone, and behind to the convex tentorium. It presents the termination of two well-pronounced sulci—the third temporal and the inferior occipito-temporal.

Fissure of Sylvius.—Between the inferior surfaces of the adjacent frontal and temporo-sphenoid lobes is seen the fissure of Sylvius, the largest of the prim-



BASE OF BRAIN AND SUPERFICIAL ORIGIN OF CRANIAL NERVES.

ary fissures of the cerebrum, through which runs the middle cerebral artery; into this fissure extends the lesser wing of the sphenoid bone, and from the floor of its anterior portion projects the island of Reil, or central lobe of the cerebrum.

The **Longitudinal Fissure** separates the two frontal lobes, and if the cerebellum is lifted, the fissure will be seen to separate completely the two occipital lobes.

Corpus Callosum.—By carefully separating the frontal lobes, the beak or rostrum of the corpus callosum will be seen in addition to two white bands,—the peduncles of the corpus callosum,—which are continued backward and outward on each side of the rostrum across the anterior perforated space to the commencement of the fissure of Sylvius.

The **Anterior Perforated Spaces**, one on each side, are situated at the inner extremity of the fissure of Sylvius. Each space is triangular in shape, bounded in front by the frontal lobes and the roots of the olfactory tracts, externally by the apices of the temporo-sphenoid lobes and the fissure of Sylvius, and posteriorly by the optic tract. They are crossed by the peduncles of the corpus callosum and the external olfactory root; they transmit small vessels, chiefly branches of the middle cerebral artery, to the corpora striata, which lie immediately above the spaces.

The **Optic Commissure** or **Chiasm**, from which arise the optic nerves, lies between the anterior perforated spaces and behind the anterior inferior portion of the longitudinal fissure. It is formed by the union of the optic tracts—two white cords seen running on the outer side of the crura cerebri.

The **Interpeduncular** or **Intercrural Space** is a lozenge-shaped or quadrilateral area, bounded by the optic commissure in front, the pons Varolii behind, and the optic tracts and the crura cerebri at the sides. It contains the tuber cinereum, the intra-dural portion of the infundibulum, the corpora albicantia, the posterior perforated space, and the oculo-motor nerves. These structures, except the last mentioned, form the floor of the third ventricle with the exception of its anterior part, which is formed by the structure next to be described—the lamina cinerea.

Lamina Cinerea.—To expose the lamina cinerea to the best advantage, displace backward the optic commissure, above which it lies. It will then be seen to extend from the beak or rostrum of the corpus callosum, to which it is attached in front, to the tuber cinereum, to which it is attached behind. It is composed of gray matter continuous with the anterior perforated spaces.

The **Tuber Cinereum** is a gray eminence, situated behind the optic commissure and in front of the corpora albicantia. It is a hollow conic process continuous with the infundibulum, which connects the third ventricle with the pituitary body. The *infundibulum* pierces the diaphragma sellæ, a process of the dura mater which bridges the pituitary fossa.

The **Pituitary Body** (**Hypophysis Cerebri**) is the small body which occupies the pituitary fossa or sella turcica and is covered superiorly by the diaphragma

sellæ. It is composed of an anterior and a posterior lobe which differ in size, structure, and origin. The *anterior lobe* is much the larger, is of reddish-gray color, and is an isolated process of the wall of the buccal cavity of the embryo. The *posterior lobe* is the smaller, is lodged in a depression in the anterior lobe, is of yellowish-gray color, and is a process of the brain. It is the only part of the pituitary body structurally continuous with the infundibulum, which, in passing from the floor of the third ventricle to the pituitary body, pierces the diaphragma sellæ.

The **Corpora Albicantia** (bulbs of the fornix), two knobs situated behind the tuber cinereum, are formed by the anterior crura of the fornix, and the bundles of Vieq d'Azyr from the optic thalamus, which reach the base of the brain.

The **Posterior Perforated Space** is triangular in shape, its base corresponding to the corpora albicantia; its apex, to the pons Varolii; and its sides, to the crura cerebri. It gives passage to postero-median ganglionic branches of the posterior cerebral and posterior communicating arteries, which run to the optic thalami.

The **Crura Cerebri**, or cerebral peduncles, are two large cylindric masses of white and gray matter. They are about three-fourths of an inch, or eighteen millimeters, long, broader in front than behind, and composed of the longitudinal fibers of the pons Varolii, together with some fibers from the cerebellum. They commence at the anterior border of the pons, from which they emerge, and then pass forward and outward. They traverse the superior occipital foramen in the tentorium cerebelli in company with the superior peduncles of the cerebellum, the oculo-motor and pathetic nerves, and the basilar artery, and each enters the anterior and inner aspect of the corresponding temporo-sphenoid lobe. The optic tract and the pathetic nerve pass around the outer border of the corresponding crus cerebri, while the oculo-motor nerve winds around the inner border. Later, when making sections of the brain to study the arrangement of its interior, the crura cerebri will be cut across, when the *locus niger*, a gray nucleus in the interior of each crus, will be exposed. The nucleus separates the fibers of the crus cerebri into two sets: a lower and smaller—the *crusta*—and an upper and larger—the *tegmentum*.

The **Pons Varolii**, or **Tuber Annulare**, the central figure in the group of the four divisions of the brain, is composed chiefly of white matter, and is situated behind the crura cerebri, in front of the medulla oblongata, and between the hemispheres of the cerebellum. It is about an inch, or twenty-five millimeters, long, and rather more than this in width: from its dorsal to its ventral surface it measures about three-fourths of an inch, or eighteen millimeters. It is markedly convex from side to side and slightly so from before backward, and presents an antero-posterior median groove which accommodates the basilar artery. It consists principally of two sets of fibers—a transverse, or superficial, and a longitudinal, or deep, set. The former set extend laterally into each hemisphere of the cerebellum, forming the middle peduncles, or great transverse commissure, of

the cerebellum; and the latter set extend forward and outward and help to form the crura of the cerebrum. Making their exit through the sides of the pons, are the trifacial nerves. The upper surface of the pons forms a part of the floor of the fourth ventricle.

The **Medulla Oblongata**, the smallest of the four divisions of the brain, is the enlarged upper end of the spinal cord. It extends from the lower border of the pons, from which it is separated by a transverse groove, to the lower border of the foramen magnum. In addition to the medulla oblongata the three membranes of the spinal cord, the vertebral artery, and the spinal accessory nerves pass through the foramen magnum of the occipital bone. Its upper surface lies in the depression between the hemispheres of the cerebellum. It is pyramidal in shape; about one and a quarter inches, or thirty-two millimeters, long; three-quarters of an inch, or eighteen millimeters, wide at its broadest part, which is its upper portion; and half an inch, or twelve millimeters, in thickness. It forms part of the sides and the largest and most important part of the floor of the fourth ventricle. Its further description will be deferred until the dissection of the cerebrum is completed.

The **Hemispheres of the Cerebellum** are situated chiefly upon each side of the medulla oblongata. The arrangement of the gray matter which forms the surface of the cerebellum differs from that of the cerebrum in the following respects: In the cerebrum it is arranged in convolutions or gyri separated by fissures, while in the cerebellum it is arranged in closely applied laminae. The upper and lower surfaces of the hemispheres are divided into lobes, which will be described with the dissection of the cerebellum. By lifting up the medulla oblongata, the depression or valley between the two hemispheres of the cerebellum will be partly exposed. There will also be visible the inferior surface of the middle lobe, or inferior vermiform process, that portion of the cerebellum which forms the roof of the fourth ventricle; projecting beyond the medulla oblongata is the posterior extremity of the inferior vermiform process of the cerebellum, called the tuber valvulae.

Next examine the roots of the cranial nerves from before backward in the order in which they are named.

THE ORIGINS OF THE CRANIAL NERVES.

The **First Cranial or Olfactory Nerve** is devoted to the special sense of smell; it is seen upon the base of the brain as the olfactory tract and bulb; in reality, the olfactory bulbs and tracts represent a portion of the brain, and are more highly developed in certain of the lower animals. The olfactory

nerves proper, about twenty in number, which arise from the olfactory bulbs, have been divided in removing the brain from the skull. The olfactory tract arises by two so-called roots, an external and an internal. The external or long root, composed of white matter, crosses the anterior perforated space to the anterior end of the hippocampal gyrus of the temporo-sphenoid lobe; and the inner or mesial root, also composed of white matter, passes backward and inward to the anterior extremity of the gyrus fornicatus. Between these two diverging roots is a small triangular area of gray matter (*trigonum olfactorium*), which receives a few fibers from the olfactory tract; when these fibers are conspicuous, they form what is sometimes called the middle or gray root. The tract thus formed is lodged in the olfactory sulcus of the cerebrum, and is surrounded at the anterior extremity by a small rounded mass of gray matter, the olfactory bulb.

The **Second Cranial** or **Optic Nerve**, which also represents a portion of the brain, is the nerve of vision, and arises from the optic commissure, which is formed by the union of the optic tracts. The optic tracts arise from the corpora geniculata, the nates of the corpora quadrigemina, and the optic thalami. Each tract is composed of three sets of fibers,—an outer, a middle, and an inner,—which have the following arrangement: the outer set passes directly to the optic nerve of the same side, the middle set to the optic nerve of the opposite side, and the inner set to the optic tract of the opposite side. On account of the course of the nerve-fibers from the optic tracts to the nerves a lesion of one optic tract causes **hemianopsia**, or obliteration of vision in the corresponding halves of both eyes: as, for example, a lesion of the left optic tract causes loss of vision in the left half of both eyes.

The **Third Cranial** or **Oculo-motor Nerve** arises superficially from a groove on the inner side of the crus cerebri, just anterior to the pons, and deeply from a nucleus in the floor of the aqueduct of Sylvius. It is a motor nerve, and supplies all the muscles of the eyeball except the superior oblique, the external rectus, and radiating fibers of the iris.

The **Fourth Cranial**, **Pathetic**, or **Trochlear Nerve** is the smallest of the cranial nerves, and apparently arises at the outer side of the crus cerebri. Its real superficial origin is from the valve of Vieussens, or superior medullary velum, immediately behind the testes or posterior pair of corpora quadrigemina. The deep origin is from a nucleus in the floor of the aqueduct of Sylvius in close relation with the nucleus of the oculo-motor nerve. In the substance of the valve of Vieussens it decussates with the opposite fourth cranial nerve. It then winds around the outer side of the crus cerebri, and appears at the base of the brain at the anterior border of the pons. It is a motor nerve, and supplies the superior oblique or trochlearis muscle.

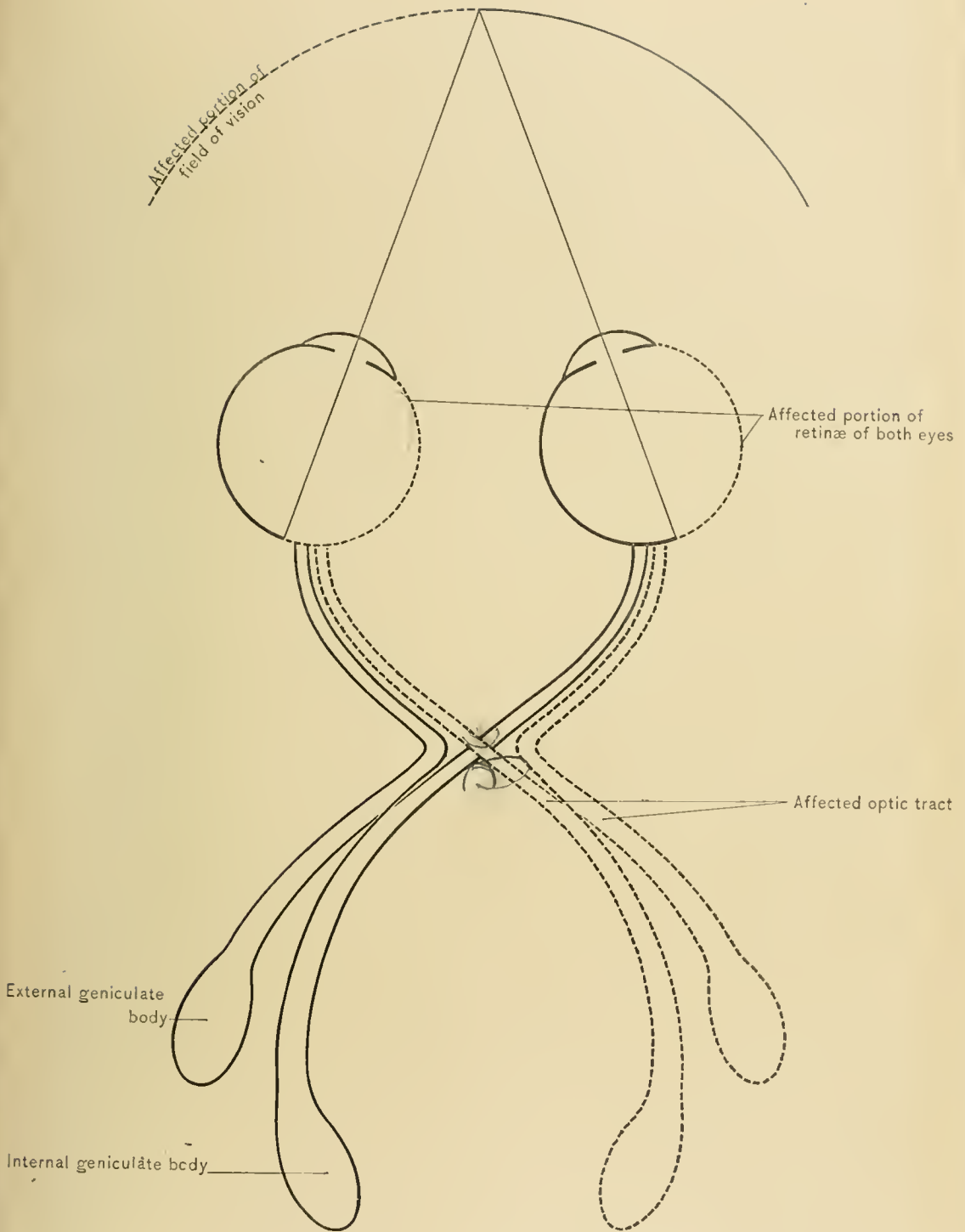


DIAGRAM OF OPTIC TRACTS.

The **Fifth Cranial, Trigeminal, or Trifacial Nerve**, the largest of the cranial nerves, arises from the sides of the pons by two roots—a larger, posterior or sensory root, and a smaller, anterior or motor root. These roots can be traced to the floor of the fourth ventricle and to the gray matter in the lower part of the medulla oblongata and in the upper part of the spinal cord. It is the only cranial nerve which resembles a spinal nerve in arising by two roots,—a posterior, or sensory, and an anterior, or motor,—and in having a ganglion on the posterior root. The trifacial is a mixed nerve. It distributes sensory filaments to the dura mater, pia mater, orbit, eyelids, nose, gums, teeth, tonsils, palate, sphenoid cells, ethmoid cells, frontal sinus, maxillary sinus, nasal fossæ, pharynx, articulation of the lower jaw, ear, parotid gland, scalp, forehead, and face; gustatory filaments to the anterior two-thirds of the tongue; and motor filaments to four of the muscles of mastication—the temporal, masseter, and the external and internal pterygoids.

The **Sixth Cranial or Abducent Nerve** arises superficially from the anterior pyramid of the medulla oblongata and the interval between the anterior pyramid and the olive, close to the lower margin of the pons. Its deep origin is from the floor of the fourth ventricle. It is a motor nerve, and supplies the external rectus muscle of the eyeball.

The **Seventh Cranial or Facial Nerve** arises as two portions. The *pars intermedia of Wrisberg* arises deeply from the forepart of the nucleus of the ninth cranial nerve, in the floor of the fourth ventricle. Its superficial origin is at the lower border of the pons, external to the facial nerve proper and between the olivary and restiform bodies. The *pars intermedia of Wrisberg* is considered a portion of the glosso-pharyngeal or ninth cranial nerve, its nucleus being continuous with that of the ninth cranial nerve. Its fibers are believed to enter the chorda tympani nerve. Thus, all of the special sensory fibers to the tongue are derived from the glosso-pharyngeal nerve. The *facial nerve proper* has its deep origin in the floor of the fourth ventricle, its fibers winding around the nucleus of the sixth cranial nerve. It arises superficially from the medulla oblongata in the groove between the olivary and restiform bodies. The facial is a motor nerve, its range of distribution is large, and its connections with other nerves are numerous. It supplies the stapedius muscle, gives off the chorda tympani nerve, the posterior auricular nerve, the nerve to the posterior belly of the digastric, and a branch to the stylohyoid muscle. In addition it supplies the muscles of expression and the buccinator muscle.

The **Eighth Cranial or Auditory Nerve**, situated immediately beneath or external to the facial, is really two nerves, and arises deeply from three nuclei,—Deiters', the accessory, and the chief nucleus,—which are all situated in the medulla oblongata. From these nuclei two roots arise which embrace the restiform

body, the lateral root arising principally from the accessory nucleus, and the mesial root from the chief nucleus and Deiters' nucleus. Its superficial origin is external to that of the facial nerve—from the groove between the olivary and restiform bodies of the medulla oblongata. From the close relation between the facial and auditory nerves at their exit from the side of the medulla oblongata, they have been described as two separate portions of the seventh cranial nerve, and on account of their difference in consistency, the facial portion was called the *portio dura* and the auditory portion the *portio mollis*. The auditory nerve is the nerve of the special sense of hearing, and supplies the internal ear. The lateral root is continued into the cochlear nerve, supplies the cochlea, and is the nerve of the sense of hearing. The mesial root is known as the vestibular nerve and supplies the vestibule and semicircular canals; it is associated with maintenance of equilibrium of the body.

The **Ninth Cranial** or **Glosso-pharyngeal Nerve** arises from the floor of the fourth ventricle in common with the pneumogastric nerve and the accessory portion of the spinal accessory nerve. It emerges from the same groove in the medulla oblongata as the facial and auditory nerves, but below them. It is distributed to the tympanum, the stylo-pharyngeus muscle, the mucous membrane of the pharynx, the tonsil, and the back of the tongue. The glosso-pharyngeal is a sensory and motor nerve, as well as the nerve of the special sense of taste, as it supplies the circumvallate papillæ at the back of the tongue.

The **Tenth Cranial** or **Pneumogastric Nerve** (*nervus vagus* or *par vagum*), the longest of the cranial nerves, commences within the cranium, extends through the neck and chest, and terminates in the upper part of the abdomen. It arises deeply from the floor of the fourth ventricle, and superficially from the side of the medulla oblongata by ten or fifteen filaments, which emerge from the medulla oblongata through the groove between the lateral column and the restiform body and below the glosso-pharyngeal nerve. The pneumogastric nerve contains both motor and sensory fibers. It supplies the dura mater, the external ear, the pharynx, the larynx, the œsophagus, the trachea, the lungs, the heart, and some abdominal viscera—viz., the liver and stomach.

The **Eleventh Cranial** or **Spinal Accessory Nerve** consists of two portions—an upper or accessory, and a lower or spinal. The **accessory portion**, the smaller, arises deeply from the floor of the fourth ventricle in common with the ninth and tenth cranial nerves. Superficially, it arises by fine filaments from the side of the medulla oblongata below the origin of the pneumogastric nerve, and emerges with it through the same groove. The **spinal portion**, the larger, arises by several filaments from the side of the spinal cord, between the ligamentum denticulatum and the posterior roots of the spinal nerves as low down as

the sixth cervical nerve. It gains entrance to the cranial cavity by way of the foramen magnum of the occipital bone, and passes out through the middle compartment of the jugular or posterior lacerated foramen. In the latter situation the accessory portion leaves it to join the ganglion of the trunk of the vagus. The spinal accessory is a sensori-motor nerve, and supplies the sterno-mastoid and trapezius muscles.

The **Twelfth Cranial** or **Hypoglossal Nerve** arises superficially from the side of the medulla oblongata by several filaments which emerge through the groove between the anterior pyramid and the olivary body; its deep origin is from the posterior portion of the floor of the fourth ventricle. The filaments of this nerve are collected into two bundles which perforate the dura mater separately before passing through the anterior condyloid foramen, in which they unite to form the trunk of the nerve. The hypoglossal is a motor nerve. It supplies the extrinsic muscles of the tongue—viz., the genio-hyo-glossus, hyo-glossus, and the stylo-glossus. Through fibers derived from the pneumogastric and sympathetic nerves it supplies a meningeal branch to the dura mater, and through fibers derived from the second and third cervical nerves it supplies motor branches to the genio-hyoid, sterno-hyoid, sterno-thyroid, omo-hyoid, and thyro-hyoid muscles.

THE CEREBRUM.

The brain is now laid on its base and the upper surface examined. This surface is formed entirely by the cerebrum, and is seen to consist of two halves, called hemispheres, which are separated from each other in the median line by the longitudinal fissure. This is one of the two largest fissures of the brain, the other being the horizontal fissure.

The Longitudinal Fissure.—By gently separating the hemispheres the longitudinal fissure will be seen to reach the base of the brain both in front and behind, while the intervening portion is rendered more shallow by a transverse band of white matter, the *corpus callosum*, which may therefore be said to form its floor. Running through the bottom of the fissure from before backward, and over the superior surface of the corpus callosum, are the anterior cerebral arteries; this fissure also lodges the falx cerebri and its contained sinuses, the superior and the inferior longitudinal.

The Horizontal Fissure.—The posterior ends of the hemispheres of the cerebrum are separated from the cerebellum by the horizontal fissure, the deep central or purely intra-cerebral portion of which is known as the *transverse fissure* or the *fissure of Bichat*. The horizontal fissure accommodates the tentorium cerebelli and its contained sinuses.—the straight, the lateral, and the superior petrosal,—while

the deep portion, or the transverse fissure, transmits the pia mater into the interior of the cerebrum, where that membrane forms the velum interpositum.

Convolution and Fissures.—The surfaces of the hemispheres of the cerebrum are composed of convolutions or gyri—elevations of gray matter which are separated by fissures or sulci. The greater the development of the hemisphere, the more numerous are the fissures and convolutions, as the increased depth and number of the fissures afford additional area to be covered with gray matter. In studying the fissures and convolutions from the fresh brain for the first time, that of a new-born child answers best, as the arrangement of these structures is somewhat simpler and agrees better with the description of the brain given in text-books.

DISSECTION.—Before studying the component parts of the brain by making sections, it is better carefully to study the surface anatomy of the hemispheres of the cerebrum. This entails separating the cerebrum from the remaining divisions of the brain and carrying an incision from the bottom of the longitudinal fissure through the median line of the corpus callosum and the structures in the median line of the cerebrum under the corpus callosum; this renders it possible to examine the three surfaces of each hemisphere of the cerebrum to the best advantage. To separate the cerebrum from the remainder of the brain, it is necessary to divide the crura cerebri and superior peduncles of the cerebellum, the latter being exposed by lifting up the posterior lobes of the cerebrum. In order to do this, and also to obtain the best idea of the topographic relations of the different parts of the brain, the dissector should have at least two good brains at his disposal.

VARIATIONS.—The two hemispheres of the cerebrum are not always the same in size, the left being usually the larger. This is supposed to be due to the fact that the blood supply of this side of the brain is more direct, as the left common carotid, and also the left subclavian artery, which gives origin to the vertebral, arise directly from the arch of the aorta.

SURFACES.—Each hemisphere of the cerebrum presents three surfaces; an outer,—convex or lateral,—an inner or median, and an inferior or basilar. The basilar surface rests in the anterior and middle cranial fossæ and upon the tentorium cerebelli.

Arrangement of the Convolution.—As has been noted, the surfaces of the hemispheres of the cerebrum are composed of gray matter arranged in folds, elevations, convolutions, or gyri; these, in turn, are separated by furrows, fissures, valleys, or sulci varying in length, depth, and importance. As Ecker well states, the chief or primary convolutions are like great mountain chains whose direction lends to a region its characteristic features. The secondary folds originate by the splitting of a primary convolution into smaller ones by the formation of longitudinal furrows, as secondary mountain ridges arise from the forma-

tion of longitudinal valleys. The deepest fissures, which separate the principal convolutions from each other, may be named the primary; those which separate the secondary convolutions from each other, the secondary; and, finally, the tertiary convolutions are those little gyri which jut out into the primary fissures from the sides of the principal convolutions, and, therefore, give to the bottom of the fissure a zigzag route. While the features of the principal convolutions are always arranged with considerable uniformity, numerous variations exist in the arrangement of the secondary and tertiary convolutions. There are several reasons for this: one is that there are sometimes only a few secondary fissures, while in other cases there are quite a number; again, in some cases tertiary convolutions which are ordinarily invisible come to the surface; while in others, convolutions which are usually superficial sink deeper; in the former case the fissures are bridged over, and in the latter new convolutions exist in places where there usually is none. The general arrangement of the fissures and convolutions of the two hemispheres is moderately symmetric, yet slight differences always occur.

The **Cerebral Fissures**, besides being classified as primary and secondary fissures, are subdivided into complete and incomplete fissures. *Complete fissures* extend through almost the entire thickness of the cerebrum, thus producing elevations in the lateral ventricles; examples of such fissures are the hippocampal and portions of the collateral and calcarine fissures. *Incomplete fissures* are furrows of variable depth which do not cause protrusions in the ventricles.

It is by means of the convolutions and fissures of the brain that the amount of the gray matter is greatly increased, without unduly augmenting the size of the brain; furthermore, the pia mater is thus enormously increased in extent, because it follows the windings of the gyri and fissures, and its vessels, which supply the cortex, are enabled to break up into fine branches before penetrating the brain tissue.

Lobes.—Each hemisphere of the cerebrum is incompletely divided by the deeper, and therefore the more important, of the fissures into the following parts, or lobes: the frontal, the parietal, the temporal or temporo-sphenoid, and the occipital. In addition to these four lobes there is a fifth lobe—the central lobe, or island of Reil; but as this projects into the bottom of the fissure of Sylvius, and can not be seen without drawing apart the sides of the latter, it will be described with the fissures. The individual lobes are distinct from each other on certain surfaces only, while on other surfaces they run into each other, and are without definite boundaries. The fissures are the landmarks which guide us in mapping out the hemispheres into districts, or lobes, and also in locating the individual convolutions. Hence our first task in the study of the surfaces of the hemispheres of the cerebrum is to locate the principal fissures.

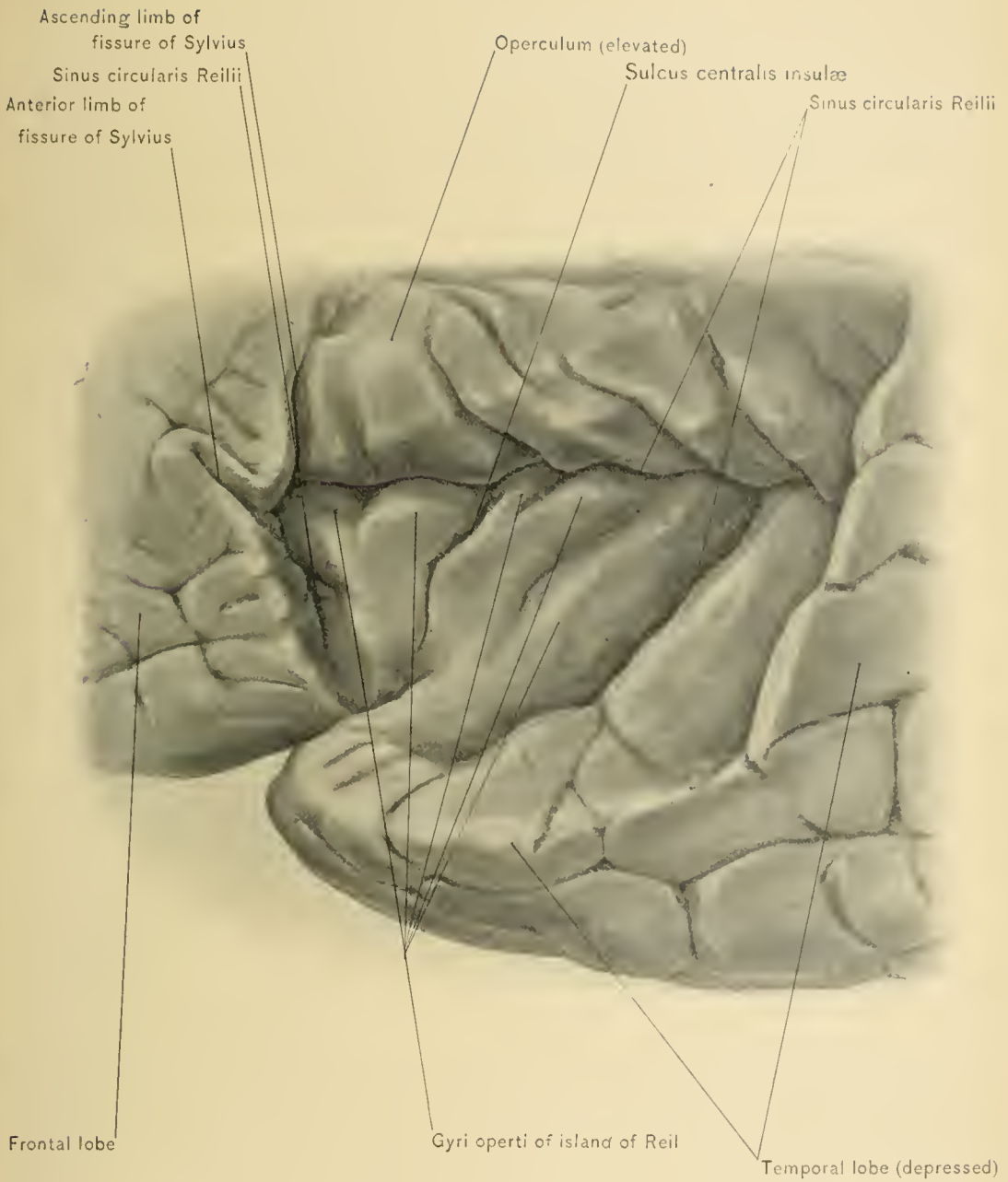The **Primary Fissures of the Cerebrum** are, in the order of their importance, the fissure of Rolando or the sulcus centralis, the fissure of Sylvius, and the parieto-occipital fissure. The fissure of Sylvius is found partly on the inferior, or basilar, and chiefly on the outer, convex, or lateral surface of the cerebrum; the fissure of Rolando, or sulcus centralis, only on the lateral surface of the cerebrum; and the parieto-occipital fissure, chiefly on the median or inner surface, and slightly on the outer surface of the cerebrum.

The **fissure of Sylvius**, within which is lodged the lesser wing of the sphenoid bone, and through which passes the middle cerebral artery, commences on the basilar surface of the hemisphere of the cerebrum, at the anterior perforated space, in a depression called the *vallecula Sylvii*. Thence it extends outward to the external convex surface of the cerebrum, where it divides into two limbs: an ascending or vertical and a posterior or horizontal, which runs backward and upward to end in the parietal lobe. The *main portion* of the fissure is that which occupies the base of the brain. The *ascending limb* passes upward for about one inch, or twenty-five millimeters, into the frontal lobe in front of the precentral fissure, and is separated from the latter by the posterior part of the inferior or third frontal convolution, which arches around the end of the ascending limb. Immediately in advance of the ascending limb there runs forward and upward from the main portion of the fissure a third limb, the *anterior limb*. This limb, which is nearly of the same length as the ascending limb, runs directly forward into the substance of the inferior frontal convolution.

The **island of Reil**, or the **central lobe**, is seen in the bottom of the fissure of Sylvius at the angle of separation of the ascending and horizontal limbs by drawing widely apart the sides of the horizontal limb of the fissure of Sylvius and lifting the operculum. It comprises a series of from five to seven small convolutions, surrounded by a limiting sulcus (*sulcus circularis Reilii*). The convolutions of this lobe are arranged so that they radiate from the apex, which looks downward and forward. A fissure, the *sulcus centralis insulæ*, running in about the same direction as the fissure of Rolando, divides it into an anterior and a posterior portion. Additional smaller fissures are seen between the convolutions of the island of Reil.

The **operculum** is that portion of the hemisphere of the cerebrum formed by the base of the inferior frontal convolution, the lower end of the ascending frontal and lower part of the ascending parietal convolution, and therefore immediately overhangs the island of Reil. The latter is external to the corpus striatum, and its fissures accommodate some of the branches of the middle cerebral artery.

Calloso-marginal Fissure.—Before attempting to trace the course of the fissure of Rolando, examine the inner surface of the hemisphere of the cerebrum and locate a secondary fissure running above the corpus callosum. It lies midway



ISLAND OF REIL.

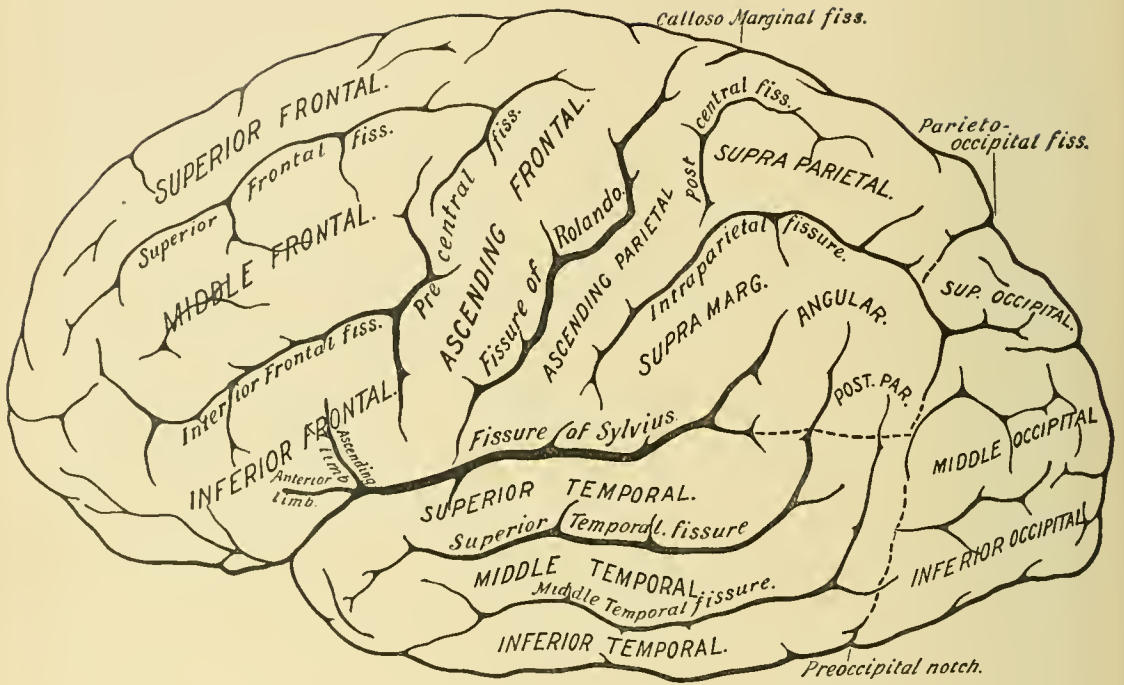


DIAGRAM OF LATERAL SURFACE OF CEREBRUM.

between the upper surface of the latter and the upper border of the hemisphere, and terminates upon the external surface of the hemisphere near this border and almost opposite the posterior end of the corpus callosum. This is the calloso-marginal fissure.

The **fissure of Rolando**, or **central fissure**, is the most important of the three primary fissures of the brain, both from the surgical and descriptive standpoints. It runs through the motor area of the cortex of the cerebrum, upon which so many operations have been performed in recent years. It commences at the upper border of the hemisphere of the cerebrum just external to the longitudinal fissure and immediately in front of the terminal part of the calloso-marginal fissure. From here it runs obliquely downward and forward over the outer surface of the hemisphere at an angle with the anterior part of the longitudinal fissure of about 71.5 degrees, terminating a slight distance above the horizontal limb and about one inch, or twenty-five millimeters, behind the ascending limb of the fissure of Sylvius. The calloso-marginal fissure is very rarely bridged over by a secondary convolution, and, therefore, there should be no difficulty in locating it. The fissure of Rolando presents two more or less distinct bends, called its genua; the superior genu, located at the junction of its middle third and upper third, has its convexity projecting backward; the inferior genu is somewhat nearer the lower extremity of the fissure, and its convexity points forward. In proportion as the frontal lobes increase in size and the brain in general attains higher development the fissure runs more obliquely backward (Ecker).

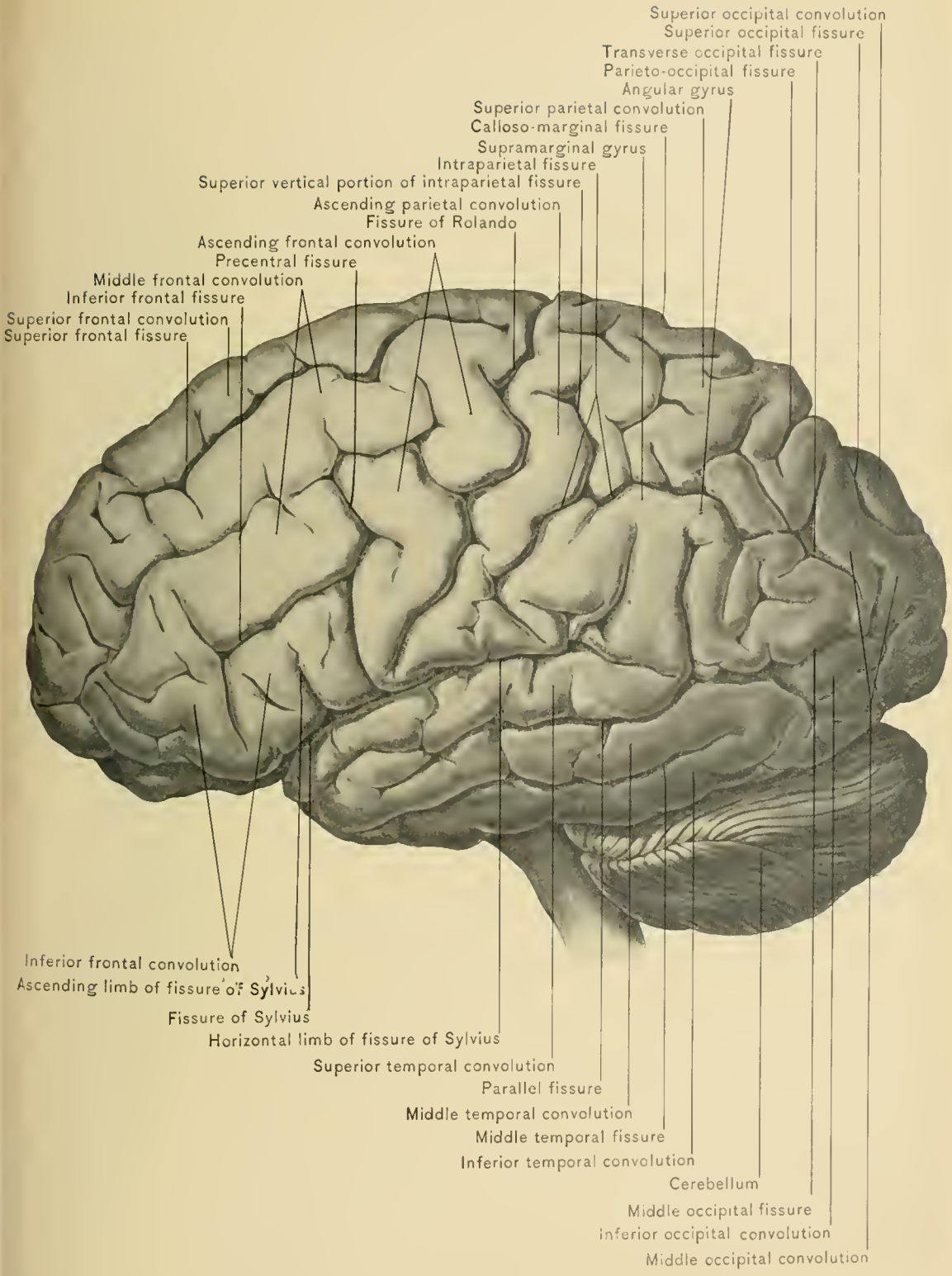
The **parieto-occipital fissure**, the smallest of the three primary fissures of the cerebrum, commences on the median surface of the hemisphere of the cerebrum about one and one-half inches, or thirty-seven millimeters, behind the corpus callosum. It begins on the inferior occipito-temporal surface at the junction of the apex of the lingual lobule with the isthmus of the gyrus fornicatus, and runs backward and upward to reach the upper border of the hemisphere; thence it runs outward and forward on the external or convex surface for about one inch, or twenty-five millimeters, and midway between the fissure of Rolando and the posterior extremity of the cerebrum. It is joined by a secondary fissure, the *calcarine*, the direction of which is nearly horizontal. The fissure may be said to consist of two portions, a median and a lateral, found respectively on the median and external surfaces of the cerebrum. The first occipital convolution arches around the end of the lateral portion of the fissure. The lateral portion of the parieto-occipital fissure is not always well marked, often appearing merely as a slight indentation upon the outer or convex surface of the hemisphere, while the median portion of the fissure is uniformly well developed.

The **Frontal Lobe**, the largest of the cerebral lobes, includes that portion of

the hemisphere of the cerebrum in front of and above the main portion of the fissure of Sylvius, and that portion in front of the fissure of Rolando; upon the inner surface it includes the corresponding portion of the hemisphere above the calloso-marginal fissure. There is generally no line of demarcation between the frontal and parietal lobes upon the mesial surface of the hemisphere, but extension of the fissure of Rolando into the longitudinal fissure (a condition sometimes existing) designates the posterior limit of the frontal lobe on this surface.

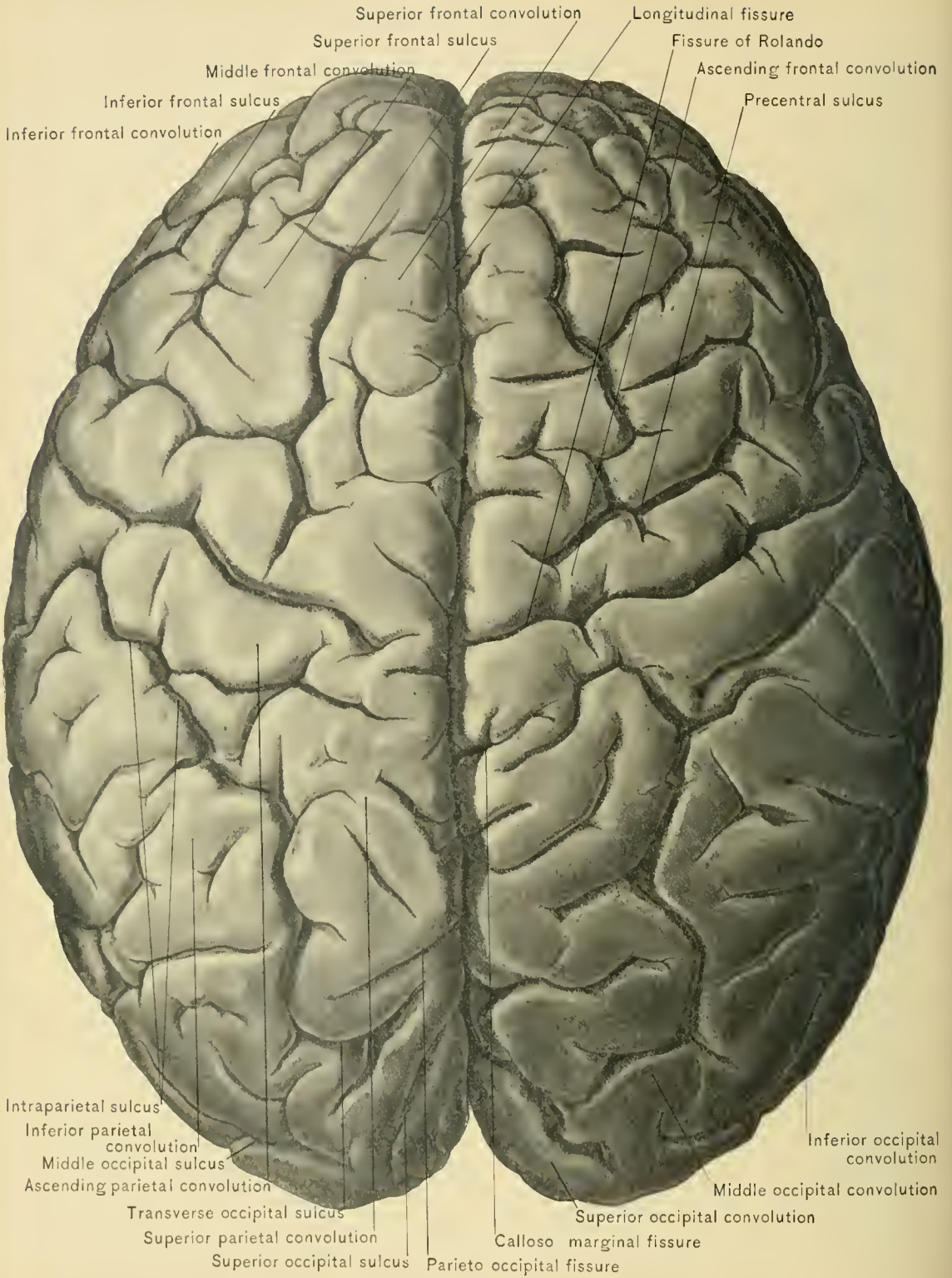The **Parietal Lobe** includes that portion of the lateral surface of the hemisphere of the cerebrum above the horizontal limb of the fissure of Sylvius, and a line representing the extension of the same limb backward to meet the posterior boundary of the lobe; also behind the fissure of Rolando and in front of the lateral portion of the parieto-occipital fissure. Upon the inner surface it includes that part of the hemisphere in front of the mesial portion of the parieto-occipital fissure; it is unlimited in front on this surface for want of a line of demarcation between it and the frontal lobe, but, as previously stated, by extending the fissure of Rolando into the longitudinal fissure, its anterior superior limit would be represented. The parietal lobe is only partly separated behind from the occipital lobe, by the lateral portion of the parieto-occipital fissure and the transverse occipital fissure; the latter is a secondary fissure which is not always present. From the temporo-sphenoid lobe, below, there is no attempt at complete separation. At the lower margin of the lateral surface of the hemisphere of the cerebrum, between the occipital and temporo-sphenoid lobes, is the *preoccipital notch* produced by the impression of the veins which enter the lateral sinus. If a line be drawn to this notch from the extremity of the lateral portion of the parieto-occipital fissure, the upper part of this line, with the lateral portion of the fissure, will about represent the junction of the parietal and occipital lobes. The lower part of the line will represent the line of junction of the occipital and temporo-sphenoid lobes. This notch must not be confounded with another impression, sometimes described as the preoccipital notch, produced by the superior border of the petrous portion of the temporal bone (Brooks).

The **Occipital Lobe** includes that portion of the convex surface of the hemisphere of the cerebrum behind the lateral portion of the parieto-occipital fissure, and a line connecting the extremity of this fissure with the preoccipital notch. Upon the inner surface of the hemisphere it includes that part behind the mesial portion of the parieto-occipital fissure. Upon the basilar surface there is no line of demarcation between it and the temporo-sphenoid lobe. The inferior surface of this lobe will be described with the same surface of the temporo-sphenoid, as two of the most important secondary fissures here seen occupy both of these lobes, and extend without breach of continuity from one to the other.



EXTERNAL SURFACE OF CEREBRUM.





SUPERIOR SURFACE OF CEREBRUM.

The **Temporal** or **Temporo-sphenoid Lobe** comprises that portion of the lateral surface of the hemisphere of the cerebrum below the horizontal limb of the fissure of Sylvius, and a line representing its continuation backward, and in front of the lower part of the line connecting the preoccipital notch with the extremity of the lateral portion of the parieto-occipital fissure. Upon the inferior surface of the cerebral hemisphere it lies immediately behind the main portion of the fissure of Sylvius; it is not separated on this surface from the occipital lobe. A line drawn from the preoccipital notch to the isthmus of the gyrus fornicatus marks the line of union of the temporo-sphenoid and occipital lobes (Brooks).

The **Island of Reil**, or the fifth lobe of the cerebrum, is described with the fissure of Sylvius.

The arrangement of the primary fissures and the boundaries of the lobes of the cerebral hemispheres having been given, the description of the secondary fissures and convolutions naturally follows. Secondary convolutions frequently bridge these secondary fissures, making it difficult to trace them.

The **Frontal Lobe** is situated in the angle between the vertical and the horizontal plates of the frontal bone, and extends backward beyond the coronal suture. It is that portion of the hemisphere in front of the fissure of Rolando, and above the anterior part of the horizontal limb of the fissure of Sylvius. Like the cerebral hemisphere, it has three surfaces: a lateral or convex, an inferior or basilar, and an inner or mesial. Upon the lateral surface are three secondary fissures: the superior and the inferior frontal, the direction of which is horizontal, and the precentral or transverse, whose direction is vertical. The ascending and the anterior limbs of the fissure of Sylvius are also in relation with it. The superior and inferior frontal fissures run parallel with the longitudinal, and the precentral follows a course nearly parallel with that of the lower half of the fissure of Rolando.

The **superior frontal fissure** commences a short distance in front of the fissure of Rolando, and runs forward and downward parallel with the longitudinal fissure, the gyrus included between the longitudinal fissure and superior frontal fissure being the first or superior frontal convolution.

The **inferior frontal fissure** usually commences in the precentral fissure, but sometimes in front of it, and runs forward and downward about midway between the superior frontal fissure and the lower border of the frontal lobe. Between the superior and the inferior frontal fissure lies the middle or second frontal convolution, and between the inferior frontal fissure and the lower margin of the lobe the inferior frontal convolution is situated.

The **precentral fissure** lies in front of and parallel with the fissure of

Rolando; its lower end is between the latter fissure and the ascending limb of the fissure of Sylvius. This fissure usually consists of two parts, a superior and an inferior precentral fissure, the former of which is, as a rule, continuous with the superior frontal fissure, and the inferior at times with the inferior frontal fissure.

The **ascending frontal convolution** is situated between the precentral fissure and the fissure of Rolando, and extends along the entire anterior border of the latter fissure. This convolution is continuous with the ascending parietal convolution around both ends of the fissure of Rolando, immediately behind which the latter convolution is situated.

The **superior or first frontal convolution** is continuous posteriorly with the ascending frontal, internally with the marginal, and anteriorly upon the basilar surface with the gyrus rectus and the internal and anterior orbital convolutions.

The **middle or second frontal convolution** is continuous in front with the anterior orbital convolution and the anterior extremities of the superior and inferior frontal convolutions. Posteriorly, it frequently bridges the precentral fissure, and joins the ascending frontal convolution.

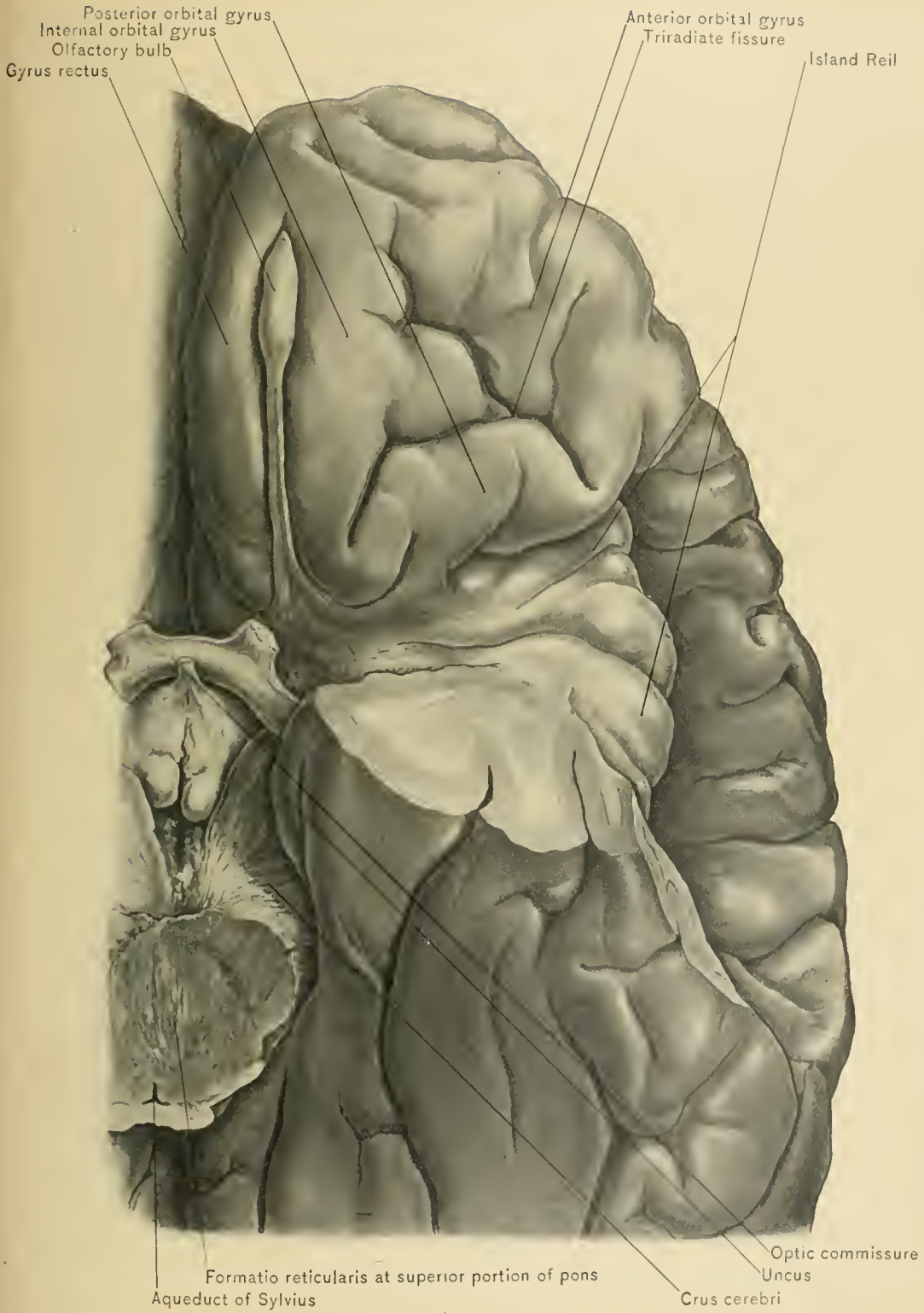
The **inferior or third frontal convolution** is continuous behind with the ascending frontal convolution, and in front, upon the inferior or basilar surface, with the anterior and posterior orbital convolutions. Through the medium of the anterior and ascending limbs of the fissure of Sylvius, both of which extend into this convolution, it is divided into three parts: namely, that in front of the anterior limb, the pars orbitalis; that between the anterior and the ascending limb, the pars triangularis (base of triangle looks upward); and that behind the ascending limb, the pars basilaris (Brooks). This convolution, as before mentioned, assists in the formation of the operculum.

The **inferior or orbital surface** of the frontal lobe is triangular in shape; the base, directed backward, is formed by the anterior perforated space and the main portion of the fissure of Sylvius. The apex is directed forward, and is formed by the curving of the convolutions in passing from the convex to the orbital surface. The sides are formed by the longitudinal fissure and the lower border of the hemisphere. On this surface are two secondary fissures, the olfactory and the orbital.

The **olfactory fissure** runs parallel with the longitudinal fissure and a short distance external to it. It lodges the olfactory tract and bulb.

The **orbital or triradiate fissure** is situated about the middle of the portion of this surface, which lies external to the olfactory fissure. It consists of a main portion, which is directed forward and runs nearly parallel with the olfactory fissure, and of two branches, one directed backward and inward, and the other outward.

The **gyrus rectus** is situated between the olfactory and longitudinal fissures.



INFERIOR SURFACE OF FRONTAL LOBE.



It is continuous in front with the superior or first frontal convolution, and internally with the marginal convolution.

The **internal, anterior, and posterior orbital gyri** are located between the branches of the triradiate fissure, and are named from their relation to the branches of the fissure. They are continuous respectively with the first, second, and third frontal convolutions.

Inner surface of the frontal lobe.—Upon this surface are tertiary fissures, the chief of which runs for some distance parallel with the calloso-marginal fissure, and partly divides the convolution of this surface into two portions.

The **marginal gyrus** lies between the calloso-marginal fissure and the upper and anterior margin of the hemisphere of the cerebrum. This convolution commences below the rostrum of the corpus callosum at the anterior perforated space, and extends upward and backward between the calloso-marginal fissure and the margin of the hemisphere, as far as a line which represents the continuation of the precentral fissure into the longitudinal fissure. It is continuous along the margin of the hemisphere with the superior or first frontal convolution.

The **Parietal Lobe** is that portion of the hemisphere situated behind the fissure of Rolando, above the horizontal limb of the fissure of Sylvius, and in front of the lateral limb of the parieto-occipital fissure. The portion of the lobe below the lateral limb of the parieto-occipital fissure and beyond the termination of the horizontal limb of the fissure of Sylvius is continuous with the occipital lobe by means of *annectant gyri*. The limit of the parietal lobe behind is represented by the lateral limb of the parieto-occipital fissure, and a line previously described, which extends from the end of that fissure to the preoccipital notch. It presents two surfaces, a lateral or convex, and an inner or mesial.

Upon the *lateral surface* one and sometimes two chief secondary fissures are to be seen. When but one fissure is present, it is the intra-parietal, and when two fissures are present, they are the intra-parietal and the post-central.

The **intra-parietal fissure** commences above the horizontal limb of the fissure of Sylvius, a short distance behind the fissure of Rolando, and runs upward, parallel to the lower portion of the latter fissure; it then turns backward, runs nearly parallel with the longitudinal fissure, and terminates in the occipital lobe, most commonly in the transverse occipital fissure. The posterior portion of the horizontal part of the intra-parietal fissure is often separated from the main fissure by a bridging convolution.

The **post-central fissure**, when present, exists either as a continuation of the ascending limb of the intra-parietal fissure beyond the junction of the ascending with the horizontal limb, thus making the intra-parietal fissure T shaped, or it is entirely separated from the ascending limb of the intraparietal fissure. The

former is the arrangement more commonly seen. The post-central fissure runs parallel to the upper portion of the fissure of Rolando almost to the longitudinal fissure.

CONVOLUTIONS.—Through the medium of the intra-parietal fissure or of the intra-parietal and post-central fissures the lateral surface of the parietal lobe is divided into three principal convolutions: the ascending parietal or post-central, the superior parietal, and the inferior parietal. The inferior parietal convolution is further subdivided into the supra-marginal and angular convolutions.

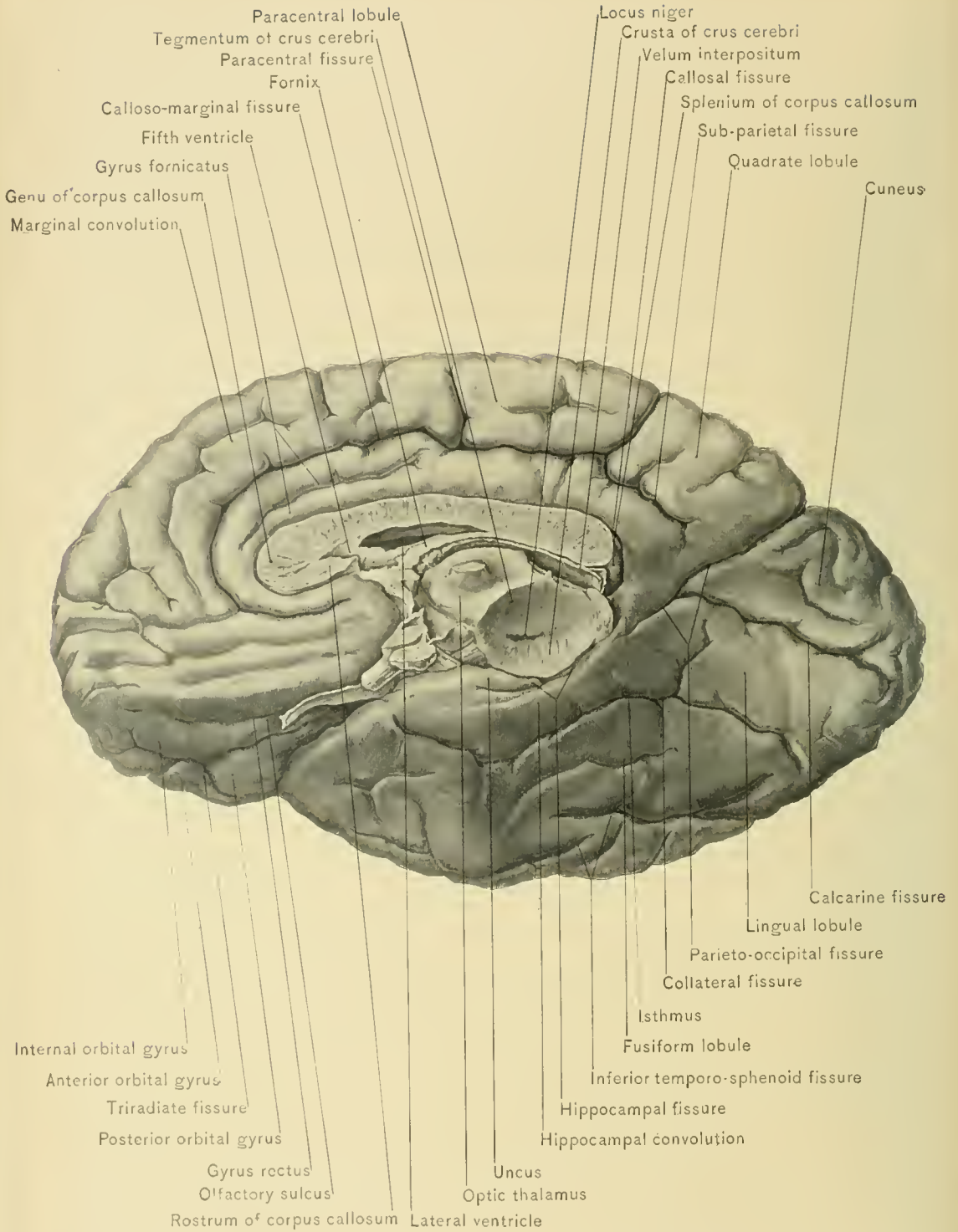
The **ascending parietal** or **post-central convolution** lies immediately behind the fissure of Rolando, in front of the ascending limb of the intra-parietal fissure, and the post-central fissure when present, and above the horizontal limb of the fissure of Sylvius. It is continuous with the ascending frontal convolution around the ends of the fissure of Rolando, and with the superior parietal convolution. It runs parallel with the ascending frontal convolution; its lower extremity extends to the horizontal limb of the fissure of Sylvius, forming the posterior part of the operculum; its upper extremity is limited by the longitudinal fissure, and, with the corresponding end of the ascending frontal convolution, forms the paracentral lobule.

The **superior parietal convolution** lies behind the ascending parietal convolution, with which it is continuous. It is situated between the longitudinal fissure and the horizontal limb of the intra-parietal fissure, and extends posteriorly as far as the lateral portion of the parieto-occipital fissure. Around the extremity of this fissure it is continuous with the first occipital convolution through the medium of the first annectant gyrus. On the mesial aspect of the hemisphere it is continuous with the quadrate lobule or preuncus.

The **inferior parietal convolution** lies behind the ascending limb and below the horizontal limb of the intra-parietal fissure, and above the horizontal limb of the fissure of Sylvius. Posteriorly it is connected with the second occipital convolution by means of the second and third annectant gyri, and also with the superior temporal and the middle temporal convolution. It is subdivided into two convolutions, the supra-marginal and the angular.

The *supra-marginal convolution* includes the anterior portion of the inferior parietal as far as the posterior extremity of the horizontal limb of the fissure of Sylvius. It winds around this limb and becomes continuous with the superior temporal convolution and the angular convolution.

The *angular convolution* is the posterior portion of the inferior parietal convolution; it lies behind the terminal part of the horizontal limb of the fissure of Sylvius as it inclines upward. It winds around the posterior end of the superior temporal fissure, and becomes continuous with the second occipital convolution



MEDIAN AND INFERIOR SURFACES OF CEREBRUM.

through the medium of the second and third annectant gyri. It is also continuous with the middle temporal convolution.

The post-parietal convolution.—In some brains the middle temporo-sphenoid fissure terminates in the inferior parietal convolution, and with the fissure of Sylvius and the superior temporo-sphenoid, or parallel, fissure divides this convolution into three, as follows: that winding around the extremity of the horizontal limb of the fissure of Sylvius forms the supra-marginal gyrus; that around the posterior extremity of the superior temporo-sphenoid fissure, the angular gyrus; and that around the posterior extremity of the middle temporo-sphenoid fissure, the post-parietal gyrus. The last-mentioned convolution is continuous with the third occipital convolution (Heath).

Upon the inner or median surface of the parietal lobe the terminal part of the **calloso-marginal fissure**, one of the most important secondary fissures, is seen and is mentioned in describing the fissure of Rolando. This fissure commences below the anterior extremity, or rostrum, of the corpus callosum. Thence it runs parallel to, and a short distance above, the corpus callosum, from which it is separated by the convolution of the corpus callosum or gyrus fornicatus, to nearly opposite the posterior extremity or splenium of the corpus callosum. Here it turns upward and pursues a slightly backward course, terminating on the superior border of the hemisphere of the cerebrum, immediately posterior to the fissure of Rolando. The calloso-marginal fissure, particularly the anterior part, is frequently bridged over by small convolutions.

The **subparietal fissure** is a much smaller fissure, which commences at the point where the terminal portion of the calloso-marginal fissure begins to turn upward. For all practical purposes it may be considered the continuation backward of the main portion of the calloso-marginal fissure.

The **paracentral fissure**, not always present, is a small tertiary fissure running out of the main portion of the calloso-marginal, on a line with the anterior limit of the median end of the ascending frontal convolution. When present, it marks definitely the posterior limit of the marginal convolution.

CONVOLUTIONS.—Through the medium of the calloso-marginal, paracentral, subparietal, and parieto-occipital fissures the inner surface of the parietal lobe is divided into two lobules or convolutions—the precuneus, or quadrate, and the paracentral, the former being posterior to the latter.

The **precuneus**, or **quadrate lobule**, lies between the median limb of the parieto-occipital and the terminal portion of the calloso-marginal fissure and above the subparietal fissure.

The **paracentral convolution** includes the median ends of the ascending parietal and ascending frontal convolutions. It lies immediately in front of the

terminal portion of the callosomarginal fissure, above the horizontal portion of this fissure, and behind the paracentral fissure, or a line representing the extension of the precentral fissure of the frontal lobe into the longitudinal fissure.

The **Occipital Lobe** forms the posterior extremity of the hemisphere of the cerebrum, and is next to the smallest of the five divisions of the hemisphere of the cerebrum—the island of Reil being still smaller. It is triangular in shape, with its base directed forward and its apex backward; it fills the superior fossa of the occipital bone, and rests upon the tentorium cerebelli. It presents three surfaces: a lateral or convex, an inner or mesial, and a tentorial or basilar surface. Owing to the absence of a distinct line of demarcation the lateral surface of the occipital lobe is continuous with the corresponding surface of the parietal and temporo-sphenoid lobes, and the basilar surface of this lobe with the corresponding surface of the temporo-sphenoid lobe. The inner surface of the occipital lobe is clearly marked off from the corresponding surface of the parietal lobe by the median limb or main portion of the parieto-occipital fissure. A line drawn from the extremity of the lateral limb of the parieto-occipital fissure over the external surface of the hemisphere to the preoccipital notch, and continued across the basilar surface to meet the end of the median limb of this fissure, will practically mark off the anterior limit of this lobe upon these two surfaces.

In studying the convolutions comprising the different lobes of the cerebrum, those of the occipital are the most difficult to understand. Upon the lateral surface of this lobe are three horizontal fissures, the superior, the middle, and the inferior occipital, with sometimes a fourth fissure, vertical in direction, and known as the transverse occipital fissure. The transverse and the superior occipital fissure, the least variable of the four fissures, are the most important in tracing the convolutions of this surface.

The **transverse occipital fissure**, into which the intra-parietal frequently opens, runs over the lateral surface of the lobe a short distance behind the terminal portion of the lateral limb of the parieto-occipital fissure.

The **superior occipital fissure** runs from before backward as though it were a continuation of the horizontal limb of the intra-parietal fissure.

The **middle occipital fissure** is seldom well developed, and extends from before backward.

The **inferior occipital fissure** is frequently interrupted by bridging convolutions, and runs from before backward along the line of junction of the lateral and basilar surfaces of the lobe.

CONVOLUTIONS.—Through the medium of the superior, middle, and inferior occipital fissures the lateral surface of the occipital lobe is divided into the superior or first, the middle or second, and the inferior or third occipital convolution.

The **superior occipital convolution** lies between the longitudinal and superior occipital fissures, and commences at the posterior end of the superior parietal convolution, to which it is connected by the first annectant gyrus. It then winds around the extremity of the lateral limb of the parieto-occipital and the mesial end of the transverse occipital fissure, when present, and becomes continuous with the cuneus, a wedge-shaped lobule seen upon the inner surface of the lobe.

The **middle occipital convolution** lies between the superior and middle occipital fissures, and commences at the outer side of the intra-parietal fissure, and behind the angular gyrus, to which it is connected by the second and third annectant gyri.

The **inferior occipital convolution** lies between the middle and inferior occipital fissures, and is connected to the inferior or third temporo-sphenoid convolution by the fourth annectant gyrus.

Upon the inner surface of the occipital lobe there is but one secondary fissure, the calcarine, and one lobule, the cuneus.

The **calcarine fissure** commences, usually, by two branches close to the lower border of the posterior extremity of the hemisphere of the cerebrum, runs almost horizontally forward along the margin formed by the median and basilar surfaces of the hemisphere, and joins the parieto-occipital fissure at an acute angle behind and below the posterior extremity of the corpus callosum. This fissure gives rise to a prominence, the calcar avis or hippocampus minor, seen in the posterior horn of the lateral ventricle.

The **cuneus** is a triangular lobule situated between the median limb or main portion of the parieto-occipital fissure and the calcarine fissure. Its base is directed upward and backward, and is formed by the inner border of the superior occipital convolution; its apex is directed downward and forward, and corresponds to the angle of union of the calcarine and parieto-occipital fissures.

The fissures and convolutions of the basilar surface of the occipital lobe are uninterruptedly continuous with those of the corresponding surface of the temporo-sphenoid lobe, and therefore the inferior surface of these two lobes will be studied as the lower occipito-temporal surface.

The **Temporal or Temporo-sphenoid Lobe** is that part of the hemisphere of the cerebrum which extends into the middle cranial fossa, its posterior portion resting upon the tentorium cerebelli. It lies behind the commencement of the basilar or main portion of the fissure of Sylvius, in front of a line drawn over the lateral surface of the hemisphere of the cerebrum from the extremity of the lateral limb of the parieto-occipital fissure to the preoccipital notch, and below the horizontal limb of the fissure of Sylvius and a line representing its continuation

backward. The posterior portion of this lobe is continuous with the parietal and occipital lobes, as mentioned under the description of those lobes.

SURFACES.—The temporo-sphenoid lobe presents an external, lateral or convex and an inferior or basilar surface. In addition some anatomists describe an upper or Sylvian surface in relation with the horizontal limb of the fissure of Sylvius. Upon the lateral surface are three secondary fissures which run horizontally: the superior temporo-sphenoid or parallel fissure, the middle temporo-sphenoid, and the inferior temporo-sphenoid fissure. Of these fissures, the superior temporo-sphenoid or parallel is the most constant, and lies entirely on the lateral surface, while the middle and the inferior are much more variable. They are seldom developed with equal clearness, and are frequently interrupted and bridged by convolutions. The middle temporo-sphenoid fissure lies almost entirely on the lateral surface, while the greater part of the inferior temporo-sphenoid fissure is on the basilar surface.

The **superior temporo-sphenoid** or **parallel fissure** commences near the anterior extremity or apex of the lobe. It then runs backward and upward, parallel with the horizontal limb of the fissure of Sylvius,—hence the name of parallel fissure,—and terminates in the inferior parietal convolution, its posterior extremity being surrounded by the angular convolution.

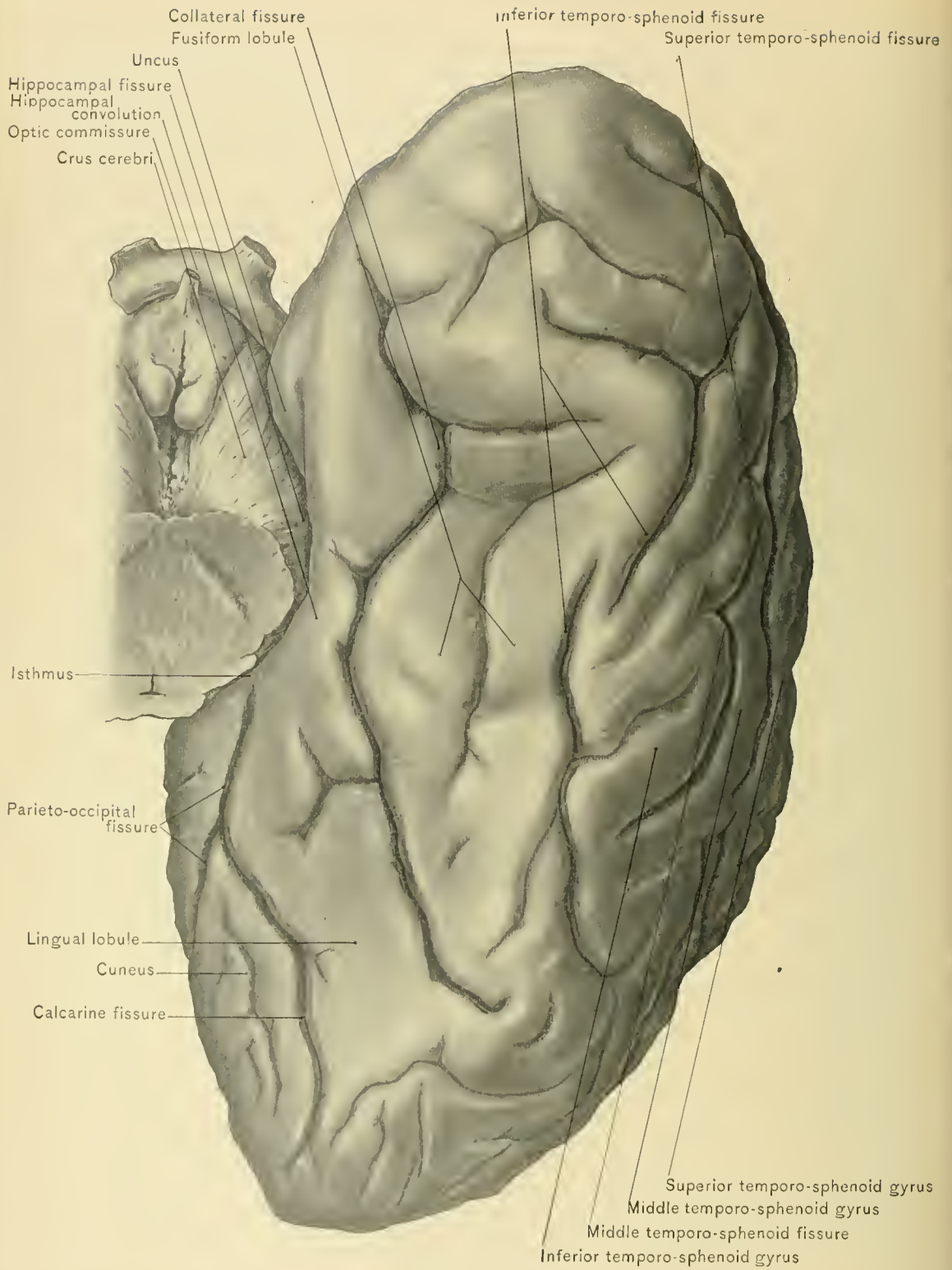
The **middle temporo-sphenoid fissure** commences on the basilar surface of the lobe, and runs upward and backward, parallel with the superior temporo-sphenoid fissure. It terminates in the inferior parietal convolution, its posterior extremity being surrounded by the post-parietal convolution.

The **inferior temporo-sphenoid fissure** lies in great part on the basilar surface, near the margin of the hemisphere, and terminates posteriorly on the lateral surface; it separates the inferior temporo-sphenoid convolution from the lateral occipito-temporal convolution or fusiform lobule.

CONVOLUTIONS.—Through the medium of the superior, middle, and inferior temporo-sphenoid fissures the lateral surface of the temporo-sphenoid lobe is divided into three convolutions: the superior temporo-sphenoid, the middle temporo-sphenoid, and the inferior temporo-sphenoid convolution.

The **superior temporo-sphenoid** or **infra-marginal convolution** lies between the horizontal limb of the fissure of Sylvius and the parallel fissure; it is continuous at its posterior part with the supra-marginal and angular convolutions.

The **middle temporo-sphenoid convolution** lies between the parallel fissure and the middle temporo-sphenoid fissure, being clearly marked off above by the parallel fissure. Its lower boundary is by no means so constantly well marked, and it is frequently continuous with the inferior temporo-sphenoid convolution. It is continuous posteriorly with the angular convolution.



INFERIOR SURFACE OF OCCIPITAL AND TEMPORAL LOBES.

The **inferior temporo-sphenoid convolution** lies along the lateral margin of the hemisphere, between the middle temporo-sphenoid fissure and the inferior temporo-sphenoid fissure; it passes above the preoccipital notch, and is continuous behind with the third occipital convolution. Upon the basilar surface of the lobe it is continuous with the external occipito-temporal convolution, or fusiform lobule.

The **upper or Sylvian surface of the temporo-sphenoid lobe** is in contact with the operculum, and intimately related to the island of Reil; it presents two or three transverse convolutions.

The fissures and convolutions presenting on the *basilar surface* being continuous with those of the occipital lobe, they will be described as part of the lower occipito-temporal surface.

Collateral fissure.—The basilar surface of the temporo-sphenoid lobe contains the greater portion of the inferior temporo-sphenoid fissure, as previously described. That portion of this surface which is continuous with the occipital lobe, and designated as the lower occipito-temporal surface, presents a constant and important secondary fissure, the inferior occipito-temporal or collateral fissure. This commences at the posterior extremity of the occipital lobe; thence it runs forward parallel to and below the calcarine fissure, nearly to the apex of the temporo-sphenoid lobe, extending almost as far as the commencement of the Sylvian fissure. It is sometimes bridged over by a secondary convolution. It produces the eminentia collateralis, a prominence in the floor of the descending cornu of the lateral ventricle, seen at the point of divergence of the middle and posterior cornua of the ventricle. Through the medium of the collateral and hippocampal fissures the lower occipito-temporal surface is divided into three convolutions: the fusiform lobule, the lingual lobule, and the hippocampal or uncinate convolution. The hippocampal convolution and the lingual lobule are but portions of the internal or mesial occipito-temporal convolution.

The **lingual lobule** lies between the collateral fissure on the outer side, and the calcarine fissure on the inner side. It occupies chiefly the occipital part of the lower occipito-temporal surface. It is wide behind and narrow in front.

The **hippocampal or uncinate convolution** lies between the collateral fissure on the outer side and the hippocampal on the inner side. It is formed by the union of the isthmus or posterior continuation of the gyrus fornicatus with the lingual lobule at the anterior extremity of the mesial limb of the parieto-occipital fissure. It continues forward, bordering the hippocampal fissure and embracing the crura cerebri, to terminate immediately behind the anterior perforated space by turning upward and backward upon itself in the *uncus*.

The **external or lateral occipito-temporal convolution, or fusiform lobule**, lies between the collateral fissure on the inner side, and the inferior temporo-

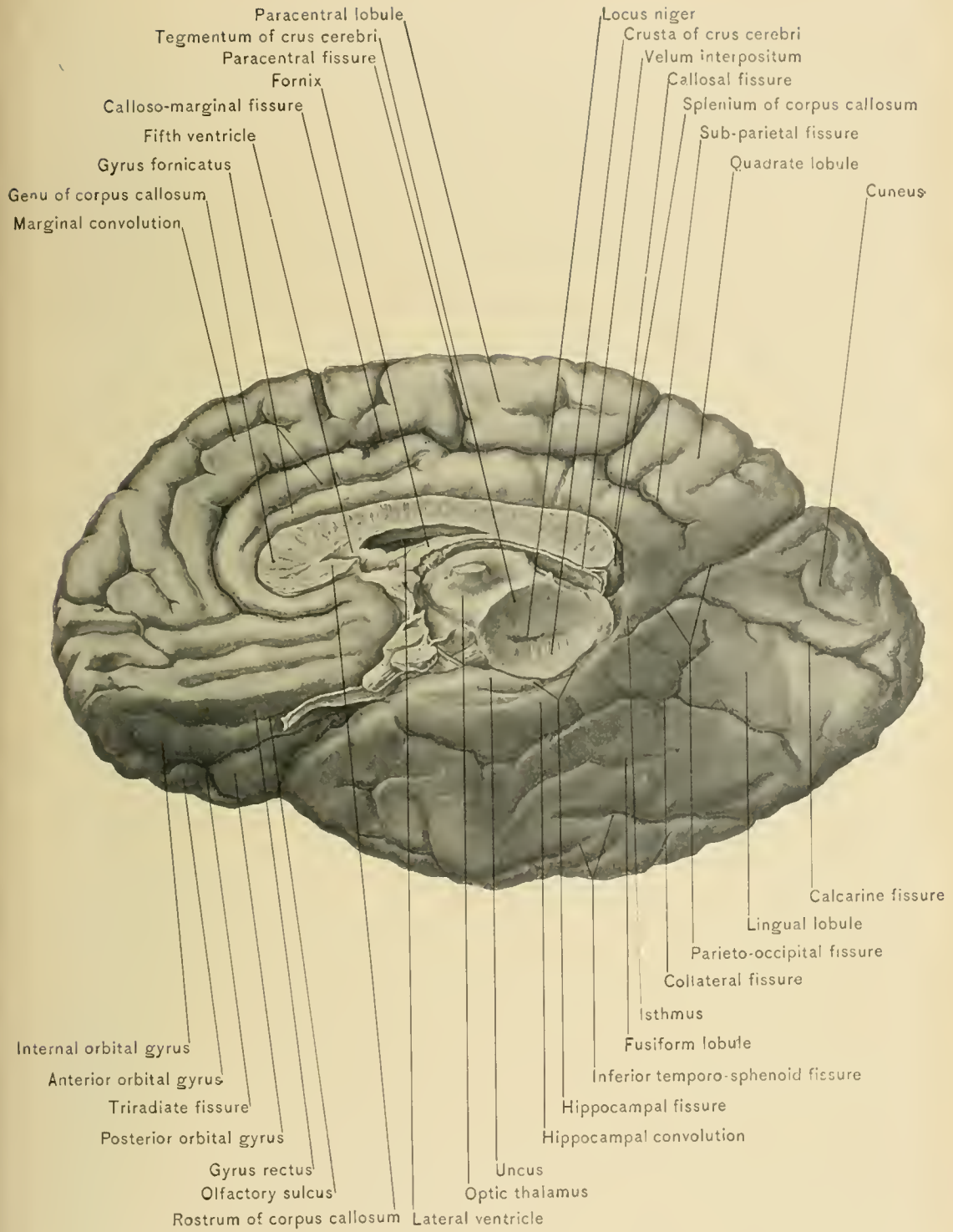
sphenoid fissure, when present, on the outer side. When the inferior temporo-sphenoid fissure is wanting or is incomplete, the lateral boundary of this convolution is indistinct. It extends from the apex of the temporo-sphenoid lobe to the posterior extremity of the occipital lobe.

The **hippocampal** or **dentate fissure**, previously mentioned as being bordered by the hippocampal convolution, corresponds to the lateral portion of the transverse fissure of Bichat. It is situated in front of the calcarine fissure, between the crura cerebri and the hippocampal convolution, and extends outward, downward, and forward from the splenium of the corpus callosum to the uncus. It produces the cornu Ammonis or hippocampus major, a prominence forming part of the inner wall of the middle cornu of the lateral ventricle. By drawing the hippocampal convolution away from the crus cerebri, thus widening the hippocampal fissure, there will be seen a band of gray matter which reaches from the splenium of the corpus callosum to the uncus. This is the free edge of the hippocampal convolution, and its notched appearance is produced by the choroid arteries, which pass through the fissure with the pia mater into the descending horn of the lateral ventricle; this gray matter is known as the *fascia dentata*, or the *dentate convolution*.

The remaining fissures seen on the inner surface of the hemisphere of the cerebrum are the calloso-marginal and the callosal fissure, and the remaining convolution is the gyrus fornicatus.

The **calloso-marginal fissure**, the terminal portion of which was mentioned when describing the location of the fissure of Rolando, commences below the rostrum of the corpus callosum, curves forward around the genu, and backward above the body of the corpus callosum. It runs about midway between the corpus callosum and the upper border of the hemisphere to a point opposite the splenium of the corpus callosum, where it turns upward and slightly backward to terminate on the upper border of the hemisphere of the cerebrum, immediately behind the commencement of the fissure of Rolando. From the point where the fissure turns upward to reach the margin of the hemisphere there is frequently found, following the original direction of the calloso-marginal, a small fissure which separates the quadrate lobule from the gyrus fornicatus. This, under the name of the subparietal fissure, is a branch of the calloso-marginal, as is also the paracentral fissure. The calloso-marginal fissure is not infrequently bridged over in places by secondary convolutions which connect the marginal gyrus with the gyrus fornicatus.

The **callosal fissure**, or ventricle of the corpus callosum, commences below the rostrum, follows the superior surface of the corpus callosum, and terminates behind the splenium of the corpus callosum in the hippocampal fissure.



MEDIAN AND INFERIOR SURFACES OF CEREBRUM.



The **gyrus fornicatus** lies between the calloso-marginal fissure and the callosal fissure. It commences in front of the anterior perforated space, between the rostrum of the corpus callosum and the marginal convolution, follows the superficial surface of the corpus callosum, and terminates below the splenium of the corpus callosum in a narrow extremity, the *isthmus*, which joins the hippocampal convolution.

The **Limbic Lobe** includes a number of convolutions arranged in a ring-like manner; some of the parts are quite rudimentary in the human brain, and are the representatives of more highly developed structures in some of the lower animals. The limbic lobe is made up of the gyrus fornicatus, hippocampal gyrus, the rudimentary gyrus supra-callosus of Zuekerkandl (formed by the peduncles of the corpus callosum, fascia dentata, and the longitudinal strie on the upper surface of the corpus callosum), together with half of the fornix and the corresponding lamina of the septum lucidum. This lobe is bounded by the calloso-marginal and collateral fissures, and each extremity of it is continuous with one of the roots of the olfactory tract.

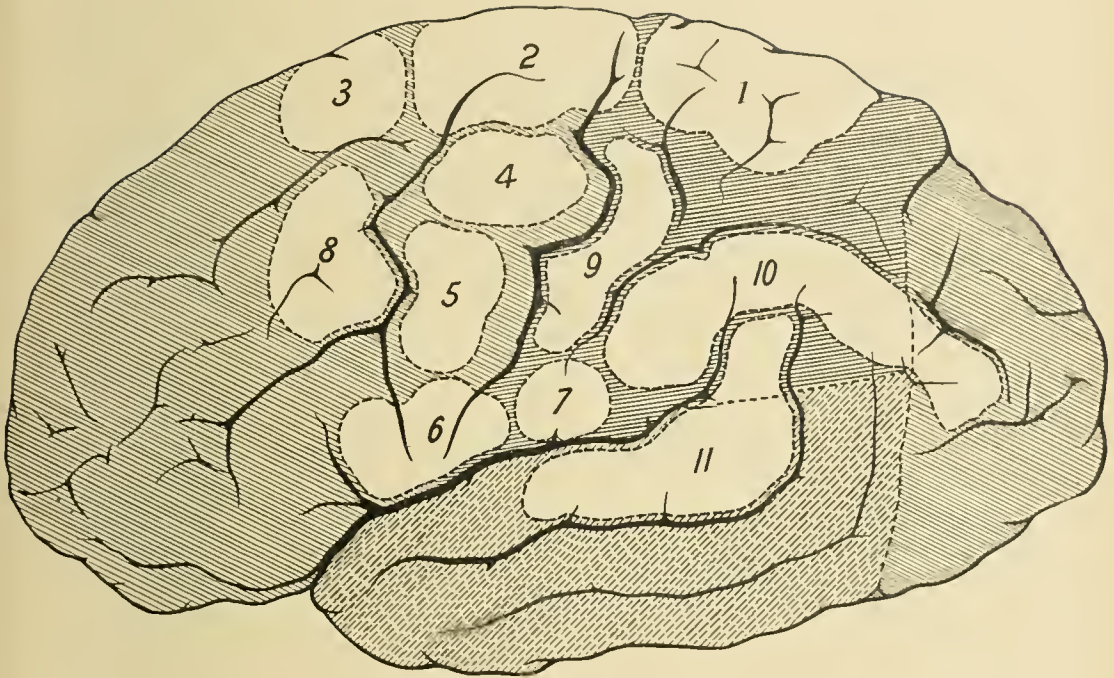
CRANIO-CEREBRAL TOPOGRAPHY.

Sensory and Motor Areas.—Having completed the study of the fissures, the lobes, and the convolutions of the hemisphere of the cerebrum, consider the functions of the convolutions in certain areas of the surfaces of the cerebrum before commencing the dissection of that part of the brain. The two principal regions of the hemisphere are the motor area and the sensory area. The motor area comprises the posterior ends of the superior, middle, and inferior frontal convolutions, the ascending frontal convolution, the ascending parietal convolution, and the adjoining part of the superior parietal convolution. The sensory area of the surface of the cerebrum has been imperfectly outlined on account of the greater difficulty attending its localization.

The Silent Region.—The anterior two-thirds of the superior, middle, and inferior frontal convolutions, or that portion of the frontal lobe which practically lies in advance of the coronal suture with the brain in its natural position, is the *prefrontal* or *silent region* of the brain, where, if a lesion be present, it does not give rise to any localizing symptoms. The author has frequently seen the prefrontal region severely injured in gunshot wounds with entire absence of any paralytic symptoms. He has also seen cases of abscess of this region with similar absence of any localizing symptoms. One case in particular in his experience was that of a large abscess of the left prefrontal region, which followed a punctured fracture of the cribriform plate of the ethmoid bone. The patient was a boy, who, while playing with a hoisted umbrella, threw it up in the air. In its descent it turned,

and a portion of one of the ribs passed into his left nostril and penetrated the cranial cavity, fracturing the cribriform plate of the ethmoid bone, tearing through the dura mater, and finally entering the frontal lobe. A brain abscess developed—so considered at the time and afterward proved by autopsy. The collection occupied the left prefrontal lobe, and at no time in the course of the disease were there any localizing symptoms. The function over which this region of the brain is believed to preside is that of the higher mental faculties, and in disease or injury of this region, particularly upon the left side, there is very apt to be more or less hebetude, dullness of intellect, and lack of self-control.

Motor Centers.—The motor area embraces the centers which preside over the movements of the opposite side of the body, and is conveniently divided into thirds—an upper, a middle, and a lower. The upper third includes the centers which control the movements of the muscles of the lower extremity; the middle third, the centers which control the movements of the muscles of the upper extremity; and the lower third, the centers which control the movements of the muscles of the face, the mouth, and the tongue. It would seem from recent investigation that the centers for *tactile sensation* are located in the same area as that occupied by the motor centers, for some loss of tactile sense may accompany motor paralysis; hence the centers about to be described are at times referred to as the sensori-motor areas. There is some evidence in favor of locating the centers for *muscular sense* in the region just posterior to the motor area, in the neighborhood of the great longitudinal fissure. The following is a detailed description of the location of the individual centers of the motor and sensory areas (Ferrier): The centers which control the movements of the opposite leg and foot, such as are concerned, for example, in walking, are situated in the anterior part of the superior parietal convolution, at its junction with the ascending parietal, in the paracentral lobule and part of the quadrate lobule. The upper part of the ascending frontal convolution with the neighboring part of the base of the superior frontal convolution include the centers which control the various complex movements of the arms and legs, such as climbing, swimming, etc. The posterior third of the superior frontal convolution anterior to the junction of its base with the ascending frontal includes the centers for the forward extension of the arm and hand, as in reaching forth the hand to touch something in front. The upper part of the middle third of the ascending frontal convolution includes the centers for those movements of the hand and forearm which call into action the biceps, as supination of the hand and flexion of the forearm. The ascending frontal convolution, at about the junction of its middle and lower thirds, includes the centers which control the action of the elevators and depressors of the angle of the mouth.



Centers for (1) Opposite leg and foot, as in walking. (2) Arms and legs, as in climbing or swimming. (3) Forward extension of arm and hand. (4) Supination of hand and flexion of forearm. (5) Elevators and depressors of angle of mouth. (6) Lips and tongue in talking. (7) Platysma myoides muscle. (8) Lateral movement of head and eyes, elevation of eyelids, and dilatation of pupil. (9) Movement of fingers and wrist. (10) Vision. (11) Hearing.

The base of the third frontal convolution and, to a slight degree, the lower end of the ascending frontal and ascending parietal convolutions include the centers for the movements of the lips and tongue in talking. This region is known as *Broca's region*, disease of which on the left side causes aphasia, or loss of the power of speech. The speech center, however, is not always in the left side of the brain. In left-handed persons it is located, as has been demonstrated clinically, in the base of the right third frontal convolution.

Aphasia is of two varieties, the motor or ataxic, and the sensory or amnesic. In the motor variety there is inability to properly coordinate the muscles presiding over articulation, while in the sensory variety there is loss of memory for words. The speech center is connected with the centers of hearing and vision through the medium of the associating fibers of the cerebrum, and also, through the medium of the speech tract, with the centers in the medulla oblongata which give origin to the nerves which are employed in speech. Only through this connection between the speech center, the centers of hearing, and the centers of vision can the two forms of sensory aphasia—namely, word-deafness and word-blindness—be understood. The ability to write is, as a rule, lost in cases of destruction of the motor area for speech.

The lower third of the ascending parietal convolution, at its junction with the inferior parietal, includes the center which controls the movements of the platysma myoides muscle in bringing about retraction of the angle of the mouth. The base of the middle frontal convolution includes the center for lateral movements of the head and eyes, with elevation of the eyelids and dilatation of the pupil. The middle third of the ascending parietal convolution includes the centers for the movements of the fingers and wrist.

The cortical centers for the different muscles and limbs overlap to a certain extent, so that while there is a more or less distinct focus of representation for a given set of muscles, adjacent parts of the cortex are also concerned in governing the muscles presided over by the focus; hence total paralysis does not necessarily follow removal of a limited area of the cortex of the cerebrum.

The supra-marginal and angular convolutions, in addition to the occipital lobe, include the *centers of vision*; these, taken together, have been termed by Ferrier the occipito-angular region. The posterior part of the superior temporo-sphenoid convolution includes the *centers of hearing*. The anterior extremity of the hippocampal convolution or uncus includes the *center of smell*, while in close proximity to the center of smell is the *center of taste*. The convolution of the corpus callosum and the posterior part of the hippocampal convolution include the *center of touch*.

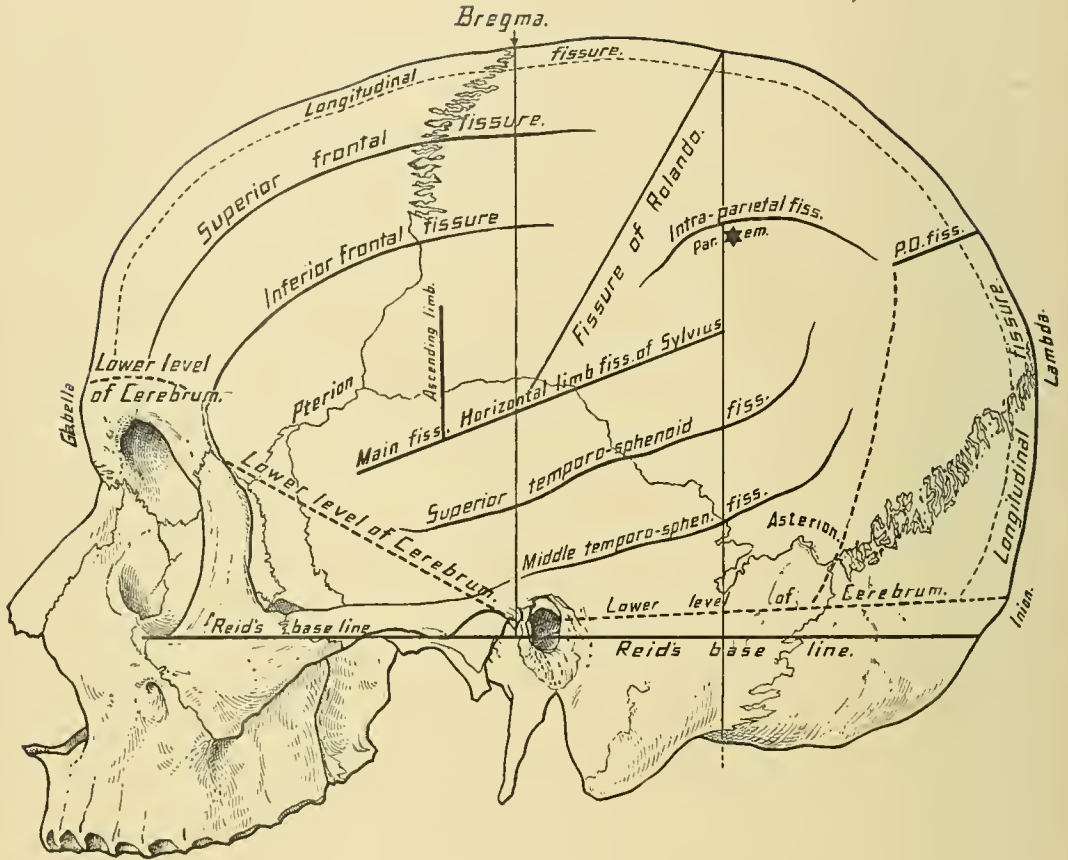
Each occipital lobe receives visual impulses from one-half of both retinæ, so

that a unilateral cerebral lesion may produce what is known as *hemianopsia*, a symmetric defect in the field of vision of the two eyes.

Disease of the Cortex of the Cerebrum.—Irritation of the motor area, as by a small meningeal hemorrhage, meningitis, or the application of a weak Faradic current, causes twitching or convulsive movements of the muscles of the opposite side. When the motor area is destroyed by disease or injury, there is complete paralysis of motion of the opposite side. If both the motor and the sensory areas are involved in the pathologic process, both sensation and motion of the opposite side will be affected. In trephining for focal, or Jacksonian, epilepsy it is customary when the brain cortex has been exposed to apply a weak Faradic current to that portion believed to include the centers which are concerned in the initial convulsive seizure; in other words, the convulsive movements which the patient exhibited during the attacks are reproduced by the application of the current. In this manner the different centers presiding over the various movements of the opposite side can be located. When the affected centers have been definitely located, the entire thickness of the gray matter in the affected area is excised. This naturally results in paralysis of the parts over whose motion they have heretofore presided. The arrest of any bleeding and closing and dressing the wound complete the operation. It is hardly necessary to say that if a lesion such as an enlarged Pacchionian body, a cyst, a cicatrix, or a neoplasm is found, it should be excised. This operation demonstrates, therefore, the effect of both irritation and destruction of the motor area. In following up the cases of Jacksonian epilepsy treated by operation, it is interesting to note that the paralysis which follows the excision of the cortex diminishes, after a time, to such an extent as to permit of a return of the convulsions. These operations, therefore, afford but temporary relief in the great majority of cases. The return of function occurs through the compensatory action of the neighboring cells.

Abolition of the function of certain groups of centers in the motor area of the cortex cerebri results in one or other of the following varieties of paralysis: If of the arm and leg, it is called brachio-crural paralysis, or hemiplegia; if of the leg alone, crural monoplegia; if of the arm alone, brachial monoplegia; and if of the face alone, facial monoplegia. Facial monoplegia seldom occurs alone, and is most commonly associated with aphasia, owing to the close proximity of the facial and speech centers.

The centers of hearing, vision, smell, and taste may be irritated by various lesions, so that hallucinations of these senses may, like motor disturbances, arise from irritation of the motor cortex. Thus, the so-called sensory equivalent of a Jacksonian convulsion is produced, and from the character of this attack deductions as to the location of the lesion may be drawn.



LINES FOR FISSURES, LOWER LEVEL OF CEREBRUM.

DISSECTION.—Shave the scalp upon one side of the head, and upon the other, turn its entire thickness down in one flap. Upon that side where the skull wall is exposed remove half of the calvaria with a saw or a chisel and mallet. Next reflect the dura mater in one flap and dissect off the arachnoid and pia mater to expose the fissures and convolutions.

A familiarity with certain of the cranial landmarks is essential in the study of cranio-cerebral topography. These include the glabella (a point between the eyebrows), the frontal eminence, the external angular process of the frontal bone, the zygomatic arch, the preauricular fossa (the depression in front of the tragus on a level with the upper border of the external auditory meatus), the external auditory meatus, the mastoid process, the parietal eminence, and the external occipital protuberance or inion.

The Lower Level of the Cerebrum.—A line drawn horizontally across the forehead through the upper part of the glabella approximately corresponds to the lower level of the cerebrum in front. A line drawn from the external angular process of the frontal bone through the preauricular fossa to the external occipital protuberance approximately corresponds to the lower level of the cerebrum at the sides and behind. The **cerebellum** lies below that portion of the last-mentioned line included between the posterior border of the mastoid process and the inion.

Longitudinal and Transverse Fissures.—A line drawn from the glabella over the vertex and along the median line to the inion corresponds to the position of the longitudinal fissure. A line drawn from the inion along the superior curved line of the occipital bone to a point an inch, or 2.5 centimeters, above the external auditory meatus corresponds to the position of the transverse fissure.

Fissure of Sylvius.—To indicate the position of the fissure of Sylvius, draw a line from a point one and one-fourth inches, or three centimeters, behind the external angular process of the frontal bone to a point three-fourths of an inch, or two centimeters, below the most prominent part of the parietal eminence. The first three-fourths of an inch, or two centimeters, of the line represent the main fissure; and the remainder of the line, the horizontal limb of the fissure. The ascending limb of the fissure is represented by drawing a line one inch, or 2.5 centimeters, in length vertically upward from the point of termination of the main fissure—that is, three-fourths of an inch, or two centimeters, from its commencement, or five centimeters behind the external angular process of the frontal bone.

Reid's base line is drawn from the lower border of the orbit through the center of the external auditory meatus. This line is of assistance in locating the fissure of Rolando.

Fissure of Rolando.—To represent the position of the fissure of Rolando, first draw two perpendicular lines from the base line to the line representing the

position of the great longitudinal fissure. The anterior of these passes through the preauricular fossa, and the posterior passes along the posterior border of the mastoid process. From the point of intersection of the posterior perpendicular line with that of the great longitudinal fissure to the point of intersection of the anterior perpendicular line with that of the horizontal limb of the fissure of Sylvius, draw a third line, which represents the position of the fissure of Rolando. The fissure of Rolando may also be located by drawing a line downward, outward, and forward from a point one-half of an inch, or one centimeter, behind a point midway between the glabella andinion and at an angle of 71.5 degrees with the anterior portion of the line for the longitudinal fissure. The angle formed by the fissure of Rolando and the anterior portion of the longitudinal fissure varies, but, in any instance, the line for the fissure is merely an approximate guide. The fissure measures about three and three-eighth inches, or eight and one-half centimeters, in length. Upon each side of and running parallel with the fissure of Rolando are the ascending frontal and ascending parietal convolutions, each of which occupies a space about three-fourths of an inch, or two centimeters, in width.

Parieto-occipital fissure.—Extend the line indicating the horizontal limb of the fissure of Sylvius backward to that of the longitudinal fissure, and the lateral limb of the parieto-occipital fissure will be represented by about the posterior inch, or 2.5 centimeters, of this line. The lateral portion of the parieto-occipital fissure is also found from three to three and one-half inches, or eight to nine centimeters, above the external occipital protuberance.

Frontal Lobe.—Through the medium of the lines indicating the course of the primary fissures of the hemisphere the lobes are mapped out. The frontal lobe lies external to the line of the longitudinal fissure, in front of the line of the fissure of Rolando, and above the lines for the lower level of the cerebrum and for the main and horizontal limbs of the fissure of Sylvius. The course of the secondary fissures and the position of the convolutions of this lobe will be represented by the following lines: A line drawn from the supra-orbital notch backward and parallel with the line of the longitudinal fissure to within about three-fourths of an inch, or two centimeters, of the line of the fissure of Rolando indicates the course of the superior frontal sulcus. A line drawn from the external angular process of the frontal bone upward and backward along the temporal ridge to within about three-fourths of an inch, or two centimeters, of the line of the fissure of Rolando indicates the course of the inferior frontal fissure. A line drawn three-fourths of an inch, or two centimeters, in front of, and parallel with, the lower two-thirds of the line of the fissure of Rolando indicates, approximately, the course of the precentral fissure. The superior frontal convolution

corresponds to the interval between the lines of the longitudinal and superior frontal fissures. The middle frontal convolution corresponds to the interval between the lines of the superior and inferior frontal fissures. The inferior frontal convolution corresponds to the interval between the line of the inferior frontal fissure and the lines representing the fissure of Sylvius and the lower level of the cerebrum in front. The ascending frontal convolution corresponds to the interval between the lines of the fissure of Rolando and the precentral fissure.

The **Parietal Lobe** lies between the lines of the longitudinal fissure and the horizontal limb of the fissure of Sylvius, and between the line of the fissure of Rolando and that of the lateral limb of the parieto-occipital fissure. The boundary between the parietal and occipital lobes is indicated approximately by a line drawn from the lateral limb of the parieto-occipital fissure to the posterior border of the base of the mastoid process. The course of the intra-parietal fissure and the position of the convolutions of the parietal lobe are represented as follows: To indicate the course of the intra-parietal fissure, draw from a point one-half of an inch, or one centimeter, external to the end of the lateral limb of the parieto-occipital fissure to a point three-fourths of an inch, or two centimeters, behind the lower end of the fissure of Rolando, a line which is convex forward; the lower third of the line should run parallel with the fissure of Rolando. The interval bounded by this line and the lines of the fissures of Rolando, the longitudinal fissure, and the lateral limb of the parieto-occipital fissure will correspond to the ascending and superior parietal convolutions. The ascending parietal convolution runs parallel with the line of the fissure of Rolando, and corresponds to the space directly behind it to the extent of three-fourths of an inch, or two centimeters, while the remaining portion of the space included in the above boundaries corresponds to the superior parietal convolution. The inferior parietal convolution, including the supra-marginal and angular gyri, corresponds to the interval bounded by the line of the intra-parietal fissure, that of the horizontal limb of the fissure of Sylvius, and the line drawn from the lateral limb of the parieto-occipital fissure to the posterior margin of the base of the mastoid process. The supra-marginal gyrus lies under the most prominent part of the parietal eminence.

The **Occipital Lobe** lies behind the line drawn from the lateral limb of the parieto-occipital fissure to the posterior margin of the base of the mastoid process.

The **Temporal** or **Temporo-sphenoid Lobe** lies below the line of the horizontal limb of the fissure of Sylvius and above the upper border of the zygoma, and a line representing the continuation of the latter backward to a point slightly above the superior curved line of the occipital bone. The posterior boundary of this lobe corresponds approximately to a line drawn from the external portion of the

parieto-occipital fissure to the posterior limit of the base or root of the mastoid process. This lobe in front reaches as far as the posterior superior border of the malar bone. A line drawn parallel with and one inch, or two and one-half centimeters, below the line of the horizontal limb of the fissure of Sylvius indicates the course of the superior temporo-sphenoid fissure. A line drawn parallel with and three-fourths of an inch, or two centimeters, below the latter line, indicates the course of the middle temporo-sphenoid fissure. The superior temporo-sphenoid convolution corresponds to the interval between the line of the horizontal limb of the fissure of Sylvius and the line of the superior temporo-sphenoid fissure. The middle temporo-sphenoid convolution corresponds to the interval between the lines of the superior and middle temporo-sphenoid fissures.

Individual Variations and How to Determine Them.—It is to be borne in mind that the brain of one individual differs from that of another, and, therefore, there is no method which will in all instances represent the position of the fissures and convolutions with absolute correctness. After the brain cortex is exposed in an operation, the Faradic current can be applied to decide what portion of the motor area of the cortex has been exposed. It can be readily appreciated that through so small an opening as that made by the trephine it is scarcely possible to recognize special fissures and convolutions, especially when we recollect how difficult it is at times to locate them in the dissection of the brain.

Indications for Trephining.—Excluding trephining for fracture of the skull, the cranial cavity is opened for one of several purposes—namely, to expose the superior and inferior maxillary nerves when it is purposed to excise one or both for trifacial neuralgia; for the removal of the Gasserian ganglion, as described; to remove a blood clot; to control hemorrhage from one or both branches of the middle meningeal artery; to open the lateral sinus in septic thrombosis consequent upon middle ear disease; to remove part of the brain cortex, as in Jacksonian epilepsy; to remove a brain tumor or a foreign body; to evacuate an abscess; to relieve intra-cranial pressure; to tap the lateral ventricles; for the relief of otherwise uncontrollable headache when the point of greatest pain can be located; and for traumatic epilepsy.

To Expose the Lateral Sinus.—In septic thrombosis of the lateral sinus consequent upon middle ear disease that portion of the sinus in relation with the mastoid process, the sigmoid portion, is exposed. To reach this portion, first draw two lines, one vertical through the middle of the mastoid process, and a second on a level with the roof of the external auditory meatus and at a right angle to the first. At the point of junction of these two lines apply the center pin of a one-inch trephine. The most superficial portion of this sinus is not so deeply situated as the mastoid antrum, being, as a rule, about one-fourth of an inch, or six milli-

eters, from the surface of the bone. Before removing the clot from the sigmoid sinus the internal jugular vein should be ligated, to control hemorrhage and prevent dissemination of emboli. As a thrombus of the sigmoid sinus seldom occurs except as a complication of disease of the mastoid antrum, the latter is usually opened first, and then it is desirable to expose the sinus on its anterior aspect by removing the bony tissue between the antrum and the sinus, which often contains the channels through which the sinus has become infected.

Localized Affections.—In operating for focal epilepsy, brain tumor, or blood clot the trephine is applied to the skull directly over the part of the brain believed to be the site of involvement, as determined by localizing symptoms. The lines which indicate the courses of the fissures are the principal guides.

Foreign Bodies.—In the removal—or perhaps it would be better to say the attempt at removal—of a foreign body, as these are most commonly bullets and in the majority of cases located with difficulty, the cranial cavity is attacked at the wound of entrance. The operation of trephining in this class of cases increases the chance of finding the foreign body and establishes drainage.

Temporo-sphenoid Abscess.—The most common forms of intra-cranial abscess are temporo-sphenoid, cerebellar, and extradural, which are usually the result of middle ear disease. In operating for temporo-sphenoid abscess, which is usually located in the posterior half of the lobe, first draw two parallel lines at right angles to Reid's base line, the anterior passing through the center of the external auditory meatus, and the other about one and one-fourth inches, or three centimeters, behind it. Apply the center pin of the trephine over a point one and one-fourth inches, or three centimeters, above Reid's base line and between the two vertical lines (Barker).

Cerebellar Abscess.—In operating for cerebellar abscess, which is usually situated in the front and outer part of the hemisphere of the cerebellum, apply the center pin of the trephine at a point one and one-half inches, or four centimeters, behind the center of the external auditory meatus, and one inch, or two and one-half centimeters, below Reid's base line (Barker).

Extradural Abscess.—The point over which to trephine in extradural or subdural abscess must depend, in a great degree, upon the presence of localizing symptoms. The constitutional evidences of pus and the history of the case, together with circumscribed edema and localizing symptoms, such as spastic contraction or paresis of certain muscles, would constitute the most reliable guides. Septic meningitis, as far as the constitutional symptoms are concerned, frequently so closely simulates cerebral abscess that a differential diagnosis, in the absence of localizing symptoms, is impossible.

To Tap the Lateral Ventricles apply the center pin of the trephine one and

one-quarter inches, or three centimeters, behind the center of the external auditory meatus and the same distance above Reid's base line. The ventricle is reached by carrying a grooved director obliquely forward and upward toward a point two and one-half to three inches, or six to seven and one-half centimeters, above the opposite external auditory meatus. The distance to which the grooved director must be inserted to reach the ventricle is from two to two and one-quarter inches, or five to five and one-half centimeters (Keen).

Headache and Traumatic Epilepsy.—In otherwise uncontrollable headache, when the point of greatest pain can be located, the trephine is applied at that point. In traumatic epilepsy the trephine is applied to the site of the original injury.

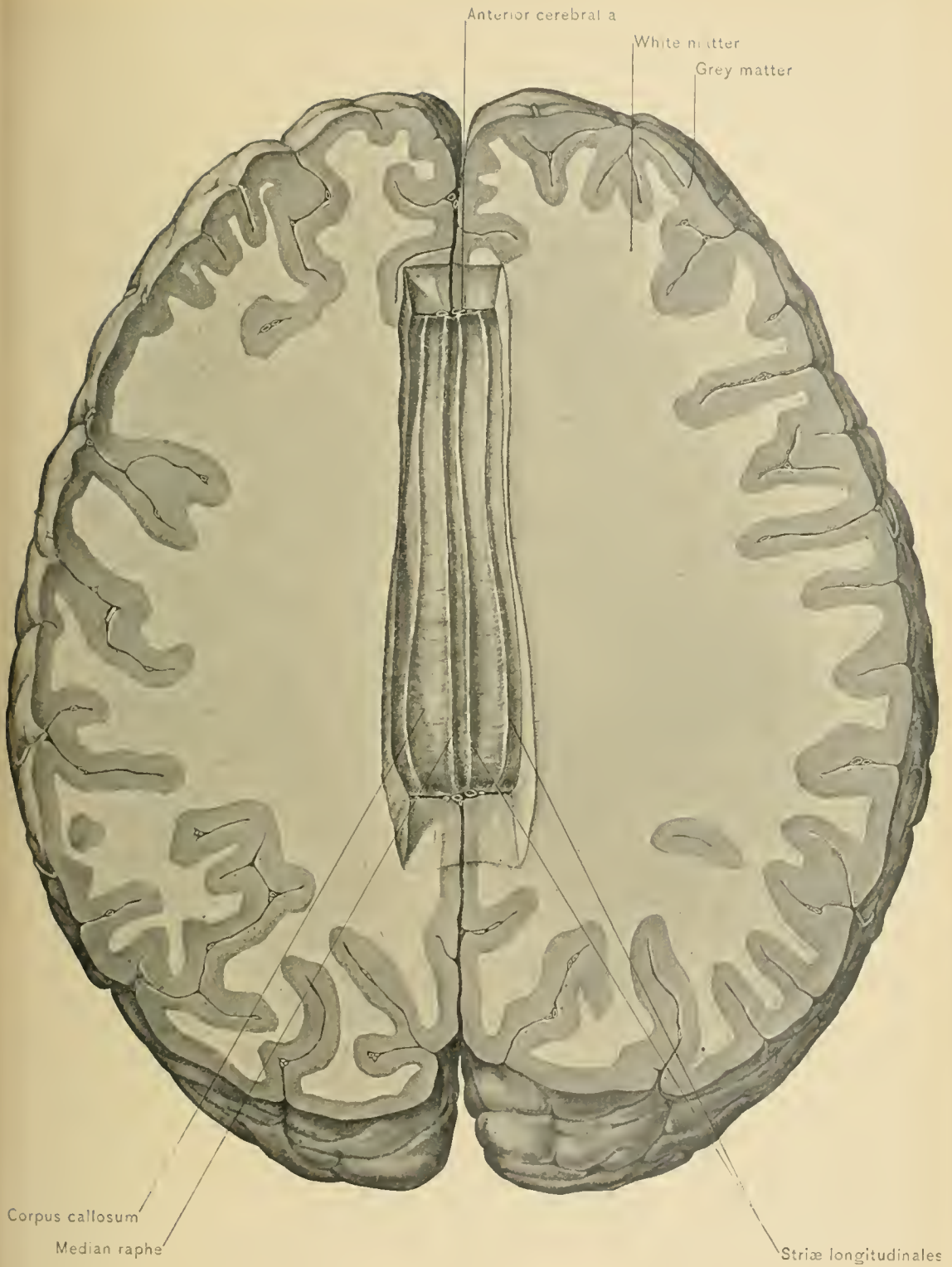
Craniectomy, or removal of a section of the calvaria to allow expansion of the brain in cases of idiocy, is, in the author's opinion, inadvisable, and might be compared to removal of a section of a nutshell to allow increased growth of a nut, the kernel of which is dead.

THE INTERIOR OF THE CEREBRUM.

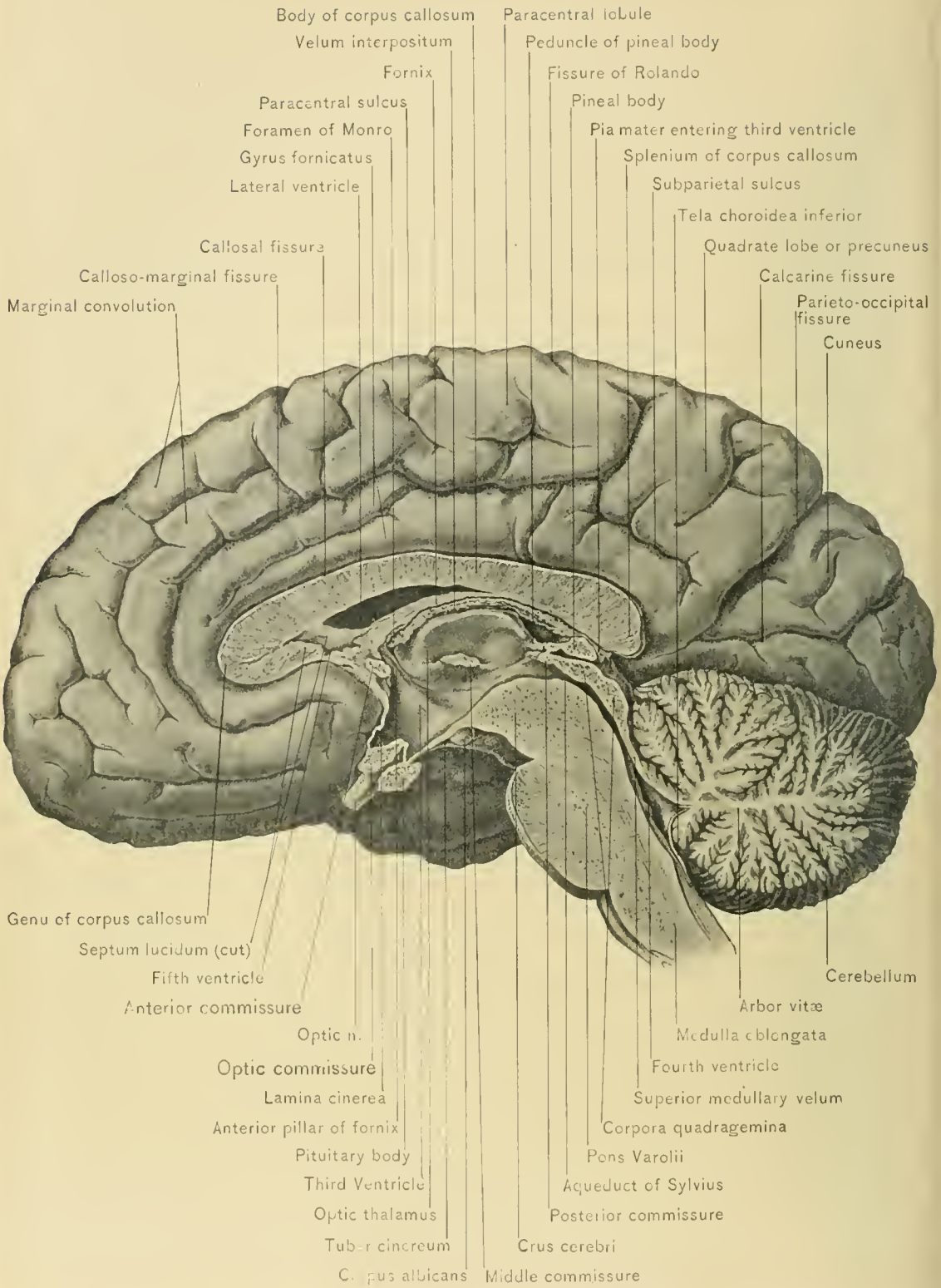
Material.—In order to study the brain to the best advantage the dissector, as previously remarked, should have at least two preserved brains at his disposal. One brain may be used for the study of the fissures, convolutions, and interior of the brain; and the other for making sections of the brain.

DISSECTION.—Having completed the study of the fissures and the convolutions, next examine the interior of the cerebrum. Place the brain on its base, and separate the hemispheres of the cerebrum, to widen the longitudinal fissure, thus exposing the bottom of the fissure. This is formed in great part by a mass of white matter,—the corpus callosum, or the great transverse commissure of the cerebrum,—while in front of and behind the corpus callosum the fissure extends without interruption to the base of the brain. Make a horizontal section of one or both hemispheres on a level with the floor of the longitudinal fissure. When both hemispheres are sliced away to the level of the floor of the longitudinal fissure, the upper surface of the corpus callosum is well exposed. The corpus callosum can now be studied from two points of view: from above in the present dissection, and from the side by looking at its sagittal section, seen in the preparation previously made by severing the two halves of the brain in the line of the longitudinal fissure.

The **Corpus Callosum**, the great transverse commissure of the cerebrum, is a transverse band of white matter which spans the longitudinal fissure and connects the hemispheres of the cerebrum for nearly half their length. The *falx cerebri*



CORPUS CALLOSUM AND HORIZONTAL SECTION OF CEREBRUM.



INTERNAL SURFACE OF CEREBRUM AND SECTION OF VENTRICLES OF BRAIN.

touches the posterior portion of the corpus callosum ; the greater part of the body of the corpus callosum and its anterior extremity are separated for a considerable distance from the falx cerebri. The corpus callosum is slightly convex from before backward on the upper surface, is between three and four inches, or seven to ten centimeters, in length, and extends nearer to the anterior than to the posterior end of the cerebrum. It is wider behind, where it measures about one inch, or two and one-half centimeters, and is thicker at each end, especially at the posterior extremity, than in the middle. It forms the roof of the lateral ventricles, which are cavities located within the hemispheres of the cerebrum. On its dorsal surface, extending along its middle line, a linear depression exists, the **raphe**. On each side of the raphe, and running parallel with it, are two slightly elevated longitudinal bands, the **striæ longitudinales**, or **nerves of Lancisi**. External to these are the faintly marked **striæ longitudinales laterales**, or **tæniæ tectæ**, which, with the brain intact, underlie the convolutions of the corpus callosum, or gyri fornicati. The tæniæ tectæ are separated bundles of a group of fibers known as the **cingulum**, which forms part of the callosal and hippocampal gyri. The fibers proper of the corpus callosum run transversely, as its name, the great transverse commissure, implies. The corpus callosum consists of a main portion or body, seen best on longitudinal section, and of two extremities, the anterior and the posterior.

The **anterior extremity**, or **genu**, is formed by the bending downward and then backward of the corpus callosum ; from this bend it is continued to the base of the brain as the beak, or **rostrum**, which is the reflected portion of the genu, and is thin and narrow. Within the concavity of the genu is situated the septum lucidum, which contains between its layers the fifth ventricle. The rostrum of the corpus callosum has previously been described with the base of the brain ; it is connected to the tuber cinereum by the lamina cinerea. It gives off two bands of white substance, which are continuations of the nerves of Lancisi and form the peduncles of the corpus callosum. These then diverge from each other and run backward and outward across the anterior perforated space to the tips of the temporal lobes, meeting the inner roots of the olfactory tracts. The fibers from the genu of the corpus callosum pass outward and forward and then inward, into the prefrontal region, forming the *forceps minor*.

The **posterior extremity of the corpus callosum**, or **splenium**, is formed by a bending of the corpus callosum downward and forward upon itself, thus making a free, thickened, rounded border. This border forms the upper boundary of the central part of the transverse fissure, and beneath it passes the process of the pia mater known as the velum interpositum. The splenium is connected anteriorly with the fornix. The fibers of the splenium which curve outward and backward over the posterior horn of the lateral ventricle constitute the *forceps major* ; some

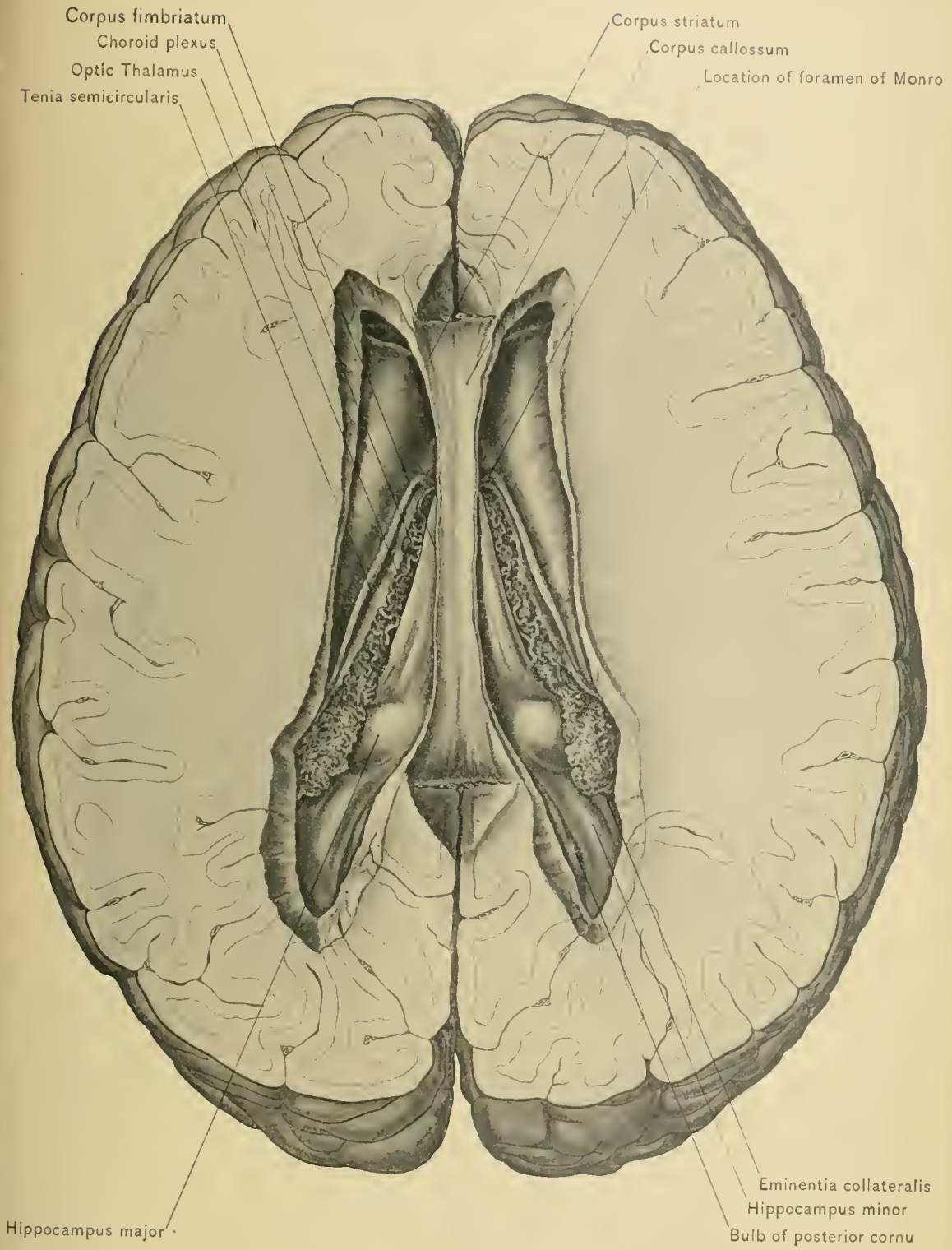
of these fibers form a long, rounded elevation, the bulb of the posterior cornu of the lateral ventricle.

The under surface of the body of the corpus callosum is connected along the middle line with the fornix and the septum lucidum, while laterally it forms the roof of the lateral ventricles.

DISSECTION.—Make two sagittal incisions from before backward, through the corpus callosum, from three-eighths to one-half an inch, or one centimeter, to each side of the median line; this will open the lateral ventricles—cavities which occupy the interior of the hemispheres of the cerebrum. To expose the interior of one or both lateral ventricles so as fully to disclose the contained structures, cut away with a pair of scissors as much of the corpus callosum on each side of the incision as may be necessary. This dissection will not open the middle or descending cornu; to accomplish this a section of the lateral portion of the hemisphere (temporo-sphenoid lobe) must be removed. This can be done either from without inward or from within outward by following the course of the cornu with the scalpel.

The **Lateral Ventricles** (trihorned ventricles, *ventriculi tricornes*) are two irregularly shaped cavities, one of which is situated in each hemisphere of the cerebrum. They communicate with the third ventricle by way of the foramina of Monro, and through the third ventricle with the fourth ventricle, by way of the aqueduct of Sylvius, or *iter e tertio ad quartum ventriculum*. They are lined by a membrane, the *ependyma*, whose function is to secrete part of the cerebro-spinal fluid. Each of the ventricles, which are separated in front by a vertical partition, the septum lucidum, consists of four parts: a body, or central portion, and three horns, or *cornua*. The *cornua* are designated anterior, middle or descending, and posterior, and extend, respectively, into the frontal, the temporo-sphenoid, and the occipital lobe of the cerebrum.

The **body of the lateral ventricle** is triangular in shape in a coronal section, its antero-posterior diameter being the longest, and its vertical diameter the shortest. It extends from the foramen of Monro to the splenium of the corpus callosum. It is bounded *above* by the corpus callosum; *internally*, by the posterior narrow portion of the septum lucidum, and the attachment of the corpus callosum to the fornix; and *externally*, by the merging angle formed by the corpus callosum and the white substance of the hemisphere. Its *floor* is formed by the following parts, named in their order from without inward: the intra-ventricular portion of the corpus striatum, or caudate nucleus, the tania semicircularis and a small vein of the corpus striatum contained in an oblique groove, the optic thalamus, the choroid plexus, half of the body of the fornix, with its lateral edge or corpus fimbriatum.



BODIES, ANTERIOR CORNUA, AND POSTERIOR CORNUA OF LATERAL VENTRICLES.

The **anterior cornu of the lateral ventricle** is triangular in shape on coronal section of the brain. It extends forward, downward, and outward into the frontal lobe. It curves around the anterior end of the corpus striatum, and diverges from the anterior cornu of the lateral ventricle of the other side as it passes forward. It is bounded *above* by the fibers of the corpus callosum (*forceps minor*), which curve outward and forward; *internally*, by the septum lucidum, which separates it from the corresponding cornu of the opposite ventricle; in *front*, by the genu of the corpus callosum; and externally, by the caudate nucleus. Its *floor* is formed in great part by the caudate nucleus, which projects into it, and to a slight extent by the rostrum of the corpus callosum.

The **posterior cornu of the lateral ventricle**, the smallest of the three cornua, commences in the body of the ventricle opposite the splenium of the corpus callosum, and at the same point as the middle cornu. It extends horizontally backward, outward, and then inward into the occipital lobe. Its *roof* is formed by those fibers of the splenium of the corpus callosum (*forceps major*) which pass backward and outward and become continuous with the white matter of the occipital lobe. On its *inner wall* is seen the hippocampus minor, or calcar avis, produced by the calcarine fissure; above this is a smaller prominence, the bulb of the cornu, produced by the bulging of the fibers of the forceps major into the cavity, above and internal to the hippocampus minor. On the *floor* is seen a slight elevation, produced by the fasciculus longitudinalis inferior, which passes from the occipital to the temporal lobe. At the point where the middle and posterior cornua meet a triangular, smooth surface is seen, called by Schwalbe the trigonum ventriculi.

The **middle or descending cornu of the lateral ventricle**, the longest of the three cornua, may be considered the continuation of the cavity of the ventricle into the temporal lobe; it commences opposite the splenium of the corpus callosum, in the body of the ventricle, at the same point at which the posterior cornu begins. It extends backward and outward around the posterior extremity of the optic thalamus, and then runs downward, forward, and inward to reach the base of the brain, terminating about an inch, or 2.5 centimeters, from the tip of the temporo-sphenoid lobe. Its *roof* is formed by those fibers of the body of the corpus callosum (tapetum) which pass outward and become continuous with the white matter of the temporo-sphenoid lobe, and by the tail of the caudate nucleus, the tania semicircularis, and the amygdaloid tubercle. The *floor* is formed in great part by the eminentia collateralis. Upon the *inner wall* are seen the following structures, named from without inward: the hippocampus major, and pes hippocampi, the corpus fimbriatum, the choroid plexus, and the fascia dentata or dentate convolution.

DISSECTION.—Next make a transverse section of the remaining portion of the body of the corpus callosum at about its middle, and dissect one half forward and the other half backward. If carefully executed, this dissection exposes the fornix and the septum lucidum.

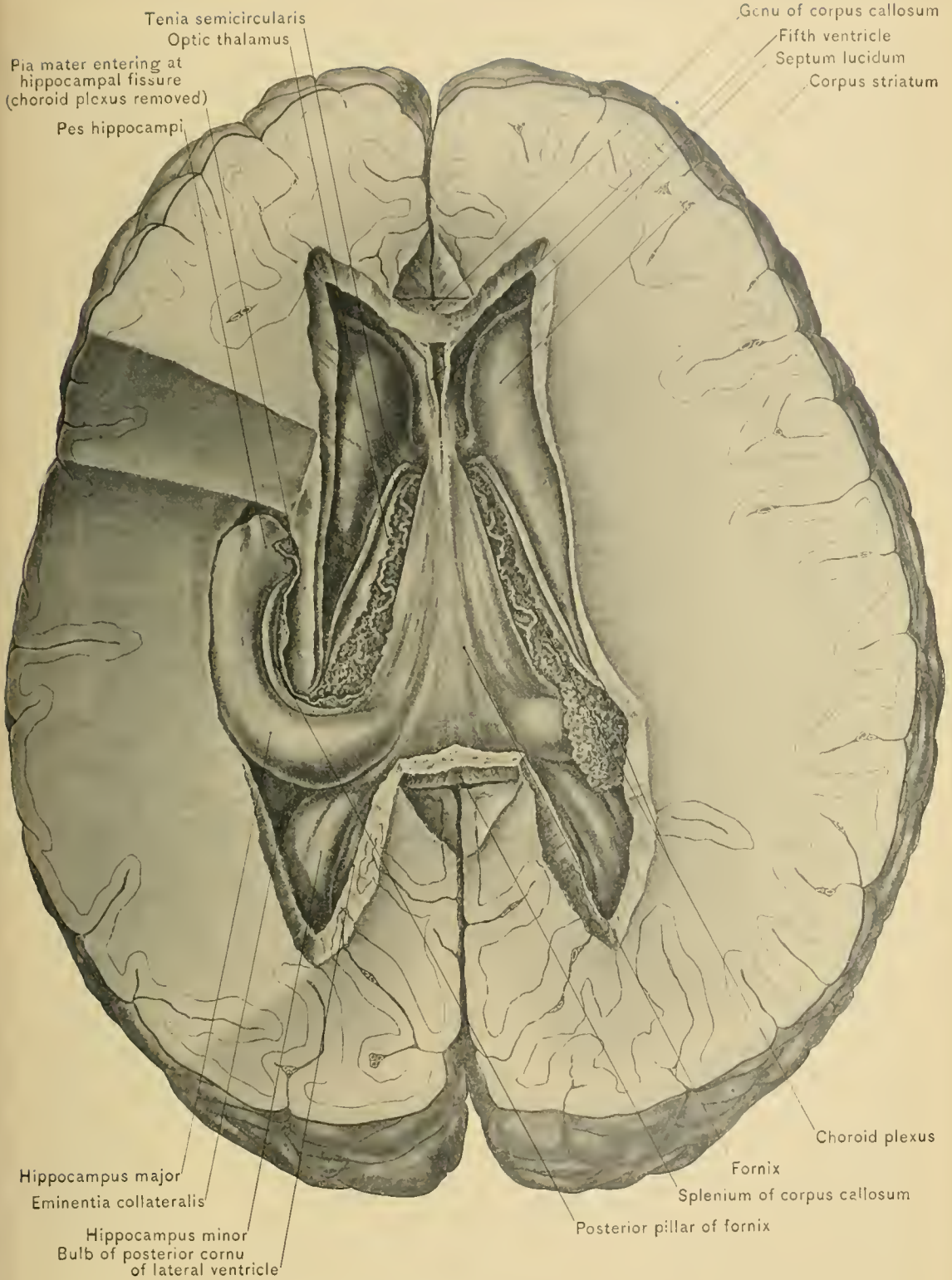
The **Fornix**, the longitudinal commissure of the cerebrum, is a triangular mass of white matter situated beneath the corpus callosum, and is continuous posteriorly with the splenium of the corpus callosum. It overlies the velum interpositum, which separates it from the third ventricle and the optic thalamus. It consists of a main portion, or body, and an anterior and a posterior crura.

The **body of the fornix** is triangular in shape, the apex of the triangle being directed anteriorly. The fornix is adherent behind to the splenium of the corpus callosum, and is attached above and in front to the septum lucidum, and above and behind to the corpus callosum; below, it rests upon the velum interpositum, and lies above the third ventricle. The sides of the body of the fornix project into the lateral ventricles, overlapping the inner portion of the optic thalami and choroid plexuses. The fibers of the under surface of the fornix behind are so arranged as to give rise to the designation *the lyre*, which has been bestowed upon them.

The **anterior crura**, or **pillars of the fornix**, are two cylindric bundles of nerve-fibers which are given off from the anterior extremity or apex of the body of the fornix, whence they diverge and descend in front of the optic thalami and the foramina of Monro and then through the gray matter in the sides of the third ventricle, to the base of the brain, where they form the white matter of the corpora albicantia, or mammillary eminences. Fibers pass from the corpora albicantia to the optic thalami; these fibers constitute the bundles of Vieq d'Azyr, and are probably not directly continuous with the fibers of the fornix. In their descent the anterior pillars are joined by the *tæniæ semicirculares* and by fibers from the septum lucidum and peduncles of the pineal gland. Between the anterior crura and the anterior extremities of the optic thalami are the oval openings of communication between the lateral ventricles and the third ventricle, the foramina of Monro.

The **posterior crura**, or **pillars of the fornix**, arise posteriorly from each side of the body of the fornix, whence they diverge and descend into the middle cornua of the lateral ventricles. Here each crus lies within the concavity of the curve described by the hippocampus major as far as the pes hippocampi. The lateral borders of the posterior crura of the fornix are known as the **corpora fimbriata**, or **tæniæ hippocampi**.

The **septum lucidum** is a triangular vertical partition situated between the



FORNIX AND LATERAL VENTRICLES, AND DESCENDING CORNU OF LEFT LATERAL VENTRICLE.

anterior portion of the bodies of the two lateral ventricles and between the anterior cornua of those ventricles. The base of the triangle is directed downward and forward, and the apex backward, into the narrow interval between the anterior part of the body of the fornix below, and the corpus callosum above. The septum lucidum is attached above to the under surface of the body of the corpus callosum; in front, to the concavity of the genu of the corpus callosum; and below, to the rostrum of the corpus callosum and to the body and anterior crura of the fornix. It is composed of two laminae, between which is the cleft-like interval known as the fifth ventricle.

The **fifth** or **Sylvian ventricle** is not provided with an outlet, but is a completely inclosed space. Each of the laminae of the septum lucidum, which bound this ventricle laterally, consists of an inner gray layer, a middle white layer, and an outer layer of ependyma which is part of the ependyma that lines the lateral ventricles. The fifth ventricle differs from the other ventricles in its mode of development; it is a portion of the great longitudinal fissure which has become inclosed by the formation of the corpus callosum and fornix.

DISSECTION.—With a pair of scissors slice away a horizontal section from the superior portion of the septum lucidum, when, with a little care, the laminae can be pushed apart and the fifth ventricle opened. Should the ventricle contain more than the usual quantity of fluid, it can be more readily seen than if it were in a normal state.

Before reflecting the fornix examine the structures seen within the lateral ventricle, commencing with the corpora striata, which project into the anterior cornua.

Corpus Striatum.—The corpora striata (anterior cerebral ganglia) are the anterior pair of basal ganglia. The portion seen within the anterior cornu of the lateral ventricle is the intra-ventricular portion, or caudate nucleus. It is so called in contradistinction to the larger extra-ventricular portion, or lenticular nucleus, which occupies the white substance of the hemisphere of the cerebrum. To expose both the lenticular nucleus and the caudate nucleus in one dissection it is necessary to make horizontal sections of the hemisphere; these sections will be described further on.

The **Caudate Nucleus** is a pear-shaped mass of gray matter having its broad extremity, or head, directed forward into the forepart of the body and the anterior cornu of the lateral ventricle, and its narrow extremity, or tail, directed outward and backward. It lies to the outer side of the optic thalamus, and is prolonged into the roof of the middle horn of the lateral ventricle as far as its anterior extremity, where it terminates in the amygdaloid tubercle. Crossing the surface of the caudate nucleus are numerous small veins emptying into the vein of the

corpus striatum, which lies in the groove between the caudate nucleus and the optic thalamus.

The **Tænia Semicircularis**, or **Stria Terminalis**, is a very narrow longitudinal band of white fibers, which lies in the groove between the caudate nucleus and the optic thalamus, and conceals from view the vein of the corpus striatum. It extends from the anterior crus of the fornix, with which it is continuous in front, backward through the floor of the body of the ventricle, and into and along the roof of the middle cornu as far as the amygdaloid tubercle, where it ends. Where the surface of the anterior portion of the tænia semicircularis is more transparent and less dense than elsewhere was called by Tarinus the "horny band."

The **Optic Thalami** (posterior cerebral ganglia), the posterior pair of basal ganglia, can not be seen to advantage at this stage of the dissection without disarranging the parts overlying them and until the fornix and the velum interpositum have been removed; their description, therefore, will be deferred. It is sufficient to say here that the optic thalamus is an oblong mass of white and gray matter lying to the inner side of the caudate nucleus and the tænia semicircularis, part of the upper surface of which is hidden by the choroid plexus, the corpus fimbriatum, and the lateral portion of the body of the fornix.

The **Choroid Plexus** is a red, convoluted, vascular fringe, formed in the free margin of the velum interpositum, extending from the foramen of Monro backward over the optic thalamus into the descending cornu of the lateral ventricle, where it lies on the hippocampus major and extends to the end of this cornu of the ventricle. It is covered throughout by the ventricular epithelium, or ependyma, which passes from the corpus fimbriatum to the tænia semicircularis and optic thalamus; the ependyma thus separates the plexus from the cavity of the ventricle. Behind and between the foramina of Monro the choroid plexus of one lateral ventricle becomes continuous with that of the other, and from the point of junction the choroid plexuses of the ventricle extend backward.

The **Corpus Fimbriatum**, **Tænia Hippocampi**, or **Fimbria**, a narrow band of white matter, is the edge of the posterior crus of the fornix, which rests upon the posterior end of the optic thalamus, the choroid plexus intervening, and is continued into the descending cornu of the lateral ventricle. Here it rests between the concave margin of the hippocampus major and the pia mater, which passes through the hippocampal fissure. It extends as far as the uncus of the hippocampal gyrus.

The **Hippocampus Major**, or **Cornu Ammonis**, is the prominent convex, white eminence which forms part of the floor and inner wall of the descending cornu of the lateral ventricle, and extends throughout the entire length of this cornu. It is produced by extension of the hippocampal fissure into the descending cornu of

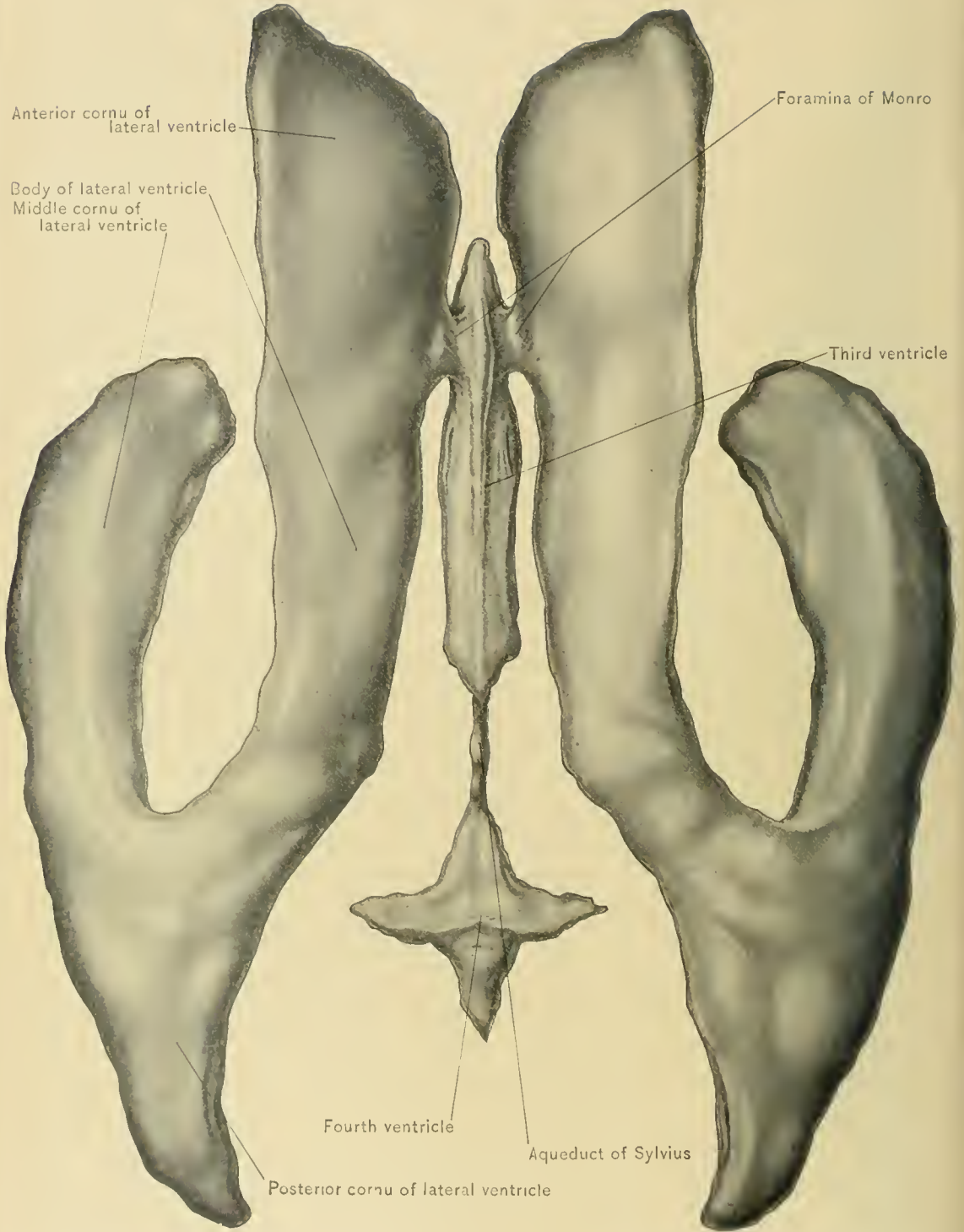


DIAGRAM OF THE VENTRICLES—SUPERIOR VIEW.

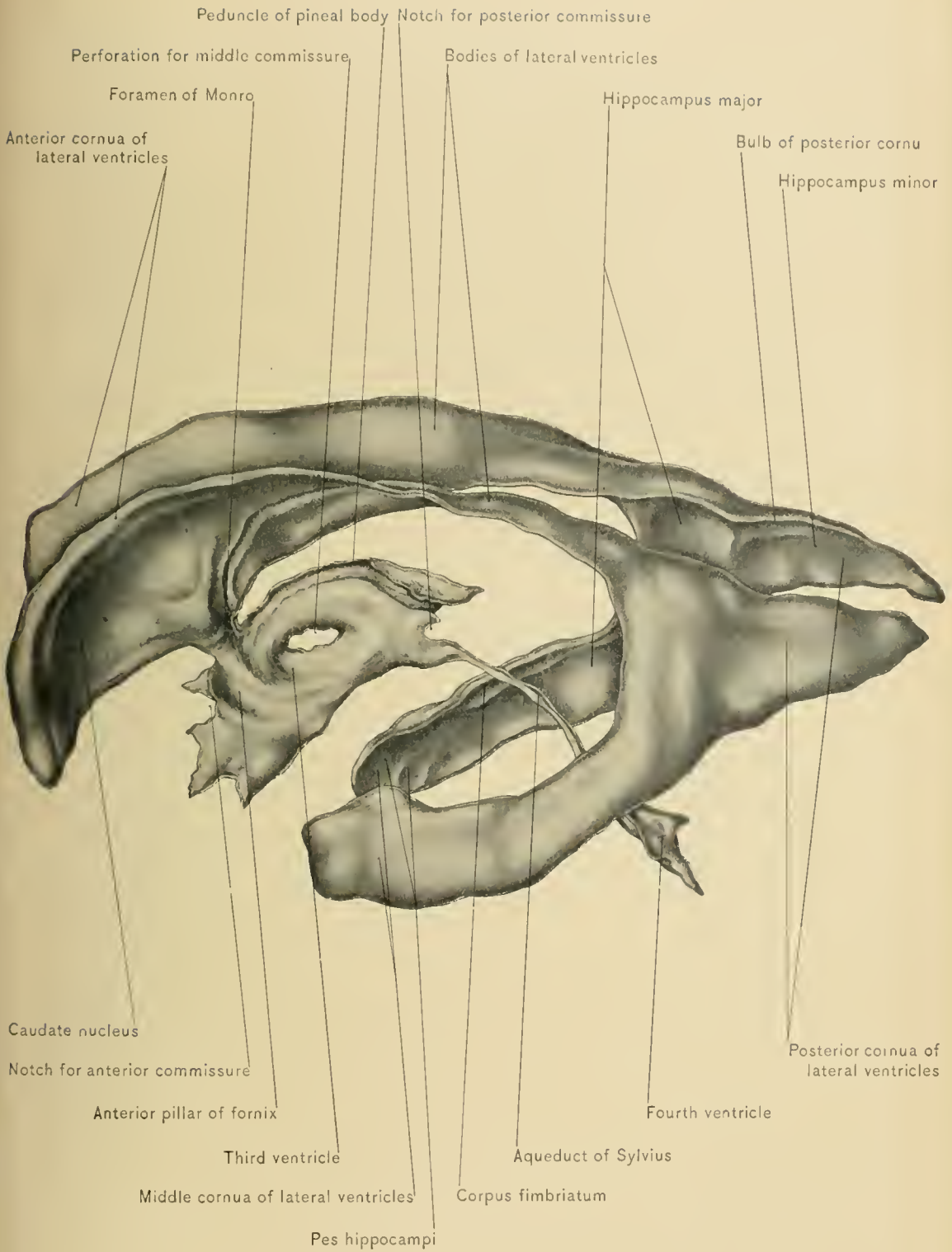

DIAGRAM OF THE VENTRICLES—LATERAL VIEW.

the lateral ventricle. Along its antero-superior or concave margin is the corpus fimbriatum. Its anterior extremity, the *pes hippocampi*, is enlarged, and presents two or more grooves, so that it somewhat resembles the paw of an animal.

DISSECTION.—Carefully separate the inner border of the corpus fimbriatum from the choroid plexus of the descending cornu of the lateral ventricle, thus breaking through the epithelial lining of the ventricle; displace the choroid plexus inward, and slightly depress the corpus fimbriatum and hippocampus major. This procedure exposes the fascia dentata, and separates the margins of the hippocampal fissure.

The **Fascia Dentata**, or **Dentate Convolution**, a serrated band of gray matter, is the margin of the hippocampal convolution in relation with the hippocampal fissure. The serrations or indentations of the fascia dentata are produced by the vessels of the pia mater, which projects through the hippocampal fissure into the descending cornu of the lateral ventricle. The fascia dentata extends from near the splenium of the corpus callosum to the anterior extremity of the descending cornu of the lateral ventricle. As the epithelial lining of the ventricle must be divided in order to expose the fascia dentata, that convolution is external to the wall of the ventricular cavity.

The **Hippocampus Minor**, **Calcar Avis**, or **Ergot**, is a small, convex, white eminence which occupies the floor and inner wall of the posterior cornu of the lateral ventricle. It is produced by the calcarine fissure, and is at times but faintly marked.

The **Eminentia Collateralis**, or **Pes Accessorius**, may be recognized at its commencement as a smooth white eminence fitting into the angle of divergence of the hippocampus major and hippocampus minor, at the junction of the middle and posterior cornua of the lateral ventricle. It extends forward as the floor of the middle cornu of the lateral ventricle almost to the extremity of this cornu. It is produced by the collateral fissure.

DISSECTION.—Next dividé the fornix transversely at about its middle, and reflect the one half forward and the other backward, thus exposing the greater part of that process of pia mater—the velum interpositum—which lies above the epithelial roof of the third ventricle. To expose thoroughly the velum interpositum, especially that part of it which occupies the central portion of the transverse fissure, make a longitudinal incision through the posterior part of the fornix and corpus callosum; then reflect these flaps laterally.

The **Velum Interpositum**, or **Tela Choroidea Superior**, is that process of the pia mater which reaches the interior of the brain by way of the horizontal portion of the transverse fissure, passing between the splenium of the corpus callosum and the corpora quadrigemina. It is a double layer of pia mater, and is triangular in

shape, like the fornix; it lies beneath the fornix and the corpus callosum. It covers the quadrigeminal bodies, the pineal body, the third ventricle, and part of the optic thalami. Its borders contain the choroid plexuses of the lateral ventricles, while in its under surface are situated the two choroid plexuses of the third ventricle. The latter plexuses are continuous with the choroid plexuses of the lateral ventricles just behind the foramina of Monro. Running one on each side of the median line of the velum interpositum, between its two layers, are the two veins of Galen, formed by the union of the veins of the corpora striata and the choroid veins, in addition to small twigs from surrounding structures. They unite posteriorly to form a single trunk, which joins the inferior longitudinal sinus to form the straight sinus at the junction of the inferior margin of the falx cerebri with the anterior margin of the tentorium cerebelli.

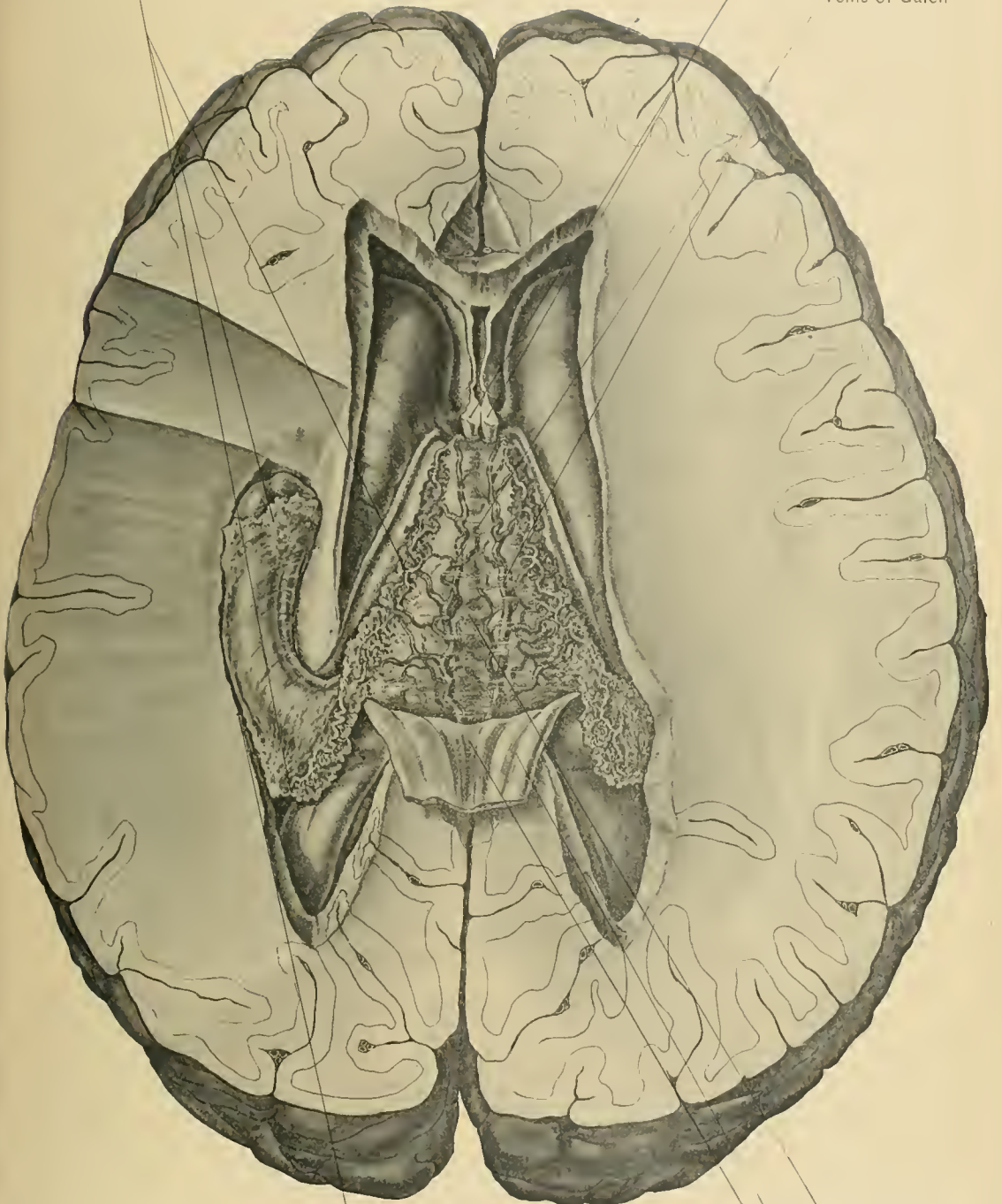
DISSECTION.—Raise the velum interpositum and the choroid plexuses and turn them backward. Especial care is necessary in raising the posterior part of the velum interpositum so as not to raise the pineal gland with it, as the gland is closely invested by the lower layer of pia mater entering the velum. This dissection exposes the third ventricle, the three commissures of that ventricle, the anterior crura of the fornix, the optic thalami, the pineal body and its peduncles, and the quadrigeminal body. In making the dissection it frequently happens that the middle commissure of the third ventricle is broken, and the dissector, if not familiar with this fact, might conclude that it was absent in the brain under examination.

Fissure of Bichat.—Before describing the parts exposed by the removal of the velum interpositum, the great transverse fissure of the brain, or fissure of Bichat, which is now opened up throughout, should be carefully observed. To do this to the best advantage it is necessary to remove the velum interpositum and the choroid plexuses of the lateral and third ventricles with the adherent epithelium. The central horizontal or transverse portion of this fissure, through which the velum interpositum passes, is the continuation of the interspace between the cerebrum and the cerebellum seen in the undissected brain with the pia mater removed. This central portion is continuous with the lateral portions, or hippocampal fissures, which are seen in the dissection of the middle cornua of the lateral ventricles, thus making the fissure, as a whole, horseshoe shaped.

The **Third Ventricle** is a narrow, oblong cavity situated in the middle line of the cerebrum, between the optic thalami and the peduncles of the pineal body, and reaching to the base of the brain. It is wider and shallower behind than in front. It is bounded *above* by the velum interpositum, although its immediate roof is formed by a thin epithelial layer which is continuous with the lining epithelium or ependyma of the ventricle; on the *sides*, by the optic thalami and the peduncles

Choroid plexus

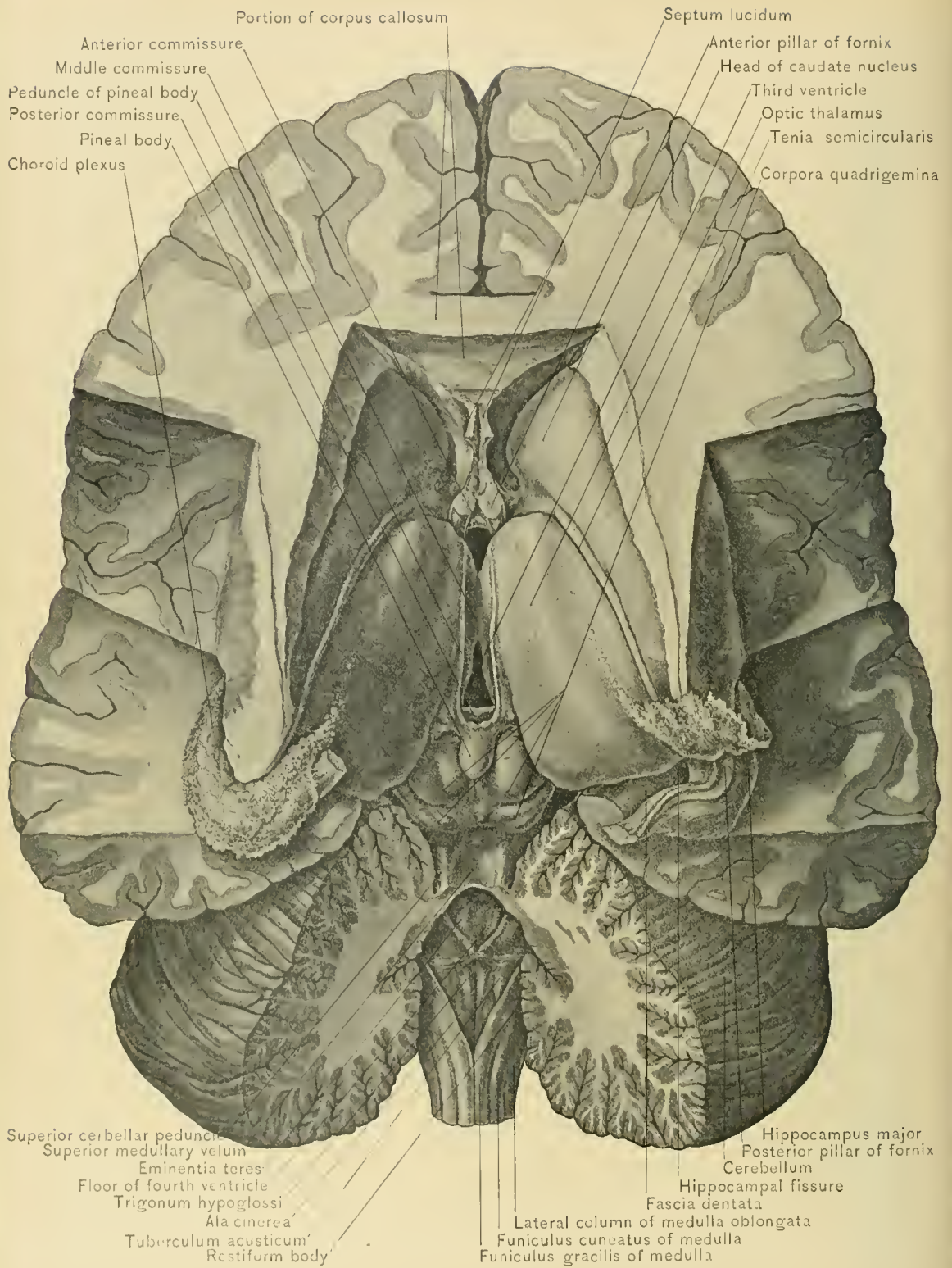
Anterior pillars of fornix(cut)
Veins of Galen



Descending cornu of left lateral ventricle

Velum interpositum
Body of fornix(reflected)
Lyra

VELUM INTERPOSITUM AND CHOROID PLEXUS.



VENTRICLES AND NUCLEI OF THE BRAIN.

of the pineal body ; in *front*, by the anterior commissure and the anterior pillars of the fornix ; and *behind*, by the posterior commissure, the orifice of the aqueduct of Sylvius, and the pia mater, passing from the upper surface of the pineal body to the inferior layer of the velum interpositum. Its *floor* is formed by the bodies which fill the interpeduncular space of the base of the brain and the superior surface of the crura cerebri at their origin from the pons Varolii. The structures in the interpeduncular space are named, from before backward, the lamina cinerea, the tuber cinereum, the infundibulum, the corpora albicantia, and the posterior perforated space.

Commissures.—Stretching across the ventricle are the anterior, middle, and posterior commissures. The *anterior commissure* is situated in front of the anterior crura of the fornix. It is composed of white matter and connects the two temporal lobes of the cerebrum. The *middle commissure* is composed almost entirely of gray matter, is the largest, and is about one-half an inch, or twelve millimeters, in width. It connects the optic thalami, and, as has been observed, is frequently torn across in the dissection of the brain. The *posterior commissure*, the smallest of the three, is situated in front of and beneath the pineal body, and above the anterior opening of the aqueduct of Sylvius. It is composed of white matter, connects the optic thalami, and probably contains decussating fibers derived from various sources.

The **Foramina of Monro** are the orifices of communication between the lateral ventricles and the third ventricle. Each foramen is bounded in front by the corresponding anterior crus of the fornix, behind by the optic thalamus and choroid plexus, above by the anterior crus of the fornix, and below by the ependyma reflected from the optic thalamus to the anterior crus of the fornix. The two foramina have a common orifice in the third ventricle, thus forming a Y-shaped passage, called the *foramen commune anterius*, through which cerebro-spinal fluid in one lateral ventricle may enter the other lateral ventricle.

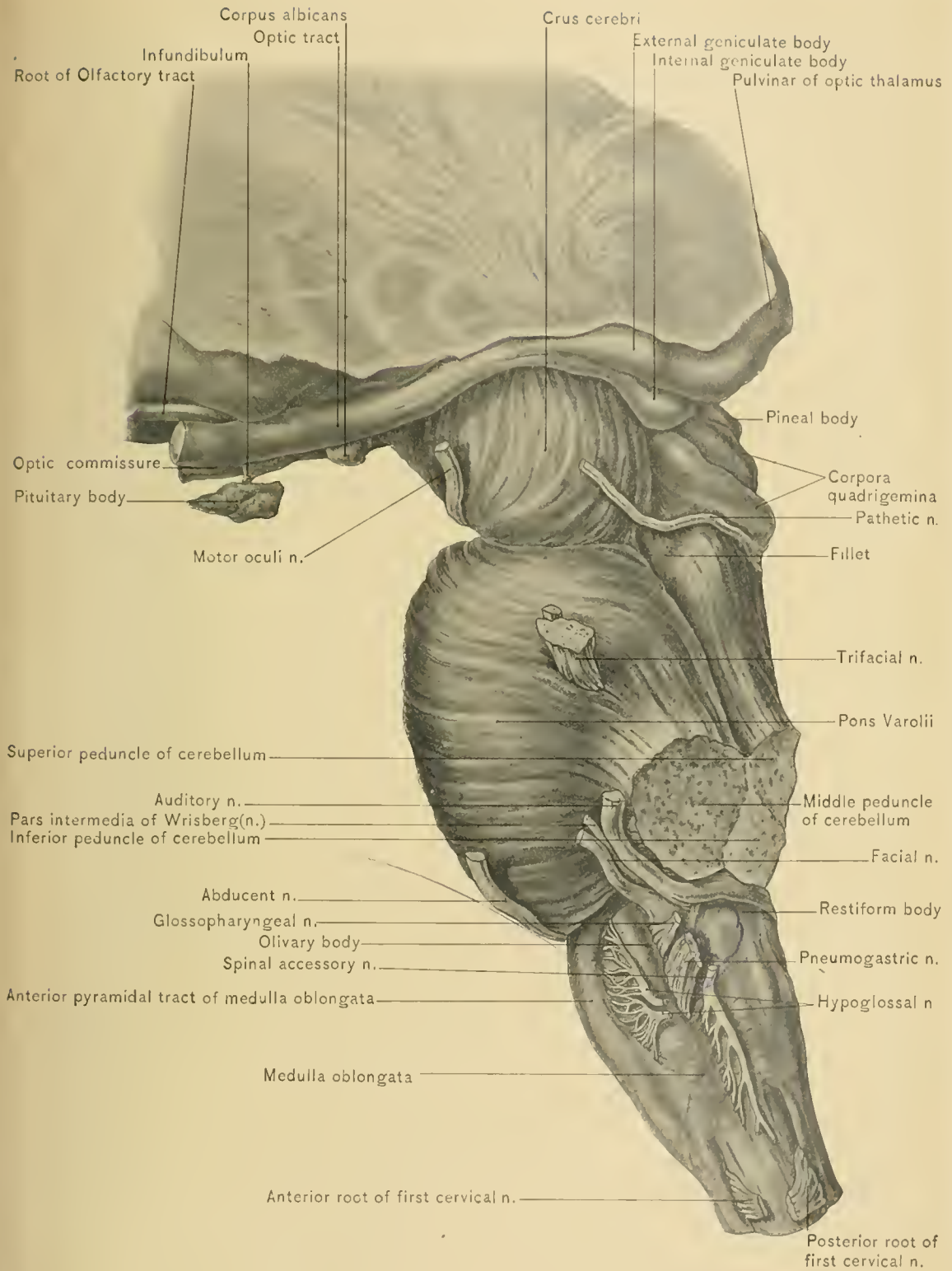
Aqueduct of Sylvius.—At the posterior extremity of the third ventricle, and beneath the posterior commissure, is seen the anterior orifice of the aqueduct of Sylvius, or *iter e tertio ad quartum ventriculum*. This is a narrow passageway about three-fourths of an inch, or two centimeters, in length, and passes beneath the quadrigeminal body to establish a communication between the third and fourth ventricles. It is lined with ependyma which is continuous with, and similar to, that lining the ventricles which it connects. Its *roof* is formed by the lamina quadrigemina, a plate of gray matter which supports the corpora quadrigemina. Its *floor* is formed by the tegmental portions of the crura cerebri. The gray matter in its floor contains the nuclei which give origin to the third and fourth cranial nerves.

The **Optic Thalami**, the posterior pair of cerebral ganglia, are two oval masses of white and gray matter. They are convex from before backward, and slightly so from side to side, and have their long axis directed obliquely from before backward and from within outward. They lie one upon each side of the third ventricle, between the tails of the caudate nuclei, and rest upon the crura cerebri. Each optic thalamus forms a large portion of the floor of the body of the lateral ventricle, while its posterior end projects into the descending cornu of that ventricle. Each optic thalamus consists of two extremities: an anterior, called the **anterior tubercle**, which forms the posterior boundary of the foramen of Monro, and a posterior, called the **pulvinar**, or **posterior tubercle**. The upper surface of each is partly free and partly covered by the choroid plexus of the lateral ventricle, the velum interpositum, and the lateral border of the body of the fornix. On its upper surface is situated an antero-posterior groove, called the **sulcus choroideus**, for the attachment of the velum interpositum. In the groove between the caudate nucleus and the optic thalamus lies the tenia semicircularis. The optic thalami are connected by the middle and posterior commissures of the third ventricle. Running along the upper border of each optic thalamus from behind forward are the peduncles of the pineal gland.

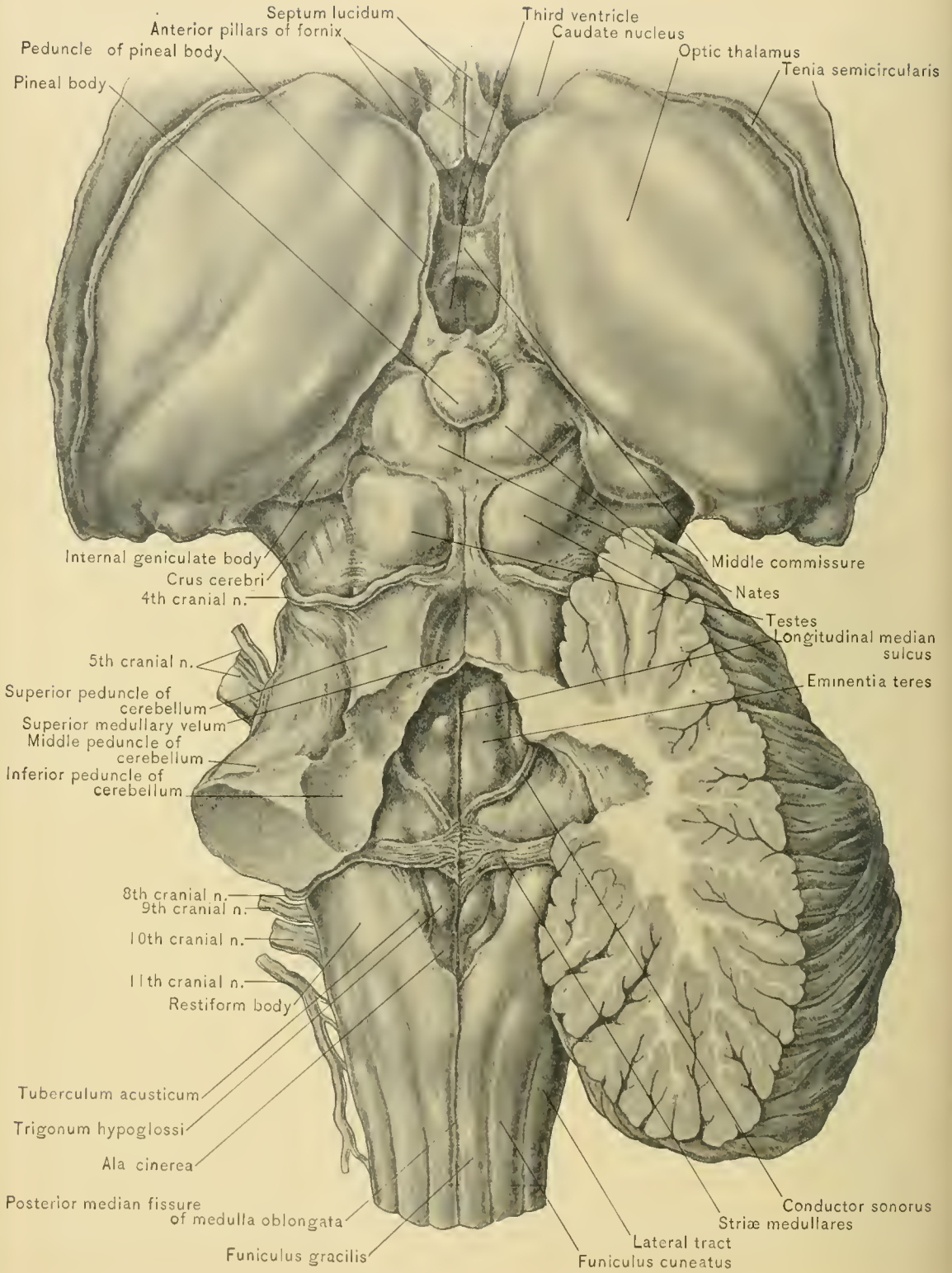
Geniculate Bodies.—The under surface of the posterior extremity of each optic thalamus, which forms part of the roof of the middle cornu of the lateral ventricle, presents two small gray eminences, the **internal** and **external geniculate bodies**. To see these bodies satisfactorily, turn the brain on its side and raise the posterior extremity of the optic thalamus. The internal geniculate bodies are connected internally with the nates of the corpora quadrigemina through the medium of the brachia, and externally are directly continuous with the optic tract.

The **Pineal Gland** or **Body**, **Conarium**, or **Epiphysis Cerebri**, is a small, reddish gray, oval body, about one-fourth of an inch, or six millimeters, in length. It is directed forward and upward, and rests upon the groove between the anterior pair of the corpora quadrigemina and above the posterior commissure of the third ventricle. From the base of the pineal body a white crus, or peduncle, passes forward upon each side of the third ventricle and along the upper and inner surface of the optic thalami to the anterior crura of the fornix, with which the peduncles become continuous. Posteriorly they are joined together in front of the base of the pineal body, and are connected with the posterior commissure of the third ventricle.

The **Corpora Quadrigemina**, or **Optic Lobes**, are situated immediately behind the third ventricle, and are composed of four eminences. These are arranged in two pairs: an anterior or upper, the larger of the two, and called the **nates**, and a



LATERAL VIEW OF CORPORA QUADRIGEMINA, PONS, AND MEDULLA.



THIRD AND FOURTH VENTRICLES AND CORPORA QUADRIGEMINA.

posterior or lower, called the **testes**. They are situated upon a layer of gray matter known as the **lamina quadrigemina**, which overlies the aqueduct of Sylvius. They give off anteriorly four bands or brachia, which are composed of white matter externally and gray matter internally. The *brachia of the nates*, or superior brachia, pass under the internal geniculate bodies into the optic tracts. The *brachia of the testes*, or inferior brachia, pass below and external to the brachia of the nates, and below the internal geniculate bodies leave the surface. The posterior quadrigeminal bodies or testes are each connected with the hemisphere of the cerebellum by a broad band of white matter, the superior peduncle of the cerebellum (*processus e cerebello ad testes*).

DISSECTION.—In order to see the superior cerebellar peduncles more clearly, the anterior extremity of the middle lobe of the cerebellum should be lifted slightly and pushed backward, or, better, a longitudinal incision should be carried through the middle of this lobe, and each half displaced laterally. This will expose these peduncles clearly and also show the fillet and the valve of Vieussens.

The **Superior Peduncle of the Cerebellum** (*processus e cerebello ad testes*) connects the hemisphere of the cerebellum with the opposite hemisphere of the cerebrum. It passes upward, forward, and inward along the side of the anterior part of the fourth ventricle, and beneath the corpora quadrigemina, where the fibers of the two peduncles decussate; beyond the corpora quadrigemina, along with the tegmental fibers of the crura cerebri, the fibers of each peduncle are continued to the optic thalamus and lenticular nucleus of the opposite hemisphere of the cerebrum.

The **Valve of Vieussens**, the anterior or superior medullary velum, is a triangular layer of white matter, narrow in front and broad behind, stretched between the superior peduncles of the cerebellum, and extending from the anterior extremity or nodule of the inferior vermiform process of the cerebellum to the corpora quadrigemina. It forms a portion of the roof of the fourth ventricle. Along the middle line of the upper surface is a longitudinal ridge, the *frenulum*. The lower half is overlapped by the *lingula*, a corrugated lobule of gray matter prolonged from the anterior extremity of the superior vermiform process. The trochlear nerves decussate within it, and emerge from its dorsal surface, just behind the inferior quadrigeminal bodies.

The **fillet** is a small, flat band or bundle of nerve fibers situated below and external to the superior peduncle of the cerebellum. It emerges from the pons at the upper limit of its posterior region, and appears as a triangular band which is situated above the crus cerebri and disappears under the testis and brachium of the testis.

DISSECTION.—If the superior and inferior vermiform processes of the cerebellum were not divided longitudinally when exposing the valve of Vieussens,

they should be divided now, and each half reflected laterally to expose the fourth ventricle.

The **Fourth Ventricle** is a quadrangular, lozenge-shaped space, situated between the cerebellum and the posterior surface of the medulla oblongata and pons Varolii.

The *roof* is formed anteriorly by the valve of Vieussens and the superior peduncles of the cerebellum, and posteriorly by the inferior medullary velum, the inferior vermiform process of the cerebellum, the choroid plexus, and the tela choroidea inferior. The *floor* is formed by the posterior surface of the medulla oblongata and pons Varolii. It is bounded laterally by the superior peduncles of the cerebellum above, and the inferior peduncles of the cerebellum below. The ventricle is lined by the ependyma or epithelial wall of the ventricles of the brain. The ventricle presents four angles, a superior, an inferior, and two lateral (also called the lateral recesses of the ventricle). The widest part of the ventricle corresponds to the interval between the lateral angles, which are at about its middle.

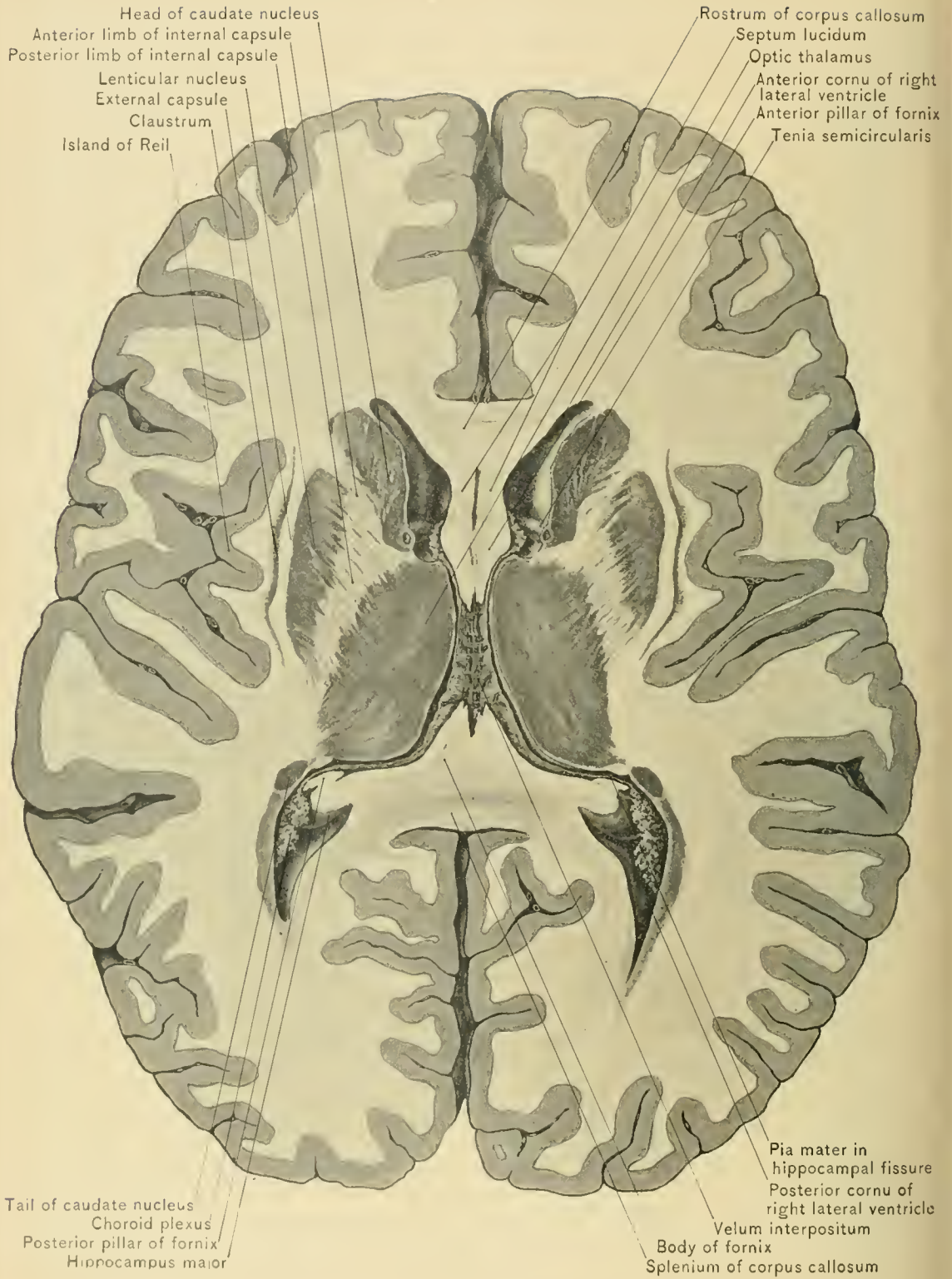
The **Tela Choroidea Inferior** is that part of the pia mater on the posterior surface of the medulla oblongata which completes the posterior part of the roof of the fourth ventricle. It contains three perforations: the foramina of Magendie, Key, and Retzius.

The foramen of Magendie is located in the median line near the inferior angle of the fourth ventricle. The foramina of Key and Retzius are located at the lateral recesses of the ventricle. By way of these openings the ventricle communicates with the general subarachnoid space.

The two **choroid plexuses** of the fourth ventricle are also derived from the pia mater by the intrusion of its folded edge into the roof of that cavity. They extend forward from the posterior angle of the fourth ventricle near the median line for a short distance, and then diverge to reach the lateral recesses of the ventricle.

The fourth ventricle communicates with the third ventricle by way of the aqueduct of Sylvius, and with the central canal of the spinal cord through an opening in the inferior angle which is dilated and is called the *ventricle of Arantius*.

The floor of the fourth ventricle is its most important part, for the reason that the nuclei of most of the cranial nerves are situated there. It is composed chiefly of gray matter continuous with the gray matter of the spinal cord. Occupying the middle line of the floor of the fourth ventricle is the **median longitudinal fissure**. It extends from the posterior orifice of the aqueduct of Sylvius to the posterior or inferior angle of the ventricle, which is at the point of divergence of the



TRANSVERSE SECTION OF CEREBRUM.

restiform bodies of the medulla. This fissure is continuous below with the central canal of the spinal cord. This portion of the fourth ventricle has received the name of **calamus scriptorius** because of the resemblance of the longitudinal fissure and the diverging posterior pyramids and restiform bodies to the point of a pen. Immediately to each side of the median furrow is a longitudinal ridge, the **eminentia teres**. Crossing this eminence in the lower half of the ventricle are bands of white matter, the auditory striæ or **striæ acusticæ**. To the outer side of the eminentia teres and anterior to the auditory striæ is a depressed area, the *superior fovea*, while behind the auditory striæ, and to the outer side of the eminentia teres, are two furrows so united as to form an inverted V, the *inferior fovea*; the floor of the inferior fovea is known as the **ala cinerea**.

The **trigonum hypoglossi** is the area of the floor of the fourth ventricle bounded by the longitudinal fissure, striæ acusticæ, and inferior fovea, and covers the nucleus of the hypoglossal nerve. The **tuberculum acusticum** is the triangular area situated between the inferior fovea and the clava of the funiculus gracilis, and extending forward under the striæ acusticæ.

In front of the superior fovea and external to the eminentia teres is a small eminence of dark gray matter, the **locus cæruleus**. Prolonged forward from the locus cæruleus, at the side of the eminentia teres and extending to the upper end of the floor of the ventricle, is a thin streak of dark gray matter, the **tænia violacea**. The locus cæruleus and tænia violacea are produced by the substantia ferruginea, whose dark color is seen through the overlying white matter. The **substantia ferruginea** is the dark, pigmented mass seen in sections of the upper part of the floor of the fourth ventricle. The ependyma lining the fourth ventricle is continuous through the aqueduct of Sylvius with that lining the third ventricle.

DISSECTION.—Next complete the dissection of the cerebrum by making horizontal sections of the corpora striata and optic thalami, carrying the incisions through to the external or lateral surface of the hemisphere. This will expose the caudate nucleus, the internal capsule, the lenticular nucleus, the external capsule, the claustrum, and the island of Reil from within outward in the order named.

The **Caudate Nucleus**, or intra-ventricular portion of the corpus striatum, is the more anterior of the gray basal ganglia, and has been described.

The **Internal Capsule** lies external to and behind the caudate nucleus, and separates the caudate from the lenticular nucleus, and the lenticular nucleus from the optic thalamus. The internal capsule, composed of white matter and somewhat crescentic or angular in shape, consists of a genu and two limbs, an anterior and a posterior. The *anterior limb*, named by Spitzka the caudo-lenticular portion, intervenes between the caudate and lenticular nuclei. The *posterior limb*, named by the same author the thalamo-lenticular portion, intervenes between the

optic thalamus and the lenticular nucleus. The *genu*, the point where the capsule presents the greatest angularity, is opposite the interval between the caudate nucleus and the optic thalamus.

Through the internal capsule the nerve fibers pass in their course from the gray matter of the cortex of the cerebrum and caudate and lenticular nuclei to the crus cerebri, which transmits these fibers from the cerebrum to the pons, medulla oblongata, and spinal cord. In addition to these fibers the internal capsule contains fibers from the cerebral cortex to the optic thalamus.

The anterior third of the internal capsule contains the fibers from the cortex of the prefrontal lobe, or silent region, the middle third, the fibers from the motor or Rolandic area of the cortex of the cerebrum, and the posterior third, the sensory fibers from the occipital and temporal lobes.

Destruction of the anterior two-thirds of the posterior segment of the internal capsule, which occurs in many cases of *apoplexy*, results in motor paralysis of the opposite side of the body. This paralysis is diffuse, and not confined to a group of muscles, as in lesions of the cerebral cortex, while destruction of the posterior part of the posterior limb of the internal capsule results in loss of sensation of the opposite side of the body. A small hemorrhage in the capsule will cause paralysis of that part of the opposite side of the body supplied by the fibers compressed by the clot of blood.

The **Lenticular Nucleus**, or extraventricular portion of the corpus striatum, is larger than the caudate nucleus, is oval in form, and lies behind and to the outer side of the caudate nucleus. It is separated from the caudate nucleus by the anterior limb and genu of the internal capsule, and from the optic thalamus by the posterior limb of the internal capsule.

The **external capsule** is a band of white matter which lies to the outer side of the lenticular nucleus, and joins the internal capsule below the lenticular nucleus.

The **claustrum** is a thin layer of gray matter, lying to the outer side of the external capsule.

The **Island of Reil**, previously described, is external to the claustrum, and separated from it by a layer of white matter.

White Matter of Cerebrum.—In the dissection of the cerebrum, which will be completed when the crura cerebri have been traced from the upper border of the pons to each hemisphere, it should be noted that the white matter of the cerebrum is composed of three systems or sets of medullated nerve fibers, the ascending or peduncular, the transverse commissural, and the longitudinal commissural. The *ascending* or *peduncular fibers* are those fibers of the crura cerebri which, in diverging to reach the nerve cells of the cerebral cortex, form the *corona*

radiata, so called on account of the crown-like radiation of its fibers. The *transverse commissural fibers* include the fibers of the corpus callosum and the anterior and posterior commissures of the third ventricle. The *longitudinal commissural fibers* include the fibers of the fornix, the striae longitudinales of the corpus callosum, the tenia semicircularis, fibers in the gyrus fornicatus and gyrus hippocampi, and the peduncles of the pineal body. They also include the associating fibers: those fibers which connect the cells of neighboring and of more distant convolutions.

THE PONS VAROLII.

DISSECTION.—Having completed the dissection of the cerebrum, excepting the tracing of the crura cerebri, turn the brain so as to expose the base, and study the pons, then the medulla oblongata, and lastly the cerebellum.

The **Pons Varolii**, or **Tuber Annulare**, is that division of the brain through the medium of which the other three divisions of the brain are united. It is connected with the cerebrum, above, by the crura cerebri, or peduncles of the cerebrum; with the cerebellum, behind, by the middle peduncles of the cerebellum; and with the medulla, below, by the fibers of the pyramidal tract of the medulla oblongata. It is situated behind the crura cerebri, in front of the medulla oblongata, between and below the hemispheres of the cerebellum, and between the posterior portion of the temporo-sphenoid lobes of the cerebrum. In the cranial cavity it lies below the level of the superior occipital foramen of the tentorium cerebelli, and rests upon the basilar process of the occipital bone and the posterior surface of the body of the sphenoid bone. It is quadrangular in shape, and is composed chiefly of white matter, the fibers of which are arranged transversely and longitudinally. It presents two surfaces, an anterior and a posterior. The *anterior surface* is markedly convex from side to side, and slightly so from before backward, and measures transversely about one and one-half inches, or four centimeters, and is about one inch, or twenty-five millimeters, in length. The anterior surface is marked along the middle line by a groove, which is broader in front than behind, and lodges the basilar artery. The anterior surface presents two borders, an upper and a lower. The upper border, the longer, is convex, and arches beneath the crura cerebri. The lower border is almost straight, and is separated from the medulla oblongata by a transverse groove. The *posterior surface* is slightly concave from side to side, and forms part of the floor of the fourth ventricle. From the side of the pons the trifacial or fifth cranial nerve is seen emerging.

In coronal sections the pons can be divided into an anterior or ventral region, and a posterior or tegmental region. The *anterior region of the pons* is composed of transverse and longitudinal fibers. The *superficial transverse fibers* of the ante-

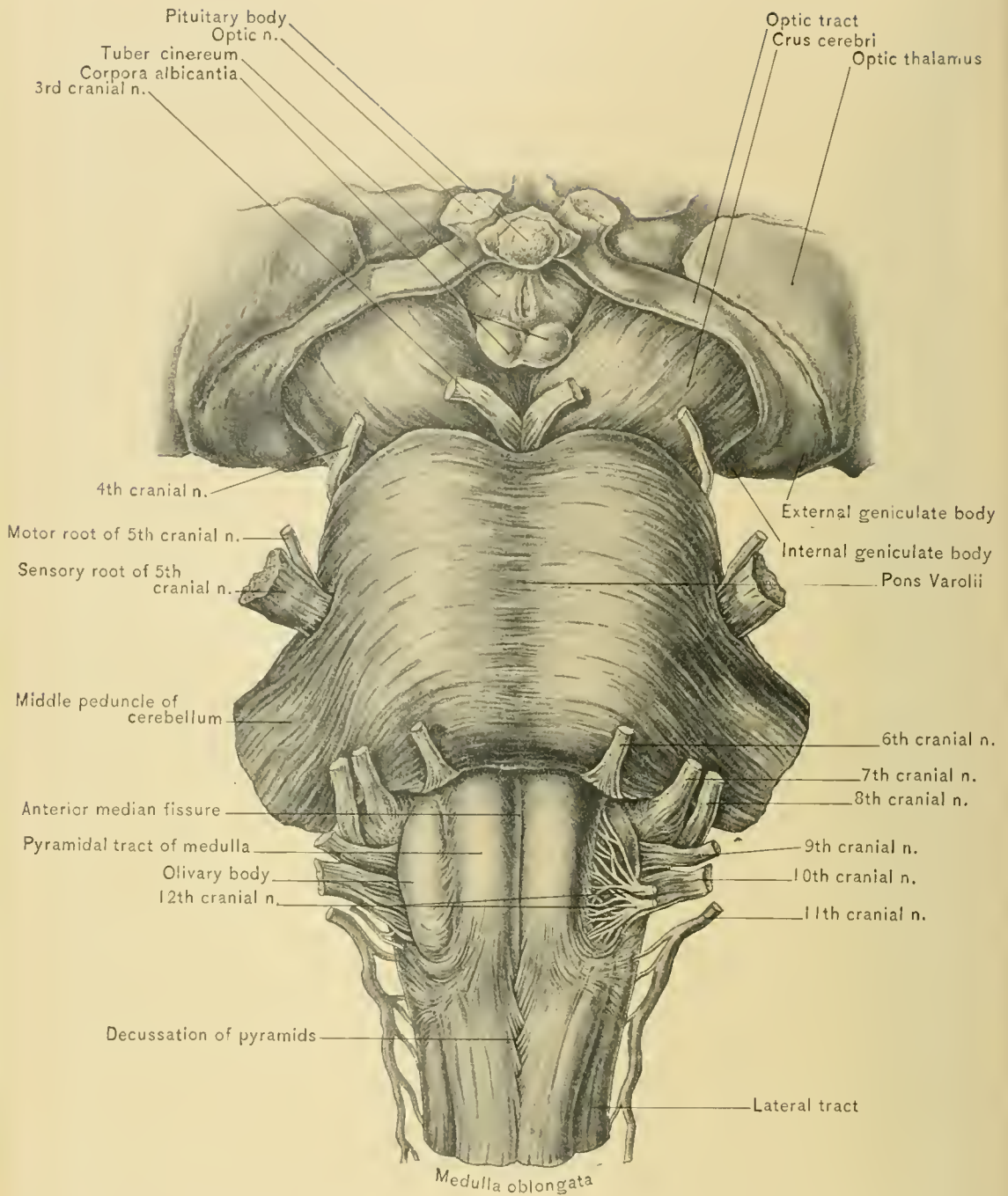
rior region of the pons pass obliquely outward and backward to the hemispheres of the cerebellum, forming the middle peduncles of the cerebellum. The *deep transverse fibers* of the anterior region of the pons are decussating fibers, which are crossing in the pons in passing from the cerebellar hemisphere of one side to the cerebral hemisphere of the opposite side. The *longitudinal fibers* are more deeply situated than the superficial transverse fibers, and are separated into bundles by the deep transverse fibers. They are the fibers of the pyramidal tracts of the medulla oblongata, passing upward to enter the crustæ of the crura cerebri.

In the *posterior or tegmental region of the pons* the chief structures observed are the tract of the fillet, which is seen nearest the anterior region, the formatio reticularis, the posterior longitudinal bundle, and the superior olivary nucleus. This region of the pons also contains the nuclei of the sixth and seventh cranial nerves, and a part of the nucleus of the eighth cranial nerve. While the importance of these nuclei has been clearly proved by clinical experience in cases of paralysis caused by hemorrhage occurring within the substance of the pons, as well as by microscopic investigation, they are not macroscopically visible.

Hemorrhage into the pons is usually followed by coma and sudden death, particularly if the hemorrhage is extensive, or if the blood escapes into the fourth ventricle. The decussation of the trifacial and the facial nerves takes place within the pons; if, therefore, a lesion—as, for example, a small hemorrhage—occur above the point of the crossing of the fibers of the facial nerve, paralysis of the face and body on the side opposite the lesion will occur; while if the lesion be immediately below the point of crossing, the paralysis of the face will be upon the side of the lesion and the hemiplegia upon the side opposite to the lesion, thus giving rise to the condition known as *crossed hemiplegia*. Nerve fibers from the motor cortical area for speech run through the pons, and may be involved in a lesion of the pons, thus giving rise to aphasia.

The **Crura Cerebri**, or **Peduncles of the Cerebrum**, are two large round bodies of white matter, about three-fourths of an inch, or two centimeters, in length, and broader in front than behind. They emerge from the upper border of the pons, whence they pass outward and forward to enter the under part of the hemispheres of the cerebrum. They pass through the superior occipital foramen in company with the superior peduncles of the cerebellum, the basilar artery, and the oculo-motor and pathetic nerves. Crossing the lower surface of the crura just before they enter the hemispheres of the cerebrum, and adherent to them, are the optic tracts, while in relation with their inner borders are the oculo-motor nerves, and with their outer margins, the pathetic nerves.

DISSECTION.—Divide one of the crura cerebri transversely, and a nucleus of



PONS, MEDULLA, AND SUPERFICIAL ORIGINS OF CRANIAL NERVES.

gray matter—the *locus niger*, or substantia nigra—will be seen in the interior of the crus. Through the medium of this nucleus the crus cerebri is divided into an upper or posterior portion and a lower or anterior portion. The upper or posterior portion is known as the tegmentum, and the lower or anterior portion as the crusta.

The **tegmentum of the crus cerebri** is composed largely of the longitudinal fibers of the tegmental region of the pons, which proceed from the lateral tract and posterior pyramids of the medulla oblongata; it also receives the fibers of the superior peduncle of the cerebellum. The tegmental fibers of the crus cerebri are sensory, and enter the hemisphere of the cerebrum below and through the optic thalamus, beyond which they form part of the corona radiata. The tegmentum contains two nuclei, the *subthalamic body* and the *tegmental* or *red nucleus*. The admixture of gray and white matter of the tegmentum forms the *formatio reticularis*.

The **crusta** is composed chiefly of the longitudinal fibers of the anterior region of the pons, which proceed from the anterior pyramids of the medulla. The fibers of the crusta are motor, and enter the hemisphere through the internal capsule, beyond which they form a part of the corona radiata. The inner one-fifth of the crusta contains fibers which are passing to the pons from the prefrontal lobe.

THE MEDULLA OBLONGATA.

The **Medulla Oblongata**, or **Bulb**, the upper continuation of the spinal cord, begins at the decussation of the pyramids or the upper border of the atlas, and extends to the lower border of the pons Varolii, being not quite one and one-half inches, or 3.5 centimeters, in length. It increases in width from below upward, and just below the pons it is about three-fourths of an inch, or two centimeters, wide. Its anterior or ventral surface rests partly upon the basilar portion of the occipital bone, and its posterior or dorsal surface is directed toward the vallecule of the cerebellum, which lodges part of the medulla. The anterior surface presents, in the median line, the *anterior median fissure*, which is the continuation upward of the anterior median fissure of the spinal cord, which fissure is, however, interrupted by white fibers crossing from one side to the other and forming the decussation of the pyramids. On its posterior aspect, for one-half the length of the medulla, is situated the *posterior median fissure* or sulcus, the continuation of the corresponding fissure of the spinal cord.

The medulla oblongata, like the spinal cord, is divided into an anterior, a lateral, and a posterior area. The *anterior area* is occupied by the anterior pyramids. The *lateral area* is occupied by the olivary body and the lateral column.

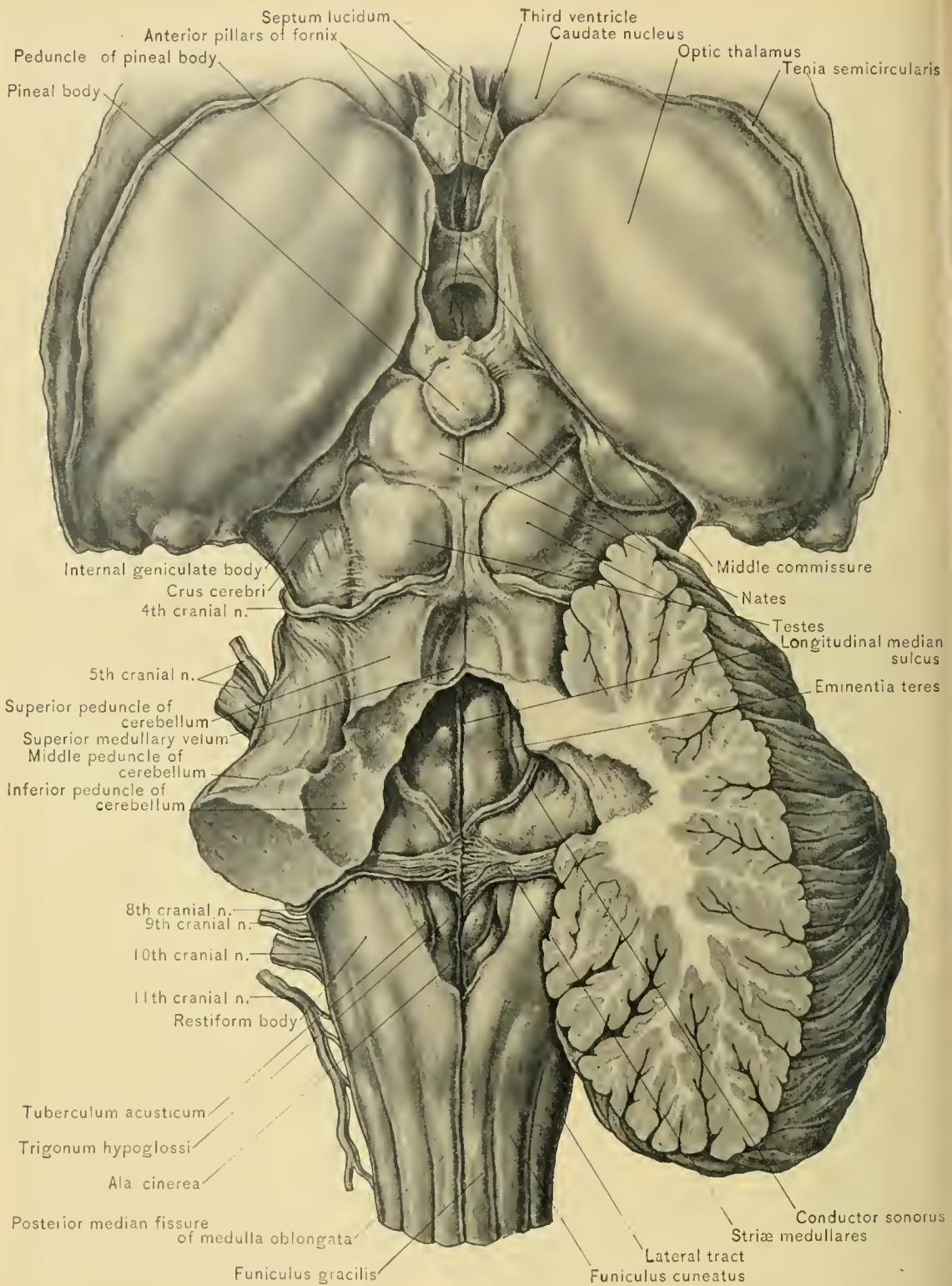
The *posterior area* contains the funiculus of Rolando, funiculus euneatus, and funiculus gracilis, and in its upper portion is the restiform body.

The **Anterior Pyramids**, or **Pyramids of the Medulla Oblongata**, are situated between the anterior median and antero-lateral fissures. They are larger above, but are somewhat constricted and rounded where they disappear beneath the superficial transverse fibers of the pons. On separating the anterior pyramids below, bundles of fibers will be seen decussating across the anterior median fissure. This decussation is produced by the innermost fibers of the pyramids, which are derived from the lateral or crossed pyramidal tracts of the spinal cord, and have reached the surface of the medulla oblongata at this point by cutting through the anterior horn of the gray matter of the spinal cord, and pushing aside the anterior pyramid. The outermost fibers, which form the smaller number of fibers of the pyramid, do not decussate, and continue downward as the direct pyramidal tract of the spinal cord; these fibers decussate in the anterior or white commissure of the spinal cord. The decussation of the pyramids of the medulla explains the fact that in disease or injury of the motor cortex of the brain the paralysis is found on the side of the body opposite to the lesion in the brain.

The continuation of the anterior ground bundle of the spinal cord is not seen in the anterior area of the medulla oblongata, as the fibers of that tract are depressed from the surface by the decussating bundles of the crossed pyramidal tract.

The **Olivary Body** is an oval prominence on the medulla oblongata, situated to the outer side of the anterior pyramid. It is separated from the anterior pyramid by a narrow longitudinal groove, the hypoglossal sulcus, or *antero-lateral furrow* of the medulla, which is continuous with the antero-lateral fissure of the spinal cord. The olivary body is limited posteriorly by the *post-olivary sulcus*. Like the anterior pyramid, it is broader above than below. It is separated from the pons by a deep groove, and is about one-half an inch, or twelve to fifteen millimeters, in length. Emerging from the hypoglossal sulcus or antero-lateral furrow are the roots of the hypoglossal nerve. Arching below and over the olivary body, and emerging from the anterior median and antero-lateral fissures, several white bundles are seen—the **superficial arciform fibers**—which enter the restiform body of the same side. If an oblique incision be carried through the olivary body, there will be revealed in its interior a nucleus of gray matter, the **corpus dentatum** of the olivary body. This nucleus is arranged in the form of a hollow capsule, and presents a convoluted outline partly incomplete at its inner side. Through this open part of the capsule passes a bundle of white fibers, the **peduncle of the olivary body**.

The **Lateral Tract of the Medulla Oblongata** is apparently the upward extension of the lateral column of the spinal cord, but it does not contain the crossed



THIRD AND FOURTH VENTRICLES AND CORPORA QUADRIGEMINA.

pyramidal tract of the cord, which enters the pyramidal tract of the medulla oblongata, and the direct cerebellar tract of the cord leaves it to enter the restiform body. It is bounded in front by the antero-lateral furrow, and behind by the postero-lateral furrow. Emerging from the antero-lateral furrow or hypoglossal sulcus are the roots of the hypoglossal nerve, and from the postero-lateral furrow the roots of the glosso-pharyngeal, pneumogastric, and spinal accessory nerves emerge. As it ascends, the lateral tract of the medulla becomes less marked, the greater portion of it passing beneath the olivary body.

DISSECTION.—To examine satisfactorily the remaining portion of the medulla oblongata, lift it out from the interval between the hemispheres of the cerebellum, and displace it forward, thus exposing the posterior surface of the medulla, as well as that portion of the floor of the fourth ventricle formed by the medulla.

The **Funiculus of Rolando**, which lies posterior to the lateral tract and on the outer side of the funiculus cuneatus, is the upward continuation of a mass of gray matter—the *substantia gelatinosa*—which caps the posterior cornu of the gray matter of the spinal cord. This funiculus presents an enlargement on a level with the lower end of the olivary body, called the **tubercle of Rolando**.

The **Funiculus Cuneatus** lies between the funiculus of Rolando and the posterior median column or posterior pyramid. It is the widest and thickest of the columns of the medulla. Opposite the clava of the funiculus gracilis it forms a prominence called the **cuneate tubercle**.

The **Posterior Pyramid**, or **Funiculus Gracilis**, the continuation upward of the posterior median column of the spinal cord, lies immediately to the outer side of the posterior median fissure. At the lower end of the fourth ventricle it swells out and forms a prominence, called the **clava**. The cuneate tubercle and the clava are produced by accumulations of gray matter known respectively as the *cuneate and gracile nuclei*; almost all the fibers of the funiculus cuneatus and funiculus gracilis terminate in these nuclei.

The **Restiform Body** appears to be formed by the funiculus gracilis, the funiculus cuneatus, and the funiculus of Rolando, passes outward and upward, and then enters the cerebellum, forming the inferior peduncle of the cerebellum. Since the fibers of the funiculus cuneatus and funiculus gracilis terminate in the cuneate and gracile nuclei, they can not, therefore, strictly speaking, be said to be directly continued into the restiform bodies. The following are the more important of the sources from which the fibers of the restiform body are derived: “(1) From the lateral column of the spinal cord, through the direct cerebellar tract; (2) from the convoluted nucleus of the olivary body of the opposite side; (3) from the gracile and cuneate nuclei of the opposite side; (4) from the gracile and cuneate nuclei of the same side” (Cunningham). By the divergence of the restiform bodies the lateral

boundaries of the lower part of the fourth ventricle are formed, while the apex of the lower triangle of the ventricle is situated at the point of separation of the two clavæ. This divergence exposes the gray matter of the interior of the medulla, which forms the floor of the lower portion of the fourth ventricle and is continuous with the gray matter of the spinal cord.

RECAPITULATION.—Review the parts seen in studying the medulla from before backward. They are: The anterior median fissure, the anterior pyramid, the hypoglossal or antero-lateral fissure with the roots of the hypoglossal nerve, the olivary body, containing the corpus dentatum, the post-olivary sulcus, the lateral tract, the postero-lateral fissure with the roots of the glosso-pharyngeal, pneumogastric, and spinal accessory nerves, the funiculus of Rolando and its tubercle, the funiculus cuneatus with the cuneate tubercle, the funiculus gracilis with the clava, and the posterior median fissure.

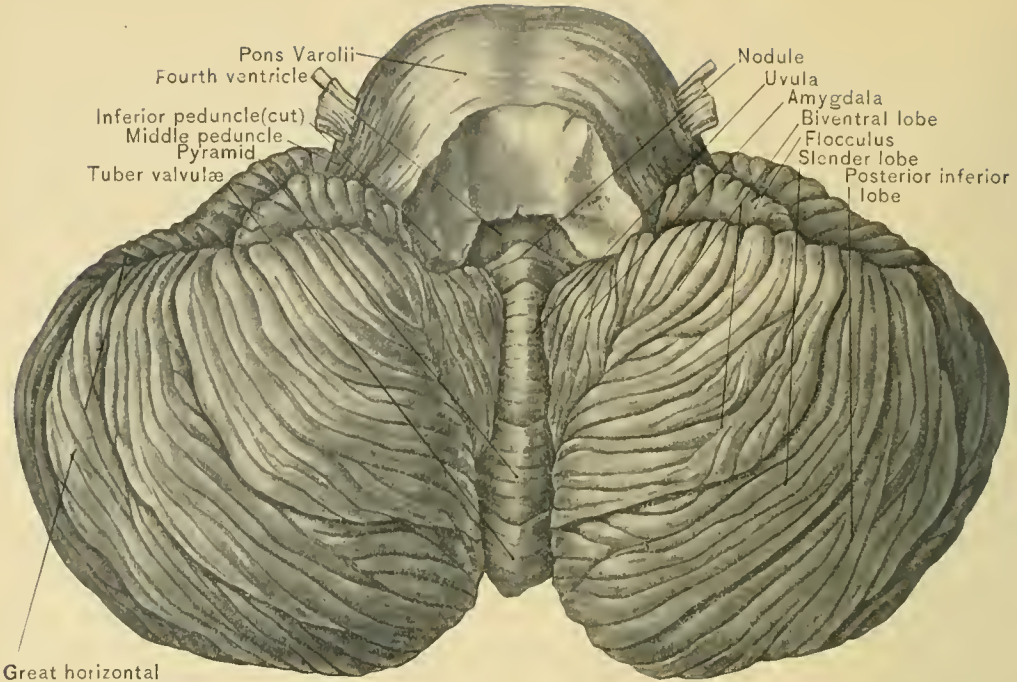
FUNCTION.—The medulla is described by Ranney as “the true nerve center of animal life.” Several of the cranial nerves have their primary, deep, or central origin wholly or in part in the medulla. Some of the centers contained within the medulla are the respiratory, the vaso-motor, the cardio-inhibitory, the diabetic, and a salivary center.

THE CEREBELLUM.

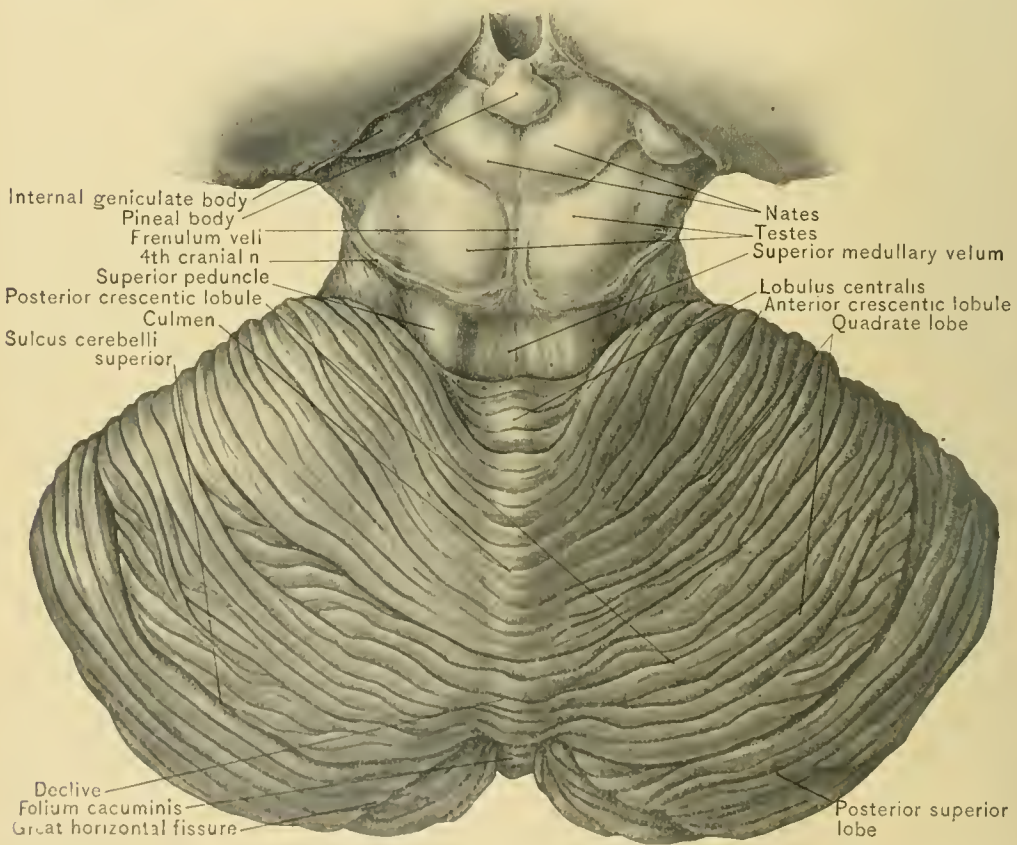
Position, Size, and Connections.—The cerebellum, or little brain, lies beneath the occipital lobes of the cerebrum, behind the pons, and above and upon both sides of the medulla oblongata. It occupies the inferior occipital fossæ, and lies beneath the tentorium cerebelli, which separates it from the cerebrum.

The surface of the cerebellum, like that of the cerebrum, is composed of gray matter, which is darker in color in the cerebellum, and arranged in *laminae* instead of in convolutions. The cerebellum measures from three and one-half to four inches, or from nine to ten centimeters, in its transverse diameter, from two to two and one-half inches, or from five to six centimeters, in its antero-posterior diameter, and about two inches, or five centimeters, in its vertical diameter at the thickest part. It is attached to the cerebrum by the superior peduncles, to the pons by the middle peduncles, and to the medulla oblongata by the inferior peduncles of the cerebellum.

Lobes.—The cerebellum consists of two hemispheres and a central lobe,—the vermiform process, or vermis,—through the medium of which the hemispheres are united. The hemispheres are separated inferiorly by a comparatively wide and deep median groove, the **vallecula**, or valley, which is occupied in great part by the medulla oblongata; the inferior vermiform process of the cerebellum also pro-



INFERIOR SURFACE.



SUPERIOR SURFACE.

INFERIOR AND SUPERIOR SURFACE OF CEREBELLUM.

jects into the valley. The hemispheres are separated in front by a notch, the **incisura cerebelli anterior**, which lodges the inferior pair of corpora quadrigemina and the superior cerebellar peduncles; and behind by another notch, the **incisura cerebelli posterior** or **incisura marsupialis**, which is the posterior extremity of the valley and lodges the falx cerebelli. The **central lobe**, or **vermiform process**, presents two aspects: an upper, seen as a slight elevation in the middle of the upper surface of the cerebellum, and called the superior vermiform process, and an inferior, which is called the inferior vermiform process. Passing along the free border of each hemisphere is the **great horizontal fissure of the cerebellum**, which commences at the point where the middle peduncle of the cerebellum enters the hemisphere, and extends backward and around to the other middle peduncle of the cerebellum. The horizontal fissure separates the upper from the lower surface of the hemisphere.

DISSECTION.—Before proceeding further with the study of the cerebellum, remove what remains of the cerebrum by carrying an incision through the optic thalami and the crura cerebri, and detach the pia mater from the cerebellum.

The **Superior Vermiform Process** is the upper surface of the vermiform process, or middle lobe of the cerebellum, and is raised above the level of the superior surface of the hemispheres of the cerebellum. It is divided into the following lobes: **lingula**, **lobulus centralis**, **monticulus cerebelli**, and **folium cacuminis**. The **lingula** overlies the posterior part of the superior medullary velum and is adherent to it. It is attached at its base to the lobulus centralis. The **lobulus centralis** lies immediately posterior to and below the corpora quadrigemina; it spreads out laterally into the *alæ of the hemispheres*. The **monticulus cerebelli** is divided into two parts, the *culmen* and the *clivus*, the latter being a sloping part; it is connected on each side to the quadrate lobe. The *culmen* joins the anterior crescentic division of the quadrate lobe, and the *clivus* joins the posterior crescentic division. The **folium cacuminis**, which connects the posterior superior lobes of the hemispheres, is posterior to the *clivus*.

The **Upper Surface of Each Hemisphere of the Cerebellum** slopes outward and backward from the superior vermiform process, and is divided into two lobes—the quadrate and the posterior superior lobe—by the **superior sulcus of the cerebellum**, which passes from the commencement of the transverse fissure toward the *incisura cerebelli posterior*. The **quadrate lobe** is situated anterior to the sulcus cerebelli superior, and extends nearly to the posterior end of the vermiform process, its laminae passing without interruption through the **monticulus cerebelli** into the corresponding lobe of the opposite side. The quadrate lobe is divided by a small fissure into an *anterior crescentic* and a *posterior crescentic lobule*. The **posterior superior lobe** is situated posterior to the sulcus cerebelli superior and

along the posterior border of the hemisphere, and is joined to the posterior superior lobe of the opposite side by the folium cacuminis.

DISSECTION.—Displace the medulla oblongata forward, and expose the inferior vermiform process at the bottom of the vallecule.

The **Inferior Vermiform Process** is divided into four lobes, named, from before backward, the nodule, the uvula, the pyramid, and the tuber valvulæ. The **nodule**, designated by Malacarne the **laminated tubercle**, is the anterior extremity of the inferior vermiform process, and projects into the fourth ventricle, forming a part of the roof of that ventricle. It is connected upon both sides to the flocculi, upon the under surface of the hemispheres, by a thin, semilunar layer of white substance, the **posterior or inferior medullary velum**. The **uvula**, situated directly behind the nodule, is an elongated lobe compressed laterally, and is connected on each side to the amygdaloid lobe, or tonsil, by an indented strip of gray matter, the **furrowed band**. The **pyramid**, situated behind the uvula, is the largest of the divisions of the process, and connects the biventral lobes of the hemispheres. The **tuber valvulæ**, the posterior extremity of the inferior vermiform process, connects the two inferior posterior and the two slender lobes of the hemispheres.

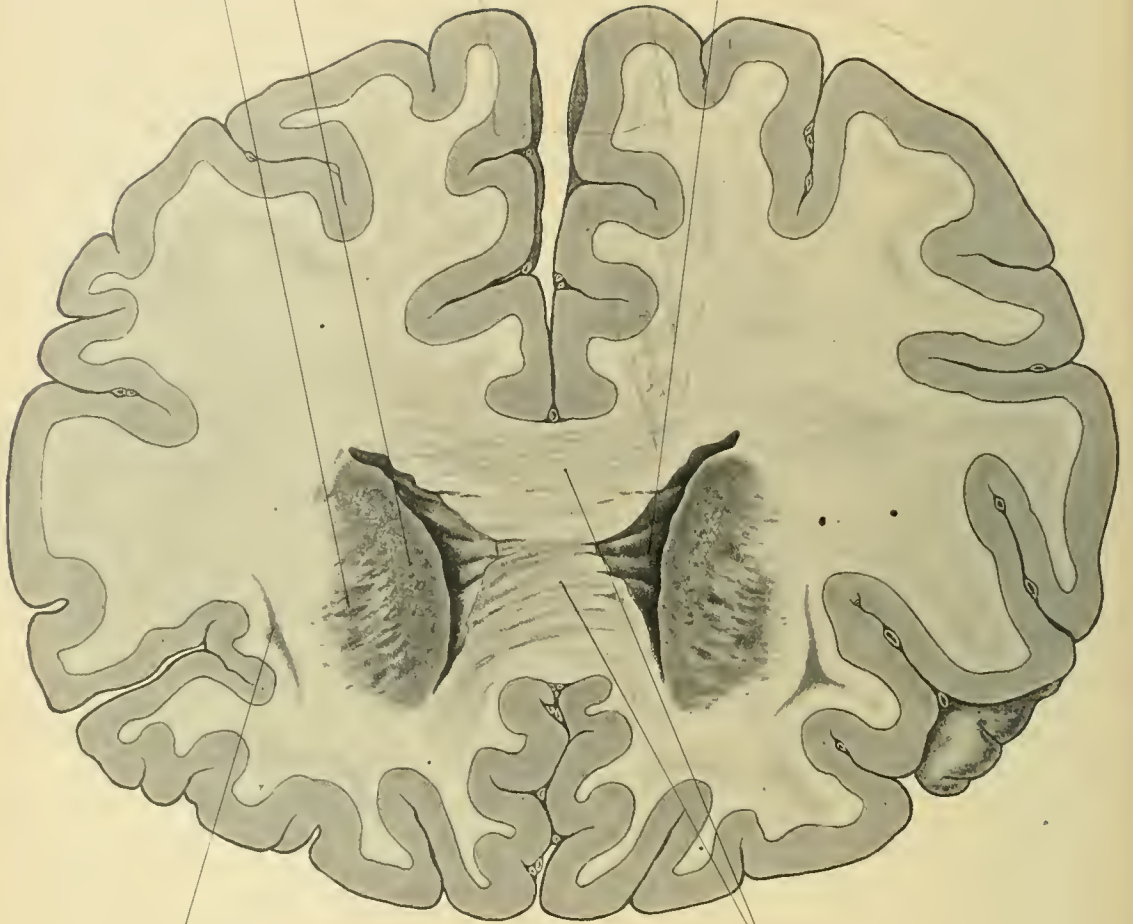
The **Under Surface of Each Hemisphere** of the cerebellum, which is convex and conforms to the occipital fossa in which it rests, is divided into five lobes, named, from before backward, the flocculus, the amygdala, or tonsil, the digastric or biventral, the slender, and the posterior inferior. The **flocculus**, the smallest lobe, is situated at the anterior part of the hemisphere, between the digastric or biventral lobe and the middle peduncle of the cerebellum, in the line of the great horizontal fissure of the cerebellum. The **amygdala**, or **tonsil**, is situated to the inner side of the digastric or biventral lobe, and between that lobe and the vallecule. It is connected with the uvula by the furrowed band. The *digastric* or *biventral*, the largest lobe, lies behind the flocculus, and external to the amygdala and the pyramid; it is connected with the digastric lobe of the other hemisphere by the pyramid. The *slender lobe*, or *lobulus gracilis*, lies immediately behind the digastric lobe, and external to the pyramid and the tuber valvulæ. The *posterior inferior lobe* lies between the posterior border of the hemisphere and the slender lobe, and external to the tuber valvulæ.

DISSECTION.—Cut away the amygdala on one side, or slice off the digastric and slender lobes until the amygdala can be turned out; this will expose the furrowed band, the posterior medullary velum and the fossa, known as the “swallow’s nest” (*nidus hirundinis*), which is indented by the posterior medullary velum, the nodule, and the uvula.

The **Peduncles of the Cerebellum** are the superior, the middle, and the inferior.

Head of caudate nucleus
Lenticular nucleus

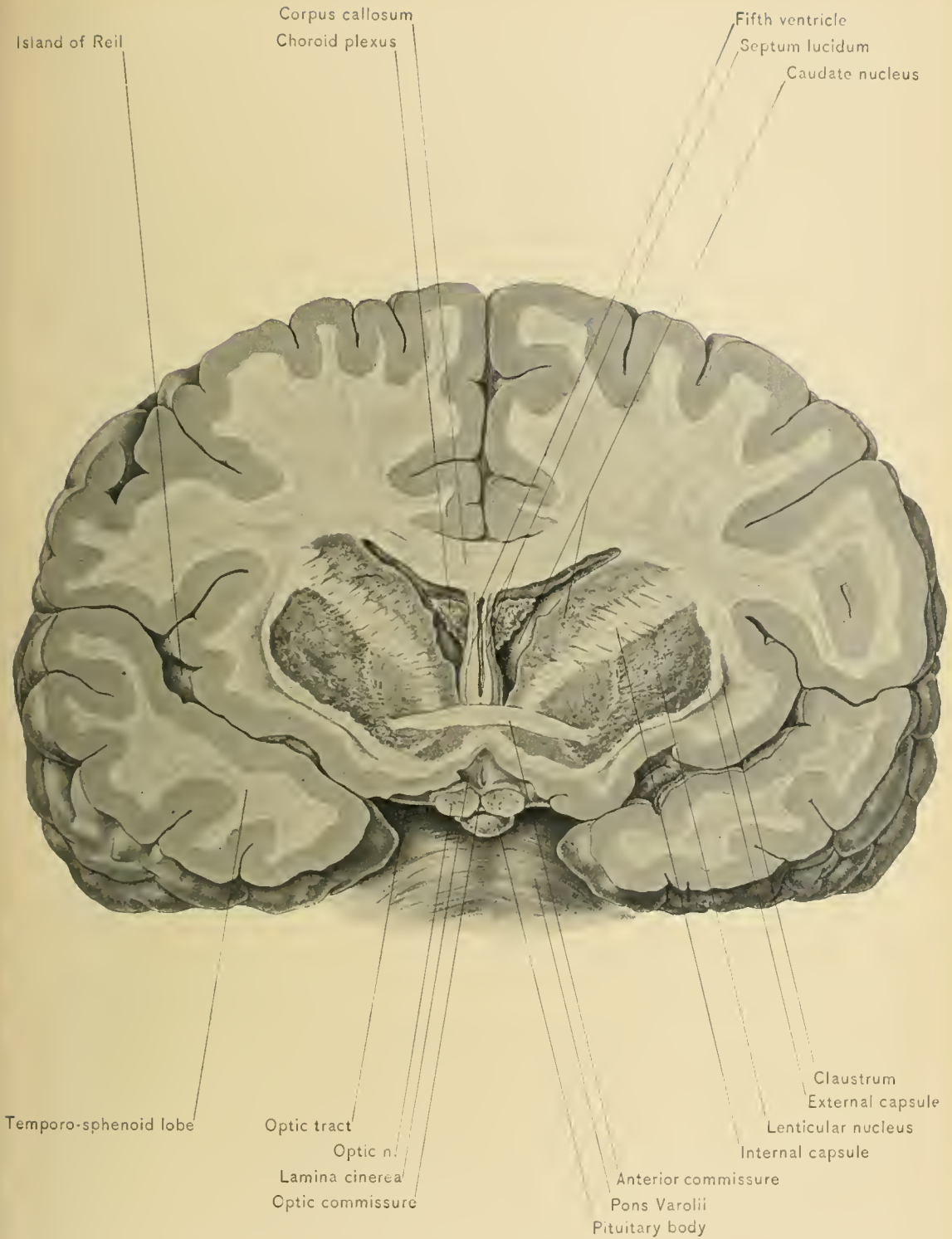
Anterior cornu of right lateral ventricle



Clastrum

Genu of corpus callosum

CORONAL SECTION OF CEREBRUM.



CORONAL SECTION OF CEREBRUM JUST ANTERIOR TO OPTIC CHIASM.

The *superior peduncles* of the cerebellum connect the cerebellum with the cerebrum, and pass forward, forming the lateral boundaries of the anterior portion of the fourth ventricle. Under the floor of the aqueduct of Sylvius the two superior peduncles decussate; each peduncle then enters the opposite subthalamie region of the cerebrum, to reach the optic thalamus and lenticular nucleus. The *middle peduncles* connect the cerebellum with the pons. The *inferior peduncles* are formed by the restiform bodies, and connect the cerebellum with the medulla oblongata and spinal cord.

DISSECTION.—Carry a vertical incision through the center of the hemisphere of the cerebellum, to expose the white matter and gray nucleus.

INTERIOR ARRANGEMENT.—In the interior of the white matter of the cerebellum is a gray nucleus, the corpus dentatum. The white matter sends processes into the laminae of the gray matter, which forms the surface of the cerebellum, and give rise to the appearance that has been termed the *arbor vitae*. The **corpus dentatum of the cerebellum**, like the nucleus of the same name in the olivary body, is arranged in the form of a capsule presenting a zigzag outline which is open at the inner side. Through this open part, or hilum, of the capsule a bundle of white fibers passes to the superior peduncles of the cerebellum and the valve of Vieussens.

SECTIONS OF THE BRAIN.

Having mastered the topography of the encephalon, together with its intraventricular aspect, in the study of which some of its parts were seen in horizontal sections, it will now be well to study coronal and sagittal sections, and so obtain a more accurate knowledge of the relations of the various parts of the encephalon.

A **sagittal section** lies in a vertical longitudinal plane, running antero-posteriorly, as if through the entire length of the brain through or parallel with the sagittal suture, hence it is so named; a section of this kind is not, however, limited to the median line.

A **coronal section** lies in a vertical transverse plane, running from side to side, at right angles to a sagittal plane; this is also called a frontal section.

A coronal section through the brain at the tips of the temporo-sphenoid lobes will traverse the anterior end of the lenticular nucleus of the corpus striatum, and one a short distance beyond this will pass through the anterior end of the caudate nucleus. A section passing through the optic commissure, or just behind it, will include the front of the optic thalami. A frontal section must, therefore, be made back of the optic commissure if it is to include both sets of basal ganglia.

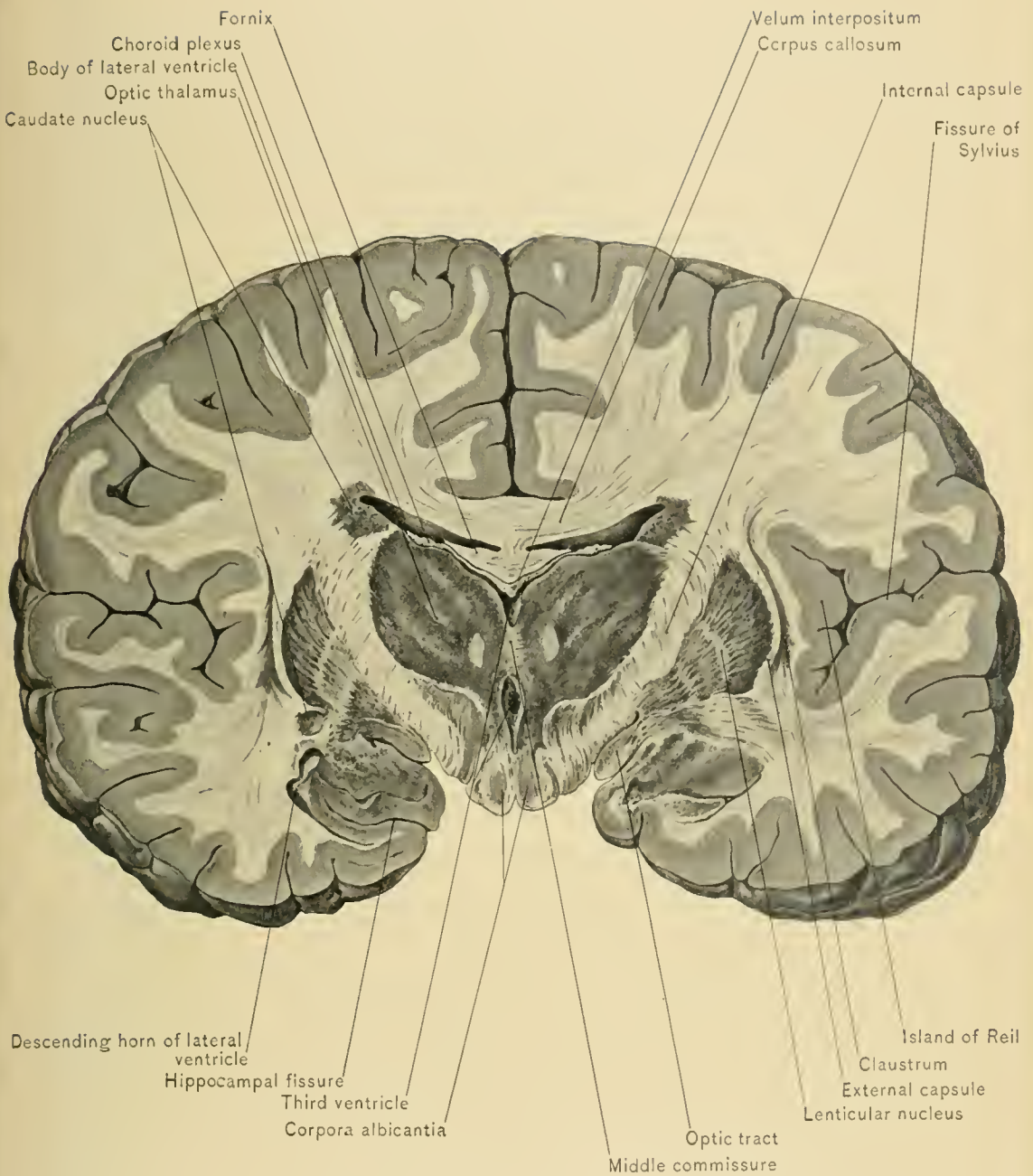
A coronal section about midway between the optic commissure and the tips of

the temporo-sphenoid lobes will not include the optic thalami. It will expose, from within outward, the septum lucidum, the lateral ventricle with the corpus callosum above it, the caudate nucleus, the internal capsule, the lenticular nucleus, the external capsule, the claustrum, the white matter, the island of Reil, and the fissure of Sylvius. The wedge shape of the lateral ventricle is plainly shown in this section, as is also the formation of its outer wall and part of its floor by the sloping caudate nucleus. The lenticular nucleus is clearly separated into three portions, defined by fine white curved lines extending between them.

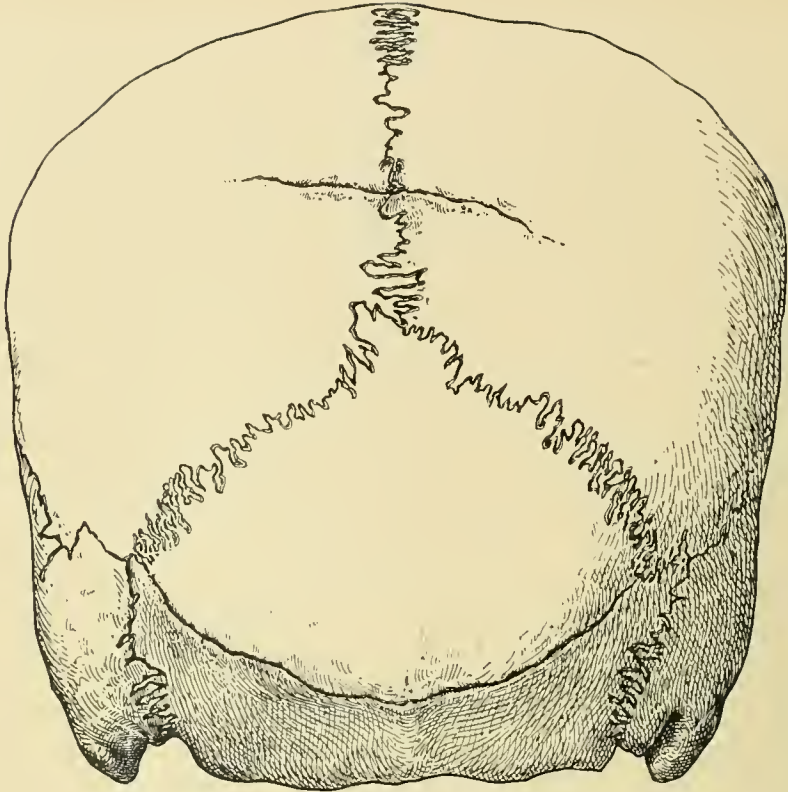
When these sections are made further back, the anteriorly situated parts become smaller, and finally disappear, while the more posteriorly situated parts gradually increase in size; the caudate nucleus grows smaller and recedes toward the upper and outer angle of the lateral ventricle, while the optic thalamus occupies an increasing amount of the lower part of the outer wall of the lateral ventricle. Notable changes in the median line also occur, the fifth ventricle and the septum lucidum vanish, and the fornix and third ventricle appear instead, while the infundibulum, mammillary bodies, and posterior perforated spaces successively appear at the base. The crura cerebri at first appear to be separated, gradually coming closer, until they merge. The locus niger is distinctly visible, as are also the two adjacent divisions of the crura cerebri. The upper or front end of the pons comes into view, and at its upper edge the aqueduct of Sylvius appears. The velum interpositum, containing the choroid plexuses, becomes wider as the sections pass backward. The tæniæ semicirculares, the dentate fasciæ, the hippocampal gyri, and the middle cornua of the lateral ventricles are also seen in these sections.

No study of the cerebrum is complete without a careful consideration of these sections, as they portray exactly the relations of the cortex and intra-encephalic parts to one another.

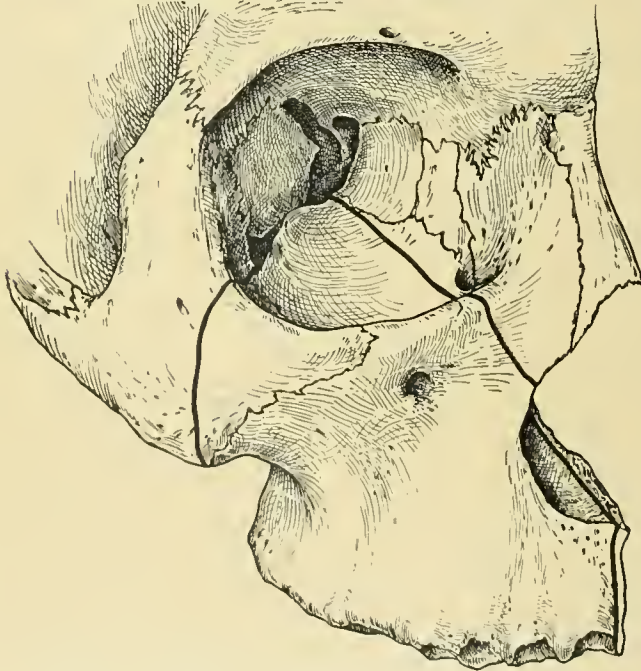
Sagittal sections do not offer so wide a field for the study of these relations, because of the rapid loss of important structures as the median line is departed from, though the length of the basal ganglia, and particularly of the caudate nucleus, is better shown in these sections than in other ways.



CORONAL SECTION OF CEREBRUM THROUGH CORPORA ALBICANTIA AND MIDDLE COMMISSURE.



PARIETAL AND TRANSVERSE OCCIPITAL FISSURES.



LINES IN WHICH BONE IS DIVIDED IN EXCISION OF UPPER JAW.

JOINTS OF THE HEAD AND NECK.

The **Joints of the Skull**, excepting the temporo-maxillary articulation and the articulations between the skull and the spinal column, are in the form of sutures which afford immobility and firmness with elasticity.

The **Sutures of the Skull** may be mistaken for fractures, and the Wormian bones, which are situated in the lines of the sutures, may be mistaken for fragments outlined by fractures.

The **sagittal suture** is situated in the median line of the vault of the cranium, and extends from the bregma to the lambda. The bregma is situated at the junction of the coronal and sagittal sutures, and at the point where a line, drawn perpendicular to Reid's base line at the preauricular fossa, crosses the median line of the cranial vault. The lambda is situated at the junction of the sagittal and lambdoid sutures, and about two and three-fourth inches, or seven centimeters, above the external occipital protuberance.

The **coronal suture** extends from the bregma downward, and slightly forward, toward the junction of the zygoma with the malar bone.

The **lambdoid suture** is situated at about the upper two-thirds of a line drawn from the lambda to the apex of the mastoid process of the temporal bone. Additional sutures not commonly present may exist in the vault of the cranium and be mistaken for fractures. These are the **frontal suture**, which extends forward between the halves of the frontal bone in the line of the sagittal suture, the **parietal fissure**, a short suture which crosses the sagittal suture one inch, or two and one-half centimeters, anterior to the lambda, and the **transverse occipital fissure**, which is a suture situated in the occipital bone near the level of the external occipital protuberance.

The **Temporo-maxillary Articulation** is the joint situated between the condyle of the inferior maxilla below, and the anterior part of the glenoid fossa and the eminentia articularis above. It is a ginglymo-arthro-dial articulation, or hinge joint, modified to allow gliding movement. The ligaments of the temporo-maxillary articulation are the capsular ligament and the interarticular fibro-cartilage. The joint is strengthened by the spheno-mandibular and stylo-mandibular ligaments.

The **capsular ligament** is thin, especially at its anterior and inner portions. It is attached above to the margins of the articular surface formed by the eminentia articularis and anterior portion of the glenoid cavity of the temporal bone, and below to the neck of the lower jaw. Its external portion is much stronger than the remainder of the capsule, and is termed the external lateral ligament.

The *external lateral ligament* is attached above to the lower margin of the zygoma and the tubercle of the zygoma, its fibers passing downward and backward to be attached below to the outer surface and posterior margin of the neck of the lower jaw.

The **interarticular fibro-cartilage** is situated between the articular surfaces of the bones entering into the formation of the joint. Through conformation to these surfaces its upper surface is concavo-convex from before backward and convex laterally, and the posterior portion of its under surface is concave, to fit the condyle. It is thinner at its center, and thickest posteriorly, where it acts as a buffer and protects the thin bone of the glenoid fossa. Its margins are attached to the capsular ligament, and some of the fibers of the tendon of the external pterygoid muscle pass between the fibers of the anterior portion of the capsular ligament, to be inserted into the anterior margin of the interarticular fibro-cartilage.

The **synovial membranes** are two in number, the superior synovial membrane being separated from the inferior by the interarticular fibro-cartilage. When the interarticular fibro-cartilage is perforated, the two synovial sacs communicate.

The **spheno-mandibular** or **internal lateral ligament** is attached above to the spine of the greater wing of the sphenoid bone and adjacent part of the temporal bone, and below to the spine of Spix, or mandibular spine, which is situated on the inner surface of the lower jaw, below and internal to the inferior dental foramen. The internal lateral ligament is separated from the temporo-maxillary joint and lower jaw by the internal maxillary artery and vein, the middle meningeal artery, the external pterygoid muscle, the inferior dental vessels and the inferior dental nerve. Its lower extremity is pierced by the mylo-hyoid nerve.

The **stylo-mandibular** or **stylo-maxillary ligament** is a part of that process of the deep cervical fascia which dips beneath the parotid gland. It extends from the styloid process of the temporal bone to the angle and posterior margin of the ramus of the lower jaw, separating the parotid from the submaxillary gland.

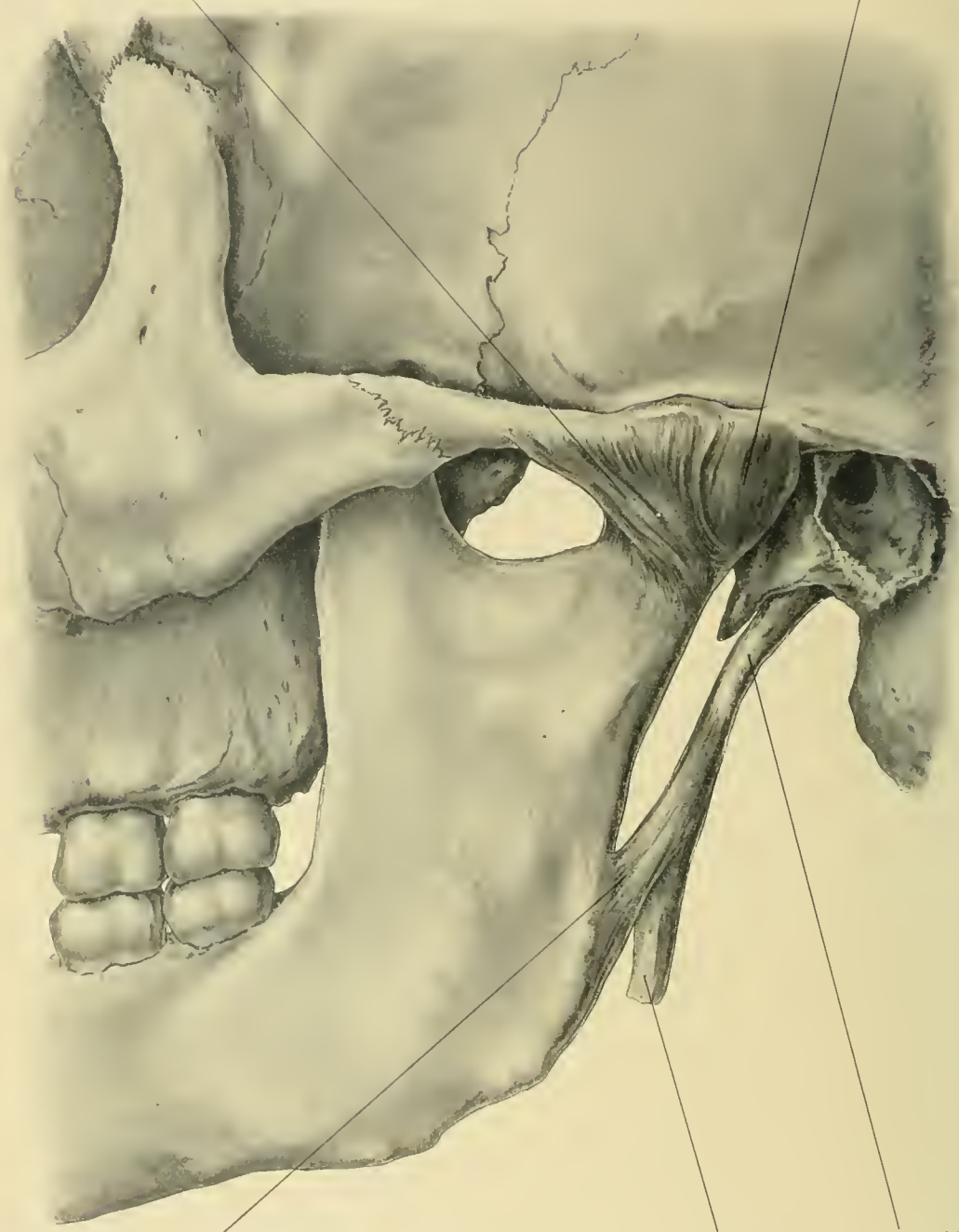
BLOOD SUPPLY.—From the temporal, middle meningeal, and ascending pharyngeal arteries.

NERVE SUPPLY.—From the auriculo-temporal and masseteric branches of the inferior maxillary nerve.

MOVEMENTS.—Rotation of the condyle around a transverse axis occurs when the mouth is opened or closed, and gliding forward of both the condyle and the interarticular cartilage when the mouth is widely opened. If the mouth is opened too widely, as in a convulsive yawn, the condyle and interarticular fibro-cartilage may be completely or incompletely dislocated forward, and locked either in front of or upon the eminentia articularis. In closing the mouth the cartilage and condyle

External lateral lig.

Capsular lig.

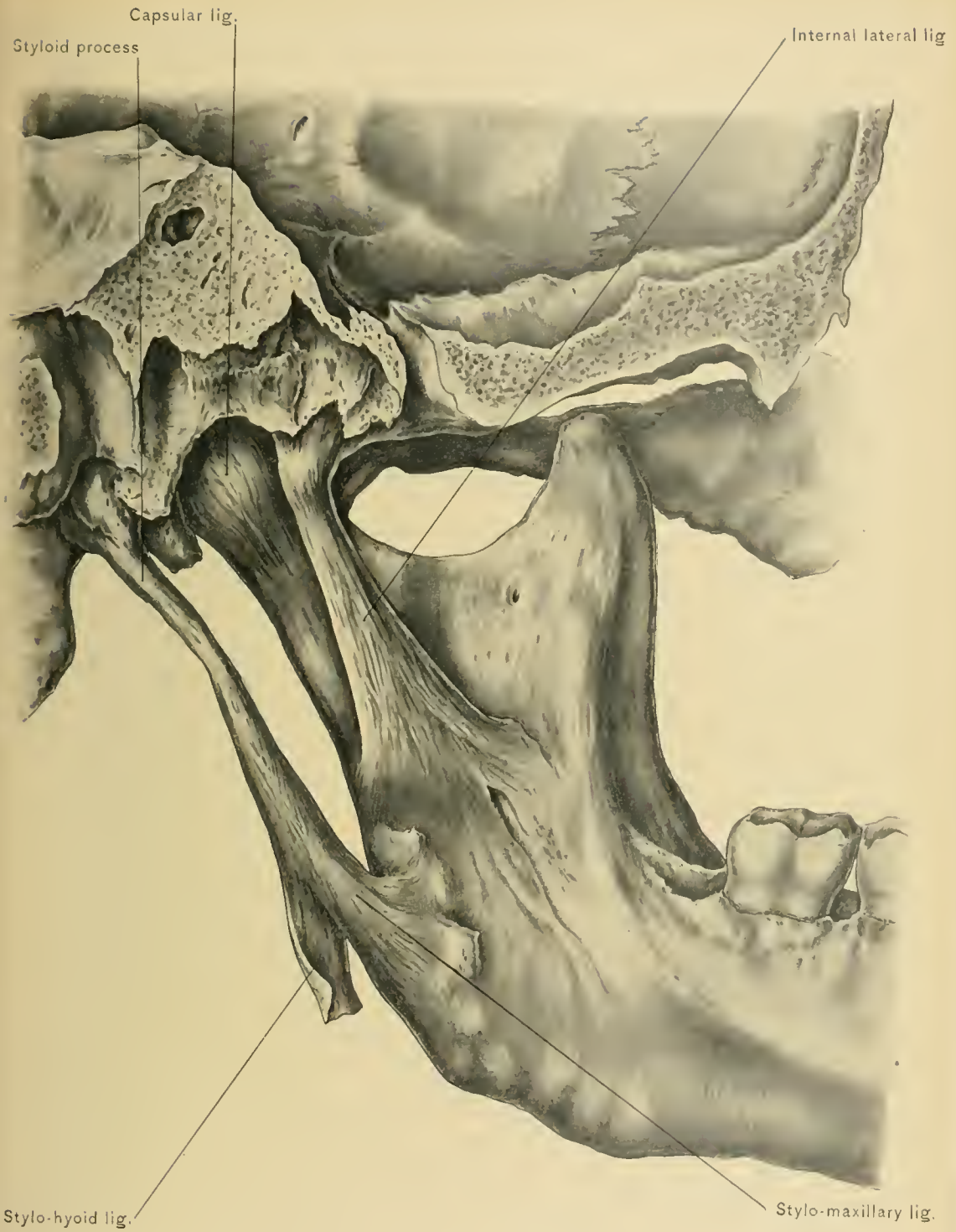


Stylo-maxillary lig.

Stylo-hyoid lig.

Styloid process

TEMPORO-MAXILLARY ARTICULATION--EXTERNAL VIEW.



TEMPORO-MAXILLARY ARTICULATION—INTERNAL VIEW.

glide backward, and the condyle rotates on the cartilage in the reverse direction. These movements result in a combination of a hinge movement of the condyle with fore-and-aft gliding movement of the interarticular fibro-cartilage. Gliding movement of the interarticular fibro-cartilage forward occurs when the lower jaw and chin are thrust forward. Rotation of the condyle around the vertical axis of the neck of the lower jaw, associated with oblique gliding of the interarticular fibro-cartilage on the glenoid fossa, occurs in the oblique movements of the lower jaw in mastication.

The **Joints of the Neck** are those of the cervical portion of the spinal column, which have been described in volume 1.

Dislocations.—**Dislocation of the bones of the vault and base of the skull** is almost entirely limited to the young skull. Such an accident rarely occurs in the adult skull, the firm union and overlapping of the bones preventing dislocation of these articulations. The squamous suture has been separated by dislocation of the temporal bone. Fractures in the line of the coronal, sagittal, and lambdoid sutures have occurred.

Dislocation of the lower jaw is of comparatively rare occurrence, and is usually forward and bilateral. *Forward dislocation* occurs while the mouth is wide open, as during convulsive yawning, manipulations of dentists, or from blows on the chin. Only a small amount of force is required at such a time to carry the condyle from a position just behind, to a point upon or immediately in front of, the summit of the eminentia articularis. The anterior portion of the capsular ligament is torn; the interarticular fibro-cartilage is usually dislocated with the condyle. The condyle is retained in its abnormal position by the upward traction of the temporal, masseter, and internal pterygoid muscles. *Backward dislocation* of the lower jaw may follow a blow on the chin, and the condyle may fracture the bony portion of the external auditory meatus or be driven into the cranial cavity.

Excisions.—**Excision of the upper jaw** is usually performed for malignant disease, as sarcoma or carcinoma of the maxillary sinus or antrum of Highmore. Generally but one superior maxilla is removed, although both upper jaws have been removed in one operation.

In excising the superior maxilla several anatomic facts are to be remembered. The upper jaw is in reality a shell of bone which envelops the maxillary sinus, forms a large part of the floor of the orbit, roof of the mouth, external wall of the nasal fossa, anterior wall of the sphenomaxillary fossa and pterygo-maxillary region, and bony basis of the front of the face below the infra-orbital ridge. Its strongest portions are the malar, alveolar, and palatal processes.

In the operation of excision of the superior maxillary bone the inferior tur-

binated bone, part of the malar bone, part of the palate bone, and the superior maxillary bone, except the upper part of its nasal process, are removed.

In the method of excision which is most commonly practised,—that is, by a median incision,—the first incision is begun one-half of an inch, or slightly less than one and one-half centimeters, below the inner canthus of the eyelids. It is carried downward along the groove between the nose and face, around the ala of the nose, below the base of the nose to the median line, and thence through the median line of the upper lip. This incision divides skin, superficial fascia, some of the muscles of expression, the angular artery and vein, the lateral nasal artery, the artery of the nasal septum, the superior coronary artery, and branches of the infra-orbital and facial nerves.

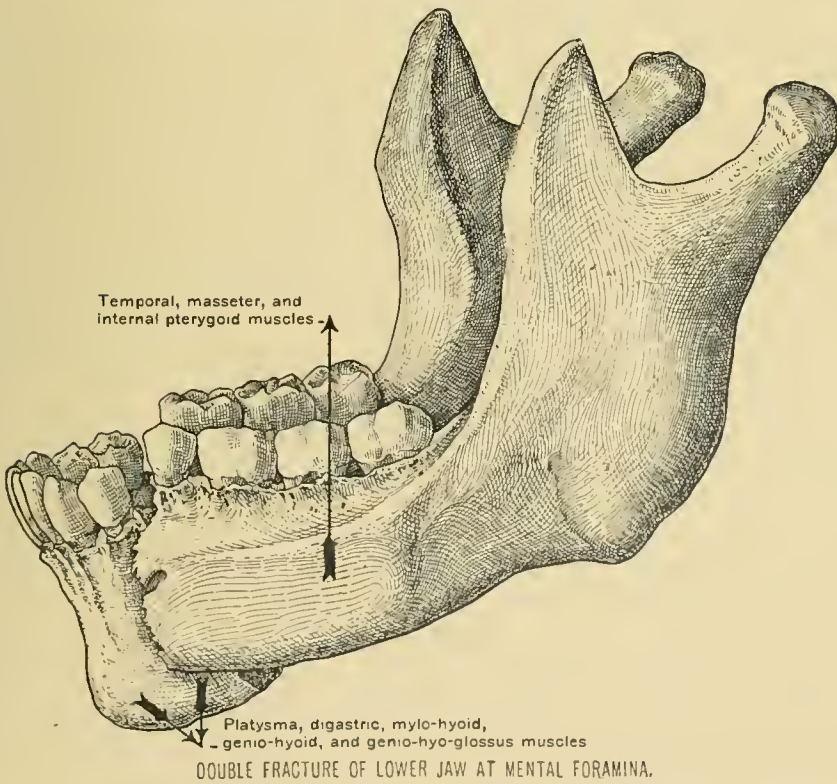
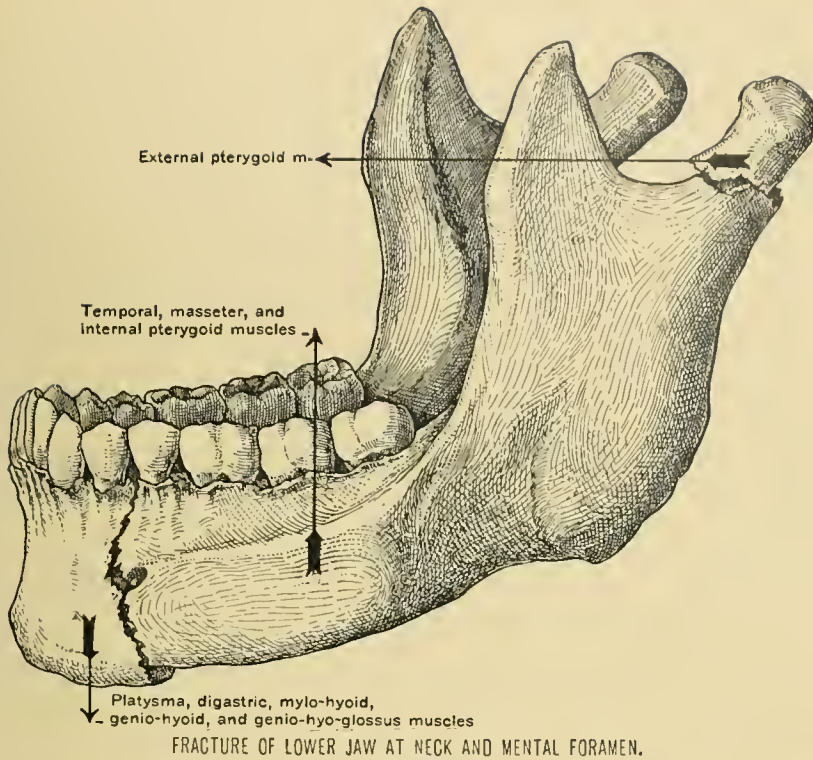
The second incision is carried from the point at which the first incision was commenced outward along the infra-orbital margin to a point over the malar bone. This incision divides a few insignificant blood-vessels. The tissues of the flap outlined are now quickly reflected outward, removing all of them down to the bone, not considering the periosteum. In elevation of this flap the infra-orbital vessels and nerve are divided.

The fibro-cartilaginous lateral portion of the nose is detached from the superior maxilla, and the base of the nasal process of the superior maxilla is severed with a fine saw or a chisel. The periosteum is divided along the infra-orbital ridge, and elevated from the floor of the orbit, at the same time detaching the origin of the inferior oblique muscle of the eyeball. The inner part of the floor of the orbit is then divided with a small chisel. The malar bone is next severed at its middle with a small saw or chisel, and in a line which extends obliquely downward and outward. The saw is carried through the floor of the orbit until it reaches the sphenomaxillary fissure. The malar bone can be divided with strong bone forceps, which are not allowed to extend into the sphenomaxillary fissure. If the forceps are inserted too deeply into the fissure, the internal maxillary artery may be severed.

The central incisor on the diseased side is extracted, the muco-periosteum of the floor of the nose is divided close to the nasal septum, the muco-periosteum of the hard palate is severed in the median line, and the soft palate is thoroughly separated from the hard palate. With a slender saw introduced through the nose the hard palate is divided close to the nasal septum.

With one blade of the forceps at the infra-orbital ridge and the other at the alveolar process, the jaw is grasped with lion forceps, and loosened from the remaining attachments. This procedure fractures the vertical plate of the palate bone, and detaches the jaw from the pterygoid process of the sphenoid bone.

The vessels ruptured or divided in removing the superior maxilla are



branches of the third portion of the internal maxillary artery. They are the alveolar, infra-orbital, posterior palatine, pterygo-palatine, and naso-palatine arteries, or some of their branches. The application of the actual cautery may be required to check hemorrhage. The cavity may be packed with gauze, and the wound in the skin is closed. The gauze is subsequently removed through the mouth.

Excision of the lower jaw is performed for the removal of malignant growths of that bone. Usually but half of the bone is excised. Segments of the lower jaw are removed in extirpation of benign tumors of that bone. The incision is carried from the attached margin of the lower lip down the middle of the chin to the lower margin of the jaw, thence just below and parallel with the body of the jaw to the angle, and thence upward along the posterior margin of the ramus of the lower jaw to the level of the lobule of the ear. In making this incision the facial artery is secured between ligatures before it is divided. The skin, superficial fascia, platysma myoides muscle, and deep fascia are divided; the parotid, submaxillary, and sublingual glands and Stenson's duct must be avoided.

Beginning at the symphysis, the soft tissues are detached from the external surface of the bone with a periosteal elevator. The depressor labii inferioris, depressor anguli oris, buccinator, and masseter muscles are thus separated from the bone.

After extraction of one of the incisor teeth the bone is divided with a small saw. The divided end of the bone is next drawn outward, and the mylo-hyoid muscle and mucous membrane of the mouth are divided close to the bone, being careful to avoid injuring the sublingual or submaxillary gland or the lingual nerve.

The internal pterygoid muscle is detached from the bone with a periosteal elevator, and the internal lateral ligament of the lower jaw and inferior dental vessels and nerve are divided.

The jaw is now depressed, to bring the coronoid process into view. This process is then divided with a chisel and a mallet, and dissected out afterward, or the tendon of the temporal muscle is severed with curved scissors. The tendon of the external pterygoid muscle is divided with scissors, or detached with a periosteal elevator.

The capsular ligament is divided, and, after severing some few remaining attachments, as the stylo-maxillary ligament, the bone can be removed. After bleeding has been checked the wound is closed.

The structures to be avoided in this operation are the three salivary glands, Stenson's duct, the buccal and supra-maxillary branches of the facial nerve, the lingual and auriculo-temporal nerves, the external carotid, temporal, and internal maxillary arteries, and the temporo-maxillary and internal maxillary veins. The

vessels which must be divided are the facial, inferior labial, mental, mylo-hyoid, inferior dental, and masseteric arteries and veins.

Excision of the condyle of the lower jaw is performed most commonly for disease of the temporo-maxillary articulation causing impaired movement in that jaw.

A vertical incision is carried from the zygoma downward over the condyle of the lower jaw, to a point just above the position of the transverse facial artery, which is one centimeter, or less than one-half of an inch, below and parallel with the zygoma. A second incision is carried forward along the lower margin of the zygoma for one inch, or 2.5 centimeters. The flap thus outlined is reflected forward and downward, avoiding the temporal branches of the facial nerve. The posterior fibers of the masseter muscle are detached from the zygoma, and the capsule of the temporo-maxillary joint is opened.

The neck of the condyle is divided with a chisel or a small saw, the condyle being firmly held with a small hook. The condyle is twisted out of the glenoid fossa, and the external pterygoid tendon and capsular ligament are divided. The instruments are kept close to the bone, to avoid injuring the temporal, internal maxillary, and masseteric vessels, the auriculo-temporal and masseteric nerves, and the parotid gland.

Development of the Bones of the Skull.—The bones of the vault of the cranium are developed in membrane, and those of the base of the skull are formed in cartilage. Just before birth the bones of the vault are imperfectly ossified at their margins, so that they are joined by membrane instead of by sutures. This condition of the bones allows diminution in the diameters of the fetal skull at birth by overlapping of the bones of the cranial vault.

At birth the bones are incompletely ossified at the angles of the parietal bone; these membranous areas are called fontanels.

The **posterior fontanel** is triangular in shape, is situated at the lambda, and closes during the first few months after birth.

The **anterior fontanel** is quadrilateral, is located at the bregma, and closes during the latter half of the second year.

The **antero-lateral fontanels**, situated at the anterior inferior angles of the parietal bones, and the **postero-lateral fontanels**, situated at the posterior inferior angles of the parietal bones, close soon after birth. Imperfect or delayed ossification at the fontanels occurs in hydrocephalus.

Fractures of the Skull.—The bones of the skull in young children are not readily fractured. When force is applied to the vault of the skull of a young infant, it is merely indented, ossification being so incomplete that the bones are flexible.

The adult skull is not readily fractured, because its curves diffuse and diminish the breaking force, and, being composed of three tables of different consistence, its strength and elasticity are much enhanced. Other conditions which lessen the danger of fracture of the vault of the cranium are: The mobility of the scalp proper, the rounded shape of the cranial vault, and the mobility of the head. As age advances and the bones become less porous, less elastic, and, at the fortieth year, the sutures begin to be obliterated by ossification of the intersutural membrane the skull is more readily fractured. Either the external table or the internal table may be fractured without injury to the other table, but both tables are usually traversed by the fracture. On account of its brittleness and the diffusion of the force in passing through the bone, the inner table is much more splintered than the external. In depressed fractures of the vault the inner table may not be broken, the outer table being merely driven into the diploë or one of the frontal sinus.

Fractures of the vault of the skull are due to direct violence. A fracture of the vault resulting from diffuse application of force, as in a fall upon the head, usually extends to the base of the skull by the shortest route, regardless of sutures or thickness of the bones traversed. This is more likely to occur if the fracture be linear. Fractures of the frontal region extend into the floor of the anterior cranial fossa, those of the parietal region into the floor of the middle cranial fossa, and those of the occipital region into the floor of the posterior cranial fossa.

Fractures of the base of the skull are caused by extension of a fracture from the vault of the skull and by direct or indirect violence. Fractures of the base by direct violence have been caused by foreign bodies having been driven through the roof of the orbit, nose, or pharynx. Fractures of the base by indirect violence usually result from the body falling upon the feet, knees, or buttocks, and from the upper part of the spinal column being driven against or through the occipital bone. In blows at the root of the nose the cribriform plate of the ethmoid bone may be fractured, and in a fall upon the chin the condyle of the lower jaw may be driven through the base of the skull at the middle cranial fossa. The cribriform plate of the ethmoid bone has been broken by counter-stroke by a blow in the occipital region.

In fracture of the base of the skull at the *anterior cranial fossa* blood may enter the orbit and produce a subconjunctival ecchymosis, or blood and cerebrospinal fluid may escape from the nose through the anterior nares or posterior nares and mouth. The blood escaping into the orbit is derived from ruptured meningeal vessels, anterior or posterior ethmoid vessels, and ophthalmic artery or vein; that entering the nose escapes from the anterior or posterior ethmoid vessels, and the vessels of the nasal mucous membrane. In fracture of the cribriform plate of

the ethmoid bone rupture of the olfactory nerves may cause loss of the sense of smell. In fractures at the *middle cranial fossa* blood and cerebro-spinal fluid may escape from the ear. To permit cerebro-spinal fluid to escape in this manner, the arachnoid, dura mater, bone and mucous membrane of the wall of the tympanum, and membrana tympani must be ruptured. In fracture of the base at this fossa the cavernous sinus may be ruptured, and if the fracture extend across the petrous portion of the temporal bone, the superior petrosal sinus, and the facial and auditory nerves may be injured. Laceration of the facial nerve causes paralysis of the muscles of expression and of the buccinator muscle; laceration of the auditory nerve causes deafness. In fractures of the base of the skull at the *posterior cranial fossa* blood may be extravasated into the tissues of the nape or posterior triangle of the neck. The symptoms of fracture of the skull are chiefly those of compression of the brain, produced by extravasated blood which arises from rupture of the meningeal vessels, sinuses of the dura mater, and diploic veins.

Fractures of the Bones of the Face are the result of direct violence. In **fracture of the nasal bones** emphysema of the soft tissues may occur. In **fracture of the lacrymal bone** obstruction of the nasal duct may cause the tears to flow over the cheek, and laceration of the muco-periosteal wall of the duct may induce emphysema of the soft tissues. In **comminuted fracture of the zygomatic arch** fragments of bone driven into the temporal muscle may interfere with the movements of the lower jaw in mastication.

Fracture of the bone of the upper jaw may cause profuse hemorrhage from a ruptured infra-orbital, superior dental, anterior palatine, or posterior palatine artery.

Fracture of the lower jaw occurs more frequently than fracture of any other bone of the face. It is usually broken by direct violence. In fractures of the *neck* of the lower jaw the condyle is drawn forward by the external pterygoid muscle. Imperfect apposition and persistent mobility of the fragments may induce excessive formation of callus, which may subsequently cause more or less ankylosis of the temporo-maxillary articulation. In fracture of the *ramus* of the bone there is slight displacement of the fragments, as the masseter and internal pterygoid muscles act as splints. In fracture in front of the attachment of the masseter muscle the posterior fragment is drawn upward by the masseter, temporal, and internal pterygoid muscles; if the plane of fracture extends obliquely backward and outward, the posterior fragment is also drawn inward by the internal pterygoid muscle. The anterior fragment is carried downward by the fracturing force, the platysma myoides, digastric, mylo-hyoid, genio-hyoid, and genio-hyo-glossus muscles. In *double fracture at the mental foramina* the middle fragment is carried downward

and backward by its weight, and the digastric, mylo-hyoid, genio-hyoid, and genio-hyo-glossus muscles. This displacement allows the base of the tongue to fall against the epiglottis, and thus asphyxiation may be produced.

SURFACE ANATOMY OF THE CRANIUM.

The **Cranium** is that portion of the head which extends from the lower margin of the forehead in front to the upper extremity of the neck behind, from ear to ear laterally, and along the base of the brain-case below. The base of the brain-case is represented by a line which extends from the eyebrows, through the external auditory meatus, to the nape of the neck. The covering of this area, with the exception of that of the forehead and part of the temporal regions, constitutes the scalp.

The **Scalp** is covered by hair, which is more or less abundant. At the junction of the middle and posterior thirds of the sagittal suture can be seen a dividing point of the hair, from which it falls radially in all directions. It is at this point that baldness usually begins. The density of the scalp is well marked. The integument is closely connected with the cranial or occipito-frontalis aponeurosis, on account of which attachment many persons can readily move the scalp by the alternate contractions of the occipital and frontal divisions of the muscle. The scalp is lacking in elasticity, especially in the back part. In peeling the scalp back, during postmortem examinations, it sometimes tears, and in the subsequent sewing stitches pull through if drawn very tightly. In this respect the scalp differs remarkably from the skin of other regions of the body. The skin elsewhere has more elasticity and allows much stretching before it tears. Tumors

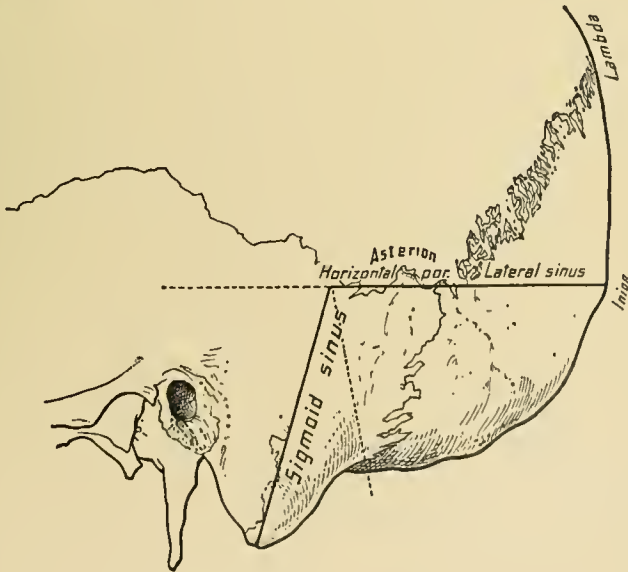
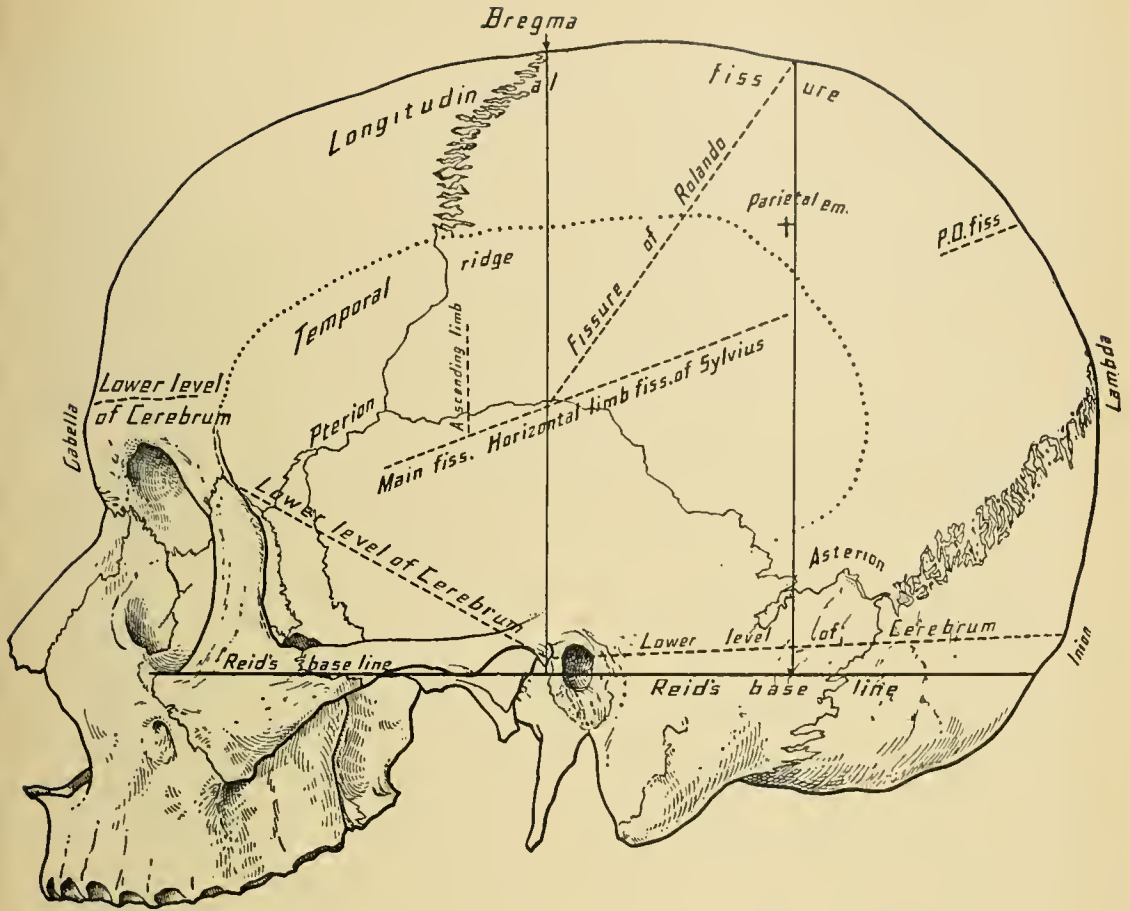
of the scalp are movable if above the cranial aponeurosis; when below it they are immovable.

The **arteries** of the scalp are the frontal, which ascends near the median line; the supra-orbital, which is found above the supra-orbital notch and for some distance up the forehead; the anterior branch of the temporal artery (often very tortuous), found about one and one-quarter inches behind the external angular process of the frontal bone; the posterior branch of the temporal, which runs above and in front of the ear; the posterior auricular, above and behind the ear; and the occipital, distinguishable about midway between the mastoid process and the external occipital protuberance.

In examining the head as a whole, it will be noticed that the two sides are not symmetric—one side almost always having larger dimensions than the other. Although the general conformation of the skull cap is a fair index of its contents, it does not follow that every minute change in form of the brain has its effect upon the skull, as is claimed by many phrenologists.

The **cranial bones** are the frontal, two parietal, two temporal, the occipital, the sphenoid, and the ethmoid. In the adult they are immovably connected with one another, the lines of their junctions being termed sutures. In infancy the frontal bone consists of two portions; these coalesce very early in life, the line of union being the **frontal suture**. The two parietal bones are joined by the **sagittal suture**. The course of the two sutures, the frontal and sagittal, corresponds to a line drawn from the root of the nose, directly backward over the median line of the vault of the skull, to the external occipital protuberance. In this line, within the skull, are the superior longitudinal sinus and the longitudinal fissure of the cerebrum. The parietal bones are joined to the frontal bone by the **coronal suture**, and to the occipital bone by the **lambdoid suture**. About one inch anterior to the center of a vertical line drawn directly over the skull from one external auditory meatus to the other, and at the junction of the coronal with the sagittal suture, is the **bregma**, which is the situation of the anterior fontanel of the infant. The **coronal suture** corresponds to a line drawn from the bregma to the middle of the zygomatic arch. The **lambdoid suture** is represented by a line drawn from the posterior border of the base of the mastoid process to a point midway between the bregma and the external occipital protuberance. The **lambda** is the point of junction of the sagittal and lambdoid sutures. This is the site of the posterior fontanel in infants. The **pterion**—the junction of the anterior inferior angle of the parietal, the frontal, the temporal, and the greater wing of the sphenoid bone—is found about one and one-half inches behind the external angular process of the frontal bone, and about the same distance above the zygoma.

The **superciliary ridges** commence on each side of the **glabella**, which is



CRANIAL LANDMARKS AND LINES OF CEREBRAL FISSURES.

the elevation above the root of the nose, and extend outward in a gentle curve, gradually becoming less prominent. The superciliary ridges mark the location of the sinuses of the frontal bone, but may vary greatly, generally because of the difference in size of the frontal sinuses. They are small in females and absent in children. Although the size of the ridge may be an indication of the size of the frontal sinus, yet this does not always hold good, as we may find a large ridge with but little development of the sinus; and vice versâ. Some of the Australian aborigines have very small sinuses, but large ridges, due to great thickness of the bone.

Above the superciliary ridges are found the **frontal eminences**. They are slightly convex elevations which mark the original centers of ossification in the two frontal bones. Their prominence is generally considered as an index of the amount of intellectual capacity of the individual. The increase in the development of the skull as a whole causes the frontal bones to become upright, and thus makes the frontal eminences more prominent.

Immediately behind the external ear is the **mastoid process** of the temporal bone. It is but rudimentary in infancy, and develops later in life. It extends downward for about an inch below the external auditory meatus, and projects forward slightly under it. The **digastric fossa** is internal to the mastoid process. The body of the process is honeycombed with air-cells, which are connected with the middle ear. At times these become so inflamed that trephining or incision is necessary to afford relief. The incision should be made in the hairless space behind the ear (Wilde's incision). A line connecting the tips of the two mastoid processes would pass through, or immediately under, the condyles of the occipital bone.

About half an inch above and three-quarters of an inch behind the posterior border of the mastoid process is the **asterion**—the junction of the lambdoid and squamous sutures.

The **external occipital protuberance (inion)** is distinctly felt in the median line at the posterior part of the head, at the junction of the skin of the neck with that of the head. It is the thickest part of the vault of the skull. From it the superior curved lines of the occipital bone extend laterally and give attachment to some of the muscles which support the head. The external occipital protuberance marks the position of the torcular Herophili, or the confluence of the superior longitudinal, two lateral, straight, and occipital sinuses. Above the superior curved lines the general contour of the skull can be readily seen, as the covering is composed of thin structures. Below these lines, however, the skull recedes to a considerable extent, the space being filled in with the strong muscles and fasciæ of the neck. In the region of the occiput there is occasionally found a bulging of the membranes of the brain (meningocele), or of the brain itself (encephalocele); in these cases there is defective ossification of the

occipital bone, and the tumor caused by the protruding cranial contents is always in the median line.

The **parietal eminences** which mark the position of the centers of ossification in the parietal bones are readily distinguishable on the sides of the skull above the ears. They are much more marked in infancy, gradually becoming rounded and less prominent. Anterior to the parietal eminences, and running along the sides of the head, are the two **temporal ridges** which limit the temporal fossæ above and give attachment to the temporal fascia. They commence at the external angular process of the frontal bone and arch upward, backward, and then downward, to become lost on the posterior roots of the zygomatic process. The point where the coronal suture is crossed by the temporal ridge is known as the **stephanion**. It is about one and one-quarter inches above the pterion.

The **middle meningeal artery** passes upward on the anterior inferior angle of the parietal bone, and is found by trephining an inch and a half behind and about an inch above the external angular process.

The **course of the superior longitudinal sinus** is indicated by a line drawn over the median line of the top of the head, or from the root of the nose to the external occipital protuberance.

The **course of the horizontal portion of the lateral sinus** is shown by the posterior part of a line drawn from the external occipital protuberance to a point one inch above the external auditory meatus. The sinus turns downward and becomes the sigmoid sinus at the point where a vertical line drawn through the posterior border of the base of the mastoid process crosses the line for the horizontal portion.

The **course of the sigmoid sinus** is marked by a line drawn from the point of termination of the horizontal portion of the lateral sinus to the tip of the mastoid process.

SURFACE ANATOMY OF THE FACE.

The appearance of the face in health and disease deserves attention from the physician. In infancy, owing to greater abundance of subcutaneous fat and the lack of development of the muscles of expression, the face is full and round; the relatively greater development of the brain and sense organs causes the upper portion of the face to be broader than the lower; the nasal fossæ are shallow, and the maxillary bones are small.

In old age the subcutaneous fat largely disappears and the integument becomes wrinkled and thinner. Not infrequently there are observed areas of

thickened, brownish epidermis (*keratosis senilis*), particularly in persons much exposed to the weather. After middle life there is a tendency to dilatation of the superficial vessels, especially on the nose and cheeks.

The absorption of the alveolar processes and loss of the teeth cause the characteristic appearance of the mouth in old age; the lips being inverted, the red border becomes narrower, and when the mouth is closed the chin is drawn toward the nose.

The more or less characteristic changes produced by disease can not, of course, be described here; allusion may be made to the waxy hue of the skin in certain renal affections, the cyanosis in grave cardiac lesions, the hectic flush associated with pulmonary tuberculosis, and the "*facies hippocratica*." In the last named the sunken temples and cheeks; the pointed nose and chin; the dull, leaden hue; the few drops of perspiration, and the cold, clammy skin portend the near approach of death.

The **supra-orbital arches** are readily recognized as the dividing line between the forehead and the face. They are strong arches which form the upper boundary of the circumference of the orbit. They are covered by the eyebrows. Internally they end in the internal angular processes of the frontal bone, which articulate with the lacrymal bone and the nasal process of the superior maxilla. Between the two internal angular processes, at the fronto-nasal suture, a meningocele or an encephalocoele sometimes appears. Externally, the supra-orbital arches terminate in the external angular processes, which articulate with the malar bone. Immediately below the supra-orbital arches are the eyes. They and their lids present points of interest. In size the eyes do not vary much in different individuals, the apparent difference being due to the variations in the length of the palpebral fissure, which thus permits a larger or smaller portion of the ocular surface to come into view. The **palpebral fissure** is the aperture between the edges of the two lids, and extends from the inner to the outer canthus. The fissure is not, as a rule, exactly horizontal, the outer canthus being generally a little higher than the inner.

By everting the eyelids, the **tarsal cartilage** may be felt as a thickened portion of the lid. The vertical arrangement of the Meibomian glands in the tarsal cartilage can also be made out. During sleep the eyeball turns upward and inward, thus sheltering the pupil behind the base of the upper lid under the supra-orbital arch, the lower lid, at the same time, moving upward and somewhat inward. In fainting spells, or during sleep, the white sclerotic of the eyeball shows through the palpebral fissure. This fact is often of value in detecting a sham sleep or a sham faint; when, after gently lifting the upper lid by pressing upward and against the eyeball, if the pupil is in view, the patient is not asleep.

The **puncta lachrymalia** are readily discernible near the inner canthus, the lower being the larger and more external. The introduction of a probe into the lacrymal canaliculus should be preceded by drawing the lid outward, thus straightening the canal.

The **tendo oculi** can be felt after drawing the eyelids outward, or forcibly closing the eye. Immediately behind this is the **lacrymal sac**. If a knife were pushed backward just below the tendo oculi it would enter the sac, with the angular artery and vein on the inner side of the puncture. A probe passing through this opening into the sac, and then downward, slightly outward, and backward, would enter the nasal duct and appear in the inferior meatus of the nose. Tension upon the tendon, as in closure of the eyelids, compresses the sac, with which it is closely connected, thus emptying the sac and forcing the tears which have collected at the inner angle of the eye down the nasal duct.

The **nasal duct** extends from the inner angle of the eye to the inferior nasal meatus, just under the inferior turbinated bone. It is about three-quarters of an inch in length, and constricted in its middle. The lower opening in the nasal mucous membrane is a slit, but there is quite a large opening in the dry bone. When the lower end of the duct lies in the lateral wall of the meatus instead of in its roof, greater difficulty is experienced in passing a probe into the duct.

The lower border of the orbit (**infra-orbital margin**) lies immediately below the eyeball and is formed by the superior maxillary and malar bones. It can be readily felt throughout its entire extent.

The **glabella** is a flat, triangular eminence situated between the two internal extremities of the superciliary ridges. Immediately below the apex of the glabella is found the prominence of the nose formed by the nasal bones.

The form of the nose and much of the general expression of the face are due to the size and form of the nasal bones. The difference in these bones accounts for the variations we find in the various races. In the Mongolian and Ethiopian the nasal bones are flat and broad at their base, and thus form the flat nose which is so characteristic of those races. In the Caucasian race, however, the nasal bones are narrow and elongated as well as prominent at the bridge. The nose is rigid at its root and base as far as its middle, beyond which it is cartilaginous and flexible. The intimate adherence of the skin to the nasal cartilages, which are attached to the lower ends of the nasal bones, makes furuncles or erysipelas in this region exceedingly painful, because of the lack of cutaneous elasticity.

The lower end of the nose is open and divided into the two **anterior nares** by the nasal septum and the *columna*. It should not be forgotten that the nose is attached lower than the floor of its cavity; so that it must be elevated when the interior is to be inspected.

Below the nose is seen the mouth, which is the upper opening of the gastrointestinal tract. The lips contain muscles and vessels, and play a large part in the general expression of the face. In the living subject the pulsations of the superior and inferior coronary arteries can be easily felt by holding the lips between the finger and the thumb. In the operation for harelip these arteries are divided, the ensuing hemorrhage being easily controlled by pressure with the finger and thumb. Although the aperture between the lips is generally spoken of as the mouth, it must be remembered that the mouth extends backward from the lips to the pharynx.

Below the lips can be found the prominence of the symphysis of the lower jaw. The lower jaw is easily felt from the symphysis to the condyle, where it articulates with the temporal bone. By slight pressure along the bone the alveolar border, in which the teeth are set, can be readily distinguished. In passing the finger backward along the lower border of the body of the jaw the angle, which is at the junction of the body with the ramus, can be distinguished. In front of the angle is a depression through which passes the facial artery, the pulsation of which can be detected in the living subject. The condyle of the lower jaw is felt in front of the tragus of the external ear and below the zygomatic arch. When the mouth of a living person is opened, the condyle can be felt leaving the glenoid fossa and advancing upon the eminentia articularis. This forward motion of the condyle affords a freer access to the external ear, which can be demonstrated by passing the little finger into the external auditory meatus and opening and closing the mouth.

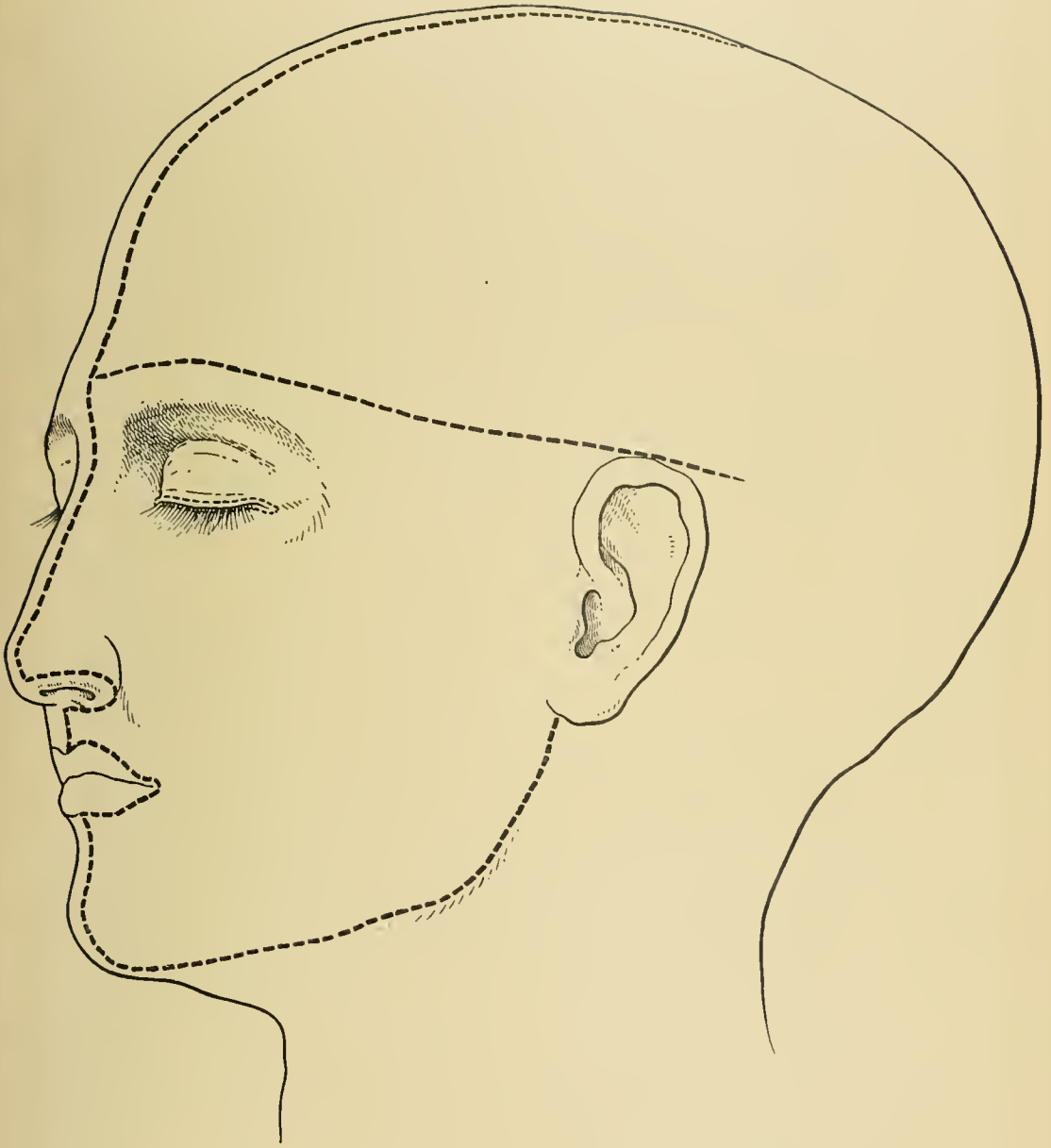
In the supra-orbital margin, at the junction of its inner with its middle third, is the **supra-orbital notch, or foramen**, which gives passage to the supra-orbital vessels and nerve. The **mental foramen** is found in the lower jaw, opposite the second bicuspid tooth; it gives passage to the mental vessels and nerve. In a line drawn between the supra-orbital notch and mental foramen, and just below the infra-orbital margin, is the infra-orbital foramen, which gives passage to the infra-orbital vessels and nerve. These nerves are derived from the fifth cranial nerve. Quite frequently accessory foramina are found external to the constant ones, and usually transmit a portion of the nerve which commonly passes through the normal foramen. These anomalies, especially on account of their frequency, are of considerable significance in the treatment of neuralgias by nerve section. The anomalous openings occur most frequently in connection with the supra-orbital, the infra-orbital, or the mental foramen, in the order named, and upon the right side. At times a deep groove extends for several inches upward from the accessory supra-orbital foramen and about a finger's breadth internal to the temporal ridge. Failure to obtain relief in some cases of neuralgia, after section of the nerve which

passes through the normal foramen, may be due to an accessory nerve, instead of to central disease or affections of the ganglia connected with the parent stem.

Continuing outward from the external angular process is the **zygomatic arch**, formed by the malar bone and the zygomatic process of the temporal bone. The anterior part of the arch is flat and broad, and forms the prominence of the cheek, or the "cheek bone." Posteriorly, the zygomatic arch terminates in front of, and just above, the external auditory meatus. On account of the attachment of the dense temporal fascia to the upper border of this arch, the lower border is more easily distinguished. The zygomatic arch forms a dividing line between two depressions. These are generally filled with fat in the healthy individual, and, therefore, are not markedly evident. As soon as a wasting disease begins to tax the organism, the fat above the zygoma is absorbed, and this bony arch becomes much more prominent; as the wasting progresses, the masseteric depression can be plainly seen, and, at the same time, the fat in front of the anterior margin of the masseter muscle and below the anterior half of the malar bone disappears, with resultant sinking of the cheeks.

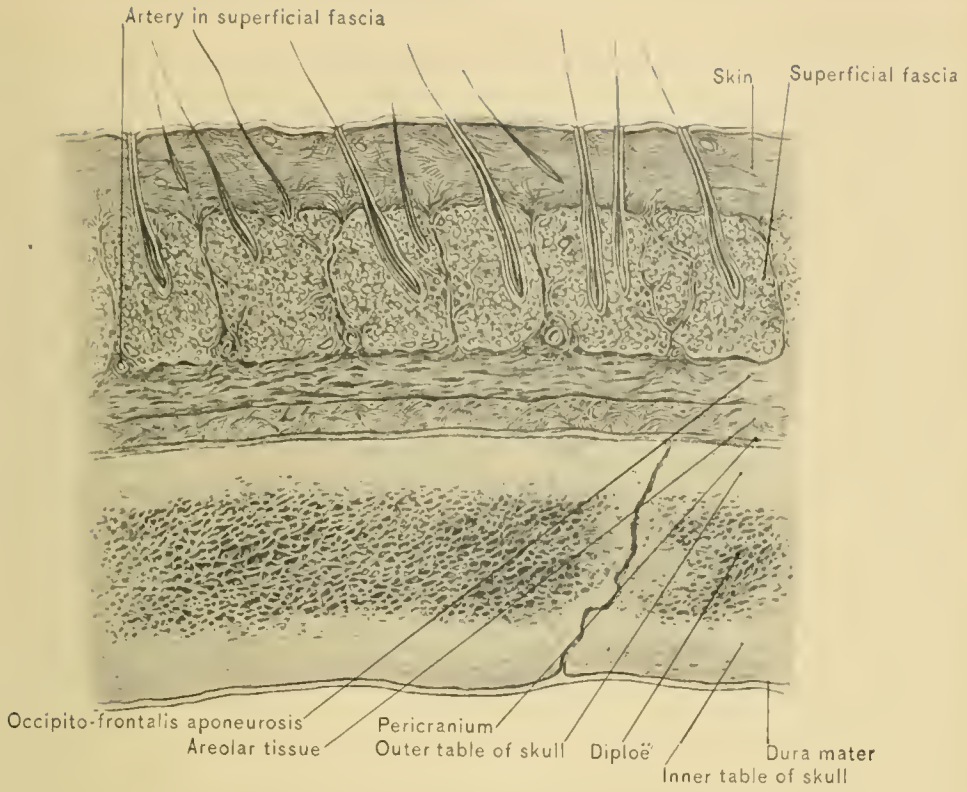
The **arteries of the face** are the temporal, between the ear and zygoma, and the facial, on the body of the lower jaw just in front of the masseter muscle, at the angle of the mouth, and passing along the naso-labial fold and side of the nose to the inner angle of the eye. The facial vein runs straight across the face from the inner canthus of the eye to the anterior inferior angle of the masseter muscle at the lower border of the lower jaw. The anterior temporal and facial arteries are useful to the anesthetizer in studying the pulse, and also to the physician when the patient is sleeping.

Expression is due to muscular traction upon the facial integument. In facial hemiplegia, when the muscles of the affected side have lost their power, expression is gone, and the wrinkles of the face disappear. The "expression of the eye" is due to wrinkling of the lids and the peri-ocular integument. The study of the relation between facial expression and the permanent markings of the face resulting therefrom, as an index to character and disposition, is still in its infancy. Note the proximity of the muscle centers of the face in the ascending frontal and parietal gyri to the speech center. The latter is at the tip of the operculum around the ascending arm of the Sylvian fissure, and at the lower part of the ascending gyri. Just above it is the lip center, followed by that of the face, fingers, hand, and arm, with that of the lower limb overtopping all. Is this not also the order in which these muscle groups are involved during increasing animation accompanying a discussion? The central excitement becomes greater and extends over wider areas, sending larger and more intense impulses to those muscle bundles which traverse the facial integument and pull its surface hither and thither, forming wrinkles,



INCISIONS FOR DISSECTION.





LAYERS OF SCALP.



dimples, scowls, and puckerings, expressive of the condition of the mind in relation to the matter engaging it. The habitual recurrence of these emotional results leaves its impress by gradually undermining the elasticity of the skin involved and by contracting the affected muscles, producing upon the individual's face indications of his character which may be read by all who are competent.

The **external ear, or pinna**, is placed at the junction of the face, neck, and cranial vault. The general conformation and direction of the pinna, and its utility for the collection and partial condensation of sound, need only be mentioned. During inspection of the tympanic membrane and of the whole length of the external auditory canal, the direction of the latter concerns us practically. It is about an inch and a quarter long. When removing foreign bodies, which frequently lodge in this canal, it is important to note that it sags at its outer end, and can be straightened by pulling the pinna upward. The greatest diameter of the canal is vertical at the external end, and transverse at the internal. The upper and posterior portions of the tympanic membrane incline outward.

SCALP.

DISSECTION.—The dissection of the scalp should be made before that of the face and neck. The body should lie on its back, the head being well elevated by means of a large block placed under the nape of the neck. The head having been shaved, an incision should be carried from the root of the nose over the middle line of the vertex to the external occipital protuberance; and a second incision, at a right angle to the first, commencing at the nasal eminence, should extend on each side as far back as the ear. Beginning at the junction of the two incisions, reflect the skin backward and outward, forming two flaps. When dissecting these flaps great care must be taken to remove only the skin, the best guide being the bulbs of the hair, which are in the superficial fascia.

The scalp is that portion of the cranial covering which lies in front of the superior curved ridges of the occipital bone and above the two temporal ridges, though in the dissection of the scalp, for convenience, the tissues in the temporal region are included.

Layers.—The scalp above the temporal ridges is made up of five layers—viz., skin, superficial fascia, occipito-frontalis aponeurosis, loose areolar tissue, and pericranium (external periosteum). In the frontal and occipital regions, in place of the aponeurosis, are the muscular bellies of the occipito-frontalis muscle. Below the temporal ridges (in the temporal regions) the scalp is composed of eight layers—

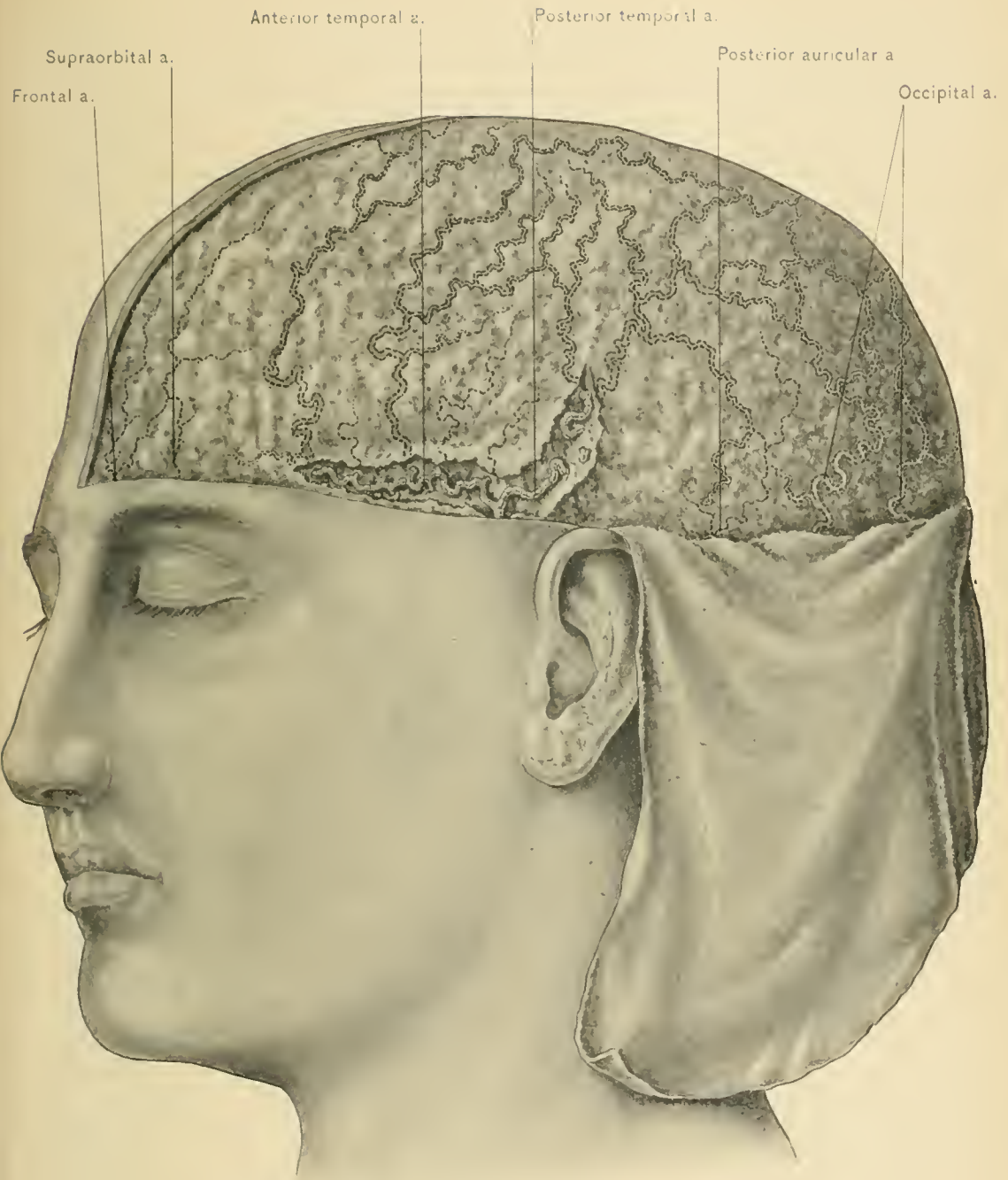viz., skin, superficial fascia, *attolens* and *attrahens aurem* muscles, occipito-frontalis (epicranial) aponeurosis, areolar tissue, temporal fascia, the temporal muscle, and the periosteum. That which is usually spoken of as the scalp includes the skin, the superficial fascia, and the occipito-frontalis muscle and aponeurosis; these three layers are closely adherent to one another.

The **skin of the scalp** is thicker than that of any other part of the body. By means of the superficial fascia the skin is closely adherent to the occipito-frontalis muscle and aponeurosis, which accounts for the movement of the skin with the muscle and its aponeurosis. It is rich in sebaceous glands which, when enlarged on account of occlusion of their ducts, constitute sebaceous cysts or wens, so common in this region. These growths, even when large, except in very rare instances, are superficial to the occipito-frontalis aponeurosis, and with care can, therefore, be removed without risk of opening the areolar tissue layer. The skin is well nourished by the vessels of the superficial fascia.

The **superficial fascia of the scalp** consists of but one layer, which presents a granular appearance, due to the nodulated fat and dense fibrous septa. Its septa firmly connect the skin to the occipito-frontalis aponeurosis. In its density and capability of resisting pressure it is like the superficial fascia of the palm of the hand and sole of the foot. It is continuous behind with the superficial fascia of the back of the neck; laterally, and in front, with the superficial fascia of the face. It contains the principal blood-vessels and nerves of the scalp, in this respect differing from the superficial fascia elsewhere, with the exception of that of the face and ischio-rectal fossæ, the muscles of the auricle, and the hair-bulbs. The arteries of the scalp lie, as it were, in canals in the fascia, and are attached to the walls of these canals by loose fibrous tissue; when divided, they have a slight tendency to retract within these channels or canals, and, on account of the density of the fascia, it may be difficult to seize them with the artery forceps. Consequently, some form of pressure is often employed to check the bleeding. The presence of the hair-bulbs in this dense fascia and their firm attachment to the scalp enable a strong person, by securely grasping the hair, to lift the entire weight of the body without tearing out the hair-roots. Owing to the density of the superficial fascia, redness and swelling are not very pronounced in inflammation of the scalp. The superficial fascia is thickest in the occipital region, and gradually grows thinner as it approaches the front and sides of the cranium.

Wounds of the scalp bleed freely, because the arteries can not contract or retract on account of the density of the superficial fascia and their close adherence to the connective-tissue septa within which they ramify.

DISSECTION.—Upon one side of the head the superficial fascia with the vessels



SUPERFICIAL FACE OF SCALP.

and nerves are to be removed as one common layer, bringing into view the corresponding half of the occipito-frontalis aponeurosis and muscle; while upon the other side only the superficial fascia in the immediate neighborhood of the vessels and nerves is to be removed, in this way exposing and giving a clear idea of the blood and nerve supply of the scalp. In reflecting the superficial fascia preserve the *attolens* and *atrahens aurem* muscles which lie between it and the aponeurosis.

The **Extrinsic Muscles of the Ear** are very feeble and rudimentary, the auricle in man being practically immovable. They are three in number—the *attolens aurem*, *atrahens aurem*, and *retrahens aurem*; they require considerable care in dissection to avoid being overlooked and destroyed.

DISSECTION.—Draw the pinna downward and fasten it with hooks; this will make tense the *attolens* and *atrahens aurem* muscles.

The ***attolens aurem***, the largest of the three muscles, is broad and fan-shaped, converging to a narrow tendon below. It arises from the superficial surface of the occipito-frontalis aponeurosis below the temporal ridge, and is inserted into the cranial aspect of the upper part of the pinna.

NERVE SUPPLY.—From the temporal branch of the facial nerve.

ACTION.—It draws the pinna upward.

The ***atrahens aurem*** is the smallest muscle of the three, and arises from the occipito-frontalis aponeurosis in front of the *attolens aurem* muscle, and is inserted into the front of the helix.

NERVE SUPPLY.—From the temporal branch of the facial nerve.

ACTION.—It draws the pinna forward and upward.

DISSECTION.—Release the pinna from its present position and draw it forward; fasten it with hooks, and divide the integument over the tense band behind the auricle to expose the *retrahens aurem* muscle.

The ***retrahens aurem*** muscle consists of two or three short muscular bundles which arise from the mastoid process of the temporal bone and are inserted into the back of the concha.

NERVE SUPPLY.—From the posterior auricular branch of the facial nerve.

ACTION.—It draws the pinna backward.

The **Arteries of the Scalp** are derived, in front, from the supra-orbital and frontal arteries; on the sides, from the temporal; and behind, from the posterior auricular and occipital arteries.

The **supra-orbital artery**, a branch of the ophthalmic, leaves the orbit through the supra-orbital notch, and divides into a superficial and a deep branch, which ascend toward the vertex, anastomosing with the temporal and frontal arteries and with the supra-orbital artery of the opposite side. It supplies the tissues of the forehead.

The **frontal artery**, one of the two terminal branches of the ophthalmic, leaves the orbit at its inner angle and ascends on the forehead, anastomosing with the supra-orbital and with the frontal artery of the opposite side.

The **temporal artery**, the smaller of the two terminal divisions of the external carotid, commences in the substance of the parotid gland and ascends over the posterior root of the zygoma, about two inches above which it divides into the *anterior and posterior temporal*; in some cases it divides immediately after crossing the zygoma; rarely, it divides below the zygoma. It is accompanied by branches of the facial and auriculo-temporal nerves. It is covered by the *attrahens aurem* muscle and crossed by one or two small veins. The temporal and anterior temporal arteries are the vessels used by the anesthetizer to ascertain the character of the pulse.

The *anterior temporal artery* passes forward in a tortuous course to anastomose with the supra-orbital and frontal arteries and with the anterior temporal artery of the opposite side. It supplies the tissues along its course. It is the branch usually selected when blood is to be extracted from the arterial system.

The *posterior temporal artery*, the larger of the two, passes upward and backward above the pinna and anastomoses with the posterior temporal artery of the opposite side and with the occipital and posterior auricular arteries.

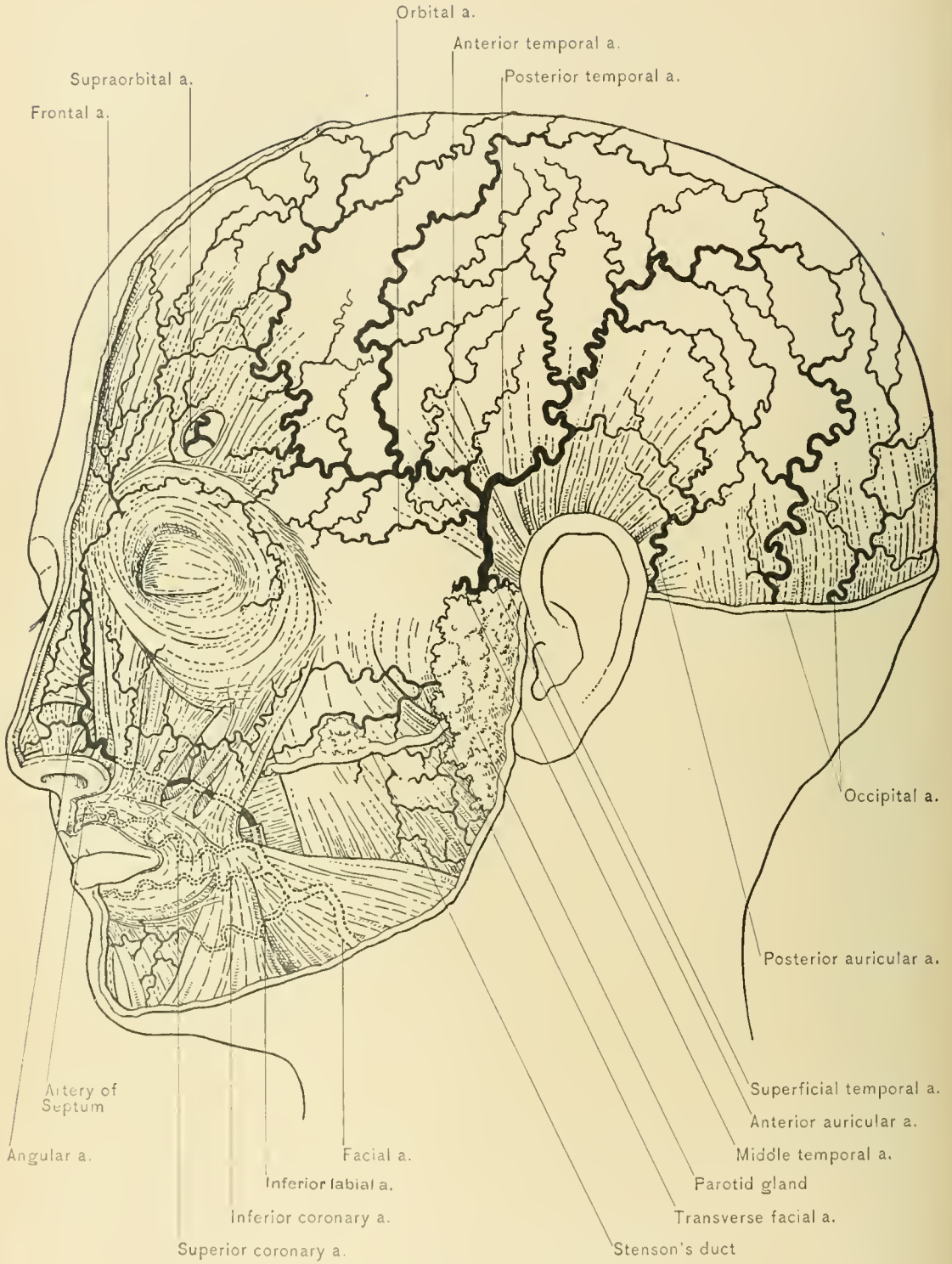
The transverse facial, anterior auricular, and middle temporal branches of the temporal artery will be described with the dissection of the face.

The *posterior auricular artery* passes over the mastoid process, and divides into two branches—an anterior and a posterior. The anterior branch passes forward and anastomoses with the posterior temporal artery; the posterior branch passes backward and anastomoses with the occipital artery. It is accompanied by the posterior auricular nerve, a branch of the facial nerve.

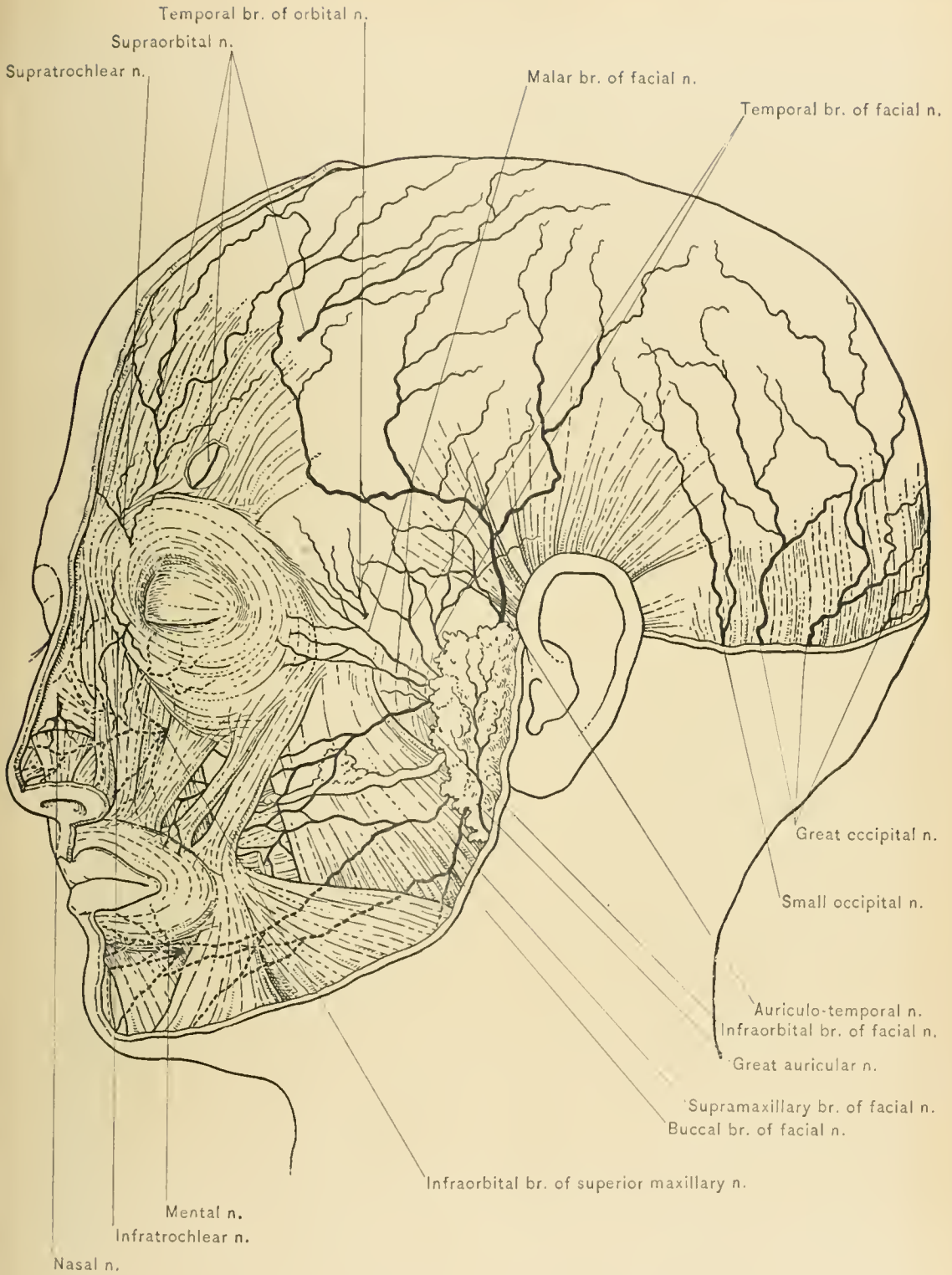
The **occipital artery** pierces the trapezius muscle at its attachment to the superior curved line of the occipital bone, about midway between the mastoid process and the external occipital protuberance. Thence it ascends in a tortuous course over the back of the head to the vertex, dividing into numerous branches, which anastomose with the occipital artery of the opposite side and with the posterior temporal and posterior auricular arteries. It is accompanied by the great occipital nerve.

The arteries of the scalp sometimes become elongated and tortuous, producing what is known as **cirroid aneurysm**. The anterior temporal artery is the one most commonly affected.

The **Veins of the Scalp** accompany the corresponding arteries, with the exception of the supra-orbital and frontal veins, which unite to form the angular, the commencement of the facial, vein. The veins of the scalp communicate with



ARTERIES OF SCALP AND FACE.



NERVES OF SCALP AND FACIAL NERVE.

the sinuses in the interior of the skull and with the veins of the diploë by means of the emissary veins.

The **Nerves of the Scalp** are branches of the trifacial, facial, and great occipital nerves, and of the cervical plexus.

The **supra-orbital nerve**, the larger of the two terminal branches of the frontal branch of the ophthalmic nerve, leaves the orbit with the supra-orbital artery through the supra-orbital notch or foramen, which is located in the upper margin of the orbit at the junction of its inner and middle thirds, and ascends upon the forehead beneath the orbicularis palpebrarum and the frontal belly of the occipito-frontalis muscle. It divides into two branches—an inner and an outer—and becomes subcutaneous; the inner branch, the smaller, pierces the frontal belly of the occipito-frontalis muscle and ascends as high as the parietal bone; the outer branch, the larger, pierces the occipito-frontalis aponeurosis and ascends over the vertex as far as the occipital bone.

The **supra-trochlear nerve**, the smaller of the two terminal branches of the frontal branch of the ophthalmic nerve, appears at the inner angle of the orbit above the pulley of the superior oblique muscle, and ascends upon the forehead. It is covered by the orbicularis palpebrarum and frontalis muscles, piercing the latter to end in the integument. It supplies the skin of the forehead and the upper eyelid.

Neurectomy.—The supra-orbital and supra-trochlear nerves are often affected by neuralgia, for the relief of which division or resection of these nerves may be required. The supra-orbital notch, if present, forms a sure guide to the position of the supra-orbital nerve, which can be reached and exposed by a vertical incision immediately over the notch, or by a transverse incision parallel to and a little below the eyebrow. The latter method, as it leaves a less noticeable scar, is the one more commonly practised. The former method, however, will expose a larger portion of the nerve. The skin having been divided by either a vertical or a transverse incision, the further dissection should be in a direction parallel to the fibers of the orbicularis palpebrarum muscle. The old subcutaneous operation is now seldom done on account of the extensive extravasation from division of the supra-orbital vessels. To divide the nerve well back in the orbit, it is necessary to sever the orbito-tarsal ligament and depress the orbital fat, when the nerve is separated from its connections and lifted on a blunt hook. The supra-trochlear nerve is exposed through an incision carried in a line drawn from the angle of the mouth through and beyond the inner canthus. The nerve will be found at the point of intersection of this line with the upper margin of the orbit. The occasional presence of an accessory supra-orbital foramen, giving passage to a division of the supra-orbital nerve, should not be overlooked. Recurrence of pain

immediately after operation is good presumptive evidence of the existence of an accessory foramen.

Temporal branch of the orbital nerve.—About an inch above the zygoma the temporal fascia is pierced by the temporal branch of the orbital branch of the superior maxillary nerve, which is distributed to the integument of the temple and communicates with the temporal branch of the facial nerve.

The **auriculo-temporal nerve**, a branch of the inferior maxillary nerve, accompanies the temporal vessels, lying posterior to them. The auriculo-temporal nerve emerges from beneath the upper part of the parotid gland, and divides into two terminal branches—the anterior and posterior temporal. The anterior temporal nerve, the larger, accompanies the anterior temporal artery to the vertex, and communicates with the facial and temporo-malar nerves. The posterior temporal nerve, the smaller, accompanies the posterior temporal artery.

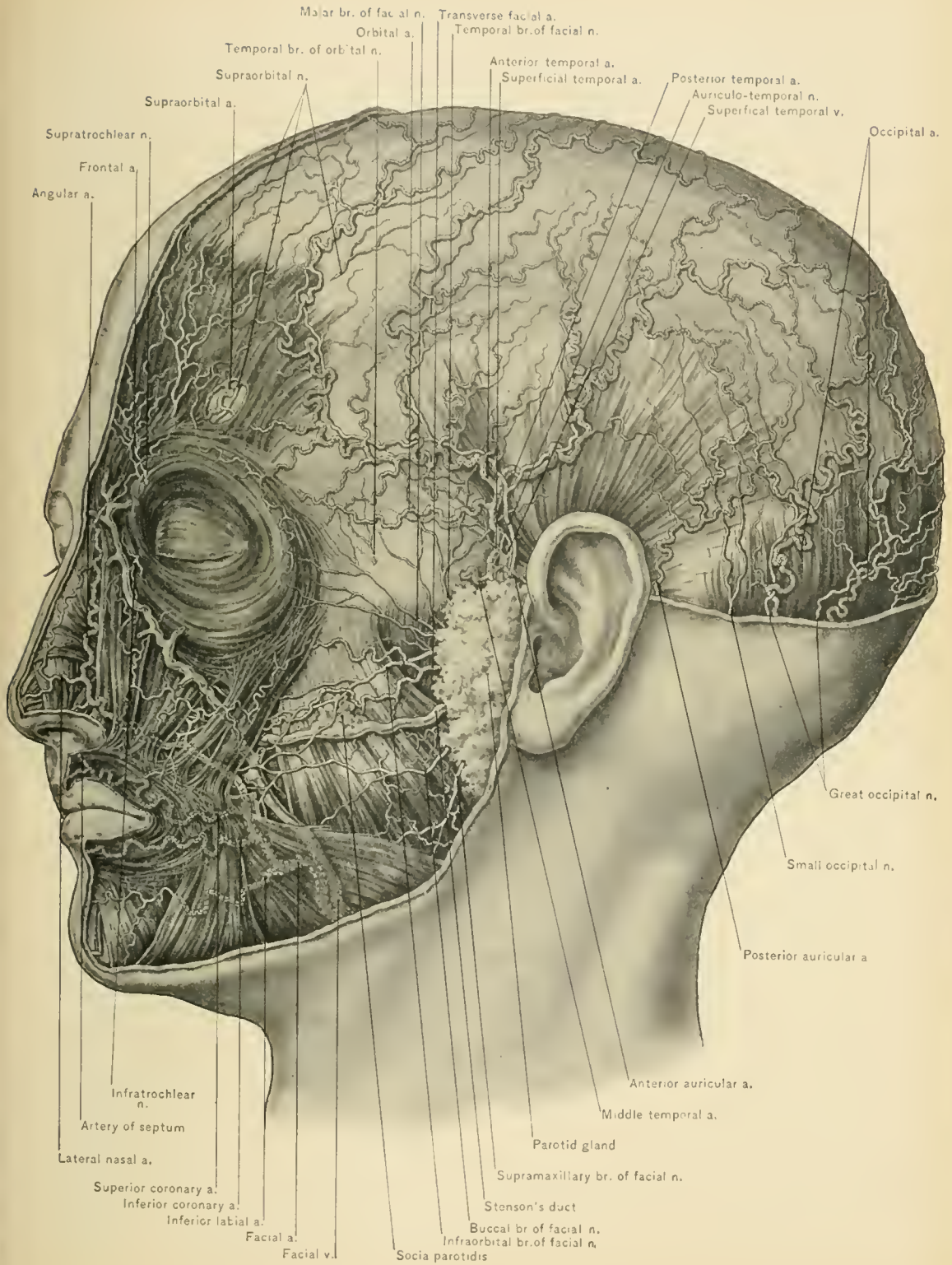
Temporal branches of the facial nerve extend upward over the zygoma upon the temple to supply the *atrahens* and *attolens aures*, the *orbicularis palpebrarum*, the *frontalis*, and the *corrugator supercilii* muscle. They communicate with the temporo-malar, auriculo-temporal, lacrymal, and supra-orbital nerves.

The **posterior auricular nerve**, a branch of the facial, accompanies the posterior auricular artery, and, like the latter, divides into two branches—a posterior and an anterior. The posterior (occipital) supplies the *occipitalis* muscle; the anterior (auricular), the auricle and the *retrahens* and *attolens aures* muscles. This nerve is joined by filaments from the auricular branch of the pneumogastric nerve and from the great auricular and small occipital nerves.

The **small occipital nerve** (*occipitalis minor*), a branch of the anterior division of the second cervical nerve, supplies the scalp behind the ear and over the occiput. It communicates with the great auricular and the great occipital nerve, and with the posterior auricular branch of the facial nerve. It can be seen in the neck running along the posterior border of the sterno-mastoid muscle.

The **great occipital nerve** (*occipitalis major*), the largest cutaneous nerve of the scalp, accompanies the occipital artery over the occiput. It is the internal branch of the posterior division of the second cervical nerve; pierces the complexus and trapezius muscles near their attachment to the occipital bone; enters the superficial fascia with the occipital artery, and breaks up into a number of large branches which spread over the back of the head, supplying the integument as far forward as the vertex. It communicates with the small occipital and the first cervical nerve, and receives a branch from the third cervical nerve.

The **Lymphatics of the Scalp** follow the same course as the blood-vessels, which is the general rule. The posterior, or occipital, lymphatics enter the occipital glands situated along the origin of the *occipitalis* muscle; the postero-



ARTERIES, NERVES, AND MUSCLES OF SCALP AND FACE.

lateral, or posterior auricular, set enter the posterior auricular glands situated upon the mastoid attachment of the sterno-mastoid muscle; the temporal lymphatics enter the glands situated upon and within the parotid gland; and a frontal set end in the facial lymphatics. In congestion of the scalp due to cold, and in other affections of this region which increase the activity of the lymphatics, these glands are considerably swollen and painful.

The occipito-frontalis muscle and aponeurosis, exposed upon the side from which the superficial fascia has been removed, will now be studied.

The **occipito-frontalis** is a broad, musculo-aponeurotic layer covering one side of the vertex of the skull from the occiput to the brow. It consists of two flattened muscular bellies, an occipital and a frontal, with an intervening aponeurosis.

The *occipital belly* (*occipitalis muscle*), thin and quadrangular, arises from the outer two-thirds of the superior curved ridge of the occipital bone and the adjoining mastoid process, thus leaving a triangular interval between the two occipitales muscles as their fibers eventually meet higher up in the median line. The fibers are about an inch and a half in length and ascend to the aponeurosis.

BLOOD SUPPLY.—From the occipital and posterior auricular arteries.

NERVE SUPPLY.—The occipitalis muscle derives its nerve supply from the posterior auricular branch of the facial and, exceptionally, from the occipitalis minor nerve.

The *frontal belly* (*frontalis muscle*), a thin, muscular layer having intimate cutaneous connections, arises from the aponeurosis below the coronal suture. It descends over the forehead and blends with the orbicularis palpebrarum, the corrugator supercilii, and the pyramidalis nasi muscle.

BLOOD SUPPLY.—From the frontal, supra-orbital, and anterior temporal arteries.

NERVE SUPPLY.—The frontalis muscle derives its nerve supply from the temporal branch of the temporo-facial division of the facial nerve.

The *aponeurosis* extends over the vertex and is continuous across the middle line with the aponeurosis of the opposite side; laterally it is continued over the temporal fascia to the zygoma, just above which it is attached to that fascia. Connected with the lateral portion of the aponeurosis are the attolens and attrahens aurem muscles. It is intimately connected with the skin through the attachment of the superficial fascia, and but loosely connected with the pericranium by the connective tissue which intervenes, thus accounting for the movement of the integument when the occipito-frontalis muscle is in action.

ACTION.—Contraction of the anterior belly of the muscle elevates the eye-

brow and produces wrinkling of the forehead ; if contraction be continued, it draws the scalp forward, and pulls up the skin of the nose, to the extent even of moving the naso-labial folds ; contraction of the occipital belly draws the scalp backward ; and alternate contraction of the two bellies moves the scalp backward and forward.

DISSECTION.—Divide the aponeurosis in the median line, and make another incision at its junction with the frontalis muscle. Reflect the aponeurosis outward and backward, and the frontalis muscle downward.

Areolar tissue layer.—The mobility of the scalp depends entirely upon the laxity of the subjacent areolar tissue layer ; it is this layer which permits extensive flaps of the scalp to be torn loose. When the hairs become caught in moving machinery the entire scalp may be torn off, laying this tissue bare. It was due to the laxity of this layer that the American Indian, with no knowledge of anatomy or surgery, was able to peel off the scalp with so much ease. Exposure of the skull in a postmortem examination is effected by peeling off the scalp along this layer of tissue, and it is remarkable with what ease the skull can thus be exposed. To further illustrate the laxity of this tissue, it will suffice to relate a case mentioned by the late D. Hayes Agnew : A midwife attending a woman in child-birth incised the child's scalp, thinking it the protruding bag of waters. Labor pains came on, and the head protruded through the scalp wound with the entire vault of the skull laid bare.

Tumors.—By careful examination tumors situated above the occipito-frontalis aponeurosis or in it will be seen to be freely movable. All immovable growths of the scalp should be most carefully examined before extirpation, for they are probably beneath the aponeurosis ; a tumor originating within the cranium may force its way outward and form a prominence on the scalp.

Wounds involving only the skin and superficial fascia of the scalp, when the occipito-frontalis muscle or its aponeurosis has not been divided, do not gape, because of the close adherence of the skin to the superficial fascia and of the superficial fascia to the aponeurosis. The areolar tissue layer permits of wide separation of the edges of a wound which divides the occipito-frontalis aponeurosis. Antero-posterior wounds which involve the aponeurosis gape but little, while the edges of transverse wounds are widely separated by the contraction of the occipito-frontalis muscle. The great vascularity of the scalp lessens the likelihood of sloughing and gangrene. A large flap of the scalp attached by but a small pedicle is much less likely to perish than a flap of skin torn from another part of the body, as the vessels of the scalp run immediately beneath the skin and are included in the flap. In phlegmonous erysipelas and in deep inflammation of the scalp the areolar tissue layer becomes infiltrated with pus and consequently sloughs. As the vessels are superficial to this layer the skin does not

necrose, ulcerate, and allow pointing, and for this reason it is important to incise early.

The **pericranium** (external periosteum) is but loosely attached to the bone, except at the sutures, where the union is firm. In lacerated wounds of the scalp the pericranium is frequently stripped from the skull to the extent of exposing large areas of bone. The pericranium differs in its functions from the periosteum covering other bones in that, if the periosteum be removed to any extent from another bone, the part of the bone from which it is removed will most probably necrose, while the pericranium may be stripped from a considerable part of the vault of the cranium without necrosis following. This is due to the fact that the bones of the skull receive their blood supply chiefly from the vessels of the external (endosteal) layer of the dura mater, while the other bones are nourished to a great extent through their periosteal covering. The pericranium at the sutures becomes continuous with the external layer of the dura mater, constituting the so-called intersutural membrane. It is also continuous with the dura at the foramina; hence it is that inflammation of the pericranium may extend by continuity and involve the dura mater, producing pachymeningitis.

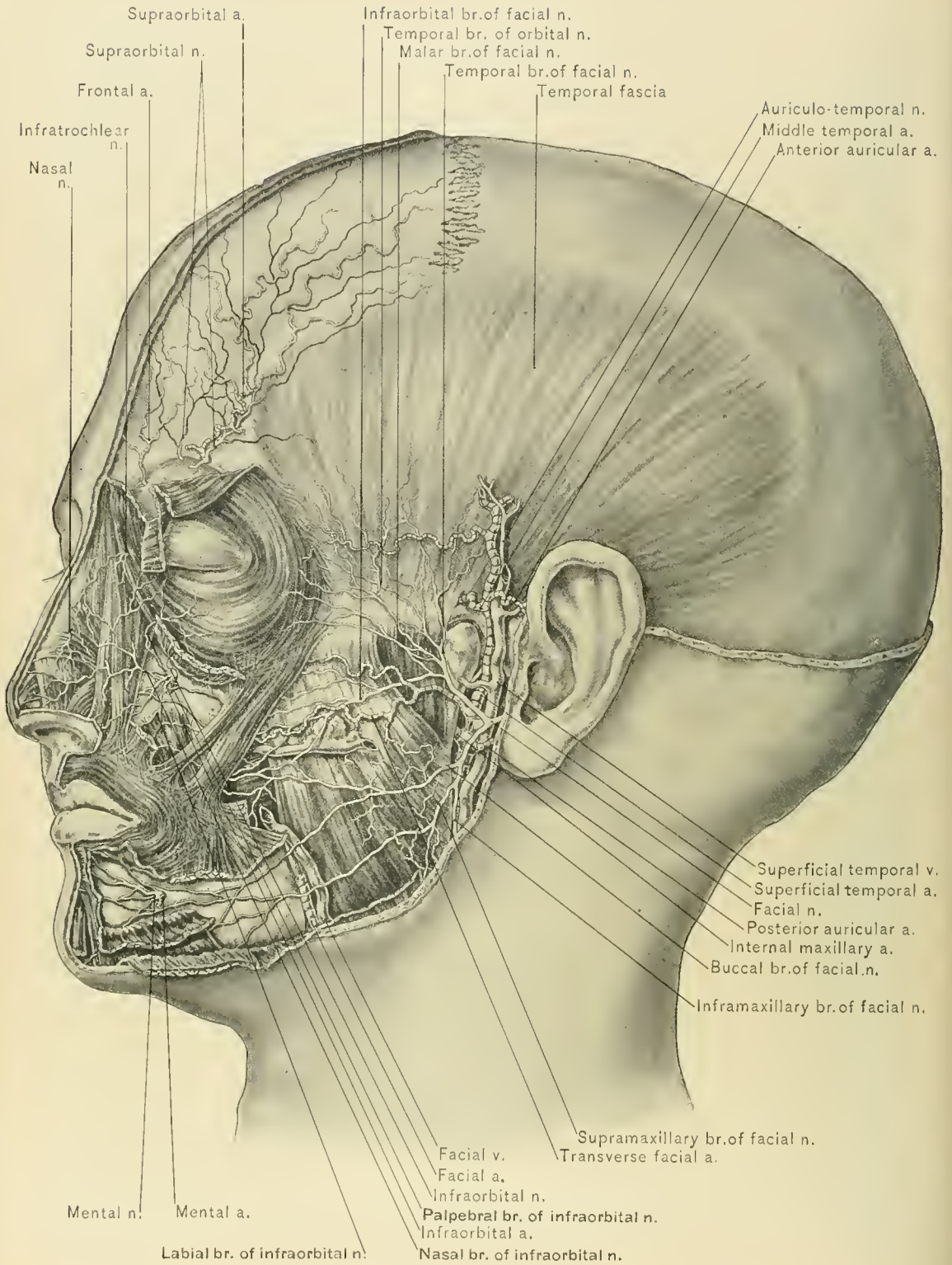
Collections of blood or pus in the scalp may be situated superficial to the occipito-frontalis aponeurosis, between the aponeurosis and the pericranium or beneath the pericranium. A collection superficial to the aponeurosis is of but little moment, since the density of the superficial fascia causes it to be circumscribed. Collections in the areolar tissue layer, between the aponeurosis and the pericranium, are limited only by the attachments of the occipito-frontalis muscle and its aponeurosis; thus they may undermine the entire scalp and prove serious if not evacuated early. Collections beneath the pericranium are limited to a single bone, on account of the sutural attachments of the membrane. Collections in the areolar tissue layer call for drainage, and should they be slow in healing, the scalp must be firmly bandaged in order to arrest the movements of the occipito-frontalis muscle. Hematomata in the areolar tissue layer are uncommon, except as a result of fissured fracture of the skull with rupture of one of the branches of the middle meningeal artery, or of the superior longitudinal or lateral sinus, as the areolar tissue between the aponeurosis and the pericranium contains but very few vessels. Collections of blood beneath the pericranium, generally termed cephalhematomata, must be limited to one bone, since the membrane dips into the sutures and becomes continuous with the dura mater; they are usually congenital and due to pressure upon the head at birth.

In **septic inflammation of the scalp** infection may reach the superior longitudinal sinus through the parietal emissary vein and the lateral sinus through the occipital and posterior auricular veins and their communications with

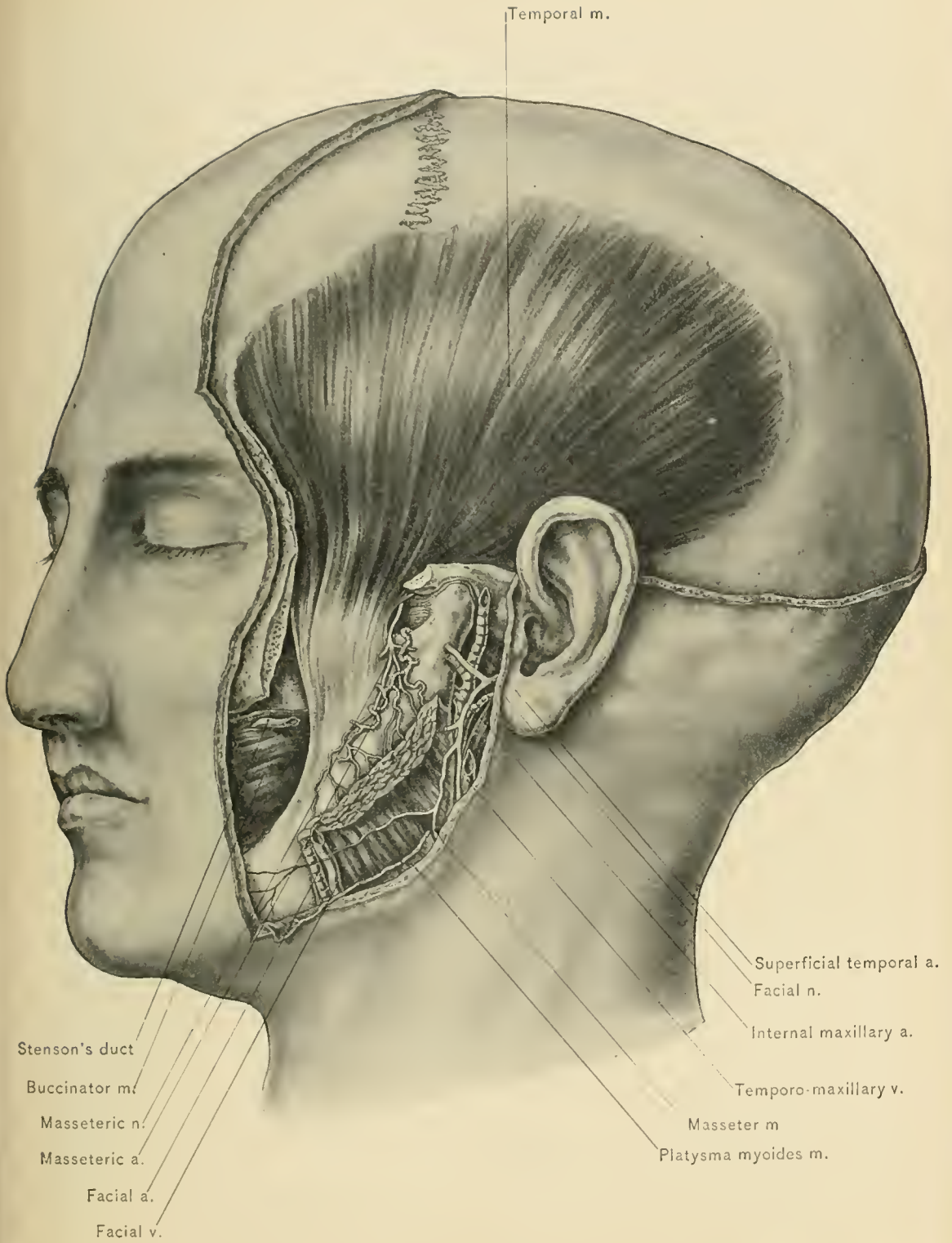
the mastoid vein which empties into the lateral sinus. Through the anastomoses between the diploic veins and the veins of the pericranium septic material in the scalp may reach the sinus *alæ parvæ* and the cavernous sinus through the fronto-sphenoid diploic vein, the superior petrosal sinus through the anterior temporal diploic vein, and the lateral sinus through the posterior temporal and occipital diploic veins. In erysipelas, abscess, and other infectious inflammations of the scalp germs may enter the sinuses through these various routes and cause thrombosis, embolism, and pyemia.

Temporal fascia.—The temporal fascia is a white, shining membrane, which is stronger than the occipito-frontalis aponeurosis in this location, and which gives attachment by its under surface to the superficial fibers of the temporal muscle. Above, it is attached to the entire extent of the temporal ridge as a single layer; while below, it divides into two layers, the outer of which is attached to the external and the inner to the internal border of the upper margin of the zygomatic arch and zygomatic process of the malar bone. Between these two layers are seen a small quantity of fat, the orbital branch of the middle temporal artery, and the temporal branch of the temporo-malar or orbital branch of the superior maxillary nerve. In relation with its outer surface is the extension of the occipito-frontalis aponeurosis, the orbicularis palpebrarum, the *attolens* and *attrahens aurem* muscles, the temporal vessels, the auriculo-temporal nerve, and the temporal branches of the orbital and facial nerves. Immediately above the zygoma it is pierced by the middle temporal artery, a branch of the temporal.

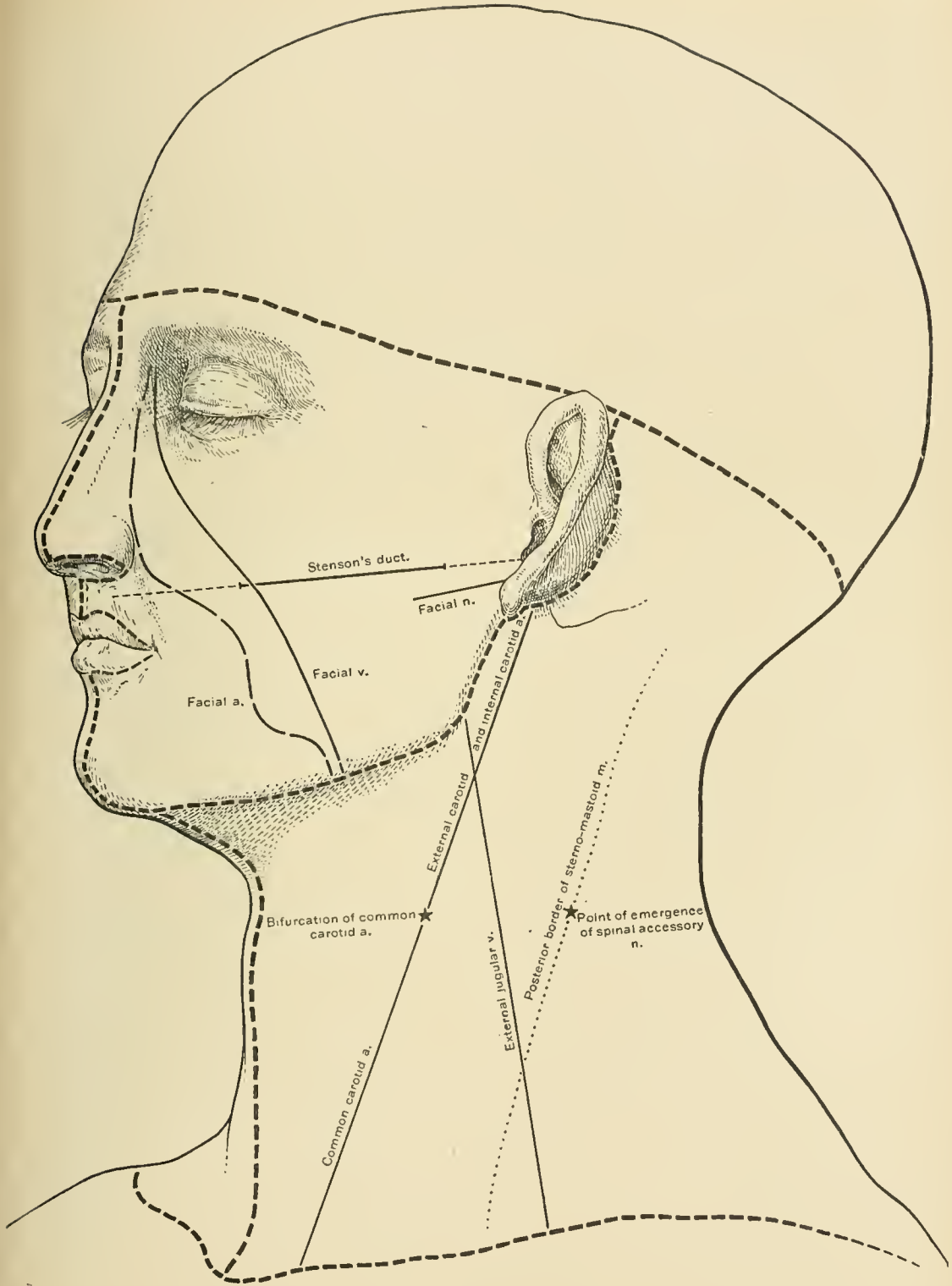
Density of the temporal fascia.—Owing to the density of this fascia abscesses beneath it very rarely point upon the surface, the pus passing in the direction of least resistance—namely, through the pterygo-maxillary region into the mouth or neck. Its unyielding nature is well illustrated by a case recorded by Denonvilliers: “A woman who had fallen in the street was admitted to the hospital with a deep wound in the temporal region; a piece of bone several lines in length was found loose at the bottom of the wound and was removed. After its removal the finger could be passed through an opening with an unyielding border, and came in contact with some soft substance beyond. The case was considered one of compound fracture of the squamous portion of the temporal bone, with separation of a fragment and exposure of the brain. A bystander, however, noticed that the bone removed was dry and white. A more thorough examination of the wound revealed the fact that the skull was uninjured, that the supposed hole in the skull was merely a laceration of the temporal fascia, that the soft matter beyond was muscle and not brain, and that the fragment removed was simply a piece of bone, which, lying on the ground, had been driven into the soft parts when the woman fell” (Treves).



TEMPORAL FASCIA AND NERVES OF FACE.



TEMPORAL MUSCLE.



INCISIONS FOR DISSECTION AND LINES FOR VESSELS AND NERVES.

DISSECTION.—The temporal fascia should now be detached from the zygomatic arch and reflected upward, when the greater portion of the temporal muscle and a quantity of fat overlying the muscle above the zygoma will be exposed. The tendon of insertion of the muscle will be seen in dissecting the face.

The **temporal muscle**, broad, flat, and triangular, is situated on the side of the head, and occupies the temporal fossa. It arises from the under surface of the temporal fascia and from the whole of the temporal fossa, whence its fibers descend and converge to a tendon which passes under the zygomatic arch to be inserted into the apex, the inner surface, and the fore part of the coronoid process of the lower jaw down to the last molar tooth.

BLOOD SUPPLY.—From the middle and deep temporal arteries.

NERVE SUPPLY.—Derived from the temporal branches of the *inferior maxillary nerve*.

ACTION.—The action of the temporal muscle is to elevate the lower jaw; its posterior fibers also assist in drawing the lower jaw backward after other muscles have carried it forward.

FACE.

DISSECTION.—The dissection of the face should follow that of the scalp. The head should be placed in the same position as for the dissection of the scalp, but slightly lower, and turned so that the side of the face to be dissected is upward. The cheeks and nostrils should be distended with cotton or oakum and the lips sewed together. The muscles and vessels should be dissected on one side of the face and the nerves on the other. The incisions are made as follows: The first incision is made from the nasal eminence along the median line of the nose, around the aperture of the nostril, along the median line of the upper lip, around the mouth along the line where the skin joins the mucous membrane to the median line of the lower lip, and thence to the point of the chin. A second incision is carried along the lower border of the jaw to the angle of the jaw, then upward to the lobe of the ear. Reflect the skin outward. The facial muscles (muscles of expression) are inserted partly into the skin, and great care must be taken that they are not removed with the skin.

The **skin of the face** is remarkably thin, and freely supplied with vessels and nerves. On account of the free blood supply it is a common site of nevi, except over the chin, where it is peculiarly dense and adherent to the parts beneath. The skin covering the eyelids and the bridge of the nose, owing to the presence

of a layer of lax cellular tissue, is loosely adherent to the parts beneath. Over the cartilages of the nose the skin is so intimately adherent to the tissues beneath that it is removed with difficulty. It is very freely supplied with sebaceous and sudoriferous glands, and hence is commonly the site of acne and eruptions which especially involve the sebaceous follicles; it is also the site of sebaceous tumors. Facial abscesses usually point quickly and seldom attain large size.

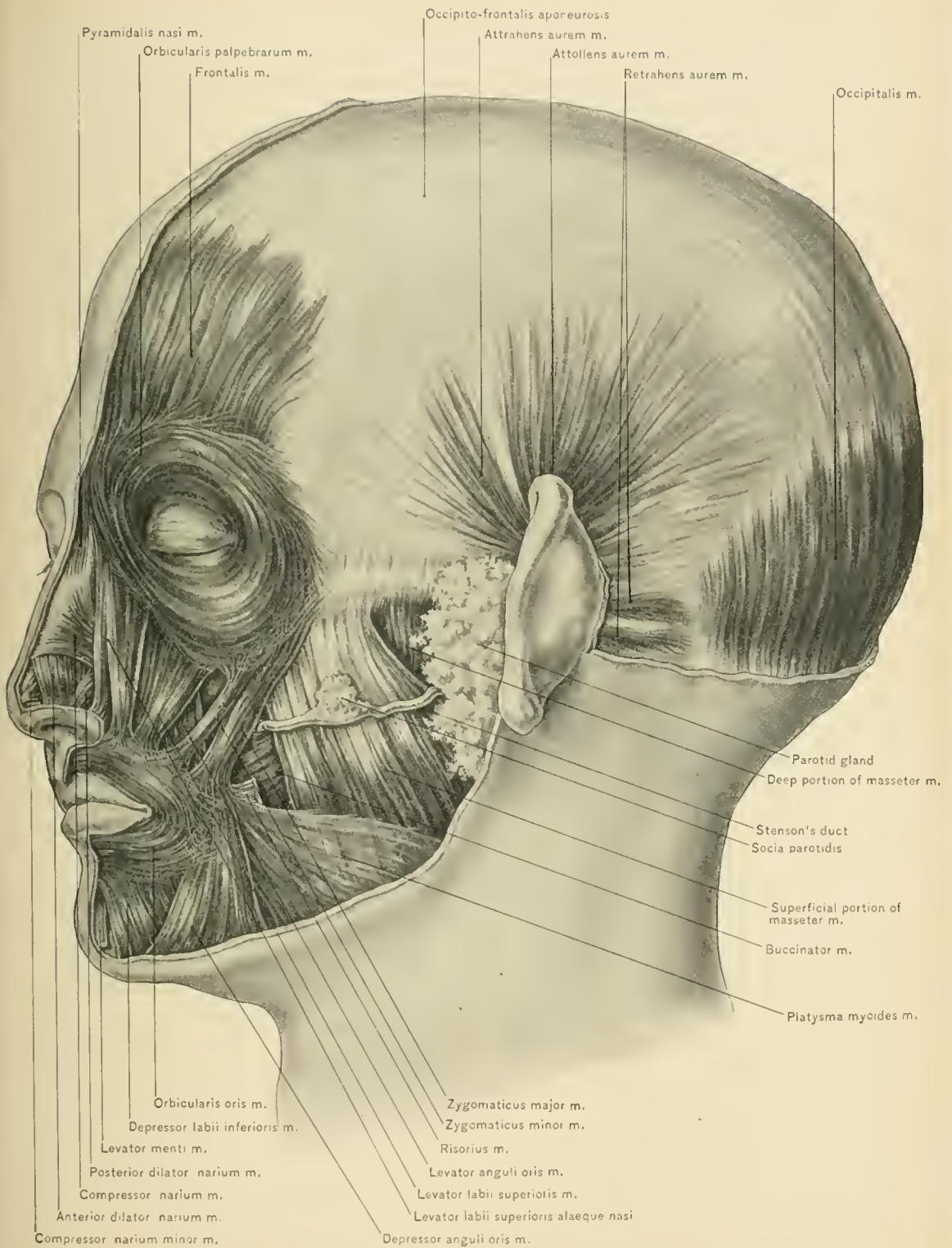
The **superficial fascia**—the cellular tissue layer of the face—contains a considerable amount of fat, except in the eyelids and over the bridge of the nose. The laxity of the cellular tissue favors the spreading of infiltrations, so that the cheeks and other parts of the face may become greatly swollen. In general dropsy the face soon becomes puffy, the edema first appearing, as a rule, in the lax areolar tissue of the lower eyelid. The soft tissues of the cheek favor the spread of destructive processes. In *canerum oris*—a form of gangrene of the mouth attacking the young—the whole cheek may be lost in a few days. Great contraction is apt to follow upon loss of substance, so that the jaw may be firmly closed in some cases, as is seen after recovery from deep ulceration (Treves). The mobility of the tissues of the face renders this region favorable for the performance of plastic operations, and their vascularity insures a prompt and perfect union. Notwithstanding the fact that there is a large quantity of fat in the subcutaneous tissue, fatty tumors are rarely seen in this region. The thickness of the tissues of the cheeks and lips favors the embedding of foreign substances in these parts. Thus, a tooth which has been knocked out has remained embedded in the lip. Henry Smith reported a remarkable case in which he removed a piece of tobacco-pipe three inches long from the cheek, where it had remained for several years.

DISSECTION.—The superficial fascia—underlying which are the muscles, vessels, and nerves—should be removed in the same manner as the skin, taking care not to disturb the muscles. As the superficial fascia is not easily removed in a continuous layer, it may be taken away in sections, the dissection being made in the line of the muscular fibers; this is necessary, too, in order to avoid dividing the blood-vessels and nerves of the face. The removal of the fascia in this manner exposes the muscles, the vessels, and the nerves.

The **Muscles of the Face** (muscles of expression) are divided into three groups: those of the nose, those of the eyebrows and eyelids, and those of the mouth—*i. e.*, nasal, palpebral, and oral.

The **Muscles of the Nose** are the *pyramidalis nasi*, the *compressor nasi*, the *levator labii superioris alæque nasi*, the *dilator naris*, and the *depressor alæ nasi*.

The **pyramidalis nasi muscle** covers the nasal bone, and is continuous above with the *frontalis* muscle, where it is attached to the deep surface of the inter-superciliary integument. It arises from the aponeurosis over the cartilage of



MUSCLES OF FACE AND SCALP.

the nose, where it joins the lower edge of the nasal bone and the compressor nasi muscle.

NERVE SUPPLY.—From the infra-orbital branch of the temporo-facial division of the facial nerve.

ACTION.—It renders the skin over the cartilages tense, and that over the root of the nose lax, thus forming the transverse crease at the root of the nose.

The **compressor nasi muscle** is triangular in shape, arises by its apex from the canine fossa of the superior maxillary bone, and ends in the aponeurosis covering the cartilaginous part of the nose, blending with the corresponding muscle of the opposite side. The origin of this muscle is concealed by the levator labii superioris alæque nasi muscle.

NERVE SUPPLY.—From the infra-orbital branch of the upper division of the facial nerve.

ACTION.—It throws the skin at the side of the nose into vertical wrinkles, aids in the elevation of the upper lip, and slightly compresses the cartilaginous ridge of the nose.

When the compressor nasi muscle is reflected from the median line outward, the superficial branch (naso-labial) of the nasal nerve, which becomes subcutaneous between the nasal bone and the lateral nasal cartilage, will be seen running downward to the tip of the nose.

The **levator labii superioris alæque nasi muscle**, placed by the side of the nose and overlapping the origin of the compressor nasi muscle, arises from the upper part of the nasal process of the superior maxilla. It descends, and divides into two portions: the inner and smaller part is inserted into the inner side of the ala nasi, and the outer into the upper lip, blending with the orbicularis oris muscle. It is partially overlapped near its origin by the orbicularis palpebrarum muscle.

NERVE SUPPLY.—From the infra-orbital branch of the facial nerve.

ACTION.—It raises the inner half of the upper lip, and draws outward the wing of the nose, thus dilating the anterior naris.

The **dilator naris muscle** consists of two portions—an anterior and a posterior. The anterior portion is a thin fasciculus which passes from the lower edge of the cartilage of the wing of the nose to the integument over the ala; the posterior portion arises from the margin of the nasal notch of the superior maxilla and from the outer surface of the sesamoid cartilages of the nose, and is inserted into the skin over the back and lower margin of the ala of the nose.

NERVE SUPPLY.—From the infra-orbital branch of the facial nerve.

ACTION.—It enlarges the anterior naris by raising and everting its outer edge, thus counteracting its tendency to be closed by atmospheric pressure. In conditions occasioning dyspnea—*e. g.*, laryngeal or tracheal obstruction—the action of

these muscles can plainly be seen, and constitutes one of the signs which indicate tracheotomy or intubation.

The **depressor alæ nasi** is a short, flat muscle which may be exposed when the upper lip is everted and its mucous membrane removed from the side of the labial frenum. It arises from the incisive fossa of the superior maxilla, whence its fibers ascend to be inserted into the septum nasi and the posterior lower part of the wing of the nose.

NERVE SUPPLY.—From the buccal branch of the cervico-facial division of the facial nerve.

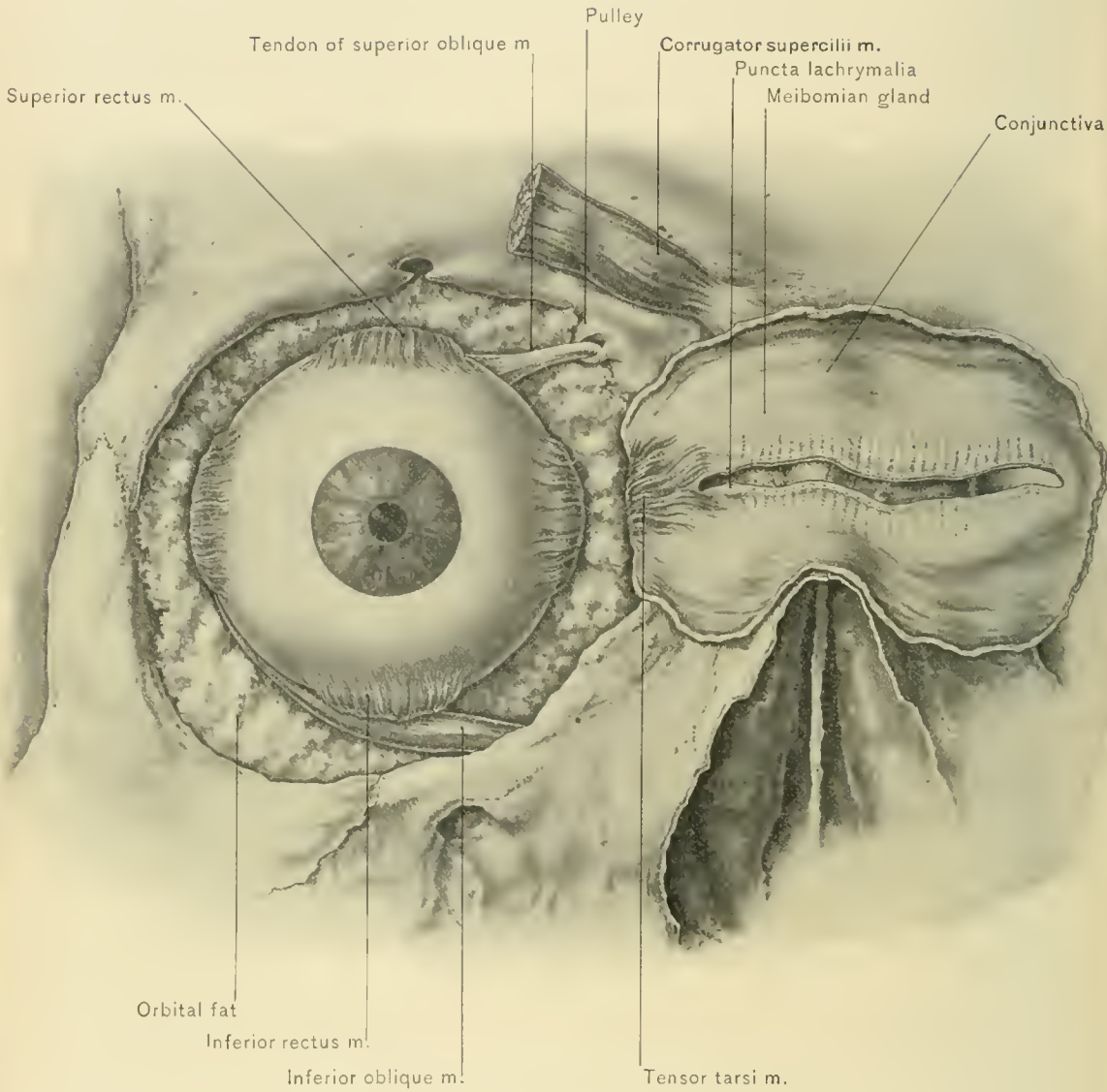
ACTION.—It draws downward and inverts the edge of the nasal cartilages.

The **Muscles of the Eyelids and Eyebrows** are the orbicularis palpebrarum, the corrugator supercilii, the levator palpebræ superioris, and the tensor tarsi.

Tendo oculi (tendo palpebrarum).—Before examining the orbicularis palpebrarum the tendo oculi (internal tarsal ligament) is to be noted. It is a short tendon, about one-sixth of an inch in length by one-twelfth of an inch in breadth, and can readily be felt at the inner angle of the eye after drawing the eyelids outward. It is attached to the nasal process of the superior maxilla in front of the lacrymal groove, passes transversely outward in front of the lacrymal sac, and divides into two portions, separated by the caruncula lachrymalis; the upper portion is attached to the inner extremity of the upper, and the lower to the inner extremity of the lower, tarsal cartilage. As the tendon crosses the lacrymal sac it gives off a strong aponeurotic lamina, which covers the sac and is attached to the margin of the lacrymal groove. This expansion will be seen on reflecting that portion of the orbicularis palpebrarum muscle which covers the lacrymal sac. To puncture the lacrymal sac a knife is inserted below the tendo oculi in a direction downward and a little backward, dividing the skin, the orbicularis palpebrarum muscle, and the fibrous expansion derived from the tendo oculi. The angular artery and vein are situated on the inner side of the incision.

The **external tarsal ligament** extends, undivided, transversely inward from the edge of the frontal process of the malar bone to the adjacent outer extremities of the two tarsal cartilages.

The **orbicularis palpebrarum** (orbicularis oculi, sphincter oculi) is a thin, broad muscle which surrounds the margin of the orbit and the eyelids, forming a sphincter; it is continuous, above, with the fibers of the frontalis muscle. It arises from the internal angular process of the frontal bone, the nasal process of the superior maxilla, the tendo oculi, and the lower margin of the orbit. From this origin the fibers are directed outward, forming a series of oval curves which cover the eyelids, surround the margin of the orbit, and spread over the forehead, temple, and cheek. The central fibers, occupying the eyelids and connected inter-



TENSOR Tarsi AND CORRUGATOR SUPERCILII MUSCLES.

nally with the *tendo oculi* and externally with the external tarsal ligament and the malar bone, constitute the *palpebral portion* of the muscle. The fibers of this portion, which are in immediate relation with the eyelashes, have been described as the *ciliary muscle*; but this, however, must not be confounded with the ciliary muscle proper—the muscle of visual accommodation. More peripheral fibers constitute the *orbital portion* of the muscle. The latter arise from the internal angular process of the frontal bone and from the nasal process of the superior maxillary bone, and are distributed around the margin of the orbit. They are continuous above with the *frontalis* and *corrugator supercilii* muscles, and extend outward upon the cheek to mingle with the elevators of the upper lip and nose and with the *zygomaticus minor* muscle.

NERVE SUPPLY.—From the temporal and malar branches of the temporo-facial division of the facial nerve; hence in paralysis of this nerve the eyelids on the paralyzed side can not be closed.

ACTION.—The *orbicularis palpebrarum* muscle closes the eyelids and protects the eye. The palpebral portion of the muscle contracts during winking. Contraction of the orbital portion presses the eyeball backward into the orbit and draws the soft parts covering the margin of the orbit around the eyeball, thus protecting it from injury. While this cushion of tissue may be severely bruised, as is seen in a “black” eye, the eyeball itself is rarely injured. As the outer portion of the *orbicularis* is mingled with the fibers of the *frontalis* muscle and the elevators of the upper lip and nose, slight depression of the eyebrow and elevation of the upper lip and of the wing of the nose follow contraction of this portion. Strong contraction of the entire muscle holds the eye firmly in the orbit, thus protecting it against the severe strain in violent coughing, sneezing, and vomiting, during which acts the muscle usually contracts spasmodically. Contraction of the palpebral portion of the muscle following that of the *orbicular* portion tends to draw the lids slightly inward, thus directing the tears to the inner angle of the fissure between the eyelids, near which are situated the *puncta lachrymalia*.

The **tensor tarsi** (Horner’s muscle) is a small muscle, really a deep portion of the *orbicularis palpebrarum*, situated at the inner angle of the orbit behind the *tendo oculi*. To expose it it is necessary to cut perpendicularly through the middle of the upper and lower eyelids, when the nasal half of each lid should be reflected inward and the mucous membrane removed. The muscle will be seen to arise from the ridge on the lacrymal bone. It passes outward behind the lacrymal sac and divides into two portions which cover the posterior aspect of the canaliculi. The two portions terminate in the inner ends of the upper and lower tarsal cartilages near the *puncta lachrymalia*.

NERVE SUPPLY.—From the infra-orbital branch of the temporo-facial division of the facial nerve.

ACTION.—It compresses the lacrymal sac.

The **corrugator supercillii muscle** arises from the inner end of the superciliary ridge of the frontal bone. Its fibers are directed outward and a little upward to the under surface of the orbicularis palpebrarum and frontalis muscles, to be inserted into the former over the middle of the supra-orbital arch.

NERVE SUPPLY.—From the temporal branch of the temporo-facial division of the facial nerve.

ACTION.—It draws the eyebrow downward and inward, thus making the vertical wrinkle of the forehead at the inner extremity of the eyebrow.

DISSECTION.—The nasal half of the orbicularis palpebrarum and a small part of the frontalis muscle having been reflected inward, the corrugator supercillii is exposed.

The **levator palpebræ superioris muscle.**—By reflecting the outer as well as the nasal half of the orbicularis palpebrarum muscle, and detaching the orbitotarsal ligament from the superior orbital margin and reflecting the ligament downward, the insertion of the levator palpebræ superioris muscle by a broad aponeurosis into the upper border of the tarsal cartilage of the upper eyelid can be seen.

The **Muscles of the Mouth** are the orbicularis oris, the levator labii superioris, the levator anguli oris, the zygomaticus major, the zygomaticus minor, the buccinator, the risorius, the depressor labii inferioris, the depressor anguli oris, and the levator labii inferioris.

The **risorius muscle** (Santorini's muscle), a part of the platysma myoides, consists of a thin bundle of fibers which arises from the fascia covering the masseter muscle and parotid gland, and passes horizontally forward to the angle of the mouth, where it joins the fibers of the orbicularis oris and depressor anguli oris muscles; some of its fibers pass to the skin at the angle of the mouth.

NERVE SUPPLY.—From the buccal branch of the lower division of the facial nerve, which enters it from beneath.

ACTION.—It retracts the corner of the mouth. Its contraction during certain conditions, as in tetanus, causes the "risus sardonicus" of the old authors.

The **orbicularis oris muscle** (sphincter oris), nearly an inch in breadth, surrounds the mouth, forming a sphincter; at its periphery it unites with several muscles which act upon that aperture. It consists of two parts—an inner, central, or labial part, and an outer, peripheral, or facial part; the two differing in appearance and in the arrangement of fibers, like the orbicularis palpebrarum muscle. The inner, central, or labial portion consists of pale, thin fibers, fine in texture,

corresponds in position with the red margin of the lips, and has no bony attachment, but is continuous around the angles of the mouth from one lip to the other. The outer, peripheral, or facial part is thinner and wider than the labial, and has a bony attachment as well as connection with the adjacent muscles. In the upper lip the orbicularis oris muscle is attached at each side of the middle line to the lower part of the septum nasi by naso-labial slips, and to the alveolar border of the upper jaw opposite the incisor teeth; in the lower lip it is attached to the alveolar border of the lower jaw opposite the canine teeth by a single fasciculus (*musculi incisivi*). The cutaneous surface of the muscle is intimately connected with the skin of the lips and surrounding parts. The intimacy of this union is so great in some instances that the mouth is surrounded by radiating wrinkles, especially marked in the upper lips of women. The labial integument of the male probably contains fewer wrinkles on account of the presence of large hair-bulbs. The deep surface of the orbicularis oris is covered by mucous membrane, between which and the muscle, in the submucous tissue, are the coronary arteries and the labial glands.

NERVE SUPPLY.—From the buccal and supra-maxillary branches of the cervico-facial division of the facial nerve.

ACTION.—When the facial and labial portions act conjointly, they press together and project the lips. The labial fibers acting alone bring the lips and the angles of the mouth together and invert the lips. The facial fibers acting alone press the lips against the alveolar borders of the jaws, and, at the same time, evert the lips. The orbicularis oris is the antagonist of all those muscles which converge to the lips from the various parts of the face. Hypertrophy of the orbicularis oris or, rather, an increase of the connective tissue, particularly of the portion in the upper lip, to the extent of producing a considerable deformity, is sometimes seen, and indicates a plastic operation involving the removal of a transverse, wedge-shaped section from the lip.

The **levator labii superioris muscle** (*levator labii proprius*) arises from the superior maxilla above the infra-orbital foramen, and is inserted into the upper lip, its fibers blending with the orbicularis oris muscle. At its origin it is overlapped by the orbicularis palpebrarum, and covers the infra-orbital vessels and nerves. It is a landmark in exposing the infra-orbital nerve.

NERVE SUPPLY.—From the infra-orbital branch of the upper division of the facial nerve.

ACTION.—It raises the upper lip, at the same time making prominent the skin below the eye.

DISSECTION.—The levator labii superioris muscle is to be reflected downward from its origin, when will be exposed the levator anguli oris, the infra-orbital plexus of nerves, and the infra-orbital vessels.

The **levator anguli oris muscle** (*musculus caninus*) arises from the canine fossa of the superior maxilla below the infra-orbital foramen, and is inserted into the angle of the mouth, superficial to the buccinator muscle, its fibers blending with the orbicularis oris, the zygomatici, and the depressor anguli oris muscle.

NERVE SUPPLY.—From the infra-orbital branch of the upper division of the facial nerve.

ACTION.—It raises and draws inward the angle of the mouth.

The **depressor labii inferioris muscle** (*quadratus menti*) arises from the oblique line of the lower jaw by a wide origin, extending from a point below the foramen mentale nearly to the symphysis. Its fibers are associated with those of the muscle of the opposite side, ascend, and are inserted into the integument of the lower lip, blending with the orbicularis oris. Its outer border is overlapped by the depressor anguli oris muscle.

NERVE SUPPLY.—From the supra-maxillary branch of the cervico-facial division of the facial nerve.

ACTION.—It depresses and everts the lip.

The **depressor anguli oris muscle**, triangular in shape, hence also called *triangularis oris*, arises from the oblique line of the lower jaw external to the depressor labii inferioris muscles. Its fibers ascend, to be inserted into the angle of the mouth, intermingling with the zygomatici, the levator anguli oris, the risorius, and the orbicularis oris muscle. Its outer border overlaps the anterior part of the buccinator muscle.

NERVE SUPPLY.—From the supra-maxillary branch of the cervico-facial division of the facial nerve.

ACTION.—It draws the angle of the mouth downward and outward, producing an expression of sorrow.

The **levator labii inferioris**, or *levator menti*, is a small muscle seen by everting the lip and dissecting off the mucous membrane on each side of the labial frenum. It arises from the fossa below the incisor teeth, near the symphysis. Its fibers descend, and are inserted into the integument of the chin.

NERVE SUPPLY.—From the supra-maxillary branch of the cervico-facial division of the facial nerve.

ACTION.—It assists in raising the lower lip, at the same time wrinkling the integument of the chin over the point of its insertion.

The **zygomatic muscles** pass obliquely from the zygomatic arch to the upper lip and angle of the mouth. The **zygomaticus major** arises from the outer part of the malar bone in front of the suture, between it and the zygoma; its fibers pass obliquely downward and inward, to be inserted into the angle of the mouth, blending with the fibers of the orbicularis and depressor anguli oris muscles.

The **zygomaticus minor** arises from the outer part of the malar bone, anterior to the zygomaticus major, and behind the suture between the malar bone and the superior maxilla; its fibers pass downward and inward, to be inserted into the lower border of the levator labii superioris muscle. It is often absent.

NERVE SUPPLY.—From the infra-orbital branch of the temporo-facial division of the facial nerve.

ACTION.—The zygomaticus major draws the corner of the mouth upward and backward; the zygomaticus minor assists the levator labii superioris muscle in raising the upper lip.

Bucco-pharyngeal fascia.—Before making a dissection of the buccinator muscle, the thin layer of fascia which covers and adheres closely to its surface should be studied; it is attached to the alveolar borders of the superior and inferior maxillary bones, and posteriorly, where it is thickest, is continuous with the fascia over the constrictors of the pharynx. It is called by Holden the “bucco-pharyngeal fascia,” since it supports and strengthens the walls of the pharynx and mouth. The density of the buccal fascia offers a barrier to the escape of pus into the mouth or pharynx from an abscess in the cheek.

The **buccinator**, quadrangular in form, is a thin, flat muscle which occupies the interval between the jaws at the side of the face. It arises from the outer surface of the alveolar borders opposite the middle and posterior molar teeth of the superior and inferior maxillæ, and behind from the pterygo-maxillary ligament. The *pterygo-maxillary ligament* is a fibrous band extending from the apex (hamular process) of the internal pterygoid plate of the pterygoid process to the posterior extremity of the internal oblique line (mylo-hyoid ridge) of the lower jaw; it separates the buccinator muscle from the superior constrictor of the pharynx. The fibers of the buccinator pass forward, to be inserted into the orbicularis oris muscle at the angle of the mouth. The central fibers intersect one another, while the upper fibers pass to the upper lip and the lower fibers to the lower lip. In relation with the superficial surface of the buccinator muscle is a large mass of fat (buccal pad), which separates it from the ramus of the lower jaw, the masseter muscle, a small portion of the temporal muscle, and the muscles converging to the angle of the mouth. Absorption of the fat overlying the muscle is followed by sinking of the cheek, as seen in persons who are emaciated. In compression of the brain the flapping of the cheeks in breathing is the result of paralysis of the nerve supplying the buccinator, while the stertorous breathing (snoring) is the result of paralysis of the nerves of the soft palate. The duct of the parotid gland (Stenson's duct), which pierces the buccinator muscle opposite the second molar tooth of the superior maxilla, crosses the upper part of the muscle obliquely, at about a finger's breadth below the zygoma. It is also crossed by the facial artery and vein and

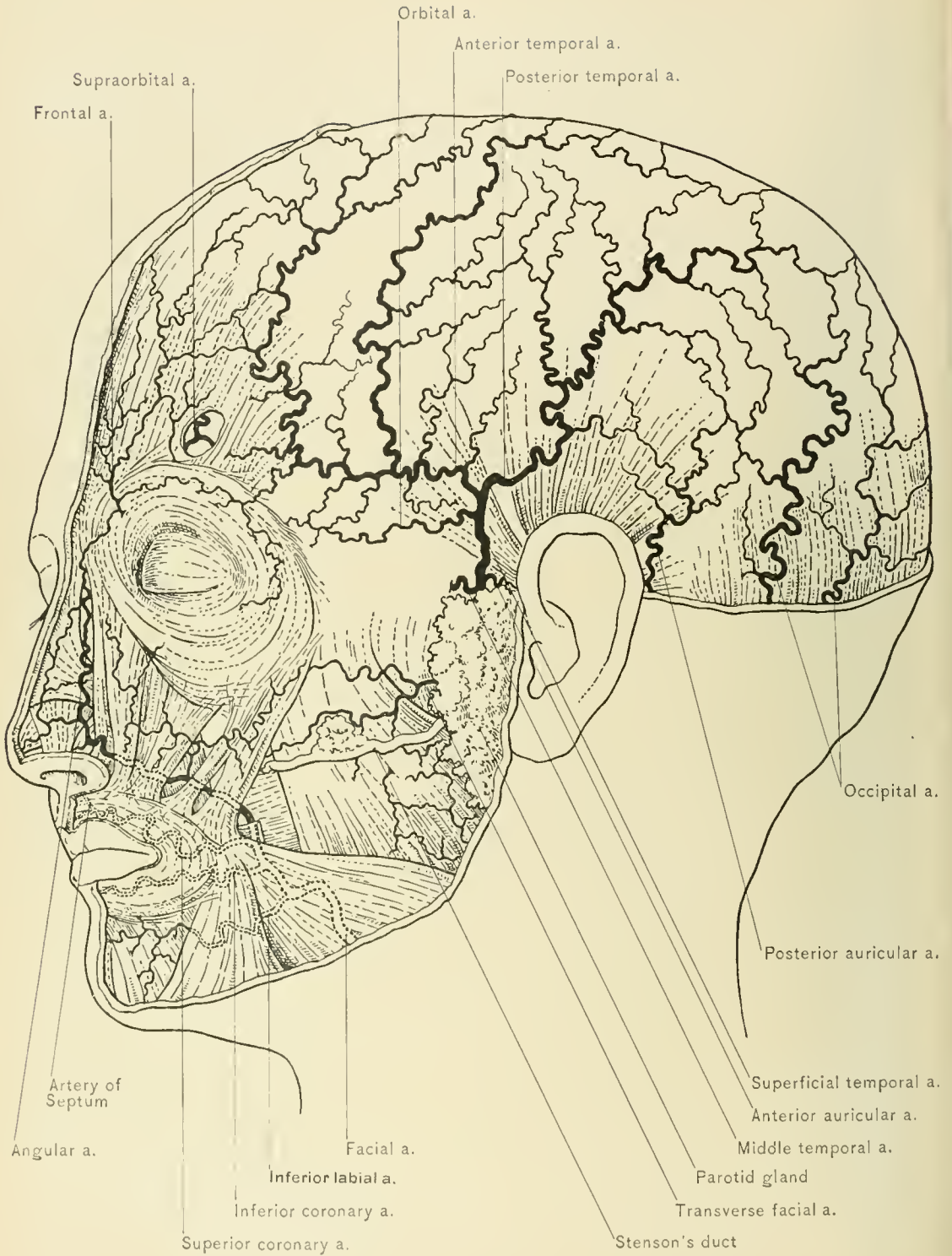
by branches of the facial nerve. Internally it is lined by the mucous membrane of the mouth; between this and the muscle lie a number of racemose glands called the buccal glands. A few of these glands are found on the outer surface of the muscle and are called molar glands.

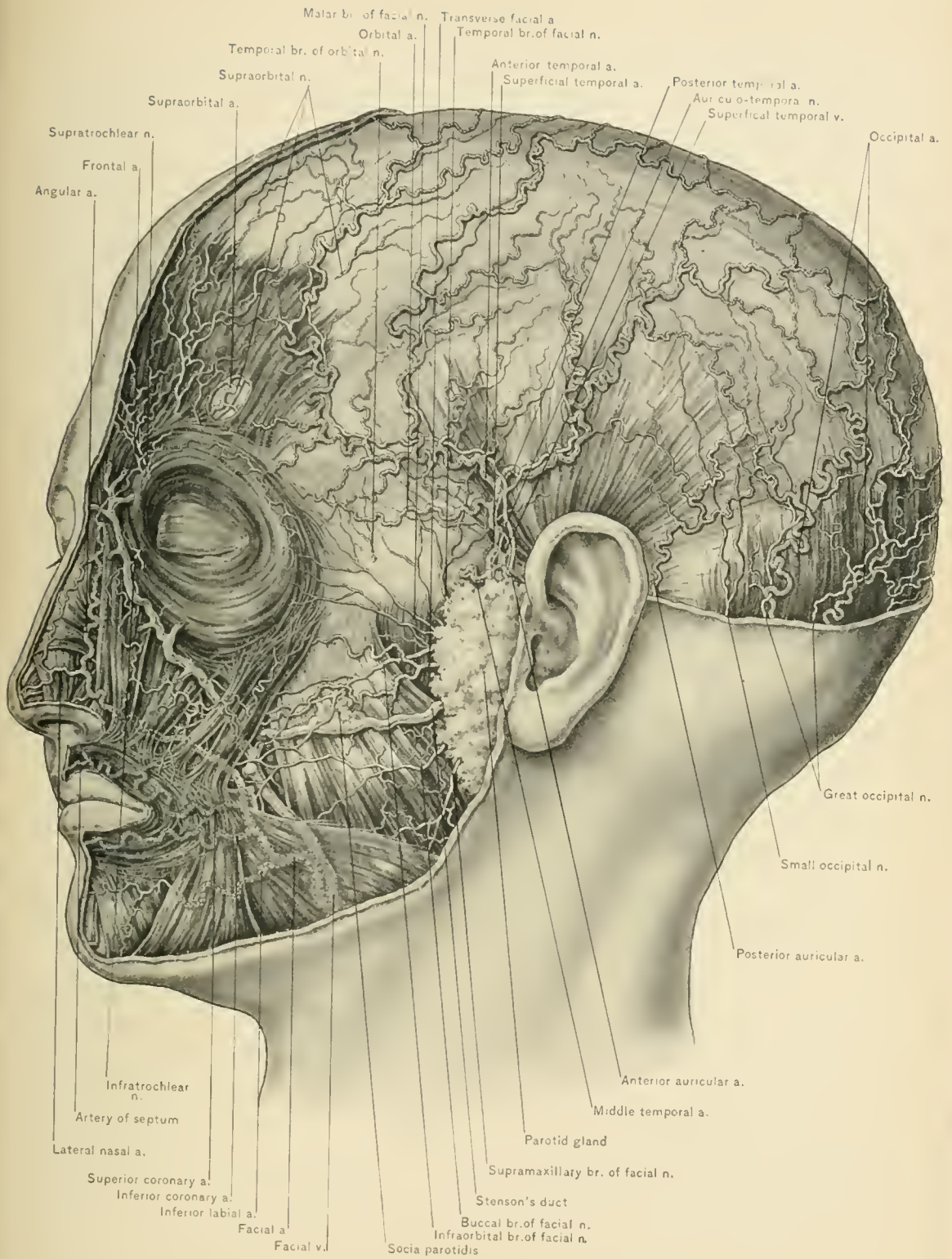
NERVE SUPPLY.—From the facial nerve. The long buccal nerve, a branch of the inferior maxillary, pierces the buccinator muscle on its way to supply the mucous membrane of the mouth.

ACTION.—The two buccinator muscles widen the aperture of the mouth transversely and contract and compress the cheeks so that during mastication the food will not remain between the cheeks and the teeth. When but one muscle acts, the angle of the mouth is drawn to that side, and the cheek is wrinkled; when whistling, the muscle contracts and prevents bulging of the cheeks.

It is hardly fair to the earnest dissector to leave this subject without the consoling reminder that the most expert dissectors can not bring out these muscles in the cadaver as they are shown in the anatomic plates. It must be remembered that some of the facial muscles belong to the panniculus carnosus group, so extensive in animals but so limited in man. In some faces the musculature is a complex network of subcutaneous fibers running in all directions. In a muscular subject a large number of distinct fasciculi are seen crossing one another, and more or less merged with the constant muscles of the face. This difference in the amount of facial musculature undoubtedly accounts for much of the variation in the amount of facial wrinkling observed in different persons. It is safe to say that a dissection of the muscles of the face with their boundaries as well defined as shown in pictures does more credit to the dissector's skill in imitating a diagram than to any painstaking effort to exhibit the natural state of the parts.

The **Facial Artery**, a branch of the external carotid, enters the face over the body of the lower jaw, at the anterior inferior angle of the masseter muscle, where its pulsation may readily be felt and it may be compressed against the bone. Thence it ascends forward across the cheek, over the buccinator muscle, and beneath the platysma myoides muscle, to the angle of the mouth; thence to the side of the nose, to terminate at the inner canthus of the eye as the angular artery. Where the artery passes over the lower jaw it is covered by the platysma myoides muscle and the deep fascia; near the mouth it passes beneath the zygomatici major and minor and the risorius muscle; and along the side of the nose it is usually covered by the levator labii superioris alaeque nasi. It rests successively on the lower jaw, the buccinator, and the levator anguli oris muscle. The companion vessel of the facial artery, the *facial vein*, runs in an almost straight line from the inner canthus of the eye to the anterior inferior angle of the masseter muscle, being in contact





ARTERIES, NERVES, AND MUSCLES OF SCALP AND FACE.

with the facial artery at these points, but elsewhere above and external to it. The artery is crossed by filaments of the facial nerve, while the levator labii superioris muscle separates it from the infra-orbital nerve behind.

Branches of the Facial Portion of the Facial Artery.—These are the muscular, inferior labial, inferior coronary, superior coronary, lateralis nasi, and angular.

The **muscular branches** are directed outward to supply the buccinator, masseter, and internal pterygoid muscles. They anastomose with the masseteric and buccal branches of the internal maxillary and with the infra-orbital and transverse facial arteries.

The **inferior labial artery** passes inward beneath the depressor anguli oris to supply the muscles and integument of the lower lip and chin. It anastomoses with the inferior coronary, the submental branch of the facial, and the mental branch of the inferior dental artery.

The **inferior coronary artery** arises, either independently or in common with the inferior labial, from the facial artery near the angle of the mouth. It passes forward and inward in a tortuous manner beneath the depressor anguli oris toward the angle of the mouth, then pierces the orbicularis oris, and continues between it and the mucous membrane along the free margin of the lower lip. It anastomoses with the inferior coronary artery of the opposite side, the inferior labial, and the mental branch of the inferior dental artery.

The **superior coronary artery**, which is larger and takes a more tortuous course than the inferior coronary, arises from the facial artery beneath the zygomaticus major muscle. It pierces the orbicularis oris, and runs between it and the mucous membrane along the free margin of the upper lip to anastomose with the artery of the opposite side. By the anastomosis of the superior and inferior coronary arteries with their fellows an arterial circle is formed, which surrounds the mouth and can be felt pulsating on the internal surface of the lips between one-fourth and one-half of an inch from the junction of the skin and the mucous membrane. A small branch to the ala nasi and numerous branches to the labial glands are given off from this circle.

The **artery of the septum of the nose** is a branch of the superior coronary. The twigs of this *arteria septum narium* are a common source of epistaxis (nose-bleed). The hemorrhage from the branches of this vessel is readily controlled by compression of the artery of the septum, either by direct backward pressure against the upper lip, or by pressure from within outward, as when a firm pledget of cotton, paper, or other substance is pushed well up under the lip so as to put its tissues upon the stretch and occlude the lumen of the artery. This is a common procedure practised by the laity. Another simple method is that of holding the cartilaginous end of the nose between the thumb and finger.

Harelip.—In the operation for harelip the bleeding can be controlled by grasping the lip between the thumb and forefinger. In introducing the harelip pin or suture, it must be passed deep enough to go beneath the divided coronary artery. Harelip is a congenital deformity consisting of one or more fissures in the upper lip, the result of arrested development. It may be single or double, the fissure or fissures being to the side of the median line of the lip, corresponding to the line of union between the intermaxillary and the superior maxillary bone. In double harelip the intermaxillary bone is often displaced forward. Double harelip is frequently associated with cleft palate.

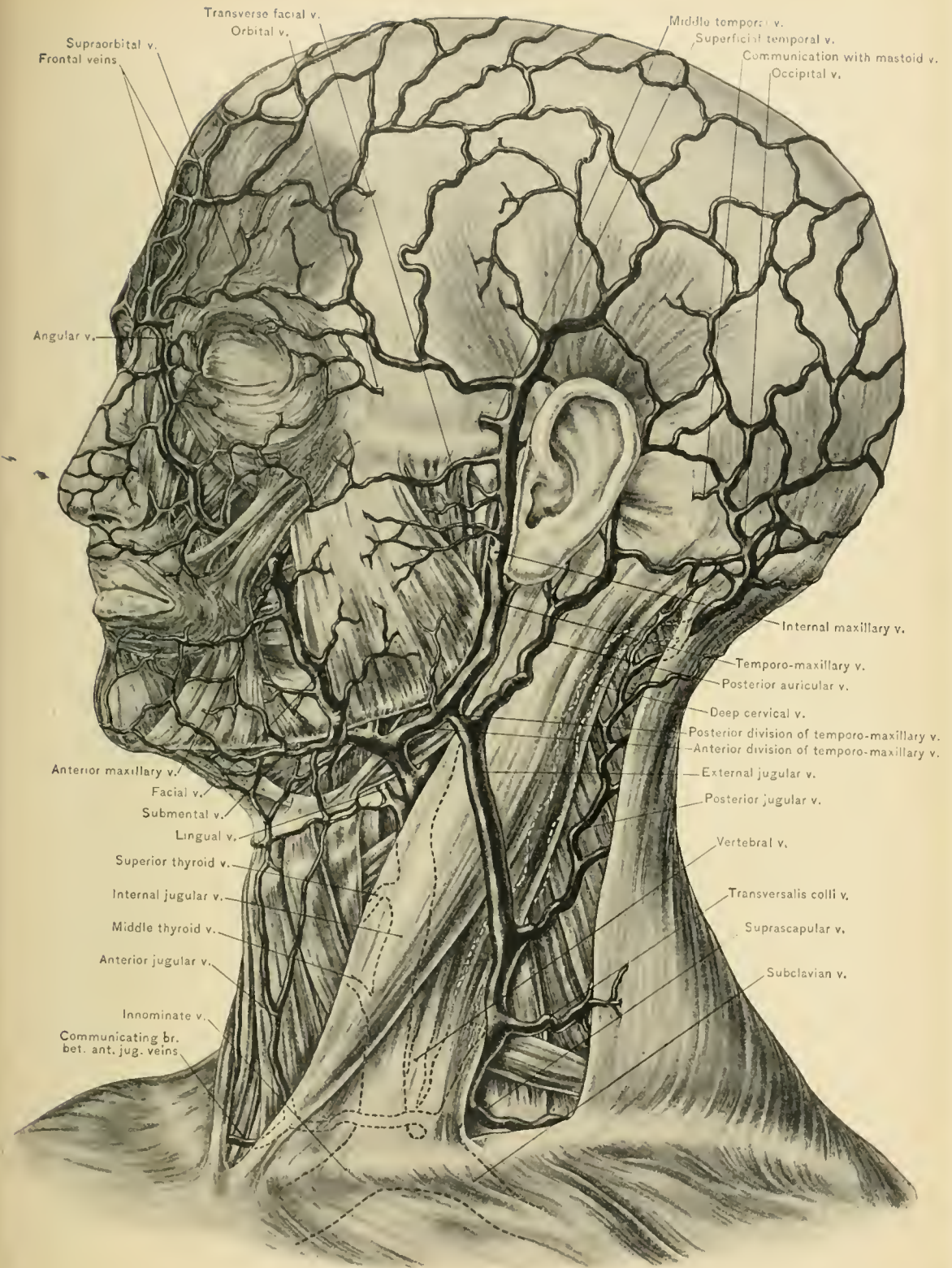
The **lateralis nasi artery** arises from the facial artery opposite the wing of the nose, and passes forward over the lower part of the nose and over the ala; it supplies the side and dorsum of the nose, and anastomoses with the lateralis nasi artery of the opposite side, the nasal branch of the ophthalmic, the infra-orbital, and the artery of the septum.

The **angular artery**, the terminal part of the facial, passes to the inner canthus of the eye, where it lies on the nasal side of the lacrymal sac and tendo oculi; it anastomoses with the nasal branch of the ophthalmic and with the infra-orbital artery, and supplies branches to the cheek. In opening an abscess of the lacrymal sac it is important to bear in mind the situation of this artery on the inner side of the sac.

Nervi molles.—The facial artery and its branches are surrounded by a minute plexus of sympathetic fibers (*nervi molles*) not demonstrable macroscopically. These fibers are branches of the superior cervical ganglion of the sympathetic, and supply the walls of the artery and its branches; they furnish the sympathetic root to the submaxillary ganglion.

Transverse facial artery.—Passing transversely across the face between the zygoma and the duct of the parotid gland, and resting upon the masseter muscle, is the transverse facial artery, which arises from the temporal artery in the substance of the parotid gland. It supplies the small, often detached, part of the parotid gland (the *socia parotidis*) in relation with the duct, the masseter and orbicularis palpebrarum muscles, and the integument. It anastomoses with the infra-orbital, facial, and masseteric arteries. It is accompanied by two or three branches of the facial nerve. It is quite small except when it supplies those parts which usually receive blood from the facial artery. It occasionally gives off the coronary and nasal arteries, the facial itself being small. It arises, at times, from the external carotid artery.

The **facial vein**, the continuation of the angular vein, and formed by the union of the frontal and supra-orbital veins, commences at the inner canthus of the eye and,



VEINS OF SCALP, FACE, AND NECK.

as already stated, runs in an almost straight line to the anterior inferior angle of the masseter muscle, where it comes into relation with the outer side of the facial artery. In its course across the face it lies above and to the outer side of the artery, passing over the levator labii superioris, beneath the zygomatic muscles, and over the parotid duct, the buccinator muscle, the anterior inferior angle of the masseter muscle and masseteric fascia, and the body of the lower jaw. Below the jaw it is joined by the anterior branch of the temporo-maxillary vein, and empties into the internal jugular vein. It receives veins from the lower eyelid (the inferior palpebral), from the side of the nose (the lateral nasal), from the orbital vein, and, beneath the zygomaticus major muscle, a branch (deep facial) from the pterygoid plexus, besides muscular branches and branches corresponding to those of the facial artery. The facial vein—through the angular, in which it commences—communicates freely with the ophthalmic vein, and thus with the cavernous sinus; and it also communicates with the cavernous sinus, through the deep facial vein with the pterygoid plexus of veins, which, in turn, communicates with the sinus by means of small veins which pass through the foramen ovale, the foramen of Vesalius, and the middle lacerated foramen. Owing to the free communication between the vein and the cavernous sinus, the latter is endangered by any inflammatory condition of the facial vein.

Disease involving the facial vein.—The facial vein, as a rule, has no valves; it will therefore be understood how emboli are readily carried to the internal jugular vein and thus into the general circulation. Carbuncle of the face may prove fatal by inducing thrombosis of the cerebral sinuses through the communications previously described. Any deep inflammation of the face, as phlegmonous erysipelas, may be complicated by thrombosis or pyemia. The injection of facial nevi in infants may result in death from thrombosis, owing to the direct communication of the facial with the internal jugular vein. Pulmonary embolism and death have followed the injection of perchlorid of iron for nevoid growths of the face. In arterio-venous aneurysm of the cavernous sinus arterial blood, through the ophthalmic and angular veins, flows through the facial vein and gives rise to a pulsating varicose condition of the latter vein and a distinct thrill and bruit.

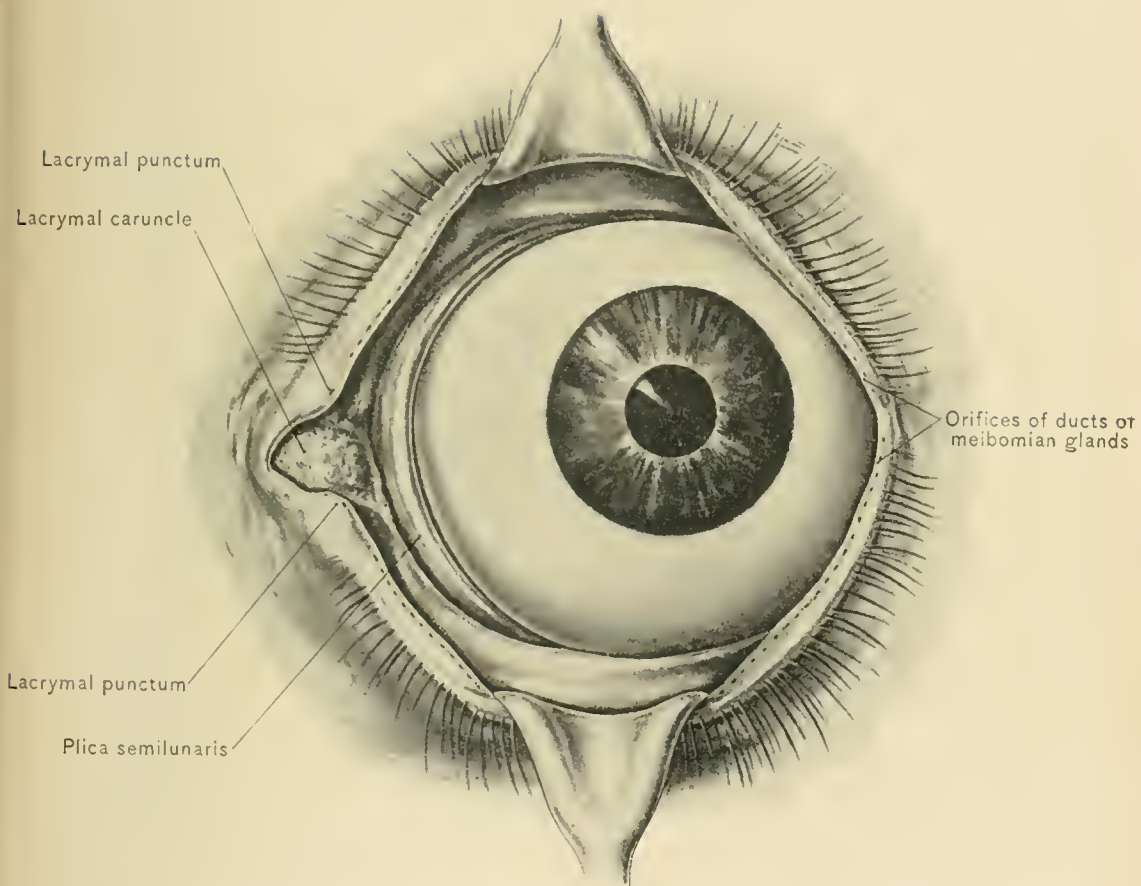
Vascularity of the face.—It has been demonstrated that the tissues of the face are very vascular. In persons exposed to cold, or in those addicted to strong drink, the very small vessels of the skin, especially over the nose, appear permanently injected or varicose. Attention has been called to the fact that nevi and various forms of erectile tumors are common about the face. Wounds of the face, while they bleed freely, heal very rapidly; their edges should be carefully adjusted as soon after the accident as possible. “Extensive flaps of

skin which have been torn up in lacerated wounds of the face often retain their vitality in almost as marked a manner as similar flaps torn from the scalp" (Treves). The anastomoses of the facial artery are so free that when the vessel is divided, both ends bleed freely and, according to the general rule, they should both be tied.

DISSECTION.—Upon the side of the face on which the muscles have been exposed the appendages of the eye,—including the eyelids, eyebrows, eyelashes, tarsal cartilages, conjunctiva, and lacrymal caruncle,—the parotid gland, and the external ear should be carefully dissected before turning the head to make the dissection of the nerves.

The **eyebrow** is a prominent arch of integument connected with the orbicularis palpebrarum, corrugator supercilii, and occipito-frontalis muscles. It is covered by numerous short, thick hairs which surmount the upper circumference of the orbit, their general direction being outward, though they interlace, the upper ones curving downward and the lower ones upward. They serve the two-fold purpose of acting as a shield against the admission of foreign bodies to the eye, and as a multiple spring buffer reducing somewhat the impact of blows against the brow, thus often preventing serious wounds of the skin from traumatism applied against the sharp supra-orbital margin.

The **eyelids** (palpebræ) are two movable semilunar curtains placed in front of each eyeball to protect that exceedingly delicate and important organ. Their free edges are transverse and are studded with hairs, called eyelashes. The upper lid is the longer, so that when the lids are closed, their margin of contact lies below the center of the eye. The upper lid is also more freely movable; it has a special muscle to raise it—the levator palpebræ superioris. The interval between the open eyelids is called the *fissura palpebrarum*, or interpalpebral slit. At the points of union of the eyelids are the *external and internal canthi*, or palpebral commissures. The internal canthus is the larger; within it is a triangular space containing a depression, the *lacus lacrymalis*, and an elevation, the *caruncula lacrymalis*. At their free margins, which are concave, the lids are thickest. At their inner extremities and upon their free surfaces are two small elevations—the *papilla lacrymalis*, in the center of which are small openings called the *puncta lacrymalia*, the orifices of the *lacrymal canaliculi*. The free margins are provided in front with eyelashes and with orifices of sebaceous and modified sweat glands; and, behind, with small openings—the orifices of the ducts of the Meibomian glands. That portion of the lids internal to the orifices of the lacrymal canaliculi is devoid of eyelashes and Meibomian glands. When the eyelids are closed, an interval exists between the lids and the eyeball for the inward passage of the tears. Inflammation of the ducts opening on the free



margin of the eyelid, which usually affects those on the anterior border, constitutes a styte.

The **eyelashes** (cilia) are two or more rows of short, thick, curved hairs, fixed in the anterior margin of the free border of the eyelids. They are longer and more numerous in the upper lid, and have their convexities directed downward, while those of the lower lid have their convexities directed upward. They protect the eye against the admission of dust and other foreign substances, especially during high winds.

The conjunctiva.—Before dissecting the eyelid, the conjunctiva and the lacrymal caruncle should be examined. The conjunctiva is the mucous membrane which covers the inner surface of the eyelids and the anterior part of the eyeball. At the free margin of the lids it is continuous with the integument. The part covering the eyeball is in relation with the sclerotic and the cornea. The conjunctiva consists of four divisions: the *palpebral*, the portion in relation with the eyelids; the *reflected*, the portion between the eyelids and the eyeball; the *sclerotic*, and the *corneal* portions. The lacrymal ducts (excretory ducts of the lacrymal gland) empty upon the free surface of the reflected portion of the conjunctiva. The palpebral portion is more vascular than the remaining parts, and is studded with a number of small papillæ, which, when enlarged by inflammation, constitute the disease known as granular lids, though this condition is at times also due to true granulations, which have a similar origin. The conjunctiva covering the sclerotic is loosely attached, and that covering the cornea is very thin, consisting merely of an epithelial layer which is very adherent. In congestion of the conjunctiva with effusion into the loose subconjunctival tissue (chemosis) the membrane is at times swollen to the very edge of the cornea, where it then forms a sharp elevated margin.

The **caruncula lachrymalis** is a small, reddish elevation situated at the inner canthus in the lacus lachrymalis. It consists of a separated portion of skin, which presents minute hairs upon its surface. It contains connective tissue, a small number of plain and striated muscular fibers and modified sweat glands, as well as a few sebaceous glands. External to the caruncle, and resting upon the eyeball, is a vertical triangular fold of conjunctiva, with its free concave margin directed toward the cornea; this is called the *plica semilunaris*, and is a rudimentary membrana nictitans (the third eyelid in birds). Müller found smooth muscular fibers in this fold, and in some of the domestic animals a thin plate of cartilage has been discovered in it (Gray).

As previously stated, the conjunctiva is continuous with the skin at the free borders of the lids. It is also continuous, through the lacrymal canaliculi, with the mucous membrane lining the lacrymal sac, the nasal duct, and the

inferior meatus of the nose. In the loose subconjunctival tissue there are not infrequently seen, especially in elderly persons, small yellowish masses of fat, called pingueculæ.

In post-conjunctival operations, as in section of the ocular muscles, the conjunctiva must be cut. Its lax attachment to the sclera is now of advantage, for a loose fold is readily raised with the forceps and incised to the required extent, after which it is with ample facility peeled back as far as necessary.

The **eyelids** are composed of the skin, subcutaneous tissue, orbicularis palpebrarum muscle, palpebral ligaments, orbito-tarsal ligaments, the tarsal cartilages, Meibomian glands, vessels, and nerves, and conjunctiva. The upper lid contains, in addition to the structures just mentioned, the aponeurotic insertion of the levator palpebræ superioris muscle. The skin of the lids and the orbicularis palpebrarum muscle have already been described.

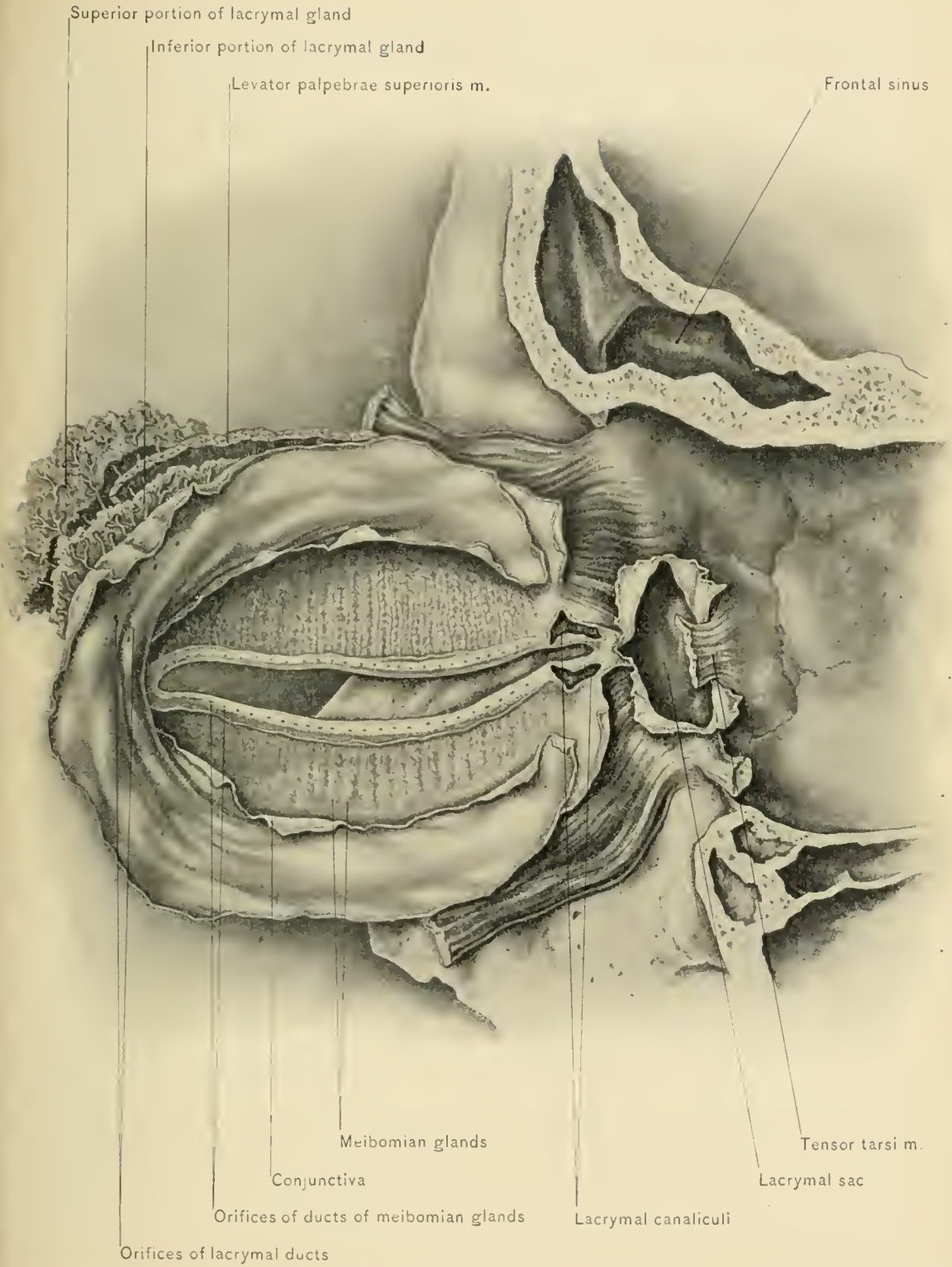
The **subcutaneous areolar tissue** of the eyelids contains no fat. Its laxity accounts for the extensive ecchymosis after comparatively slight traumatism, and for the early appearance of puffiness of the eyelids in chronic Bright's disease.

The **palpebral ligaments** are fibrous bands attaching the tarsal cartilages to the outer and inner margins of the orbit. The external ligament is undivided and extends from the malar bone to the outer extremities of the tarsal cartilages. The internal ligament (*tendo oculi*) extends from the nasal process of the superior maxilla and the crest of the lacrymal bone to the internal extremities of the tarsal cartilages. The division of the *tendo oculi* which is attached to the nasal process of the superior maxilla passes in front of the lacrymal sac, while the limb attached to the crest of the lacrymal bone passes over its outer wall.

The **orbito-tarsal ligaments** (palpebral fasciæ) are fibrous membranes continuous with the periosteum, and extend from the superior and inferior orbital margins to the tarsal cartilages. In the upper lid the orbito-tarsal ligament fuses with the tendon of the levator palpebræ superioris muscle. These ligaments prevent pus in the subcutaneous areolar tissue from making its way into the orbit, and hence are called the *septa orbitale*.

The **tarsal cartilages**, situated in the free margins of the eyelids, are two plates of dense connective tissue. They are thickest at their free, or ciliary, margins, and give support and shape to the eyelids. The cartilage of the upper lid is much larger than that of the lower, and gives attachment to the aponeurosis of the levator palpebræ superioris muscle. In both lids the attached margins of the tarsal cartilages are continuous with the orbito-tarsal ligaments.

The **Meibomian glands** are sebaceous glands lodged in the substance of the tarsal cartilages, and number between twenty and thirty in the upper and somewhat less in the lower lid. The orifices of the glands open on the free borders of



LACRYMAL APPARATUS AND MEIBOMIAN GLANDS.

the lids behind the lashes. Each gland consists of a straight tube with many short, blind, diverticula. The Meibomian glands secrete a sebaceous material which prevents the lids from adhering, and are readily distinguished as closely adjacent, vertical, parallel, yellow streaks across the inner surface of the lids. When the duct of one of these glands becomes occluded, a retention cyst, similar to a wen, is formed.

Non-striated muscular fibers are found in both lids. In the upper lid these fibers originate from the lower surface of the levator palpebræ superioris; in the lower lid they arise from the vicinity of the inferior oblique muscle. In both lids they are inserted close to the attached border of the tarsal cartilage. They are known as the superior and inferior palpebral muscles of Müller.

BLOOD SUPPLY.—The eyelids receive their blood supply from the palpebral and lacrymal branches of the ophthalmic artery and from small branches of the temporal and transverse facial arteries. The palpebral branches of the ophthalmic, two in number, arise from that artery near the pulley of the superior oblique muscle; one is found in each lid and runs through the fibrous tissue layer of the lids between the orbicularis palpebrarum muscle and the tarsal cartilages near their margins. The lacrymal is the first branch of the ophthalmic artery. It accompanies the lacrymal nerve and gives off palpebral twigs which anastomose with the other palpebral arteries to form the tarsal arches.

The *veins of the eyelids* are larger than the arteries, and outnumber them. They empty into the frontal and angular veins at the inner canthus, and into the orbital vein at the outer canthus. Some of the veins of the lids pass between and through the bundles of fibers of the orbicularis palpebrarum, and hence in many inflammatory conditions of the conjunctiva and cornea in children, in which prolonged spasm of this muscle occurs, the lids are very apt to become edematous, from interference with the venous flow (Fucho).

NERVE SUPPLY.—The nerve supply is free. The nerves to the palpebral portion of the orbicularis palpebrarum muscle arise from the facial nerve and enter the lids near the outer canthus. The cutaneous filaments of the upper lid are obtained from the lacrymal, supra-orbital, and supra-trochlear nerve, and the lower lid derives its supply from the infra-orbital and infra-trochlear nerves. The non-striated muscular tissue of the lids is supplied by the sympathetic nerve.

The *lymphatics of the eyelids* pass to the parotid and submaxillary lymph glands.

The **conjunctiva** has been described.

The **levator palpebræ superioris muscle** arises from the under surface of the lesser wing of the sphenoid bone above the optic foramen; its fibers terminate

in a broad, thin aponeurosis which is inserted into the upper border of the superior tarsal cartilage. This muscle runs above the superior rectus, and its upper surface is in relation with the frontal nerve and the supra-orbital artery.

The **parotid gland**, the largest of the salivary glands, weighs from one-half to one ounce. It is situated on the side of the face, and extends as high as the zygoma and below the level of the angle of the lower jaw. It covers about one-third of the masseter muscle, and extends backward to the external auditory meatus, the mastoid process, and the sterno-mastoid muscle. It is lodged in the space between the ramus of the lower jaw and the mastoid process. This space—known also as the bed of the parotid gland—can be increased in size by extending, and diminished by flexing, the head. With the mouth wide open—in which position the angle of the jaw is carried backward and the condyle forward—the width of the space is diminished below, but increased above. The size of the space is influenced by the age of the individual. In the infant, owing to the obliquity of the ramus and the absence of the angle of the lower jaw, it is broader, in proportion, below. In advanced age, when the teeth have fallen out, thus allowing the angle of the lower jaw to project forward, the space is broader below. When operating in this space these facts should be kept in mind, as it may be necessary to take advantage of them. The gland has three large processes or lobes: one, the *glenoid lobe*, extends upward into the posterior part of the glenoid cavity of the temporal bone which it occupies; another, the *pterygoid lobe*, extends forward beneath the ramus of the lower jaw, between the external and internal pterygoid muscles; the third process, the *carotid lobe*, passes behind the styloid process and beneath the mastoid process and the sterno-mastoid muscle, coming in contact with the internal jugular vein and the internal carotid artery. From the relation which the carotid lobe holds to the internal jugular vein, it follows that swelling of the gland, as in mumps, may cause passive congestion of the brain by compression of that vein. The anterior margin of the parotid gland overlaps the masseter muscle, and a detached portion of the gland (*socia parotidis*) lies over that muscle in relation with the upper border of Stenson's duct. From the position which the parotid gland holds with reference to the temporo-maxillary articulation it follows that, in inflammation of the gland, movement of the articulation is attended by pain; the extent to which the lower jaw can be depressed under these circumstances is dependent upon the amount of swelling.

Parotid fascia.—The parotid gland is covered by a dense and strong layer of fascia—a prolongation of the superficial layer of the deep cervical fascia, and called the parotid fascia. It is attached above to the zygoma, and is continuous in front with the fascia covering the masseter muscle. From the parotid fascia numerous processes are sent into the substance of the gland to support its lobules.

The deep fascia of the neck also sends beneath the gland a process continuous with the stylo-maxillary ligament, which separates the parotid from the submaxillary gland. The fibrous envelop of the parotid gland is incomplete above and in front, where its cavity is in communication with the pterygo-maxillary region. In parotid abscess the pus may, on account of this gap in the fascial envelop, extend into the pterygo-maxillary region, and by way of the latter into the temporal fossa, or to the side of the pharynx, meeting with less resistance in taking either of these directions than in attempting to reach the surface. The abscess may, however, extend into the neck by ulcerating through the layer of fascia beneath the gland. Many cases of retro-pharyngeal abscess are attended by swelling in the parotid region. Retro-pharyngeal growths—as, for example, sarcomata, when they have attained any size—cause bulging of the parotid region; and, conversely, tumors of the parotid may bulge into the pharynx. The severe pain in a rapidly growing tumor or abscess of the gland is due to the density of the fascia covering it. This, too, makes it difficult to detect fluctuation early. It also explains why the pus in a parotid abscess is so slow to find its way to the surface, and why an early opening should be made. The intimate relation existing between the parotid gland, the external auditory meatus, and the temporo-maxillary articulation is to be borne in mind, as a parotid abscess may open into the meatus or cause involvement of the joint.

Purulent meningitis and thrombosis of the cranial sinuses may be caused when pus finds its way through the foramina at the base of the skull.

The **sensory nerves** supplying the parotid gland are the auriculo-temporal branch of the inferior maxillary nerve, the great auricular branch of the cervical plexus, the facial nerve, and branches from the carotid plexus of the sympathetic nerve. In painful affections of the gland the pain is apt to be referred to the areas of distribution of these nerves.

The parotid lymphatic glands.—Lying upon the surface of the parotid gland (in front of the cartilage of the ear, and close to the root of the zygoma) are one or more superficial lymphatic glands, enlargement of which must not be mistaken for a similar condition of the parotid gland itself.

Contents of the parotid gland.—The parotid gland is important, not only on account of its function, of the position which it occupies, and of the relation it bears to the surrounding parts, but also because important structures are found in it. These structures are, from without inward: The facial nerve, passing from behind forward; the temporo-maxillary, superficial temporal, internal maxillary, and posterior auricular veins; the commencement of the external jugular vein; the external carotid artery which supplies branches to the gland and divides at the neck of the lower jaw into its two terminal branches—the temporal and internal

maxillary arteries; the terminal part of the great auricular nerve; and one or two lymphatic glands. The posterior auricular branch of the external carotid artery and the transverse facial branch of the temporal artery arise in the substance of the gland.

The parotid gland is separated from the internal carotid artery, from the internal jugular vein, and from the pneumogastric, glosso-pharyngeal, and hypoglossal nerves by a thin layer of fascia; therefore in stab wounds of the parotid region involving one of the two carotid arteries it may be difficult, at first, to tell which of the two vessels has been wounded.

From an anatomic point of view it is difficult to see how complete removal of the parotid gland is possible, yet the operation has been done so many times by skilful surgeons that there is no question of its feasibility. Doubtless, as long ago suggested by Führer, when the gland becomes the site of a neoplasm it becomes more compact, its processes being rounded off, as it were, and lifted away from the surrounding structures.

Complete removal of the parotid gland results in paralysis of the muscles of expression, for it is impossible to avoid dividing the facial nerve. The author has seen a growth of the overlying lymphatic gland cause facial paralysis from pressure, and thus so closely simulate a parotid neoplasm as to be pronounced a tumor of the parotid gland; but upon the removal of the growth the parotid gland was seen to occupy the bottom of the wound, and to be in a very much atrophied condition.

Socia parotidis.—That portion of the parotid gland resting upon the masseter muscle above the parotid duct (Stenson's duct), and quite separate from the gland proper, is known as the socia parotidis. Its duct empties into Stenson's duct.

Stenson's duct.—Running about one finger's breadth below the zygoma, or in a line drawn from the lower margin of the concha to a point midway between the free margin of the upper lip and the ala of the nose, is the duct of the parotid (Stenson's duct). It is about two inches in length by one-eighth of an inch in diameter, being narrowest at its point of communication with the mouth. It lies between the transverse facial artery above and the buccal branch of the facial nerve below. The duct runs over the masseter muscle, turning abruptly inward at its anterior border, passes through the mass of fat overlying the buccinator muscle and beneath the facial vein, and pierces the buccinator muscle to open into the mouth opposite the crown of the second molar tooth of the upper jaw. The turn of the duct around the anterior border of the masseter muscle must be borne in mind when passing a probe into the duct from the mouth. In opening a parotid abscess the incision should be horizontal, and should be made below the line of the duct and in front of the posterior border of the ramus of the lower jaw. Failure to observe this caution may result in section of the duct, with

resulting fistula (salivary fistula). It is also advisable to take every precaution against cutting through the gland tissue in opening a parotid abscess, for these collections of pus, like those of the mammæ, generally affect the connective tissue of the gland and not its substance or parenchyma.

Stenson's duct may be divided into a masseteric and a buccal portion. The *masseteric portion* rests upon the masseter muscle and the *buccal part* extends from the anterior border of the masseter muscle to the termination of the duct in the mucous membrane of the cheek. Fistulæ of the masseteric part are closed with difficulty, whereas fistulæ of the buccal portion are remedied by making an opening from the duct into the mouth on the proximal side of the fistula. The author has successfully treated fistulæ of the buccal portion by exposing the duct through an incision in the cheek, dividing the duct at the proximal side of the fistula, freeing the duct from the surrounding tissues, and stitching the divided end to the margins of an opening made in the mucous membrane of the mouth.

DISSECTION.—Before turning over the head to make the dissection of the opposite side of the face, the parotid gland should be removed entire; this operation will convey an approximate idea of the difficulties which would attend the removal of the gland in the living subject. The masseter muscle should then be exposed and the external ear dissected. In exposing the parotid gland, its fascial covering is seen to be continuous anteriorly with the fascia covering the masseter muscle, and, therefore, the parotid and masseteric fasciæ are practically one. These fasciæ are derived from the superficial layer of the deep cervical fascia, which is continued upward over the body of the lower jaw and attached above to the zygoma. By displacing the parotid gland forward and removing the fascia covering that portion of the masseter muscle in advance of the gland, the muscle itself is exposed.

The **masseter**, the most superficial of the muscles of mastication, is of quadrate form, and arises as two portions—a large, tendinous, superficial layer, and a small, fleshy, deep layer. The superficial sheet arises from the anterior two-thirds of the lower border of the zygomatic arch and from the lower border of the malar bone; its fibers pass downward and backward to be inserted into the outer surface of the angle and lower portion of the ramus of the lower jaw. The deep sheet arises from the posterior third of the lower border and all of the inner surface of the zygoma; it passes downward and forward to be inserted into the upper half of the ramus and the outer surface of the coronoid process of the lower jaw. The posterior portion of the muscle is concealed by the parotid gland. In relation with the superficial surface of the muscle are the orbicularis palpebrarum, the zygomatici major and minor, and the platysma myoides muscle, the anterior margin of the parotid gland, Stenson's duct, the transverse facial vessels, branches of the facial nerve, and, at its anterior inferior angle, the facial vein. In relation

with its deep surface are the buccal pad of fat, the buccinator and a small part of the temporal muscle, the masseteric artery and nerve, and the ramus of the jaw.

BLOOD SUPPLY.—From the masseteric branch of the internal maxillary, the transverse facial, and the facial artery.

NERVE SUPPLY.—From the masseteric nerve, a branch of the inferior maxillary division of the trifacial nerve.

ACTION.—It raises the lower jaw, as in mastication.

The **External Ear** consists of the pinna, or auricle, and of the tube leading to the tympanic membrane—the external auditory canal. The pinna collects the vibrations of sound, and the canal conveys them to the tympanum.

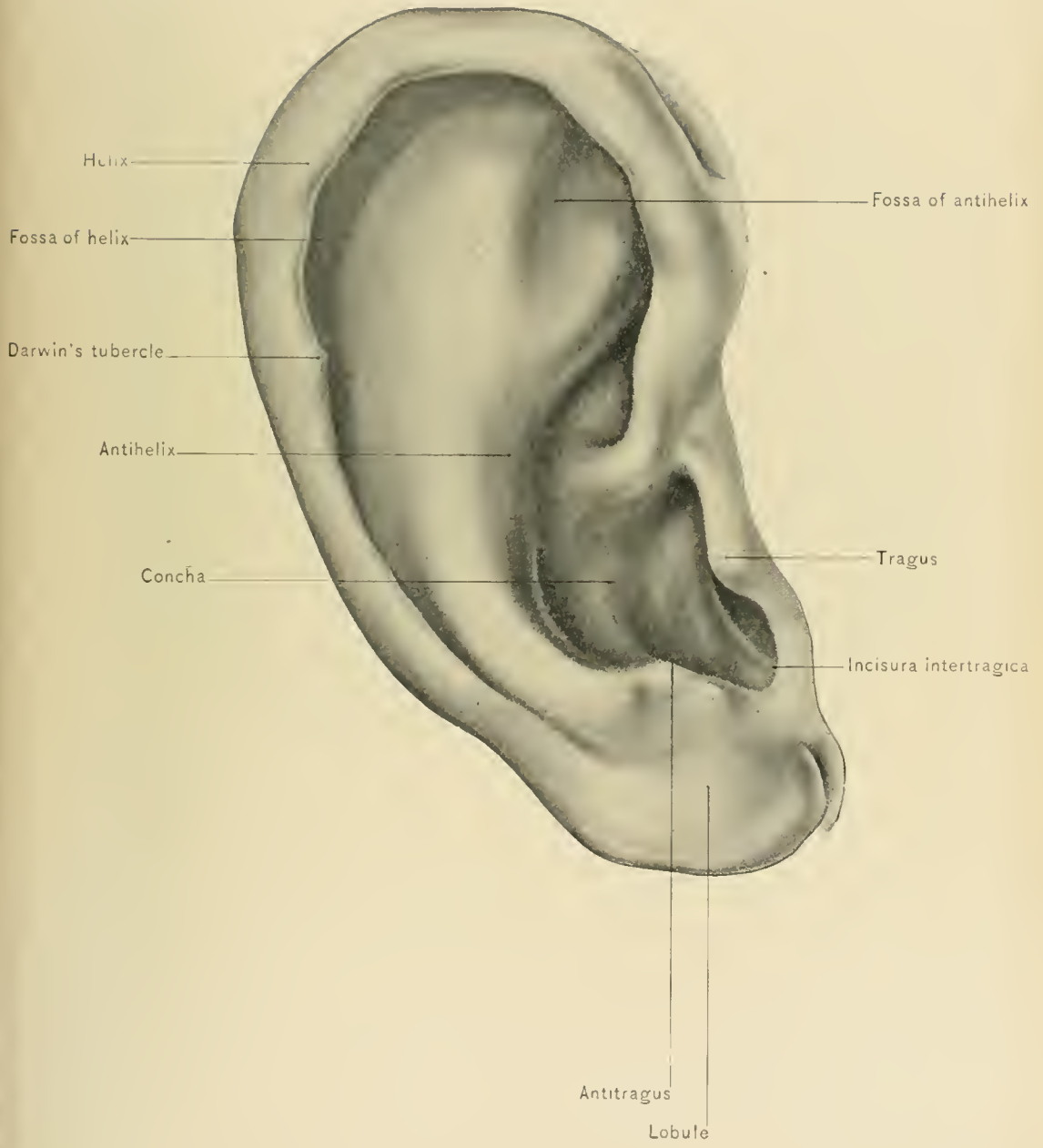
The **pinna, or auricle**, is pyriform in shape, with its concave surface directed outward and slightly forward, and consists of a layer of yellow fibro-cartilage having an uneven surface covered with integument. It is attached to the commencement of the external auditory meatus, and consists of various elevations and depressions, each elevation having a corresponding depression on its opposite surface. The deep hollow in its center, which is wide above and narrow below, is called the *concha*. The concha leads to the commencement of the external auditory meatus, and is partly divided into two by the beginning of the helix. The *helix* passes upward, forms the rim of the pinna, and terminates behind in the *lobule*, which is the lowest portion of the auricle and consists of fatty and areolar tissue. Internal to the helix is the depression called the *fossa of the helix*, or *scaphoid fossa*. Internal to the fossa of the helix is the ridge bounding the concha behind and above. This ridge is called the *anthelix*; it begins above the lobule, at a small prominence, the *antitragus*, and bifurcates at the upper part of the auricle, embracing a small triangular depression—the *fossa of the anthelix*. In front of the concha and projecting backward over the orifice of the external auditory meatus is the *tragus*. Between the tragus and antitragus is a notch—the *incisura intertragica*.

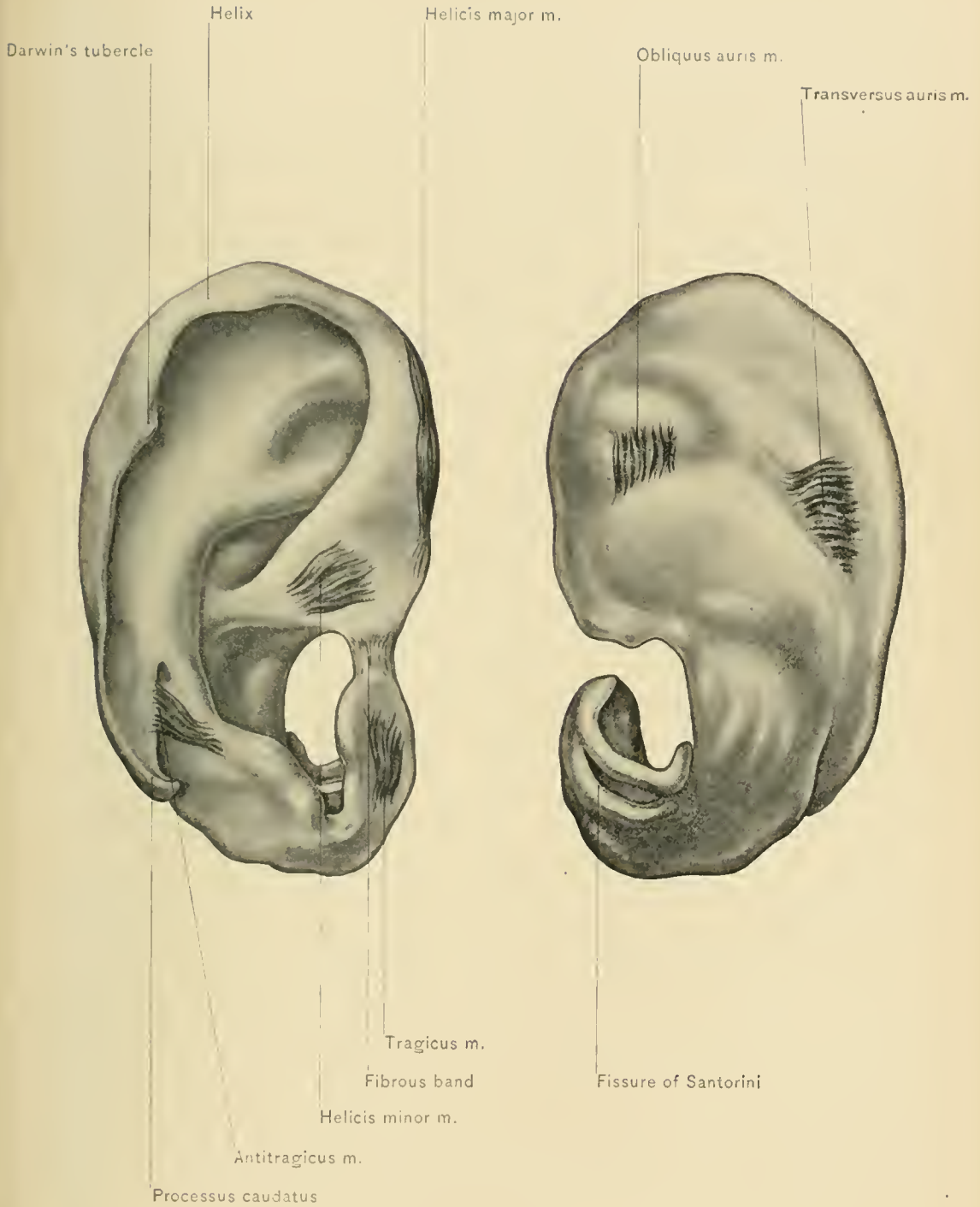
DISSECTION.—The integument should be removed from the pinna, when the small and rudimentary muscles and the cartilage will be exposed.

The integument of the pinna is thin and delicate. It contains sebaceous glands which are largest in the concha, and here the ducts of the glands often become filled with foreign matter, giving rise to the so-called comedones.

Upon the posterior aspect of the auricle the integument is less firmly attached to the underlying parts than elsewhere, consequently inflammatory swellings, as in erysipelas, are most marked in this situation.

Extravasations of blood beneath the skin are not uncommonly seen as the result of blows upon the ear; these so-called othematomata have been most often observed in insane persons and in prize-fighters. According to Virchow and





Ludwig Meyer, degenerative changes in the blood-vessels and cartilage favor the occurrence of such extravasations. Cicatricial contractions may cause deformity of the pinna after the absorption or evacuation of such hematmata. Under the integument of the lobule gouty deposits (tophi) are sometimes found.

The **Muscles** which move the cartilage of the ear as a whole, three in number, have been described under the dissection of the scalp. The muscles proper of the auricle, which extend from one part of the cartilage to another, are six in number—namely, the muscle of the tragus, the muscle of the antitragus, the small muscle of the helix, the large muscle of the helix, the transverse muscle of the auricle, and the oblique muscle of the auricle.

The **tragicus**, the muscle of the tragus, is situated upon the outer surface of the tragus.

The **antitragicus**, the muscle of the antitragus, arises from the outer part of the antitragus; its fibers pass upward and are inserted into the posterior extremity of the helix.

The **helicis minor**, the small muscle of the helix, is attached to the commencement of the helix and extends into the concha. This muscle is sometimes absent.

The **helicis major**, the large muscle of the helix, is situated upon the anterior margin of the helix; it arises above the small muscle and is inserted into the front of the helix, where it begins to curve backward.

The **transversus auris**, the transverse muscle of the auricle, is situated on the back of the auricle in the depression between the helix and the convexity of the concha; it arises from the convexity of the concha and is inserted into the back of the helix.

The **obliquus auris**, the oblique muscle of the auricle, extends from the upper back part of the concha to the convexity immediately above it.

NERVE SUPPLY.—The pinna derives its nerve supply from the auriculo-temporal, the posterior auricular, the auricular branch of the pneumogastric (Arnold's nerve), the occipitalis minor, and the auricularis magnus nerve.

ACTION.—The muscles of the helix assist those of the tragus and antitragus in retarding the passage of sound to the meatus.

BLOOD SUPPLY.—The pinna is well supplied with freely anastomosing vessels—branches of the posterior auricular, temporal, and occipital arteries. The veins accompany the corresponding arteries.

The numerous *lymphatics* empty into the pre-auricular glands and into those situated upon the insertion of the sterno-mastoid muscle.

The **cartilage of the pinna** is a single piece, and presents the irregularities characteristic of the external ear. It is prolonged inward in the shape of a tube

which forms the outer part of the external auditory meatus; it is wanting between the tragus and the commencement of the helix, the interval between them being occupied by fibrous tissue. Where the helix makes its first bend, at the front part of the pinna, is a conic projection of the cartilage—the process of the helix. At the highest part of the helix there is not infrequently to be seen another conic projection, to which Darwin first called attention; he regards it as the representative of the extreme tip of the pinna of some of the lower animals. At certain places the cartilage is incomplete; these gaps are known as fissures, and are located as follows: at the anterior part of the pinna, behind the process of the helix (fissure of the helix); on the surface of the tragus; and at the lower part of the anthelix. In the piece of cartilage which forms the outer part of the meatus are two fissures—the *fissures of Santorini*. The pinna is attached anteriorly to the root of the zygoma and posteriorly to the mastoid process by bands of fibrous tissue; in addition, there are various intrinsic ligaments, uniting the different parts.

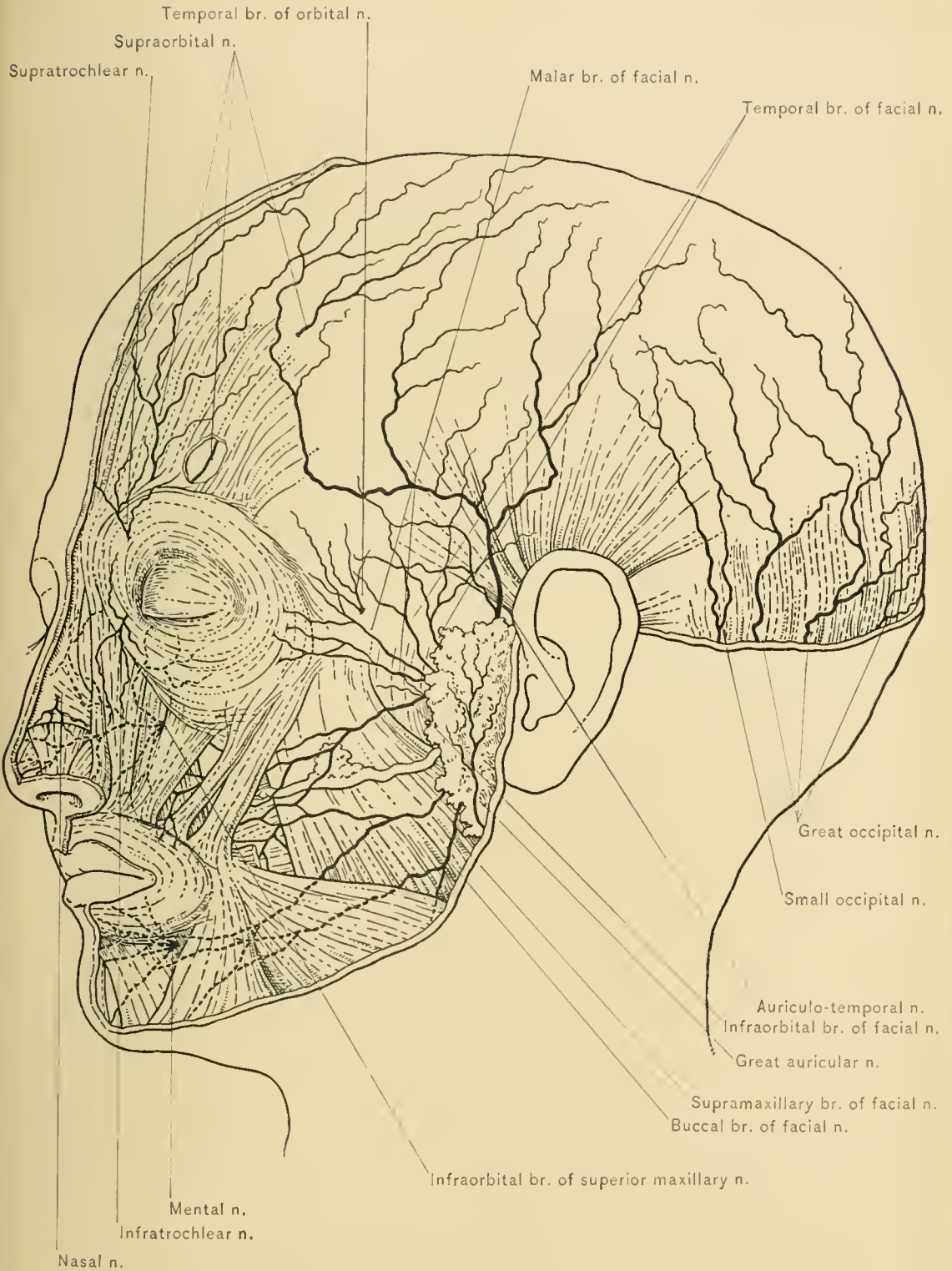
DISSECTION.—Turn the head to the opposite side, fix it with hooks, and work out the facial nerve and the branches of the trifacial nerve which make their exit upon the face. Expose the facial nerve by a longitudinal incision carried into the substance of the parotid gland in front of the lobe of the ear, cutting away a little of the gland with each movement of the knife until the nerve is seen, when it can be traced both backward and forward.

The **facial nerve** (the seventh cranial) is the motor nerve of the face; it consists of three portions—the intra-cranial, the temporal, and the facial. The facial portion, that which concerns us in this dissection, supplies all the muscles of expression and the platysma, the buccinator, the occipito-frontalis, the attrahens, attolens, and retrahens aurem, the posterior belly of the digastric, and the stylo-hyoid.

A line drawn from the anterior border of the mastoid process opposite the base of the lobule of the ear downward and forward across the face for about one inch will represent the course of the facial portion of the trunk of the nerve.

COURSE.—It leaves the cranial cavity through the internal auditory meatus in company with the auditory nerve, the *pars intermedia* of Wrisberg, and the auditory artery. Reaching the bottom of the internal auditory meatus it enters the facial canal, or aqueductus Fallopii of the temporal bone, from which it makes its exit by way of the stylo-mastoid foramen. Passing downward and forward from the foramen it enters the parotid gland, crosses the external carotid artery, gives off a posterior auricular, a digastric, and a stylo-hyoid branch, and terminates in two divisions—the temporo-facial and the cervico-facial.

The **posterior auricular nerve**, the first extra-cranial branch, passes upward in the groove between the ear and the mastoid process, communicates with the



NERVES OF SCALP AND FACIAL NERVE.

auricular branch of the pneumogastric and the great auricular branch of the cervical plexus, and divides into an auricular and an occipital branch. The auricular branch supplies the *attolens* and *retrahens aurem* muscles. The occipital branch passes along the superior curved line of the occipital bone, supplies the *occipitalis* muscle, and communicates with the small occipital branch of the cervical plexus.

The **digastric branch** supplies the posterior belly of the digastric muscle, and communicates, by a twig which usually perforates that muscle, with the glosso-pharyngeal nerve.

The **stylo-hyoid branch** is longer than the digastric; it enters the stylo-hyoid muscle about its middle, and communicates with filaments of the sympathetic nerve on the external carotid artery.

The **temporo-facial**, the larger of the two terminal divisions, runs obliquely upward and forward through the substance of the parotid gland, crosses the external carotid artery and the temporo-maxillary vein, and breaks up into the temporal, malar, and infra-orbital branches. It communicates with the auriculo-temporal nerve. The *temporal branches* ascend obliquely over the zygomatic arch to supply the *tensor tarsi*, the *orbicularis palpebrarum*, the *corrugator supercilii*, the *frontalis*, and the *attolens* and *atrahens aurem* muscles, and to communicate with the supra-orbital, the lacrymal, and the auriculo-temporal nerve, and with the temporo-malar branch of the superior maxillary nerve.

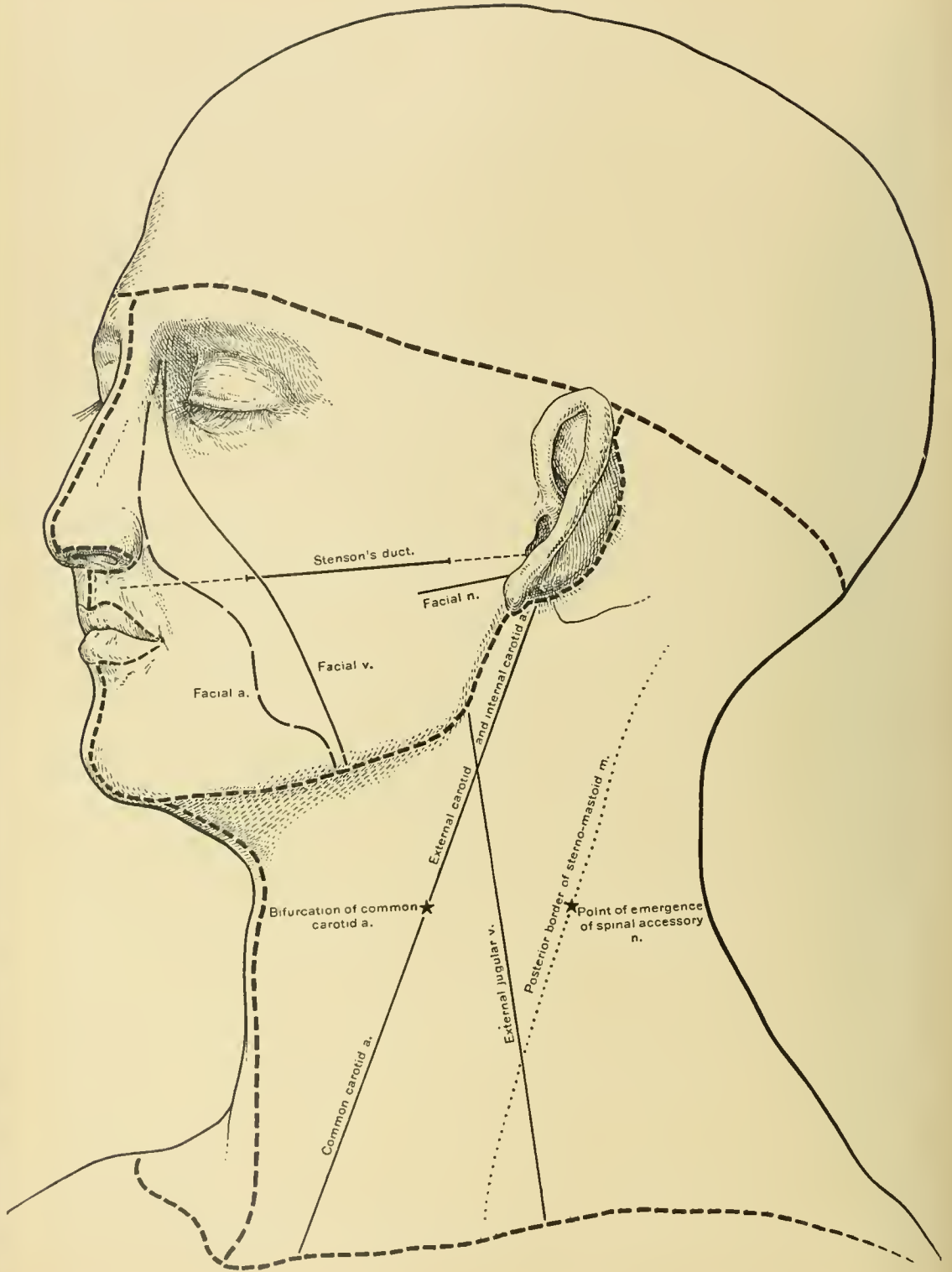
The *malar branches* run across the malar bone to the outer angle of the orbit to supply the *orbicularis palpebrarum* muscle, and communicate with the lacrymal and the supra-orbital nerve and with the infra-orbital and temporo-malar branches of the superior maxillary nerve. The *infra-orbital*, the largest branch, gives off a superficial and a deep set of branches, which pass transversely forward over the *masseter* and beneath the zygomatic muscles to supply the zygomatic muscles, the elevators of the upper lip, the muscles of the nose, and the *orbicularis oris* muscle. The superficial branches communicate with the nasal and infra-trochlear nerves which are derived from the ophthalmic division of the trifacial nerve. The deep branches form a loop with the buccal branch of the cervico-facial division, and pass beneath the *levator labii superioris* muscle, where they unite with the infra-orbital branch of the superior maxillary nerve, forming the *infra-orbital plexus*.

The **cervico-facial**, the smaller of the two terminal divisions of the facial nerve, is joined by a branch of the great auricular nerve while in the substance of the parotid gland. It passes obliquely downward toward the angle of the lower jaw, crosses the external carotid artery and the temporo-maxillary vein, and divides into buccal, supra-maxillary, and infra-maxillary branches. The *buccal branches*

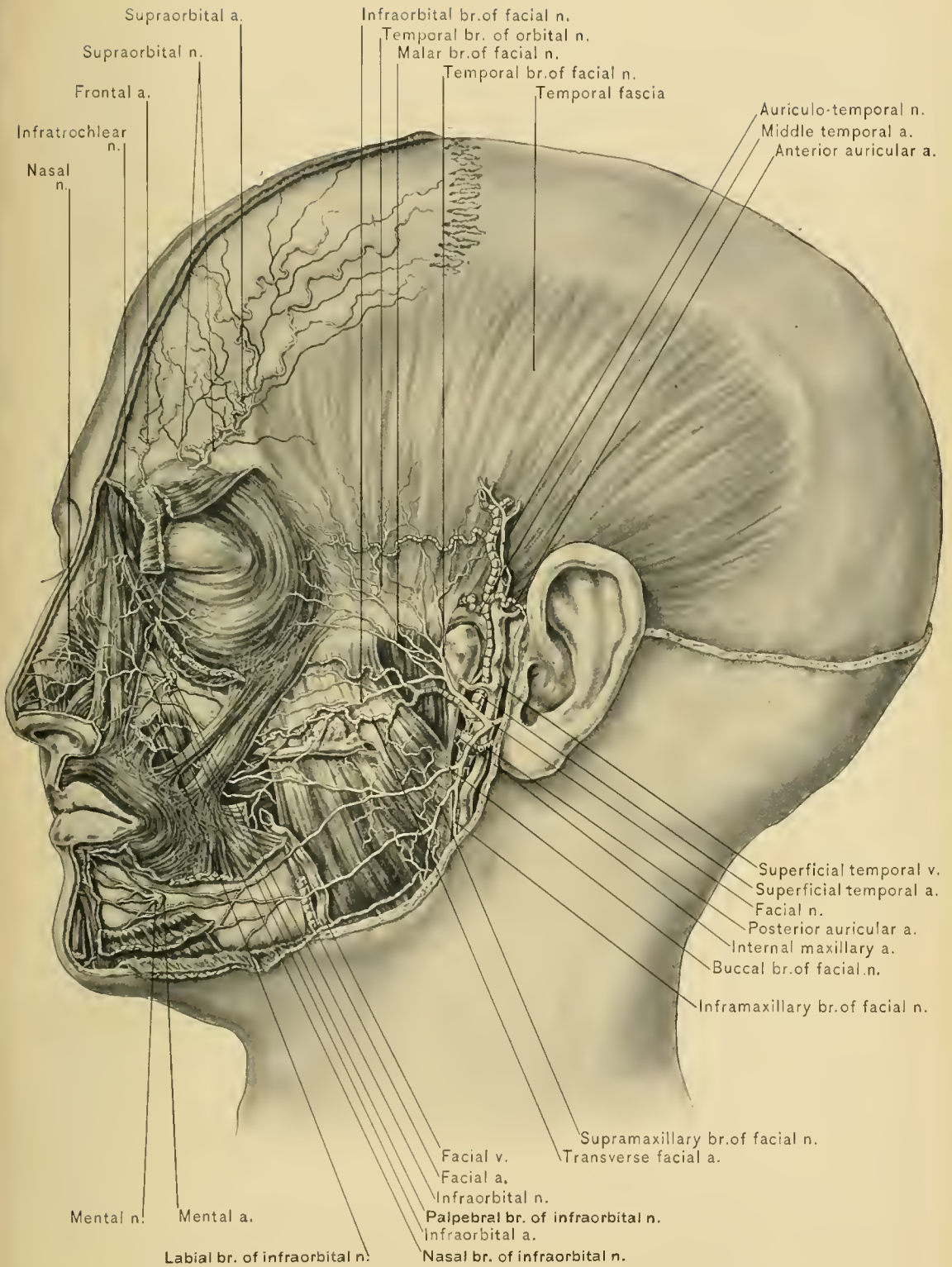
pass forward over the masseter and buccinator muscles below Stenson's duct, to the angle of the mouth, to supply the buccinator and orbicularis oris muscles, and communicate with the infra-orbital nerve, the infra-orbital branches of the temporo-facial branch, and the long buccal branch of the inferior maxillary nerve. The buccal branch of the facial nerve and the long buccal branch of the inferior maxillary nerve form a plexus over the buccinator muscle and the facial vein. The *supra-maxillary branch* passes downward and forward over the masseter muscle and the facial artery, and beneath the platysma myoides and the depressor muscles of the lower lip. It supplies the muscles of the lower lip, the risorius, and the levator menti, and communicates with the buccal branch of the facial and the mental branch of the inferior dental nerve. The *infra-maxillary branch* emerges from the lower border of the parotid gland in front of the external jugular vein and passes downward and forward toward the sternum beneath the platysma myoides muscle, which it supplies. It communicates with the great auricular and superficial cervical nerves—branches of the cervical plexus. The infra-maxillary branch can be traced when dissecting the superficial fascia of the neck.

The **pes anserinus** (plexus parotideus).—The breaking up of the two terminal divisions of the facial nerve within the substance of the parotid gland gives rise to a plexus, the pes anserinus (goose's foot).

Bell's palsy.—Paralysis of the facial nerve is known as Bell's palsy, and may be either central or peripheral. A central paralysis is due to involvement of the nucleus of the nerve, its center in the cortex of the brain, or the fibers connecting these, and results from pressure, as by hemorrhage, abscess, or tumor; it may also be brought about by degenerative processes in the brain. A peripheral paralysis is due to affection of the trunk of the nerve within the cranial cavity by tumors or meningitis; within the facial or Fallopian canal, by middle ear disease or fracture of the base of the skull; external to the stylo-mastoid foramen, by a growth at the stylo-mastoid foramen, rapidly growing tumors or abscess of the parotid gland, division during an operation, or exposure of the face to cold. When the lesion is situated beyond the origin of the chorda tympani nerve the muscles of expression and the buccinator muscle on the same side of the face become paralyzed, the mouth is drawn to the opposite side, and the affected side of the face becomes flattened and free from wrinkles. Through paralysis of the orbicularis palpebrarum muscle the eye on the paralyzed side remains open, and the tears run down the cheek. The anterior naris of the affected side is smaller in appearance through paralysis of the nasal muscles. Paralysis of the buccinator muscle causes the food to collect between the cheek and the teeth of the affected side. Through paralysis of the orbicularis oris muscle the saliva dribbles from the mouth, and the patient can not whistle. When the lesion is situated in the aqueductus Fallopii



OPERATION FOR EXPOSURE OF FACIAL NERVE.



TEMPORAL FASCIA AND NERVES OF FACE.

and above the origin of the chorda tympani nerve, there is loss of the sense of taste in the anterior two-thirds of the tongue on the diseased side, and through paralysis of the stapedius muscle loud sounds are distressing. When the lesion is central or in the brain, the brow and eyelid are not affected—*i. e.*, the frontalis, corrugator supercilii, and orbicularis palpebrarum muscles are not involved. This is probably due to escape of the fibers which arise from the nucleus of the opposite side.

Spasms, both tonic and clonic, of the muscles supplied by the facial nerve may occur. Persistent spasm of these muscles is relieved by stretching the facial nerve.

Operative exposure of the facial nerve.—The facial nerve is exposed by carrying a vertical incision from in front of the mastoid process and behind the lobule of the ear downward toward the angle of the lower jaw, laying bare first the posterior border of the parotid gland, which is displaced forward, and then the anterior border of the sterno-mastoid muscle at its insertion. The parotid gland should be separated from the mastoid process to the depth of about one centimeter, when the nerve may be seen. The exact location of the nerve in the wound can be ascertained by the use of the faradic battery.

The trifacial nerve.—The branches of the trifacial or fifth nerve which make their exit upon the face are the supra-orbital and the supra-trochlear (previously described), the lacrymal, the infra-orbital, the malar, the anterior branch of the nasal, and the mental nerve.

The **lacrymal nerve**, the smallest of the ophthalmic branches, supplies the lacrymal gland, and frequently communicates with the temporal branch of the temporo-malar nerve in the orbit; it sends a small filament—the palpebral—to the skin and conjunctiva around the outer canthus of the eye.

The **infra-orbital nerve**, the terminal branch of the superior maxillary division of the trifacial nerve, emerges from the infra-orbital foramen in company with the infra-orbital artery, under cover of the levator labii superioris muscle. It immediately divides into palpebral, nasal, and labial branches. The *palpebral branches*, the smallest, pass upward beneath the orbicularis palpebrarum muscle, supply the lower eyelid, and communicate with the facial and the malar branch of the orbital or temporo-malar nerve. The *nasal branches*, three or four in number, pass inward under the levator labii superioris alaeque nasi muscle to supply the side of the nose, and communicate with the external (naso-labial) branch of the nasal nerve. The *labial branches*, usually four, are larger than the palpebral or nasal branches, and descend beneath the levator labii superioris muscle to supply the upper lip. Beneath the levator labii superioris the branches assist in forming the infra-orbital plexus. (See description of plexus under Facial Nerve.)

The **infra-orbital artery**, a branch of the internal maxillary, accompanies the infra-orbital nerve through the infra-orbital foramen, and divides into branches which are distributed like those of the nerve. It anastomoses with the transverse facial, facial, and ophthalmic arteries.

The **infra-orbital vein** communicates with the facial vein in front, and empties into the pterygoid plexus of veins.

The **malar division** of the orbital or temporo-malar branch of the superior maxillary nerve makes its exit through a foramen in the malar bone, pierces the orbicularis palpebrarum muscle, and supplies the skin of the cheek covering the malar bone. It communicates with the facial and the palpebral branches of the infra-orbital nerve.

The **external or terminal branch of the nasal nerve**, also known as the naso-labial, emerges between the nasal bone and the lateral cartilages of the nose, supplying the tip of the nose as it descends beneath the compressor narium muscle. It communicates with the infra-orbital branches of the facial and trifacial nerves.

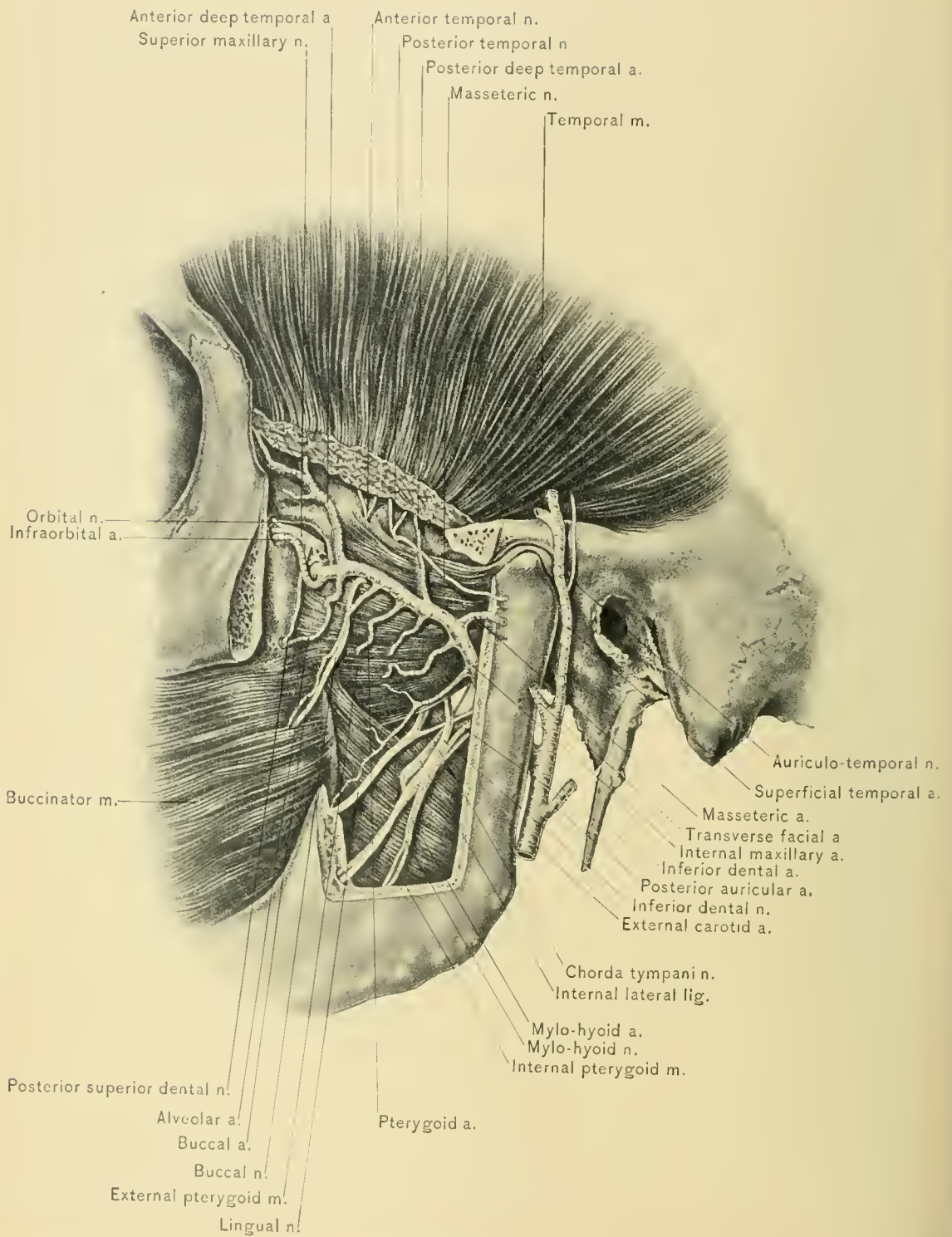
The **mental nerve**, the continuation of the inferior dental, emerges from the mental foramen in company with the mental artery. It divides beneath the depressor anguli oris muscle into three branches, the smallest of which descends to supply the chin, while the other two ascend to supply the lower lip. It inosculates with the supra-maxillary branch of the facial nerve.

The **mental artery**, the terminal portion of the inferior dental, supplies the chin and anastomoses with the submental, inferior labial, and inferior coronary arteries.

PTERYGO-MAXILLARY REGION.

The pterygo-maxillary region is the space included between the ramus of the lower jaw, externally; the lateral wall of the pharynx and the pterygoid process of the sphenoid bone, internally; the zygomatic surface of the superior maxilla, anteriorly; and the lower surface of the greater wing of the sphenoid and the adjacent temporal bone, above. The posterior limit of the space is represented by a plane passing directly inward from the posterior border of the ramus of the inferior maxilla to the pharynx.

DISSECTION.—The zygomatic arch should be removed by sawing through the zygomatic processes of both the malar and temporal bones. In the latter, the point selected should be just in front of the tubercle of the zygoma. Reflect the masseter muscle from the ramus of the inferior maxilla, carrying the zygoma with it; locate the masseteric artery and nerve which pass through the sigmoid notch of the lower jaw; trace them into the masseter muscle as far as possible, and then sever them. A portion of the ramus of the lower jaw should be



PTERYGOID MUSCLES AND INTERNAL MAXILLARY ARTERY.

removed in the following manner: With Hey's saw cut downward behind the last molar tooth, half way through the body of the jaw, then backward to near the angle. Discard the saw when it reaches the cancellous tissue, and use the chisel to avoid division of the inferior dental vessels and nerve. The saw should now be directed downward from the sigmoid notch, just in front of the neck of the jaw, through the ramus to the end of the incision in the body of the bone. The removal of this portion of the inferior maxilla is tedious, as the internal pterygoid muscle, internal lateral ligament, and the inferior dental vessels and nerve oppose elevation of the section of bone thus separated. Remove the posterior inferior corner of the section of the ramus with bone forceps as far as the inferior dental canal, which contains the inferior dental vessels and nerve; then reflect the bone with the lower portion of the temporal muscle, taking care to avoid destroying the mylo-hyoid artery and nerve which arise from the inferior dental artery and nerve, near the inferior dental foramen, and pass downward and forward in a groove on the internal surface of the ramus. In making this dissection it is advisable to use the back of the point of the scalpel, as the vessels and nerves are small, of delicate structure, and are easily severed.

The **contents of the pterygo-maxillary region** are the internal and external pterygoid muscles, the internal maxillary artery with some of its branches and their companion veins, the pterygoid plexus of veins, the inferior maxillary nerve, and the following branches of that nerve: The anterior and posterior deep temporal, long buccal, masseteric, internal and external pterygoid, inferior dental, auriculo-temporal, and lingual nerves, the chorda tympani nerve, a portion of the parotid gland, the internal lateral ligament of the lower jaw, and the internal maxillary lymphatic glands.

The **internal maxillary artery**, which is closely related to the nerves of this region, passes forward either over or behind the external pterygoid muscle.

The **internal lateral ligament** is a thin, fibrous band which lies beneath the inferior dental vessels and nerve; it passes, with the lingual and inferior dental nerves, through the triangular interval between the two pterygoid muscles and the incised edge of the jaw.

The **external pterygoid muscle**, the more superficial of the two pterygoids, arises by an upper head from that portion of the greater wing of the sphenoid bone situated between the pterygoid ridge and the foramina ovale and spinosum; by a lower head from the outer surface of the external pterygoid plate of the sphenoid bone, from the tuberosities of the palate and superior maxillary bones. Its fibers pass horizontally backward and converge for insertion into the inter-articular fibro-cartilage of the temporo-maxillary joint superiorly, and inferiorly into the anterior portion of the inner surface of the neck of the inferior maxilla.

It is related, externally, with the ramus of the inferior maxilla, the temporal and masseter muscles, the superficial portion of the internal pterygoid muscle, the internal maxillary artery, the anterior and posterior deep temporal arteries, and the buccal artery and nerve. Internally, it is in relation with the deep part of the internal pterygoid muscle, the middle meningeal artery, and the inferior maxillary nerve, the internal lateral ligament of the lower jaw, the lingual and inferior dental nerves, which emerge from beneath its lower border; the long buccal nerve, which runs between its two heads; the chorda tympani nerve, and the anterior and posterior deep temporal and masseteric nerves, which pass out from beneath the upper border of the muscle.

BLOOD SUPPLY.—From the external pterygoid branches of the internal maxillary artery.

NERVE SUPPLY.—From the inferior maxillary nerve.

ACTION.—The external pterygoid muscles acting together pull the lower jaw forward; alternately, they move it forward and laterally; and, singly, forward and to the opposite side. They are muscles of trituration.

The **internal pterygoid muscle** (the internal masseter) arises by two heads, a superficial and a deep. The superficial, the smaller, arises from the lower and back part of the tuberosity of the upper jaw, and the outer side of the tuberosity of the palate bone. The deep lies behind the lower head of the external pterygoid and arises from the internal surface of the external pterygoid plate, and from the grooved portion of the tuberosity of the palate bone situated in the pterygoid fossa. These two heads unite at the lower margin of the external pterygoid muscle, and thence extend downward, backward, and outward for insertion into the rough inner surface of the posterior portion of the ramus of the lower jaw included between the angle and the inferior dental foramen.

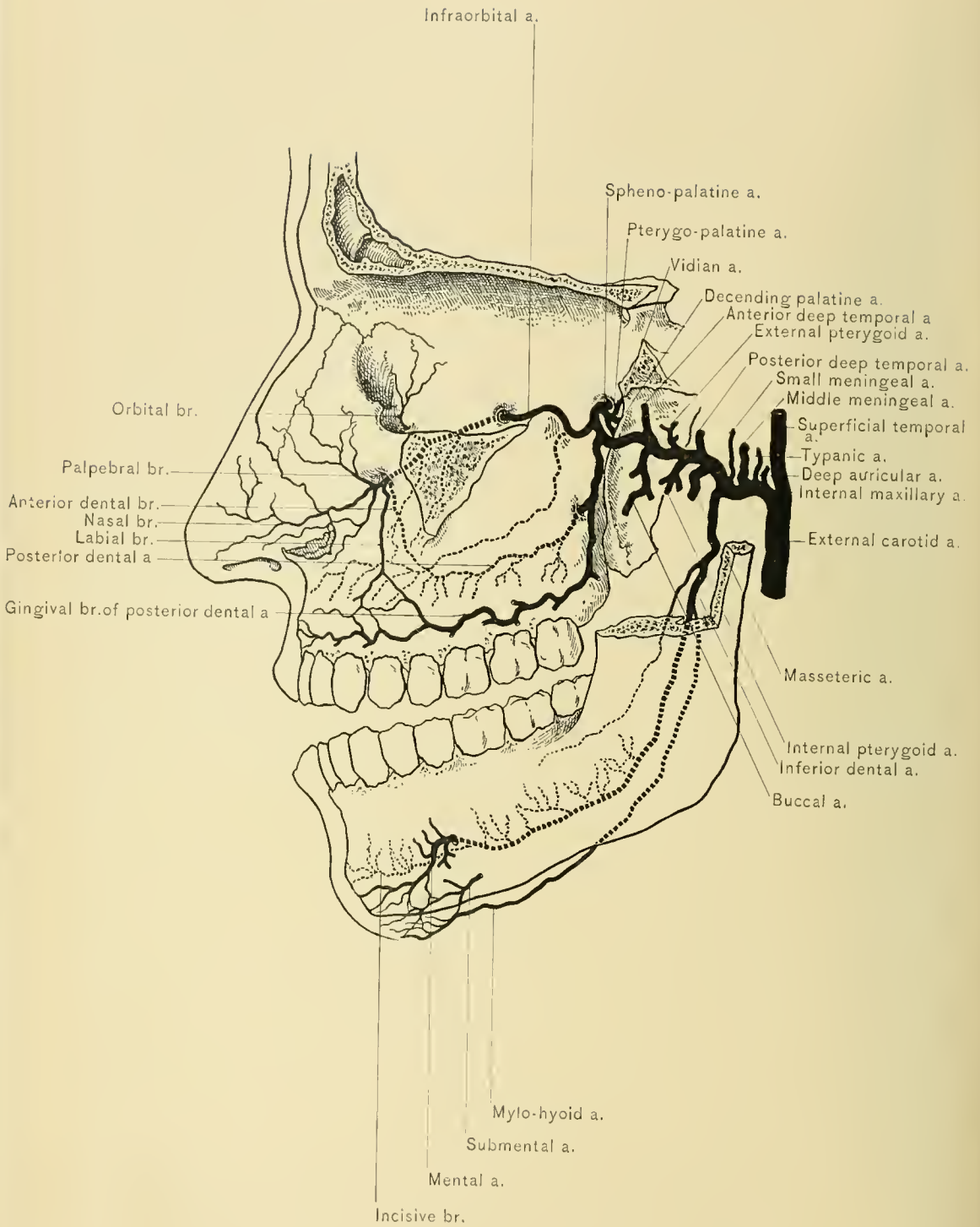
It is related, externally, with the ramus of the lower jaw, the external pterygoid muscle, the internal lateral ligament of the lower jaw, the lingual or gustatory nerve, and inferior dental and mylo-hyoid vessels and nerves; internally, with the tensor palati, stylo-glossus, stylo-hyoid, posterior belly of the digastric, and the superior constrictor muscle of the pharynx.

BLOOD SUPPLY.—From the mylo-hyoid and internal pterygoid branches of the internal maxillary artery.

NERVE SUPPLY.—From the internal pterygoid branch of the inferior maxillary nerve.

ACTION.—Both internal pterygoid muscles acting together draw the lower jaw upward and forward; and, singly, upward and to the opposite side.

The **internal maxillary artery**, the larger of the two terminal branches of the external carotid, arises in the parotid gland, opposite to or slightly lower than



INTERNAL MAXILLARY ARTERY AND BRANCHES.

the neck of the lower jaw. The artery is divided into three portions: maxillary, pterygoid, and spheno-maxillary. The *first or maxillary portion* passes forward between the internal lateral ligament and the neck of the lower jaw, and reaches the lower margin of the external pterygoid muscle. The *second or pterygoid portion* extends obliquely upward and forward upon the outer surface of the external pterygoid muscle, and is hidden by the insertion of the temporal muscle. The *third or spheno-maxillary portion* lies in the spheno-maxillary fossa. In some instances the second or pterygoid portion runs entirely beneath the external pterygoid muscle, but, by passing between the two heads of that muscle, appears upon the outer surface of the muscle just before entering the spheno-maxillary fossa.

The *branches of the first or maxillary portion of the internal maxillary artery* are: The deep auricular, tympanic, middle meningeal, small meningeal, and inferior dental arteries.

The *deep auricular artery* pierces the wall of the external auditory canal to supply the tympanic membrane.

The *tympanic artery* passes behind the temporo-maxillary joint through the Glaserian fissure to supply the tympanum.

The *middle meningeal artery* runs upward between the two roots of the auriculo-temporal nerve to the foramen spinosum, through which it enters the cranial cavity to supply the cranium and dura mater.

The *small meningeal artery* ascends to the foramen ovale, through which, after supplying a twig to the nasal fossa and soft palate, it enters the cranial cavity.

The *inferior dental artery*, with its venæ comites, accompanies the inferior dental nerve and passes downward, upon the internal pterygoid muscle and the internal lateral ligament, entering the inferior dental foramen together with the inferior dental nerve. The artery then occupies the inferior dental canal, distributing branches to the teeth; it supplies an incisive branch, and emerges, on the face, from the mental foramen; it is then called the *mental artery*; the mental artery is accompanied by the mental nerve, and is distributed to the structures of the chin and lower lip. Before entering the inferior dental canal the inferior dental artery gives off the *mylo-hyoid artery*, which accompanies the mylo-hyoid nerve.

The *branches of the second or pterygoid portion* are the anterior and posterior deep temporal, internal and external pterygoid, and the masseteric and buccal arteries.

The *anterior and posterior deep temporal arteries* pass upward through the corresponding parts of the temporal fossa, between the temporal muscle and the pericranium, which they supply.

The *pterygoid arteries*, varying in number, supply the external and internal pterygoid muscles.

The *masseteric artery*, with the masseteric nerve, passes outward behind the temporal muscle through the sigmoid notch of the lower jaw to the masseter muscle.

The *buccal artery* accompanies the long buccal nerve in its forward course between the ramus of the lower jaw and the external pterygoid to the buccinator muscle.

The *branches of the third or spheno-maxillary portion* are the alveolar, infra-orbital, posterior or descending palatine, Vidian, pterygo-palatine, and naso-palatine or spheno-palatine arteries.

The *alveolar (posterior superior dental or posterior dental) artery* gives off branches to the gums and the buccinator muscle, enters the superior maxilla at its zygomatic surface, and supplies the molar and bicuspid teeth and the mucous lining of the maxillary sinus or antrum of Highmore.

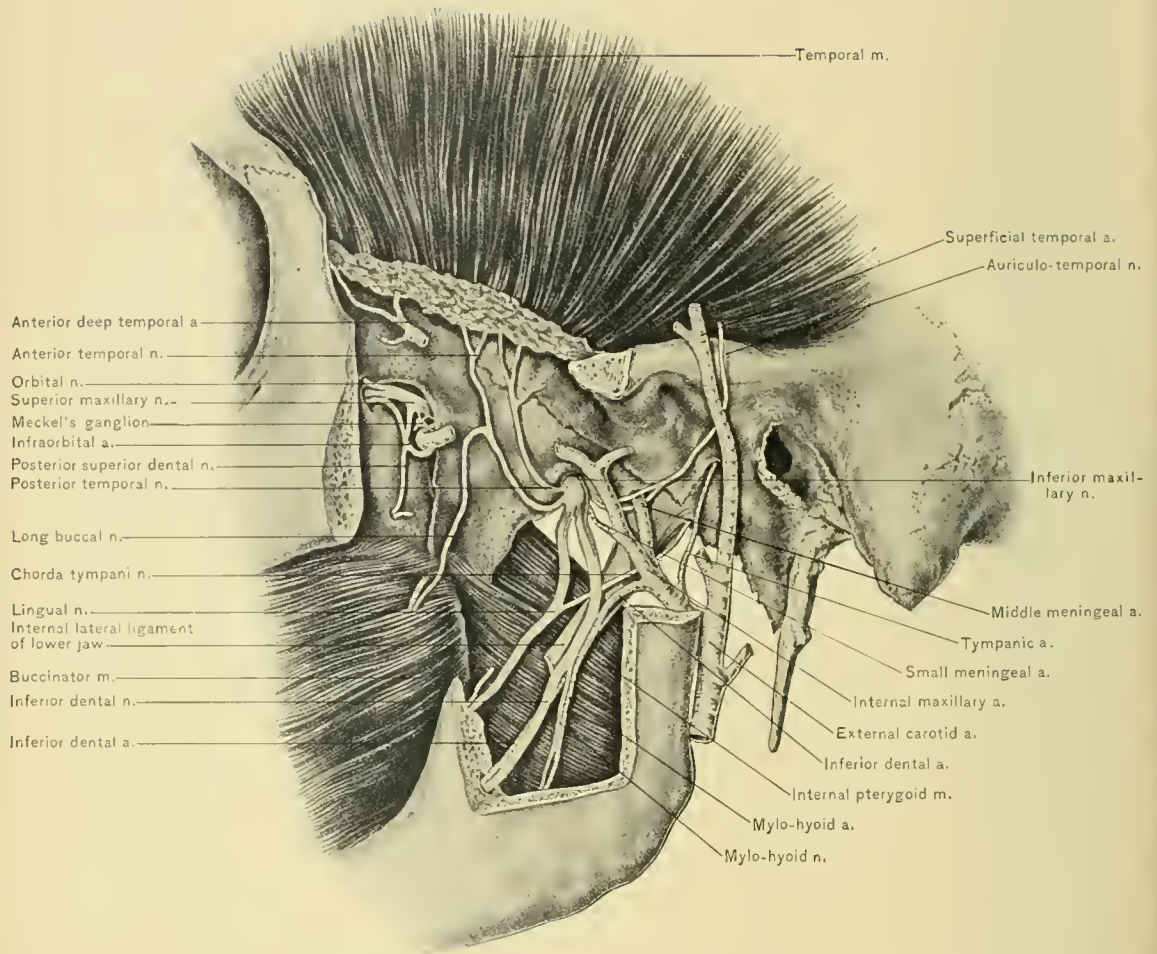
The *infra-orbital artery* immediately enters the infra-orbital groove and canal, accompanied by the superior maxillary division of the fifth pair of cranial nerves, and eventually emerges upon the face in company with the infra-orbital nerve at the infra-orbital foramen. It supplies branches to the orbit, and gives off an *anterior superior dental branch*, which runs downward in the anterior wall of the maxillary sinus and supplies the incisor and bicuspid teeth and the mucous membrane of the maxillary sinus.

The *posterior or descending palatine artery* accompanies the posterior palatine branches of Meckel's or the spheno-palatine ganglion of the fifth pair of cranial nerves, through the posterior palatine canal, then emerges from the posterior palatine foramen, and passes forward in a groove situated near the alveolar process along the under surface of the hard palate; it next enters the foramen of Stenson, a subdivision of the anterior palatine foramen, and anastomoses with the naso-palatine artery. It is distributed to the hard and soft palate, palatine glands, and gums.

The *Vidian artery* runs backward with the Vidian nerve through the Vidian canal to supply the uppermost part of the pharynx, the Eustachian tube, and the tympanum.

The *pterygo-palatine artery*, which is very small, passes backward with the pharyngeal nerve through the pterygo-palatine canal to supply the upper pharynx, the sphenoid cells, and the Eustachian tube.

The *naso-palatine or spheno-palatine*, the terminal artery, runs inward through the naso-palatine or spheno-palatine foramen into the superior meatus of the nose. It crosses the roof of this meatus between the mucous membrane and the bone to



INFERIOR MAXILLARY NERVE.

reach the septum of the nose, runs downward and forward in a groove on the vomer, to anastomose with the posterior palatine artery. Two or three external branches are distributed to the mucous lining of the lateral nasal walls, the antrum of Highmore and the ethmoid and sphenoid cells.

The **veins** of the pterygo-maxillary region accompany the branches of the internal maxillary artery, and converge toward the external pterygoid muscle, around which they form a dense plexus—the **pterygoid plexus**. This is drained from its posterior part by a short venous trunk, called the *internal maxillary vein*, which accompanies the first (maxillary) portion of the internal maxillary artery into the substance of the parotid gland. The internal maxillary vein joins the temporal vein to form the temporo-maxillary vein. The pterygoid plexus sends a branch (*anterior maxillary or deep facial vein*) from its anterior part over the buccinator muscle to the facial vein. It also communicates with the cavernous sinus by means of a small emissary vein which passes through the foramen Vesalii in the sphenoid bone.

The **lymphatics** of this region accompany the blood-vessels, and are derived from the regions which those vessels supply and drain. They empty into the deep cervical glands.

The **nerves** of the pterygo-maxillary region are the inferior maxillary division of the fifth nerve and some of its branches and the chorda tympani nerve.

The *inferior maxillary nerve* leaves the cranial cavity through the foramen ovale. It emerges from the skull as a thick trunk, which lies external to the Eustachian tube and beneath the external pterygoid muscle. It differs from the other two divisions of the fifth nerve—the ophthalmic and the superior maxillary—in being composed of both motor and sensory fibers. After leaving the skull it divides into two portions, an anterior and a posterior. From the *anterior portion*, chiefly motor, are derived the anterior and posterior deep temporal nerves, the masseteric nerve, branches to the pterygoid muscles, and the long buccal nerve. The *posterior division*, chiefly sensory, divides into three large branches: the auriculo-temporal, the lingual (gustatory), and the inferior dental nerve.

The **deep temporal nerves**, anterior and posterior, arise from the motor root of the fifth nerve, and ascend between the pericranium and the temporal muscle, which muscle they supply.

The **masseteric nerve** emerges from between the external pterygoid muscle and the pterygoid ridge. It proceeds backward along the upper border of the external pterygoid muscle; outward in front of the temporo-maxillary articulation, and through the sigmoid notch of the lower jaw, together with the masseteric artery, entering the masseter muscle, which it supplies.

The **branch to the internal pterygoid muscle** arises from the inferior maxil-

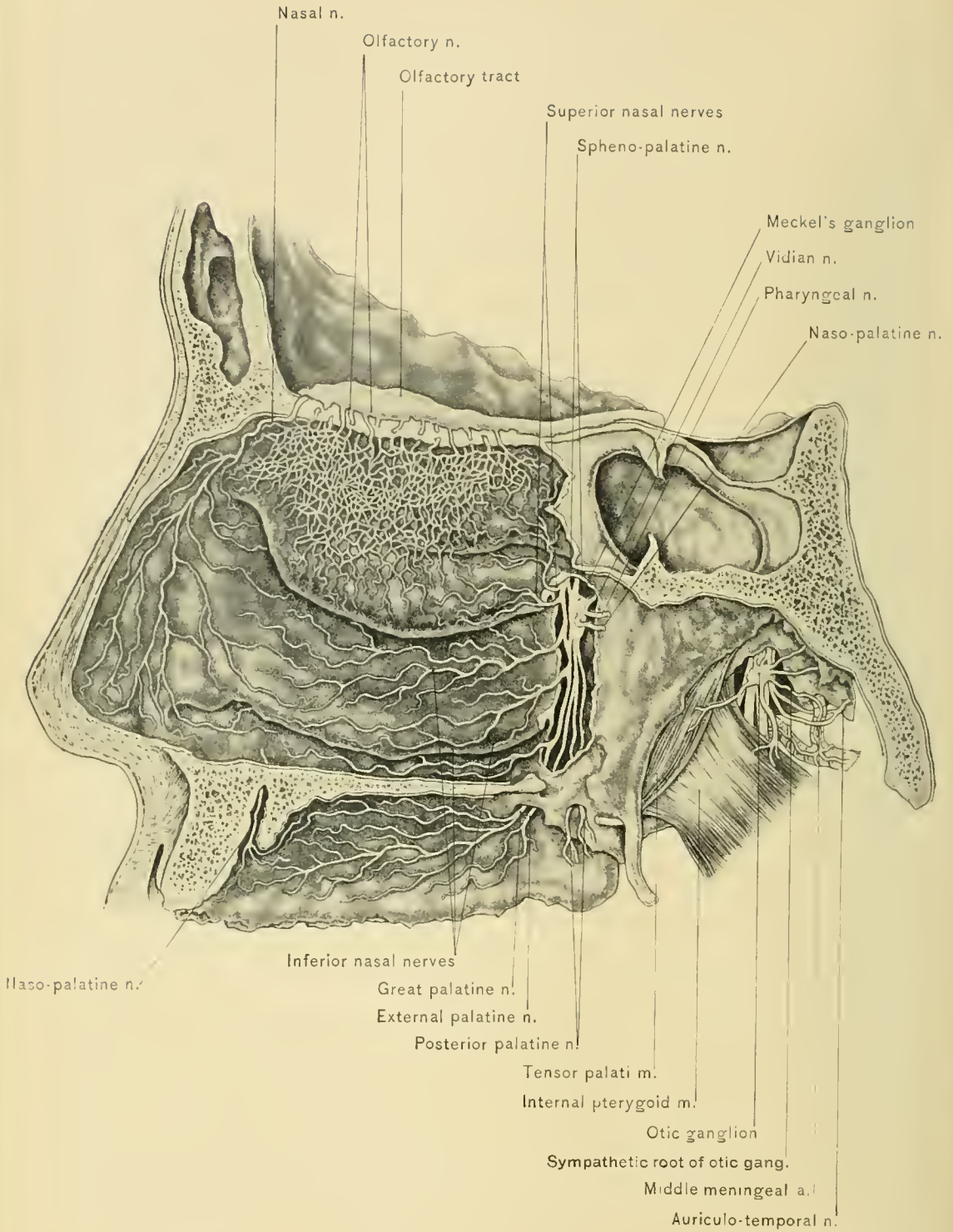
lary nerve before it divides ; it gives off a branch to the otic ganglion, and enters the deep surface of the muscle. The **branch to the external pterygoid muscle** is, usually, a twig of the long buccal nerve, and divides into two branches, which enter the deep surface of the muscle.

The **long buccal**, a sensory nerve, is derived from the anterior portion of the inferior maxillary division of the fifth nerve. It runs between the two heads of the external pterygoid muscle, and passes downward and forward beneath the temporal muscle and the anterior edge of the masseter to the buccinator muscle, upon the outer side of which it communicates with the facial nerve and forms a plexus from which filaments pass to the adjacent mucous membrane and skin of the cheek. It contains all of the sensory fibers of the anterior division of the inferior maxillary nerve, and a few fibers from the motor root of the fifth nerve. The motor fibers run to the external pterygoid and temporal muscles.

The **auriculo-temporal nerve** arises by two roots, between which passes the middle meningeal artery. It runs backward and outward beneath the external pterygoid muscle, between the internal lateral ligament and the temporo-maxillary joint, curves outward around the neck of the condyle of the lower jaw, and pierces the upper part of the parotid gland. It next ascends over the root of the zygoma, in front of the external auditory meatus and beneath the temporal artery. In its course it receives communicating twigs from the otic ganglion, and supplies branches to the external auditory meatus, the parotid gland, and the temporo-maxillary articulation. From the parotid gland it sends a communicating branch to the temporo-facial division of the facial nerve. It divides near the level of the tragus into the anterior auricular and superficial temporal branches. The *anterior auricular* supplies the upper part of the pinna. The *superficial temporal* lies on the outer side of the superficial temporal vessels, divides, and accompanies the anterior and posterior temporal arteries.

The **lingual (gustatory) nerve** emerges from beneath the lower edge of the external pterygoid muscle, whence it descends internal to the inferior dental nerve between the lower jaw and the internal pterygoid muscle ; thence it runs beneath the mylo-hyoid nerve and over the superior constrictor of the pharynx, the stylo-glossus, hyo-glossus, Wharton's duct, and genio-hyo-glossus muscle, to the tip of the tongue. On the hyo-glossus muscle it is connected with the submaxillary ganglion, which will be described with the submaxillary triangle of the neck. It lies above the ganglion and Wharton's duct, which it crosses at the anterior border of the hyo-glossus muscle, where it supplies a branch to the sublingual gland and a communicating branch to the hypo-glossal nerve. Before it emerges from behind the external pterygoid muscle it is joined by the chorda tympani nerve.

The lingual nerve supplies branches to the hypo-glossal nerve, submaxillary



OLFACTORY NERVES AND INTERNAL VIEW OF THE SPHENO-PALATINE AND OTIC GANGLIA.

ganglion, mucous membrane of the mouth, gums, sublingual gland, and lingual branches to the papillæ on the sides and tip of the tongue. As the lingual nerve supplies the tongue with common sensation, the pain due to neuralgia or cancer of the tongue may be relieved by division of this nerve. The incision should be made through the mucous membrane of the floor of the mouth opposite the second molar tooth of the lower jaw and close to the gum, where the nerve lies immediately beneath the mucous membrane.

The **inferior dental nerve**, the largest branch of the inferior maxillary, emerges from beneath the lower head of the external pterygoid muscle and descends between the internal lateral ligament and the ramus of the lower jaw to enter the inferior dental canal. At its origin it lies internal to the inferior dental artery, which it crosses at the inferior dental foramen; the artery is, therefore, nearer the teeth than the nerve. It is a sensory motor nerve, lying external to the lingual nerve and more superficial, the motor filaments being given off as the mylo-hyoid nerve just previous to its entrance into the inferior dental canal.

The **mylo-hyoid nerve** is accompanied by the mylo-hyoid artery, pierces the internal lateral ligament of the lower jaw, and descends to the mylo-hyoid groove upon the inner surface of the lower jaw. It then runs over the superficial surface of the mylo-hyoid muscle, supplying it and the anterior belly of the digastric muscle. In the inferior dental canal the inferior dental nerve supplies branches to the molar and bicuspid teeth and to the gums, and divides into an incisive and a mental branch opposite the mental foramen.

The **incisive branch** passes forward and inward in the inferior dental canal to supply the canine and incisor teeth and the adjacent region of the gum.

The **mental branch** emerges upon the face at the mental foramen, and after communicating with the supra-maxillary branch of the facial nerve divides into several branches. These supply the mucous membrane of the lower lip and the fascia and skin of the lip and chin.

The **chorda tympani nerve** arises from the facial in the aqueductus Fallopii, almost one-fourth of an inch above the stylo-mastoid foramen. It runs in the iter chordæ posterius to the middle ear, where it passes between the handle of the malleus and the fibrous layer of the membrana tympani externally, and the mucous membrane internally. It next enters the iter chordæ anterioris, or canal of Huguier, to reach the pterygo-maxillary region, where it joins the outer side of the lingual nerve beneath the external pterygoid muscle. Some of its fibers leave the lingual nerve to enter the submaxillary ganglion and sublingual gland.

The **otic** (Arnold's) **ganglion** lies upon the internal surface of the trunk of the inferior maxillary division of the fifth nerve, in front of the middle

meningeal artery, and may be found by tracing any of the larger branches of the nerve until the root of the parent stem, near the foramen ovale, is reached. Its sympathetic root is derived from the plexus on the middle meningeal artery; its sensory root from the inferior maxillary through the internal pterygoid nerve; its motor root from the small superficial petrosal nerve, which communicates with the tympanic branch of the glosso-pharyngeal nerve. It communicates with the auriculo-temporal and chorda tympani nerves. Motor fibers of the inferior maxillary nerve pass through it to the tensor palati and tensor tympani muscles.

DISSECTION.—To study the first portion of the internal maxillary artery and its branches, the trunk of the inferior maxillary nerve, the origins of its branches, and the otic ganglion, it is necessary to remove the external pterygoid muscle, the condyle of the jaw, and the remainder of the ramus as far as the transverse incision in the ramus.

Fracture of the base of the skull may cause serious hemorrhage into the pterygo-maxillary region, because of rupture of the meningeal vessels. Lacerations of the deep temporal vessels due to cranial fracture would result in the effusion of blood into this space, its escape above the zygoma being rendered impossible because of the attachments of the temporal fascia. Under these conditions pain on pressure made below the zygoma and behind the malar bone would be a rational symptom. Such effusion might give rise to secondary irritation of the nerves in this space. Thus, irritation of the chorda tympani nerve would cause salivation; of the lingual, disturbances of sensation and taste at the end of the tongue; of the inferior dental, toothache; of the motor branches, tonic or clonic spasm of the muscles of mastication; of the mylo-hyoid and anterior belly of the digastric muscles, more or less complete fixation of the jaw.

Tumors and abscess would have similar effects, but would vary in degree in accordance with the exact location and rapidity of growth. Owing to the presence of important structures in this space, it is well to practise Hilton's method of opening a deep abscess in this region; this is done as follows: Through an incision in the skin push a grooved director into the abscess; then insert a pair of forceps along the director, and withdraw them with the blades sufficiently separated to make an opening large enough to insure good drainage. It is impossible to do serious damage by this procedure.

DISSECTION.—The pterygo-maxillary region should now be thoroughly cleaned, in order to study the sphenomaxillary fissure, the pterygo-maxillary fissure, and the sphenomaxillary fossa.

It will be remembered that the zygomatic fossa was mentioned in connection with the contents of the pterygo-maxillary region; its contents have been dissected.

They consist of the lower part of the temporal muscle, the internal and external pterygoid muscles, the internal maxillary artery, the inferior maxillary nerve, branches of the artery and nerve, and the chorda tympani nerve.

The **zygomatic fossa** practically corresponds to the upper portion of the pterygo-maxillary region. It is bounded above by the under surface of the great wing of the sphenoid and adjacent portion of the temporal bone; in front, by the zygomatic surface of the superior maxilla; behind, by the posterior border of the pterygoid process of the sphenoid bone and the eminentia articularis; internally, by the external pterygoid plate; and externally, by the pterygoid ridge, the zygomatic arch, and the ramus of the inferior maxilla. At the upper and inner part of the zygomatic fossa two fissures will be observed, one horizontal, the other vertical. The horizontal fissure is the spheno-maxillary, which opens into the outer and back part of the orbit. It transmits the infra-orbital artery and vein, branches from Meckel's ganglion, and the superior maxillary nerve and its orbital branch. Its bony walls are formed, above, by the lower border of the orbital surface of the great wing of the sphenoid; below, by the orbital surface of the superior maxilla and a portion of the palate bone; externally, by a small part of the malar bone. It joins the pterygo-maxillary fissure at a right angle. The vertical fissure is the pterygo-maxillary, which is formed by the angle between the superior maxillary bone and the pterygoid process of the sphenoid bone. It transmits the internal maxillary artery.

The **spheno-maxillary fossa** lies below the great wing of the sphenoid, external to the vertical portion of the palate bone, and between the orbital process of the palate bone and the zygomatic surface of the superior maxilla, in front, and the pterygoid process, behind. It contains the terminal portion of the internal maxillary artery, the branches of this portion, the superior maxillary nerve, and Meckel's ganglion. Three foramina are found in the posterior wall: the *foramen rotundum*, which transmits the superior maxillary division of the fifth nerve; below this, the anterior opening of the Vidian canal, which transmits the Vidian nerve and vessels, and still lower the *pterygo-palatine foramen*—the anterior opening of the pterygo-palatine canal, which transmits the pterygo-palatine vessels and the pharyngeal nerve. On the internal wall is the *spheno-palatine foramen*, which transmits the spheno-palatine vessels and the naso-palatine nerve. Below the spheno-palatine foramen is the orifice of the posterior palatine canal, which transmits the posterior or descending palatine vessels and nerve.

The **superior maxillary** (second division of the fifth) **nerve** is a sensory nerve. It arises from the Gasserian ganglion at the apex of the petrous portion of the temporal bone, passes through the foramen rotundum into the spheno-maxillary fossa, and enters the infra-orbital canal with the infra-orbital artery to

become the infra-orbital nerve. Its branches are: In the cranial cavity, *recurrent twigs* to the dura mater, which communicate with branches of the inferior maxillary nerve; in the sphenomaxillary fossa, *orbital* or *temporo-malar*, *spheno-palatine*, and *posterior superior dental branches*; in the infra-orbital canal, *middle superior dental* and *anterior superior dental nerves*; and upon the face, the terminal divisions of the infra-orbital nerve, the *palpebral*, *nasal*, and *labial branches*. In the sphenomaxillary fossa Meckel's ganglion is associated with it.

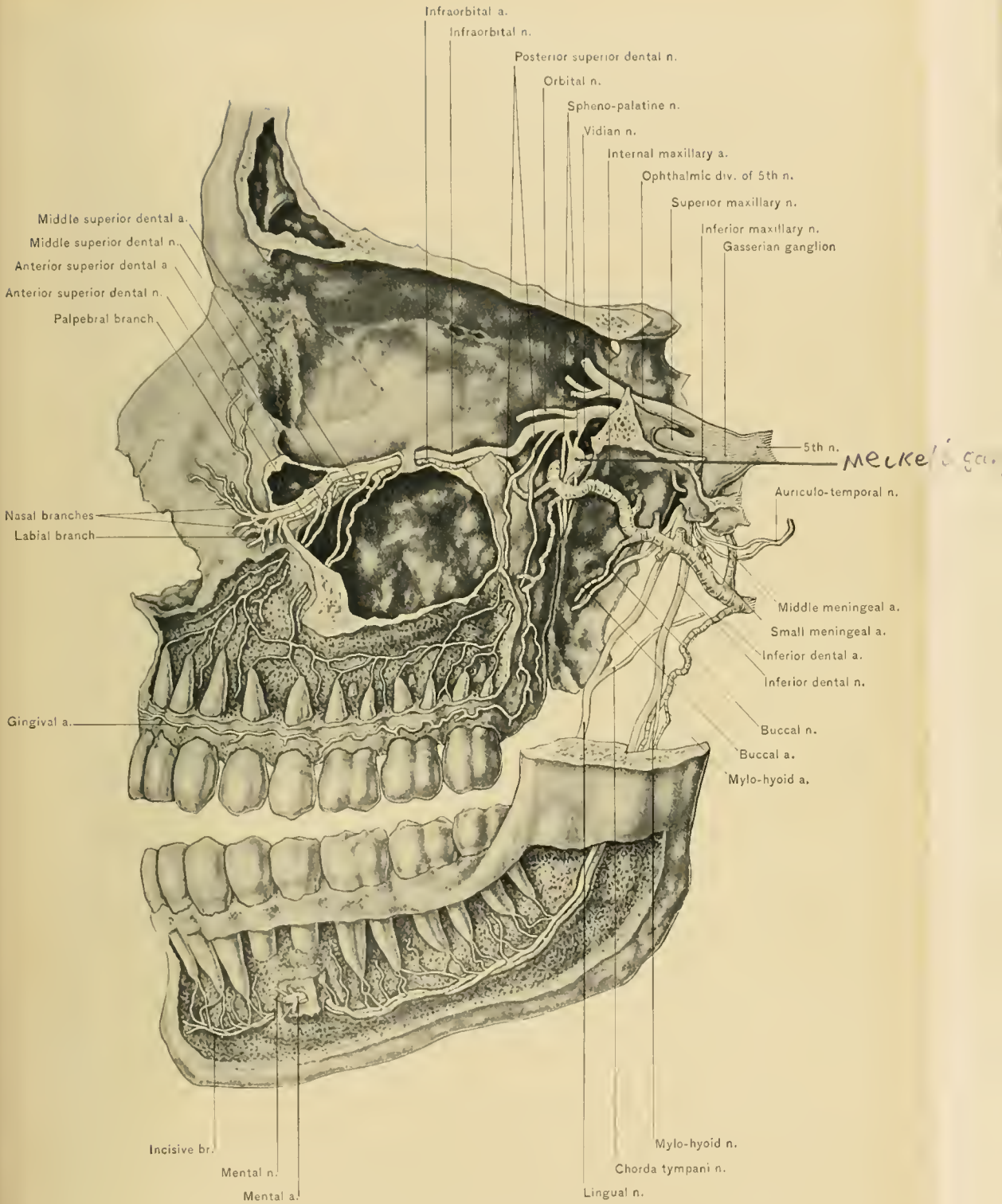
DISSECTION.—Remove the outer wall of the orbit and that portion of the greater wing of the sphenoid bone external to the foramen rotundum by sawing downward from the incised edge of the skull made in removing the brain. The saw should pass through the outer part of the sphenoid fissure and external to the foramen rotundum.

The **orbital or temporo-malar nerve** enters the orbit through the sphenomaxillary fissure. At the posterior part of the orbit it divides into a temporal and a malar branch. The *temporal branch* runs forward in the periosteum, lying in a groove in the bone, and passes through a foramen in the malar bone (sphenomalar foramen) to enter the temporal fossa. It runs upward beneath the temporal muscle, piercing it and both lamellæ of the temporal fascia to supply the skin of the temporal region; it pierces the superficial layer of the temporal fascia about an inch above the zygoma. In the orbit it communicates with the lacrymal nerve; and in the temporal region with the temporal branch of the facial nerve. The *malar branch* (ramus subcutaneus malæ) runs forward along the external and inferior portion of the orbit, passes through the malar foramen, pierces the orbicularis palpebrarum, and supplies the skin of the cheek. It communicates with the malar branch of the facial nerve and with the palpebral branches of the infra-orbital nerve.

The **spheno-palatine branches** are two twigs which descend to Meckel's ganglion from its sensory root.

The **posterior superior dental nerves** are, usually, two in number, and arise from the superior maxillary nerve as it enters the infra-orbital canal. They pass downward and enter the foramina in the zygomatic surface of the superior maxilla; they next run forward in canals in the outer wall of the antrum of Highmore and above the roots of the molar teeth to join the middle superior dental nerve. They supply branches to the pulp of the molar teeth, to the gums, and to the mucous membrane of the antrum of Highmore.

The **middle superior dental nerve** is given off at the posterior part of the infra-orbital canal, or it may be a branch of the anterior superior dental nerve. It supplies the bicuspid teeth and communicates with the anterior superior and posterior superior dental nerves.



SUPERIOR AND INFERIOR MAXILLARY NERVES.

The **anterior superior dental nerve** is larger than the other two superior dental nerves, and arises posterior to the infra-orbital foramen; it runs downward in the anterior wall of the antrum of Highmore, and supplies the incisor and canine teeth, and also a branch to the nasal fossa. The anterior and middle superior dental nerves may be seen by raising the superior maxillary nerve from the floor of the infra-orbital canal.

The **infra-orbital nerve** emerges upon the face at the infra-orbital foramen, which lies beneath the levator labii superioris muscle. It divides here into palpebral, nasal, and labial branches, which, with the infra-orbital branch of the facial nerve, form the *infra-orbital plexus*.

The *palpebral branches* pierce the origin of the levator labii superioris muscle and supply the integument and conjunctiva of the lower eyelid.

The *nasal branches* pass inward under the levator labii superioris alaeque nasi muscle to supply the skin of the nose.

The *labial branches* are the largest and most numerous. They run downward beneath the levator labii superioris muscle to supply the skin, mucous membrane, and other tissues of the upper lip.

Meckel's or the sphenopalatine ganglion is situated in the sphenomaxillary fossa below the superior maxillary nerve. It is triangular in shape, of a reddish-gray color, and measures about one-fifth of an inch in its longest diameter. Its sensory root is derived from the superior maxillary through the sphenopalatine nerve, most of the fibers of which do not enter the ganglion but pass anterior to it. Its motor root is derived from the facial through the great superficial petrosal nerve, which assists the great deep petrosal in forming the Vidian nerve. Its sympathetic root, the great deep petrosal nerve, just mentioned, is derived from the carotid plexus. The motor and sympathetic roots enter the sphenomaxillary fossa as the Vidian nerve. Its branches are classified as ascending, descending, internal, and posterior.

The **ascending or orbital branches** pass through the sphenomaxillary fissure, and pierce the inner wall of the orbit to supply the mucous membrane of the sphenoid sinus and posterior ethmoid cells.

The **descending or palatine branches** are derived mainly from the sphenopalatine branches of the superior maxillary nerve. They are divided into anterior, external, and posterior palatine nerves.

The *anterior or large palatine nerve* passes downward in the posterior palatine canal together with the posterior palatine artery, and appears on the hard palate at the posterior palatine foramen. It runs forward in a groove on the under surface of the hard palate, and joins the terminal portion of the naso-palatine nerve. It supplies the gums and the muco-periosteum of the hard palate. While in the poste-

rior palatine canal it gives off two branches (inferior nasal nerves), which pierce the vertical plate of the palate bone to supply the mucous membrane of the back part of the middle and inferior meatuses and the inferior turbinated bone.

The *external or middle palatine nerve*, when present, is small; it descends in the external palatine canal to supply the tonsil and adjacent mucous membrane.

The *posterior or small palatine nerve* descends in the accessory palatine canal to supply the tonsil, adjacent mucous membrane, levator palati, and azygos uvulæ muscles. With the external palatine nerve it joins a branch from the glossopharyngeal nerve to form the *circulus tonsillaris*, a plexus around the tonsil.

The **internal or nasal branches** are derived partly from the sphenopalatine ganglion and partly from the sphenopalatine nerve. They are divided into septal and superior nasal branches.

The *septal branches* pass through the sphenopalatine foramen with the nasopalatine artery, and cross the roof of the nasal fossa beneath the mucous membrane and below the opening of the sphenoid sinus to reach the septum, where the smaller branches terminate.

The *naso-palatine nerve* (nerve of Cotunnius), the largest of these branches, runs downward and forward on the septum of the nose, between the periosteum and the mucous membrane, to the anterior palatine canal, where it passes through one of the foramina of Scarpa (subdivisions of the anterior palatine foramen) to supply the mucous membrane of the anterior portion of the hard palate and to join the terminal portion of the anterior palatine nerve.

The *superior nasal nerves* are several twigs which pass through the sphenopalatine foramen to supply the mucous membrane of the posterior part of the middle and superior turbinated bones, and of the posterior ethmoid cells and antrum of Highmore.

The **posterior branch** is the pharyngeal nerve.

The **pharyngeal or pterygo-palatine nerve** runs backward through the pterygo-palatine canal in company with the pterygo-palatine artery; it supplies the upper portion of the pharynx and the Eustachian tube.

The **Vidian nerve** has been considered a posterior branch of the sphenopalatine ganglion, but it is really the nerve which is formed by the junction of its motor and sympathetic roots. It will be seen emerging from the Vidian canal at the root of the pterygoid process.

The **superior maxillary nerve** and its many communications are especially important, because it is so frequently affected by neuralgia, the operation for which follows.

Trifacial neuralgia may be due to many causes; among these are: Reflected irritation from diseased teeth, eruption of the wisdom teeth, irritable ulcers in the

area of distribution of the nerve, and abscess or tumors of the antrum of Highmore, of the pterygo-maxillary region, or of the spheno-maxillary fossa. The **infra-orbital foramen** is on a line drawn from the supra-orbital notch to a point between the bicuspid teeth of the upper jaw. It corresponds to a point about one-half of an inch below the junction of the inner and the middle one-third of the infra-orbital margin. The infra-orbital nerve is best exposed through a semilunar incision with its convexity directed downward, and carried a short distance below the foramen. A flap, including skin, cellular tissue, and the orbicularis palpebrarum muscle, is raised. The levator labii superioris muscle, which covers the foramen, is now apparent, and must be displaced laterally or divided, when both the infra-orbital plexus and nerve will readily be found, surrounded by a small quantity of fatty tissue.

In some cases of obstinate neuralgia of the peripheral branches of the trifacial nerve it becomes necessary to remove a portion of the affected nerve in order to give the patient relief. The infra-orbital nerve may be divided at its exit from the infra-orbital foramen by either a subcutaneous or a conjunctival section; in the latter method the tenotome is introduced through the conjunctiva and carried over the infra-orbital margin; it is best to expose the infra-orbital nerve by turning up a flap from the face, when a portion of the nerve can be removed. The nerve being exposed and freed at its point of exit, a slightly curved or hooked knife can be entered close to the external canthus just below the outer palpebral ligament, and passed backward along the floor of the orbit toward the apex, and along the anterior border of the spheno-maxillary fissure, which is crossed by the nerve at about an inch behind the orbital margin. The knife is then carefully withdrawn, and the nerve divided as it enters the infra-orbital canal. Traction is then made upon the peripheral end of the nerve to remove it from the infra-orbital canal. Should the knife be carried too far and the spheno-maxillary fossa be entered, serious hemorrhage would result.

The objections to this last method are, first, the hemorrhage which results from the division of the infra-orbital vessels inaccessible for ligature; second, the uncertainty of accomplishing the division of the nerve; and third, in many of these cases the posterior, as well as the anterior, dental branches are involved; if this be the case, removal of the superior maxillary nerve behind Meckel's ganglion will be required in order to insure positive relief.

The best method for removing the superior maxillary nerve through the face from behind Meckel's ganglion is the following: Expose and free the infra-orbital nerve at its exit from the infra-orbital foramen; then, with a three-quarter-inch trephine, remove a button of bone from the anterior wall of the antrum of Highmore; this button should include the outer wall of the infra-orbital foramen, and

in removing it care must be taken not to sever the infra-orbital nerve. Open the antrum by tearing through the lining membrane, and then, with a trephine one-half of an inch in diameter or with a small chisel, perforate its posterior wall. This opens up the sphenomaxillary fossa, and will be followed by considerable bleeding from wounded branches of the internal maxillary vessels. Before proceeding with the next step in the operation pack the opening in the posterior wall with sterile gauze to check the hemorrhage; then, with a small chisel, break away the floor of the infra-orbital canal and the back part of the floor of the orbit along the roof of the antrum; this permits the infra-orbital nerve to be drawn down into the antrum, when, by making slight traction upon it, a pair of long, slender scissors, sharply curved and with blunt points, can be carried along the nerve through the antrum, and the superior maxillary nerve divided behind Meckel's ganglion. In breaking away the floor of the infra-orbital canal the infra-orbital vessels will be torn, but the bleeding therefrom is of no serious consequence and can be controlled by packing a strip of sterile gauze into the broken canal. If hemorrhage persists after the removal of the superior maxillary nerve, the sphenomaxillary fossa also may be packed with gauze, which should protrude through the opening in the anterior wall of the antrum. The gauze may remain for two or three days and serves a two-fold purpose: in controlling the bleeding and in favoring drainage. The operation is facilitated by the use of an incandescent lamp attached to a head-band.

Clavus (nail) is the name given to a neuralgic pain, which, from its intensity and the smallness of its area, is likened to a nail being driven through the flesh and bone. It generally affects hysterical young women.

It is not inappropriate for the author to say here that, having had a large experience in the operative treatment of cases of trigeminal neuralgia (*tic douloureux*), he is of the opinion that the simpler operative procedure should first be pursued, for the period of relief following any operation is, comparatively speaking, but temporary in the majority of cases. This is not in accord with the views of some of the leading operators, but it has, nevertheless, been the author's experience. He has operated on a number of cases several times,—in one instance as many as five,—each operation having been followed by relief for from twelve to eighteen months. The peripheral operations may be repeated, a little more of the nerve being removed at each operation. This course affords the patient a more prolonged period of relief than could be obtained by first performing the more radical operation. As a last resort, the most radical operation of all, intra-cranial section of the affected nerve or removal of the Gasserian ganglion, may be done. In cases where the neuralgia has returned after removal of the superior maxillary nerve back of Meckel's ganglion by opening both walls of the antrum and removing

the infra-orbital nerve from its canal, the author has, by simply cleaning out the track of the original wound, seen relief follow.

In trifacial neuralgia one, two, or all three branches of the trifacial nerve may be involved. The ophthalmic division supplies the skin above the palpebral fissure; the superior maxillary division, the skin between the palpebral and oral fissures, including the temple; the inferior maxillary division supplies the skin below the oral fissure as far as the hyoid bone. The superior and the inferior maxillary nerves also supply the teeth through their branches, while the latter supplies the anterior two-thirds of the tongue through its lingual branch; the motor root of the third division also supplies the muscles of mastication, except the buccinator—*i. e.*, the temporal, masseter, and external and internal pterygoid muscles. Thus, *complete paralysis* of the trifacial nerve abolishes sensation upon one side of the face and on top of the head, from the highest point of the vertex above to the hyoid bone below; laterally, to and including the front of the ear and external auditory canal and temple; mesially, the anterior nares and the sensibility as to touch and taste of the anterior two-thirds of the tongue, besides completely paralyzing the muscles of mastication on the affected side, with the exception of the buccinator. Because of the insensibility of the conjunctiva the lids do not properly protect this membrane, and it becomes congested and inflamed, a condition which often occurs spontaneously through implication of the trophic fibers of the trifacial nerve. At the same time anterior rhinitis may result from similar causes, or may be excited by the discharge of the conjunctival secretion into the inferior meatus of the nose.

Trifacial neuralgia may be accompanied by active implication of the trophic filaments, so that there is not only conjunctivitis and rhinitis, but vesicles may form upon the lips and anterior nares. This should be borne in mind, as these trophic nerve disturbances, when overlooked, may be the source of much perplexity to the physician.

Paralysis of the orbicularis palpebrarum muscle also leads to conjunctivitis, from inability to close the eyelids; this must not be confounded with the inflammation of perverted function of the trophic nerves.

The **trophic filaments** are derived from the sympathetic nerve; this is a general rule worth remembering.

The entire width of the occiput, as high up as the vertex, and the back of the pinna are supplied by the occipitalis major nerve. As Hilton pointed out, the pinna may, therefore, often be used to differentiate between spinal and cerebral central nerve disease causing neuralgia; if spinal, the back of the pinna is affected and the front is not; if cerebral, the signs are reversed.

Reflex or referred pains are frequent in the area of distribution of the trifacial

nerve because of the abundance of its filaments and their numerous inosculations. The physician must, therefore, be careful not to be misled by the location of pain, for an earache may be due to a diseased tooth, as was the case in a patient treated by Hilton: The patient had consulted several leading aurists for a persistent earache without obtaining relief except from the use of anodynes; the ingenious Hilton sagaciously concluded it to be useless to treat where so many others had failed, and looked elsewhere than at the ear for the cause of the trouble. This he found in a jagged molar tooth which was continually irritating a small nerve filament at the bottom of an ulcer upon the side of the tongue adjoining the tooth. He advised the removal of the tooth, which resulted in healing of the ulcer and in cure of the earache. In a similar manner affections of any filament of the trifacial nerve may produce pain in any part supplied by other branches of the nerve.

The **Lymphatic Glands of the Head** are divided into a superficial and a deep set. The **superficial set** is composed of the occipital, posterior auricular, parotid, buccal, and submaxillary lymphatic glands.

The **occipital or suboccipital lymphatic glands** are situated in the superficial fascia along the superior curved line of the occipital bone over the attachments of the trapezius muscle and the occipital belly of the occipito-frontalis muscle. These glands receive the lymphatic vessels from the posterior portion of the scalp or that area supplied by the occipital artery, and may be involved in erysipelas or other septic conditions of the posterior portion of the scalp. The efferent vessels from these glands empty into the superficial lymphatic glands of the neck.

The **posterior auricular or mastoid lymphatic glands** are situated behind the pinna, over the mastoid process and the insertion of the sterno-mastoid muscle. They receive the lymphatic vessels from the posterior auricular region and the portion of the scalp above it. Their efferent vessels empty into the superficial lymphatic glands of the neck.

The **parotid lymphatic glands** lie upon the parotid salivary gland in front of the pinna, below the zygoma, and a few are found in the substance of the parotid salivary gland. They receive the lymphatic vessels from the temporal region, the portion of the scalp above it, and the outer portion of the eyelids and of the cheek. Their efferent vessels empty into the superficial lymphatic glands of the neck and into the submaxillary lymphatic glands.

The **buccal lymphatic glands** rest upon the buccinator muscle. They receive some of the lymphatics from the anterior portion of the face, inner half of the eyelids, brow, and front of the scalp. Their efferent vessels empty into the submaxillary and the internal maxillary lymphatic glands.

The **submaxillary lymphatic glands** are the largest group. They are

situated below the border of the lower jaw, most of them lying in the submaxillary triangle in relation with the submaxillary salivary gland; two or three of them (supra-hyoid lymphatics) lie above the body of the hyoid bone, between the anterior bellies of the two digastric muscles. The submaxillary lymphatic glands receive the lymphatic vessels from the front of the scalp, inner part of the eyelids, anterior portion of the face, floor of the mouth, anterior portion of the tongue, sublingual and submaxillary salivary glands, and some of the efferent vessels from the parotid lymphatic glands. Their efferent vessels empty into the superficial and deep cervical lymphatic glands.

The **deep lymphatic glands** of the head are the internal maxillary, lingual, and post-pharyngeal lymphatic glands.

The **internal maxillary lymphatic glands** are situated in the pterygo-maxillary region; some are in relation with the internal maxillary artery, others lie upon the posterior portion of the buccinator muscle, and still other deep glands lie upon the side of the pharynx. They receive the lymphatic vessels from the orbital, nasal, temporal, and zygomatic fossæ, the roof of the mouth, and the soft palate, and some of the efferent vessels from the buccal lymphatic glands. Their efferent vessels empty into the deep cervical lymphatic glands and partly into the deep parotid lymphatic glands.

The **lingual lymphatic glands** lie upon the hyo-glossus and genio-hyo-glossus muscles. They receive the lymphatic vessels from the upper surface and posterior part of the tongue. Their efferent vessels unite with the upper glands of the deep cervical chain.

The **post-pharyngeal lymphatic gland** is situated below the base of the skull, between the posterior wall of the pharynx and the rectus capitis anticus major muscle. It receives the lymphatic vessels from the upper part of the pharynx, part of the nasal fossa, and the upper part of the prevertebral muscles.

The **lymphatic vessels of the scalp**, which drain that portion behind a vertical line passing through the external auditory meatus, terminate in the occipital and posterior auricular lymphatic glands; the lymphatics of the temporal region of the scalp and that portion above it empty into the superficial and deep parotid lymphatic glands; the lymphatic vessels of the frontal region of the scalp follow the frontal, supra-orbital, and the facial veins downward over the face to the submaxillary lymphatic glands.

The **lymphatic vessels of the face** are divided into a superficial and a deep set. The superficial lymphatics of the anterior portion of the face—*i. e.*, of the inner half of the eyelids, of the nose, lips, and anterior part of the cheek—pass downward into the submaxillary lymphatic glands, and those of the outer half of

the eyelids and outer part of the cheek terminate in the parotid lymphatic glands. The *deep lymphatics of the face*—*i. e.*, those of the orbit, part of the nasal fossa, the hard and soft palates, deeper portion of the cheek, temporal fossa, and pterygo-maxillary region—enter the internal maxillary lymphatic glands.

From the course of the lymphatic vessels it follows that in septic conditions, such as infected wounds, erysipelas, and abscess of the posterior portions of the scalp, the occipital and posterior auricular glands may become affected, and that in the same condition of the lateral part of the scalp the parotid lymphatic glands may become enlarged or inflamed, and septic matter from the frontal region of the scalp may eventually reach the submaxillary lymphatic glands. The course of the lymphatic vessels usually corresponds to that of the veins.

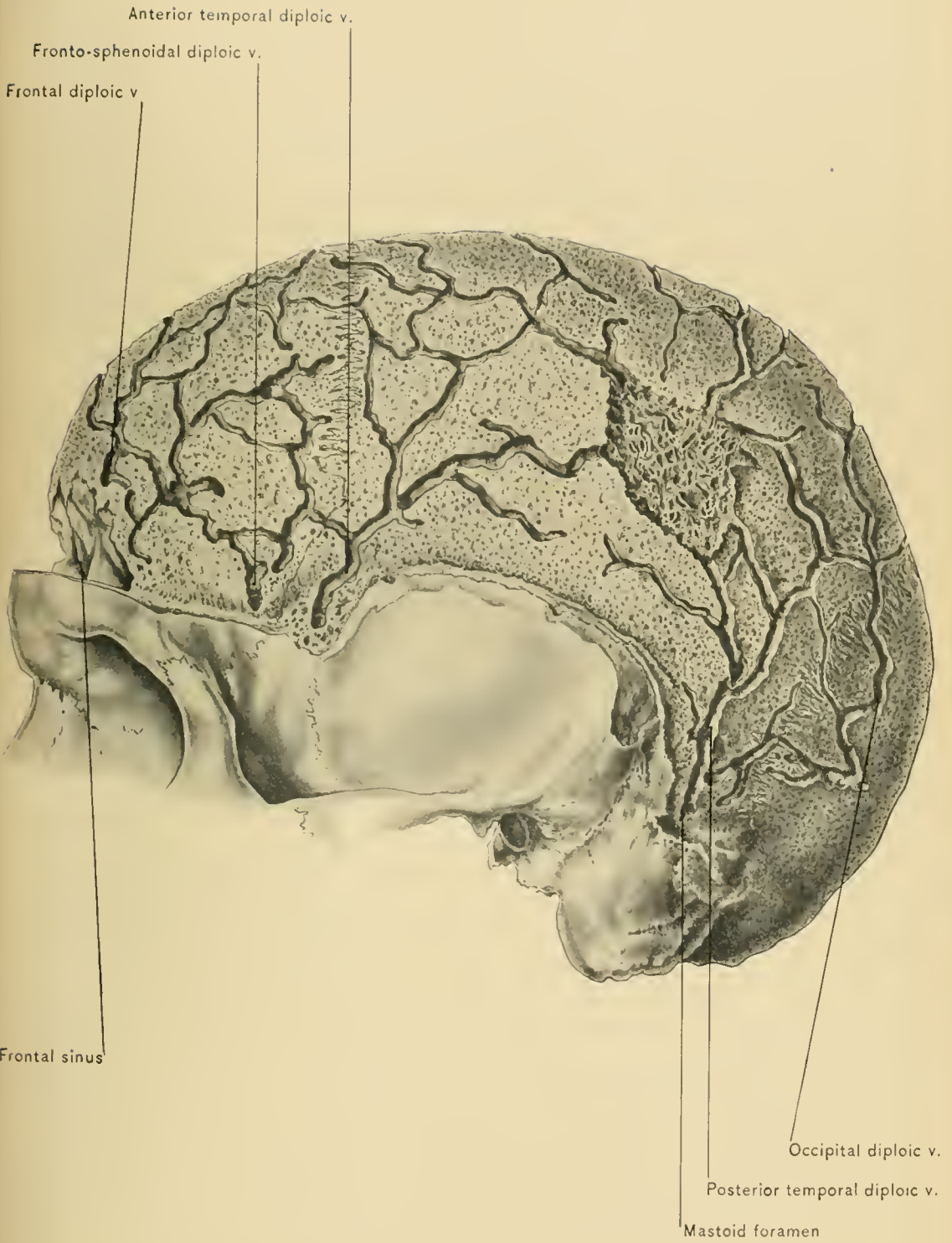Metastasis from carcinomatous growths generally follows the lymphatic vessels. In septic conditions or carcinomata of the anterior portion of the face, of the lips, of the tongue, and of the sublingual and submaxillary salivary glands the submaxillary lymphatic glands become enlarged. Similar affections of the outer part of the eyelids and face involve the parotid lymphatic glands; and in corresponding conditions of the orbital, nasal, temporal, and zygomatic fossæ, of the deeper tissues of the cheek and of the roof of the mouth, the internal maxillary lymphatic glands may be affected.

Before dissecting the neck, the student should remove the brain and place it in a solution to prepare it for dissection; he should study the diploic veins, the dura mater and its processes, trace the meningeal vessels and the sinuses, and follow the cranial nerves to their respective foramina of exit from the cranial cavity. These structures and their dissection are described under the Membranes and Vessels of the Brain.

THE MEMBRANES AND VESSELS OF THE BRAIN.

DISSECTION.—Before removing the calvaria, or skull cap, entire, its outer compact table should be removed on one side, so as to expose the diploë or middle table, with its bony channels for the accommodation of the diploic veins. This is most readily done by sawing through the outer table in the horizontal line described in the removal of the calvaria as a whole, and in the sagittal line of the skull, when, with a chisel, it can be lifted off piecemeal. To remove the portion below the line of the horizontal section a Hey's saw may be used.

The **Diploic Veins**, named from the bones in which they ramify, are the frontal, the fronto-sphenoid, the fronto-parietal (anterior temporal), the external parietal (posterior temporal), and the occipital (parieto-occipital). They vary greatly,



however, in different subjects (Merkel). These veins are distinct before the cranial bones unite with one another, after which there is a free anastomosis between them. In young subjects they are small, but they increase in size as age advances (Quain). They have no valves, and their walls are extremely thin.

The **frontal veins** are situated in the anterior part of the frontal bone; they pass most frequently through the supra-orbital foramen and empty into the supra-orbital vein; they may, however, empty into the fronto-sphenoid vein. Varicosity of this vein, even to the extent of causing absorption of the outer table of the bone, may occur.

The **fronto-sphenoid veins** lie in the lateral part of the frontal and in the sphenoid bone; they empty into the sinus *alæ parvæ*.

The **fronto-parietal or anterior temporal veins** are situated in the posterior part of the frontal and in the anterior part of the parietal bone; externally they empty into the deep temporal veins, and internally into the superior petrosal sinus or a meningeal vein.

The **external parietal or posterior temporal vein** is situated in the parietal bone; it passes through a foramen in the posterior inferior angle of this bone, or through the mastoid foramen to empty into the lateral sinus.

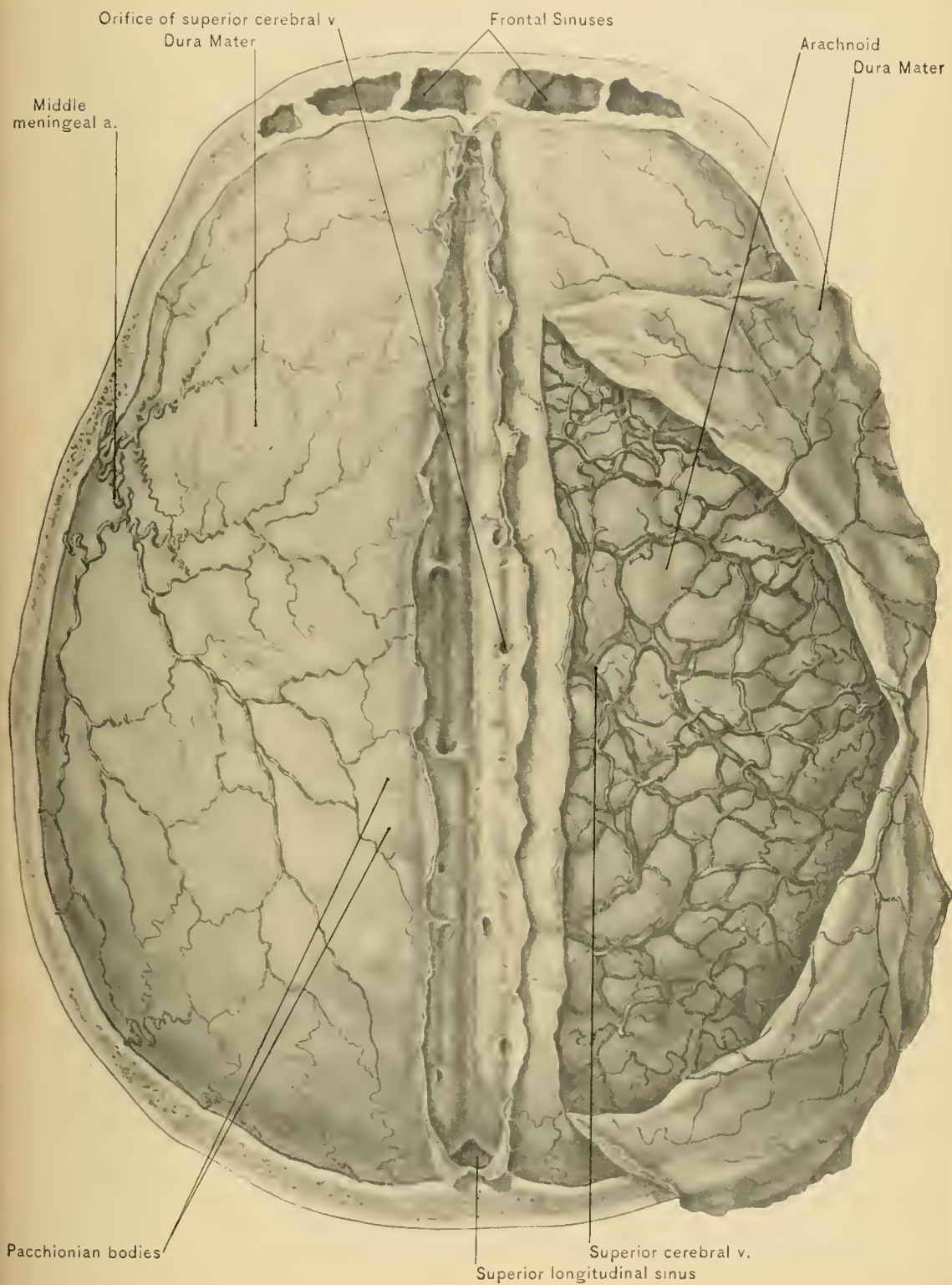
The **occipital or parieto-occipital vein**, the largest of the diploic veins, is confined to the occipital bone; it empties externally into the occipital vein, or internally into the lateral sinus.

In **compound fractures of the skull** the diploic veins offer an opening favorable to the introduction of septic matter into the circulation, thereby permitting thrombosis of the sinuses, septic meningitis, general sepsis (pyemia), or, possibly, abscess of other organs, especially the liver. The diploic veins communicate with those of the scalp by means of very small vessels; through these the septic matter may be conveyed to the diploic veins and thence to the sinuses. It is doubtless through one or more of these emissary veins, in the majority of cases, that septic material—the result of inflammation of the scalp—enters the venous system.

DISSECTION.—Remove the calvaria (skull cap) by sawing through the outer and middle tables along a line carried horizontally around the skull, connecting a point one-half of an inch above the supra-orbital margin with a point the same distance above the external occipital protuberance; then, with a chisel and mallet, cut through the inner table, prying the calvaria from the underlying dura mater. In breaking through the inner table the mallet and chisel are preferred to the saw, there being less danger of cutting the dura mater; even when closely adherent to the calvaria, the dura mater should only be divided as a last resort. In dividing the bone in the temporal region its thinness must be borne in mind, otherwise the brain, as well as the dura mater, may be injured.

Pacchionian bodies.—The outer surface of the dura mater being exposed by removal of the skull cap, it appears rough, especially along the lines of the sutures and in the neighborhood of the foramina, where it is most closely attached to the bone. The anterior and posterior branches of the middle meningeal artery, with the corresponding veins, will be seen to ramify upon the dura mater over each hemisphere; in most instances granular masses, the Pacchionian bodies, which are villous processes of the arachnoid, will be observed upon the surface on each side of the middle line. The position of these bodies should be carefully noted, and they must not be regarded as pathologic when seen on the operating or postmortem table. In some cases they are quite large: the author has known one to be so large as to occasion sufficient pressure to give rise to focal (Jacksonian) epilepsy; the patient was trephined, and the enlarged Pacchionian body with the underlying cerebral cortex removed, in the belief that it was a neoplasm. The convulsions were arrested temporarily, but returned after a time; this, unfortunately, occurs in the majority of cases of Jacksonian epilepsy operated upon. These bodies are always impressed upon the calvaria, so that depressions, corresponding in size to the bulk of the bodies causing them, may be seen upon each side of the median line of the skull; at times they almost perforate the bone. As a rule, they hollow the bone out sufficiently to render it translucent. The existence of these bodies may, therefore, be ascertained by inspection of the interior of the calvaria, and it is even possible, by the aid of transmitted light, to determine their presence by examining from without. The Pacchionian bodies, as previously stated, are processes of the arachnoid, and serve as channels for the passage of the cerebro-spinal fluid into the venous sinuses of the dura mater; in this way they relieve intra-cranial pressure. They vary greatly in size in different persons, and in children are quite small.

The **dura mater**, the most external of the three membranes of the brain, forms the internal periosteum of the skull, and affords an excellent protection to the brain. Through the medium of this internal periosteum the bones of the skull receive the greater part of their nourishment; this explains why they seldom necrose in scalp wounds in which the pericranium or external periosteum is torn away. The dura mater is a dense, tough, inelastic, fibrous membrane. It is intimately adherent to the base of the skull, owing, partly, to the numerous foramina found there; therefore, extra-dural extravasations or collections of blood or pus between the dura and skull rarely, if ever, occur at the base of the skull; at the sides and roof of the cranial cavity, however, where the membrane is comparatively loosely attached (except along the sutures and around the foramina), purulent collections and extravasations from rupture of one or both branches of the middle meningeal artery are not uncommon. These conditions cause *compression of the brain*, the symptoms of which, coming on immediately after



DURA MATER, ARACHNID, AND MENINGEAL VESSELS.

an injury to the head, indicate depressed fracture; if they appear a short time thereafter, hemorrhage; some days after, pus. Tillaux has demonstrated that the dura mater is less firmly attached to the temporal fossa, the most frequent site of extra-dural hemorrhage, than to any other portion of the interior of the skull (Treves). It is most closely adherent to the bone in infancy and old age. It has been demonstrated by Sir Charles Bell that the dura mater may be separated from the vault and sides of the skull by striking the head of a cadaver a hard blow with a heavy mallet.

Extra-dural hemorrhage.—The most common cause of extra-dural hemorrhage is rupture of the branches of the **middle meningeal artery**; this is usually associated with fracture of the parietal bone at its anterior inferior angle, the site of the groove through which the anterior branch of the artery passes. The author has trephined for compression of the brain produced by an extra-dural clot not associated with fracture. The next most frequent source of extra-dural hemorrhage is the lateral sinus.

Attachments of the dura mater.—Besides being closely adherent to the base of the skull, the dura mater is continuous, through the optic foramen, with the periosteum of the orbit; through the foramen magnum, with the dura mater of the spinal canal; and through the fissures and the various foramina through which the vessels and nerves enter and leave the cranial cavity, clothed by prolongations of this membrane, with the perieranium. As the dura mater is directly continuous with these various structures, it can be readily understood how inflammation may extend by continuity into the cranial cavity and cause secondary meningitis.

Pulsations of the dura mater.—The dura mater, when exposed in the living subject, may present two distinct pulsations, communicated from the underlying brain: one synchronous with the pulsation of the arteries, the other with respiration, rising in expiration and sinking in inspiration.

Layers of the dura mater.—The dura mater consists of two layers: an outer, the endosteal, and an inner, the meningeal; the latter is lined by endothelium, which gives it its shiny appearance. Between the two layers venous channels or sinuses and the Gasserian ganglion are found. The inner or meningeal layer sends in partitions which separate and support the different portions of the brain.

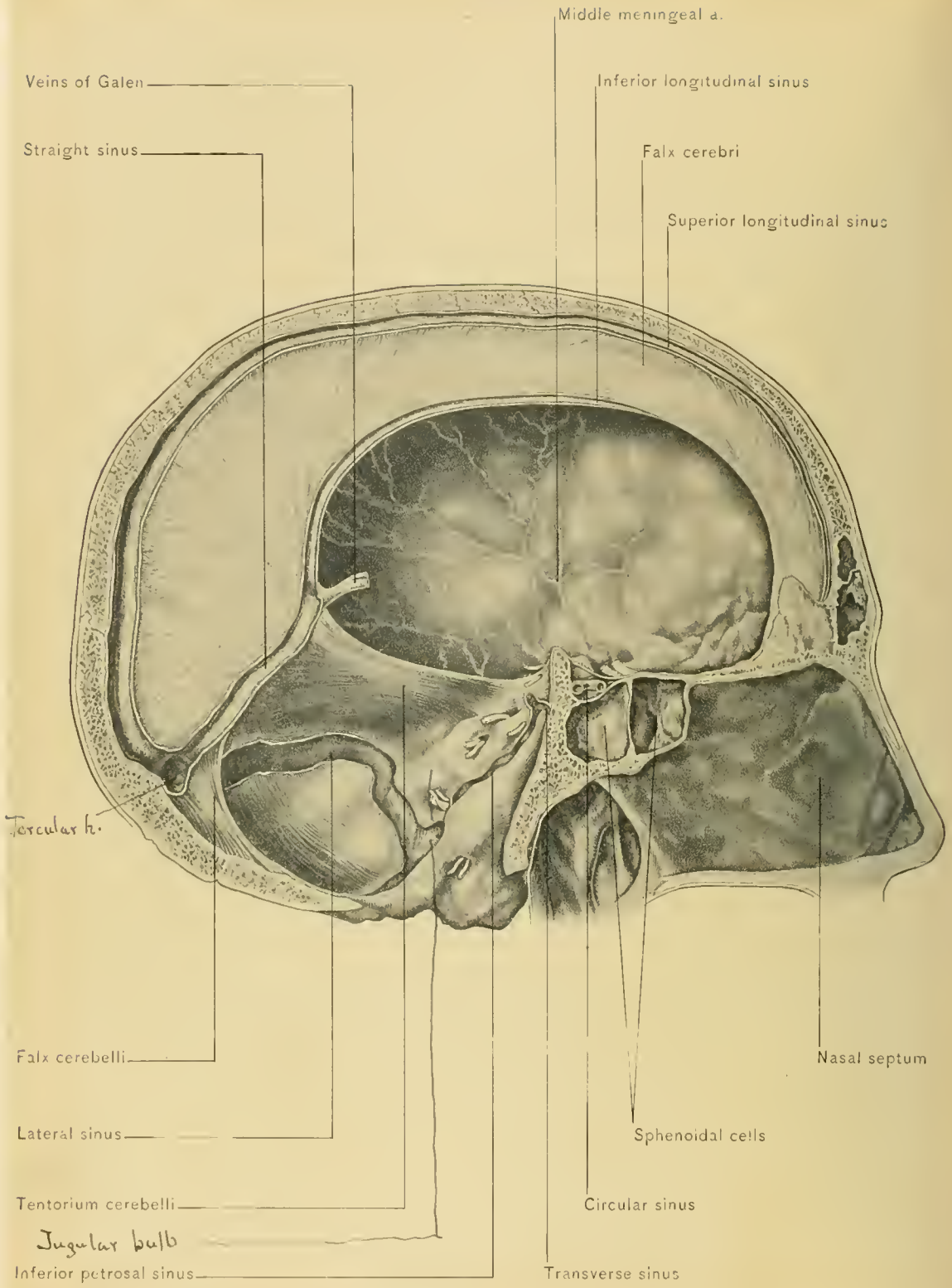
Sarcomata of the dura mater may protrude through the bones of the cranium and cause a swelling in the scalp.

DISSECTION.—Preliminary to removing the brain, and in order to obtain the most correct idea of the normal relations of the two larger partitions formed by the inner layer,—namely, the falx cerebri and the tentorium cerebelli,—divide the dura mater in the following manner: Carry two incisions through it from before

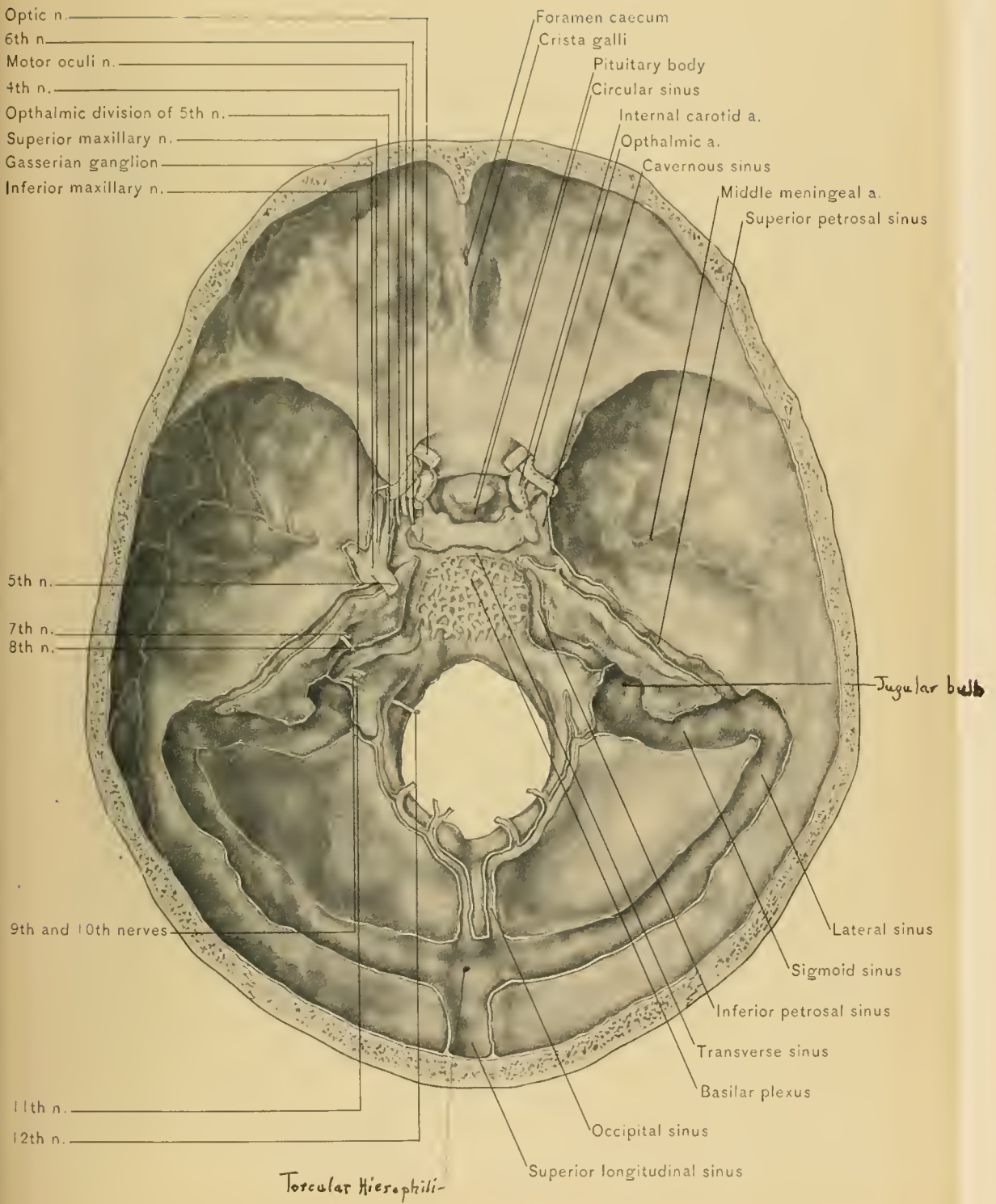
backward, one-half of an inch on each side of the median line, thus avoiding the superior longitudinal sinus. From the center of these incisions carry a transverse incision upon each side as far as the divided margin of the bone. Reflect the flaps thus made, and with the fingers gently separate the hemispheres of the cerebrum. The falx cerebri, with the veins from the surface of the cerebrum which empty into the superior longitudinal sinus, may then be seen. The tentorium cerebelli can now be readily exposed by lifting up the posterior extremities of the hemispheres of the cerebrum (occipital lobes). Next lay open the superior longitudinal sinus and inspect its interior. The small openings of the veins from the top of the hemispheres (superior cerebral veins), the diploë, and the dura mater will be seen along its entire course; they generally enter from behind forward. Divide the anterior uncut portion of the dura mater, and sever the falx cerebri from its attachment to the crista galli, along with the veins which empty into the superior longitudinal sinus; together with the falx cerebri turn back the strip of dura mater in which is contained the superior longitudinal sinus.

Removal of the brain.—The brain should now be removed in the following manner:

Draw the subject well up so that the head will hang over the edge of the table. With the fingers of the left hand lift the frontal lobes of the cerebrum from the anterior cranial fossa and raise the olfactory bulbs from the cribriform plate of the ethmoid bone, thus severing the olfactory nerves. The optic nerves with the ophthalmic arteries beneath will now be seen, and both should be cut across (preferably with scissors), a short distance from the brain. By gently lifting and displacing the hemispheres backward, the internal carotid arteries and the infundibulum (a process of gray matter which connects the pituitary body with the tuber cinereum) will be seen. These should next be divided or the artery should be severed and the pituitary body removed from the pituitary fossa after incising the diaphragma sellæ. The third pair of cranial nerves, the oculo-motor, will be seen lying behind the anterior clinoid processes on their way to reach the cavernous sinuses. Divide these nerves and then, turning the head to the right, lift the temporo-sphenoid lobes from the middle cranial fossa, and the tentorium cerebelli will be brought into view. This should be cut through close to its attachment to the posterior clinoid process and to the petrous portion of the temporal bone. The pathetic, or fourth, and the trifacial, or fifth, pairs of cranial nerves should be severed on the left side; turn the head to the left, and divide the corresponding structures on the right side. Bring the face back to the middle line, draw the brain well backward, and divide the following structures from within outward in the order named: The abducens or sixth, the facial or seventh, the auditory or eighth, the glosso-pharyngeal or ninth, the pneumogastric or vagus or



SINUSES AND PROCESSES OF DURA MATER.



SINUSES AND CRANIAL NERVES.

tenth, the spinal accessory or eleventh, and the hypo-glossal or twelfth pair of cranial nerves. The next and final step consists of carrying a scalpel down into the spinal canal as far as possible and cutting through the spinal cord, the two vertebral arteries, and the spinal portions of the spinal accessory nerves. The fingers of the right hand should then be slipped beneath the cerebellum and pons, and the brain removed.

Preservation of the brain.—If the brain be not dissected at once, it should be placed in a solution of chlorid of zinc, in alcohol and formaldehyd, or Müller's fluid. If placed in the zinc solution, the pia mater should be removed later, for if allowed to remain in this solution for some time, it is more easily separated than in the fresh condition. If alcohol alone be used to preserve the brain, the pia mater must be removed before placing it therein; this is most readily done under water; but if preserved in alcohol and formaldehyd, the membrane may be removed at leisure. Brains hardened in chlorid of zinc should afterward be kept in alcohol. When the brain has been removed from a subject injected (embalmed) with chlorid of zinc, the pia mater can at once be separated and the brain placed in alcohol. If the brain from a fresh subject be immediately placed in alcohol, subsequent removal of the pia mater will be found almost impossible on account of its firm adherence. If the pia mater is not removed, the study of the convolutions is much less satisfactory. Brains which have been hardened in chlorid of zinc and afterward kept in alcohol are much easier to handle than when kept in zinc alone, as the latter, by its action on the skin, makes the fingers sticky. Brains preserved in alcohol and formaldehyd are preferable to those preserved in a solution of zinc chlorid and alcohol, because they are not shrunken so much as the latter. Brains taken from a subject embalmed with zinc chlorid should be hardened in a solution of the same; only fresh brains should be hardened and preserved in alcohol and a two per cent. solution of formaldehyd.

Processes of the dura mater.—The dura mater, through duplication of its inner or meningeal layer, sends three larger and five smaller partitions, folds, or processes into the cavity of the skull and between certain divisions of the brain; these afford support to the latter. The three larger processes are the *falx cerebri*, the *tentorium cerebelli*, and the *falx cerebelli*. The five smaller processes or folds comprise two pairs and a single one. Of the two pairs, the larger are attached to the lesser wings of the sphenoid bone and project into the Sylvian fissure. The smaller pair, crescentic in shape, are attached to the clinoid processes and overhang the optic nerves. The single fold of the smaller group stretches across the pituitary fossa covering the pituitary body, and is known as the *diaphragm* of the *pituitary fossa*, or *diaphragma sellæ*. Its center contains an opening for the passage of the infundibulum.

The **falx cerebri** is a sickle-shaped process, narrowed almost to a point in front, where it is attached to the crista galli; it is broad behind, where it is attached to the middle of the upper surface of the tentorium cerebelli. It projects into the great longitudinal fissure of the brain and separates the hemispheres of the cerebrum. Its convex upper border is attached upon the inner surface of the calvaria to the edges of the groove which accommodates the superior longitudinal sinus. The concave lower border is free, arches over the corpus callosum, and contains the inferior longitudinal sinus.

The **tentorium cerebelli** is a somewhat triangular-shaped process, having its base attached upon the inner surface of the occipital bone to the edges of the groove for the lateral sinuses; the sides are attached to the line of junction of the upper and posterior surfaces of the petrous portion of the temporal bone, from the apex of which they are continued to the posterior and anterior clinoid processes. The apex corresponds to the free edge, which forms the lateral and posterior boundaries of the triangular opening known as the *superior occipital foramen or superior foramen magnum*. This foramen gives passage to the crura cerebri, the superior peduncles of the cerebellum, the oculo-motor and pathetic nerves, and the basilar artery. The tentorium cerebelli projects into the great transverse fissure of the brain and separates the posterior lobes of the cerebrum from the cerebellum. In the convex border of the base of the tentorium cerebelli the horizontal portions of the lateral sinuses are contained; in the sides, the superior petrosal sinuses; and in the middle, at its union with the falx cerebri, the straight sinus. The base of the falx cerebri is attached along the entire median line of the upper surface of the tentorium cerebelli, and the falx cerebelli to the median line of the lower surface. The tentorium serves to support the posterior lobes of the cerebrum, thus protecting the cerebellum from pressure.

The **falx cerebelli** is a small, vertical fold attached posteriorly to the internal occipital crest or inferior vertical limb of the occipital cross, and above to the under surface of the tentorium cerebelli; it is situated between the hemispheres of the cerebellum. In its posterior border is contained the occipital sinus. This border at times splits into two parts, which are attached to the sides of the back part of the foramen magnum.

Sinuses of the dura mater.—The sinuses of the dura mater are venous channels formed by the separation of its endosteal and meningeal layers, and are lined by a prolongation of the lining membrane of the veins. They are rigid tubes, which always remain patent (Macewen); their function is to return the venous blood from the brain and its coverings, the *diploë* (with a few exceptions), and also the greater part of the blood from the orbit and eyeball. They collect this blood and convey it to the jugular or posterior lacerated foramina, where it is taken

up by the internal jugular veins. There are sixteen in all, and they consist of two groups: those situated at the upper and back part of the cranial cavity, and those situated at the base of the skull. The former group includes the superior longitudinal, the inferior longitudinal, the straight, the lateral, and the occipital sinuses. The last-named group includes the cavernous, the sinuses *alae parvae*, the circular, the superior petrosal, the inferior petrosal, and the transverse. They can also be divided into a median and a lateral group, the former including the single sinuses, situated in the middle line of the skull, and the latter the paired sinuses, situated on both sides of the middle line. Five are in pairs and six are single. The five pairs are the lateral, the superior petrosal, the inferior petrosal, the cavernous, and the sinuses *alae parvae*. The six single sinuses are the superior longitudinal, the inferior longitudinal, the circular, the transverse, the straight, and the occipital. Some anatomists describe the sigmoid portions of the lateral sinuses as an additional pair, thus making the number eighteen.

The **superior longitudinal sinus**, which has already been exposed, occupies the convex border of the falx cerebri. It passes from the foramen cecum at the root of the frontal crest through the mesial groove on the inner surface of the calvaria; deviating slightly to the right in the posterior part of its course, it runs to the internal occipital protuberance, to end in the torcular Herophili. The *torcular Herophili* is the point of confluence of the superior longitudinal, lateral, straight, and occipital sinuses, and is situated a little to the right of the internal occipital protuberance. The superior longitudinal sinus is triangular on section, the base being directed toward the calvaria; it is narrower in front, gradually increasing in width as it passes backward. Its lumen is crossed by a number of fibrous bands, the *chordæ Willisii*, and Pacchionian bodies are frequently found projecting into it. It receives veins from the scalp through the parietal foramina, from the diploë, the dura mater, and the hemispheres of the cerebrum. These veins, particularly those from the cerebrum,—the superior cortical,—run into the sinus from behind forward in the direction opposite to that in which the blood current passes; furthermore, they pierce the wall of the sinus very obliquely. In the fetus the sinus communicates with the veins of the nose by a small emissary vein which passes through the foramen cecum, but this seldom occurs in the adult. The superior longitudinal sinus presents a variable number of lateral outgrowths or pouches, which have been named the *lacunæ laterales*. It is into these that the Pacchionian bodies project.

Wounds of, and line for, the superior longitudinal sinus.—The relation of the sinus to the skull renders it likely to be wounded in compound fracture of the vertex, and in trephining operations over the median line of the vertex. Hemorrhage from this or any of the sinuses is best controlled by plugging with sterile

gauze, unless the wound be small, in which case it can be closed by sutures. The course of the sinus is represented on the scalp by a straight line drawn from the root of the nose over the median line of the vertex to the external occipital protuberance.

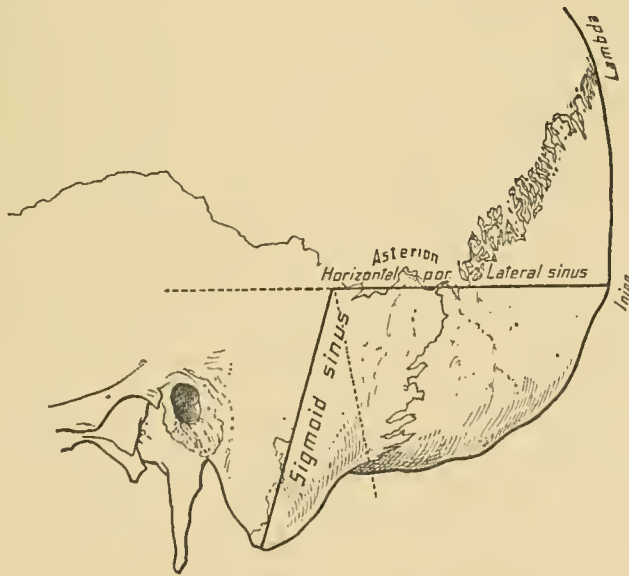
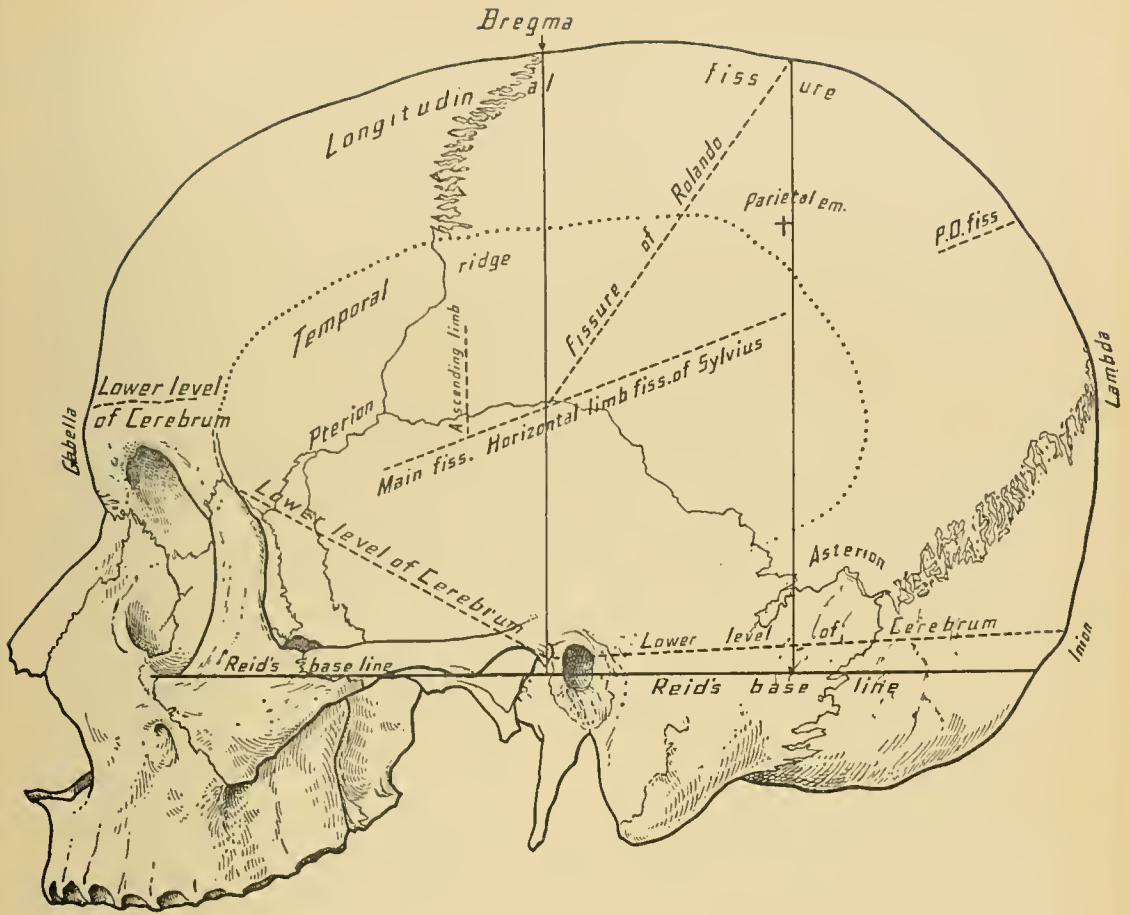
Septic or infective processes of the scalp may enter the superior longitudinal sinus through the parietal emissary veins; septic processes of the nose may reach that sinus through the vein in which the sinus has its origin.

The **lateral sinuses**, the largest of the cranial sinuses, extend from the internal occipital protuberance to the jugular foramina, terminating at the beginning of the internal jugular veins. They arise on each side of the internal occipital protuberance, across which they are connected by a small branch; thence they pass outward and forward, grooving the squamous portion of the occipital, the posterior inferior angle of the parietal, the mastoid portion of the temporal, and the jugular process of the occipital bone. Each sinus consists of two portions, a horizontal and a sigmoid. The *horizontal portion* is situated in the base of the tentorium cerebelli; it is triangular on section, the base of the triangle being directed toward the occipital bone and the posterior inferior angle of the parietal bone. The *sigmoid portion* is situated below the tentorium cerebelli, and grooves the mastoid portion of the temporal and the jugular process of the occipital bone; it is semicylindric on section, and is considered by some anatomists a separate sinus—the sigmoid. The superior petrosal sinus empties posteriorly into the sigmoid portion of the lateral sinus at its origin. The lateral sinus varies somewhat in size and position, a fact to be remembered in trephining operations.

Tributaries of the lateral sinus.—The right lateral sinus is usually larger than the left; it begins at the torcular Herophili, and is the continuation of the superior longitudinal sinus. The left lateral sinus is the continuation of the straight sinus. In addition to the superior petrosal sinuses, the lateral sinuses receive emissary veins from the scalp, which pass through the mastoid and posterior condyloid foramina; veins from the diploë (the occipital and the external parietal); the lateral inferior cerebral, and some of the superior and inferior cerebellar veins.

Leeching.—A suitable site for applying leeches in meningitis is behind the ear; in this way blood is extracted directly from the lateral sinus through the mastoid emissary vein, thus depleting the intra-cranial circulation. Another, but less favorable, location for the application of leeches in meningitis is near the inner canthus of the eye, where the angular vein anastomoses with the ophthalmic vein.

Thrombosis of the lateral sinus.—The sigmoid portion of the lateral sinus, or the sigmoid sinus, is the portion of the intra-cranial venous circulation most con-



LINES FOR SINUSES.

cerned in diseases of the middle ear. Thrombosis of this portion of the sinus and of the commencement of the internal jugular vein constitutes one of the complications of suppurative middle ear disease, and is due to the proximity of the sinus to the middle ear and mastoid cells, and to the fact that veins pass directly from the mastoid portion of the temporal bone to the lateral sinus. This condition demands exposure of the sinus and removal of the clot; this is best done before general systemic infection has occurred. When sepsis is present and the mastoid antrum has been drained by trephining the mastoid process without producing the desired effect, the sigmoid portion of the lateral sinus should be exposed without delay. The presence of a clot can readily be determined by palpation; removal of the clot should immediately be followed by antiseptic packing of the sinus. The four most serious complications of suppurative otitis media are septic thrombosis of the lateral sinus, septic meningitis, abscess of the temporo-sphenoid lobe of the cerebrum, and cerebellar abscess.

Infective processes may also reach the lateral sinus from the scalp through the mastoid vein, occipital diploic and posterior temporal diploic veins, and through the superior longitudinal and the cavernous sinus.

Line for the lateral sinus.—In trephining for depressed fracture of the occipital bone, cerebellar tumor, cerebellar abscess; in opening the mastoid cells or mastoid antrum; or in exposing the sinus itself in septic thrombosis, it is highly important to bear in mind the relation of the lateral sinus to the exterior of the skull. Its course is represented as follows: Draw a line from the external occipital protuberance to a point an inch above the external auditory meatus. The sinus follows this line as far as the base of the mastoid process; thence it runs downward parallel with the middle line of the mastoid. According to Macewen, the right sigmoid groove is generally wider and deeper, projects farther outward, and reaches farther forward than the left sigmoid groove. The closer proximity of the sigmoid portion of the right lateral sinus to the middle ear perhaps explains the greater frequency of intra-cranial lesions consecutive to right-sided otitis media.

Operations on the mastoid process.—In opening the mastoid cells or mastoid antrum it is better to expose the entire surface of the mastoid process by turning up a large flap, than to expose a limited surface through a vertical incision behind the ear; this is particularly the case if the disease be advanced, when the overlying soft parts become so swollen as to render it impossible to outline the process with any degree of certainty. When the mastoid process is exposed, draw two lines—a horizontal one through the roof of the external auditory meatus, and a vertical one through its posterior wall. In adults apply the trephine or gouge at a point a little below the horizontal and behind the perpendicular line; in children apply

the instrument at a point directly over the horizontal and behind the perpendicular line. With the trephine or gouge make an opening in a forward and inward direction. Having removed the external table, the mastoid antrum can usually be entered with a small elevator or a stiff director; this is to be preferred to the trephine or gouge, as it lessens the risk of injuring the sigmoid portion of the lateral sinus. Both the tympanum, or middle ear, and the mastoid cells can be drained through the mastoid antrum. In the majority of cases the pus is primarily in the tympanum, yet occasionally suppuration takes place *ab origine* in the mastoid cells. It must not be forgotten that in children and in many adults there are no well-developed mastoid cells; opening directly into the mastoid antrum is, therefore, the safest course to pursue in all cases.

The **inferior longitudinal sinus** is situated in the free concave margin of the falx cerebri. It is of small size, cylindric on section, and terminates in the straight sinus at the junction of the falx cerebri with the anterior margin of the tentorium cerebelli and at the posterior boundary of the superior occipital foramen. It receives veins from the falx cerebri, the median surface of the cerebral hemispheres, and the basilar surface of the frontal lobes.

The **straight sinus** is formed by the union of the inferior longitudinal sinus with the veins of Galen. It is situated at the junction of the falx cerebri with the tentorium cerebelli, and terminates at the internal occipital protuberance, whence it is continued as the left lateral sinus. It is triangular on section and increases in size as it passes backward. It receives veins from the tentorium cerebelli and the upper surface of the cerebellum (the superior cerebellar). Its direction is downward and backward.

The **occipital sinus** is formed by the union of two small veins (marginal sinuses) which pass around the lateral margins of the foramen magnum and communicate with the sigmoid portion of the lateral sinus near the jugular foramen and with the posterior spinal veins. It passes along the attached margin of the falx cerebelli to the internal occipital protuberance, where it empties into the torcular Herophili. It may empty into one of the lateral sinuses or into the straight sinus. It receives veins from the tentorium cerebelli and cerebellum, communicating also with the vertebral veins and the anterior spinal plexus.

The **sinus alæ parvæ**, or sphenoparietal sinus, one of the paired sinuses, occupies a groove on the inferior surface of the lesser wing of the sphenoid bone, and runs through the *sphenoid fold* of the dura mater. This fold is attached to the base of the lesser wing of the sphenoid bone, and is continuous with the dura mater at its attachment to the anterior clinoid process. It empties into the cavernous sinus, and often receives the fronto-sphenoid veins of the diploë as tributaries.

The **cavernous sinuses** are situated along the sides of the body of the sphenoid bone, and extend from beneath the anterior clinoid processes to the apices of the petrous portions of the temporal bones. The outer wall of the sinus—the most distinct—contains the third and fourth nerves and the ophthalmic division of the fifth, while the inner wall contains the internal carotid artery, the sixth nerve, and the cavernous plexus of the sympathetic. “Tillaux alludes to some cases of aneurysmal communication between the internal carotid artery and the sinus; the signs of such lesion are dilatation of the ophthalmic vein and a pulsatory swelling behind the internal angular process of the frontal bone” (Owen). The endothelial lining membrane of the sinus prevents the blood from coming into contact with the nerves and artery. Practically speaking, the inner wall of the sinus does not exist as a distinct lamella, but is formed by the structures previously enumerated as being contained therein. Section of the sinus discloses numerous bands and spaces on its interior—hence its name. The nerves which occupy the outer wall of the sinus observe the same order, both from above downward and from within outward, in which they have been mentioned. Of the structures occupying the inner wall, the sixth nerve is the most external. The sinus receives the ophthalmic vein in front, and the sinus *alæ parvæ* above the third nerve. It communicates with its fellow by means of the circular sinus, and divides posteriorly (at the apex of the petrous portion of the temporal bone) into the superior and inferior petrosal sinuses. It receives the middle cerebral veins and those from the basilar surface of the frontal lobe, communicating with the pterygoid plexus of veins by means of the Vesalian vein, which runs through the Vesalian foramen in the greater wing of the sphenoid bone. It also communicates with the internal jugular vein through the venous plexus surrounding the petrous portion of the internal carotid artery, and with the pterygoid and pharyngeal plexuses of veins by means of veins which run through the foramen ovale and the foramen lacerum medium.

Infective material may reach the cavernous sinus from the scalp through the supra-orbital or frontal and ophthalmic veins, and through the fronto-sphenoid diploic vein and the sinus *alæ parvæ*; from the orbit through the ophthalmic vein; and from the pterygo-maxillary region through the vein of Vesalius and emissary veins which pass through the foramina at the base of the skull.

Relations of the cavernous sinus to the Gasserian ganglion.—But one of the cavernous sinuses should be opened at this stage of the dissection, the opening of the other being deferred until the nerves which run in the walls of the sinus to enter the orbit have been traced. Upon opening the cavernous sinus it will be seen to occupy an interval between the endosteal and meningeal layers of the dura mater, as is the case with the other sinuses. In this interval Meckel’s space, which is

occupied by the Gasserian ganglion, may also be demonstrated at this time. The comparatively intimate relation existing between the sinus and the ganglion should, therefore, be borne in mind when attempting to remove the ganglion for relief of trifacial neuralgia, otherwise the sinus might be injured; an accident of this kind, it is hardly necessary to say, might be serious.

The **circular sinus**, through which the two cavernous sinuses communicate, surrounds the pituitary body. The anterior half is larger than the posterior, and in advanced life is larger than in early life. At times one-half is absent. It receives veins from the pituitary body and the neighboring bone and dura mater.

The **superior and inferior petrosal sinuses** are the terminal divisions of the cavernous sinus. The *superior petrosal sinus* runs in a small groove in the superior edge of the petrous portion of the temporal bone, in the margin of the tentorium cerebelli. It terminates in the lateral sinus at the point where the sigmoid portion of the sinus begins. At its origin it is crossed by the fourth nerve, and, in turn, crosses the fifth nerve. It receives some of the inferior cerebral and superior cerebellar veins, a vein from the middle ear which makes its exit through the petro-squamous suture, and some diploic veins.

The *inferior petrosal sinus*, which is shorter and wider than the superior, runs in the groove formed by the junction of the inferior border of the petrous portion of the temporal with the basilar process of the occipital bone, and at the jugular foramen empties into the commencement of the internal jugular vein. The terminal portion of the inferior petrosal sinus separates the glosso-pharyngeal from the pneumogastric and spinal accessory nerves. It receives some of the inferior cerebellar veins and some from the medulla oblongata and pons; veins from the internal ear which make their exit by way of the aqueductus vestibuli and aqueductus cochleæ also empty into it.

The **transverse sinus**, through which the inferior petrosal sinuses communicate with each other, passes across the basilar process of the occipital bone. It extends inferiorly as far as the anterior margin of the foramen magnum, where it communicates with the anterior spinal veins. The sixth pair of nerves pass through it. Some authors describe the transverse sinus as a plexus of veins (basilar plexus).

BLOOD SUPPLY.—The blood supply of the dura mater is derived from the meningeal arteries, though the chief function of these vessels is to supply the bones of the cranium. These arteries comprise practically three sets,—an anterior, a middle, and a posterior,—and in the dried skull their course can readily be traced by following the grooves in the bones which they occupy. The meningeal arteries are accompanied by relatively small veins.

NERVE SUPPLY.—The nerve supply of the dura mater is derived from the

Gasserian ganglion, the first, second, and third divisions of the trigeminal or fifth, the pneumogastric, the hypo-glossal, and the sympathetic nerves.

DISSECTION.—Before studying the courses of the meningeal arteries, which necessitates stripping the dura mater from the skull, examine the cranial nerves as they pass through the foramina at the base of the skull. The dura mater should then be disposed of in the foregoing manner.

INTRA-CRANIAL COURSE AND MODE OF EXIT OF THE CRANIAL NERVES.

Coverings.—In tracing the cranial nerves to their exit through the foramina at the base of the skull, observe that each pair of nerves receive investments from all three membranes of the brain. The coverings derived from the dura mater and the pia mater are continuous with the sheaths of the nerve, while that from the arachnoid terminates as the nerves enter the dura mater.

Enumeration.—The names of the twelve pairs of nerves, mentioned from before backward, are: The olfactory, the optic, the oculo-motor, the pathetic, the trifacial, the abducent, the facial, the auditory, the glosso-pharyngeal, the pneumogastric, the spinal accessory, and the hypo-glossal nerves.

The **olfactory nerves**, the first pair, consist of the olfactory tracts and bulbs, and have been removed with the brain and their branches divided. Strictly speaking, the olfactory bulb and tract are to be regarded as portions of the brain. Arising from the lower surface of the olfactory bulb are some twenty filaments,—the real olfactory nerves,—which are arranged in two rows, an inner and an outer. They supply the upper portions of the septum and the outer wall of the nose respectively, and terminate in cells in the mucous membrane. By carefully separating the dura mater from the grooves in the base of the skull on each side of the crista galli, these real olfactory nerves may be seen running through the foramina in the cribriform plate of the ethmoid bone.

The **optic nerves**, the second pair, pass through the optic foramina accompanied by the ophthalmic artery.

The **oculo-motor nerves**, the third pair, pierce the dura mater near the anterior clinoid processes, and enter the outer wall of their respective cavernous sinuses. In this situation they lie above the fourth nerve and the ophthalmic branch of the fifth. They enter the orbits through the sphenoid fissures, and here lie below the fourth nerve and part of the ophthalmic. They next divide into two branches, which pass between the heads of the external recti muscles, separated from each other by the nasal branches of the ophthalmic nerves; they supply all the extrinsic muscles of the eyeball with the exception of the superior oblique and

external rectus, and also supply the circular muscular fibers of the iris and the ciliary muscle.

The **pathetic nerves** (trochlearis), the fourth and smallest pair of cranial nerves, pierce the dura mater near the free edge of the tentorium cerebelli, a little behind the posterior clinoid processes and above the oval openings for the fifth nerves. Each enters the outer wall of its respective cavernous sinus, where it lies below the third nerve and above the ophthalmic nerve, and passes into the orbit through the sphenoid fissure, in which it lies above the third nerve and the ophthalmic division of the fifth. It supplies the superior oblique or trochlearis muscle.

The **trifacial nerves**, the fifth pair, have two roots,—a larger sensory and a smaller motor,—and pass through an oval opening in the dura mater beneath the free border of the tentorium cerebelli. Above the fifth nerve is the fourth nerve, and below it are the apex of the petrous portion of the temporal bone and the internal auditory meatus. Upon the larger or sensory root is the Gasserian ganglion, which can not be seen until the dura mater is raised from the base of the skull. Its description will therefore be deferred until this has been done. The ophthalmic branch of the trifacial nerve is exposed, and is seen running through the outer wall of the cavernous sinus, where it lies beneath the fourth nerve. It divides into three branches,—the lacrymal, frontal, and nasal,—after which it enters the orbit by way of the sphenoid fissure. In the wall of the sinus the ophthalmic branch is joined by filaments from the carotid plexus of the sympathetic nerve, communicating with the third, fourth, and sixth nerves, and giving off a recurrent branch which passes backward between the layers of the tentorium cerebelli.

The **abducent nerves**, the sixth pair, pierce the dura mater behind the body of the sphenoid bone immediately below the posterior clinoid processes, and pass through the transverse sinus. Each then courses along the inner wall of the cavernous sinus to the outer side of the internal carotid artery, and enters the orbit by way of the sphenoid fissure, lying between the ophthalmic vein and the inferior branch of the oculo-motor nerve. It supplies the external rectus muscle, between the two heads of which it passes. Within the wall of the cavernous sinus it is joined by filaments from the carotid plexus of the sympathetic nerve.

The **facial nerves**, the seventh pair, leave the cranial cavity by way of the internal auditory meatus. Each nerve is accompanied by the *pars intermedia of Wrisberg*, the auditory nerve, and the auditory artery. At the bottom of the meatus it enters the facial or Fallopian canal. (For a description of the course of the nerve through the facial canal see the Dissection of the Internal Ear.) It lies within the meatus, first to the inner side of, and then directly over, the auditory nerve.

The **auditory nerves**, the eighth pair, leave the cranial cavity through the internal auditory meatuses in company with the auditory arteries, the facial nerves, and the pars intermedia. Reaching the bottom of the meatus each nerve divides into two branches, the cochlear and the vestibular, for the supply of the cochlea, the vestibule, and the semicircular canals.

The **glosso-pharyngeal nerves**, the ninth pair; the **pneumogastric** (vagus), the tenth pair; and the **spinal accessory**, the eleventh pair, leave the cranial cavity by way of the jugular or posterior lacerated foramen, passing through its middle compartment. The glosso-pharyngeal nerves have a separate sheath of dura mater and arachnoid, and lie in front of the pneumogastric and spinal accessory nerves. The last-mentioned two have a sheath of dura mater common to both, but they have separate sheaths of arachnoid. The spinal accessory nerve is made up of two parts: a smaller or accessory portion (accessory to the pneumogastric nerve), which runs with the pneumogastric, and a spinal, which arises from the spinal cord, and is by far the larger portion. The latter enters the cranial cavity through the foramen magnum and joins the accessory portion shortly after the latter emerges from the medulla.

The **hypo-glossal nerves**, the twelfth pair, leave the cranial cavity through the anterior condyloid foramina.

The internal carotid artery.—When the cavernous sinus has been laid open and the nerves within its wall exposed, carefully examine the internal carotid artery running in the inner wall of the sinus before disturbing the dura mater further. After its exit from the carotid canal, the curves which the artery makes in reaching the brain can now be seen to the best advantage. Having emerged from the carotid canal the artery turns upward, passing toward the posterior clinoid process. It next runs forward through the inner wall of the sinus to reach the inner side of the anterior clinoid process, where it again turns upward and pierces the dura mater on the inner aspect of the anterior clinoid process; just before piercing the dura mater it gives off the ophthalmic branch. The cranial or terminal portion thus makes two bends, which give it the shape of the letter **S**. Running along with the artery and external to it is the abducent (sixth) nerve. The lining membrane of the sinus alone separates both the artery and the nerve from the interior of the sinus. Within the walls of the sinus the artery gives off branches known as the arteriæ receptaculi, which supply the walls of the sinus, the pituitary body, the Gasserian ganglion, and the dura mater (through the anterior meningeal). It is surrounded by filaments of the sympathetic nerve which form two plexuses, the carotid on the outer and the cavernous on the inner side of the artery. The former plexus communicates with the abducent nerve and the Gasserian and Meckel's ganglia; the latter communicates with the oculo-

motor, pathetic, and ophthalmic nerves, and furnishes the sympathetic root to the ophthalmic or lenticular ganglion.

DISSECTION.—The dura mater should now be dissected from the sides and base of the skull; it will be found closely adherent to the latter, requiring care in its removal in order to avoid injuring the following structures: The Gasserian ganglion, the superior and inferior maxillary nerves, which are branches from the ganglion, the large superficial petrosal, the external superficial petrosal when present, and the motor root of the trifacial nerve. The last and the large superficial petrosal nerve run beneath the ganglion.

The **Gasserian ganglion** occupies a depression on the superior surface of the petrous portion of the temporal bone near the apex, and rests to a slight extent on the cartilage filling the middle lacerated foramen. It holds an intimate relation, therefore, to both the internal carotid artery and the cavernous sinus. It is crescentic in outline, its concavity being directed backward and its convexity forward and outward, and it measures about one-half of an inch in width. Its upper and lower surfaces are slightly convex. It occupies an interval between the endosteal and meningeal layers of the dura mater (*Meckel's space*), and for this reason the endosteal layer of the dura mater must be divided in attempting its removal through the side or base of the skull. From the convexity of the ganglion arise the ophthalmic, superior maxillary, and inferior maxillary nerves, the first two being sensory nerves throughout. The inferior maxillary nerve is sensory until it reaches the outside of the skull; here it is joined by the motor root of the trifacial nerve, which leaves the cranial cavity with it by way of the foramen ovale; the inferior maxillary thus becomes a mixed nerve.

The **superior maxillary nerve**, intermediate in size between the ophthalmic and the inferior maxillary, leaves the cranium by way of the foramen rotundum.

The **inferior maxillary nerve**, the largest branch of the fifth, leaves the cranial cavity by way of the foramen ovale which also transmits the small superficial petrosal nerve and the small meningeal artery.

Intra-cranial neurectomy of the superior and inferior maxillary nerves.—This is one of the operations for relief of trifacial neuralgia, and is performed in the following manner: An Ω -shaped flap is made over the temporal region, beginning near the tragus of the auricle and carried upward to about the level of the temporal ridge, ending near the external angular process of the frontal bone. All the structures down to the bone are divided. They include the skin and superficial fascia, the *atrahens aurem* muscle, the temporal branches of the facial and auriculo-temporal nerves, the anterior and posterior temporal arteries and veins, the occipito-frontalis aponeurosis, the areolar tissue layer, the temporal fascia and muscle, the deep temporal vessels, and the periosteum. The bone is then cut through in

the line of the original incision, preferably with an instrument specially constructed for this purpose. Care must be taken to avoid injuring the membranes of the brain. An elevator is introduced beneath the bone after it has been cut through along the whole line of the incision, and the entire flap is forced outward and downward. The bone will fracture between the ends of the oval incision a little above the line of the zygomatic arch. The bone and soft structures should be reflected as one flap in thus exposing the dura mater of the brain. When the middle meningeal artery lies in a canal in the temporal and parietal bones, it may be torn in forcing the flap downward. This necessitates tying the vessel or plugging the canal for the vessel with gauze, as the bleeding would be severe. The dura mater is separated from the floor of the middle cranial fossa, and when the brain is lifted upward, the superior and inferior maxillary divisions of the fifth or trifacial nerve will be exposed. As much as possible of both nerves is then excised, and the distal ends pushed through their respective foramina of exit. The operation is completed by repositing the flap of bone, suturing the soft parts, and dressing the wound.

Removal of the Gasserian ganglion.—In removing the Gasserian ganglion one of two routes can be selected, either through the side of the skull or through its base; the latter method was first practised by Mr. Rose. In the former method, by far the most preferable, an osteo-plastic resection of the side of the skull is made, similar to that in the previous operation. The flap of bone includes part of the frontal, greater wing of the sphenoid, parietal, and the squamous portion of the temporal bone. After the superior and inferior maxillary nerves are exposed, they should be traced backward to the Gasserian ganglion; this is lodged in a depression near the apex of the petrous portion of the temporal bone, in a space (Meekel's) situated between the two layers of the dura mater. The outer layer of the dura mater should be incised, and the ganglion removed. The inferior and superior maxillary divisions of the trifacial nerve are then resected up to their point of exit from the skull, and the distal ends pushed through their respective foramina. The inferior maxillary nerve leaves the skull through the foramen ovale; the superior maxillary nerve through the foramen rotundum. The osteo-plastic flap is then replaced and the wound closed. The first steps of this and the succeeding operation will be greatly facilitated by the use of an electric headlight attached to a head-band.

In the second method the first step consists of dissecting up a flap of skin, superficial and deep fascia from the side of the face, and exposing the zygoma, taking care not to wound the parotid duct. The zygoma should be sawed through at each end and turned down, along with the masseter muscle. Next divide the coronoid process of the inferior maxilla and turn it upward with

the temporal muscle; this exposes the internal maxillary artery and pterygoid muscles. The internal maxillary artery should be tied at two points and divided. The external pterygoid muscle should then be carefully detached from its origin, thus exposing the inferior maxillary nerve as it emerges from the foramen ovale, which is the point at the base of the skull to be attacked with the trephine. If the inferior maxillary nerve has not been removed by a previous operation, it acts as an important guide in locating the foramen. The eminentia articularis and the root of the pterygoid process are additional guides, the foramen being usually just in front of a transverse line drawn through the eminence, and immediately behind the root of the external pterygoid plate. When the foramen has been clearly exposed, apply a small trephine, one-half of an inch in diameter, to the base of the skull and remove a button of bone which includes the margin of the foramen. The proximity of the foramen to the carotid canal renders this step a very important one. The disc of bone having been removed, the exposed dura mater, which bulges more or less into the trephine hole, should be opened and the inferior maxillary nerve, if not already exposed, sought. When found, it is traced to the Gasserian ganglion, which is then removed piecemeal. The operation is completed by replacing the tissues in as nearly the normal position as possible; the zygoma and the bone on each side of it are drilled and sutured, drainage is introduced, and the wound closed. The button of bone is not replaced. Extreme care should be exercised throughout this operation, which is one of great magnitude. The nutrition of the eyeball may be so seriously affected as to result in its destruction.

DISSECTION.—To continue the dissection, divide the larger or sensory root of the trifacial nerve, lift the Gasserian ganglion, and displace it forward and downward so as to better expose the smaller motor root and the large superficial petrosal nerve, both of which lie beneath the ganglion. The motor root of the trifacial nerve can be traced to the foramen ovale, where, with the inferior maxillary nerve, it makes its exit from the skull.

The **large superficial petrosal nerve** arises from the geniculate ganglion of the facial nerve, and will be seen emerging from the hiatus Fallopii. Thence it runs in a small groove on the side of the superior surface of the petrous portion of the temporal bone to reach the cartilage which fills the middle lacerated foramen; it pierces the cartilage and is joined by the great deep petrosal nerve from the carotid plexus of the sympathetic, thus forming the Vidian nerve.

The **small superficial petrosal nerve** arises from the facial nerve, emerges from the facial canal by way of a small foramen situated external to the hiatus Fallopii, passes to the foramen ovale, and joins the otic ganglion. Occasionally it passes through a small foramen situated between the foramina ovale and spinosum.

The **external superficial petrosal nerve** leaves the facial nerve and canal by way of a small foramen placed external to that for the small superficial petrosal nerve, on its way to join the plexus of the sympathetic upon the middle meningeal artery. This nerve is seldom found in the dissection of the interior of the base of the cranium, for in lifting up the endosteal layer of the dura mater the petrosal nerves are very apt to be severed unless the utmost care is observed.

The **Meningeal Arteries**—the anterior, the middle, the small, and the posterior meningeal—run between the skull and the dura mater, and are apt to be destroyed, or at least cut, when removing the dura mater; notwithstanding this they can be traced by the grooves in the bones which they occupy. The greater part of the anterior branch of the middle and the terminal part of the posterior meningeal arteries have been observed when removing the calvaria.

The **middle meningeal artery**.—The largest and most important of the meningeal arteries is the middle. As seen when dissecting the pterygo-maxillary region, both this and the small meningeal are branches of the internal maxillary artery. The middle meningeal artery runs between the two roots of the auriculo-temporal nerve and enters the cranial cavity by way of the foramen spinosum; it occupies a groove in the greater wing of the sphenoid bone, and almost immediately divides into two branches, the anterior and the posterior. Small branches of the middle meningeal artery pierce the cranial bones and anastomose with the vessels of the scalp.

The *anterior branch* runs through a groove across the great wing of the sphenoid, and continues into another groove in the anterior inferior angle of the parietal bone. The commencement of this latter groove for a distance of one-fourth to one-half of an inch is often bridged over by a thin plate of bone, and is thus converted into a canal. The vessel continues along the groove near the anterior border of the parietal bone, runs almost parallel with the coronal suture to within a short distance of the superior longitudinal sinus, and gives off branches which run upward to the vertex and backward toward the occipital bone. The sinus *alæ parvæ* or spheno-parietal venous sinus at times accompanies the artery for a part of its course, and may consequently be injured in fracture or during the manipulations of the surgeon.

The *posterior branch*, the smaller of the two, crosses the squamous portion of the temporal bone along the line of junction of the squamous with the petrous portion, and then upon the posterior inferior angle of the parietal bone, where it divides into its branches.

Extra-dural hemorrhage.—From the relation which the anterior branch of the middle meningeal artery holds to the anterior inferior angle of the parietal bone, it follows that fracture of this part of the skull is apt to result

in hemorrhage, which would be located between the bone and the dura mater. The vessel may be injured either by sharp bony spicula or by the sudden alteration in shape to which the skull is subjected in cases of severe head injury. It has already been noted that the dura mater is loosely attached to the vault of the cranium; this accounts for the size of the large extra-dural blood-clots occasionally seen. From the relation of this branch to the motor area of the brain it can readily be understood why the symptoms consequent upon the pressure of an extra-dural clot are largely, if not altogether, motor. These cases constitute an especially favorable class for trephining, which should be done as soon as the diagnosis is made, or as early as possible. If upon the removal of the clot the bleeding has not ceased, the vessel should be tied. This may necessitate enlarging the original trephine opening in order to expose the bleeding points. The author has found it necessary to tie both the anterior and the posterior branch. It occasionally happens that the injury to the middle meningeal artery occurs on the opposite side to that upon which the external lesion exists.

Point for trephining.—The point of election for applying the trephine in a suspected case of extra-dural hemorrhage, meningeal in origin, is at a point one and one-half inches behind and one inch above the external angular process of the frontal bone. When a simple or a compound depressed fracture is associated with the hemorrhage, the trephine should be applied near the fracture. To reach the posterior branch the trephine should be applied immediately below the parietal eminence, and on the same horizontal level as in the preceding operation. The opening can subsequently be enlarged in a downward or backward direction and the vessel thus brought into view.

Branches of the middle meningeal artery.—The middle meningeal artery gives off branches within the cranial cavity to the Gasserian ganglion: a petrosal branch, which enters the hiatus Fallopii to supply the facial nerve and anastomoses with the stylo-mastoid branch of the posterior auricular artery; a lacrymal branch which enters the orbit by way of the sphenoid fissure, or by a separate canal in the greater wing of the sphenoid bone, and anastomoses with the ophthalmic artery; a branch to the tensor tympani muscle; and branches which leave the cranial cavity through foramina in the great wing of the sphenoid bone to anastomose in the temporal fossa with the deep temporal arteries. It is accompanied by two veins which empty into the internal maxillary vein.

The **anterior meningeal arteries** are branches of the ethmoid arteries; they supply the dura mater of the anterior cranial fossa in the region of the median line. One of the *arteria receptaculi*, derived from the cavernous portion of the internal carotid artery, supplies the dura mater of the middle cranial fossa. It

anastomoses with the middle meningeal artery, and it also receives the name of anterior meningeal. The dura mater of the middle cranial fossa is supplied chiefly by the *small meningeal artery*, a branch of the internal maxillary, which enters the cranial cavity by way of the foramen ovale, and one or two branches from the ascending pharyngeal artery, which enter the cranial cavity through the middle lacerated foramen.

The **posterior meningeal arteries** are the cranial branches of the ascending pharyngeal, the occipital, and the vertebral arteries; those arising from the ascending pharyngeal and the occipital artery enter the cranial cavity by way of the posterior lacerated or jugular foramen, and those from the vertebral artery by way of the occipital foramen (foramen magnum); they supply the dura mater of the occipital or posterior cranial fossa.

The ascending pharyngeal artery also sends a meningeal branch through the middle lacerated foramen, and an occasional one through the anterior condyloid foramen.

The **meningeal veins**, with the exception of those accompanying the middle meningeal artery, empty into the sinuses.

INDEX.

In this Index the references in **heavy-face type** are to the pages containing plates illustrating the subject named. References in regular type are to the text.

- A.**
- Abducent n., 465, 728, **539**.
Vide Sixth Cranial Nerve.
- Abscess beneath temporal fascia, 620
cerebellar, 423
 trephining, 511
cerebral, 423
extradural, 423
 trephining, 511
intra-cranial, 511
mastoid, 420
of antrum of Highmore, 312
of cornea, 364
of face, 626
of frontal sinus, 311
of lacrymal sac, 644
of neck, 31, 47
of occipital triangle, 59
of pterygo-maxillary region, 692
of scalp, 617
orbital, 323
parotid, 657
 incision for, 658
 post-pharyngeal, 232
 temporo-sphenoid, 511
 trephining, 511
- Absence of iris, 368
- Accessory cartilages of nose, 293
 quadrate cartilages, 293
- Accommodation, 386
- Aene, 285
- Aeromio-thoracic a., **133**
- Adam's apple, 23
- Adduction of cornea, 348
- Air-chambers of nose, accessory, **314**
 orifices, **298**
- Ala cinerea, 547, **536, 542, 556**
- Alae of nose, 284
- Alcock, canal, 599
- Alveolar a., 684, **678**
- Ampulla of semicircular canals, 432, **439**
- Ampullae of semicircular canals, **427**
- Amputation of tonsil, 225
- Amygdala, 562, **560**
- Anastomosis of angular a. 611
 of anterior temporal a., 606
 of cerebellar a., posterior inferior, 450
 of cerebral a., 453
 of cerebral a., anterior, 416
 posterior, 453
 of cerebral a.s, 453
 of cervical a., ascending, **145**
 deep, 147
 of coronary a., 613
 inferior, 613
 superior, 643
 of facial a., 618
 transverse, 644
 of frontal a., 337, 606
 of inferior coronary a., 613
 labial a., 613
 of infra-orbital a., 676
 of lateralis nasi a., 644
 of lingual a., 114
 of mental a., 676
 of nasal a., 337
 of occipital a., 606
 of posterior auricular a., 606
 temporal a., 606
 of princeps cervicis a., 95
 of ramine a., 114
 of scapular a., posterior, 146
 of sublingual a., 115
 of superior coronary a., 613
 of supra-orbital a., 336, 605
 of thyroid a., inferior, 144
 of transverse facial a., 611
- Andersch, ganglion, 116
- Anesthesia of cornea, 379
 temporal a. in, 606
- Aneurysm, circoid, 606, **599**
- Angle, filtration, 391, **394**
 of chamber of eye, anterior, 391
- Angles of mouth, 210
- Angular a., 638, 611, **608, 613, 640**
 anastomosis, 644
 convolution, 486, 489, **474, 477**
 gyrus, 489. *Vide* Angular Convolution.
 vein, **35, 645**
- Aniridia, 368
- Annectant gyri, 485
- Annular synechia, **394**
 posterior, 395
- Annulus tympanicus, 403
- Anosmia, 302
- Ansa hypoglossi nerve, 66, 73, **71**
- Ansa Vieussenii, 85
- Anterior chamber of eyeball. *Vide* Chamber of Eyeball, Anterior.
- Antero-lateral fontanel, 584
- Anthelix. *Vide* Antihelix.
- Antihelix, 399, 660, **398, 661**
 fossa, 399, 660, **398, 661**
- Antitragiens m., **401, 663, 665**
- Antitragus, 399, 660, **398, 661**
- Antrum, mastoid, 412, **413**
 trephining, 415
 of Highmore, 312, **339, 350**
 abscess, 312
 cysts, 315
 dropsy, 315
 empyema, 312
 mucocoele, 312
 orifice, **298**
 tumors, 312
- Anvil, 423. *Vide* Incus.
- Aorta, **129, 133, 137**
- Aperture of larynx, **218**
 superior, 237, 247, **250**
- Apex of lung, 18
- Aphasia, 503
- Aponeurosis, palatine, 246, **242**
 of occipito-frontalis m., 615, **599, 627**
 pharyngeal, 231, **229, 243**
 supra-hyoid, 98
- Apoplexy, danger, 451
 internal capsule, 548
- Apparatus, lacrymal, 351, **350, 355**
- Appendages of eye, 618
- Aqueduct of Sylvius, 537, **483, 516, 528, 529**
- Aqueductus cochlea, **434, 436**
 orifice, **430**
 vestibuli, 431
 orifice, **430**
- Aqueous humor, 392
- Araclnoid, 438
 membrane of brain, **709**
 removal, 438
- Arantius, ventricle, 511
- Arbor vitae, 567, **516**
- Arch, supra-orbital, 593
 zygomatic, 596
 fracture, 586
- Arches, branchial, 25
 visceral, 25
- Arciform fibers, superficial, 554
- Arcus senilis, 361

- Area, dangerous, of eye, 368
of muscular sense in brain, 500
of tactile sensation in brain, 500
- Areas of brain, motor, 499, **501**
sensory-motor, 500
sensory, 499, **501**
- Areolar tissue of eyelids, 652
of scalp, 616
- Argyll Robertson pupil, 367
- Arnold's ganglion, 691
nerve, 81
- Arteria aberrans, 117
- comes nervi phrenici, 66
septum narium, 643
- Arteriae receptaculi, 729
- Arterial blood in facial vein, 647
- Arteries at base of brain, **452**
carotid, 23
branches, **87**
diagram, **87**
cerebral, anastomosis, 453
ciliary, 336, 379
of brain, 415, **444**
of ear, 665
of face, 640, 596, **608, 613**
of larynx, **263**
of neck, ligation, 160
of orbit, **334**
of scalp, 640, 588, 605, **608, 613**
of septum of nose, 643, **608, 613, 640**
hemorrhage from, 613
of thyroid gland, 126
of tongue, **105**
of tonsil, **105**
subclavian, differences between, 128
to brain, peculiarities, 453
- Artery, acromio-thoracic, **133**
alveolar, 684, **678**
angular, 638, 643, **608, 613, 640**
anastomosis, 613
anterior auricular, **608, 613, 620, 640**
deep temporal, 683, **678, 682, 686**
dental, 676
meningeal, 731
superior dental, 684, **686**
temporal, 606, **603, 608, 613, 640**
anastomosis, 606
- aorta, **129, 133**
- ascending cervical, **78, 79**
frontal, **447**
parietal, **447**
pharyngeal, **105**
- auditory, internal, 450
- auricular, 95
anterior, 606, **608, 613, 620, 640**
anastomosis, 606
deep, 683, **682**
of post-auricular, 96
posterior, 96, 606, **50, 70, 71, 78, 79, 203, 603, 608, 613, 620, 640, 678**
- Artery, auricular, anastomosis, 606
branches, 96
relations, 96
- axillary, **133**
- basilar, 119, 150, **137, 444, 452**
branches, 450
buccal, 684, **678, 682, 695**
carotid, common, 61, 62, 71, **39, 41, 70, 78, 129, 133, 164, 174, 177, 229**
aneurysm, 75
course, 74
irregularities, 186
ligation, 75, 179
collateral circulation, 185, **133**
line for, **20, 27, 67, 623**
operation to expose, **182**
position, 18
relations, 74, 180
external, 62, **50, 70, 78, 105, 133, 177, 229, 678, 682, 686**
branches, 86
irregularities, 187
ligation, 186
collateral circulation, 187
line for, 86, **20, 67**
operation to expose, **183**
relations, 86
internal, 62, 119, 445, **729, 50, 70, 78, 79, 133, 229, 334, 343, 405, 444, 452, 715**
course, 729
irregularities, 196
ligation, 195
collateral circulation, 196
line for, **20, 67**
operation to expose, **183**
relations, 119, 196
- central, of retina, 336, **380, 384**
- cerebellar, anterior, inferior, 450, **444, 452**
posterior, inferior, 449, **444, 452**
anastomosis, 450
superior, 450, **444, 452**
- cerebral, anterior, 446, **444, 452, 513**
anastomosis, 446
middle, 446, **444, 447, 452**
branches, 446
posterior, 453, **444, 452**
anastomosis, 453
- cervical, ascending, 114, **70, 78, 79, 138**
anastomosis, 115
deep, 117
anastomosis, 117
- Artery, cervical, superficial, 59, 116, **133**
transverse, 146. *Vide* Artery, Transversalis Colli.
choroid, anterior, 449, **444, 452**
posterior, **444, 452**
- ciliary, **377**
anterior, 336, 379, **377, 384**
posterior, **334**
long, 336, 379, **377, 384**
short, 336, 379, **377, 384**
- circumflex, anterior, **133**
posterior, **133**
- common carotid, **623**
line, **623**
- communicating anterior, 446, **444, 452**
posterior, 446, **444, 452**
- conjunctival, **384**
- coronary, inferior, of lip, 643, **608, 613, 640**
anastomosis, 643
course, 643
superior, of lip, 643, **608, 613, 640**
anastomosis, 643
- crico-thyroid, 91, **78, 123, 251**
- deep auricular, 683, **682**
temporal, anterior, **678**
posterior, 683, **678, 682**
- dental, anterior, **682**
superior, 684, **695**
inferior, 683, **678, 682, 686, 695**
middle superior, 695
posterior, 684, **682**
- descending palatine, 684, **682**
- diplois, of supraorbital, 336
- dorsalis lingue, 114, **105**
scapulae, **133**
- esophageal, of inferior thyroid, 145
- ethmoid, 337
anterior, 307, 337, **334**
branches, 337
posterior, 307, 337, **334**
- external carotid, **678, 682, 686**
pterygoid, 684, **682**
- facial, 92, 50, **70, 78, 79, 105, 133, 608, 613, 620, 621, 640**
anastomosis, 648
branches, 613
cervical portion, 92
branches, 92
course, 638
irregularities, 190
ligation, 190
line for, **20, 27, 67, 623**
operation to expose, **182, 183**
relations, 638
transverse, **608, 613, 620, 640, 678**

- Artery, facial, anastomosis, 644
 frontal, 337, 606, **603, 608, 613, 620, 640**
 anastomosis, 337, 606
 ascending, **447**
 inferior, **447**
 of anterior ethmoid, 337
 ganglionic, antero-lateral, **444**
 antero-median, **444**
 postero-median, **444**
 gingival, **682, 695**
 hyaloid, 385
 hyoid, 86
 incisive, 683, **682**
 inferior coronary, of lip, 643, **608, 613, 640**
 anastomosis, 643
 course, 643
 dental, 683, **678, 682, 686, 695**
 labial, 643, **608, 613, 640**
 anastomosis, 643
 infra-hyoid, 86, **50, 70**
 infra-orbital, 676, 684, **620, 678, 682, 686, 695**
 anastomosis, 676
 innominate, **78, 129, 133, 164**
 bifurcation, **70, 78**
 guide to, 166
 irregularities, 166
 ligation, 160, 165
 collateral circulation, 165
 line for, **20**
 operation to expose, **164**
 pulsations, 18
 relations, 165
 intercostal, **133**
 first, 117
 superior, 147, **133, 137**
 internal carotid, 729, **715**
 course, 729
 maxillary, 679, 680, **620, 621, 678, 682, 686, 695**
 branches, 683
 divisions, 683
 pterygoid, 684, **682**
 labial, inferior, **608, 613, 640, 682**
 anastomosis, 643
 lacrymal, 323, 336, **334**
 branches, 336
 laryngeal, inferior, 115, 265, **263**
 of inferior thyroid, 115
 superior, 91, 265, **50, 70, 78, 123, 251, 263**
 lateral nasal, **613**
 lateralis nasi, 644
 anastomosis, 644
 lenticulo-striate, 416
 lingual, 91, 114, **50, 70, 78, 79, 105, 133, 177**
 anastomosis, 114
 irregularities, 190
 ligation, 64, 188, **177**
 line for, **20, 67**
 operation to expose, **183**
- Artery, lingual, relations, 92
 malar, of lacrymal, 336
 mammary, internal, 146, **78, 79, 129, 133**
 masseteric, 684, **621, 678, 682**
 mastoid, 95, 96
 maxillary, internal, 679, 680, 683, **133, 620, 621, 678, 682, 686, 695**
 meningeal, anterior, 734
 middle, 592, 683, 733, **303, 682, 686, 690, 695, 709, 714, 715**
 branches, 733, 734
 wound, 734
 of anterior ethmoid, 337
 of ascending pharyngeal, 97
 posterior, 95, 149, 735, **444**
 small, 683, 735, **682, 686, 695**
 mental, 676, 683, **620, 682, 695**
 anastomosis, 676
 middle meningeal, 592, 733, **682, 686, 690, 695, 709, 714, 715**
 branches, 733, 734
 wound, 734
 superior dental, **695**
 temporal, **608, 613, 620, 640**
 mylo-hyoid, 104, 683, **682, 686, 695**
 nasal, 337, **682**
 anastomosis, 337
 lateral, **613**
 of anterior ethmoid, 337
 naso-palatine, 684
 occipital, 93, 606, **50, 70, 133, 603, 608, 613, 640**
 anastomosis, 606
 branches, 94
 irregularities, 195
 ligation, 94, 195
 operation to expose, **183, 192**
 relations, 93
 of cerebral hemorrhage, 146
 of frenum of tongue, 115, **105**
 of septum, 307
 ophthalmic, 335, **229, 334, 444, 715**
 branches, 335
 muscular, 337
 orbital, **608, 640, 682**
 palatine, ascending, 92
 descending, 307, 684, **105, 682**
 of ascending pharyngeal, 97
 palpebral, **682**
 inferior, 337
 of lacrymal, 336
 of supraorbital, 336
 superior, 337
 parietal, ascending, **447**
- Artery, parieto-temporal, **447**
 parotid, of posterior auricular, 96
 perineal, of female, transverse, 267
 periosteal, of supraorbital, 336
 pharyngeal, ascending, 97, **70, 78, 79, 105, 229**
 relations, 97
 of ascending pharyngeal, 97
 posterior auricular, 606, **603, 608, 613, 620, 640, 678**
 anastomosis, 606
 deep temporal, 683, **678, 682**
 dental, 684, **682**
 meningeal, 599
 temporal, 606, **603, 608, 613, 640**
 anastomosis, 606
 prevertebral, of ascending pharyngeal, 97
 princeps cervicis, 95, **133, 137**
 anastomosis, 95
 profunda cervicis, 174, **133, 137**. *Vide* Deep Cervical Artery.
 pterygoid, **678**
 external, 684, **682**
 internal, 684, **682**
 pterygo-palatine, 684, **682**
 ramine, 92, 114, **105, 221**
 anastomosis, 114
 recurrent, of lacrymal, 336
 retinal, **381**
 scapular, posterior, 59, 146, **70, 133**
 anastomosis, 146
 small meningeal, 683, 735, **686, 695**
 sphenopalatine, 307, 684, **682**
 spinal, anterior, 449, **444, 452**
 lateral, of vertebrae, 143
 posterior, 449, **444**
 sterno-mastoid, inferior, 446, **70, 78**
 middle, 58, 91, **50, 70, 78, 177**
 superior, 95, **70, 78**
 stylo-mastoid, 96
 subclavian, 23, 60, 127, 166, **50, 70, 78, 79, 133, 208**
 branches, 136, **87**
 compression, 23
 diagram, **87**
 first portion, **129, 164, 174**
 ligation, 135, 166
 irregularities, 170
 left, 128
 relations, 128
 ligation, collateral circulation, 135, **133**
 line for, **20, 67**

- Artery, subelavian, right, 127
 relations, 127
 second portion, 131
 ligation, 135, 166
 relations, 131
 third portion, 131
 guide, 175
 ligation, 132, 166, 169
 ligation, collateral circulation, 170
 operation to expose, 167
 relations, 131, 166
 variations, 132
 sublingual, 115, **78, 79, 105**
 anastomosis, 115
 submaxillary, 93
 submental, 93, **50, 70, 105, 682**
 relations, 93
 subscapular, **133**
 superficial cervical, **70**
 temporal, **620, 621, 640, 678, 682, 686**
 superior coronary, of lip, 643, **608, 613, 640**
 anastomosis, 643
 supra-acromial, of supra-scapular, 146
 supra-orbital, 336, 605, **197, 334, 603, 608, 613, 620, 640**
 anastomosis, 336, 605
 branches, 336
 operation to expose, **197**
 supra-scapular, 60, 145, **50, 70, 78, 79, 129, 133, 174**
 branches, 146
 relations, 145
 Sylvian, 446
 temporal, 606, **193, 621**
 anterior, 606, **603, 608, 613, 640**
 anastomosis, 606
 deep, 683, **678, 682, 686**
 in anesthesia, 606
 middle, **608, 613, 620, 640**
 operation to expose, **193**
 posterior, 606, **603, 613, 640, 678, 682, 686**
 superficial, **133, 620, 621, 640, 678, 682, 686**
 ligation, 195
 thoracic, long, **133**
 superior, **133**
 thyroid axis, 144, **78, 79, 174**
 inferior, 61, 144, **20, 78, 119, 133, 174, 177, 229**
 anastomosis, 144
 zygoid, inferior, branches, 144
 irregularities, 179
 ligation, 145, 179, **177**
 line for, **67**
 operation to expose, **174**
 superior, 86, **20, 50, 70, 78, 105, 123, 133, 177, 251**
 irregularities, 188
 ligation, 187, **177**
 line for, **67**
 operation to expose, **183**
 thyroideæ ima, 126, **133**
 tonsillar, 93
 of facial, **105**
 of dorsalis lingue, **105**
 tracheal, of inferior thyroid, 145
 transversalis colli, 59, 60, 146, **50, 70, 78, 129, 133, 174, 208**
 humeri, 145
 transverse, facial, 641, **608, 613, 620, 640, 678**
 anastomosis, 644
 transverse, of basilar, 450, **444, 452**
 trochlear, of supra-orbital, 336
 tympanic, 683, **682, 686**
 of ascending pharyngeal, 97
 vas aberrans, **133**
 vertebral, 61, 136, 449, **39, 70, 78, 79, 129, 133, 137, 152, 164, 174, 444, 452**
 branches, 143
 cervical portion, 136
 guide, 176
 irregularities, 176
 ligation, 143, 175
 occipital portion, 143
 operation to expose, **174**
 relations, 136, 175
 vertebral portion, 136
 Vidian, 684, **682**
 Articulation, crico-arytenoid, 276
 ligaments, 276
 crico-thyroid, 276, **263**
 movements, 276
 of head, 573
 of larynx, 276
 of neck, 573, 579
 of skull, 573
 temporo-maxillary, 573, **576, 577**
 blood supply, 574
 inter-articular fibro-cartilage, 574
 ligaments, 573
 internal lateral, 574
 movements, 574
 nerve supply, 574
 synovial membrane, 574
 Artificial membrana tympani, 420
 Aryteno-epiglottidean folds, 248, **212, 218, 236, 250, 258, 259**
 Aryteno-epiglottidean muscle, 261, **258, 259, 263**
 action, 262
 insertion, 261
 nerve supply, 262
 origin, 261
 Arytenoid cartilage, 275, **267, 271**
 Arytenoidens m., 256, **258, 259, 263**
 action, 261
 insertion, 256
 nerve supply, 256
 origin, 256
 Ary-vocalis of Ludwig, 261
 Ascending cervical a., **78, 79**
 pharyngeal a., **105**
 Aspiration of subarachnoid space, 442
 Asterion, 591, **506**
 Asthma, laryngeal, 262
 Astigmatism, 363
 Atrium of meatus of nose, 299
 Atrophy of testicle, 648
 of tongue, 220
 Attachments of dura mater of brain, 711
 Attic, 407, **405, 409, 422**
 Attolens aurem m., 605, **627**
 anastomosis, 605
 insertion, 605
 nerve supply, 605
 origin, 605
 Attrahens aurem m., 605, **627**
 action, 605
 insertion, 605
 nerve supply, 605
 origin, 605
 Auditory a., internal, 450
 canal, external, 403. *Vide*
 Auditory Meatus.
 meatus, external, 403, **405, 409**
 blood supply, 404
 lymphatics, 407
 nerve supply, 407
 occlusion, 404
 relations, 404
 sinus, 403
 veins, 407
 nerve, 438, 465, 729, **539.**
Vide Eighth Cranial Nerve.
 ossicles, 423
 stria, 547
 Anral vertigo, 437
 Auricle, 660, **661**
 cartilage, 400
 integument, 400
 landmarks, 660
 muscles, intrinsic, 400
 supernumerary, 400
 Auricular a., 95
 anterior, 606, **608, 613, 620, 640**
 anastomosis, 606
 deep, 683, **682**
 posterior, 96, 606, **50, 70, 71, 78, 79, 203, 603, 608, 613, 620, 640, 678**
 anastomosis, 606
 branches, 96
 relations, 96

- Auricular branch of auricularis magnus n., 28
of posterior auricular a., 96
fistula, 100
lymphatic glands, 702
vessels, 615
nerve, 81, 664
anterior, 688
great, **30, 609**
posterior, 97, 612, **51, 70, 71, 78, 79, 203**
region, dissection, 660
vein, posterior, 96, **35, 50, 51, 70, 645**
- Auricularis magnus n., 32, 38, **34, 51**
branches, 38
relations, 206
- Auriculo-temporal n., 205, 612, 688, **193, 303, 609, 613, 620, 686, 678, 690, 695**
divisions, 688
operation to expose, 205, **193**
- Axillary a., **133**
nerve plexus, 148. *Vide* Brachial Nerve Plexus.
- Axis of eyeball, 357
- Azygos uvulae m., 246, **242, 243**
action, 246
insertion, 246
origin, 246
- B.**
- Band, furrowed, of cerebellum, 562
horny, 526
- Bartholin, duct, 114
- Base of brain, **458**
arteries, **452**
structures, 456
of nose, 284
of skull, dislocation, 579
fracture, 585, 692
- Basilar a., 149, 550, **137, 444, 452**
branches, 450
plexus, **714**
- Bichat, fissure, 467, 532
- Bifurcation of innominate a., **70**
- Bimanual examination of female, 662
- Biventral lobe of cerebellum, **560**
- Blandin, gland, 219
- Blindness, word-, 503
- Body, ciliary, 368
geniculate, 538
external, 538, **463, 539, 552**
internal, 538, **463, 539, 542, 552, 556, 560**
of corpus callosum, **516**
of fornix, 522, **533, 546**
of lateral ventricle, 518, **519, 529, 569**
olivary, 554, **458, 539, 552**
corpus dentatum, 554
peduncle, 554
- Body, pineal, 538, **6, 539, 542, 556, 560**
peduncle, **516, 529, 536, 542, 556**
pituitary, **343, 458, 516, 539, 552, 565, 715**
restiform, 554, 557, **536, 542, 556**
subthalamic, 553
thyroid, **39**
vitreous, 385
- Bone, cheek, 596
frontal, sinuses, 591
hyoid, 23, 281, **109**
turbinate, **296**
inferior, 299, **350**
middle, 299, **350**
superior, 299
- Bones, nasal, 286
of face, fracture, 586
of skull, development, 584
- Bowman, membrane, 363
- Brachia of testes, 543
of testes, 543
- Brachial monoplegia, 504
nerve plexus, 60, 148, **51, 71, 149, 208**
branches, 148
dissection, 148
formation, 148
line for, **20, 67**
stretching, 209
- Brain, arachnoid membrane, **709**
areas, motor, 499, **501**
sensory, 499, **501**
arteries, 445, **444**
peculiarities, 453
base, **458**
arteries, **452**
structures, 456
centers, motor, 500
compression, 708
contour, 456
convolutions. *Vide* Convolutions of Brain.
definition, 455
dissection, 455
divisions, 455
foreign bodies, 511
fissures. *Vide* Fissure of Brain.
line, **506**
gyri. *Vide* Convolutions of Brain.
large, 455
lobes. *Vide* Lobes of Brain.
lobules. *Vide* Convolutions of Brain.
lymphatics, 445
membranes, 438, 704
nuclei, **536**
preservation, 717
removal, 712
section, 507
coronal, 567
sagittal, 567
small, 455
sulcus. *Vide* Fissure of Brain.
variations, 510
veins, 454
vessels, 438, 704
weight, 455
- Branchial arches, 25
cyst, 26
furrow, 26
- Breathing, stertorous, 637
- Bregma, 573, 588, **506**
- Bridge of nose, 284
- Broca's region, 503
- Bronchus, left, **129**
- Buccal a., 681, **682, 695**
branch of cervico-facial n., 669
of facial n., 609, **613, 620**
cavity, 209
glands, 213, 638
lymphatic glands, 702
nerve, 688, **678, 686, 695**
orifice, 210
portion of Stenson's duct, 659
- Buccinator m., 637, **229, 242, 621, 627, 678, 686**
action, 638
insertion, 637
nerve supply, 638
origin, **637**
relations, 637
- Bucco-pharyngeal fascia, 213, 637
- Bulb of cornua, posterior, of lateral ventricles, **529**
of penis, 553
olfactory, 456, **458, 483**
- Bulbs of fornix, 460
- Bulla ethmoidalis, 299, 315, **298, 314**
- Bundles of Vieq d'Azyr, 522
- Bursa, pharyngeal, 232, **233**
sublingual, 216
thyro-hyoid, 255
- Burse of neck, 156
- C.**
- Calamus scriptorius, 547
- Calcar avis, 491, 521, 531
- Calcarine fissure, 475, 491, **488, 494, 497, 516**
- Callosal fissure, 496, **488, 497, 516**
- Calloso-marginal fissure, 470, 489, 496, **474, 477, 480, 497, 516**
- Canal, auditory, external, 403.
Vide Meatus, Auditory.
hyaloid, 385, 392
lacrimal, 352
of Cloquet, 385
of His, 125
of Hugnier, 691
of Petit, 386, **360**
of Schlemm, 362, **360, 365, 384, 394**
of Stilling, 385
semicircular, 431, **427**
ampulla, 432
external, **427, 430, 439**
membranous, 437
posterior, **426, 430, 439**
superior, **427, 430, 439**
spiral, 432
Vidiam, **309**

- Canalis centralis modioli, 432
 reuniens, 437, **439**
- Cancerum oris, 626
- Canthus, external, 648
 internal, 648
- Capsular ligament of crico-aryte-
 noid articulation, 276
 of temporo-maxillary
 articulation, 573, **576**,
557
- ligaments of tympanum, 425
- Capsule, external, 548, **546**, **565**,
569
 internal, 547, **565**, **569**
 genu, 548
 in apoplexy, 548
 limb, anterior, 547, **546**
 posterior, 547, **546**
 of lens, 391
 of Tenon, 324, 342, **320**, **321**
 of thyroid gland, 126
- Caruncle of neck, 26
- Carcinoma of breast, pain, 45
- Cardiac n., **78**, **79**
 cervical, of pneumogast-
 ric, 83
 middle, 85
 sympathetic, inferior, 85
 superior, 84
- Caries of incus, 424
 of malleus, 424
 of vertebrae, **682**
- Carotid arteries, 23
 branches, **87**
 diagram, **87**
 artery, **682**
 common, 61, 62, 74, **39**,
41, **70**, **78**, **129**,
133, **164**, **174**,
177, **229**
 aneurysm, 75
 course, 74
 irregularities, 186
 ligation, 75, 179
 collateral circula-
 tion, 185,
133
 line for, **20**, **27**, **67**,
623
 operation to expose,
182
 position, 18
 relations, 74, 180
 external, 62, **50**, **70**, **78**,
105, **133**, **177**,
229, **678**, **686**
 branches, 86
 irregularities, 187
 ligation, 186
 collateral circula-
 tion, 187
 line for, 86, **20**, **67**
 operation to expose,
183
 relations, 86
 internal, 62, 119, 445, 729,
50, **70**, **78**, **79**,
133, **229**, **334**,
343, **405**, **444**,
452, **715**
 course, 729
 irregularities, 196
 ligation, 195
- Carotid artery, internal, ligation,
 collateral circula-
 tion, 196
 line for, **20**, **67**
 operation to expose,
183
 relations, 119, 196
 branch of glosso-pharyngeal,
 116
 lobe of parotid gland, 656
 sheath, 66
 contents, 73
 lymphatic glands, 73
 triangle, inferior, 54, 61, **55**
 contents, 61
 dissection, 61
 superior, 54, 62, **55**
 contents, 62
 dissection, 62
 tubercle, 24, **152**
- Cartilage, arytenoid, 275, **267**,
271
 cricoid, 21, 274, **123**, **251**,
254, **258**, **259**, **263**,
271
 ossification, 274
 cuneiform, 274, **218**, **236**,
250, **271**
 lateral, of nose, inferior, 286
 superior, 286
 of pinna, 665
 of Santorini, 275
 of Wrisberg, 274
 septal, of nose, 293, **291**
 tarsal, 593, 652
 thyroid, 23, 273, **123**, **251**,
254, **258**, **259**, **271**
 fracture, 274
 ossification, 274
- Cartilages, accessory quadrate, 293
 of auricle, 400
 of larynx, 270, **271**
 of nose, 286, **290**
 accessory, 293
 lateral, 286, **287**
 sesamoid, 293
- Cartilago triticea, 255, **254**, **263**
- Caruncula lachrymalis, 648, 651,
649
- Cataract, 391
- Catarth, nasal, 301
- Caudate nucleus, 525, 547, **529**,
542, **546**, **556**, **565**,
569
 head, **536**, **564**
- Cavernous sinus, 725, **715**
 relation of, to Gasserian
 ganglion, 725
 sections, **343**
- Cavity, buccal, 209
- Cavum sellae, **212**, **296**, **298**,
314
- Cells, ethmoid, 315, **321**
 mastoid, 412, 416, **413**
 sphenoid, 315, **212**, **296**,
298, **309**, **714**
- Center of hearing, 503
 of smell, 503
 of taste, 503
 of touch, 503
 of vision, 503
- Centers of brain, motor, 500
- Central a. of retina, 336, **360**, **384**
- Central fissure, 475
 lobe of cerebellum, 561
 of cerebrum, 470
 vein of retina, **360**, **384**
- Cerebellar abscess, 423
 trephining, 511
 artery, anterior inferior, 450,
444, **452**
 posterior inferior, 449,
444, **452**
 anastomosis, 450
 superior, 450, **444**, **452**
 veins, 454
- Cerebellum, 558, **458**, **477**, **516**,
536, **560**
 amygdala, 562
 arbor vite, 567
 corpus dentatum, 567
 fissure, great horizontal, 561,
560
 superior, 561
 flocculus, 562
 folium caecuminis, 561
 furrowed band, 562
 hemispheres, 461
 interior arrangement, 567
 laminae, 558
 laminated tubercle, 562
 lingula, 561
 lobe, biventral, **560**
 central, 561
 digastric, 562
 posterior inferior, 562,
560
 superior, 561, **560**
 quadrate, 561, **560**
 slender, **560**
 lobes, 558, 561, 562
 lobule, crescentic, anterior,
560
 posterior, **560**
 lobulus centralis, 561
 gracilis, 562
 monticulus cerebelli, 561
 nodule, 562
 peduncles, 562
 inferior, 567, **539**, **542**
 middle, 567, **458**, **539**,
542, **552**
 superior, 543, 567, **536**,
539, **542**
 position, 455
 pyramid, 562
 relations, 558
 tonsil, 562
 tuber valvulae, 562
 uvula, 562
 vallecule, 558
 vermiform process, 561
 inferior, 562
 superior, 561
- Cerebral abscess, 423
 arteries, anastomosis, 453
 artery, anterior, 446, **444**,
452, **513**
 anastomosis, 446
 middle, 446, **444**, **452**
 branches, 446
 posterior, 453, **444**, **452**
 anastomosis, 453
 fissures, lines, **589**
 ganglia, anterior, 525. *Vide*
 Corpus Striatum.

- Cerebral ganglia, posterior, 526.
Vide Optic Thalamus.
hemorrhage, a. of, 446
vein, superior, 709
- Cerebro-spinal fluid, 442
circulation, 442
- Cerebrum, 467, 477
commissure, anterior, 565
middle, 569
convolutions, 468. *Vide* Con-
volutions of Brain.
cortex, disease, 504
crus, 552
diagram, 474
dissection, 467
fibers, commissural, longitudi-
nal, 549
transverse, 549
peduncular, 548
fissures, 468. *Vide* Fissures
of Brain.
complete, 469
incomplete, 469
primary, 470
interior, dissection, 512
lobes, 469. *Vide* Lobes of
Brain.
lower level, 507
peduncles, 460, 550
position, 455
section, horizontal, 513
transverse, 546
surface anatomy, 468
inferior, 488, 497
internal, 516
median, 488, 497
veins, 451
white matter, 548
- Cervical a., ascending, 144, 70,
78, 79, 133
anastomosis, 145
deep, 147
anastomosis, 147
superficial, 59, 146, 70,
133
transverse, 59. *Vide*
Transversalis Colli
Artery.
fascia, deep, 45
course, 46
diagram, 41
fistulae, congenital, 25
ganglion of sympathetic, in-
ferior, 85
middle, 84
superior, 84
lymphatic gland, deep, 157
superficial, 37, 157
nerve, eighth, 149
anterior division, 79
fifth, 149
anterior division,
39, 71, 78
first, 539
fourth, 149
anterior division,
71, 78
plexus, 48, 65, 44
branch, descending,
45, 51
branches, 48
descending,
208
- Cervical nerve plexus, branches,
superficial, 38
supra-acromial,
34
supra-clavic-
icular, 34
supra-sternal,
34
dissection, 38, 65
second, anterior division,
71, 78
seventh, 149
anterior division,
71, 78
sixth, 149
anterior division,
39, 71, 78
superficial, 45, 34, 51
relations, 206
third, anterior division,
71, 78
portion of sympathetic n.,
85
vein, deep, 96, 147, 35, 645
superficial, 70
- Cervicalis ascendens m., 39
- Chamber of eye, anterior, 391,
360, 369, 394
angle, 391
sinus, 391
posterior, 392, 394
vitreous, 385, 360
Prussak's, 409
- Chambers of eye, 391
of nose, accessory air, 314
air, orifices, 298
- Cheek ligament, external, 324,
321
internal, 324, 321
- Cheek bone, 596
- Cheeks, 213
- Chiasm, optic, 459, 334
- Chimney-sweep's cancer, 610
- Choanae, 232
- Choked disc, 442
- Chorda tympani n., 426, 691,
422, 678, 686,
695
in otis media, 426
- Chordae Willisii, 719
- Chorio-capillaris, 374, 377
- Choroid, 374, 360, 376, 381
artery, anterior, 449, 444,
452
posterior, 453, 444, 452
layers, 374
melanotic sarcoma, 379
plexus, 511, 526, 511, 519,
523, 533, 536, 546, 565,
569
- Ciliary arteries, 336, 379
artery, 377
anterior, 336, 379, 377,
384
posterior, 334
long, 336, 379, 377,
384
short, 336, 379, 377,
384
body, 368
ganglion, 338. *Vide* Len-
ticular Ganglion.
branches, 311
- Ciliary muscle, 368, 360, 365,
369, 376, 394
action, 373
blood supply, 373
fibers, 373
nerve supply, 373
of orbicularis palpebra-
rum, 633
nerve, 376
long, 335, 376
posterior, 379, 326,
377
short, 379, 339, 377
posterior, 377
nerves, 379
process, 360, 365
processes, 374, 372
region of eyeball, 372
section, 365
vein, anterior, 379, 369, 377,
384
- Cilium, sebaceous gland, 353
- Cingulum, 517
- Circle of Willis, 445, 133, 444
- Circular sinus, 726, 714, 715
- Circulation, collateral. *Vide* Col-
lateral Circulation.
of cerebro-spinal fluid, 442
- Circulum iridis minor, 379, 377
- major, 379, 377
- Circulus tonsillaris, 698
- Circumflex a., anterior, 133
posterior, 133
nerve, 149
- Circumvallate papillae, 219, 109,
218, 236, 250
- Cirsoid aneurysm, 606, 599
- Cisterna basilis, 441
magna, 411
pontis, 441
subarachnoid, 411
- Clastrum, 548, 546, 564, 565,
569
- Clava, 557
- Cleft of iris, 368
palate, 244
operation, 215
soft, 246
- Clivus of monticulus cerebelli, 561
- Cloquet, canal of, 385
- Coats of eye, 361, 369
fibrous, 361
dissection, 361
sclerotic, 361
vascular, 367
- Cochlea, 432, 427, 434, 436
columnella, 432
cupola, 432, 427
membranous, 437
modiolus, 432
vestibule, 427
- Cochlear duct, 432, 437
nerve, 438
- Collateral circulation after liga-
tion of a., common
carotid, 185, 133
of a., external caro-
tid, 187
of a., internal caro-
tid, 196
of a., innominate, 165
of a., subclavian,
135, 133

- Collateral circulation after ligation of a., subclavian, third portion, 170
fissure, 495, **488, 494, 497**
- Coloboma, 368
- Color of iris, 367
- Column of medulla oblongata, lateral, **536**
- Columna, nasal, 594
- Columnella of cochlea, 432
- Comedones, 660
- Commissural fibers, longitudinal, of cerebrum, 549
transverse, of cerebrum, 519
- Commissure of cerebrum, anterior, 537, **516, 536, 565**
middle, 537, **516, 536, 542, 569**
palpebral, 648
posterior, 537, **516, 536**
optic, 459, **458, 483, 494, 516, 539, 565**
- Common carotid a., line, **623**.
Vide Carotid Artery, Common.
- triangle, anterior, 51
posterior, 51
- Communicantes, hypoglossi n., **66, 71**
noui n., 66
- Communicating a., anterior, 446, **444, 452**
posterior, 446, **444, 452**
vein, **70**
- Communications of facial vein, 617
- Complexus m., **39, 50, 71, 78**
- Compression of brain, 708
of subclavian a., 23
- Compressor narium minor m., **627**
nasi m., 629, **627**
action, 629
insertion, 629
nerve supply, 629
origin, 629
- Conarium, 538. *Vide* Pineal Body.
- Concha, 399, 660, **398, 661**
- Conductor sonorus, **542, 556**
- Condyle of inferior maxilla, excision, 584
- Cone of light, 419, **418**
- Congenital cervical fistula, 25
- Congestion of conjunctiva, 651
of frontal sinus, 311
of scalp, 615
- Conic cornea, 364
- Conjunctiva, 358, 651, **321, 346, 353, 355, 360, 365, 369, 377, 394, 632, 653**
congestion, 651
corneal portion, 358, 651
destruction of, 358
palpebral portion, 651
reflected portion, 651
sclerotic portion, 358, 651
- Conjunctival a., 358, **384**
papille, **353**
vein, **384**
- Conjunctivitis, purulent, 361
- Constrictor muscles of pharynx, inferior, 228, **71, 79, 123, 177, 229, 236, 251**
insertion, 228
origin, 228
middle, 228, **50, 71, 79, 105, 229**
superior, 228, **71, 79, 229**
muscles of pharynx, nerve supply, 231
- Contents of carotid sheath, 73
triangle, inferior, 61
superior, 62
- of occipital triangle, 57
- of parotid gland, 657
- of pterygo-maxillary region, 679
- of spheno-maxillary fossa, 693
- of subclavian triangle, 60
- of submaxillary triangle, 63, 98
- of zygomatic fossa, 693
- Convergent squint, 373
- Convolution, angular, 486, 489, **474, 477**
cuneus, 491
dentate, 496, 531
frontal, ascending, 482, **474, 477, 480**
inferior, 482, **474, 477, 480**
middle, 482, **474, 477, 480**
superior, 482, **474, 477, 480**
third, 482
- fusiform, 495, **488, 494, 497**
- hippocampal, 495, **488, 494, 497**
- infra-marginal, 492
- lingual, 495, **488, 494, 497**
- marginal, 485, **488, 497, 516**
- occipital, inferior, 491, **474, 477, 480**
middle, 491, **474, 477, 480**
superior, 491, **474, 477, 480**
- occipito-temporal, 495
- orbital, anterior, 485, **483, 488, 497**
inferior, **483**
internal, 485, **497**
posterior, 485, **483, 488, 497**
- paracentral, 489, **488, 497, 516**
- parietal, ascending, 486, **474, 477, 480**
inferior, 486, **480**
posterior, **474**
superior, 486, **477, 480**
- post-central, 486
- post-parietal, 489
- precuneus, 489
- quadrate, 489, **488, 497**
- Convolution, supra-marginal, 486, 489, **474, 477**
supra-parietal, **474**
temporal, inferior, 492, **474, 477**
middle, 492, **474, 477**
superior, 492, **474, 477**
temporo-sphenoid, inferior, 495, **494**
middle, 492, **494**
superior, 492, **494**
uncinate, 495
- Convolutions, 468
arrangement, 468
- Cords, vocal, 24
false, 248, 266, **212, 218, 250, 296**
true, 248, 266, **212, 218, 250, 296**
- Cornea, 362, **360, 365, 369, 376, 377, 394**
abscess, 364
adduction, 384
anesthesia, 379
blood supply, 364
conic, 364
depression, 348
elevation, 348
layers, 363
lymph spaces, 392
movements, 348
nerve supply, 364
rotation, 348
staphyloma, 364
ulcers, 363
wounds, 363
- Corneal portion of conjunctiva, 358, 651
- Corniculum laryngis, 275, **218, 236, 250, 267, 271**
- Cornu ammonis, 496, 526
of lateral ventricle, **519**
anterior, 521, **528, 529, 546**
middle, 521, **528, 529**
posterior, 521, **528, 529, 546**
bulb, **529**
- Corona ciliaris, 374
of glans penis, 627
radiata, 548
- Coronal section of brain, 567
suture, 573, 588
- Coronary a., inferior, of lip, 643, **608, 613, 640**
anastomosis, 643
course, 643
superior, of lip, 643, **608, 613, 640**
anastomosis, 643
- Corpora albicantia, 460, **458, 552, 569**
fimbriata, 522
quadrigemina, 538, **516, 536, 539, 542**
- Corpus albicans, 460, **516, 539**
callosum, 459, 467, 512, **513, 519, 536, 565, 569**
body, **516**
genu, 517, **488, 497, 516, 523, 564**

Corpus callosum, peduncle, 517
 raphe, 517
 rostrum, 517, **488, 497, 546**
 splenium, 517, **483, 497, 516, 523, 546**
 ventricle, 496
 dentatum of cerebellum, 567
 of olivary body, 551
 limbriatum, 526, 531, **519, 529**
 striatum, 525, **519, 523**
 Corrugator supercilii m., 634, **346, 632**
 action, 634
 insertion, 634
 nerve supply, 634
 origin, 634
 Cortex of cerebrum, disease, 501
 of lens, 391
 Corti, organ, 437
 Cranial n., eighth, 465, **458, 542, 556. Vide**
 Auditory Nerve.
 origin, **552**
 eleventh, 57, 466, **458, 542, 556**
 origin, **552**
 fifth, 465, **326, 339, 458, 542, 556**
 ophthalmic division, **326**
 origin, **552**
 first, 461. *Vide* Olfactory Nerve.
 fourth, 327, 462, **326, 339, 343, 458, 542, 556, 560. Vide**
 Pathetic Nerve.
 origin, **552**
 recurrent branch, **326**
 ninth, 466, **458, 542, 556**
 origin, **552**
 second, 462. *Vide* Optic Nerve.
 seventh, 465, **458**
 origin, **552**
 sixth, 311, 465, **326, 339, 458. Vide** Abducent Nerve.
 tenth, 76, 466, **458, 542, 556**
 origin, **552**
 third, 311, 462, **326, 458. Vide** Oculomotor Nerve.
 origin, **552**
 twelfth, 104, 467, **458**
 origin, **552**
 nerves, origin, **452, 715**
 superficial origin, **458**
 Craniectomy, 512
 Cranio-cerebral topography, 499
 Cranium, bones of, 588
 landmarks, 587, **589**
 Crescentic lobule of cerebellum,
 anterior, **560**
 posterior, **560**
 Crico-arytenoid articulation, 276

Crico-arytenoid articulation, ligaments, 276
 ligament, posterior, 276
 transverse, 276
 muscle, posterior, 263
 Crico-arytenoides lateralis m.,
 261, **259**
 action, 261
 insertion, 261
 nerve supply, 261
 origin, 261
 posticus muscle, 256, **258, 259**
 action, 256
 insertion, 256
 nerve supply, 256
 origin, 256
 Cricoid cartilage, 21, 274, **123, 251, 254, 258, 259, 263, 271**
 ossification, 274
 Crico-thyroid a., 91, **78, 123, 251**
 articulation, 267, **263**
 movements, 276
 membrane, 21, 255, **123, 251, 254**
 muscle, 255, **123, 251**
 action, 255
 insertion, 255
 nerve supply, 255
 origin, 255
 space, 24
 Crista Galli, **715**
 vestibuli, 431
 Crura cerebri, 460, 550
 of stapes, 424
 Crural monoplegia, 504
 Crus cerebri, 460, 550, **458, 483, 494, 516, 539, 542, 552, 556**
 crusta, 553, **488, 497**
 tegmentum, 553, **488, 497**
 nuclei, 553
 Crusta of crus cerebri, 460, 553, **488, 497**
 Crypts of iris, 392
 of tonsils, 224
 Crystalline lens, 386, **360, 372, 394. Vide** Lens.
 relations, 386
 Culmen, **560**
 of monticulus cerebelli, 561
 Cuneate nucleus, 557
 tubercle, 557
 Cuneiform cartilage, 274, **218, 236, 250, 271**
 Cuneus, 491, **488, 494, 497, 516**
 Cupola of cochlea, 432, **427, 434**
 Cutaneous n., internal, **149**
 lesser internal, **149**
 of perineum, male, 603
 Cyclon, 368
 Cyst, branchial, 26
 dermoid, of pinna, 400
 sebaceous, of pinna, 400
 Cystotomy, median perineal, 622
 Cysts of antrum of Highmore, 315

D.

Darwin's tubercle, 399, **398, 401, 527**
 Deafness, 424
 word-, 503
 Deceive, 561, **560. Vide** Clivus.
 Decussation of pyramids, 553,
 554, **458, 552**
 Deiters' nucleus, 465
 Density of temporal fascia, 618
 Dental a., anterior, **682**
 superior, 684, **695**
 inferior, 683, **678, 682, 686, 695**
 middle superior, **695**
 posterior, 684, **682**
 nerve, anterior superior, 697,
 595
 inferior, 691, **678, 686, 695**
 line for, **20, 67**
 operation to expose,
 182
 resection, 200
 middle superior, 694,
 695
 posterior superior, 694,
 678, 695
 Dentate convolution, 496, 531
 fissure, 496
 Dentition with otitis media, 426
 Depression of cornea, 347
 Depressor alæ nasi m., 630
 action, 630
 insertion, 630
 nerve supply,
 630
 origin, 630
 anguli oris m., 636, **627**
 action, 636
 insertion, 636
 nerve supply,
 636
 origin, 636
 relations, 636
 labii inferioris m., 636, **627**
 action, 636
 insertion, 636
 nerve supply,
 636
 origin, 636
 relations, 636
 Dermoid cyst of pinna, 400
 Descemet, membrane of, 363
 Descendens hypoglossi n., 73, **41, 51, 71, 78**
 noni n., 73
 Descending branch of cervical
 plexus, 45, **51**
 palatine a., 684, **105, 682**
 Destruction of conjunctiva, 385
 of tægmen antri, 420
 tympani, 420
 Development of bones of skull, 584
 of neck, 25
 of pinna, 400
 Deviation of nasal septum, 294
 Diagram of carotid a., **87**
 of cerebrum, **474**
 of cervical fascia, deep, **41**
 of membranous labyrinth,
 439

- Diagram of optic tract, **463**
 of subclavian a., **87**
 of triangles of neck, **55**
 of ventricles of brain, **528, 529**
- Diameter of eyeball, sagittal, **357**
 transverse, **357**
 vertical, **357**
- Diaphragm, faradization, **155**
 of mouth, **107**
 of pituitary fossa, **717**
- Diaphragma sellæ, **717, 212, 296, 298, 314**
- Digastric fossa, **591**
 lobe of cerebellum, **562**
 nerve, **669**
 muscle, **98, 71, 78, 79, 105, 117**
 action, **98**
 anterior belly, **50**
 blood supply, **98**
 insertion, **98**
 nerve supply, **98**
 origin, **98**
 posterior belly, **50**
 relations, **98**
- triangle, **54, 63**
 dissection, **63**
- Dilator naris m., **629**
 action, **629**
 insertion, **629**
 nerve supply, **629**
 origin, **629**
- narium m., anterior, **627**
 posterior, **627**
- tubæ, **408**
- Diploë, **599**
- Diploic branch of supraorbital a., **336**
 vein, **704, 705**
- Diplopia, **316**
- Dise, choked, **442**
- Disease, Ménière's, **437**
 middle ear, **420**
- Diseases involving facial v., **647**
- Dislocation of base of skull, **579**
 of lower jaw, **579**
- Dissection of auricular region, **660**
 of brachial nerve plexus, **148**
 of brain, **455**
 of carotid triangle, inferior, **61**
 superior, **62**
 of cerebrum, **467**
 interior, **512**
 of cervical plexus, **38, 65**
 of digastric triangle, **63**
 of dura mater, **711**
 of ear, **399**
 of eyeball, **357**
 of face, **625**
 incision, **597, 623**
 of fibrous coat of eye, **361**
 of larynx, **248**
 of lateral ventricles, **518**
 of lingual triangle, **61**
 of membranes of brain, **707**
 of middle ear, **407**
 of mouth, **209**
 of muscles of tongue, **108**
 of neck, **17, 26**
 incision, **623**
- Dissection of neck, muscles, **48**
 of nose, **284**
 of occipital triangle, **57**
 of orbit, **360**
 of pharynx, **227**
 of pons Varolii, **549**
 of pterygo-maxillary region, **676**
 of scalp, **601**
 of subclavian triangle, **59**
 of submaxillary triangle, **63**
 of supraclavicular triangle, **59**
 of temporal region, **625, 621**
 of tongue, **216**
 of triangles of neck, **54**
- Diverticulum, esophageal, **26**
 pharyngeal, **26**
- Divisions of nasal fossæ, **300**
- Dorsalis linguae a., **114, 105**
 scapulae a., **133**
- Double chin, **17, 31**
- Douche, nasal, **308**
- Dropsy of antrum of Highmore, **315**
- Duct, cochlear, **432, 437**
 lacrymal, **352**
 orifice, **355**
 lacrymo-nasal, **352, 350**
 lymphatic, **160**
 nasal, **352, 594, 314**
 orifice, **299, 298**
 of Bartholin, **114**
 of Meibomian gland, **353**
 salivary, obstruction, **114**
 Stenson's, **658, 608, 613, 621, 627, 640**
 course, **658**
 divisions, buccal, **659**
 masseteric, **659**
 line, **27, 623**
 relations, **658**
 thoracic, **128, 160, 129**
 relations, **131**
 thyro-glossal, **125, 216**
 Wharton's, **113, 70, 71, 78**
 relations, **113**
- Ducti Rivini, **111**
- Ducts, lacrymal, orifice of, **653**
 of Meibomian gland, **648**
 orifice, **653**
- Ductus endolymphaticus, **431, 437, 439**
- Dura mater, of brain, **708, 709**
 attachment, **711**
 blood supply, **726**
 dissection, **711**
 layers, **711**
 nerve supply, **726**
 processes, **717, 714**
 pulsations, **711**
 sarcoma, **711**
 sinuses, **718, 715**
 hemorrhage
 from, **719**
- E.**
- Eauche, **407**
- Ear cough, **81, 107**
 dissection, **399**
 external, **399, 601, 660, 405**
- Ear, external, arteries, **665**
 divisions, **660**
 muscles, **665**
 extrinsic, **605**
 intrinsic, **665, 663**
 pinna, **660, 661**
 landmarks, **701**
 internal, **399, 431**
 blood supply, **437**
 lymphatics, **438**
 veins, **437**
 labyrinth, bony, **430, 427**
 middle, **399, 407, 405**
 blood supply, **425**
 disease, **420**
 dissection, **407**
 inflation, Politzer's
 method, **411**
 Valsalva's method,
411
 lymphatics, **425**
 pyramid, **412**
 veins, **425**
- Edema of glottis, **269**
- Eighth cervical n., **149**
 anterior division, **79**
 cranial n., **456, 458, 542, 556, 715, Vide**
 Auditory Nerve.
 origin, **552**
- Ejaculator seminis m., **604**
- Elevation of cornea, **348**
- Eleventh cranial n., **57, 466, 729, 458, 542, 556, 715**
 origin, **552**
- Eminence frontal, **591**
- Eminentia collateralis, **495, 531, 519, 523**
 teres, **517, 536, 542, 556**
- Emmetropia, **395**
- Emmetropic eye, **388**
- Empysema of orbit, **323**
- Empyema of antrum of Highmore, **312**
 of frontal sinus, **311**
- Encephalocele, **591**
- Encephaloceles, sincipital, **286**
- Encephalon, **455, Vide** Brain.
- Endolymph, **431, 432**
- Entropion, **361**
- Embleation of eyeball, **396**
- Epiglottis, **270, 123, 218, 236, 250, 251, 254, 258, 259, 267, 296**
 action, **270**
 tubercle, **270**
- Epilepsy, Jacksonian, trephining, **504**
- Epiphysis cerebri, **528, Vide** Pineal Body.
- Epistaxis, **301, 613**
- Epithelioma of nose, **285**
- Equator of eyeball, **357**
- Equilibrium, maintenance, **432**
- Ergot, **531**
- Erysipelas, **616**
- Esophageal branch of inferior thyroid a., **115**
 diverticulum, **25**
- Esophagotomy, **226**
- Esophagus, **226, 39, 41, 129, 236**
 muscles, **229**

- Esophagus, relations, 226
 Ethmoid, **291**
 artery, 337
 anterior, 307, 337, **334**
 branches, 337
 posterior, 307, 337, **334**
 cells, 315, **321**
 sinuses, 315. *Vide* Ethmoid Cells.
 Eustachian tube, 408, **243, 405, 409**
 blood supply, 412
 mucous glands, 411
 nerve supply, 412
 occlusion, 411
 orifice, 232, **298, 422**
 relations, 411
 Evisceration of the eyeball, 396
 Excision of condyle of inferior maxilla, 584
 of eyeball, 396
 of inferior maxilla, 583
 of larynx, 281
 of superior maxilla, line of incision, **572**
 of tongue, 223
 of upper jaw, 579
 Exenteration of orbital contents, 396
 Exophthalmos, 357
 Expression, facial, 596
 External auditory canal, 403
 capsule, 548, **546, 565, 569**
 ear, 399
 lateral ligament of temporo-maxillary articulation, 574
 Extradural abscess, 423
 trephining, 511
 hemorrhage, 711, 733
 trephining in, 734
 Extrinsic m. of tongue, **109**
 Eye. *Vide* Eyeball.
 chamber, anterior, 391, **360, 369, 394**
 angle, 391
 sinus, 391
 posterior, 392, **394**
 vitreous, 385, **360**
 chambers, 391
 coats, 361, **369**
 dangerous area, 368
 emmetropic, **388**
 enucleation, 396
 evisceration, 396
 excision, 396
 hyperopic, **389**
 landmarks, 593
 lymph passage, anterior, 392
 posterior, 392
 myopic, **389**
 refracting media, 361
 section, **360**
 vascular coat, 367
 Eyeball, 357, **330, 334, 649**
 axis, 357
 blood vessels, **384**
 chamber, anterior, 391, **360, 369, 394**
 ciliary region, 368, **372**
 section, **365**
 coats, 361, **369**
 diameter, sagittal, 357
 transverse, 357
 Eyeball, diameter, vertical, 357
 dissection, 357
 equator, 357
 inflation, 318
 lymphatic system, 392
 mobility, 357
 pole, anterior, 357
 posterior, 357
 sinking, 357
 suspensory ligament, 324
 veins, 379
 Eyebrow, 618
 muscles, 630
 Eyelash, **353**
 Eyelashes, 618, 651
 Eyelid, section, sagittal, **353**
 skin, **353**
 Eyelids, 352, 618, 652
 areolar tissue, 652
 blood supply, 655
 lymphatics, 655
 muscles, 630
 nerve supply, 655
 veins, 655

F.
 Face, abscess, 626
 appearance, 592
 arteries, 596, **608, 613, 640**
 bones, fracture, 586
 dissection, 625
 incision, **597, 623**
 fascia, superficial, 626
 incision for dissecting, **597, 623**
 landmarks, 592
 lymphatics, 703
 muscles, 626, **613, 627**
 nerves, 691, **609, 613, 620**
 skin, 625
 surface markings, 592
 vascularity, 617
 veins, **35, 645**
 wounds, 617
 Facial a., 92, 638, **50, 70, 78, 79, 105, 133, 608, 613, 620, 621, 640**
 anastomosis, 648
 branches, 643
 cervical portion, 92
 branches, 92
 course, 638
 irregularities, 190
 ligation, 190
 line for, **20, 27, 67, 623**
 operation to expose, **182, 183**
 relations, 638
 transverse, 611, **608, 613, 620, 640, 678**
 anastomosis, 644
 expression, 596
 monoplegia, 504
 nerve, 165, 666, 728, **51, 71, 78, 79, 203, 539, 620, 621. Vide** Seventh Cranial Nerve.
 auricularis magnus, 38
 branches, 666
 Facial nerve, buccal branch, 669, **609, 613, 620**
 course, 666
 digastric branch, 669
 divisions of, facial, 666
 intra-cranial, 666
 temporal, 666
 infra-maxillary branch, **34, 620**
 infra-orbital branch, **609, 613, 620**
 line for, **20, 27, 67**
 malar branch, **609, 613, 620**
 operation to expose, 666, **203**
 paralysis, 670
 stretching, 205
 stylo-hyoid branch, 669
 supra-maxillary branch, 670, **609, 613, 620**
 temporal branch, 612, **609, 613, 620**
 vein, 93, 644, **35, 50, 70, 613, 620, 621, 645**
 arterial blood in, 617
 communications, 647
 course, 647
 deep, 687
 diseases involving, 647
 line, **623**
 relations, 93, 647
 transverse, **35, 645**
 Facies Hippocratica, 593
 Falx cerebelli, 717, 718, **714**
 cerebri, 512, 712, 717, 718, **714**
 Faradization of diaphragm, 155
 Far-sightedness, 363
 Fascia, bucco-pharyngeal, 213, 226
 cervical, deep, 45
 course, 46
 diagram, **41**
 deep, of neck, **34**
 dentata, 496, 531, **536**
 orbital, 323, **320, 321**
 lamina, 323
 parotid, 520
 pretracheal, 47, **39, 41**
 prevertebral, 46, **39, 41**
 salpingo-pharyngeal, 408
 superficial, of face, 490
 of neck, 26
 of scalp, 602, **599, 603**
 temporal, 618, **620**
 abscess beneath, 618
 density, 618
 relations, 618
 Fat, orbital, 323, **326, 330, 632**
 foreign body, 323
 Fauces, isthmus, 213, 221, 237
 pillar, anterior, **212, 218, 250**
 posterior, **212, 218, 236, 250**
 pillars, 224
 recess, 221
 Fenestra ovalis, 420, **427**
 rotunda, 420, **427**
 Fever blister, 210
 Fibers, arciform, superficial, 554

- Fibro-cartilage, interarticular, of temporo-maxillary articulation, 574
- Fibrous coat of eye, 361
dissection, 361
- Fifth cervical n., **149**
anterior division, **39, 71, 78**
cranial n., 465, **326, 339, 458, 542, 556**
ophthalmic division, **326**
origin, **552**
nerve, 539, 675, 728, **695, 715**
branches, 675
ventricle, 525, **497, 516, 523, 565**
- Filiform papilla, 219
- Fillet, 543, **539**
- Filtration angle, 391, **394**
- Fimbria, 526
- First cervical, n., 727, **539**
cranial n., 461. *Vide* Olfactory Nerve.
thoracic n., anterior division, **79**
- Fissura palpebrarum, 648
- Fissure, calcarine, 475, 491, **488, 494, 497, 516**
callosal, 496, **488, 497, 516**
calloso-marginal, 470, 489, 496, **474, 477, 480, 497, 516**
central, 475. *Vide* Fissure of Rolando.
collateral, 495, **488, 494, 497**
dentate, 496
frontal, inferior, 481, **474, 477, 480**
line, 508, **506**
superior, 481, **474, 477, 480**
line, 508, **506**
hippocampal, 496, **488, 494, 497, 536, 569**
pia mater, **546**
horizontal, of brain, 467
hypoglossal, 554
intra-parietal, 485, **474, 477, 480**
line, 509
longitudinal, 459, **480**
line, 507, **506**
of brain, 467
median, longitudinal, 544
posterior, **542**
occipital, inferior, 490
middle, 490, **477, 480**
posterior, line, **506**
superior, 490, **477, 480**
transverse, 490, **477, 480, 572**
of anus, 591
of Bichat, 467, 532
of cerebellum, great horizontal, 561, **560**
superior, 561
of helix, 400, 666
of medulla oblongata, anterior median, 553, **552**
postero-median, 553
- Fissure of Rolando, 475, **474, 477, 480, 516**
line, 507, **506**
of Santorini, 666, **401, 663**
of Sylvius, 456, 470, **471, 474, 477, 569**
line, 507, **506**
olfactory, 456, 482, **488, 497**
orbital, 456, 482. *Vide* Triradiate Fissure.
palpebral, 593, **649**
paracentral, 489, **488, 497, 516**
parallel, 492, **477**
parietal, **572**
parieto-occipital, 475, **474, 477, 480, 488, 494, 497, 516**
line, 508
post-central, 485, **474**
post-olivary, 554
precentral, 481, **474, 477, 480**
line, 508
sphenoid, nerves in, 342
structures traversing, **343**
subparietal, 489, 496, **488, 497, 516**
temporal, middle, **474, 477**
superior, **474**
temporo-sphenoid, inferior, 492, **488, 494, 497**
middle, 492, **494**
line, 510, **506**
superior, 492, **494**
line, 510, **506**
transverse, 467, 481. *Vide* Fissure, Precentral.
line, 507
triradiate, 456, 482, **458, 483, 488, 497.** *Vide* Fissure, Orbital.
- Fissures, cerebral, lines, **589**
of brain, lines, **506**
of cerebrum, 468
complete, 469
incomplete, 469
primary, 470
- Fistula, auricular, 400
salivary, 659
- Fistule, cervical, congenital, 25
lachrymalis, 311
- Flocculus of cerebellum, 562
- Floor of fourth ventricle, **536**
- Fluid, cerebro-spinal, 442
- Fold, aryteno-epiglottidean, 248, **218, 250, 258, 259**
glosso-epiglottidean, 216, **218**
lateral, 216, **250**
median, 216, **250**
interarytenoid, 218, **250**
- Folds, aryteno-epiglottidean, 248
of membrana tympani, 419
- Folium cauminis of cerebellum, 561, **560**
- Fontana, spaces, 362, 392, **365**
- Fontanel, anterior, 584, 588
antero-lateral, 584
posterior, 584, 588
postero-lateral, 584
- Fonticulus gutturis, 18
- Foramen cecum, 216, **218, 236, 250, 715**
commune anterius, 537
infra-orbital, 595, 699
magnum, structures traversing, 461
magnum, superior, 718
mental, 595
occipital, superior, 718
of Key, 441, 544
of Magendie, 441, 544
of Monro, 518, 537, **516, 519, 528, 529**
of Retzius, 441, 544
of spheno-maxillary fossa, 693
pterygo-palatine, 693
rotundum, 693, **309**
sclerae, 361
spheno-palatine, 693
superior occipital, 718
supra-orbital, 595
- Forceps minor, 517
major, 517
- Foreign bodies in brain, 511
body in orbital fat, 323
- Foreskin, 628
- Formatio reticularis, 550, 553, **483**
- Fornix, 522, **488, 497, 516, 523, 569**
body, 522, **533, 546**
bulbs, 460
conjunctivæ, **320**
pillar, anterior, 522, **516, 529, 533, 536, 542, 546, 556**
posterior, 522, **523, 536, 546**
- Fossa, digastric, 591
innominata, 269
lacrymal, 316
of antihelix, 339, 660, **398, 661**
of helix, 339, 660, **398, 661**
patellar, 385
pituitary, diaphragm, 717
scaphoid, of ear, 660
scaphoidea, 399
spheno-maxillary, 693
contents, 693
foramina, 693
supra-clavicular, **18, 21**
supraclavicularis minor, **18, 21**
supra-sternal, **18, 21**
zygomatic, 693
contents, 693
- Fosse, nasal, 294
anterior view, **306**
divisions, 300
lymphatics, 307
mucous membrane, 309
olfactory portion, 300
posterior view, **309**
respiratory portion, 300
- Fourth cervical n., anterior division, **71, 78, 149**
cranial n., 327, 462, **326, 339, 343, 458, 542, 556, 560.** *Vide* Pathetic Nerve.

- Fourth cranial n., origin, **552**
 recurrent branch, **326**
 nerve, 728, **715**
 ventricle, 544, **516, 528, 529, 560**
 floor, **536**
- Fovea centralis, 380
 inferior, 517
 hemielliptica, 431, **430**
 hemispherica, 431, **430**
 superior, 517
- Fracture into frontal sinus, 311
 of bones of face, 586
 of hyoid bone, 281
 of inferior maxilla, 586, **581**
 of lacrymal bone, 586
 of nasal bones, 286, 586
 of skull, 581
 base, 585
 vault, 585
 of superior maxilla, 586
 of thyroid cartilage, 274
 of zygomatic arch, 586
- Fractures, compound, of skull, 707
 of skull, base, 692
- Frænum epiglottidis, 216
 labii inferioris, 210
 superioris, 210
- Frenulum, 513
 veli, **560**
- Frenum of tongue, 215
 artery, 115, **105**
- Frontal a., 337, 606, **603, 608, 613, 620, 640**
 anastomosis, 337, 606
 ascending, **447**
 inferior, **447**
 bone, sinuses, 591
 branch of anterior ethmoid a., 337
 convolution, ascending, 182, **474, 477, 480**
 inferior, 482, **474, 477, 480**
 middle, 482, **474, 477, 480**
 superior, 482, **474, 477, 480**
 diploic v., 707, **705**
 eminences, 591
 fissure, inferior, 481, **474, 477, 480**
 line, 508, **506**
 superior, 481, **474, 477, 480**
 line, 508, **506**
 lobe, 456, 475, 481
 inner surface, 485
 landmarks, 508
 orbital surface, 482
- Lymphatics, 615
 nerve, 327, **326, 339, 343**
 sinus, 308, **298, 314, 339, 355**
 congestion, 311
 empyema, 311
 fracture, 311
 polypus, 311
 pus, 311
 sinuses, **653, 705, 709**
 suture, 573, 588
- Frontal vein, **35, 645**
 Frontalis m., 615, **627. Vide**
 Occipito-frontalis Muscles.
- Fronto-sphenoid diploic v., 707, **705**
 Frost-bite of pinna, 400
- Fungiform papille, 219, **218, 250**
- Fungus, 648
- Funiculus caruncatus, 554, 557, **536, 542, 556**
 gracilis, 554, 557, **536, 542, 556**
 of Rolando, 554, 557
- Furrow, branchial, 26
 of medulla oblongata, antero-lateral, 554
- Furrowed band, 562
- Fusiform convolution, 495, **488, 494, 497**
- G.**
- Galen, vein, **714**
 veins, 442, 532, **533**
- Ganglia, cerebral, anterior, 525.
Vide Corpus Striatum.
 posterior, 526. *Vide*
 Optic Thalamus.
 of pneumogastric n., 76
- Ganglion, Arnold's, 691
 ciliary, 338. *Vide* Ganglion, Lenticular.
 branches, 344
 Gasserian, 730, **326, 339, 695, 715**
 branches, 730
 relations, 730
 to cavernous sinus, 725
 removal, 731
 resection, 199
 intercarotid, 76
 jugular, 116
 lenticular, 338, **326, 339. Vide**
 Ganglion, Ciliary.
 sensory root, 335
 Meckel's, 697, **303, 686, 690**
 of Andersch, 116
 of sympathetic cervical, inferior, 85
 middle, 84
 superior, 84
 ophthalmic, 338
 otic, 691, **303, 690**
 petrous, 116
 sphenopalatine, 697
 submaxillary, 113
- Ganglionic a., antero-lateral, **444**
 antero-medial, **444**
 postero-medial, **444**
- Gangrene of pinna, 400
- Gasserian ganglion, 730, **326, 339, 695, 715**
 branches, 730
 relations, 730
 to cavernous sinus, 725
 removal, 731
 resection, 199
- Geniculate bodies, 538
 external, 538
 internal, 538
 body, external, **463, 539, 552**
 internal, **463, 539, 542, 552, 556, 560**
- Genio-hyo glossus m., 111, 220, **78, 79, 105, 109, 212, 296**
 action, 111
 blood supply, 111
 insertion, 111
 nerve supply, 111
 origin, 111
 relations, 111
- Genio-hyoid m., 107, **78, 79, 105, 109, 212, 296**
 action, 108
 blood supply, 107
 insertion, 107
 nerve supply, 107
 origin, 107
- Genu of corpus callosum, 517, **488, 497, 516, 523, 564**
- Gingival a., **682, 695**
- Glabella, 507, 588, 594, **506**
- Gland, lacrymal, **653**
 parotid, 656, **608, 613, 627, 640**
 contents, 657
 lobe, carotid, 656
 glenoid, 656
 pterygoid, 656
 removal, 658
 sensory nerves, 657
 wounds, 658
- Glands, auricular, posterior, **157**
 buccal, 213, 638
 cervical, deep, **157**
 superficial, 37, **157**
 infraclavicular, **157**
 labial, 210
 lacrymal, 323, 328, **326, 330, 334, 339, 355**
 inferior, 328
 superior, 328
 suspensory ligament, 328
- Lymphatic, auricular, posterior, 702
 buccal, 702
 lingual, 703
 mastoid, 702
 maxillary, internal, 703
 occipital, 702
 of head, 702
 parotid, 657, 702
 posterior pharyngeal, 703
 submaxillary, 702
 suboccipital, 702
- Meibomian, 593, 652, **346, 355, 632, 653**
 duct, **353**
 ducts, 648
 orifice, **653**
- molar, 213
 mucous, of Eustachian tube, 411
 of larynx, 269
 of nose, 302
 occipital, **157**
 of Blandin, 219
 of carotid sheath, 73
 of neck, 159, **157**

- Glands of Nuhn, 219
of tongue, 219
parotid, 63, **157**
pineal, 539. *Vide* Body,
Pineal.
sebaceous, of cilium, **353**
sublingual, 113
 blood supply, 114
 nerve supply, 114
 relations, 113
submaxillary, 63, 103, 113,
51, 157, 177
 relations, 103
sweat, of Moll, **353**
thyroid, 23, 122, **123, 129,**
251
 arteries, 126
 capsule, 126
 in tracheotomy, 122
 isthmus, **251**
 nerves, 126
 relations, 122
 structure, 122
 Waldeyer's, **353**
- Glaucoma, 395
 pain, 362
- Glossio-epiglottidean fold, 216,
218
 lateral, 216, **250**
 median, 216, **250**
- Ligament, 270
 pouch, 216
 valleculæ, 216
- Glossio-pharyngeal n., 115, 116,
466, 729, **79, 539. Vide**
Ninth Cranial Nerve.
 relations, 116
 tympanic branch, 426
- Glottis, edema of, 269
 false, 266
 respiratoria, 266
 vocalis, 266
- Goitre. *Vide* Thyroid Gland.
- Gracile nucleus, 557
- Gracilis funiculus, 557
- Great horizontal fissure of cerebel-
lum, 261
- Groove, lacrymal, 317
- Guide to subclavian a., third
 portion, 175
 to vertebral a., 176
- Gum boil, 214
- Gums, the, 214
- Gustatory n., 112, 688
- Gyri, 468. *Vide* Convolutions,
 annectant, 485
 operti, of island of Reil, **471**
- Gyrus, angular, 489
 fornicatus, 499, **488, 497,**
516
 rectus, 482, **483, 488, 497**
- H.**
- Hammer, 423. *Vide* Malleus.
- Handle of malleus, **418, 422**
- Harelip, 213, 614
 operation, 210, 213, 614
 hemorrhage in, 614
- Head, arteries, 573
 lymphatic glands, 702
 nerves, operations, 196
 of caudate nucleus, **536**
- Head of malleus, **422**
 veins, 665
- Headache, trephining, 512
- Hearing, center, 503
 organ, 399
- Helicis major m., 665, **401, 663**
 minor m., 665, **401, 663**
- Helicotrema, 432
- Helix, 399, 660, **398, 401, 661,**
663
 fissure, 400, 666
 fossa, 399, 660, **398, 661**
- Hematoma of scalp, 617
- Hemianopsia, 462, 504
- Hemiplegia, 504
 crossed, 550
- Hemispheres of cerebellum, 461
- Hemorrhage, cerebral, a. of, 446
 extra-dural, 711, 733
 trephining in, 734
 from artery of septum, 643
 from nose, 301
 from sinus of dura, 719
 in operation for hare-lip, 644
 into pons Varolii, 550
 into pterygo-maxillary re-
 gion, 692
 subconjunctival, 358
- Herpes cervico-occipitalis, 45
 labialis, 210
- Hiatus semilunaris, 299, **298,**
314
- Highmore, antrum of, 312, **339,**
350
 abscess, 312
 cysts, 315
 dropsy, 315
 empyema, 312
 mucocœle, 312
 orifice, **298**
 tumors, 312
- Hippocampal convolution, 495,
488, 494, 497
 fissure, 196, **488, 494, 497,**
536, 569
 pia mater, **546**
- Hippocampus major, 496, 526,
519, 523, 529, 536, 546
 minor, 491, 521, 531, **519,**
523, 529
- His, canal, 125
- Horizontal division of lateral
 sinus, 720
 fissure of brain, 467
- Hornor's m., 633. *Vide* Tensor
 Tarsi Muscle.
- Horny band, 526
- Huguier, canal, 691
- Humor, aqueous, 392
- Hutchinson, test teeth of, 214
- Hyaloid artery, 385
 canal, 385, 392
 membrane, 385
- Hydrocephalus, internal, 412
- Hyo-epiglottidean ligament, 270
- Hyo-glossus m., 108, 220, **78, 79,**
105, 109, 177
 action, 108
 blood supply, 108
 insertion, 108
 nerve supply, 108
 origin, 108
 relation, 108
- Hyoïd a., 86
 bone, 23, 281, **109, 123**
 fracture, 281
- Hypermetropia, 362, 373, 395
- Hyperopia, 395
- Hyperopic eye, **389**
- Hypertrophy of pharyngeal tonsil,
 232
- Hypo-glossal fissure, 554
 membrane, 216, 220, 270
 nerve, 104, 112, 177, 467,
 554, 729, **51, 71, 78,**
79, 539. Vide Twelfth
 Cranial Nerve.
 paralysis, 104
 relations, 104
- Hypopyon, 392
- I.**
- Incision for abscess of parotid, 658
 for dissection of face, **597,**
623
 of neck, **623**
 for exposing facial n., **672**
 infra-orbital n., 699
 for laryngotomy, **21**
 for tracheotomy, **21**
 Wilde's, 591
- Incisive a., 683, **682**
 branch of mylo-hyoid n., 691,
695
- Incisura cerebelli anterior, 561
 posterior, 561
- intertragicæ, 399, 660, **398,**
661
 marsupialis, 561
 Santorini, 403
 thyroidea, **254, 271**
- Incus, 423, **405, 409, 413, 422**
 caries, 424
 ligament, 424
 posterior, **422**
 long process, **418**
 os orbiculare, 424
- Inferior condyle, excision, 584
 maxilla, excision, 583
 fracture, 586
 oblique m., **339**
- Inflammation of scalp, 617
- Inflation of eyeball, 318
 of middle ear, Politzer's me-
 thod, 411
 Valsalva's method,
 411
- Infraclavicular lymphatic gland,
157
- Infra-hyoid a., 86, **50, 70**
 vein, **117**
- Infra-marginal convolution, 462
- Infra-maxillary branch of cervico-
 facial n., 45
 of facial n., 670, **34, 620**
- Infra-orbital artery, 676, 684, **620,**
678, 682, 686, 695
 anastomosis, 676
 branch of facial n., 669, **609,**
613, 620
 foramen, 595, 699
 margin, 316, 594
 nerve, 675, 697, **609, 620,**
695
 branches, 675, 697
 labial, 675, **620**

- Infra-orbital nerve, branches,**
 nasal, 675, **620**
 palpebral, 675, **620**
 operation to expose, 699
 structure involved,
 699
 resection, 199
 plexus of nerves, 669, 675
 vein, 676
Infraorbital portion of larynx, 296
Infra-trochlear n., 335, 326, 609,
613, 620
Infundibuliform fascia, 613
Infundibulum, 539
Inion, 591, 506
Injuries of neck, 31
Innominate a., 78, 129, 133,
164
 bifurcation, **70, 78**
 guide, 166
 irregularities, 166
 ligation, 160, 165
 collateral circula-
 tion, 165
 line, **20**
 operation to expose, **164**
 pulsations, 18
 relations, 165
 vein, **35, 645**
 left, **129**
 right, **129**
Integument of auricle, 400
Interarticular fibro-cartilage of
temporo-maxillary articulation,
574
Interarytenoid fold, 218, 236,
250
 ganglion, 76
Intercostal a., 133
 first, 147
 superior, 147, **133, 137**
 nerve, first, **149**
Interosseal space, 159
Internal capsule, 547, 565, 569
 genu, 548
 hemorrhage, 548
 limb, anterior, 547, **546**
 posterior, 547, **546**
 ear, 399, 431
 blood supply, 437
 lymphatics, 438
 veins, 437
 lateral ligament of temporo-
 maxillary articulation, 574
 maxillary v., **35**
Interpeduncular space, 459
Interstitial keratitis, 362, 363
Intersutural membrane, 617
Intervaginal lymph space, 395
Intra-cranial abscess, 511
 division of facial n., 666
 nerves, 727
 course, 727
 neurectomy of inferior maxil-
 lary n., 730
 of superior maxillary n.,
 730
Intra-parietal fissure, 485, 474,
477, 480
 line, 509
Intrinsic m.'s of pinna, 400, 401,
663
Irido-cyclitis, 374
Iris, the, 367, 360, 365, 369,
376, 394
 absence, 368
 blood supply, 368
 cleft, 368
 color, 367
 crypts, 392
 lymph spaces, 392
 nerve supply, 368
 pectinate ligament, 364
 reflex, 368
Irregularities of carotid a., inter-
nal, 196
 of occipital a., 195
Irritation of laryngeal n., supe-
rior, 82
 of lingual n., 223
Island of Reil, 170, 481, 548, 471,
483, 546, 565, 569
 gyri operi, **471**
Isthmus, 199, 488, 494, 497
 of fauces, 213, 224, 237
 of thyroid gland, **251**
 tubae, 411
Iter chordae arterius, 691
 posterius, 112
 e tertio ad quartum ventric-
 ulum, 518, 537. *Vide* Aque-
 duct of Sylvius.
 J.
Jacksonian epilepsy, trephining,
504
Jacobson's n., 116
 organ, 300
Jaw, lower, dislocation, 579
 upper, excision, 579
Joints. *Vide* Articulations.
Jugular ganglion, 116
 vein, anterior, 23, 37, **30, 34,**
35, 39, 50, 70, 117,
174, 177, 645
 external, 32, 60, **30, 34,**
35, 39, 50, 70,
174, 208, 645
 jugulo-cephalic
 branch, 23
 line, 23, 32, **27, 623**
 pulsation, 32
 termination, 18
 internal, 61, 62, 73, **35,**
39, 41, 50, 70,
78, 129, 164,
174, 645
 position, 18
 relations, 73
 posterior, **30, 50, 70,**
208, 645
 external, 37
Jugulo-cephalic branch of exter-
nal jugular v., 23
 K.
Keratitis, interstitial, 362, 363
Keratoses senilis, 593
Key, foramen, 411, 511
 L.
Labial a., inferior, 643, 608, 613,
640, 682
 anastomosis, 643
 branch of infra-orbital n.,
 675, 697, **620, 695**
Labial glands, 210
 vein, inferior, **117**
Labyrinth, 399, 431. *Vide* In-
ternal Ear.
 bony, 431
 external view, **427**
 internal view, **430**
 membranous, 431, 432
 diagram, **439**
 vestibule, 431
Lacrimal apparatus, 351, 350,
355
 dissection, 351
 artery, 323, 336, **334**
 branches, 336
 bone, fracture, 586
 canal, 352
 canaliculi, 351, 648, **355,**
653
 canaliculus, **350**
 caruncle, **649**
 duct, 352
 ducts, orifice of, **355, 653**
 fossa, 316
 gland, 323, 328, **326, 330,**
334, 339, 355, 653
 inferior, 328
 superior, 328
 suspensory ligament, 328
 groove, 317
 nerve, 323, 327, 675, **326,**
339, 343
 punctum, **649**
 sac, 352, 591, **321, 350,**
355, 653
 abscess, 644
Lacrymo-nasal duct, 352, 350
Lacunae lateralis, 719
Lacus lacrymalis, 648
Lambda, 573, 588
Lambdoid suture, 573, 588
Lamina cinerea, 459, 516, 565
 cribrosa, 361, 362
 fusca, 362
 of orbital fascia, 323
 quadrigena, 537, 543
 spiralis, 432, **430, 434, 436**
 supraorbital, 362, 374,
 369
 vitrea, 374
Laminae of cerebellum, 558
Laminated tubercle of cerebel-
lum, 562
Lancei n.'s, 517
Landmarks, cranio-cerebral, 499
 of auricle, 601
 of cerebrum, 168
 of cranium, 587, **589**
 of ear, 701
 of eye, 593
 of face, 592
 of frontal lobe, 598
 of limbic lobe, 199
 of neck, 17
 of occipital lobe, 509
 of parietal lobe, 509
 of pinna, 701
 of temporal lobe, 509
 of temporo-sphenoid lobe, 509
Laryngeal a., inferior, 145, 265,
263
 superior, 91, 265, **50, 70,**
78, 123, 251, 263

- Laryngeal asthma, 262
 branch of inferior thyroid a., 145
 nerve, **123**
 external, 262, **51, 71, 78, 79, 177**
 inferior, 82
 internal, 262, **51, 71, 78, 79, 177, 251, 263**
 recurrent, 82, 127, 262, **71, 78, 263**
 superior, 62, 81, 262
 irritation, 82
 paralysis, 82
 pouch, 269
 sac, 269
- Laryngismus stridulus, 262
 Laryngo-pharynx, 227, **212, 296**
 Laryngoscopic examination, 276
 Laryngotomy, 281, 279
 incision, **21**
 Larynx, 247, **251**
 aperture, **218**
 superior, 237, 247, **250**
 arteries, **263**
 blood supply, 265
 cartilages, 270, **271**
 dissection, 247
 excision, 281
 joints, 276
 infrarimal portion, 296
 ligaments, 276
 lymphatics, 265
 movements, 24, 281
 mucous glands, 269
 membrane, 269
 muscles, **258, 259**
 extrinsic, 262
 intrinsic, 262
 nerves, 262, **263**
 paralysis, 262
 relations, 247
 section, **212**
 sinus, 266
 suprarimal portion, **296**
 veins, 265
 ventricle, 248, 266, **212, 218, 250, 296**
- Lateral cartilage of nose, **287**
 superior, 286
 lithotomy, 621
 sinus, 720, **714, 715**
 course, 592
 divisions, 720
 line, 721, 723
 operation to expose, 510
 thrombosis, 511, 720
 tributaries, 720
 tract of medulla oblongata, 551, **552, 556**
 ventricle, 518, **497, 516, 523**
 body, 518, **519, 528, 569**
 corua, **519**
 anterior, 521, **528, 546**
 middle, 521, **528**
 posterior, 521, **528, 546**
 dissection, 518
 tapping, 511
- Lateral ventricles, 518
 Lateralis nasi a., 644
 anastomosis, 644
 Laxator tympani m., 424
 Layers of cornea, 363
 of dura mater of brain, 711
 of scalp, 601
 Lead poisoning, 214
 Leeching, 720
 Length of neck, 17
 Lens, 386, **360, 372, 394**
 capsule, 381
 cortex, 391
 crystalline, 386
 relations, 386
 nucleus, 391
 substance, 391
 suspensory ligament, 385, **360, 372, 394**
- Lenticular ganglion, 338, **326, 339**
 sensory root, 335
 nucleus, 525, 548, **546, 564, 565, 569**
- Lenticulo-striate a., 446
 Leukoma, 364
- Levator anguli oris m., 636, **627**
 action, 636
 insertion, 636
 n.-supply, 636
 origin, 636
 anguli scapulae m., **39, 50, 71, 152**
 glandulae thyroideae m., 122, **123, 251**
 labii inferioris m., 636
 action, 636
 insertion, 636
 nerve supply, 636
 origin, 636
 superioris aequae nasi m., 629, **627**
 action, 629
 insertion, 629
 nerve supply, 629
 origin, 629
 relations, 629
 muscle, 635, **627**
 action, 635
 insertion, 635
 nerve supply, 635
 origin, 635
 relations, 635
 menti m., **627**. *Vide Levator Labii Inferioris Musc.*
 palati m., 245, **242, 243**
 action, 245
 insertion, 245
 origin, 245
 palpebrae m., **339**
 superioris m., 320, 655, **320, 326, 330, 334, 353, 355, 653**
 action, 331
 insertion, 328, 634, 655
- Levator palpebrae superioris muscle, nerve supply, 331
 origin, 328, 655
 relations, 656
- Ligament, capsular, of crico-arytenoid articulation, 276
 of temporo-maxillary articulation, 573, **576, 577**
 of tympanum, 425
 cheek, external, 324, **321**
 internal, 324, **321**
 crico-arytenoid, posterior, 276
 transverse, 276
 external lateral, of temporo-maxillary articulation, 574
 glosso-epiglottidean, 270
 hyo-epiglottidean, 270
 internal lateral, of temporo-maxillary articulation, 574
 of lower jaw, 679, **678, 686**
 tarsal, 630
 in tympanum, 424
 of incus, 424
 posterior, **422**
 of malleus, anterior, 424
 external, 424, **409**
 internal, 424
 superior, 423, 424
 suspensory, 424, **409, 422**
 of Zinn, 347, **334**
 orbito-tarsal, 652, **320, 321**.
Vide Septum Orbitale.
 palpebral, 652
 pectinate, of iris, 364
 pterygo-maxillary, 231, **229**
 sphenio-mandibular, 574
 stylo-hyoid, 115, **576, 577**
 stylo-mandibular, 574
 stylo-maxillary, 46, 63, 574, **576, 577**
 suspensory, of eyeball, 324
 of lacrimal gland, 328
 of lens, 385, **360, 372, 394**
 of malleus, **413**
 thyro-arytenoid, superior, 266
 thyro-epiglottidean, 270
 thyro-hyoid, 255, **254, 263**
- Ligaments of crico-arytenoid articulation, 276
 of larynx, 276
 of pinna, 400
 of temporo-maxillary articulation, 573
- Ligamentum jugale, 270, 275
 nuclia, 25, **39, 41**
- Ligation of arteries of neck, 160
 of carotid arteries, common, 179
 collateral circulation, 185, **133**
 artery, external, 186
 collateral circulation, 187

- Ligation of carotid a., internal, 195
 collateral circulation, 196
 of facial artery, 190
 of innominate a., 160, 165
 collateral circulation, 165
 of lingual a., 61, 188, **177**
 of occipital a., 91, 195
 of subclavian a., 132
 collateral circulation, 135, **133**
 first portion, 135, 166
 second portion, 135, 166
 third portion, 166, 169
 collateral circulation, 170
 of temporal superficial a., 195
 of thyroid a., inferior, 145, 179, **177**
 superior, 147, **177**
 of vertebral a., 143, 175
 Limbic lobe, landmarks, 499
 Line for brachial n. plexus, **20, 67**
 for carotid a., common, **20, 27, 67**
 external, 86, **20, 67**
 internal, **20, 67**
 for dental n., inferior, **20, 67**
 for facial a., **20, 27, 67**
 nerve, **20, 27, 67**
 for fissure of Rolando, 507, **506**
 of Sylvius, 507, **506**
 for frontal fissure, inferior, 508, **506**
 superior, 508, **506**
 for innominate a., **20, 67**
 for intra-parietal fissure, 509
 for jugular v., external, 23, 32, **27**
 for lingual a., **20, 67**
 for longitudinal fissure, 507, **506**
 for occipital fissure, posterior, **506**
 for parieto-occipital fissure, 508
 for precentral fissure, 508
 for spinal accessory n., **20, 67**
 for Stenson's duct, **27**
 for subclavian a., **20, 67**
 for temporo-sphenoid fissure, middle, 510, **506**
 superior, 510, **506**
 for thyroid a., inferior, **20, 67**
 superior, **20, 67**
 for transverse fissure, 507
 Reid's base, 507, **506, 589**
 Lines for carotid a., common, **623**
 for common carotid a., **623**
 for external jugular v., **623**
 for facial a., **623**
 vein, **623**
 for fissures of brain, **506**
 for jugular v., external, **623**
 for lateral sinus, 723, **721**
- Lines for longitudinal sinus, superior, 719
 for sigmoid sinus, 723, **721**
 for Stenson's duct, **623**
 of cerebral fissures, **689**
 Lingual a., 91, 114, **50, 70, 78, 79, 105, 133, 177**
 anastomosis, 114
 irregularities, 190
 ligation, 61, 188, **177**
 line for, **20, 67**
 operation to expose, **183**
 relations, 92
 branch of glosso-pharyngeal n., 119
 convolution, 495, **488, 494, 497**
 lymphatic glands, 703
 nerve, 112, 688, **78, 202, 678, 686, 695**
 branches, 688
 irritation, 223
 operation to expose, **202**
 relations, 112
 resection, 205
 tonsil, 219
 triangle, 61
 dissection, 61
 vein, 92, 112, **35, 50, 51, 70, 177, 645**
 relations, 112
 Lingualis m., 220
 inferior, 220, **221**
 superior, 220, **221**
 Lingula, 543
 of cerebellum, 561
 Lip, lymphatics, 210
 Lips, 210
 lymphatic vessels, 223
 Lobe of cerebellum, biventral, **560**
 central, 561
 digastric, 562
 posterior inferior, 562, **560**
 superior, 561, **560**
 quadrate, 561, **560**
 slender, **560**
 of cerebrum, central, 470
 frontal, 475, 481, **471**
 inner surface, 485
 landmarks, 508
 orbital surface, 482
 limbic, landmarks, 499
 occipital, 476, 490, **458**
 inferior surface, **494**
 landmarks, 509
 parietal, 476, 485
 landmarks, 509
 quadrate, **516**
 temporal, 481, 491, **471**
 inferior surface, **494**
 landmarks, 509
 temporo-sphenoid, 456, 481, 491, **458, 565**. *Vide* Lobe of Brain, Temporal.
 landmarks, 509
- Lobes of brain, frontal, 456
 temporal, 156. *Vide*
 Lobe, Temporo-sphenoid.
 of cerebellum, 558, 561, 562
 of cerebrum, 469
 of parotid gland, 656
 optic, 538
 Lobule of cerebellum, crescentic, anterior, **560**
 posterior, **560**
 of cerebrum. *Vide* Convulsions.
 of ear, 399, 660, **398, 661**
 of nose, 284
 of testicle, 648
 Lobulus centralis, 561, **560**
 gracilis, 562
 Locus caeruleus, 547
 niger, 553, **488, 497**
 Long buccal n., 688
 Longitudinal fissure, 459, **480**
 line, 507, **506**
 of brain, 467
 median sulcus, **542**
 sinus, inferior, 724, **714**
 superior, 719, **709, 714, 715**
 course, 592
 line, 719
 wounds, 719
 Longus colli m., 155, **39, 152**
 action, 156
 insertion, 155
 nerve supply, 156
 origin, 155
 relations, 155
 Ludwig's angina, 64
 Lung, apex, 18
 Lupus vulgaris, 293
 Luschka, pharyngeal tonsil, 232
 Lymphatic duct, 160
 gland, auricular, posterior, **157**
 glands, auricular, 702
 buccal, 702
 cervical, deep, **157**
 superficial, **157**
 infraclavicular, **157**
 lingual, 703
 mastoid, 702
 maxillary, 703
 occipital, 702, **157**
 of carotid sheath, 73
 of head, 702
 of neck, 159, **157**
 parotid, 657, 702, **157**
 posterior pharyngeal, 703
 submaxillary, 63, 702, **157**
 suboccipital, 702
 Lymphatics, auricular, posterior, 615
 frontal, 615
 occipital, 612
 of brain, 445
 of external auditory meatus, 407
 of eyeball, 392
 of eyelids, 655
 of face, 703
 of internal ear, 438
 of larynx, 265

Lymphatics of lip, 210, 223
 of middle ear, 425
 of mouth, 223
 of nasal fosse, 307
 of neck, **157**
 of nose, 286
 of orbit, 351
 of pharynx, 238
 of pinna, 403, 665
 of pterygo-maxillary region, 687
 of scalp, 612, 703
 of tongue, 223
 of tonsils, 225
 posterior auricular, 615
 temporal, 615
 Lymph passage of eye, anterior, 392
 posterior, 392
 spaces, intervaginal, 385
 of cornea, 392
 of iris, 392
 perichoroid, 392
 supra-vaginal, 324, 395
 Lyre, 522, **533**

M.

MacEwen, supra-meatal triangle, 415
 Macrogllossia, 223
 Macula lutea, 380, **381**
 Magendie foramen, 411, 544
 Malar branch of facial n., **609, 613, 620**
 of lacrymal a., 336
 of orbital n., 354, 694
 of temporo-facial n., 669
 of temporo-malar n., 676
 Malleolus, ligament, suspensory, **422**
 Malleus, 423, **405, 409, 413**
 caries, 421
 handle, **418, 422**
 head, **422**
 ligament, anterior, 424
 external, 424, **409**
 internal, 424
 superior, 423, 424
 suspensory, 424, **409, 413**
 manubrium, 423
 processus brevis, 423
 gracilis, 423
 short process, **418**
 Mammary a., internal, 146, **78, 79, 129, 133**
 gland, carcinoma, pain, 45
 Manubrium of malleus, 423
 Marginal convolutions, 185, **488, 497, 516**
 Masseter m., 659, **621, 627**
 action, 660
 blood supply, 660
 insertion, 659
 nerve supply, 660
 origin, 659
 relations, 659
 Masseteric a., 681, **620, 678, 682**
 nerve, 687, **621, 678**
 portion of Stenson's duct, 659
 Mastoid abscess, 420
 antrum, 412, **413**
 trephining, 415
 artery, 95, 96
 branch of auricularis magnus nerve, 38
 of small occipital nerve, **51**
 cells, 412, 416, **413**
 disease, pus, 423
 lymphatic glands, 702
 nerve, **30, 34**
 process, 591
 operations, 723
 vein, 37
 Maxilla, inferior condyle, excision, 584
 excision, 583
 fracture, 586, **581**
 superior, excision, 579
 line of incision, **572**
 fracture, 586
 Maxillary a., internal, 679, 680, **133, 620, 621, 678, 682, 686, 695**
 branches, 683, **682**
 divisions, 683
 division of internal maxillary a., 683
 lymphatic glands, internal, 703
 nerve, inferior, 687, 730, **326, 339, 686, 695, 715**
 branches, 687
 neurectomy of intra-cranial, 730
 structures involved, 730
 resection, 199
 superior, 693, 698, 730, **326, 339, 678, 686, 715**
 branches, 694
 course, 693
 infra-orbital branch, **609**
 neurectomy of, intra-cranial, 730
 structures involved, 730
 resection, 199
 sinus, 312. *Vide* Antrum of Highmore.
 vein, anterior, 687, **35, 645**
 internal, 687, **35, 50, 70, 645**
 Measurements of orbit, 317
 Meatus, auditory, external, 403, **405, 409**
 blood supply, 404
 lymphatics, 407
 nerve supply, 407
 occlusion, 404
 relations, 404
 sinus, 403
 veins, 407
 inferior, **212**
 of nose, **296**
 Meatus of nose, fourth, 299
 inferior, 299, **296, 298, 350**
 middle, 299, **212, 296, 298, 350**
 atrium, 299
 superior, 299, **212, 296, 298**
 Meckel's ganglion, 697, **303, 686, 690**
 branches, 697
 removal, 699
 structures involved, 699
 space, 730
 Media, refracting, of eye, 361
 Median fissure, longitudinal, 544
 posterior, **542**
 nerve, **149**
 suleus, longitudinal, **542**
 Medulla oblongata, 461, 533, **516, 539, 552**
 fissure, antero-lateral, 554
 anterior median, 553, **552**
 posterior median, 553
 function, 558
 funiculus dentatus, **536**
 gracilis, **536**
 position, 456
 pyramid, anterior, **458**
 pyramids, 554
 decussation, 553, 554, **552**
 tract, lateral, 554, **536, 552, 556**
 pyramidal, **552**
 Medullary velum, posterior, 562
 superior, 543, **516, 536, 542, 560. Vide** Valve of Viessens.
 Meibomian glands, 593, 652, **346, 355, 632, 653**
 ducts, 648, **353**
 orifice, **653**
 Melanotic sarcoma of choroid, 379
 Membrana basilaris, 432
 flaccida, 419, **409**
 nictitans, **321**
 rudimentary, 651
 tensa, 419
 tympani, 416, **405, 409, 413**
 artificial, 420
 blood supply, 420
 external view, **418**
 folds, 419
 inner wall, 420
 internal view, **422**
 mucous membrane, 420
 nerve supply, 420
 pancatesis, 419
 perforation, 419
 promontory, 420
 pyramid, 420
 rupture, 419
 secundaria, 420, 432
 Membrane, crico-thyroid, 24, 255, **123, 251, 254**
 hyaloid, 385
 hypo-glossal, 216, 220, 270

- Membrane, intersutural, 617
 mucous, of larynx, 269
 of membrana tympani, 420
 of mouth, 215
 of nasal fosse, 300
 of nose, nerve supply, 302
 of pharynx, 232
 of Bowman, 363
 of brain, 704
 of Descemet, 363
 of Reissner, 432
 pituitary, 300
 nerve supply, 302
 pupillary, 367
 Schneiderian, 300
 nerve supply, 302
 Shrapnell's, 419, **418**
 synovial, of temporo-maxillary articulation, 574
 thyro-hyoid, 255, **123, 212, 251, 254, 263**
- Membranes of brain, 438
 Membranous coecllea, 437
 labyrinth, 431, 432
 diagram, **439**
 semicircular canals, 137
 Ménière's disease, 437
 Meningeal a., anterior, 734
 middle, 592, 683, 733, **303, 682, 688, 690, 695, 709, 714, 715**
 branches, 733, 734
 wounds, 734
 posterior, 95, 449, 735, **444**
 small, 683, 735, **682, 686, 695**
 branch of anterior ethmoid artery, 337
 of ascending pharyngeal artery, 97
 of glosso-pharyngeal nerve, 116
 of pneumogastric nerve, 81
 vein, 735
- Meningitis, 423
 Meningocele, 594
 sincipital, 286
 Mental a., 676, 683, **620, 682, 695**
 anastomosis, 676
 branch of mylo-hyoid n., 691, **695**
 foramen, 595
 nerve, 676, **609, 620, 686**
- Meyer, spheno-ethmoid recess of, 299
 Middle ear, 399, 407
 blood supply, 425
 disease, 420
 dissection, 407
 lymphatics, 425
 pyramid, 412
 veins, 425
- Mobility of eyeball, 357
 of scalp, 616
 Modiolus, 432, **434, 436**
 Molar glands, 213
 Moll, sweat gland, **353**
- Monoplegia, brachial, 504
 crural, 504
 facial, 504
 Monro, foramen, 518, 537, **516, 519, 528, 529**
 Monticulus cerebelli, 561
 clivus, 561
 culmen, 564
 Morgagni, sinus of, 231, **229**
 Motor areas of brain, 449, **501**
 centers of brain, 500
 oculi n., 311, **539, 715**
- Mouth, 209, 213, 594
 angles, 210
 anterior view, **239**
 diaphragm of, 107
 dissection, 209
 lymphatics, 223
 mucous membrane, 215
 muscles, 634
 section, **212**
 vestibule, 210, **212**
- Movements of larynx, 24, 284
 Mucocle of antrum of Highmore, 312
 Mucous gland of Eustachian tube, 411
 of larynx, 269
 of nose, 302
 membrane of larynx, 269
 of membrana tympani, 420
 of mouth, 215
 of nasal fosse, 300
 of nose, nerve supply, 302
 of pharynx, 232
 of urethra, 637
- Müller, palpebral muscle, superior, **353**
 ring muscle of, 373
 Multifidus spine m., **39**
 Musce volitantes, 385
 Muscles, anterior dilator narium, **627**
 antitragicus, 665, **401, 663**
 aryteno-epiglottideus, 261, **258, 259, 263**
 arytenoideus, 256, **258, 259, 263**
 attolens aurem, 605, **627**
 attrahens aurem, 605, **627**
 azygos uvulae, 246, **242, 243**
 buccinator, 637, **229, 242, 621, 627, 678, 686**
 bulbo-cavernosus, 604
 ciliary, 368, **360, 365, 369, 376, 394**
 of orbicularis palpebrarum, 633
 complexus, **39, 50, 71, 78**
 compressor narium, **627**
 minor, **627**
 nasi, 629
 constrictor, of pharynx, inferior, 228, **71, 79, 123, 177, 229, 236, 251**
 middle, 228, **50, 71, 79, 105, 229**
 superior, 228, **71, 79, 229**
 corrugator supercillii, 634, **346, 632**
- Muscle, crico-arytenoideus lateralis, 261, **259**
 posticus, 256, **258, 259**
 crico-thyroid, 255, **123, 251**
 posterior, **263**
 depressor alae nasi, 630
 anguli oris, **627**
 labii inferioris, 636, **627**
 digastric, 98, **71, 78, 79, 105, 117**
 anterior belly, **50**
 posterior belly, **50**
 dilator naris, 629
 narium, anterior, **627**
 posterior, **627**
 external pterygoid, 679, **678**
 genio-hyo-glossus, 114, 220, **78, 79, 105, 109, 212, 296**
 genio-hyoid, 107, **78, 79, 105, 109, 212, 296**
 helicis major, 665, **401, 663**
 minor, 665, **401, 663**
 Horner's, 633. *Vide* Tensor Tarsi Muscle.
 hyo-glossus, 108, 220, **71, 78, 79, 105, 109, 177**
 inferior oblique, 317, **320, 339, 632**
 rectus, **632**
 internal pterygoid, 680, **303, 678, 686, 690**
 laxator tympani, 424
 levator anguli oris, 636, **627**
 scapulae, **39, 50, 71, 152**
 glandulae thyroideae, 122, **124, 251**
 labii inferioris, 636
 superioris, 635, **627**
 alaeque nasi, 629, **627**
 menti, **627**
 palati, 245, **242, 243**
 palpebrae superioris, 320, 328, 655, **326, 330, 334, 353, 355, 653**
 palpebral, **339**
 lingualis, 220
 inferior, 220, **221**
 superior, 220, **221**
 longus colli, 155, **39, 152**
 masseter, 659, **621, 627**
 multifidus spine, **39**
 mylo-hyoid, 107, **50, 71, 78, 79, 107, 109, 177, 296**
 oblique, inferior, 317, **326, 330, 334, 339, 346, 632**
 superior, 331, **326, 330, 334**
 pulley, 331, **334**
 obliquus auris, 665, **401, 663**
 capitis inferioris, **152**
 superioris, **152**
 occipitalis, 615, **79. Vide** Occipito-frontalis Muscle.
 occipito-frontalis, 615
 omo-hyoid, 119, **71, 117**
 anterior belly, 119, **50**
 posterior belly, 120, **50**

- Muscle, orbicularis oris, 634, **627**
 palpebrarum, 630, **321**,
353, 627
 palato-glossus, 220, 246, **105**,
109, 242, 243
 palato-pharyngeus, 245, **242**,
243
 palpebral, superior, of Mül-
 ler, **353**
 platysma myoides, 31, **30**,
177, 621, 627
 posterior dilator narium, **627**
 pterygoid, external, 679, **678**
 internal, 680, **303, 678**,
686, 690
 pyramidalis nasi, 626, **627**
 quadratus menti. *Vide* De-
 pressor Labii Inferioris
 Muscle.
 rectus capitis anticus major,
 156, **78, 79**,
152
 minor, 156, **152**
 lateralis, 156, **152**
 external, 342, **321, 326**,
330, 334, 339
 inferior, 347, **339, 346**,
496
 internal, 342, **326, 330**,
334, 339
 superior, 331, **320, 326**,
330, 334, 339, 346,
632
 retrahens aurem, 605, **627**
 ring, of Müller, 373
 risorius, 31, 631, **627**
 salpingo-pharyngeus, 245,
243
 Santorini's. *Vide* Risorius
 Muscle.
 scalenus anticus, 153, **39**,
71, 78, 79, 129, 152
 medius, 154, **39, 50, 71**,
129, 152
 posticus, 154, **39, 129**,
152
 semispinalis colli, **39**
 serratus magnus, **50, 71**
 sphincter oculi. *Vide* Or-
 bicularis Palpebrarum
 Muscle.
 oris. *Vide* Orbicularis
 Oris Muscle.
 splenius, **39, 78, 79**
 capitis, **50, 71, 152**
 stapedius, 425, **422**
 sterno-cleido-mastoid, 17, 48.
Vide Muscle, Sterno-Mas-
 toid.
 sterno-hyoid, 120, **39, 50**,
71, 78, 117
 sterno-mastoid, 17, 48, **39**,
41, 50, 71, 78, 117, 177
 sterno-thyroid, 121, **39, 50**,
71, 78, 117
 stylo-glossus, 111, 220, **79**,
105, 109
 stylo-hyoid, 98, **50, 51, 71**,
105, 177
 stylo-pharyngeus, 115, **79**,
105, 229
 superficial cervical, 31
 superior rectus, **632**
- Muscle, temporal, 625, **321, 621**,
678, 686
 tensor palati, 245, **303, 690**
 tarsi, 633, **321, 346**,
355, 632, 653
 tympani, 425, **405, 422**
 thyro-arytenoidens, 261, **259**
 thyro-epiglottidens, 261
 thyro-hyoid, 121, **50, 71**,
87
 trachelo-mastoid, **152**
 tragicus, 665, **401, 663**
 transversalis colli, **39**
 transversus auris, 665, **401**,
663
 deep, 613
 trapezius, **39, 41, 50, 71**,
78, 79
 zygomaticus major, 636, **627**
 minor, 637, **627**
- Muscles, constrictor, of pharynx,
 228, 231, **229**
 intrinsic, of pinna, 400, **401**,
663
 of auricle, intrinsic, 400
 of ear, 605, 665
 of esophagus, **229**
 of eyebrows, 630
 of eyelids, 630
 of face, 626, **613, 627**
 of larynx, **258, 259**
 extrinsic, 262
 intrinsic, 262
 of mouth, 631
 of neck, dissection, 48
 of nose, 626
 of orbit, 328, **326, 330**
 of palate, paralysis, 247
 of pharynx, 227
 paralysis, 247
 of scalp, **613, 627**
 of soft palate, **242, 243**
 of tongue, 219
 dissection, 108
 extrinsic, 219, **109**
 intrinsic, 220
 of tympanum, 425
 prevertebral, 155, **152**
 recti, common tendon, in-
 ferior, 347
 superior, 347
- Muscular branch of facial a., 643
 of ophthalmic artery, 337
 sense, area of, 500
- Musculo-cutaneous n., **149**
 Musculo-spiral n., **149**
- Mylo-hyoid a., 104, 683, **678**,
682, 686, 695
 muscle, 107, **50, 71, 78, 79**,
107, 109, 117, 177,
296
 action, 107
 blood supply, 107
 insertion, 107
 nerve supply, 107
 origin, 107
 relations, 107
 nerve, 104, 691, **51, 678**,
686, 695
 branches, **695**
 incisive branch, 691
 mental branch, 691
- Myopia, 363, 396
- Myopic eye, **389**
 Myxedema, 126
- N.**
- Nares, anterior, 284, 594
 posterior, 232, **236**
- Nasal a., 337
 anastomosis, 337
 lateral, 613, **682, 695**
 bones, 286
 fracture, 286, 586
 branch of anterior ethmoid
 a., 337
 of infra-orbital n., 675,
 697, **620**
 of Meckel's ganglion, 698
- catarrh, 301
- cavities, 294
 blood supply, 307
 of pharynx, 300
 veins, 307
- columna, 594
 donche, 308
 duct, 352, 594, **314**
 orifice, 299, **298**
- fosse, 294
 anterior view, **306**
 divisions, 300
 lymphatics, 307
 mucous membrane, 300
 olfactory portion, 300
 posterior view, **309**
 respiratory portion, 300
 nerve, 302, 332, 675, 697,
303, 326, 339, 343,
609, 620, 690, 695
 branches, 335
 external branch, 676
 inferior, **303**
 naso-labial branch, 629
 of Meckel's ganglion,
 698
 superior, 698, **303, 690**
- nerves, inferior, **690**
 polypi, 301
 septum, 294, **236, 291, 306**,
714
 deviation, 294
 perforation, 294
- Naso-labial branch of nasal n., 629
- Naso-palatine a., 684, **690**
 branch of Meckel's ganglion,
 698
 nerve, 302, **303**
- Naso-pharynx, 227, **212, 296**
- Nates, 538, **542, 556, 560**
 brachia, 543
- Near-sightedness, 363
- Nebula, 364
- Neck, abscess of, 31, 47
 arteries, ligation, 160
 articulations, 573, 579
 back of, surface anatomy, 24
 bursa, 156
 caruncle, 26
 development, 25
 dissection, 17, 26
 fascia, deep, **34**
 superficial, 26
 incision for dissection, **623**
 injuries, 31
 length, 17

- Neck, lymphatic glands, 159, **157**
vessels, **157**
muscles, dissection, 18
nerves, **70, 71**
operations upon, 196
skin, 17, 26
surface markings, **21**
transverse section, **39**
triangles, 54
anterior, 18
diagram, **55**
dissection, 51
posterior, 12
veins, **35, 645**
vessels, **70, 71**
- Necrosis of turbinated bones, 300
- Nerve, abducent, 465, 728, **539**.
Vide Nerve, Sixth Cranial.
- ansa hypoglossi, **71**
anterior auricular, 688
superior dental, 697, **695**
temporal, **678, 686**
- Arnold's, 81
- auditory, 438, 465, 729, **539**.
Vide Nerve, Eighth Cranial.
- auricular, 81
anterior, 688
great, **30, 609**
of auricularis magnus, 38
posterior, 97, 612, 666, **51, 70, 71, 78, 79, 203**
- auricularis magnus, 32, 38, **34, 51**
branches, 38
relation, 206
- auriculo-temporal, 612, 688, **193, 303, 609, 613, 620, 678, 686, 690, 695**
divisions, 688
operation to expose, 205, **193**
- buccal, 669, **609, 613, 620, 678, 695**
long, 688, **686**
- cardiac, **78, 79**
cervical, pneumogastric, 83
sympathetic, inferior, 85
superior, 84
middle, 85
- carotid, of glosso-pharyngeal, 116
- cervical, eighth, **149**
anterior division, **79**
fifth, **149**
anterior division, **39, 71, 78**
fourth, **149**
anterior division, **71, 78**
second, anterior division, **71, 78**
seventh, **149**
anterior division, **71, 78**
sixth, **149**
anterior division, **39, 71, 78**
- cervical, superficial, 15, **34, 51**
relations, 206
third, anterior division, **71, 78**
- cervico-facial, 669
branches, 669
- chorda tympani, 426, 691, **422, 678, 686, 695**
in otitis media, 426
- ciliary, **376**
long, 335, **376**
posterior, **326, 377**
short, **339, 376**
posterior, **377**
- circumflex, **149**
- cochlear, 438, 466
- communicantes hypoglossi, 66, **71**
noni, 66
- cranial, **715, 461**
eighth, 465, **458, 542, 556**
origin, **552**
eleventh, 57, 466, **458, 542, 556**
origin, **552**
fifth, 465, **326, 339, 458, 542, 556**
ophthalmic division, **326**
origin, **552**
fourth, 327, 462, **326, 339, 343, 458, 542, 556, 560**.
Vide Pathetic Nerve.
origin, **552**
recurrent branch, **326**
ninth, 466, **458, 542, 556**
origin, **552**
second, 462. *Vide* Nerve, Optic.
seventh, 465
origin, **552**
sixth, 341, 465, **326, 339, 458**
tenth, 76, 466, **458, 542, 556**
origin, **552**
third, 341, 462, **326, 458**. *Vide* Nerve, Oculo-motor.
origin, **552**
twelfth, 104, 467, **458**
origin, **552**
- cutaneous, internal, **149**
lesser internal, **149**
deep temporal, 687
- dental, anterior superior, 697, **695**
inferior, 691, **678, 686, 695**
line, 20, **67**
operation to expose, **182**
resection, 200
middle superior, 691, **695**
posterior superior, 691, **695, 678, 686**
- Nerve, descendens hypoglossi, 73, **41, 51, 71, 78**
noni, 73
- digastric, 669
- eighth cervical, **149**
anterior division, **79**
cranial, 465, 729, **458, 542, 715**
- eleventh cranial, 57, 466, 729, **458, 542, 715**
- external palatine, 690
respiratory, of Bell, 153
superficial petrosal, 733
- facial, 465, 666, 728, **51, 71, 78, 79, 203, 539, 620, 621**. *Vide* Nerve, Seventh Cranial.
branches, 666
buccal branch, 669, **609, 613, 620**
course, 666
digastric branch, 669
division of, facial, 666
intra-cranial, 666
temporal, 666
infra-maxillary branch, 670, **34, 620**
infra orbital branch, 669, **609, 613, 620**
line, 20, **27, 67**
malar branch, 669, **609, 613, 620**
of auricularis magnus, 38
operation to expose, 675, **203**
paralysis, 670
stretching, 205
stylo-hyoid branch, 669
supra-maxillary branch, 670, **609, 613, 620**
temporal branch, 612, **609, 613, 620**
- fifth cervical, **149**
anterior division, **78**
cranial, 465, 675, 728, **326, 339, 458, 542, 695, 715**
branches, 675
ophthalmic division, **326**
- first cervical, **539**
cranial, 461, 727. *Vide* Nerve, Olfactory.
thoracic, anterior division, **79**
- fourth cervical, **149**
anterior division, **78**
cranial, 327, 462, 728, **326, 339, 343, 458, 542, 715**. *Vide* Nerve, Pathetic.
recurrent branch, **326**
- frontal, 327, **326, 339, 343**
glosso-pharyngeal, 115, 466, 729, **79, 539**. *Vide* Nerve, Ninth Cranial.
branches, 116
relations, 116
tympanic branch, 426

- Nerve, gustatory, 112, 688
 hypoglossal, 104, 112, 467, 554, 729, **51, 71, 78, 79, 177, 539**. *Vide* Nerve, Twelfth Cranial.
 paralysis, 104
 hypoglossi descendens, **71**
 communicantes, **71**
 incisive branch of mylohyoid, 691, **695**
 inferior dental, 691, **595, 678, 686**
 maxillary, 687, 730, **686, 695, 715**
 branches, 687
 divisions, 687
 neurectomy, intracranial, 730
 nasal, **690**
 infra-maxillary branch of cervico-facial, 670, **620**
 of cervico-facial, 45
 of facial, **34**
 infra-orbital, 675, **695**
 branch of superior maxillary, 675, 697, **609, 620, 695**
 branches, 675, 697, **609, 620, 695**
 labial, 675, **620**
 nasal, 675, **620**
 palpebral, 675, **620**
 operation to expose, 699
 structures involved, 699
 resection, 199
 infratrochlear, 335, **326, 609, 613, 620**
 intercostal, first, **149**
 intra-cranial, 727
 course, 727
 Jacobson's, 116
 labial, 675, 697, **620, 695**
 lacrymal, 323, 327, 675, **326, 339, 343**
 laryngeal, external, 262, **51, 71, 78, 79, 177**
 inferior, 82
 internal, 262, **51, 71, 78, 79, 123, 177, 251, 263**
 recurrent, 127, 262, **71, 78, 263**
 superior, 62, 81, 262
 irritation, 82
 paralysis, 82
 lingual, 112, 688, **78, 202, 678, 686, 695**
 branches, 688
 irritation, 223
 of glosso-pharyngeal, 119
 operation to expose, **202**
 relations, 112
 resection, 205
 long buccal, 688
 malar branch of facial, 669, 676, **609, 613, 620**
 of orbital, 351, 691
 masseteric, 687, **621, 678**
 mastoid, **30, 34**
- Nerve, mastoid, branch of auricularis magnus, 38
 of small occipital, **51**
 maxillary, inferior, 687, 730, **326, 339, 686, 695, 715**
 branches, 687
 neurectomy, intracranial, 730
 structures involved, 730
 resection, 199
 superior, 693, 698, 730, **326, 339, 678, 686, 715**
 branches, 694
 course, 693
 infra-orbital branch, **609**
 neurectomy, intracranial, 730
 structures involved, 730
 resection, 199
 median, **149**
 meningeal, of glosso-pharyngeal, 116
 of pneumogastric, 81
 mental, 676, **609, 620, 686**
 middle superior dental, 694, **695**
 motor oculi, 311, **539, 715**
 musculo-cutaneous, **149**
 musculo-spiral, **149**
 mylo-hyoid, 104, 691, **51, 71, 117, 678, 686, 695**
 branches, 691, **695**
 incisive branch, 691
 mental branch, 691
 nasal, 302, 332, 675, 697, **303, 326, 339, 343, 609, 620, 690, 695**
 branches, 335
 external branch, 676
 inferior, **303, 690**
 naso-labial branch, 629
 of Meckel's ganglion, 698
 superior, 698, **303, 690**
 naso-labial branch of nasal, 629
 naso-palatine, 302, 698, **303, 690**
 ninth cranial, 466, 729, **458, 542, 715**
 occipital, great, **609, 613**
 small, 612, **609, 613**
 occipitalis major, 612, **79**
 minor, 38, 612, **30, 34, 15**
 mastoid branch, **34**
 relations, 206
 oculo-motor, 311, 462, 727.
Vide Nerve, Third Cranial.
 olfactory, 302, 461, 727, **303, 690**. *Vide* Nerve, First Cranial.
 ophthalmic, 326, **339, 343, 695, 715**
 optic, 312, 462, 727, **320, 326, 330, 334, 360, 369, 458, 516, 552, 565, 715**. *Vide* Nerve, Second Cranial.
- Nerve, optic, division, 316
 entrance, 362
 orbital, 351, 691, **339, 678, 686, 695**
 of Meckel's ganglion, 697
 temporal branch, 612, **609, 613, 620**
 palatine, anterior, 697
 external, 698, **303, 690**
 great, **303, 690**
 posterior, 698, **303, 690**
 palpebral, 675, 697, **620, 695**
 pars intermedia of Wisberg, **539**
 pathetic, 327, 462, 728, **539**.
Vide Nerve, Fourth Cranial.
 petrosal, external superficial, 84
 small, 426
 superficial external, 733
 large, 732
 small, 732
 pharyngeal, 698, **303, 690**
 of glosso-pharyngeal, 116
 of pneumogastric, 81
 phrenic, 60, 65, **71, 78, 79, 149**
 plexus, axillary, 148. *Vide* Nerve Plexus, Brachial.
 brachial, 60, 148, **51, 71, 149, 208**
 branches, 148
 formation, 148
 line, **20**
 operation to expose, **208**
 stretching, 209
 cervical, 48, 65, **44**
 branches, 48
 descending branches, **51, 208**
 superficial branches, 38
 pharyngeal, 81, 116, 231
 subtrapezial, 66
 tympanic, 426
 vertebral, 85
 pneumogastric, 76, 466, 729, **39, 41, 78, 79, 164, 539**. *Vide* Nerve, Tenth Cranial.
 branches, 81
 cardiac branches, cervical, 83
 ganglia, 76
 relations, 76
 posterior auricular, 612, 666
 superior dental, 694, **678, 686, 695**
 temporal, **678, 686**
 pterygo-palatine, 698
 ramus subcutaneous make, 694
 recurrent branch of fourth cranial, **326**
 laryngeal, 82, 127, **78, 79**
 rhomboid, **149**

- Nerve, second cervical, anterior division, **78**
 cranial, 465, 727. *Vide* Nerve, Optic.
 sensory, of parotid gland, 657
 septal, of Meckel's ganglion, 698
 seventh cervical, **149**
 anterior division, **78**
 cranial, 465
 sixth cervical, **149**
 anterior division, **78**
 cranial, 311, 465, **326, 339, 343, 458**
 sphenopalatine, **303**
 spinal accessory, 57, 466, **39, 51, 71, 78, 79, 539**. *Vide* Nerve, Eleventh Cranial.
 line, **20, 67**
 operation to expose, **182**
 resection, 58, 205
 sterno-mastoid, **71**
 subscapular, lower, **149**
 middle, **149**
 upper, **149**
 superficial cervical, **34**
 superficialis colli, **45**
 supra-acromial, **45, 34**
 supra-clavicular, **45, 34**
 supra-maxillary branch of facial, 670, **620**
 supra-orbital, 327, 611, **197, 326, 339, 609, 613, 620**
 neurectomy, 611
 operation to expose, 196, **197**
 supra-scapular, 153, **51, 71, 149**
 supra-sternal, **45, 34**
 supra-trochlear, 327, 611, **326, 339, 609, 613**
 neurectomy, 611
 sympathetic, **78, 79**
 cervical portion, 83
 temporal, anterior, 612, **686**
 branch of facial, 612, 669, **609, 613, 620**
 of orbital, 351, 612, 694, **609, 613**
 posterior, 612, **678**
 superficial, 688
 temporo-facial, 669
 branches, 669
 temporo-malar, 351, 694
 tenth, 729, **715**
 cranial, 466, **458, 542**
 third, 727
 cervical, anterior division, **78**
 cranial, 311, 462, **458, 326**. *Vide* Oculomotor Nerve.
 thoracic, external anterior, **149**
 first, **149**
 anterior division, **79**
- Nerve, thoracic, internal anterior, **149**
 posterior, or long, 153, **51, 71, 149**
 to levator anguli scapulae muscle, **149**
 to longus colli muscle, **149**
 to rhomboidei muscle, 148
 to sculeni muscle, **149**
 to stylo-hyoid muscle, **51**
 to subclavius muscle, 148, **149**
 tonsillar, of glosso-pharyngeal, 119
 trifacial, 465, 675, 728, **339, 539**. *Vide* Nerve, Fifth Cranial.
 branches, 675
 trigeminus, 465. *Vide* Nerve, Fifth Cranial.
 trochlear, 327, 462, 543. *Vide* Nerve, Fourth Cranial.
 twelfth, 729, **715**
 cranial, 467, **458**
 tympanic, of glosso-pharyngeal, 116, 426
 ulnar, **149**
 vagus, 76, 729. *Vide* Nerve, Pneumogastric.
 vestibular, 438, 466
 Vidian, 302, 698, **303, 690, 695**
- Nerves, ciliary, 379
 cranial, origins, **552**
 superficial, origin, **458**
 deep temporal, 687
 of face, 666, **609, 613, 620**
 of head, operations, 196
 of Lancisi, 517
 of larynx, 262, **263**
 of neck, **70, 71**
 operations, 196
 of orbit, 327, **326, 339**
 arrangement, **342**
 of pterygo-maxillary region, 687
 of scalp, 611, **609, 613**
 of thyroid gland, 126
 plexus of, basilar, **715**
 infra-orbital, 669, 675
- Nervi molles, 84, 614
 Nervus vagus, 466
 Neuralgia, trifacial, 698, 700
 Neurectomy, intra-cranial, of inferior maxillary n., 730
 of superior maxillary n., 730
 of supra-orbital n., 611
 of supra-trochlear n., 611
 Nidus hirundinis, 562
 Ninth n., 729, **715**
 cranial n., 466, **458, 542, 556**
 origin, **552**
- Nodule of cerebellum, 562, **560**
- Nose, 281, 591
 air-chambers, accessory, **314**
 orifices, **298**
 ala, 281
 base, 281
 bleeding from, 301
 blood supply, 285
 bridge, 281
- Nose, cartilages, 286
 accessory, 293
 at base, **290**
 lateral, **287**
 inferior, 286
 sesamoid, 293
 dissection, 281
 divisions, 281
 epithelioma, 285
 hemorrhage from, 301
 lobule, 284
 lymphatics, 286
 meatus, **296**
 fourth, 299
 inferior, 299, **296, 298, 350**
 middle, 299, **296, 298, 350**
 atrium of, 299
 superior, 299, **296, 298**
 mucous glands, 302
 membrane, nerve supply, 302
 nerve supply, 285
 rodent ulcer, 285
 section, **212**
 skin, 285
 veins, 285
 vestibule, 285, 302
 wings, 284
- Nose-bleed, 643
 Notch of Rivini, 416
 preoccipital, 476
 supra-orbital, 316
- Nuclei of brain, **536**
 of pons Varolii, 550
 of tegmentum of crus cerebri, 553
- Nucleus, caudate, 525, 547, **529, 542, 546, 556, 565, 569**
 head, **536, 564**
 euneate, 557
 Deiters', 465
 gracile, 557
 lenticular, 525, 548, **546, 564, 565, 569**
 of lens, 391
 olivary, superior, 550
 red, 553
 tegmental, 553
- Nuhn, gland, 219
- O.
- Oblique m., inferior, 347 **320, 326, 330, 334, 339, 346, 362**
 action, 317
 insertion, 317
 nerve supply, 318
 origin, 317
 superior, 331, **326, 330, 334**
 action, 331
 insertion, 331
 nerve supply, 331
 origin, 331
 pulley, 331, **334, 632**
- Obliquus auris m., 665, **401, 636**
 capitis inferioris m., **152**
 superioris m., **152**

- Occipital a., 93, **50, 70, 133, 603, 608, 613, 640**
 anastomosis, 606
 branches, 94
 irregularities, 195
 ligation, 94, 195
 operation to expose, **183, 192**
 relations, 93
 convolution, inferior, 491, **474, 477, 480**
 middle, 491, **474, 477, 480**
 superior, 491, **474, 477, 480**
 diploic v., 707, **705**
 fissure, inferior, 490
 middle, 490, **477, 480**
 posterior, line, **506**
 superior, 490, **477, 480**
 transverse, 490, **477, 480, 572**
 foramen, superior, 718
 lobe, 476, 490, **458**
 inferior surface, **494**
 landmarks, 509
 lymphatic gland, **157**
 glands, 702
 lymphatics, 612
 nerve, great, 612, **79, 609, 613**
 small, 612, **30, 34, 51, 609, 613**
 mastoid branch, **34**
 protuberance, external, 25, 591
 sinus, 724, **715**
 suture, transverse, 573
 triangle, 51, **55**
 abscess, 59
 contents, 57
 dissection, 57
 vein, 95, **35, 645**
 relations, 95
 Occipitalis major n., 612
 minor n., 38, 612
 relations, 206
 muscle, 615, **79. Vide Occipito-frontalis Muscle.**
 Occipito-angular region, 503
 Occipito-frontalis aponeurosis, 615, **599, 627**
 muscle, 615
 action, 615
 aponeurosis, 615, **599, 627**
 blood supply, 615
 insertion, 615
 nerve supply, 615
 origin, 615
 relations, 615
 Occipito-temporal convolution, external, 495
 Occlusion of Eustachian tube, 411
 of external auditory meatus, 404
 Oculo-motor n., 341, 462, 727.
Vide Third Cranial Nerve.
 Olfactory bulb, 156, **458, 483**
 fissure, 456, 482, **488, 497**
 nerve, 302, 461, 727, **303, 690. Vide First Cranial Nerve.**
 Olfactory portion of nasal fosse, 300
 sulcus, 456
 tract, 456, 462, **303, 458, 539, 690**
 Olfactory body, 554, **458, 539, 552**
 corpus dentatum, 554
 peduncle, 554
 nucleus, superior, 550
 Omo-hyoid m., 119, **71, 117**
 action, 120
 belly, anterior, 119, **50**
 insertion, 120
 origin, 119
 posterior, 120, **50**
 insertion, 120
 origin, 120
 nerve supply, 120
 tendon, **39**
 Onyx, 364
 Operation, enucleation of eyeball, 396
 esophagotomy, 226
 evisceration of eyeball, 396
 excision of condyle of inferior maxilla, 584
 of eyeball, 396
 of inferior maxilla, 583
 of larynx, 281
 of superior maxilla, 579
 for abscess, cerebellar, 511
 extradural, 511
 temporo-sphenoid, 511
 for cleft palate, 215
 for harelip, 210, 213, 644
 hemorrhage in, 644
 for headache, 512
 for removal of Gasserian ganglion, 731
 structures involved, 731
 of parotid gland, 658
 for tongue-tie, 115, 215
 for traumatic epilepsy, 512
 for trifacial neuralgia, 699
 laryngotomy, 281, **279**
 ligation of carotid artery, common, 179
 internal, 195
 of inferior thyroid artery, 179
 of innominate artery, 160, 165
 of lingual artery, 64
 of occipital artery, 195
 of subclavian artery, 132
 third portion, 169
 of temporal artery, superficial, 195
 of vertebral artery, 143, 175
 on mastoid process, 723
 resection of dental nerve, inferior, 200
 of Gasserian ganglion, 199
 of infra-orbital nerve, 199
 of lingual nerve, 205
 of maxillary nerve, inferior, 199
 superior, 199
 of spinal accessory nerve, 58, 205
 Operation, rhinoplasty, 285
 Rouge's, 300
 stretching brachial nerve plexus, 209
 facial nerve, 205
 thyroidectomy, 126
 to expose auriculo-temporal nerve, 205, **193**
 brachial nerve plexus, **208**
 carotid artery, common, **182**
 external, **183**
 internal, **183**
 facial artery, **182, 183**
 nerve, **203**
 inferior dental nerve, **182**
 innominate artery, **164**
 lateral sinus, 510
 lingual artery, **183**
 nerve, **202**
 occipital artery, **183, 192**
 spinal accessory nerve, **182**
 subclavian artery, third portion, **167**
 supra-orbital artery, **197**
 nerve, 196
 temporal artery, 193
 thyroid artery, inferior, **174**
 superior, **183**
 vertebral artery, **174**
 to tap lateral ventricles, 511
 tracheotomy, 122, 282, **279**
 upon nerves of head, 196
 of neck, 196
 Operculum, 470, **471**
 Ophthalmia, purulent, 361
 Ophthalmic a., 335, **229, 334, 444, 715**
 branches, 335
 muscular branches, 337
 division of fifth cranial nerve, **326, 339**
 ganglion, 338
 nerve, **343, 695, 715**
 vein, 337, **343**
 common, 338, **334**
 inferior, 338, **334**
 phlebitis, 338
 pulsation, 338
 superior, 338, **334**
 Optic chiasm, 459, **334**
 commissure, 459, **458, 483, 494, 516, 539, 565**
 disc, 380, **381**
 lobes, 538
 nerve, 342, 462, 727, **320, 326, 330, 334, 360, 369, 458, 516, 552, 565, 715. Vide Second Cranial Nerve.**
 division, 316
 entrance of, 362
 thalamus, 526, 538, **488, 497, 519, 523, 536, 542, 546, 552, 556, 569**
 pulvular, **539**

- Optic thalamus, tubercle, anterior, 538
 posterior, 538
 tract, 462, **458, 539, 552, 565, 569**
 diagram, **463**
- Ora serrata, 380
- Orbicularis ciliaris, 371
 oris m., 631, **627**
 action, 635
 nerve supply, 635
 relations, 635
- palpebrarum m., 630, **321, 353, 627**
 action, 633
 insertion, 633
 nerve supply, 633
 origin, 630
 relations, 630
- Orbit, 316
 abscess, 323
 apex, 316
 arteries, **334**
 base, 316
 dissection, 316
 emphysema, 323
 exenteration of contents, 396
 floor, 316
 lymphatics, 351
 measurements, 317
 muscles, 328, **326, 330**
 nerves, 327, **326, 339**
 arrangement, 342
 periosteum, 318, **320**
 pulsation, 338
 roof, 316
 veins, **334**
- Orbital a., **608, 613, 640, 682**
 branch of Meckel's ganglion, 697
 of superior maxillary n., 691
- convolution, anterior, 485, **483, 488, 497**
 inferior, **483**
 internal, 485, **488, 497**
 posterior, 485, **483, 488, 497**
- fascia, 323, **320, 321**
 lamina, 323
- fat, 323, **321, 326, 330, 632**
 foreign body, 323
- fissure, 456, 482. *Vide* Tri-radiate Fissure.
- nerve, 351, **339, 678, 686, 695**
 temporal branch, 612, **609, 613, 620**
 sulcus, 456
 vein, **35, 645**
- Orbito-tarsal ligament, 652, **320, 321**
- Organ of Corti, 437
 of hearing, 399
- Orifice, buccal, 210
 of antrum of Highmore, **298**
 of aqueductus cochleæ, **430**
 vestibuli, **430**
 of duct of Meibomian gland, **653**
 of Eustachian tube, 232, **298, 422**
- Orifice of lacrymal ducts, **355, 653**
 of nasal duct, 299, **298**
- Orifices of air-chambers of nose, **298**
- Oro-pharynx, 227, **212, 296**
- Os orbiculare of incus, 424
- Ossicles, auditory, 423
- Ossification of cricoid cartilage, 274
 of thyroid cartilage, 247
- Othematomata, 400, 660
- Otic ganglion, 691, **303, 690**
- Otitis externa, 401
 media, chorda tympani nerve, 426
 during dentition, 426
 ligaments, 424
 pus, 423
- Otoliths, 437
- Oval window, 420, 431. *Vide* Fenestra Ovalis.
- Ozæna, 301
- P.**
- Pacchionian bodies, 445, 708, **709**
- Pain in glaucoma, 362
- Palate, cleft, 214
 operation, 215
 hard, 214, **212, 239, 296**
 blood supply, 214
 nerve supply, 215
 soft, 238, **212, 236, 239, 296**
 cleft, 216
 muscles, **242, 243**
- Palatine aponeurosis, 246, **242**
 ascending, 92
 descending, 307, **105**
 artery, 684, **682**
 branch of ascending pharyngeal artery, 97
 nerve, anterior, 697, 698
 external, **303, 690**
 great, **303, 690**
 posterior, 698, **303, 690**
- Palato-glossus muscle, 220, 246, **105, 109, 242, 243**
 action, 246
 insertion, 246
 origin, 246
- Palato-pharyngeus m., 245, **242, 243**
 action, 245
 insertion, 245
 origin, 245
- Palpebræ, 618
- Palpebral artery, **682**
 inferior, 337
 superior, 337
 branch of infra-orbital n., 675, 697, **620, 695**
 of lacrymal artery, 336
 of supra-orbital artery, 336
 commissures, 648
 fascia, 652
 fissure, 593, **649**
 ligaments, 652
 muscle of Müller, superior, **353**
 portion of conjunctiva, 651
- Palsy, Bell's, 670
- Pannus, 364
- Papillæ, circumvallate, 219, **109, 218, 236, 250**
 conjunctival, **353**
 filiform, 219
 foliata, 219
 fungiform, 219, **218, 250**
 lacrymalis, 648
- Papillitis, 415
- Paracentesis of membrana tympani, 419
- Paracentral convolution, 489, **488, 497, 516**
 fissure, 489, **488, 497, 516**
- Parallel fissure, 492, **477**
- Paralysis of facial n., 670
 of hypo-glossal nerve, 104
 of laryngeal nerve, superior, 82
 of larynx, 262
 of muscles of pharynx, 247
 of palate, 247
 of tongue, 220
 varieties, 504
- Parietal artery, a-scending, **447**
 convolution, ascending, 486, **474, 477, 480. Vide** Post-central Convolution.
 inferior, 486, **480**
 posterior, **474**
 superior, 486, **477, 480**
 eminences, 592
 fissure, 573, **572**
 lobe, 476, 485
 landmarks, 509
- Parieto-occipital fissure, 475, **474, 477, 480, 488, 494, 497, 516**
- Parieto-temporal a., **447**
- Parotid abscess, 657
 incision, 658
 branch of post-auricular a., 96
 fascia, 656
 gland, 63, 656, **157, 608, 613, 627, 640**
 contents, 657
 lobe of, carotid, 656
 glenoid, 656
 pterygoid, 656
 relations, 656
 removal, 658
 sensory nerve supply, 657
 wounds, 658
 lymphatic glands, 657, 702
- Par vagum, 466
- Pars basilaris, 482,
 ciliaris retinæ, 380
 intermedia of Wrisberg, 465, **539**
 iridica retinæ, 380
 optica retinæ, 380
 orbitalis, 482
 triangularis, 482
- Patellar fossa, 385
- Pathetic n., 327, 462, 728, **539. Vide** Cranial Nerve.
- Pectinate ligament of iris, 364
- Peduncle of cerebellum, inferior, 567, **539, 542**
 middle, 567, **539, 542, 552**

- Peduncle of cerebellum, superior, 543, 567, **536, 539, 542**
of olivary body, 554
of pineal body, **516, 529, 536, 542, 556**
- Peduncles of cerebellum, 562
of cerebrum, 460, 550. *Vide* Crura Cerebri.
of corpus callosum, 517
- Peduncular fibers of cerebrum, 548
- Perforated space, anterior, 459, **458**
posterior, 460, **458**
- Perforation of membrana tympani, 419
of nasal septum, 294
- Perichoroid lymph space, 392
- Pericranium, 617, **599**
- Periglottis, 270
- Perilymph, 431, 432
- Periorbita, 318
- Periosteal branch of supraorbital a., 336
- Periosteum of orbit, 318, **320**
- Pes accessorius, 531
anserinus, 670
hippocampi, 531, **523, 529**
- Petit, canal, 386, **360**
- Petrosal nerve, external superficial, 84
small, 426
superficial external, 733
large, 732
small, 732
sinus, inferior, 726, **714, 715**
superior, 726, **715**
thrombosis, 423
- Petrous ganglion, 116
- Pharyngeal aponeurosis, 231, **229, 243**
artery, ascending, 97, 105, **70, 78, 79, 229**
relations, 97
branch of ascending pharyngeal a., 97
of glosso-pharyngeal n., 116
of pneumogastric n., 81
bursa, 232, **233**
diverticulum, 26
nerve, 698, **303, 690**
plexus, 81, 116, 231
pouch, 26
recess, 232, **233**
tonsil, 232, **233**
hypertrophy, 232
of Luschka, 232
vein, descending, 97
- Pharyngitis, 232
- Pharyngo-esophageal junction, 227
- Pharynx, 227, **242**
blood supply, 238
coats, 237
constrictor m.'s, 228, **229**
inferior, **71**
middle, **71**
superior, **71**
dissection, 227
divisions, 227
foreign bodies, 227
interior, **236**
lymphatics, 238
- Pharynx, mucous membrane, 232
muscles, 227
nerve supply, 238
openings, 232
relations, 237
section, **212**
veins, 238
- Phlebitis of ophthalmic v., 338
- Phlebotomy, 32
- Phlegmonous erysipelas, 616
- Phrenic n., 60, **71, 78, 79, 149**
- Pia mater, 454
in hippocampal fissure, **546**
nerve supply, 455
- Pillar of fauces, 224
anterior, **212, 218, 250**
posterior, **212, 218, 236, 250**
of fornix, anterior, 522, **516, 529, 533, 536, 542, 546, 556**
posterior, 522, **523, 536, 546**
- Pineal body, 538, **516, 536, 539, 542, 556, 560**
peduncle, **516, 529, 536, 542, 556**
gland, 538. *Vide* Pineal Body.
- Pinguecula, 652
- Pinna, 399, 601, 660, 665, **398, 405, 661**
action, 665
blood supply, 400, 665
cartilage, 665
dermoid cyst, 400
development, 400
frost-bite, 400
gangrene, 400
intrinsic muscles, **401, 663**
ligaments, 400
lymphatics, 403, 665
nerve supply, 403, 665
sebaceous cyst, 400
skin, 660
- Pituitary body, 459, **343, 458, 516, 539, 552, 565, 715**
fossa, diaphragm, 717
membrane, 300
nerve supply, 303
- Platysma myoides m., 31, **30, 177, 621, 627**
action, 31
blood supply, 31
insertion, 31
nerve supply, 31
origin, 31
- Plexus, choroid, 454, 526, 544, **519, 523, 533, 536, 546, 565, 569**
of nerves, axillary, 148. *Vide* Plexus of Nerves, Brachial.
basilar, **715**
brachial, 60, 148, **51, 71, 149, 208**
line for, **67**
operation to expose, **208**
stretching, 209
cervical, 48, 65, **44**
branches, 48
- Plexus of nerves, cervical, descending branch, 45, **51, 208**
dissection, 38, 65
superficial branches, 38
supra-acromial branch, **34**
supra-clavicular branch, **34**
infra-orbital, 669, 675
pharyngeal, 81, 116, 231
subtrapezial, 66
tympanic, 426
vertebral, 85
of veins, pterygoid, 687
parotideus, 670
- Plica semilunaris, 651, **649**
- Pneumogastric n., 76, 466, 729, **39, 41, 78, 79, 164, 539. Vide Tenth Cranial Nerve.
branches, 81
cardiac branches, cervical, 83
ganglia, 76
relations, 76**
- Poisoning, lead, 214
- Pole of eyeball, anterior, 357
posterior, 357
- Politzer's method of inflating middle ear, 411
- Polypi, nasal, 301
- Polypus of frontal sinus, 311
- Pomum Adami, 273
- Pons varii, 460
Varolii, 460, 549, **458, 516, 539, 552, 560, 565**
dissection, 549
hemorrhage, 550
nuclei, 550
position, 455
relations, 549
- Portio dura, 466
mollis, 466
- Porus opticus, 362, 380
- Post-central convolution, 486.
Vide Parietal Convolution, Ascending.
fissure, 485, **474**
- Postero-lateral fontanel, 584
- Post-olivary fissure, 554
- Post-parietal convolution, 489
- Post-pharyngeal abscess, 232
- Pouch, glosso epiglottidean, 216
laryngeal, 269
pharyngeal, 26
- Precentral fissure, 481, **474, 477, 480**
line, 508
- Precuneus, **516**
convolution, 489
- Prefrontal region of brain, 499
- Preoccipital notch, 476
- Presbyopia, 391
- Preservation of brain, 717
- Pretracheal fascia, 47, **39, 41**
- Prevertebral branch of ascending pharyngeal a., 97
fascia, 46, **39, 41**
muscles, 155, **152**
- Princeps cervicis a., 95, **133, 137**
anastomosis, 95

- Process, ciliary, 374, **360, 365**
 mastoid, 591
 operation upon, 723
 of incus, **418**
 of malleus, **418**
 vermiform, of cerebellum,
 561, 562
- Processes of dura mater of brain,
 717, **714**
- Processus brevis, 423, **409**
 caudatus, 400, **401, 663**
 e cerebello ad testes, 543.
Vide Peduncle of Cerebellum,
 Superior.
 gracilis, 423, **409**
- Profunda cervicis a., 147, **133,**
137. *Vide* Cervical Artery,
 Deep.
- Promontory of membrana tym-
 pani, 420
- Protuberance, external occipital,
 25, 591
- Prussak's chamber, **409**
- Pterion, 588, **506**
- Pterygoid a., 683, **678**
 external, 684, **682**
 internal, 684, **682**
 lobe of parotid gland, 656
 muscle, external, 679, **678**
 action, 680
 blood supply, 680
 insertion, 679
 nerve supply, 680
 origin, 679
 relations, 680
 internal, 680, **303, 678,**
686, 690
 action, 680
 blood supply, 680
 insertion, 680
 nerve supply, 680
 origin, 680
 relations, 680
 plexus of veins, 687
- Pterygo-maxillary ligament, 231,
 637, **229**
- region, 676, **678**
 abscess, 692
 contents, 679
 dissection, 676
 hemorrhage into, 692
 lymphatics, 687
 nerves, 687
 veins, 687
- Pterygo-palatine a., 684, **682**
 foramen, 693
 nerve, 698
- Pulley for superior oblique m.,
 331, **334, 632**
- Pulsation in jugular vein, exter-
 nal, 32
 of dura mater of brain, 711
 of innominate a., 18
 of ophthalmic v., 338
 of orbit, 338
- Pulvinar, 538, **539**
- Puncta lachrymalia, 594, 618,
346, 632, 649
- Pupil, 367, **369**
 Argyll Robertson, 367
- Pupillary membrane, 367
- Purulent conjunctivitis, 361
- Pus in mastoid disease, 423
- Pus in otitis media, 423
- Pyramid of membrana tympani,
 420
 of middle ear, 412
- Pyramidal tract of medulla ob-
 longata, **552**
- Pyramidalis nasi m., 626, **627**
 action, 629
 insertion, 626
 nerve supply, 629
 origin, 626
 relations, 626
- Pyramids, decussation, **458**
 of cerebellum, 562
 of medulla oblongata, 551
 anterior, **458**
 decussation, 553,
 554, **552**
- Q.**
- Quadrate convolution, 489, **488,**
497
 lobe of cerebellum, 561, **560**
 of cerebrum, **516**
- Quadratus menti m., 636. *Vide*
 Depressor Labii Inferioris Mus-
 cle.
- Quinsy, 225
- R.**
- Ramus subcutaneus mææ n., 694
- Ranine a., 92, 114, **105, 221**
 anastomosis, 114
- Ranula, 114, 216
- Raphe of corpus callosum, 517
 of pharynx, **229**
- Recess of fauces, 221, **239**
 pharyngeal, 232, **233**
 sphenoid, of Meyer,
 229
 tonsillar, 224
- Recessus epitympanicus, 407
- Recti m.'s, common tendon, infe-
 rior, 347
 superior, 347
- Rectus capitis anticus major m.,
 156, **78, 79,**
152
 m., action, 156
 m., insertion,
 156
 m., nerve sup-
 ply, 156
 m., origin, 156
 minor m., 156, **152**
 m., action, 156
 m., insertion,
 156
 m., nerve sup-
 ply, 156
 m., origin, 156
 lateralis m., 156, **152**
 action, 156
 insertion, 156
 nerve supply,
 156
 origin, 156
 muscle, external, 342, **321,**
326, 330, 334,
339
 action, 342
- Rectus capitis muscle, external,
 insertion, 342
 nerve supply, 342
 origin, 342
 inferior, 346, 347, **339,**
632
 action, 347
 insertion, 347
 nerve supply, 347
 origin, 347
 internal, 342, **326, 330,**
334, 339
 action, 342
 insertion, 342
 nerve supply, 342
 origin, 342
 superior, 331, **320, 326,**
330, 334, 339,
346, 632
 action, 331
 insertion, 331
 nerve supply, 332
- Recurrent branch of lacrymal a.,
 336
- laryngeal n., 82, 127, **71,**
78, 79
 nerve of fourth cranial, **326**
- Red nucleus, 553
- Reflected portion of conjunctiva,
 651
- Reflex iris, 368
- Refracting media of eye, 361
- Region of brain, Broca's, 503
 occipito-angular, 203
 prefrontal, 499
 silent, 499
- Reid's base line, 507, **506, 589**
- Reil, island, 470, 481, 548, **471,**
483, 546, 565, 569
- gyri aperti, **471**
- Reissner, membrane, 432
- Removal of brain, 712
 of Gasserian ganglion, 731
 structures involved,
 731
- Resection, Gasserian ganglion,
 199
 of dental n., inferior, 200
 of infra-orbital n., 199
 of lingual n., 205
 of maxillary n., inferior, 199
 superior, 199
 of spinal accessory n., 58, 205
- Respiratory portion of nasal fosse,
 300
 nerve of Bell, external, 153
- Restiform body, 465, 554, 557,
536, 542, 556
- Retina, 380, **360, 381**
 blind spot, 380
 blood supply, 380
 central a., 336, **360, 384**
 vein, **360, 384**
- Retinal a., **381**
 veins, 385, **381**
- Retrahens aurem m., 605, **627**
 action, 605
 insertion, 605
 nerve supply, 605
 origin, 605
- Retzius, foramen, 441, 544
- Rhinoliths, 300
- Rhinoplasty, 285

- Rhinocopy, anterior, 307
 posterior, 308
 Rhomboid n., **149**
 Ridges, superciliary, 588
 temporal, 592
 Rima glottidis, 248, 266, **267**
 Risorius m., 31, 634, **627**
 action, 634
 insertion, 634
 nerve supply, 634
 origin, 634
 Risus sardonius, 634
 Rivini, notch, 416
 Rodent ulcer of nose, 285
 Rolando, fissure, 475, **474, 477, 480, 516**
 line, 507, **506**
 funiculus, 554, 557
 tubercle, 557
 Rostrum of corpus callosum, 517, **488, 497, 546**
 Rotation of cornea, 348
 Rouge's operation, 300
 Rupture of membrana tympani, 419
- S.**
- Sac, lacrymal, 352, 594, **321, 350, 355, 653**
 abscess, 644
 laryngeal, 269
 Saccule, 431, 437, **439**
 Saccus endolymphaticus, 437
 Sagittal section of brain, 567
 of eyelid, **353**
 suture, 573, 588
 Salivary duct, obstruction, 114
 fistula, 658
 Salpingo-pharyngeus m., 245, **243**
 Santorini, cartilage of, 275
 fissure, 666, **401, 663**
 muscle, 634. *Vide* Risorius Muscle.
 Sarcoma, melanotic, of choroid, 379
 of dura mater of brain, 711
 Scala media, 432, 437, **439**
 tympani, 432, **436**
 vestibuli, 432, **436**
 Scalene m., posterior, **39**
 tubercle, 154
 Scalenus anticus m., 153, **39, 71, 78, 79, 129, 152**
 action, 154
 insertion, 153
 nerve supply, 154
 origin, 153
 relations, 153
 medius m., 154, **39, 50, 71, 129, 152**
 action, 154
 insertion, 154
 nerve supply, 154
 origin, 151
 relations, 154
 posticus m., 151, **129, 152**
 action, 151
 insertion, 154
 nerve supply, 154
 origin, 151
 Scalp, 587, 601
 abscess, 617
 Scalp, areolar tissue, 616
 arteries, 588, 605, **608, 613, 640**
 congestion, 615
 dissection, 601
 fascia, 602, **603**
 hematoma, 617
 inflammation, 617
 layers, 601, **599**
 lymphatics, 612, 703
 mobility, 616
 muscles, **613, 627**
 nerves, 611, **609, 613**
 skin, 602
 tumors, 587, 616
 veins, 606, **35, 645**
 wounds, 602, 616
 Scalping, 616
 Scaphoid fossa, 660
 Scapular a., posterior, 59, 146, **70, 133**
 anastomosis, 146
 vein, posterior, **70**
 Schlemm, canal of, 362, **360, 365, 384, 394**
 Schneiderian membrane, 300
 nerve supply, 302
 Sclera, 361, **360, 365, 369, 376, 381, 394**
 Scleral sulcus, 362
 Sclerotic coat, 361
 portion of conjunctiva, 358, 651
 Sebaceous cyst of pinna, 400
 gland of cilium, **353**
 Second cervical n., anterior division, **71, 78**
 cranial n., 462, 727. *Vide* Optic Nerve.
 sight, 396
 Section of brain, coronal, 567
 sagittal, 567
 of cerebrum, **546**
 of ciliary region of eyeball, **365**
 of eye, **360**
 of eyelid, **353**
 of tongue, **221**
 transverse, of neck, **39**
 Sections of brain, 567
 Semicircular canal, ampulla, 432
 external, 439, **427, 430**
 posterior, **427, 430, 439**
 superior, **427, 430, 439**
 canals, 431, **427**
 membranous, 437
 Semispinalis colli m., **39**
 Sensori-motor area of brain, 500
 Sensory areas of brain, 499, **501**
 nerves of parotid gland, 657
 root of lenticular ganglion, 335
 Septa orbitale, 652
 Septal branch of nasal n., 335
 of Meckel's ganglion, 698
 cartilage of nose, 293, **291**
 Septum, artery of, 307
 linguae, 111, 220
 lucidum, 522, **516, 523, 536, 542, 546, 556, 565**
 Septum, nasal, 294, **236, 291, 306**
 deviation, 294
 perforation, 294
 of nose, artery, 643, **613, 640**
 hemorrhage from, 643
 orbitale, **320**
 Serratus magnus m., **50, 71**
 Sesamoid cartilages of nose, 293
 Seventh cervical n., anterior division, **71, 78**
 cranial n., 465, 728, **458, 715**
 origin, **552**
 Sheath, carotid, 66
 contents, 73
 Shrapnell's membrane, 419, **418**
 Sight, second, 396
 Sigmoid sinus, 720, **715**
 course, 592
 thrombosis, 423, 511
 Silent region of brain, 499
 Sinking of eyeball, 357
 Sinus alae parvae, 721
 cavernous, relation to Gasserian ganglion, 725
 section, **343**
 cervicalis, 26
 circular, 726, **714, 715**
 circularis rectii, **471**
 ethmoid, 315. *Vide* Cells, Ethmoid.
 frontal, 308, **298, 314, 339, 355, 653, 705, 709**
 congestion, 311
 pyramida, 311
 fracture, 311
 polypus, 311
 pus, 311
 inferior longitudinal, 724, **714**
 petrosal, 726, **714, 715**
 lateral, 720, **714, 715**
 course, 592
 divisions, 720
 line, 723, **721**
 operation to expose, 510
 thrombosis, 511, 720
 tributaries, 720
 longitudinal, inferior, 724, **714**
 superior, 719, **714, 715**
 course, 592
 line, 719
 wound, 719
 maxillary, 312. *Vide* Antrum of Highmore.
 occipital, 724, **715**
 of chamber of eye, anterior, 391
 of external auditory meatus, 403
 of larynx, 266
 of Morgagni, 231, **229**
 petrosal, inferior, 726, **714, 715**
 superior, 726, **715**
 thrombosis, 723
 pyriformis, 237, 248, **218, 236, 250**
 sigmoid, **715**

- Sinus, sigmoid, course, 592
 thrombosis, 423, 514
 sphenoid, 315, **291**
 sphenoparietal, 724
 straight, 532, 724, **714**
 superior longitudinal, 719,
714, 715
 course, 592
 line, 719
 wound, 719
 petrosal, 726, **715**
 transverse, 726, **714, 715**
- Simuses, cavernous, 725, **715**
 of dura mater of brain, 718,
714, 715
 hemorrhage
 from, 719
 of frontal bone, 591
- Sixth cervical n., **149**
 anterior division, **39,**
71, 78
 cranial n., 311, 465, 728,
326, 339, 343, 458, 715
- Skin of eyelid, **353**
 of face, 625
 of neck, 17, 26
 of nose, 285
 of pinna, 660
 of scalp, 602, **599**
- Skull, arteries, 573
 base, dislocation, 579
 fracture, 585
 blood supply, 617
 bones, development, 584
 bregma, 573
 fontanel, 584
 fracture, 692, 707
 fractures, 584
 lambda, 573
 sutures, 573
 vault, fracture, 585
- Slender lobe of cerebellum, **560**
- Slit, interpalpebral, 648
- Smegma præputii, 628
- Smell, center, 503
- Snoring, 637
- Socia parotidis, 656, 658, **613,**
627
- Soft palate, 238
- Space, erico-thyroid, 24
 intererural, 459
 interpeduncular, 459
 of Tenon, 324, 395, **321**
 perforated anterior, 459, **458**
 posterior, 460, **458**
 subarachnoid, 441
 aspiration, 442
 subdural, 441
 supra-sternal intra-aponeu-
 rotic, of Grüber, 37
 supravaginal lymph, **321**
- Spaces of Fontana, 362, 392, **365**
- Spheno-ethmoid recess of Meyer,
 299
- Sphenoid cells, 315, **212, 296,**
298, 309
 fissure, nerves in, 312
 structures traversing,
343
 sinus, 315, **291**. *Vide* Sphe-
 noid Cells.
- Sphenoidal cells, **714**
- Spheno-mandibular ligament, 574
- Spheno-maxillary division of in-
 ternal maxillary a., 683
 fossa, 693
 contents, 693
 foramina, 693
 Spheno-palatine a., 307, 684, **682**
 foramen, 693
 ganglion, 697
 nerve, 694, **303, 690, 695**
- Spheno-parietal sinus, 724
- Sphincter oculi m. *Vide* Orbicu-
 laris Palpebrarum Muscle.
- oris m., 634. *Vide* Orbicu-
 laris Oris Muscle.
- Spina helieis, 400
- Spinal accessory n., 57, 466, 729,
39, 51, 71, 78,
79, 539. *Vide*
 Eleventh Cranial
 Nerve.
 line for, **20, 67**
 operation to expose,
182
 resection, 58, 205
 artery, anterior, 449, **444,**
452
 lateral, of vertebral a.,
 143
 posterior, 449, **444**
- Spiral canal, 432
- Splenium of corpus callosum, 517,
488, 497, 516, 523, 546
- Splenius m., **39, 78, 79**
 capitis m., **50, 71, 152**
- Squint, convergent, 373
- Stapedius m., 425, **422**
 action, 425
 insertion, 425
 nerve supply, 425
 origin, 425
- Stapes, 424, **405, 409, 422**
 emra, 424
- Staphyloma of cornea, 364
- Stenson's duct, 658, **609, 613,**
621, 627, 640
 course, 658
 divisions, 659
 line, **27, 623**
 relations, 658
- Stephanion, 592
- Sterno-clavicular joint, 18
- Sterno-cleido-mastoid m., 17, 48.
Vide Sterno-mastoid Muscle.
- Sterno-hyoid m., 120, **39, 50, 71,**
78, 117
 action, 121
 blood supply, 121
 insertion, 120
 nerve supply, 120
 origin, 120
 relations, 120
- Sterno-mastoid a., inferior, 146,
70, 78
 middle, 58, 91, **59, 70,**
78, 177
 superior, 95, **70, 78**
 muscle, 17, 48, **39, 41, 50,**
71, 78, 79, 117
 action, 53
 blood supply, 53
 contraction, 53
 insertion, 53
 nerve supply, 53
- Sterno-mastoid muscle, origin, 48
 nerve, **71**
- Sterno-thyroid m., 121, **39, 50,**
71, 78, 117
 action, 121
 insertion, 121
 nerve supply, 121
 origin, 121
 relations, 121
- Stertorous breathing, 637
- Stilling, canal, 385
- Stirrup, 423. *Vide* Stapes.
- Strabismus, 348, 373
- Straight sinus, 532, 724, **714**
- Stretching brachial nerve plexus,
 209
 facial nerve, 205
- Stria terminalis, 526. *Vide* Tania
 Semicircularis.
- Striae acustice, 517
 auditory, 547
 longitudinales, 517, **513**
 laterales, 517
 medullares, **542, 556**
- Structure traversing sphenoid fis-
 sure, **343**
- Stylo-glossus m., 111, 220, **79,**
105, 109
 action, 111
 blood supply, 111
 insertion, 111
 nerve supply, 111
 origin, 111
- Stylo-hyoid branch of facial n.,
 669
 ligament, 115, **576, 577**
 muscle, 98, **50, 71, 105,**
177
 action, 103
 blood supply, 103
 insertion, 103
 nerve supply, 103
 nerves, **51**
 origin, 103
- Stylo-mandibular ligament, 574
- Stylo-mastoid a., 96
- Stylo-maxillary ligament, 46, 63,
 574, **576, 577**
- Stylo-pharyngeus m., 115, **79,**
105, 229
 origin, 115
- Subarachnoid cisterns, 441
 space, 441
 aspiration, 442
- Subclavian arteries, differences
 between, 128
 artery, 23, 60, 127, 166, **50,**
70, 78, 79, 133, 208
 branches, 136, **87**
 compression, 23
 diagram, **87**
 first portion, **129, 164,**
174
 ligation, 135,
 166
 irregularities, 170
 left, 128
 relations, 128
 ligation, collateral circula-
 tion, 135, **133**
 line, **20, 67**
 right, 127
 relations, 127

- Subclavian artery, second portion, 131
ligation, 135, 166
relations, 131
third portion, 131
guide, 175
ligation, 132, 166, 169
ligation, collateral circulation, 170
operation to expose, 167
relations, 131, 166
variations, 132
triangle, 51, 59, 55
contents, 60
dissection, 59
vein, 60, 35, 70, 78, 79, 129, 174, 645
- Subconjunctival hemorrhage, 358
- Subdural space, 441
- Sublingual a., 115, 78, 79, 105
anastomosis, 115
bursa, 216
gland, 113
blood supply, 114
nerve supply, 114
relations, 113
- Submaxillary a., 93
ganglion, 113
gland, 103, 113, 51, 177
relations, 103
lymphatic glands, 63, 702, 157
triangle, 54, 63, 55
contents, 63, 98
dissection, 63
- Submental a., 93, 50, 70, 105, 682
relations, 93
vein, 35, 645
- Suboccipital lymphatic glands, 702
- Subparietal fissure, 489, 496, 488, 497, 516
- Subpubic ligament, 616
- Subscapular a., 133
nerve, lower, 149
middle, 149
upper, 149
- Substantia ferruginea, 547
nigra, 553
propria, 363
- Subthalamic body, 553
- Subtrapezial nerve plexus, 66
- Sulcus centralis insule, 470, 471
Reilii, 470
cerebelli, superior, 560
choroideus, 538
circularis Reilii, 470
median longitudinal, 542
of brain. *Vide* Fissure.
olfactory, 456
orbital, 456
scleral, 362
triradiate, 456
- Superficial cervical n., 31
Superficialis colli n., 45
- Superior maxilla, excision, 579
lines of incision, 572
fracture, 586
- Supermeritary auricles, 400
- Supra-acromial branch of cervical plexus, 34
of supra-scapular artery, 146
nerve, 45
- Supra-clavicular branch of cervical plexus, 34
fossa, 18, 21
nerve, 45
triangle, 59
dissection, 59
- Supra-hyoid aponeurosis, 98
- Supra-marginal convolution, 486, 489, 474, 477
- Supra-maxillary branch of facial n., 670, 609, 613, 620
- Supra-meatal triangle of MacEwen, 415
- Supra-orbital arches, 593
artery, 336, 605, 197, 334, 603, 608, 613, 620, 640
anastomosis, 336, 605
branches, 336
operation to expose, 197
foramen, 595
margin, 316
nerve, 327, 611, 197, 326, 339, 609, 613, 620
neurectomy, 611
operation to expose, 196, 197
notch, 316, 595
vein, 35, 645
- Supra-parietal convolution, 474
- Supra-rimal portion of larynx, 296
- Supra-scapular a., 60, 145, 50, 70, 78, 79, 129, 133, 174
branches, 146
relations, 145
nerve, 153, 51, 71, 149
vein, 60, 35, 50, 70, 167, 645
- Supra-sternal branch of cervical plexus, 34
fossa, 18, 21
intra-aponeurotic space of Grüber, 37, 46
nerve, 45
- Supra-trochlear n., 327, 611, 326, 339, 609, 613
neurectomy, 611
- Supra-vaginal lymph space, 324, 395, 321
- Surface anatomy of neck, back of, 25
markings of neck, 17, 21
of auricle, 601
of cranium, 587, 589
of ear, 701
of eye, 593
of face, 592
of pinna, 701
- Suspensory ligament of eyeball, 324
of lachrymal gland, 328
of lens, 360, 372
of malleus, 424, 409, 413, 422
- Suture, coronal, 573, 588
- Suture, frontal, 573, 588
lambdoid, 573, 588
parietal, 573
sagittal, 573, 588
transverse occipital, 573
- Sutures of skull, 573
- Sylvian a., 446
ventricle, 525. *Vide* Fifth Ventricle.
- Sylvius, aqueduct, 537, 483, 516, 528, 529
fissure, 456, 470, 471, 474, 477, 569
line, 507, 506
- Symblepharon, 361
- Sympathetic n., 78, 79
cervical portion, 83
- Synechia, annular posterior, 395, 394
anterior, 367
posterior, 367
- Synovial membrane of temporo-maxillary articulation, 574
- Swallow's nest, 562
- Sweat gland of Moll, 353

T.

- Tactile sensation, area, 500
- Tænia violacea, 547
- Tæniæ hippocampi, 522, 526
semicircularis, 526, 538, 519, 523, 536, 542, 546, 556
tectæ, 517
- Tapping lateral ventricles, 442
- Tarsal cartilage, 593, 652
ligament, external, 630
internal, 630
- Taste center, 503
- Tears, 328
course, 352
- Teeth, 213
test, of Hutchinson, 214
- Tegmen antri, 412
destruction, 420
- tympani, 422
destruction, 420
- Tegmental nucleus, 553
- Tegmentum, 460
of crus cerebri, 553, 488, 497
nuclei, 553
- Tela choroidea, inferior, 544, 516
superior, 531
- Temporal a., 606, 193
anterior, 606, 603, 608, 613, 640
deep, 683, 678, 682, 686
middle, 608, 613, 620, 640
operation to expose, 193
posterior, 606, 603, 608, 613, 640
anastomosis, 606
deep, 683, 678, 682
superficial, 133, 608, 613, 620, 621, 640, 678, 682, 686
ligation, 195
branch of facial n., 612, 669, 609, 613, 620

- Temporal branch of orbital n., 351, 612, 674, **609, 613, 620**
 convolution, inferior, **474, 477**
 middle, **474, 477**
 superior, **474, 477**
 division of facial n., 666
 fascia, 618, **620**
 abscess beneath, 618
 density, 618
 relations, 618
 fissure, middle, **474, 477**
 superior, **474**
 lobe, 181, 191, **471**
 inferior surface, **494**
 landmarks, 509
 lobes, 456
 lymphatics, 615
 muscle, 625, **321, 621, 678, 686**
 action, 625
 blood supply, 625
 insertion, 625
 nerve supply, 625
 origin, 625
 nerve, anterior, 612, **686**
 posterior, 612, **678**
 superficial, **688**
 nerves, deep, 687
 region, 625, **621**
 ridges, 592
 vein, **50, 70, 319**
 middle, **35, 645**
 superficial, **35, 613, 620, 645**
- Temporo-facial n., 669
 branches, 669
- Temporo-malar n., 351, 691
- Temporo-maxillary articulation, 573, **576, 577**
 blood supply, 574
 interarticular fibro-cartilage, 571
 ligaments, 573
 capsular, **576, 577**
 internal lateral, 574
 movements, 574
 nerve supply, 574
 synovial membrane, 574
 vein, **35, 621, 695**
- Temporo-sphenoid abscess, 511
 trephining, 511
 convolution, inferior, 495, **494**
 middle, 492, **494**
 superior, 492, **494**
 fissure, inferior, 492, **488, 494, 497**
 middle, 492, **494**
 line, 510, **506**
 superior, 492, **494**
 line, 510, **506**
 lobe, 456, 181, 491, **458, 565. Vide Temporal Lobe.**
 landmarks, 509
- Tendo oculi, 591, 630, 652, **350**
 palpebrarum, 630
- Tendon, central, of perineum, 590
 common, of recti muscle, inferior, 347
 superior, 347
- Tendon of omo-hyoid m., **39**
 tensor tympani, **409**
- Tenon, capsule, 321, 342, **320**
 capsula, **321**
 space, 324, 395, **321**
- Tenotomy in torticollis, 37
- Tensor palati m., 245, **303, 690**
 action, 245
 insertion, 245
 origin, 245
- tarsi m., 633, **321, 346, 355, 632, 653**
 action, 634
 insertion, 633
 nerve supply, 634
 origin, 633
 relations, 633
- tympani m., 425, **405, 422**
 action, 425
 insertion, 425
 nerve supply, 425
 origin, 425
 tendon, **409**
- Tenth cranial n., 76, 466, **458, 542, 556**
 origin, **552**
 nerve, 729, **715**
- Tentorium cerebelli, 455, 712, 717, 718, **714**
- Terminal branch of anterior ethmoid a., 337
- Testes, 543, **542, 556, 560**
 brachia, 543
- Tetanus, 231
- Thalamus, optic, 526, 538, **519, 523, 542, 546, 552, 569**
 pulvinar, **539**
 tubercle, anterior, 538
 posterior, 538
- Third cervical n., anterior division, **71, 78**
 cranial n., 341, 462, 727, **326, 458. Vide Oculo-motor Nerve.**
 origin, **552**
 ventricle, 532, **516, 528, 529, 536, 556, 569**
- Thoracic a., long, **123**
 superior, **133**
- duct, 128, 160, **129**
 relations, 131
 nerve, external anterior, **149**
 first, **149**
 anterior division, **79**
 internal anterior, **149**
 posterior, or long, 153, **51, 71, 149**
- Thrombosis of lateral sinus, 511, 720
 of petrosal sinus, superior, 423
 of sigmoid sinus, 423, 511
- Thyro-arytenoid ligaments, superior, 266
- Thyro-arytenoideus m., 261, **259**
 action, 261
 insertion, 261
 nerve supply, 261
 origin, 261
- Thyro-epiglottidean ligament, 270
- Thyro-epiglottideus m., 261
 action, 261
 nerve supply, 261
- Thyro-glossal duct, 125, 216
- Thyro-hyoid bursa, 255
 ligament, 255, **254, 263**
 membrane, 255, **123, 212, 251, 254, 263**
 muscle, 121, **50, 71, 78, 177**
 action, 121
 blood supply, 121
 insertion, 121
 nerve supply, 121
 origin, 121
 relations, 121
- Thyroid a., inferior, 61, 144, **78, 129, 133, 174, 229**
 anastomosis, 144
 branches, 144
 irregularities, 179
 ligation, 145, 179, **177**
 line, **20, 67**
 operations to expose, **174**
 superior, 86, **50, 70, 78, 105, 123, 133, 177, 251**
 irregularities, 188
 ligation, 187, **177**
 line, **20, 67**
- axis, 114, **78, 79, 133, 174**
 branches, 144
- body, **39, 78**
- cartilage, 23, 273, **123, 251, 254, 258, 259, 271**
 fracture, 274
 ossification, 274
- gland, 23, 122, **123, 129, 251**
 arteries, 126
 capsule, 126
 in tracheotomy, 122
 isthmus, **251**
 nerves, 126
 relations, 122
 structure, 122
- veins, 126
 inferior, **78, 79, 123, 164, 251**
 middle, **35, 70, 645**
 superior, 91, **35, 70, 645**
- Thyroidea ima a., 126, **133**
- Thyroidectomy, 126
- Tic convulsif, 205
 douloureux, 700
- Tissue of eyelids, 652
- Tongue, 216, **212**
 apex, 216
 arteries, **105**
 atrophy, 220
 base, 216
 blood supply, 223
 dissection, 216
 dorsum, 216, **218**
 excision, 223
 glands, 219
 in anesthesia, 223
 lymphatics, 223
 muscles, 219

- Tongue, muscles, dissection, 108
 extrinsic, 219, **109**
 intrinsic, 220
 nerve supply, 223
 paralysis, 220
 root, 216
 section, **221**
 tip of, 216
- Tongue-tie, 115, 216
 operation, 115, 215
- Tonsil, **221, 218, 239**
 amputation, 225
 arteries, **105**
 hypertrophy, 225
 lingual, 219
 lymphatics, 225
 malignant growths, 226
 of cerebellum, 562
 of Luschka, pharyngeal, 232
 pharyngeal, **233**
 hypertrophy, 232
 relations, 225
 tubal, 411
- Tonsillar a., 93
 branch of dorsalis linguæ a.,
105
 of facial a., **105**
 of glosso-pharyngeal n.,
 119
 recess, 224
- Tonsillitis, 225
- Tonsils, blood supply, 224
 crypts, 224
 nerve supply, 225
 veins, 225
- Tophi, 400, 665
- Toreular Herophili, 591, 719
- Torticollis, 53
 spasmodic, 58
 tenotomy, 37
- Touch, center, 503
- Trabeculae, 647
- Trachea, 24, 282, **39, 41, 123, 129**
 cervical portion, relations, 282
- Tracheal branch of inferior thyroid a., 145
- Trachelo-mastoid m., **152**
- Tracheotomy, 24, 282, **279**
 incision, **21**
 thyroid gland in, 122
 veins in, 37
- Tract of medulla oblongata, lateral, 554, **552, 556**
 pyramidal, **552**
 olfactory, 456, 462, **303, 458, 539, 690**
 optic, 462, **458, 539, 552, 565, 569**
 diagram, **463**
 uveal, 367
- Tracts, optic, 462
- Tragicus m., 665, **401, 663**
- Tragus, 399, 660, **398, 661**
- Transversalis colli a., 59, 60, 146, **50, 70, 78, 129, 133, 174, 208**
 vein, 60, **35, 50, 70**
 humeri a., 145
- Transverse a., 450, **444, 452**
 facial a., 644, **608, 613, 620, 640, 645**
- Transverse facial vein, **35, 678**
 fissure, 467, 481. *Vide* Pre-central Fissure.
 line, 507
 occipital fissure, **572**
 suture, 573
 sinus, 726, **714, 715**
- Transversus auris m., 665, **401, 663**
- Trapezins m., **39, 41, 50, 71, 78, 79**
- Traumatic epilepsy, trephining, 512
- Trephining in abscess, cerebellar, 511
 extradural, 511
 temporo-sphenoid, 511
 indications, 510
 in epilepsy, Jacksonian, 504
 traumatic, 512
 in extradural hemorrhage, 734
 in headache, 512
 mastoid antrum, 415
- Triangle, carotid, inferior, 54, 61, **55**
 contents, 61
 dissection, 61
 superior, 54, 62, **55**
 contents, 62
 dissection, 62
- common, anterior, 54
 posterior, 54
- digastric, 54, 63
 dissection, 63
- lingual, 64
 dissection, 64
- occipital, 54, **55**
 abscess, 59
 contents, 57
 dissection, 57
- of election, 63
- of neck, anterior, 18
 posterior, 18
- subclavian, 54, 59, **55**
 contents, 60
 dissection, 59
- submaxillary, 54, 63, **55**
 contents, 63, 98
 dissection, 63
- supra-clavicular, 59
 dissection, 59
- supra-meatal, of MacEwen, 415
- Triangles of neck, 54
 diagram, **55**
 dissection, 54
- Tributaries to lateral sinus, 720
- Trifacial n., 465, 728, **339, 539**.
Vide Fifth Cranial Nerve.
 neuralgia, 698
- Trigeminal neuralgia, 700
- Trigeminus n., 465. *Vide* Fifth Cranial Nerve.
- Trigonum hypoglossi, 547, **536, 542, 556**
 olfactorium, 462
 omo-clavicular, 59
 ventriculi, 521
- Tricorned ventricles, 518
- Triradiate fissure, 456, 482, **458, 483, 488, 497**. *Vide* Orbital Fissure.
- Triradiate sulcus, 456
- Trochlear branch of supraorbital a., 336
 nerve, 327, 462, 543. *Vide* Fourth Cranial Nerve.
- Tubal tonsil, 411
- Tube, Eustachian, 408, **405, 409**
 blood supply, 412
 mucous glands, 411
 nerve supply, 412
 occlusion, 411
 orifice, **298, 422**
 relations, 411
- Tuber annulare, 460, 549. *Vide* Pons Varolii.
 cinereum, 459, **458, 516**
 valvulae of cerebellum, 562, **560**
- Tubercle, carotid, 24, **152**
 cuneate, 557
 Darwin's, 399, **398, 401, 663**
 of cerebellum, laminated, 562
 of epiglottis, 270
 of optic thalamus, anterior, 538
 posterior, 538
 of Rolando, 557
 scalene, 154
- Tuberculum acusticum, 547, **536, 542, 556**
- Tumors of antrum of Highmore, 312
 of scalp, 587, 616
- Turbinated bone, **296**
 inferior, 299, **309, 350**
 middle, 299, **309, 350**
 superior, 299
 bones, necrosis, 300
- Twelfth cranial n., 104, 467, **458**
 origin, **552**
 nerve, 729, **715**
- Tympanic a., 683, **682, 686**
 branch of ascending pharyngeal a., 97
 of glosso-pharyngeal n., 116, 426
 plexus of nerves, 426
- Tympanum, 407
 anterior view, **409**
 ligaments, 424
 nerve supply, 425
 nerves, 425

U.

- Ulcer of cornea, 363
 rodent, of nose, 285
- Ulnar n., **149**
- Umbo, 416, **418**
- Uncinate convolutions, 495
- Uncus, **483, 488, 494, 497**
- Utricle, 431, 437, **439**
- Uveal tract, 367
- Uvula, 238, **212, 236, 239, 296**
 of cerebellum, 562, **560**
 of mouth, 224

V.

- Vagus n., 76, 729
- Vallecula, **218, 250**

- Valleculea of cerebellum, 558
 Sylvii, 470
 Vallecule, glosso-epiglottidean, 216
 Vallum, 219
 Valsalva method of inflating middle ear, 111
 Valve of Vieussens, 543. *Vide* Medullary Velum, Superior.
 Variations in brain, 510
 Vas aberrans, artery, 133
 Vascular coat of eye, 367
 Vascularity of face, 617
 Vault of skull, fracture, 585
 Vein, angular, 606, **35, 645**
 anterior jugular, **645**
 maxillary, 687, **645**
 temporal diploic, 707, **705**
 auricular posterior, 96, **35, 50, 51, 70, 645**
 central, of retina, **360, 384**
 cerebral superior, **709**
 cervical, deep, 96, 147, **35, 645**
 superficial, **70**
 ciliary, anterior, 379, **369, 377, 384**
 communicating, **70**
 conjunctival, **384**
 deep cervical, 96, **35, 645**
 facial, 687
 external jugular, **645**
 line, **623**
 facial, 93, 606, 644, **35, 50, 70, 613, 620, 621, 645**
 arterial blood in, 617
 communications, 647
 course, 617
 deep, 617
 disease, 647
 line, **623**
 relations, 93
 transverse, **35, 645**
 frontal, **35**
 infra-hyoid, **117**
 infra-orbital, 676
 innominate, **35, 645**
 left, **129**
 right, **129**
 internal jugular, **645**
 maxillary, 687, **645**
 jugular, anterior, 23, 37, **30, 34, 35, 39, 50, 70, 117, 164, 174, 177, 645**
 external, 32, 60, **30, 34, 35, 39, 50, 70, 174, 208, 645**
 jugulo-cephalic branch, 23
 line, 23, 32, **27, 623**
 pulsation in, 32
 termination of, 18
 internal, 61, 62, 73, **35, 39, 41, 50, 70, 78, 129, 164, 174, 645**
 position, 18
 relations, 73
 posterior, **30, 35, 50, 70, 208, 645**
- Vein, jugular, posterior, external, 37
 jugulo-cephalic, 23
 labial, inferior, **117**
 lingual, 92, 112, **35, 50, 51, 70, 177, 645**
 relations, 112
 mastoid, 37
 maxillary, anterior, 687, **35, 645**
 internal, 687, **35, 50, 70, 645**
 middle temporal, **645**
 thyroid, **645**
 occipital, 95, **35, 645**
 diploic, 707, **705**
 relations, 95
 ophthalmic, 337, **343**
 common, 338, **334**
 inferior, 338, **334**
 phlebitis, 338
 pulsation, 338
 superior, 338, **334**
 orbital, **35, 645**
 pharyngeal, descending, 97
 posterior auricular, **35**
 pubic, internal, 615
 retinal, **381**
 scapular, posterior, **70**
 subclavian, 60, **35, 70, 78, 79, 129, 174, 645**
 submental, **35, 645**
 superficial temporal, 620, **645**
 superior thyroid, **645**
 supra-orbital, **35, 645**
 supra-scapular, 60, **35, 50, 70, 167, 645**
 temporal, **50, 70, 193**
 diploic, anterior, 707, **705**
 middle, **35, 645**
 superficial, **35, 613, 620, 645**
 temporo-maxillary, **35, 621, 645**
 thyroid, inferior, **78, 79, 123, 164, 251**
 middle, **35, 70, 645**
 superior, 91, **35, 70, 645**
 transversalis colli, 60, **35, 50, 70, 645**
 transverse facial, **35, 645**
 vertebral, 113, **35, 39, 78, 79, 129, 137, 174, 645**
- Veins, cerebellar, 451
 diploic, 701, **705**
 frontal, 707, **645**
 diploic, 707, **705**
 fronto-sphenoid, 707, **705**
 in tracheotomy, 37
 meningeal, 735
 of brain, 451
 of cerebrum, 454
 of external auditory meatus, 407
 of eyeball, 379
 of eyelids, 655
 of face, **35, 645**
 of Galen, 442, 532, **533, 714**
 of head, **645**
 of internal ear, 437
 of larynx, 265
- Veins of middle ear, 425
 of nasal cavities, 307
 of neck, **35, 645**
 of nose, 285
 of orbit, **334**
 of pharynx, 238
 of pterygoid plexus, 687
 of pterygo-maxillary region, 687
 of scalp, 606, **35, 645**
 of serotum, 611
 of tonsils, 225
 pterygoid plexus, 687
 retinal, 385
 thyroid, 126
- Velum interpositum, 454, 531, **488, 497, 516, 533, 546, 569**
 medullary, posterior, 562
 superior, 543, **516, 536, 542, 560. Vide** Valve of Vieussens.
- Vena aqueductus cochleae, 437
 vestibuli, 437
 cava, superior, **129, 137**
 vorticosa, 374, 379, **360, 369, 376, 377, 384**
- Venesection, 32
- Ventricle of Arantius, 544
 of brain, fifth, 525, **488, 497, 516, 523, 565**
 fourth, 544, **516, 528, 529, 542, 560**
 floor, **536**
 lateral, 518, **488, 497, 516, 523**
 body, 518, **519, 528, 569**
 cornu, anterior, 521, **528, 529, 546**
 middle, 521, **528, 529**
 posterior, 521, **528, 529, 546**
 posterior, bulb, **529**
 cornua, **519**
 dissection, 518
 tapping, 412, 511
 Sylvian, 525
 third, 532, **516, 528, 529, 536, 542, 556, 569**
 trihorned, 518
 of corpus callosum, 496
 of larynx, 248, 266, **212, 218, 250, 296**
- Ventricles of brain, **536**
 bodies, **529**
 diagram, **528, 529**
 section, **516**
- Ventriculi tricornes, 518
- Vermiform process of cerebellum, 561
 inferior, 562
 superior, 561
- Vertebra prominens, 25
- Vertebral a., 61, 136, 119, **39, 70, 78, 79, 129, 133, 137, 152, 164, 174, 444, 452**

Vertebral a., branches, 143
 cervical portion, 136
 guide, 176
 irregularities, 176
 ligation, 143, 175
 occipital portion, 143
 operation to expose, **174**
 relations, 136, 175
 vertebral portion, 136
 nerve plexus, 85
 vein, 143, **35, 39, 78, 79, 129, 137, 645**

Vertigo, aural, 437

Vesico-prostatic plexus of veins, **263**

Vessels of brain, 438
 of neck, **70, 71**

Vestibular n., 438, 466

Vestibule of cochlea, **427**
 of labyrinth, 431
 of mouth, 210, **212**
 of nose, 285, 302

Vicq d'Azyr, bundles, 522

Vidian a., 684, **682**
 canal, **309**
 nerve, 302, 698, **303, 690, 695**

Vieussens, valve, 543

Visceral arches, 25

Vision centers, 503

Vitreous body, 385
 chamber, 385, **360**

Vocal cords, 24
 false, 248, 266, **212, 218, 250, 296**
 true, 248, 266, **212, 218, 250, 296**

Vomer, **291**

W.

Waldeyer's glands, **353**

Weight of brain, 455

Wharton's duct, 113, **70, 71, 78**
 relations, 113

Wilde's incision, 591

Willis' circle, 445, **444**

Window, oval, 420
 round, 420

Wings of nose, 284

Word-blindness, 503

Word-deafness, 503

Wounds of cornea, 363
 of face, 647
 of longitudinal sinus, superior, 719

Wounds of middle meningeal a.,
 734
 of parotid gland, 658
 of scalp, 602, 616

Wrisberg, cartilage, 274
 pars intermedia, 465

Wry-neck, 53

Z.

Zinn, ligament, 347, **334**
 zone, 385
 zonula, 385


Zone of Zinn, 385


Zonula of Zinn, 385


Zygomatic arch, 596
 fossa, 693
 contents, 693
 fracture, 586

Zygomaticus major m., 636, **627**
 action, 637
 insertion, 636
 nerve supply, 637
 origin, 636

minor m., 637, **627**
 action, 637
 insertion, 637
 nerve supply, 637
 origin, 637







UNIVERSITY OF CALIFORNIA LIBRARY

Los Angeles

This book is DUE on the last date stamped below.

MAY 20 1959

MAY 1 RECD

Biomed. Lib.

MAR 23 1962

MAR 23 RECD

APR 30 1965

MAY 1 RECD

FEB 8 1965

JAN 19 RECD

OCT 5 1967

SEP 26 RECD

NOV 7 1967

NOV 5 RECD

Biomed. Lib.

SEP 29 1970

OCT 13 RECD

BIOMED LIB.
APR 5 1973

MAR 24 1973
BIOMED LIB.

BIOMED SEP 20 '75
SEP 8 RECD

BIOMED OCT 5 '75
OCT 1 RECD

BIOMED LIB.
BIOMED JAN 25 '76
MAR 30 RECD

BIOMED APR 13 1978

BIOMED APR 25 '78
BIOMED LIB.

APR 14 RECD

BIOMED JUN 13 1979
BIOMED LIB.

JUN 1 RECD

BIOMED LIB.
BIOMED SEP 25 '79
SEP 17 RECD

BIOMED OCT 5 '79

BIOMED LIB.

OCT 16 1979

BIOMED APR 19 1981
BIOMED LIB.


APR 5 RECD

BIOMED JAN 13 1983

BIOMED LIB.
JAN 21 RECD

Form L9-42m-8, '49 (B5573) 444

WD
101
D349.5
1904



3 1158 00343 6200

