



Annular Pancreas

KEYWORDS

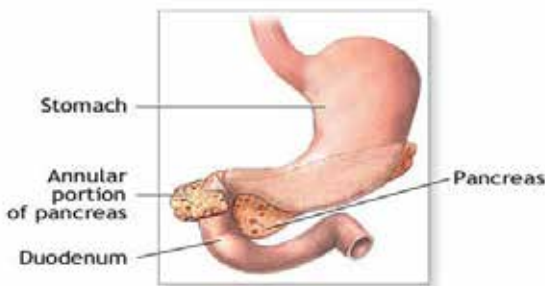
Annular pancreas, MRCP, ERCP, Duodeno-duodenostomy. Gastrojejunostomy.

M.Vijayarathi

Lecturer, Sree Balaji College of Nursing, Bharath University, Tamilnadu, India.

ABSTRACT Annular pancreas is a condition in which the second part of the duodenum is surrounded by a ring of pancreatic tissue continuous with the head of the pancreas and constrict the duodenum and block or impair the flow of food to the rest of the intestines. The incidence is probably 1 in 250 person.

Introduction:



ADAM

Annular pancreas is a rare condition in which the second part of the **duodenum** is surrounded by a ring of **pancreatic** tissue continuous with the **head of the pancreas**. This portion of the pancreas can constrict the duodenum and block or impair the flow of food to the rest of the **intestines**. It is estimated to occur in 1 out of 12,000 to 15,000 newborns. The ambiguity arises from the fact that not all cases are symptomatic. An annular pancreas is a ring of pancreatic tissue that encircles the **duodenum** (the first part of the small intestine). Normally, the pancreas sits next to, but does not surround, the duodenum.

Epidemiology:

The incidence is probably 1 in 250, however accurate incidence is not reported. It is as common in adults as among children. Age of detection however usually corresponds to 3rd - 6th decade of life.

Associations:

- Down syndrome
- Pancreas divisum
- Pancreatitis
- Pancreatic cancer
- Intraductal papillary mucinous tumour (IPMT)

General Considerations:

- Rare, congenital anomaly that may not become apparent until adult life
- Pancreas completely (or sometimes incompletely) encircles 2nd portion of duodenum occasionally obstructing more proximal duodenum
- More commonly affects males
- Pancreas develops from two analogues
- Larger is dorsal bud which forms body and tail of

gland

- Ventral bud is smaller and forms head of gland as well as parts of the hepatic duct and gallbladder
- Annular pancreas is believed to develop as a result of abnormalities in migration of the ventral bud such that the two buds join to encircle the duodenum
- Pancreatic duct from the annular portion may drain into the main pancreatic duct or directly into the duodenum

Causes:

It is typically associated with abnormal embryological development, however adult cases can develop. It can result from growth of a bifid ventral pancreatic bud around the duodenum, where the parts of the bifid ventral bud fuse with the dorsal bud, forming a pancreatic ring. It can also result if the ventral pancreatic bud fails to fully rotate, so it remains on the right or if the dorsal bud rotates in the wrong direction, such that the duodenum is surrounded by pancreatic tissue. Blockage of the duodenum develops if inflammation (pancreatitis) develops in the annular pancreas. Symptoms occur when the ring of pancreas squeezes and narrows the small intestine so that food cannot pass easily or at all.

Newborns may have symptoms of complete blockage of the intestine. However, up to half of people with this condition do not have symptoms until adulthood.

Pathology :

Embryology:

The pancreas develops from a single dorsal and two ventral buds, which appear as outgrowths of primitive foregut at 5 weeks of gestation. Ventral buds fuse rapidly. In 7th week of gestation, duodenum expands, and rotates the ventral bud from right to left, and causes fusion with dorsal bud. The ventral bud forms the inferior part of uncinate process and inferior head of pancreas while the dorsal bud gives rise to tail and body of pancreas. Annular pancreas develops due to failure of ventral bud to rotate with duodenum, causing encasement of duodenum.

Classification:

Annular pancreas can be either 'complete' or 'incomplete'.

Complete annular pancreas is the condition when pancreatic parenchyma or annular duct is seen to completely surround the 2nd part of duodenum.

Incomplete annular pancreas is a condition where the annulus does not surround the duodenum completely, giving a 'crocodile jaw' appearance

Symptoms:

Early signs of abnormality - [Polyhydramnios](#)

Newborn symptoms :

- Feeding intolerance immediately after birth
- They may spit up more than normal
- Not drink enough breast milk or formula
- Continuous cry
- [Low birth weight](#).

Adult symptoms:

- Fullness after eating
- [Nausea or vomiting](#)

Diagnosis:

Tests include:

- [Abdominal ultrasound](#)
- [Abdominal x-ray](#)
- CT scan

[Upper GI and small bowel series](#) Postnatal diagnostic procedures include abdominal x-ray and ultrasound, CT scan, and upper GI and small bowel series.

Clinical Findings

- Frequently asymptomatic
- May present either in infancy or, more commonly, 4th-5th decade of life
- In newborn, duodenal obstruction with bilious vomiting may be present
- May be associated with duodenal stenosis or atresia
- There is a 50% association with other congenital anomalies of involving the heart, trachea and esophagus and malrotation of the intestine
- In adult, there may be,
- Upper abdominal colicky pain
- Postprandial fullness
- Vomiting
- Higher incidence of pancreatitis
- Peptic ulcers may develop

Imaging Findings

In newborn, there may be a double bubble sign from dilatation of the stomach and first portion of the duodenum

In, adult the diagnosis is usually suggested first by CT and can be confirmed with MRCP (magnetic resonance cholangio-pancreaticography) or ERCP (endoscopic retrograde cholangio-pancreaticography)

UGI series

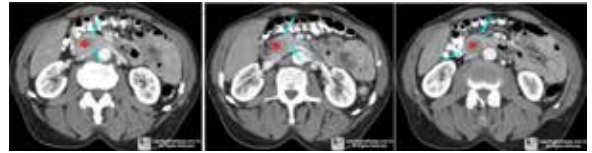- May show extrinsic compression on both lateral and medial walls of the 2nd portion of duodenum
- CT - May be mistaken for thickening of the duodenal wall
- On MRCP or ERCP, the duct of the annular pancreas usually originates anterior to the duodenum sweeps posteriorly and opens into the main pancreatic duct or ampulla.

Differential Diagnosis

- Pancreatic divisum
- Failure of the dorsal and ventral pancreatic ducts to fuse resulting in the majority of secretions exiting via

the accessory pancreatic duct of Santorini

- Pancreatic neoplasms
- Duplication cyst of the duodenum
- [Duodenal atresia](#)

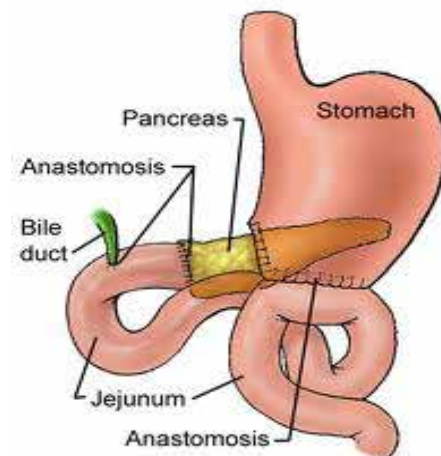
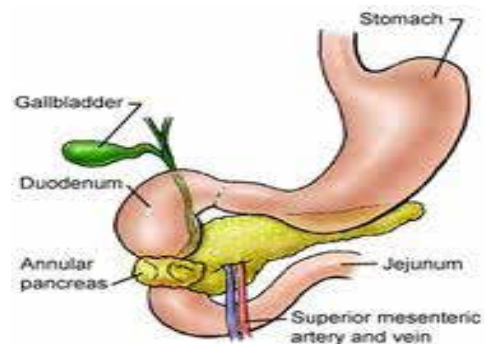


Treatment:

Symptomatic newborns require surgical intervention

Most symptomatic adults will undergo a surgical bypass of the duodenal obstruction

Surgical bypass of the blocked part of the duodenum is the usual treatment for this disorder. Treatment usually is bypassing the obstructed segment of duodenum by [duodeno-duodenostomy](#). Another approach is [laparoscopic gastrojejunostomy](#).



Prognosis:

The outcome is usually good with surgery. Adults with an annular pancreas are at increased risk for pancreatic or biliary tract cancer.

Possible Complications

- Obstructive jaundice
- Pancreatitis
- [Peptic ulcer](#)
- Perforation (hole) in the intestine
- Peritonitis

High risk for developing certain types of cancer, including biliary tract and [pancreatic cancer](#).

Prevention:

It is not possible to prevent annular pancreas. However, there are few steps that can take prevent this.

- Maintain a healthy diet during pregnancy, including fruits, vegetables, and whole grains.
- Regular prenatal check-ups.
- Stop smoking
- Avoiding self medications

Health education:

1. Avoid drugs not prescribed by physician eg. Analgesics.
2. Advised to take rich carbohydrate, low sodium limited protein such as little amount milk, egg, fish.
3. Fluid restriction if required.
4. Signs & symptoms requiring immediate follow up.
5. Continuing prescribed drug therapy.
6. Activity plan that promotes adequate rest.

Conclusion:

Since the condition of annular pancreas is not a preventable disease, but still by following correct life style modification and treatment modality, those who are suffering with can have a normal or near normal life.

Reference:

1. Joycae Black.M (1998), Medical-surgical Nursing, 5th edition, Harcourt Brace & Company Asia PTE LTD.
2. Brunner & Suddharta (1998) Text book of Medical & Surgical Nursing, 8th Edition, Lippincott Company, Philadelphia.
3. Phipps Cassmejer etal (1994) medical surgical nursing, 5th edition.