



EXHIBIT SELECTION

The Management of Extensor Mechanism Complications in Total Knee Arthroplasty

AAOS Exhibit Selection

Denis Nam, MD, Matthew P. Abdel, MD, Michael B. Cross, MD, Lauren E. LaMont, MD, Keith R. Reinhardt, MD, Benjamin A. McArthur, MD, David J. Mayman, MD, Arlen D. Hanssen, MD, and Thomas P. Sculco, MD

Investigation performed at the Hospital for Special Surgery, New York, NY

Abstract: Complications involving the knee extensor mechanism and patellofemoral joint occur in 1% to 12% of patients following total knee arthroplasty and have major negative effects on patient outcomes and satisfaction. The surgeon must be aware of intraoperative, postoperative, and patient-related factors that can increase the rate of these problems. This review focuses on six of the most commonly encountered problems: patellar tendon disruption, quadriceps tendon rupture, patellar crepitus and soft-tissue impingement, periprosthetic patellar fracture, patellofemoral instability, and osteonecrosis of the patella. The goals of this report are to (1) review the relevant anatomy of the knee extensor mechanism, (2) present risk factors that may lead to extensor mechanism complications, (3) provide a diagnostic and treatment algorithm for each of the aforementioned problems, and (4) review the specific surgical techniques of Achilles tendon allograft reconstruction and synthetic mesh augmentation. Extensor mechanism disorders following total knee arthroplasty remain difficult to manage effectively. Although various surgical techniques have been used, the results in patients with a prior total knee arthroplasty are inferior to the results in the young adult without such a prior procedure. Surgical attempts at restoration of the knee extensor mechanism are usually warranted; however, the outcomes of treatment of these complications are often poor, and management of patient expectations is important.

Complications involving the knee extensor mechanism and patellofemoral joint are relatively common following total knee arthroplasty, with a reported prevalence of 1% to 12%.¹ Although the majority of these complications occur postoperatively, the surgeon must be aware of intraoperative, postoperative, and patient-related factors that may increase the risk of an extensor mechanism complication.

This review focuses on six of the most commonly encountered extensor mechanism complications: patellar tendon disruption, quadriceps tendon rupture, patellar crepitus and soft-tissue impingement, periprosthetic patellar fracture, patellofemoral

instability, and osteonecrosis of the patella. A description of the epidemiology, risk factors, clinical presentation, and management options is presented for each of these complications. Although various surgical procedures have been attempted, the results in patients with a prior total knee arthroplasty are inferior to the results in the young adult without such a prior procedure. The goals of this report are to (1) review the relevant anatomy of the knee extensor mechanism and how it is affected by a total knee arthroplasty, (2) present risk factors that may lead to disruption of the extensor mechanism, (3) provide a diagnostic and treatment algorithm for each of the aforementioned

Disclosure: None of the authors received payments or services, either directly or indirectly (i.e., via his or her institution), from a third party in support of any aspect of this work. One or more of the authors, or his or her institution, has had a financial relationship, in the thirty-six months prior to submission of this work, with an entity in the biomedical arena that could be perceived to influence or have the potential to influence what is written in this work. No author has had any other relationships, or has engaged in any other activities, that could be perceived to influence or have the potential to influence what is written in this work. The complete **Disclosures of Potential Conflicts of Interest** submitted by authors are always provided with the online version of the article.

complications, and (4) review the specific surgical techniques of Achilles tendon allograft reconstruction and synthetic mesh augmentation.

Anatomy of the Extensor Mechanism and Risk Factors for Disruption Following Total Knee Arthroplasty

The extensor mechanism of the knee consists of the quadriceps muscle group, quadriceps tendon, patella, patellar retinaculum, patellar tendon, adjacent soft tissues, and tibial tubercle. The primary blood supply to the extensor mechanism is supplied by the descending genicular, superior and inferior medial genicular, and superior and inferior lateral genicular arteries and the recurrent branch of the anterior tibial artery. Depending on the surgical approach and soft-tissue dissection, all aspects of the blood supply to the extensor mechanism may potentially be compromised during total knee arthroplasty^{1,2}.

A medial parapatellar arthrotomy is the most common surgical approach used in total knee arthroplasty and can potentially disrupt all of the medial vessels supplying the extensor mechanism (descending genicular and superior and inferior medial genicular arteries). In addition, excision of the lateral meniscus and infrapatellar fat pad can disrupt the inferior lateral genicular artery and the recurrent branch of the anterior tibial artery, whereas a concomitant lateral parapatellar release can compromise the superior lateral genicular artery (Fig. 1). Pawar et al. performed preoperative and postoperative technetium-99m

methylene diphosphate scans of seventy-two patients treated with total knee arthroplasty. Thirty-six of the patients required a lateral release intraoperatively, and the prevalence of transient patellar hypovascularity was 3.95 times higher in these patients². Disruption of the extensor mechanism vascularity also limits healing capacity after a surgical repair or reconstruction.

Additional surgical factors that may increase the risk of extensor mechanism complications following total knee arthroplasty include poor patellar alignment^{3,4} and over-resection of the patella during patellar resurfacing; the latter increases the risk of iatrogenic damage to the quadriceps and patellar tendons, and it increases the risk of fracture if the anteroposterior dimension of the remaining bone is <12 mm⁵. Furthermore, prior surgical procedures such as a high tibial osteotomy or tibial tubercle osteotomy and the presence of patella baja due to infrapatellar scar tissue may increase the difficulty of exposure and the risk of iatrogenic damage to the extensor mechanism (Fig. 2). Lastly, the presence of systemic disorders, including obesity, inflammatory arthritis, diabetes mellitus, and hyperthyroidism, as well as a history of chronic corticosteroid use or multiple corticosteroid injections, may increase the risk of quadriceps and patellar tendon rupture⁶.

Patellar Tendon Rupture

Prevalence

Patellar tendon rupture is a relatively rare occurrence following total knee arthroplasty, affecting <1% of patients^{1,7}.

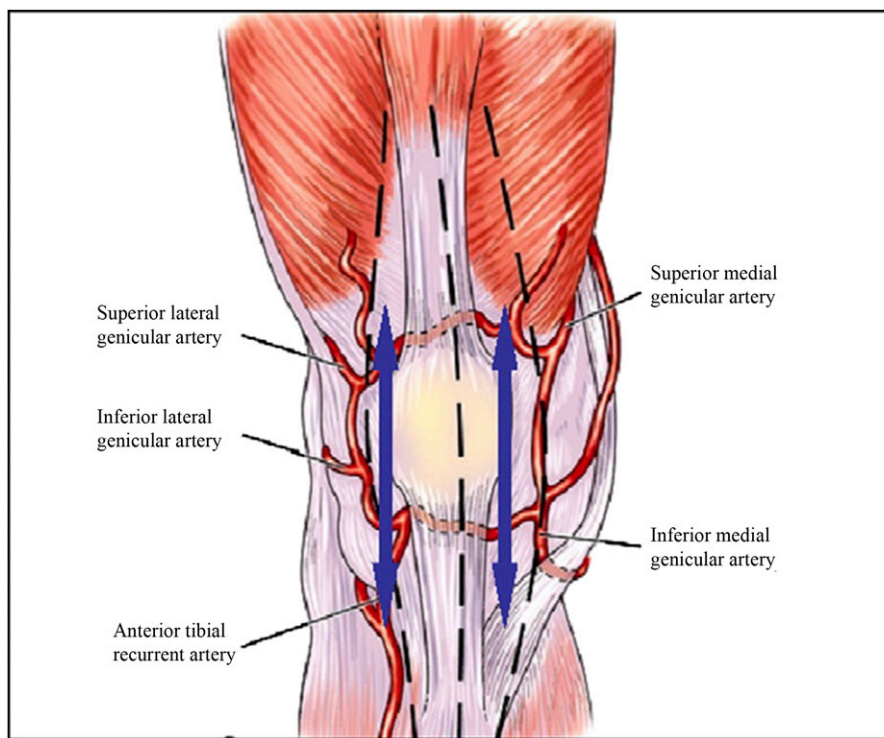


Fig. 1
Diagram of the blood supply to the extensor mechanism disrupted when performing a medial parapatellar arthrotomy and a concomitant lateral parapatellar release. (Reproduced from *J. Arthroplasty*, Vol. 24, Pawar U, Rao KN, Sundaram PS, Thilak J, Varghese J. Scintigraphic assessment of patellar viability in total knee arthroplasty after lateral release, pp 636-40. Copyright 2009, with permission from Elsevier.)

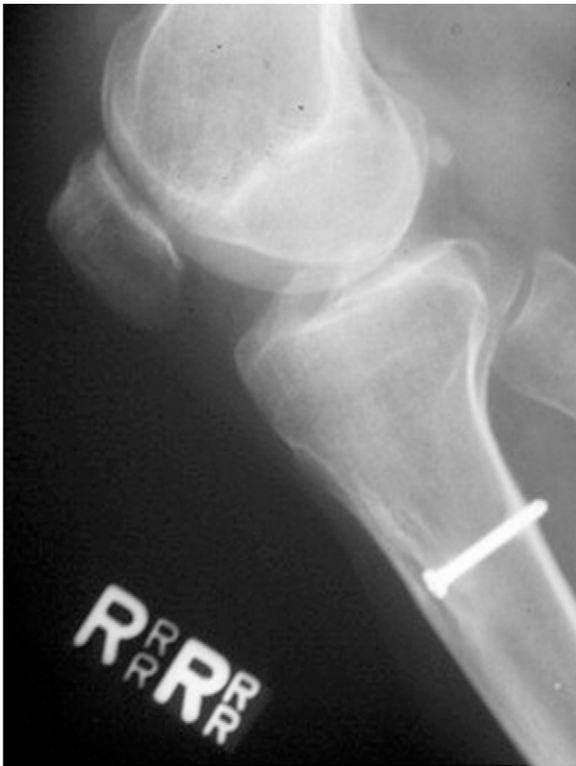

Fig. 2
Lateral knee radiograph demonstrating the presence of patella baja resulting from a prior tibial tubercle osteotomy.

The majority of ruptures occur at the tibial tubercle insertion; intrasubstance or infrapatellar avulsions are less common. Patients with major scarring and stiffness following a primary total knee arthroplasty and patients with multiple prior surgical procedures are at increased risk for this complication.

Clinical Presentation and Diagnosis

An intraoperative patellar tendon rupture typically occurs secondary to a difficult exposure in a stiff knee, often in a patient with patella baja. The most common mechanism of postoperative patellar tendon injury is a fall on a hyperflexed knee, although atraumatic rupture may occur secondary to repetitive contact or impingement of the patellar tendon on the polyethylene tibial insert¹.

Patients with a patellar tendon rupture often present with pain, swelling, an extensor lag, inability to perform a straight leg raise, and a palpable infrapatellar soft-tissue defect. Diagnostic imaging includes standard anteroposterior and lateral knee radiographs, which often demonstrate patella alta (Fig. 3)⁸. An ultrasonographic or magnetic resonance imaging (MRI) study may aid in the initial diagnosis and also guide treatment options by indicating the quality of the remaining tissue.

Management and Surgical Techniques

Treatment options depend on the acuity and location of the injury, the quality of the remaining tissue, and the physiologic

age and activity demands of the patient. Bracing may be used in patients with low functional demands, those with a partial tendon tear, and those who are poor surgical candidates, whereas arthrodesis may be considered if infection is present.

If a patellar tendon rupture occurs intraoperatively or in the immediate postoperative period, attempts at a direct repair using drill holes, staples, or suture anchors remain reasonable options^{1,9,10}. However, in the presence of poor tissue quality, augmentation techniques should be used^{10,11}. It has been demonstrated that primary repair without augmentation resulted in high rates of deep infection, tendon rerupture, and extensor lag⁹⁻¹¹. In the late postoperative or chronic setting, augmentation should always be used to supplement a repair.

Numerous augmentation options are available, including hamstring autograft, fresh-frozen or freeze-dried Achilles tendon-bone block, extensor mechanism allograft (Fig. 4), and a synthetic graft such as Marlex mesh (C.R. Bard, Murray Hill, New Jersey)¹¹⁻¹³. Browne and Hanssen described a surgical technique using a knitted, monofilament polypropylene graft to reconstruct the patellar tendon and facilitate fixation of adjacent host tissue to the graft. Nine of thirteen patients possessed an extensor lag of $<10^\circ$ with preserved knee flexion, and improvements in the mean Knee Society scores for pain and function were significant ($p < 0.01$)¹¹. Therefore, augmentation of a patellar tendon repair can improve clinical outcomes, especially in the setting of poor tissue quality or a chronic rupture.

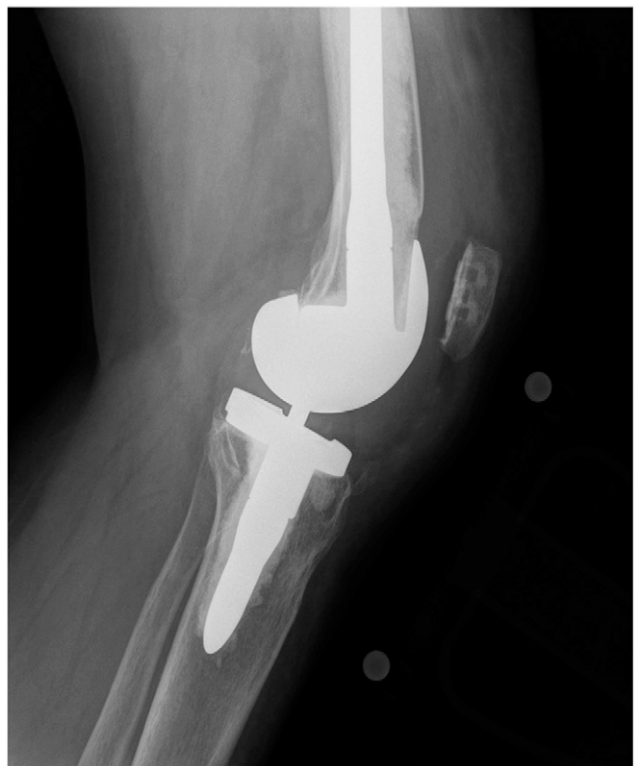

Fig. 3
Lateral knee radiograph of a patient who sustained a patellar tendon rupture with subsequent patella alta following a total knee arthroplasty.

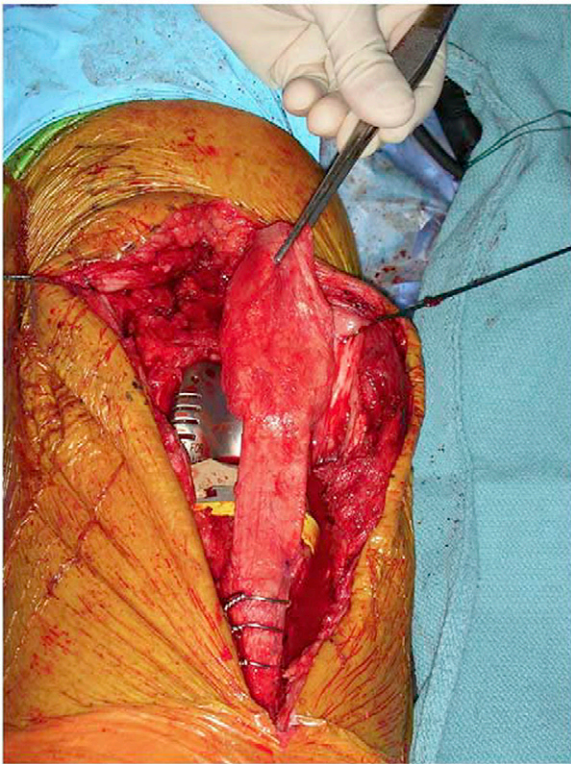


Fig. 4
Intraoperative photograph of an extensor mechanism allograft reconstruction. (Reproduced from *J. Arthroplasty*, Vol. 23, Springer BD, Della Valle CJ. Extensor mechanism allograft reconstruction after total knee arthroplasty, pp 35-8. Copyright 2008, with permission from Elsevier.)

Quadriceps Tendon Rupture

Prevalence

Dobbs et al. performed a review of 23,800 total knee arthroplasties recorded in the Mayo Clinic Joint Registry and noted only a 0.1% prevalence of quadriceps tendon rupture¹⁴. Specific risk factors for this complication include systemic disorders, excessive resection of the patella, and a prior quadriceps snip or V-Y turndown¹⁶.

Clinical Presentation and Diagnosis

Dobbs et al. reported that only nine patients sustained a quadriceps tendon rupture as a result of what would be considered a substantial traumatic mechanism, thus indicating the importance of a patient's predisposing risk factors¹⁴. As with a patellar tendon rupture, patients may present with an extensor lag or inability to perform a straight leg raise as well as a palpable defect. Standard imaging studies include anteroposterior and lateral radiographs, whereas advanced imaging such as ultrasonography or MRI can help to confirm the diagnosis.

Management and Surgical Techniques

Patients with a partial rupture of the quadriceps tendon can be successfully managed nonoperatively with immobilization of the knee in extension¹⁴. Unfortunately, surgical repair of a complete rupture of the quadriceps tendon has had limited success,

with reported rerupture rates of 33% to 36% and overall rates of complications (including infection) of 33% to 100%^{6,14,15}. As with a patellar tendon rupture, surgeons should strongly consider using augmentation techniques. Described augmentation options include the use of semitendinosus or gracilis autografts, synthetic grafts, and Achilles tendon or complete extensor mechanism allografts. On the basis of the poor results in their initial series of direct surgical repairs, Dobbs et al. currently recommend the use of augmentation in all cases of complete quadriceps tendon rupture¹⁴. A treatment algorithm for the management of quadriceps tendon rupture following total knee arthroplasty is presented in Figure 5.

Patellar Crepitus and Soft-Tissue Impingement

Prevalence

Patellofemoral crepitus, or soft-tissue impingement, occurs following 0% to 25% of total knee arthroplasties and is highly dependent on the prosthesis design¹⁶⁻¹⁸. Risk factors include a posterior-stabilized total knee arthroplasty design, a femoral component with a shallow trochlear groove or with a sharp transition to the intercondylar region of the implant, and poor patellofemoral tracking¹⁹.

Pathophysiology

Patellofemoral crepitus is often caused by the development of synovial hyperplasia (a soft-tissue nodule) at the junction of the superior pole of the patella and the quadriceps tendon. This

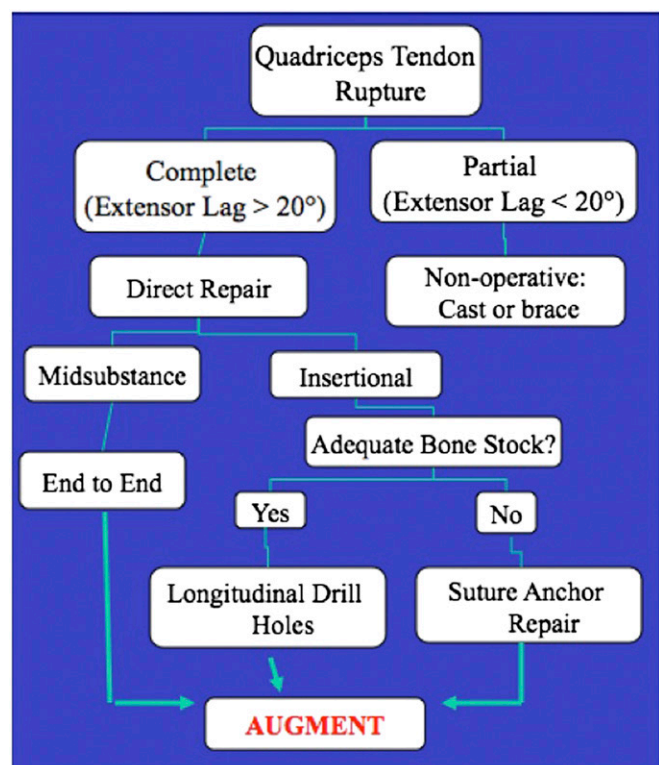


Fig. 5
Proposed treatment algorithm for the management of quadriceps tendon rupture following total knee arthroplasty.

nodule engages the box of the posterior-stabilized femoral component with the knee in flexion, then causes a painful “clunk” when the knee is actively extended¹⁹.

Clinical Presentation and Diagnosis

Typically, patients present with symptoms within twelve months of the index procedure. They note a palpable patellofemoral clunk with active extension, typically at 30° of knee flexion¹. This phenomenon is typically not observed in a stiff knee with limited flexion (as sufficient knee flexion is required for the soft-tissue nodule to engage the box of the femur) or during passive knee extension (as the clunk only occurs with active contraction of the quadriceps mechanism). Ultrasonography or MRI can demonstrate a suprapatellar soft-tissue nodule, but the diagnosis can often be made solely on the basis of the clinical examination.

Management and Surgical Techniques

Nonoperative management, including quadriceps strengthening and intra-articular corticosteroid injections, may be successful in up to 20% of patients, although most patients with an established patellofemoral clunk will require surgical treatment¹. Excellent results have been reported following arthroscopic resection of the fibrous nodule, with 74% to 100% of patients demonstrating resolution of their symptoms (Fig. 6)²⁰⁻²². In refractory cases or in the presence of substantial adhesions obscuring arthroscopic visualization, an open peripatellar synovectomy can be performed and has a high rate of success¹.

Periprosthetic Patellar Fracture

Prevalence

The reported prevalence of periprosthetic patellar fracture following total knee arthroplasty ranges from 0.68% to 5.2%²³⁻²⁶. Risk factors include resurfacing of the patella, especially with excessive resection; use of a patellar implant with a large central plug; and use of a metal-backed cementless patellar component^{5,27-29}. Combined femoral and tibial malrotation and overall mechanical malalignment in the coronal plane may increase the stress placed on the patella^{3,4}. Patient-related risk factors include a body mass index of >30 kg/m² and osteoporosis^{26,28,30}.

Clinical Presentation and Diagnosis

Periprosthetic patellar fracture can occur secondary to direct trauma to the anterior aspect of the knee or because of eccentric contraction of the quadriceps mechanism, which typically causes an avulsion fracture. Patients will present with anterior knee pain, an effusion, difficulty walking on stairs, an extensor lag, and/or inability to perform a straight leg raise, depending on the integrity of the peripatellar retinaculum. The fracture can typically be seen on conventional anteroposterior, lateral, and skyline radiographs of the knee, although a technetium-99m bone scan may be useful to diagnose an occult fracture³¹.

Classification Systems

Several classification systems of periprosthetic patellar fractures have been reported^{124,32,33}. Ortiguera and Berry proposed a system in

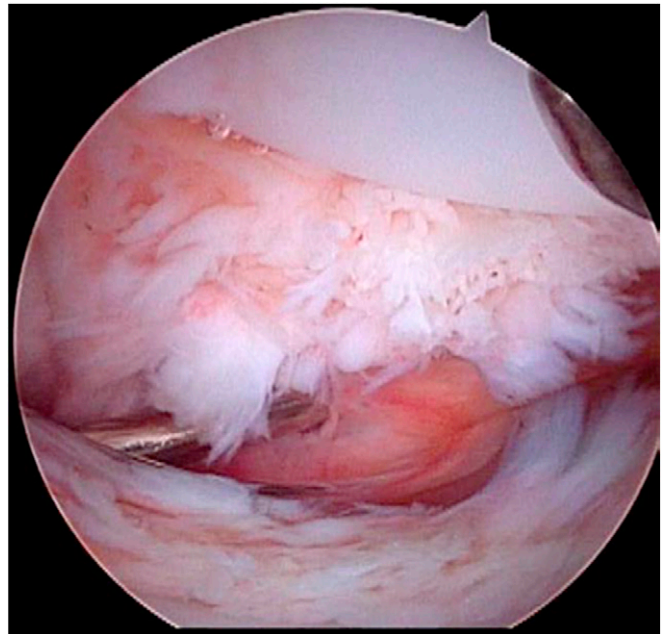


Fig. 6

Arthroscopic view of the patellofemoral articulation via an inferolateral portal, demonstrating the presence of hypertrophic synovium on the undersurface of the rectus femoris tendon. (Reproduced from J. Arthroplasty, Vol. 25, Dajani KA, Stuart MJ, Dahm DL, Levy BA. Arthroscopic treatment of patellar clunk and synovial hyperplasia after total knee arthroplasty, pp 97-103. Copyright 2010, with permission from Elsevier.)

which type I involves a stable implant and intact extensor mechanism, type II involves an intact implant but extensor mechanism disruption, and type III involves a loose implant, with patellar bone being good in subtype IIIa and poor in subtype IIIb²⁴.

Management and Surgical Techniques

Key treatment considerations include the location and pattern of the fracture, the integrity of the extensor mechanism, implant stability, and the quality of the remaining bone stock. Ortiguera and Berry demonstrated excellent results with nonoperative management in thirty-seven patients with a well-fixed implant and an intact extensor mechanism following a periprosthetic patellar fracture, with only one late failure of nonoperative management. In twelve patients with extensor mechanism disruption, surgical repair of either the extensor mechanism or the fracture resulted in a 42% reoperation rate, 50% complication rate, and 58% prevalence of extensor lag postoperatively. Similarly, surgical management of patients with a loose patellar component resulted in a reoperation rate of 20% and an overall complication rate of 45%²⁴. Several other series of periprosthetic patellar fractures have demonstrated similarly guarded results^{5,32}. Even with anatomic fracture reduction and reconstitution of the extensor mechanism, the rate of complications including nonunion, ipsilateral tendon rupture, secondary fatigue fracture, and infection remains high^{1,5,24,26,30-32,34}. A proposed treatment algorithm for the management of periprosthetic patellar fracture is presented in Figure 7.

TABLE 1 Potential Etiologies and Management Options for Patellofemoral Instability Following Total Knee Arthroplasty

Etiology	Problem	Management
Patellar component	Inadequate resection	Revise patellar cut
	Lateralization	Revise position
	Oversized	Downsize
Femoral component	Internal rotation, medialization, or oversized	Revise component to appropriate position or size
Tibial component	Internal rotation or medialization	Revise component to appropriate position
Soft tissue	Tight lateral retinaculum	Lateral release

Patellofemoral Instability

Prevalence

The prevalence of patellofemoral subluxation or dislocation was as high as 27% in earlier series^{1,35}. However, with advances in surgical techniques and implant design, recent studies have indicated the prevalence to be <1% to 12%^{7,36}. Patient-related risk factors for patellofemoral instability include poor preoperative patellar tracking and a dysplastic trochlea. Femoral components with a shallow trochlear groove and without a lateral flange may also increase the likelihood of patellofemoral instability, as may component malpositioning. Lateralization of the patellar implant, “overstuffing” of the patellofemoral joint, internal rotation of the femoral or tibial component, and medialization of the femoral component can all increase the prevalence of lateral subluxation of the patella. It is essential that the surgeon intraoperatively assess patellofemoral tracking following component placement (with the tourniquet deflated) to assess the necessity of further soft-tissue balancing.

Clinical Presentation and Diagnosis

Patients often present with anterior knee pain, patellar malpositioning during knee motion, and, in some instances, an acute subluxation or dislocation event. Diagnostic imaging studies include standard anteroposterior, lateral, and Merchant view radiographs. A computed tomography (CT) scan may be useful to evaluate possible femoral or tibial component malrotation.

Management and Surgical Techniques

Poor outcomes are associated with nonoperative management of patellofemoral instability, including management by bracing and physical therapy. The most important aspect in the management of these patients is identifying the etiology, whether it is component malpositioning, overstuffing of the patellofemoral joint, soft-tissue imbalance, or a combination of factors. Surgical interventions aimed at treating the specific etiology are associated with the best outcomes^{1,6,18,37}. A summary of the possible causes of

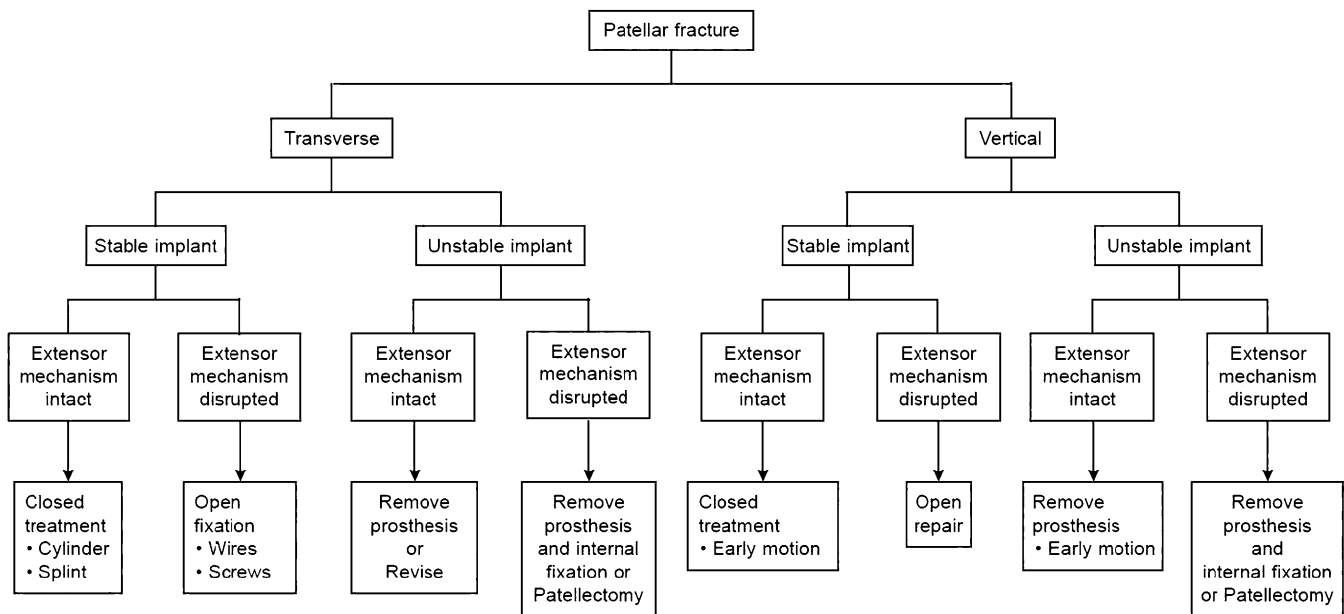


Fig. 7

Treatment algorithm outlining the management of periprosthetic patellar fracture following total knee arthroplasty. (Reproduced from: Parker DA, Dunbar MJ, Rorabeck CH. Extensor mechanism failure associated with total knee arthroplasty: prevention and management. *J Am Acad Orthop Surg*. 2003 Jul-Aug;11[4]:238-47.)



Fig. 8
Intraoperative photograph showing the placement of three 16-gauge wires prior to fixation of the allograft to the host tibial bone. (Reproduced, with permission, from: Burnett RS, Butler RA, Barrack RL. Extensor mechanism allograft reconstruction in TKA at a mean of 56 months. *Clin Orthop Relat Res.* 2006 Nov;452:159-65.)

patellofemoral instability along with corresponding management options are presented in Table I.

Patellar Osteonecrosis

Prevalence

The reported prevalence of patellar osteonecrosis following total knee arthroplasty is approximately 1.4%¹⁹. As noted earlier, disruption of the extraosseous, anastomotic vascular ring surrounding the patella can occur during a standard medial parapatellar arthrotomy with a concomitant lateral parapatellar release. However, disruption of the blood supply is difficult to associate directly with the clinical occurrence of patellar osteonecrosis. Ritter and Campbell compared eighty-four total knee arthroplasties incorporating a lateral release with 471 procedures that did not require a lateral release and noted no increase in patellar osteonecrosis in patients who underwent a lateral release³⁸.

Clinical Presentation and Diagnosis

Patients with patellar osteonecrosis may be asymptomatic, thus possibly contributing to underreporting of its true prevalence. However, patients with symptoms often present with anterior knee pain and they may have patellofemoral instability, depending on the degree of bone resorption or patellar component loosening. Patients can also present with a periprosthetic fracture secondary to osteonecrosis. The most useful diagnostic images are typically lateral and Merchant view radiographs, which demonstrate sclerosis, flattening, and fragmentation of the remaining patellar bone. An MRI or bone scan may assist in obtaining an earlier diagnosis.

Management and Surgical Techniques

The management of patellar osteonecrosis is based on the presence of symptoms and on patellar component stability. In asymptom-

atic patients, no intervention is required. However, with patellar fragmentation and component loosening, the decision regarding whether to revise the patellar component or simply remove the component along with loose osseous fragments depends on the remaining bone stock. It is important to preserve as much of the remaining bone stock as possible to improve the competency of the extensor mechanism, although the clinical outcomes of surgery are guarded, as with all of the aforementioned complications.

Achilles Tendon Allograft Reconstruction and Synthetic Mesh Augmentation

Barrack et al., Burnett et al., and Springer and Della Valle have all reported on the use and outcomes of complete extensor mechanism allografts in total knee arthroplasty^{12,39-41}. Burnett et al. emphasized the importance of tensioning the graft in full extension and of not testing the repair after tensioning³⁹. This section will briefly review the steps in use of an Achilles tendon-bone block allograft and augmentation with a synthetic mesh for a patellar tendon disruption following total knee arthroplasty.

Use of an Achilles tendon-bone block allograft may be considered in patients in whom the patella is intact and its inferior pole can be brought down to within 2 to 3 cm of the joint line¹². A small burr can be used to make a 2.5-cm long, 1.5-cm wide, and 1.0-cm deep tibial trough that is slightly distal and medial to the tibial tubercle. The allograft-calcaneal bone block is trimmed and dovetailed to help prevent proximal migration, and three 16-gauge wires are placed through drill holes in the tibia to fix the allograft to the host tibia (Fig. 8). The proximal portion of the allograft is secured on both sides with heavy, nonabsorbable sutures in a Krackow fashion, resulting in four proximal strands of suture⁴². The Achilles tendon itself can then be divided and passed through the extensor mechanism in a figure-of-eight fashion, sutured back on itself, and tensioned in full extension.



Fig. 9
Intraoperative photograph showing the Achilles tendon allograft being placed lateral to the remaining native extensor mechanism. (Reproduced, with permission, from: Burnett RS, Butler RA, Barrack RL. Extensor mechanism allograft reconstruction in TKA at a mean of 56 months. *Clin Orthop Relat Res.* 2006 Nov;452:159-65.)

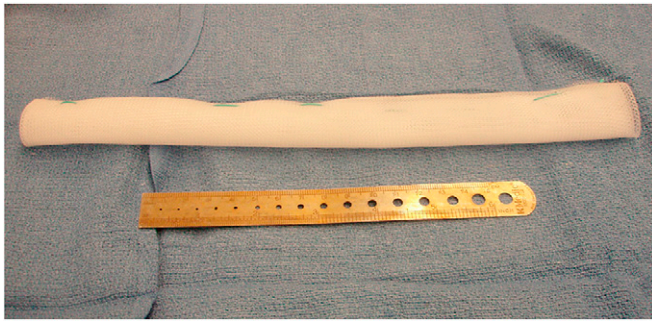


Fig. 10
Photograph showing the synthetic mesh (knitted monofilament polypropylene) used in the surgical technique described by Browne and Hanssen¹¹. (Reproduced from: Browne JA, Hanssen AD. Reconstruction of patellar tendon disruption after total knee arthroplasty: results of a new technique utilizing synthetic mesh. *J Bone Joint Surg Am.* 2011 Jun 15;93[12]:1137-43.)

Alternatively, the allograft can be passed through a slit in the posterior retinaculum (posterior and lateral to the host patellar tendon remnant), then pulled proximally anterior to the host patella (Fig. 9) and tensioned proximally in full extension⁴¹. Finally, the host quadriceps is sewn over the allograft.

Browne and Hanssen initially described the use of a synthetic mesh (knitted monofilament polypropylene, Fig. 10) for reconstruction of a patellar tendon disruption following total knee arthroplasty¹¹. In this technique, a synthetic graft is fashioned by folding a 10 × 14-in (25.4 × 35.6-cm) sheet of mesh and securing it with heavy, nonabsorbable sutures. A burr is used to make a trough in the anteromedial aspect of the host tibia to accept the mesh graft. The graft is inserted into the tibial trough and secured with polymethylmethacrylate cement and a transfixion screw with a washer. A portal is made in the lateral soft tissues to allow delivery of the graft from deep to superficial. The patella and quadriceps tendon are mobilized and advanced to restore the appropriate patellar height, and suture is used to secure the graft to the lateral retinaculum, vastus lateralis muscle, and quadriceps tendon. The vastus medialis muscle is mobilized to advance in a pants-over-vest manner over the mesh graft and is secured with suture. The distal arthrotomy is closed tightly to completely cover the mesh graft with host soft tissue. A video of this procedure is

available with the online version of the original article by Browne and Hanssen at <http://dx.doi.org/10.2106/JBJS.J.01036>¹¹.

Conclusions

Complications involving the knee extensor mechanism following total knee arthroplasty can be difficult to manage. Nonoperative management may be an option for patients with asymptomatic osteonecrosis of the patella, a stable patellar fracture, or a partial quadriceps or patellar tendon tear. A notable number of patients with complete disruption of the extensor mechanism will require surgical interventions, which have had mixed results. Complications following reconstruction of the extensor mechanism include rerupture, postoperative infection, and persistent extensor lag. Patients should be counseled regarding the severity of their problem, and their expectations should be managed appropriately. ■

Denis Nam, MD
Department of Orthopaedic Surgery,
Washington University School of Medicine,
Barnes Jewish Hospital,
660 South Euclid Avenue,
Campus Box 8233, St. Louis, MO 63110.
E-mail address: namd@wudosis.wustl.edu

Matthew P. Abdel, MD
Arlen D. Hanssen, MD
Division of Adult Reconstruction,
Department of Orthopedic Surgery,
Mayo Clinic, 200 First Street S.W.,
Rochester, MN 55905

Michael B. Cross, MD
Lauren E. LaMont, MD
Keith R. Reinhardt, MD
Benjamin A. McArthur, MD
David J. Mayman, MD
Thomas P. Sculco, MD
Adult Reconstruction and
Joint Replacement Division,
Department of Orthopaedic Surgery,
Hospital for Special Surgery,
535 East 70th Street, New York, NY 10021

References

- Parker DA, Dunbar MJ, Rorabeck CH. Extensor mechanism failure associated with total knee arthroplasty: prevention and management. *J Am Acad Orthop Surg.* 2003 Jul-Aug;11(4):238-47.
- Pawar U, Rao KN, Sundaram PS, Thilak J, Varghese J. Scintigraphic assessment of patellar viability in total knee arthroplasty after lateral release. *J Arthroplasty.* 2009 Jun;24(4):636-40. Epub 2008 May 19.
- Figgie HE 3rd, Goldberg VM, Figgie MP, Inglis AE, Kelly M, Sobel M. The effect of alignment of the implant on fractures of the patella after condylar total knee arthroplasty. *J Bone Joint Surg Am.* 1989 Aug;71(7):1031-9.
- Berger RA, Crossett LS, Jacobs JJ, Rubash HE. Malrotation causing patellofemoral complications after total knee arthroplasty. *Clin Orthop Relat Res.* 1998 Nov;356:144-53.
- Bourne RB. Fractures of the patella after total knee replacement. *Orthop Clin North Am.* 1999 Apr;30(2):287-91.
- Lynch AF, Rorabeck CH, Bourne RB. Extensor mechanism complications following total knee arthroplasty. *J Arthroplasty.* 1987;2(2):135-40.
- Mont MA, Yoon TR, Krackow KA, Hungerford DS. Eliminating patellofemoral complications in total knee arthroplasty: clinical and radiographic results of 121 consecutive cases using the Duracon system. *J Arthroplasty.* 1999 Jun;14(4):446-55.
- Järvelä T, Halonen P, Järvelä K, Moilanen T. Reconstruction of ruptured patellar tendon after total knee arthroplasty: a case report and a description of an alternative fixation method. *Knee.* 2005 Apr;12(2):139-43.
- Rand JA, Morrey BF, Bryan RS. Patellar tendon rupture after total knee arthroplasty. *Clin Orthop Relat Res.* 1989 Jul;244:233-8.
- Schoderbek RJ Jr, Brown TE, Mulhall KJ, Mounasamy V, Iorio R, Krackow KA, Macaulay W, Saleh KJ. Extensor mechanism disruption after total knee arthroplasty. *Clin Orthop Relat Res.* 2006 May;446:176-85.

11. Browne JA, Hanssen AD. Reconstruction of patellar tendon disruption after total knee arthroplasty: results of a new technique utilizing synthetic mesh. *J Bone Joint Surg Am.* 2011 Jun 15;93(12):1137-43.
12. Springer BD, Della Valle CJ. Extensor mechanism allograft reconstruction after total knee arthroplasty. *J Arthroplasty.* 2008 Oct;23(7)(Suppl):35-8.
13. Cadambi A, Engh GA. Use of a semitendinosus tendon autogenous graft for rupture of the patellar ligament after total knee arthroplasty. A report of seven cases. *J Bone Joint Surg Am.* 1992 Aug;74(7):974-9.
14. Dobbs RE, Hanssen AD, Lewallen DG, Pagnano MW. Quadriceps tendon rupture after total knee arthroplasty. Prevalence, complications, and outcomes. *J Bone Joint Surg Am.* 2005 Jan;87(1):37-45.
15. Yun AG, Rubash HE, Scott RD, Laskin RS. Quadriceps rupture associated with a proximal quadriceps release in total knee arthroplasty. A report of three cases. *J Bone Joint Surg Am.* 2003 Sep;85(9):1809-11.
16. Fyfe BM, Floyd MW, Pham DC, Feldman JJ, Hamlin BR. Effect of femoral component design on patellofemoral crepitance and patella clunk syndrome after posterior-stabilized total knee arthroplasty. *J Arthroplasty.* 2012 Jun;27(6):1166-70. Epub 2012 Jan 27.
17. Aglietti P, Buzzi R, Gaudenzi A. Patellofemoral functional results and complications with the posterior stabilized total condylar knee prosthesis. *J Arthroplasty.* 1988;3(1):17-25.
18. Anderson JA, Baldini A, Sculco TP. Patellofemoral function after total knee arthroplasty: a comparison of 2 posterior-stabilized designs. *J Knee Surg.* 2008 Apr;21(2):91-6.
19. Healy WL, Wasilewski SA, Takei R, Oberlander M. Patellofemoral complications following total knee arthroplasty. Correlation with implant design and patient risk factors. *J Arthroplasty.* 1995 Apr;10(2):197-201.
20. Lucas TS, DeLuca PF, Nazarian DG, Bartolozzi AR, Booth RE Jr. Arthroscopic treatment of patellar clunk. *Clin Orthop Relat Res.* 1999 Oct;367:226-9.
21. Vernace JV, Rothman RH, Booth RE Jr, Balderston RA. Arthroscopic management of the patellar clunk syndrome following posterior stabilized total knee arthroplasty. *J Arthroplasty.* 1989;4(2):179-82.
22. Dajani KA, Stuart MJ, Dahm DL, Levy BA. Arthroscopic treatment of patellar clunk and synovial hyperplasia after total knee arthroplasty. *J Arthroplasty.* 2010 Jan;25(1):97-103. Epub 2008 Dec 23.
23. Hozack WJ, Goll SR, Lotke PA, Rothman RH, Booth RE Jr. The treatment of patellar fractures after total knee arthroplasty. *Clin Orthop Relat Res.* 1988 Nov;236:123-7.
24. Ortiguera CJ, Berry DJ. Patellar fracture after total knee arthroplasty. *J Bone Joint Surg Am.* 2002 Apr;84(4):532-40.
25. Chalidis BE, Tsiroidis E, Tragas AA, Stavrou Z, Giannoudis PV. Management of periprosthetic patellar fractures. A systematic review of literature. *Injury.* 2007 Jun;38(6):714-24. Epub 2007 May 02.
26. Meding JB, Fish MD, Berend ME, Ritter MA, Keating EM. Predicting patellar failure after total knee arthroplasty. *Clin Orthop Relat Res.* 2008 Nov;466(11):2769-74. Epub 2008 Aug 19.
27. Rorabeck CH, Angliss RD, Lewis PL. Fractures of the femur, tibia, and patella after total knee arthroplasty: decision making and principles of management. *Instr Course Lect.* 1998;47:449-58.
28. Brick GW, Scott RD. The patellofemoral component of total knee arthroplasty. *Clin Orthop Relat Res.* 1988 Jun;231:163-78.
29. Grace JN, Sim FH. Fracture of the patella after total knee arthroplasty. *Clin Orthop Relat Res.* 1988 May;230:168-75.
30. Sheth NP, Pedowitz DI, Lonner JH. Periprosthetic patellar fractures. *J Bone Joint Surg Am.* 2007 Oct;89(10):2285-96.
31. Engh GA, Ammeen DJ. Periprosthetic fractures adjacent to total knee implants: treatment and clinical results. *Instr Course Lect.* 1998;47:437-48.
32. Goldberg VM, Figgie HE 3rd, Inglis AE, Figgie MP, Sobel M, Kelly M, Kraay M. Patellar fracture type and prognosis in condylar total knee arthroplasty. *Clin Orthop Relat Res.* 1988 Nov;236:115-22.
33. Windsor RE, Scuderi GR, Insall JN. Patellar fractures in total knee arthroplasty. *J Arthroplasty.* 1989;4(Suppl):S63-7.
34. Parvizi J, Kim KI, Oliashirazi A, Ong A, Sharkey PF. Periprosthetic patellar fractures. *Clin Orthop Relat Res.* 2006 May;446:161-6.
35. Cameron HU, Fedorkow DM. The patella in total knee arthroplasty. *Clin Orthop Relat Res.* 1982 May;165:197-9.
36. Eisenhuth SA, Saleh KJ, Cui Q, Clark CR, Brown TE. Patellofemoral instability after total knee arthroplasty. *Clin Orthop Relat Res.* 2006 May;446:149-60.
37. Akagi M, Matsusue Y, Mata T, Asada Y, Horiguchi M, Iida H, Nakamura T. Effect of rotational alignment on patellar tracking in total knee arthroplasty. *Clin Orthop Relat Res.* 1999 Sep;366:155-63.
38. Ritter MA, Campbell ED. Postoperative patellar complications with or without lateral release during total knee arthroplasty. *Clin Orthop Relat Res.* 1987 Jun;219:163-8.
39. Burnett RS, Berger RA, Pappas WG, Della Valle CJ, Jacobs JJ, Rosenberg AG. Extensor mechanism allograft reconstruction after total knee arthroplasty. A comparison of two techniques. *J Bone Joint Surg Am.* 2004 Dec;86(12):2694-9.
40. Barrack RL, Stanley T, Allen Butler R. Treating extensor mechanism disruption after total knee arthroplasty. *Clin Orthop Relat Res.* 2003 Nov;416:98-104.
41. Burnett RS, Butler RA, Barrack RL. Extensor mechanism allograft reconstruction in TKA at a mean of 56 months. *Clin Orthop Relat Res.* 2006 Nov;452:159-65.
42. Krackow KA, Thomas SC, Jones LC. A new stitch for ligament-tendon fixation. Brief note. *J Bone Joint Surg Am.* 1986 Jun;68(5):764-6.