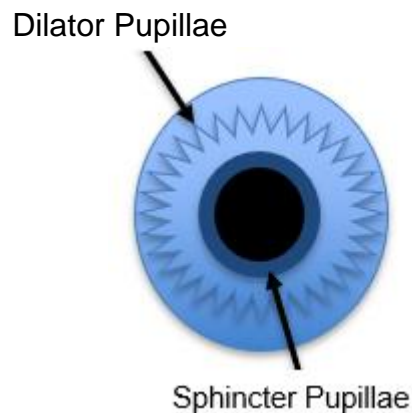


Pupil Testing in the Optometric Practice

Tamara Petrosyan O.D.

Pupillary evaluations are one of the few objective reflexes that detect and quantify abnormalities of the retina, optic nerve, optic chiasm, optic tract, midbrain, and peripheral nerves. Pupil abnormalities can reveal serious neuro-ophthalmic disease and help aid in the diagnosis and management of many ophthalmic conditions. Pupil testing should be incorporated into every comprehensive eye examination and thus it is important for paraoptometrics to understand the neuroanatomy, normal pupillary function, how to identify pupillary dysfunction and what it might mean.



The pupil is a hole in the center of the iris (colored part of the eye) and has several functions. The pupil unconsciously and involuntarily controls how much light enters the eye, improves vision by preventing irregular refraction from the peripheral cornea, and allows passage of aqueous humor from the posterior to anterior chamber. The iris contains two groups of smooth muscle. The sphincter pupillae is a circularly oriented muscle at the pupillary margin which constricts the pupil and the dilator pupillae is a radially oriented muscle which causes dilation of the pupil when the muscle is constricted. When illumination is dim, the radial dilator pupillae muscle constricts and pulls the pupil open (mydriasis) while the sphincter pupillae relaxes. When illumination is bright, the

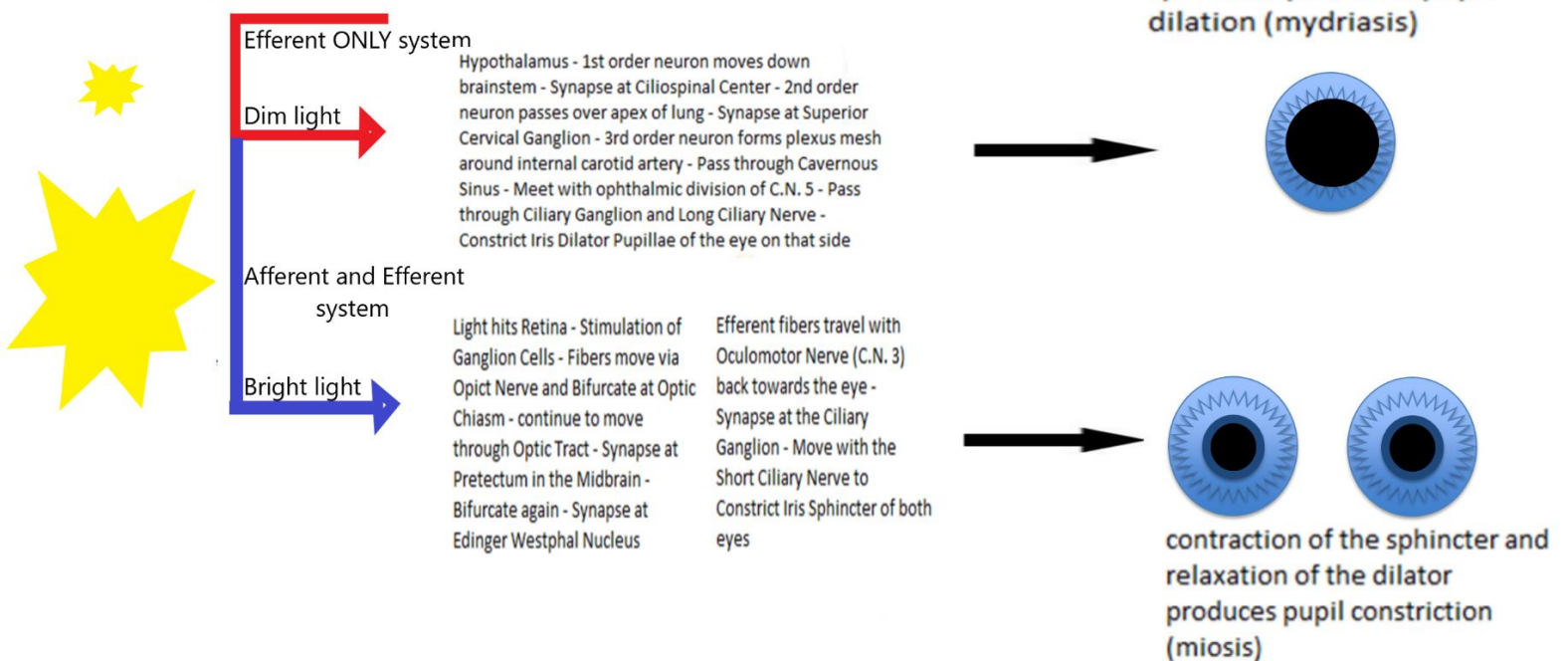
circular sphincter pupillae muscle constricts and the pupil becomes smaller (miosis) while the dilator pupillae relaxes.

The amount of light entering the eye is the main source of input which balances the sympathetic and parasympathetic innervation of the iris muscles. However, pupil size may also be influenced by accommodation, viewing distance, the patient's mood, alertness, cognitive load, and any drug use. The pupillary response summates the light intensity received by the entire retina, although there is some increased weight given to the amount of light hitting the central 10 degrees. The average pupil size in normal illumination is about 3.5mm but can range from 1.0-10.0mm. A pupil smaller than 2.0mm is considered miotic (small) and a pupil larger than 7.0mm is considered mydriatic (large). Senile miosis is the gradual decrease in pupil size with age due to a higher rate of atrophy of the dilator pupillae vs. sphincter pupillae muscles.

The autonomic nervous system consists of the parasympathetic, sympathetic, and enteric nervous systems. It supplies innervation to smooth muscles and glands and unconsciously regulates body function and the internal organs. The enteric division governs the function of the gastrointestinal tract and can act independently of the parasympathetic and sympathetic systems. The parasympathetic system is responsible for stimulation of the 'feed, breed, rest, and digest' responses such as stimulating saliva flow, slowing heart rate, constricting bronchi, stimulating bile release, bladder constriction, and pupil constriction. The sympathetic nervous system stimulates the 'fight or flight' responses such as accelerating the heartbeat, dilating bronchi, inhibiting gastrointestinal peristalsis, converting glycogen to glucose, secreting adrenaline, inhibiting bladder constriction, and pupil dilation. Although the pupil size is dependent on a balance between the parasympathetic and sympathetic nervous systems, the iris sphincter (which is

controlled by the parasympathetic nervous system) has more powerful and active control of pupil size than the iris dilator (which is controlled by the sympathetic nervous system).

Overview of the sympathetic and parasympathetic control of pupil size

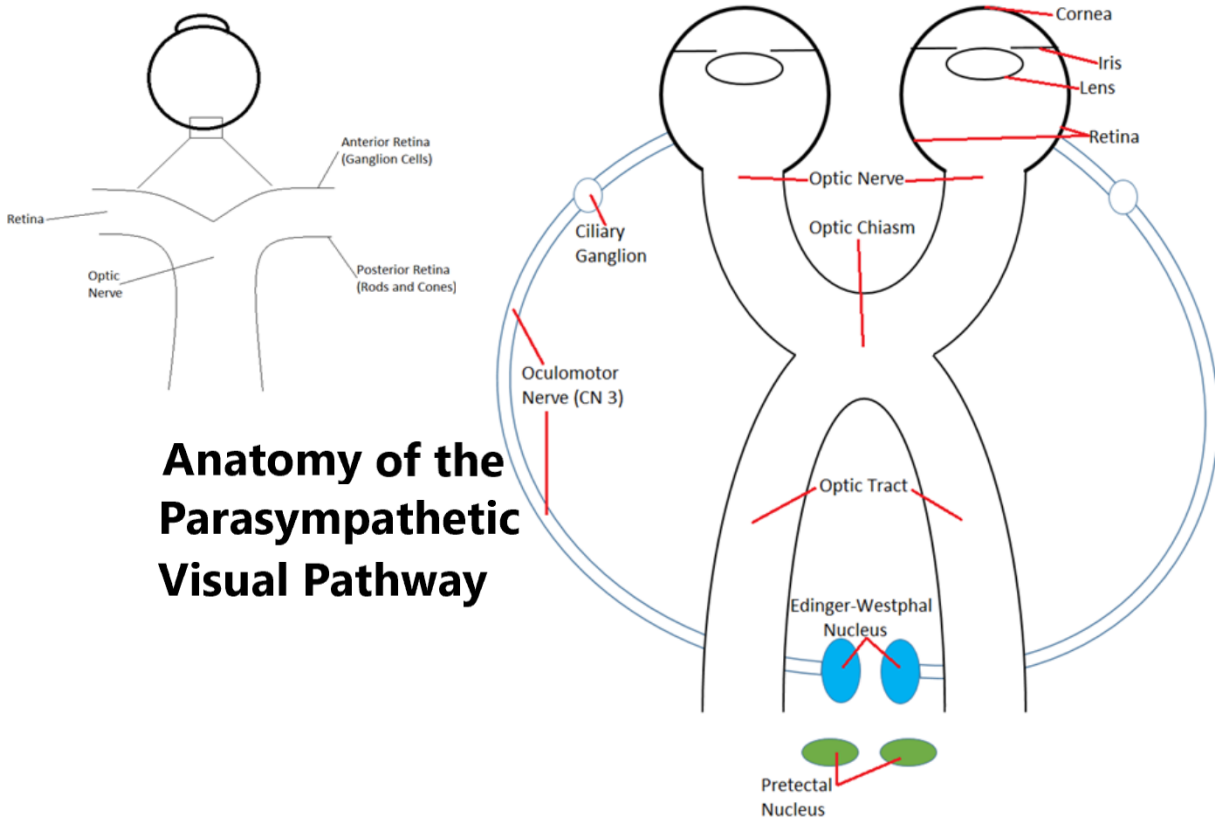


Parasympathetic Pupil Innervation

The parasympathetic pupillary pathway consists of both an afferent (moving from the eye to the brain) and an efferent (moving from the brain back to the eye) pathway.

Afferent parasympathetic pupillary pathway: As light enters the eye, the cornea and lens refract the light and focus it onto the retina. When the retina is stimulated by the light, it transduces the light image into electrical pulses via the retinal rods and cones in the posterior retina. The electrical signal from the rods and cones then moves forward in the retina to the ganglion cells. The ganglion cell axons move the information into the optic

nerve and then towards the brain. At the optic chiasm, the nerve fibers bifurcate allowing



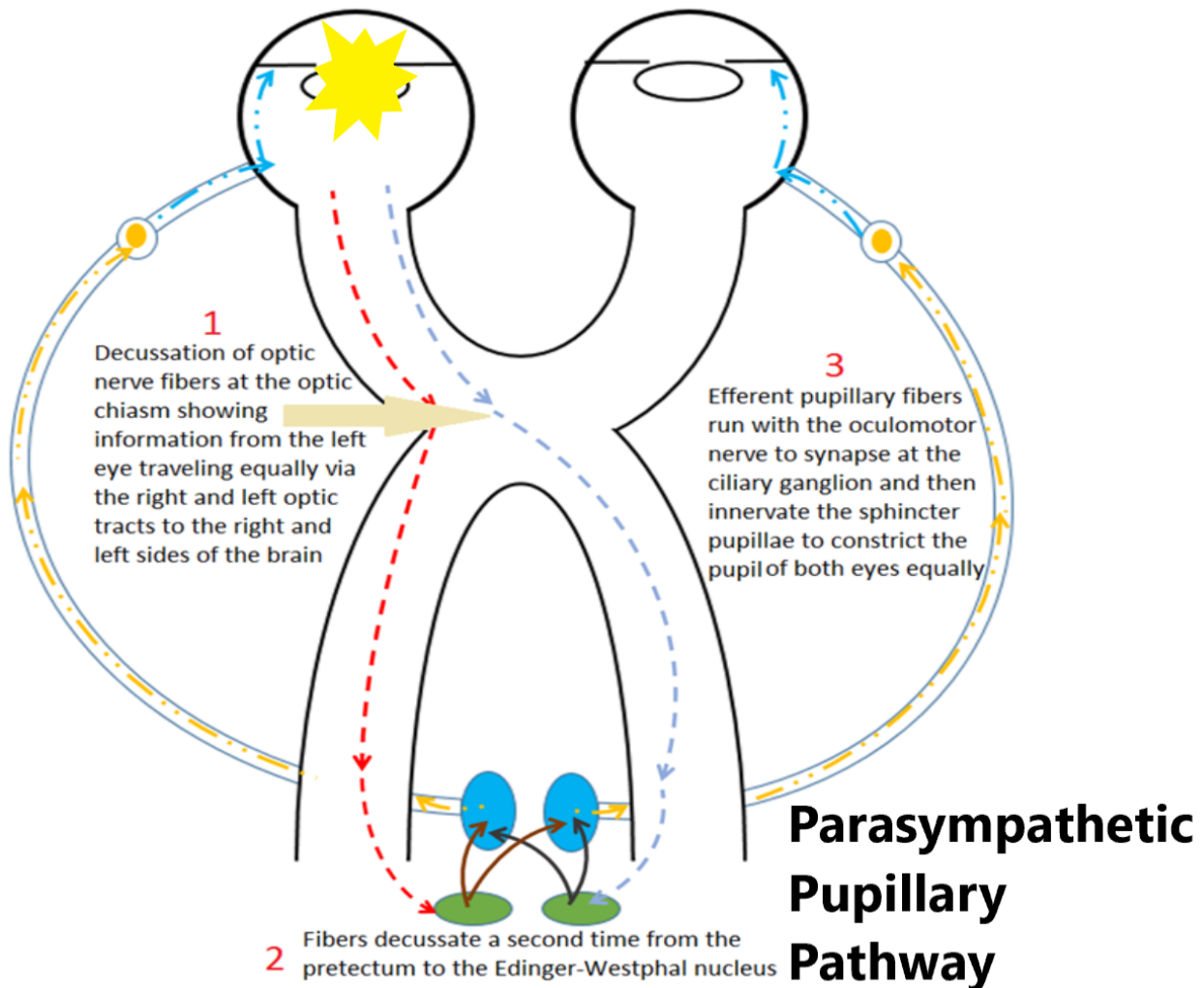
Anatomy of the Parasympathetic Visual Pathway

the nasal fibers from the right eye to move into the left optic tract and the nasal fibers from the left eye to move into the right optic tract. This means that the right optic tract equally contains visual information from both eyes and so does the left optic tract. From the optic tract, fibers break off to synapse primarily at lateral geniculate nucleus in the thalamus and then move to the visual cortex in the occipital lobe. Some fibers will break off from the optic tract to synapse at the hypothalamus for circadian rhythm control, the superior colliculus for saccadic function control, and the pretectum in the midbrain for pupillary control. Once the pupillary fibers synapse at the pretectal nuclei, they *bifurcate a second time* and synapse at the Edinger-Westphal (EW) nuclei of the oculomotor nerve (cranial nerve three). The synapse between the Pretectum and the EW nuclei is called the internuclear pathway (not afferent or efferent).

Efferent parasympathetic pupillary pathway: After synapsing at the Edinger-Westphal nuclei, the efferent parasympathetic fibers travel back towards the orbit and synapse at the ciliary ganglion. From the ciliary ganglion, the fibers run with the short ciliary nerves. 97% of the fibers go on to innervate the ciliary body to stimulate accommodation and 3% of the fibers go on to innervate the iris sphincter pupillae muscles to stimulate pupil constriction.

The efferent parasympathetic pupillary pathway shows a tie between the pupillary and accommodative systems. While pupil constriction due to increased illumination will not cause an increase in accommodation, when a patient fixates at near, this causes a triad of convergence, accommodation, and pupillary constriction. If the pupil responds normally to light, the pupillary near response (pupil constricts when fixating at near and accommodating) is always intact.

The iris sphincter has more powerful control of the pupil size than the dilator muscles. When illumination increases or the near reflex is stimulated, the parasympathetics cause a constriction of the iris constrictor and miosis of pupils size. Once that light or near stimulus is dampened or removed, the parasympathetic signal dampens (sphincter relaxes) and the sympathetics become activated (dilator constricts) causing an increase in pupil size.

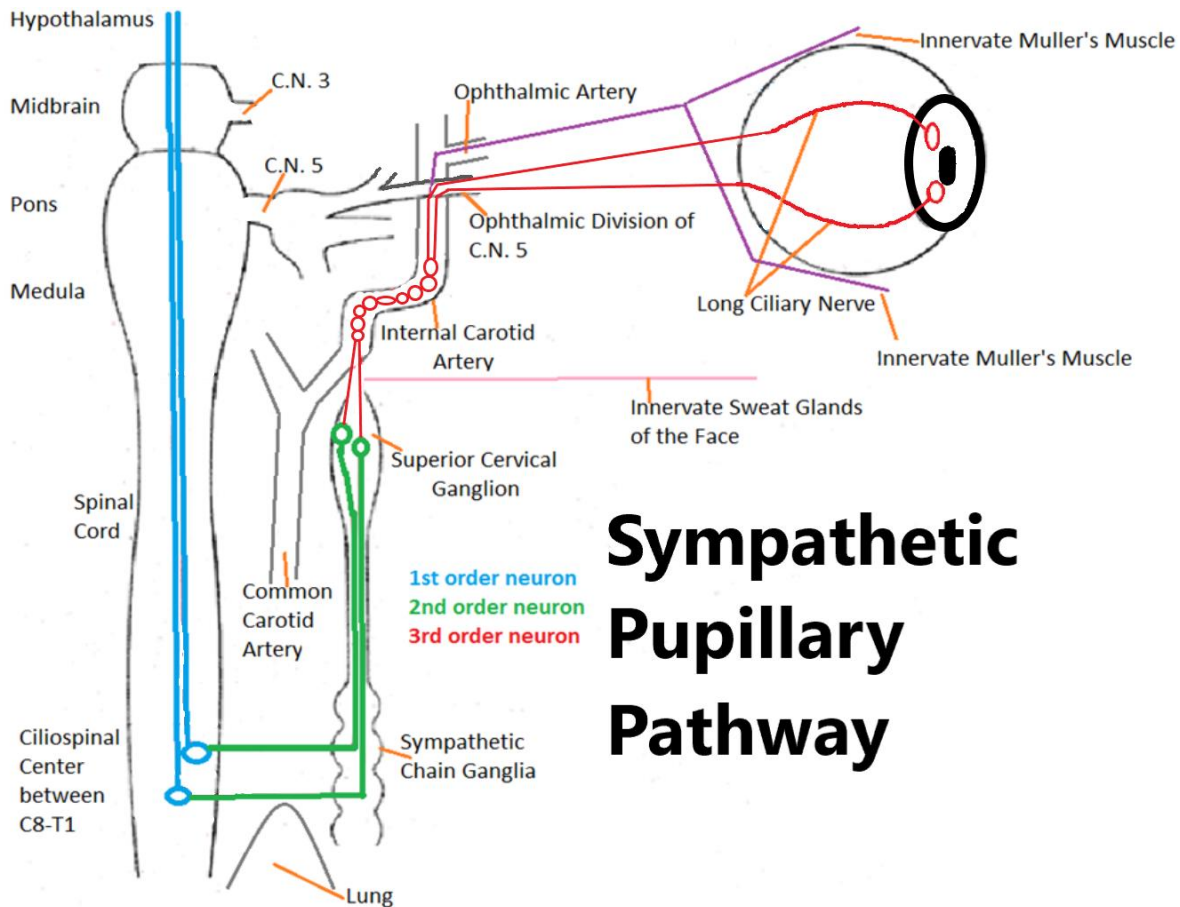


Sympathetic Pupil Innervation

Unlike the parasympathetic pupillary pathway, the sympathetic pupillary pathway is an efferent only pathway (signals move from the brain to the eye only) and has no bifurcation (the right side innervates the right eye and the left side innervates the left eye). The sympathetics respond when there is a dampening of the parasympathetic system (dim

illumination) and are increased during situations such as intense concentration, fright, and arousal.

The sympathetic pupillary pathway starts at the hypothalamus. From the hypothalamus, the 1st order neurons descend through the brainstem on the right and left side with no bifurcation and synapse at the ciliospinal center at the level of spinal cords C8-T1. The 2nd order neuron exits the spinal cord and passes over the apex of the lung and goes up to synapse at the superior cervical ganglion, which lies immediately anterior to the common carotid artery bifurcation. After synapsing at the superior cervical ganglion, the 3rd order neurons form a plexus mesh around the internal carotid artery and run along the internal carotid artery into the cavernous sinus. Inside the cavernous sinus, the fibers meet with the ophthalmic division of the fifth cranial nerve (CN 5) and the ophthalmic artery. The fibers that travel with the ophthalmic artery go on to innervate Mueller's muscle for eyelid control and the fibers traveling with the ophthalmic division of CN 5 move past the ciliary ganglion and then through the long ciliary nerve (do not synapse) to innervate the radial pupil dilator muscle. A small portion of the 3rd order neurons branch off before the cavernous sinus to innervate the sweat glands on that side of the face. Activation of the sympathetic pupillary pathway results in pupillary dilation, eyelid elevation, and facial sweating. Interruption of the ocular sympathetic pathway at any level results in miosis (pupil constriction), ptosis (lid droop), and facial anhidrosis (lack of sweating in the face) on the same side (ipsilateral).



Sympathetic Pupillary Pathway

Anisocoria

Anisocoria is when a patient has an unequal size between the pupils. Physiologic anisocoria is a normal difference in pupil diameter which occurs in 20% of the population. The difference in pupil size should be less than 1.0mm and the difference must be the same between the pupils whether the eye is in bright or in dim illumination to classify as physiologic. Physiologic anisocoria can vary in magnitude day to day and may switch eyes where one day the right pupil is larger and the next the left pupil is larger. Non-physiologic anisocoria is usually the result of an iris innervation or efferent pathway

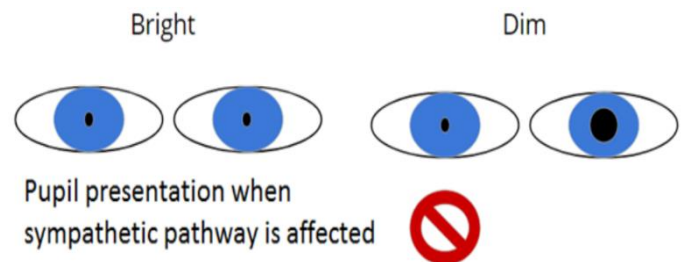
problem but can also be due to previous trauma or surgery, ocular inflammation, or iris synechia.

If anisocoria or other pupillary dysfunction is observed, a comprehensive and detailed case history can be key to making a proper diagnosis. It is important to question the patient about recent contact with medications or agents that may affect pupil size and any history of ocular trauma, surgery, or inflammation. It may be necessary to evaluate old photos of the patient to determine if the anisocoria is longstanding as many patients may not be aware of the condition. The iris sphincter and dilator muscles should be evaluated in the slit lamp for trauma as well as for signs of synechia and atrophy.

Anisocoria Worse in Dim Illumination

If the anisocoria appears worsen in dim illumination and improves in bright illumination, that implies that the iris dilator is not functioning and the smaller pupil is the irregular one. This suggests an impairment of the oculo-sympathetic nervous system.

The three most common causes of an anisocoria worse in dim illumination is pharmacologic agents, Argyll-Robertson pupil, and Horner's syndrome.



➤ Pharmacologic

- Pharmacologic constriction will occur from medications that stimulate the parasympathetic or inhibit the sympathetic nervous systems.
- Pupil constriction due to systemic medication such as codeine and oxycodone or illegal drugs such as morphine and heroin will present with bilaterally constricted and non-reactive pupils. Certain antipsychotics,

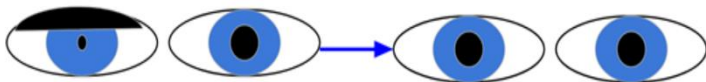
antidepressants, antihypertensives, and other medications such as pilocarpine and monoamine oxidase inhibitors may also cause bilateral pupil constriction.

- Certain sprays or patches for flea and tick control contain cholinergic agents (stimulate parasympathetics) so if a patient gets some on their hand and rubs one eye, the constriction will be unilateral.
- Argyll-Robertson pupil
 - Presents with asymmetrically bilateral, small, and irregular pupils which respond poorly to light and respond poorly to dilation. Light-near dissociation is present in these patients: the pupil will constrict when fixating at near markedly better than pupil constriction to light.
 - Argyll-Robertson pupils are now very rare in developed nations and are due to a bilateral lesion in the Edinger-Westphal nucleus mainly from chronic neurosyphilis. Other causes may include multiple sclerosis, diabetes mellitus, and Wernicke's encephalopathy.
- Horner's syndrome / Oculo-sympathetic paresis
 - An interruption along the oculo-sympathetic pathway between the origin (hypothalamus) and the iris dilator muscle will produce the classic triad of ipsilateral (same side) ptosis, miosis, and facial anhidrosis.
 - If the damage occurs in the 3rd order neuron, after the branching off of the fibers that innervate facial sweating, the defect will appear as an ipsilateral ptosis and miosis only.
 - 33% of Horner's syndrome are idiopathic (unknown cause) and 4-13% are congenital (present from birth). Idiopathic causes of Horner's syndrome usually occur before the patient is 2 years old. Trauma during delivery may also be a causative factor. The sympathetic nervous system plays a role in iris pigmentation so if the Horner's is present before the patient turns 2

years old, the affected eye will have less iris pigmentation and the patient will exhibit iris heterochromia (different colored irises with the lighter iris having the Horner's syndrome).

- A detailed case history, pharmacologic testing, and diagnostic imaging such as x-ray, computed tomography (CT), and magnetic resonance imaging (MRI) can be helpful in differential diagnosis and management of acquired Horner's syndrome.
- A hallmark of patients with Horner's syndrome is something called *dilation lag*. This occurs when the anisocoria is most evident in the first 4-5 seconds after the illumination is dimmed and decreases after 10-15 seconds. The Horner's pupil will have a delayed dilation after dimming of illumination due to the passive dilation of the iris from relaxation of the iris sphincter vs. the normal rapid and active dilation of the pupil with an intact sympathetic pathway.
 - Acquired causes of central or 1st order neuron deficits include:
 - Stroke
 - Trauma or surgery to the neck
 - Aortic or carotid artery dissection (*an emergency that requires immediate intervention*)
 - Pancoast (lung) tumor
 - Tuberculosis
 - Otitis media
 - Acquired causes of preganglionic or 2nd order neuron deficits include:
 - Pancoast (lung) tumor
 - Trauma or surgery to the neck

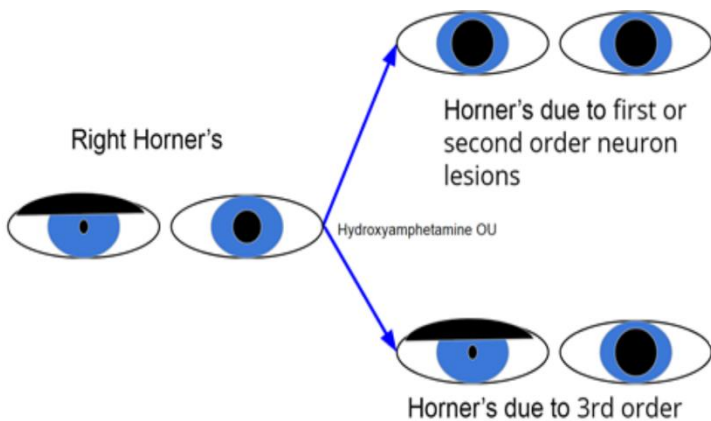
- Tuberculosis
- Thyroid surgery or neoplasm
- Acquired causes of postganglionic or 3rd order neuron deficits include:
 - Trauma or surgery to the neck
 - Raeder's syndrome
 - Giant cell arteritis (*an emergency that requires immediate intervention*)
 - Disorders affecting the cavernous sinus or superior orbital fissure
 - Nasopharyngeal carcinoma
- Pharmacologic testing to confirm Horner's syndrome and to isolate the location of the lesion can be performed in the office.
 - To help confirm Horner's syndrome is present: apraclonidine
 - Apraclonidine (Iopidine) is an alpha-adrenergic



0.5% or 1% Iopidine will have no effect on normal pupil dilate a Horner's pupil by at least 1.0mm in 30-40 min

receptor agonist (stimulates sympathetic nervous system) which can help identify if a patient has Horner's syndrome. One drop of 0.5% or 1% will have no effect on a normal pupil's size but will dilate a Horner's syndrome pupil by 1.0mm or more. The drop is instilled into both eyes and pupil size is evaluated before and then 30-45 minutes after drop instillation in normal room illumination. The 'normal' pupil's size should not change. If the suspected pupil has a dilation of 1.0mm or more, it is a positive test for Horner's syndrome.

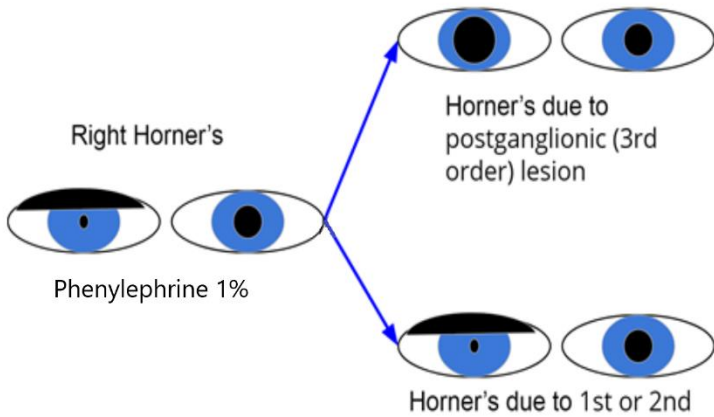
- Once Horner's syndrome is confirmed, either 1% hydroxyamphetamine or 1% phenylephrine can be used to localize the lesion.
 - 1% hydroxyamphetamine will dilate a non-Horner's or a 1st or 2nd order neuron Horner's lesion. 1% hydroxyamphetamine will not dilate a 3rd order



Horner's neuron lesion. The medication works by releasing stored norepinephrine from 3rd order (postganglionic) axon terminals into the neuromuscular junction at the iris dilator. This will only occur if the 3rd order neurons are intact. The drop is instilled into both eyes and pupil size is evaluated before and 30 minutes after drop

instillation. The 'normal' pupil will dilate and if the Horner's syndrome is due to a 1st or 2nd order neuron lesion, the Horner's pupil will also dilate. If the Horner's is due to a 3rd order lesion, it will not dilate. This test does not differentiate between 1st and 2nd order neuron lesions.

- 1% phenylephrine will dilate a 3rd order postganglionic Horner's syndrome in long standing cases. This occurs due to denervation super-



sensitivity and so new or acute onset cases may not respond properly. 1% phenylephrine will have a very mild dilation effect on a 'normal' non-Horner's pupil and will have no dilation effect on a 1st or 2nd order Horner's lesion. The drop is instilled into both eyes and pupil size is evaluated before and 30 minutes after drop instillation. The 'normal' pupil will dilate minimally and if the Horner's syndrome is due to a 1st or 2nd order neuron lesion the Horner's pupil will not dilate. If the Horner's syndrome is due to a 3rd order neuron lesion, the pupil will dilate more than the 'normal' pupil.

- In most instances, radiologic imaging such as x-ray, CT, and MRI take precedence over localization of the lesion via drops. If you review the possible causes, some of them are true emergencies which require immediate evaluation and treatment. This is especially true if the patient has any symptoms of diplopia, cranial nerve palsy, numbness, headache, or pain accompanying the Horner's syndrome.

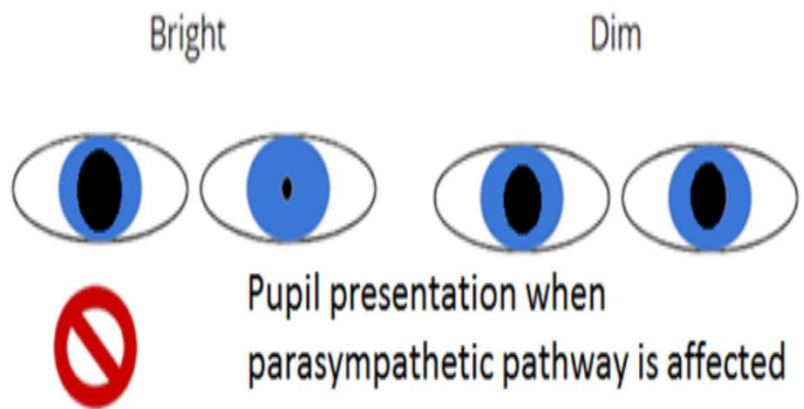
Localizing Horner's Syndrome

Is it a Horner's? 0.5-1% apraclonidine will dilate Horner's (but not a normal pupil) by >1mm after 30-40min	1% hydroxyamphetamine	1% phenylephrine (longstanding Horner's only)
Central (1st order)	Dilation of Horner's pupil Dilation of normal pupil	No dilation of Horner's pupil Minimal dilation of normal pupil
Preganglionic (2nd order)	Dilation of Horner's pupil Dilation of normal pupil	No dilation of Horner's pupil Minimal dilation of normal pupil
Postganglionic (3rd order)	No dilation of Horner's pupil Dilation of normal pupil	Dilation of Horner's pupil Minimal dilation of normal pupil

- There is no treatment for Horner’s syndrome itself, however resolution is often seen a few weeks or months after the underlying cause is treated. If the Horner’s syndrome persists, a daily 1.0-2.5% phenylephrine drop can be used to cosmetically resolve the anisocoria by slightly dilating the pupil.
-

Anisocoria Worse in Bright Illumination

If anisocoria appear worsen in bright illumination and improves in dim illumination, that implies that the iris sphincter is not functioning and the larger pupil is the irregular one. This suggests an impairment of the



parasympathetic nervous system. The four most common causes of anisocoria worse in bright illumination is pharmacologic agents, injury to the sphincter muscle, Adie’s tonic pupil, and cranial nerve 3 palsy.


➤ Pharmacologic

- Depending on the mode of administration, a pupil may be unilaterally or bilaterally dilated. If the agent is taken systemically, then the pupils will be bilaterally dilated while a drop or something topical may only affect one eye. Anticholinergics which act against the parasympathetic nervous system such as scopolamine found in motion sickness pills and patches and Permethrin found in insecticides will cause pupil dilation. Plants such as Angel’s trumpet, jimson weed, and belladonna as well as over-the-counter products containing phenylephrine (a sympathetic system stimulator) such as antihistamines, ‘get the red out’ eye drops, anti-itch creams, and nose sprays will all dilate the pupils. Recreational drugs such

as alcohol, marijuana, hallucinogens such as ecstasy, LSD, and acid, cocaine, methamphetamines, and inhaled propellants will produce bilaterally dilated pupils.

- A way to identify a bilaterally fixed or sluggish pupil dilated due to pharmacologic effects is to use 1% pilocarpine. Normal or neurologically dilated pupils will constrict to 1% pilocarpine while pharmacologically dilated pupils will not.
- Injury to sphincter
 - Injury or atrophy of the iris sphincter muscle from inflammation, trauma, or surgery can result in a dilated pupil. The injury can be sectoral affecting only parts of the sphincter and causing an irregularly shaped pupil, or affect the entire sphincter and appear as a dilated round pupil.
 - While it is possible to have trauma to the iris dilator muscles, the iris sphincter muscle is much more vulnerable to trauma due to its location and more likely to be affected.
- Adie's tonic pupil
 - Tonic pupils present with a dilated pupil exhibiting poor, sluggish, and segmental pupillary constriction to light with a slow redilation in the dark.

The segmental iris sphincter palsies are better observed under slit lamp evaluation of the iris vs. using a transilluminator. The patient will exhibit light-near dissociation: the pupil will constrict to accommodation better than to light, however even this will be slightly sluggish with a slow



redilation (as opposed to an Argyll-Robertson pupil). The tonic pupil is rare and usually initially unilateral in 80% of patients with the second pupil becoming involved with an increased incidence of 4% per year. 70% of patients are females age 25-45 and may exhibit diminished deep tendon reflexes and orthostatic hypotension. Adie's tonic pupil is thought to be a benign syndrome which is either idiopathic or due to syphilis, varicella-zoster, giant cell arteritis, diabetes, and/or orbital trauma. It may be caused by an infection, either bacterial or viral, which causes inflammation and secondary damage to the ciliary ganglion or short ciliary nerves. This damage leads to a loss of postganglionic parasympathetic innervation of the iris sphincter. As a result, the iris sphincter becomes super-sensitive and so a tonic pupil can be confirmed by using low dose pilocarpine drops.

- A normal pupil will constrict very slightly, if at all, to 0.1% pilocarpine while a super-sensitive tonic pupil will have a significant constriction after 30 minutes.
- After a few months or years, the dilated tonic pupil will constrict and become smaller than the unaffected pupil and remain that way, making it difficult to differentiate from Argyll-Robertson pupils.
- There is no treatment available for Adie's tonic pupils. When photophobia due to dilation becomes symptomatic, 0.1% pilocarpine or 0.2% brimonidine drops may be used for symptom relief. Cosmetic soft contact lenses may be used to mask the anisocoria as well. If accommodation is affected, bifocals may be prescribed to improve visual acuity at near.

➤ Cranial nerve 3 palsy

- The 3rd (oculomotor) cranial nerve (C.N. 3) innervates the levator

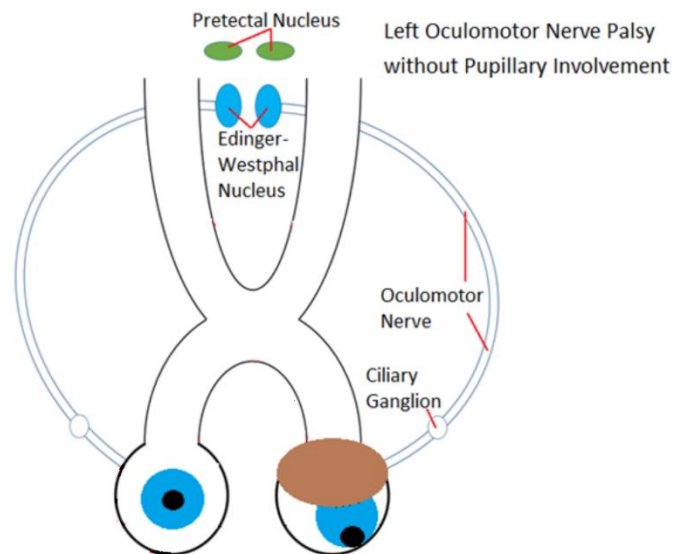
palpebrae superioris muscle in the upper eyelid and 4 of the 6 extraocular muscles (medial rectus, superior rectus, inferior rectus, and inferior oblique). In an oculomotor nerve palsy, the patient will exhibit a moderate-large ptosis and an eye that appears to be positioned down and out

(hypotropia and exotropia) when looking ahead. On extraocular

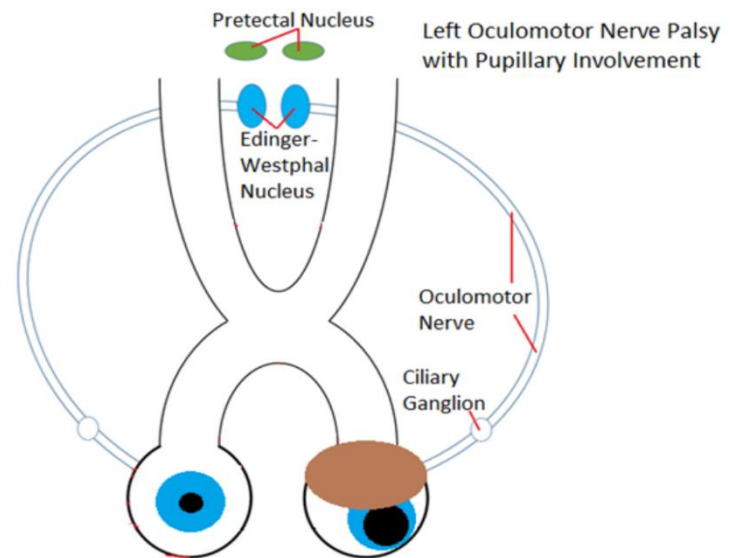
motility testing, the eye is unable to adduct (turn in towards the nose). The efferent parasympathetic pupillary fibers run with the oculomotor nerve *after* they have bifurcated 2 times so damage to the pupillary fibers during a CN 3 palsy will result in an ipsilateral pupillary defect.

- The parasympathetic fibers are located on the surface of cranial nerve 3, making them very susceptible to compression via a space occupying lesion or an aneurysm at or close to C.N. 3. Since the efferent fibers do not bifurcate, damage to these fibers results in an ipsilateral (same side) ptosis, hypotropia and exotropia, and an inability of the pupil to constrict with poor accommodation.

- A dilated pupil with intact accommodation and no ptosis or exotropia is very unlikely to be due to an oculomotor nerve palsy.



- The best corrected visual acuity is not affected in oculomotor nerve palsies and the dilated pupil will constrict to 1% pilocarpine (vs. a pupil that is pharmacologically dilated which would not).
- A 3rd cranial nerve palsy with no pupil involvement can occur and is usually ischemic in nature. Ischemic CN3 palsies without pupillary involvement can be due to systemic conditions such as diabetes and hypertension. Most of these will self improve or fully resolve within several months after the systemic disease is controlled.
- A recent onset oculomotor nerve palsy with a dilated pupil is an emergency and the patient should be sent to the emergency room right away for neuroimaging and angiography to rule out aneurysm, tumor, and thrombosis as the cause.

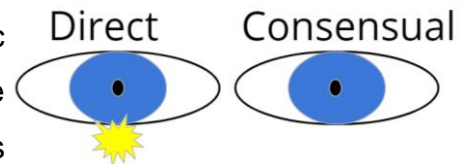


- An aneurysm of the posterior communicating artery will present with pupil involved C.N. 3 palsy 30-60% of the time.
 - Other causes of pupil involved C.N. 3 palsy includes tumors, thrombosis, uncal herniation, and trauma.
- 14% of C.N. 3 palsies due to an aneurysm of the posterior communicating artery do not have pupil involvement in the early stages and progress to involve the pupil.
 - Any recent onset oculomotor nerve palsy without a dilated pupil must be followed closely in conjunctions with a

neurologist to ensure that a pupil sparing palsy does not convert to pupil-involving over time.

Defects of Afferent Pupillary Light Response (APD)

An afferent pupillary defect (damage to the parasympathetic pathway going from the eye to the brain) will not cause anisocoria (pupils of different sizes) in normal illumination. This is because there are two bifurcations in the parasympathetic pupillary pathway resulting in an equal constriction in both eyes. A light shone into the right eye will produce an equal direct constriction in the right eye and a consensual constriction in the left eye.



Pupil Testing

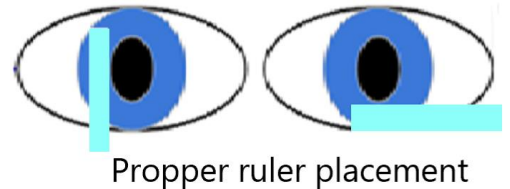
Since pupil size is a balance between the parasympathetic (afferent and efferent) and sympathetic (efferent) systems, pupil testing can objectively measure the integrity of both the afferent (eye to brain) and efferent (brain to eye) pupillary pathways. Pupillary testing involves evaluation of pupil size in light and dim illumination, pupil shape, location, and the strength of the direct pupillary light response compared to the strength of the consensual pupillary light response in the same eye. On observation, pupils should be equal, round, centered in the iris, and symmetrical in shape and size.

➤ Shape

- A non-round pupillary shape may be attributed to things such as previous surgery or trauma, ocular inflammation, iris atrophy, ocular ischemia, posterior synechiae, or congenital iris disorders.

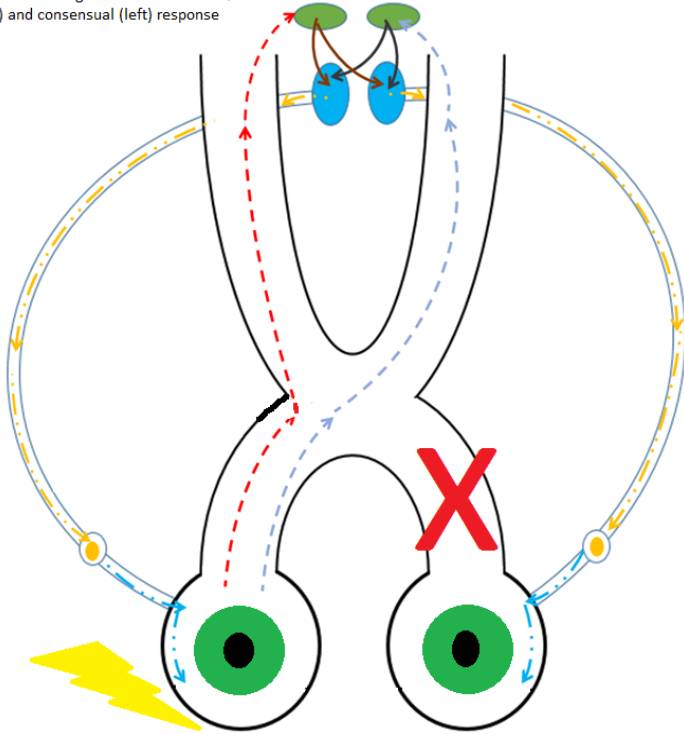
➤ Size

- Observation in normal illumination is usually used to gauge if pupil size is equal. If there is ambiguity about the size of the pupils or an observed anisocoria, the pupil size is measured in bright and dim illumination.

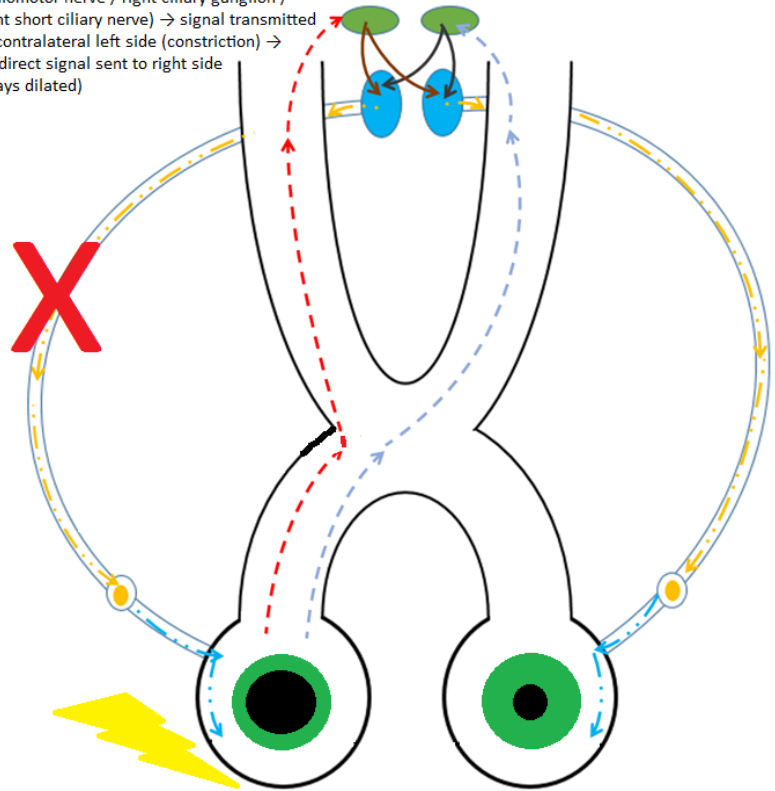


Pupil size can be measured using a millimeter ruler, although some newer auto refractor machines and digital pupillometers can measure the size as well. If a ruler is being used, the provider should have the patient take off their glasses and look straight ahead. The provider should stand to the side and present the ruler either on the temporal side or underneath the iris the patient's visual axis to measure the pupil size. If the provider or the ruler is within the visual axis of the patient, this may produce accommodation and thus miosis and false anisocoria.

Light into right eye → damage to left side afferent pathway (optic nerve / chiasm / tract) → signal transmitted to midbrain since right afferent is intact → normal direct (right) and consensual (left) response

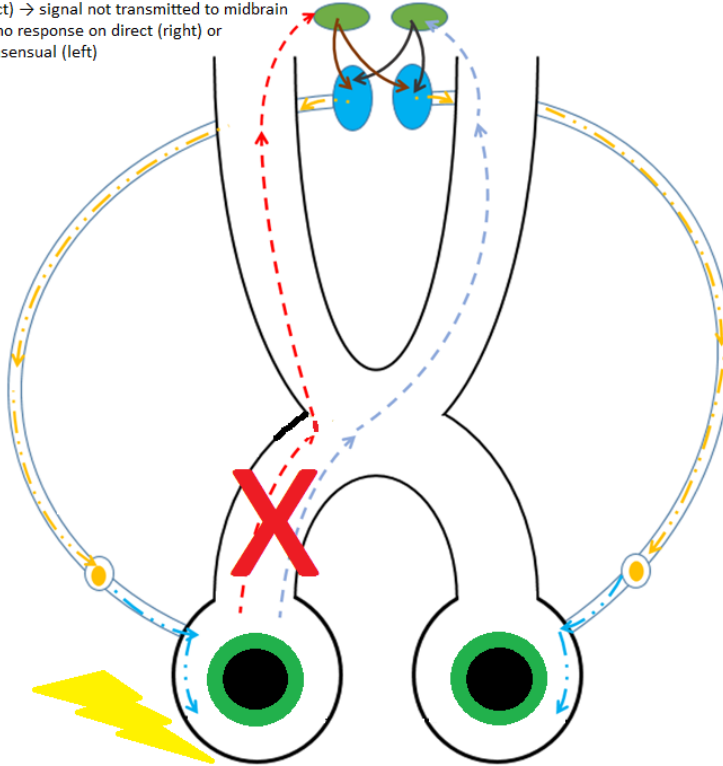


Light into right eye → damage to right side efferent pathway (midbrain / right oculomotor nerve / right ciliary ganglion / right short ciliary nerve) → signal transmitted to contralateral left side (constriction) → no direct signal sent to right side (stays dilated)

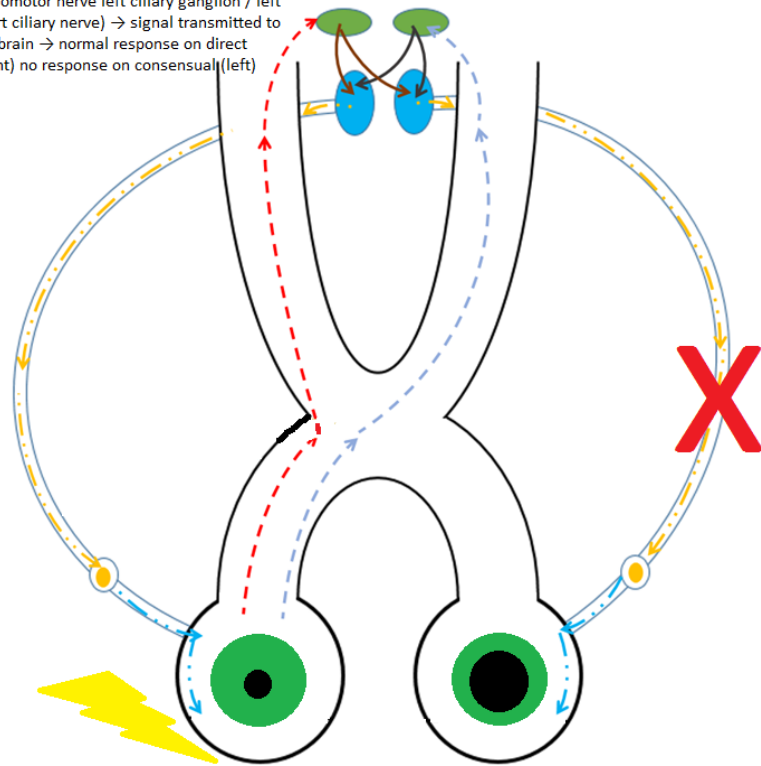


Pupillary response ...
various optic pathway lesions

Light into right eye → damage to the right side afferent pathway (optic nerve / chiasm / tract) → signal not transmitted to midbrain → no response on direct (right) or consensual (left)



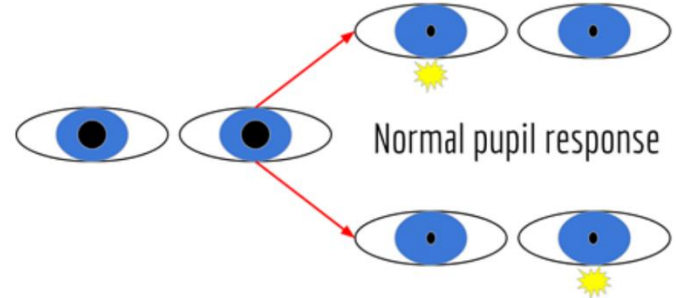
Light into right eye → damage to left efferent pathways (midbrain / left oculomotor nerve / left ciliary ganglion / left short ciliary nerve) → signal transmitted to midbrain → normal response on direct (right) no response on consensual (left)



The steps for pupillary testing are as follows:

- Instruct patient to take off glasses and fixate at a distant target
- Observe pupils for anisocoria in normal room illumination before introducing any light
- Dim room lights and observe for anisocoria again (make sure lights are not too dim so that pupils are still visible)
- Use a transilluminator, shine light ~1 inch away directly into eye being tested
 - Make sure no light is getting into the non-testing eye as stray light can cause the non-tested pupil to constrict

- Hold light for 2-4 seconds
 - Observe both tested (direct) and non-tested (consensual) pupil response. The constriction amount (quantity), rapidity (quality), and time to release should be the same for both eyes.

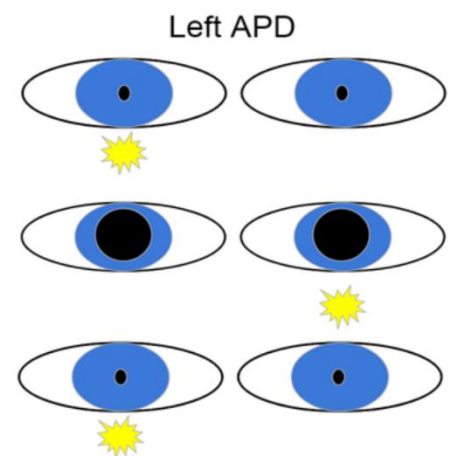


- Once a pupil constricts, it is normal to observe hippus - a minute rhythmic continuous dilation and contraction of the pupil.

- Move light to the other eye and hold for 2-4 seconds
 - Observe both tested (direct) and non-tested (consensual) pupil response. The constriction amount (quantity), rapidity (quality), and hippus should be the same for both eyes. Make sure to spend an equal amount of time on each eye, as shining the light longer into one eye may produce false results.

- Perform the swinging flashlight / Marcus Gunn / Relative Afferent Pupillary Defect test

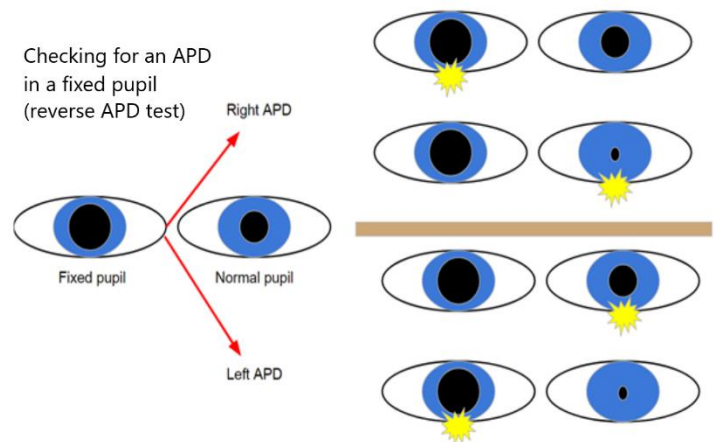
- Hold light on eye A for 2 seconds and then quickly move the light to eye B. Move the light in a slight downward 'U' motion to avoid stimulating accommodation by moving directly across the visual axis. Hold the light on eye B for 2 seconds while still observing eye A. Move the light back to eye A and observe eye A. Repeat this 2-3 times and look for a constant and equal amount of pupillary constriction in eye A during direct and consensual responses. Repeat for eye B.



- You are comparing the strength of the direct pupillary light response to the strength of the consensual pupillary light response in the *same eye*. This test performs a relative comparison between the direct and consensual responses and is looking for damage at or before the midbrain.
- A relative afferent pupillary defect is present when the consensual constriction of the pupil is greater than the direct response.
- If there is only one functioning (due to trauma, surgery, or pharmacologic effect) or only one visible (corneal edema or scar) pupil, a RAPD / Marcus Gunn evaluation can still be performed

- Perform the swinging flashlight test as noted above, but only

observe the functional / visible pupil. Compare the functional pupil's direct response to that same eye's consensual response. If the functional pupil constricts more with direct illumination than with consensual illumination, a 'reverse RAPD' is present in the opposite unreactive / unobservable eye.



While visual acuity does not necessarily correlate with a RAPD, a provider should carefully evaluate for a RAPD when the best corrected visual acuity is reduced. It helps to grade the magnitude of a RAPD to help identify subtle defects and to monitor for progression. Grading can be done via observation and a grading scale or quantitatively via neutral density filters.

- Observational grading Scale of RAPD
 - Grade 1+: weak initial pupillary constriction followed by greater redilation
 - Grade 2+: initial pupillary stall followed by greater redilation
 - Grade 3+: immediate pupillary dilation
 - Grade 4+: no reaction to light (amaurotic)
- Neutral density filters reduce the amount of light entering the eye with an equal reduction of all wavelengths. A filter is placed in front of the 'better / non-APD' eye and the swinging flashlight test is performed. The filter strength is increased until the afferent responses are equal in both eyes and the RAPD resolves.

Normal pupil testing results are recorded as PERRLA (+/- RAPD)

- PE: pupils are equal
- R: pupils are round
- RL: pupils are equally reactive to light on direct and consensual testing
- A: pupils are responsive to accommodation
 - If the accommodative pupil response is not performed, the A is left off
- (-) RAPD or MG: negative relative afferent pupillary defect / Marcus Gunn pupil

If there is an abnormal finding on pupillary testing, it should be fully documented. If the pupils are not equal in size (anisocoria), the size of both pupils should be noted in both light and dark illumination. If the pupils are not round, their shape should be described. If the pupils are not equally reactive to light, it should be noted if the issue is with the direct, consensual, or both responses. If the pupils are not briskly and fully responsive to accommodation, it should be noted if there is no response at all or a poor and sluggish response. If an RAPD is present, it should be recorded which eye has the RAPD and a grade should be provided.



Pupillary testing is an important component of every comprehensive eye examination. Careful observation along with a comprehensive and detailed case history may reveal key information about the visual pathway and autonomic nervous system and help make the proper diagnosis. Eye care providers must understand this complex pathway as well as what a dysfunction might signify.

References

1. Spalton DJ. (1984). Neuro-Ophthalmology in *Atlas of Clinical Ophthalmology*. (pp. 19.2-19.24). London, England. Gower Medical Publishing.
2. Young K. (2013). Autonomic Reflexes and Homeostasis in *Anatomy and Physiology*. OpenStax. Accessed July 10, 2018.
<https://cnx.org/contents/FPtK1z mh@6.27:C650g-ah@2/Autonomic-Reflexes-and-Homeost>
3. McDougal D. H., Gamlin P. D. (2015). Autonomic control of the eye. *Compr. Physiol.* 5, 439–473.
4. Gray, H. (1918). Sympathetic connections of the ciliary and superior cervical ganglia in *Anatomy of the Human Body*. Bartleby. Accessed July 10, 2018.
<https://upload.wikimedia.org/wikipedia/commons/a/a5/Gray840.png>

Image References

All images created by Dr. Tamara Petrosyan.

© 2019 American Optometric Association

