

University of Udaipur
College of Agriculture
Department of Entomology
Campus Jobner, Rajasthan (India)

V. P. SHARMA

Induced pathology of certain insecticides in *Dysdercus koenigi* FABRICIUS

With 20 textfigures

Histological effect of DDT has been reported by a number of workers and there is controversy on the induced pathology. There are no accounts available on the histological effect of dimecron, phosdrin and sevin.

During the course of present investigations, studies have been made on the histological effect of these insecticides on the tissues of Red cotton bugs *Dysdercus koenigi* FABRICIUS, in order to find out the nature of histological degenerations caused by DDT which has been the subject of controversy, and certain other new insecticides.

Material and Methods

Dysdercus koenigi FABRICIUS were collected from Hollihock plants and reared in laboratory. Bugs were provided with crushed cotton seeds, fresh leaves of Malvaceous plants and optimum humidity.

DDT, dimecron, phosdrin and sevin insecticides were selected for the study.

Descriptions of the insecticides:

1. DDT, P,P'
1,1,1-trichloro-2,2-bis (p-chlorophenyl) ethane (p,p' isomer) 100%
2. Dimecron 50 E. C. One imperial gallon contains 5 lbs. of Phosphomidon
3. Phosdrin, technical
purity —
alpha isomer of 2 — carbomethoxy — 1 — methylvinyl dimethyl phosphate . . . min. 60%
Insecticidally active, related compounds Max. 40%
4. Sevin (carbaryl), technical
1-naphthyl N-methyl carbamate 100%

These insecticides were dissolved in acetone in volumetric flasks. The insecticides were applied through a micro-applicator. Male bugs were used during the studies to avoid any controversy on sex and all conditions of test insects were kept identical. Moribund bugs were selected for histological examinations and permanent preparations were made following the usual technique of paraffin imbedding and sectioning. Haemotoxylin eosin Y stain was used for both alimentary canal and nervous tissues however, gold chloride and silver albumose stain was also used for nervous tissues. The staining procedures were same as have been reported by SHARMA (1965).

Red cotton bugs were applied topically on the pronotum with the following lethal doses:

Insecticides	Dosages
DDT	57.15 r/gm.
Dimecron	37.21 r/gm.
Phosdrin	24.62 r/gm.
Sevin	33.57 r/gm.

Observations

Alimentary canal

There are no appreciable histological changes in muscles of the alimentary canal. Muscles of foregut remain attached to the epithelial cells and they become shrunk and vacuolated. The cytoplasm of the epithelial cells become unevenly stained and disintegrated and their nuclei appear shrunk and dislocated (Figs. 1 to 4)¹. Vacuoles of DDT are usually big and uniform in size (Fig. 2) as compared to other poisonings and DDT effected nuclei appear vacuolated and ruptured expelling the chromatin granules in cytoplasm.

Histological changes remain of the same nature in midgut and hindgut excepting the pathology which varies with the insecticide (Figs. 5 to 10).

Central Nervous System]

Neuropathological degenerations also vary in intensity with the insecticides. Neurilemma of the brain, thoracic and thoracico-abdominal ganglia has not been affected with any of these insecticides. Histological changes are very intense in thoracic and thoracico-abdominal ganglia than in the brain. The observations reveal degeneration and lysis of the cortical tissue, presence of clear spaces, acute vacuolation, dissolution of cell components, and the nuclei appear distorted and vacuolated. The chromatin granules clump under the effect of sevin and show chromatolysis with other insecticides. The neurosecretory cells show vacuolation and distortion. In neurospongium, there is intense vacuolation, dissolution of fibre tracts, lysis and nuclear degeneration. Lesions are not formed with the application of any of these insecticides (Figs. 11 to 20).

Discussion

Histological changes brought by DDT have been observed in all parts of the alimentary canal. Earlier works of SALKELD (1951) and CHADBOURNE & RAINWATER (1953) have reported absence of any pathology with DDT treatment.

NELSON et. al. (1944) while studying the histopathological changes following the administration of DDT to several species of animals concluded that though there is a wide variation in the sensitivity to the compound among different individuals of a given species, the lesions caused were consistent throughout the different species. DDT caused no effect

¹ Abbreviations: *M* — Muscles; *COR* — Cortex; *CS* — Clear spaces; *EP* — Epithelium; *NU* — Nucleus; *NEL* — Neurilemma; *NER* — Neurospongium; *VAC* — Vacuoles.

on the nerve cells of the brain and spinal cord. They concluded that because of the tremors of long duration produced by DDT, it would appear to be a promising experimental agent for the neuropathologists. LAUGER et. al (1945) noticed vacuole formation and disappearance of cell nuclei in ganglion cell of the DDT poisoned insects. LUDWIG (1946) attributed DDT toxicity to the greater metabolic activity of the poisoned Japanese beetle. YEAGER & MUNSON (1945) suggested that DDT in roaches must have caused receptive discharges of the motor nerve impulses at some points or point along the nerves. BODENSTEIN (1946) found that DDT could effect the peripheral nervous system without necessarily affecting the central nervous system. ROEDER & WEIANT (1946) pointed out that undoubtedly DDT effects motor nerves and muscle fibres of cockroach, the tremors characteristic of DDT poisoning being due to the intense bombardment of motor neurones. TOBIAS & KOLLROS (1946) found a rise of acetylcholine contents in the ventral nerve cord of DDT poisoned roaches, they noticed an increase of glycogen, glucose and non-fermentable reducing substances and that the thoracic ganglia are the critical loci for the action of DDT. WELSH & GORDON (1947) observed that DDT acted on peripheral nerve fibrils of insects and a single nerve impulse on arriving at DDT treated region of motor nerve axon gives rise to high frequency valley of nerve impulses and resulted in a tetanic contraction of the muscle. BOZKURT (1948) concluded that DDT and gamma BHC are taken up through the insect cuticle and they are not dependent on the nerve endings and nerves of American Cockroach killed by DDT. RICHARDS & CUTKOMP (1945) have reported that DDT has not produced any histopathological change in *Periplaneta americana* however, relatively slight changes were noted in the brain of contact poisoned *Musca*, consisting of partial lysis of fibres and nuclear degeneration (HARTZELL 1945). LORD (1949) suggested that the action of DDT increased the activity of insects thus shortening their life. SALKELD (1951) reported distinct histological differences in midguts from the normal structures in DDT poisoned bees. CHADBOURNE & RAINWATER (1953) found no histological change in larvae of *Heliothis armigera* with DDT treatment. SOLIMAN & SOLIMAN (1958) observed histological changes brought about in the midguts, fat bodies, muscles, malpighian tubules, ventral nerve ganglia and haemolymph of larvae of *Prodenia litura* with DDT poisoning.

There are conflicting reports on the histological changes induced by DDT and during the course of present investigations it was found that DDT causes path ology in alimentary canal and central nervous system of Red cotton bugs.

No literature is available on the histological effect of dimecron, phosdrin and sevin. The observations reveal that these insecticides have been causing equally acute histological degenerations in the alimentary canal and central nervous system of the Red cotton bugs.

Conclusions

All the four insecticides i.e., DDT, dimecron, phosdrin and sevin cause same nature of histological effect in the alimentary canal and the central nervous system, excepting the intensity of pathology which varies with the insecticide.

Vacuolation is caused in all parts of the alimentary canal however, it has been observed that the vacuoles of DDT are big and uniform in size as compared to other insecticides and DDT effected nuclei appear vacuolated and ruptured expelling the chromatin granules in the cytoplasm. Other histological changes remain of the same type with all the insecticides.

Neuropathological changes are intense in thoracic and thoracico-abdominal ganglia than in the brain. It has been observed that the application of insecticides cause degeneration and lysis of the cortical tissue, presence of clear spaces, acute vacuolation and dissolution of cell components. The nuclei appear distorted and vacuolated and the chromatin granules clump with DDT poisoning

and show chromatolysis with other insecticides. In neurospongium, there is intense vacuolation, dissolution of fibre tracts, lysis and nuclear degeneration. Lesions are absent with the application of these insecticides.

Summary

Histological changes were observed with the application of DDT, dimecron, phosdrin and sevin in the alimentary canal and central nervous system of Red cotton bugs *Dysdercus koenigi* FABRICIUS. It is concluded that the application of these insecticides causes equally acute histological degenerations both in the alimentary canal and the central nervous system.

Zusammenfassung

Bei Anwendung von DDT, Dimecron, Phosdrin und Sevin wurden beim Roten Baumwollkäfer *Dysdercus koenigi* FABRICIUS histologische Veränderungen im Ernährungskanal und im Zentralnervensystem beobachtet. Daraus wird geschlossen, daß die Anwendung dieser Insektenbekämpfungsmittel gleichermaßen akute histologische Zerfallserscheinungen im Ernährungskanal und im Zentralnervensystem hervorruft.

Резюме

При применении DDT, Dimecron, Phosdrin и Sevin отмечались у *Dysdercus koenigi* FABRICIUS гистологические изменения в пищеварительной и центральной нервной системах. Из этого вытекает, что применение этих средств вызывает гистологические разложения и в пищеварительной и в центральной нервной системах.

References

- BODENSTEIN, D., Investigation on the locus of action of DDT in flies (*Drosophila*). Biol. Bull., **90** (2), 148—157; 1946.
- BOZKURT, B., Vergleichende Untersuchungen zur Aufnahme von Insekticiden (DDT und Gammexane) in den Arthropodenkörper. Rev. Fac. Sci. Univ. Istanbul, Ser. B. Sci. Nat., **13** (1), 55—56; 1948.
- CHADBOURNE, D. S. & RAINWATER, C. T., Histological effects of calcium arsenate, DDT and dieldrin on larval tissues of the Bollworm. Journ. Econ. Ent., **46**, 44—48; 1953.
- HARTZELL, A., Histological effects of certain sprays and actmatoy on the nerves and muscles of the houseflies. Contrib. Boyce Thomp. Inst., **13**, 443—454; 1945.
- LAUGER, P. et. al., Mechanism of intoxication by DDT. Address reprinted by Geigy Co., New York; 1945.
- LORD, K. A., The effect of insecticides on the respiration of *Oryzaephilus surinamensis*; an attempt to compare the speeds of action of a number of DDT analogues. Ann. appl. Biol., **36**, 113—138; 1949.
- LUDWIG, D., The effect of DDT on the metabolism of the Japanese beetle, *Popillia japonica* NEWMAN. Ann. ent. Soc. Amer., **39**, 496—509; 1946.
- NELSON, A. A. et al., Histopathological changes following administration of DDT to several species of animals. U. S. Public Health Reports., **59** (31), 1009—1020; 1944.
- RICHARDS, A. G. & CUTKOMP, L. K., Neuropathology in insects. Journ. New York ent. Soc., **53** (4), 313—354; 1945.
- ROEDER, K. D. & WEIANT, E. A., The site of action in DDT in the Cockroach. Science, **103** (2671), 304—306; 1946.
- SALKELD, E. H., A toxicological and histophysiological study of certain new insecticides as "stomach poisons" to the honey-bee *Apis mellifera* L. Canadian Ent., **S3** (2), 39—52 & (3), 53—61; 1951.

- SHARMA, V. P., Pharmacology and histopathology of certain insecticides in grasshopper, *Poecilocus pictus* FABR. Beitr. Ent., 15 203–212; 1966.
- SOLIMAN, S. A. & SOLIMAN, A. A., Histopathological destruction caused to the cotton leaf worm, *Prodenia litura* F. by some of the newer insecticides. (Lepidoptera: Noctuidae). Bull. Soc. Ent. Egypt., 42, 199–228; 1958.
- TOBIAS, J. M. & KOLLROS, J. J., Loci of action of DDT in the Cockroach (*Periplaneta americana*). Biol. Bull., 91 (3); 247–255; 1946.
- WELSH, J. H. & GORDON, H. T., The mode of action of certain insecticides on the arthropod nerve axon. Journ. Cellular Comp. Physiol., 30 (2), 147–171; 1947.
- YEAGER, J. F. & MUNSON, S. C., Physiological evidence of a site of action of DDT in an insect. Science, 102, 305–307; 1945.

Figures

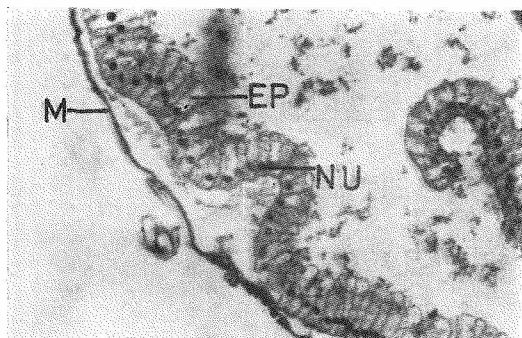


Fig. 1. Control. T. S. of crop showing muscles, epithelium and their nuclei

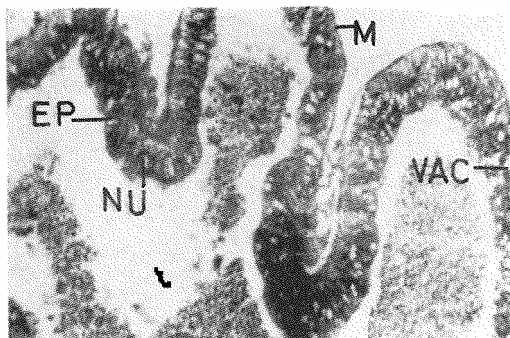


Fig. 2. DDT treatment. T. S. of crop showing muscles, contracted and vacuolated epithelium, and shrunken and dislocated nuclei

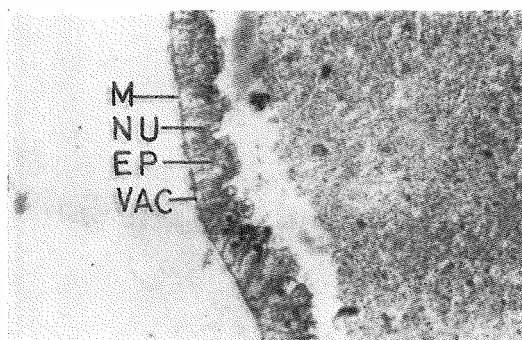


Fig. 3. Dimecron treatment. T. S. of crop showing marked reduction in size of epithelial cells and vacuolation

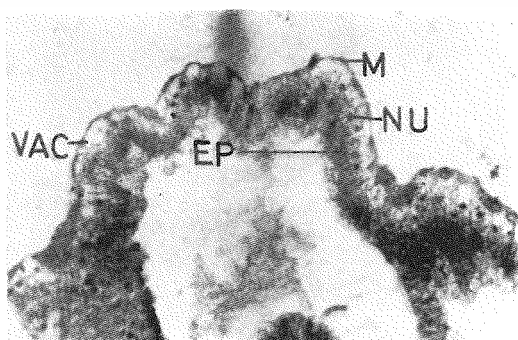


Fig. 4. Sevin treatment. T. S. of crop showing the contracted epithelium and their nuclei

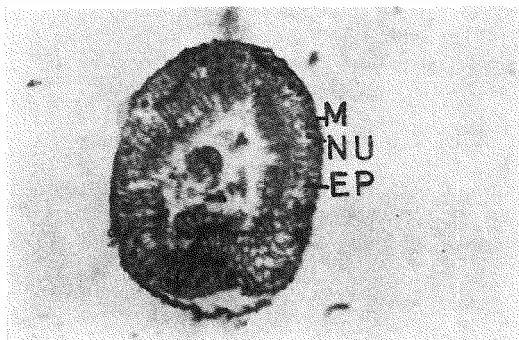


Fig. 5. Control. T. S. of midgut showing muscles, epithelium and their nuclei

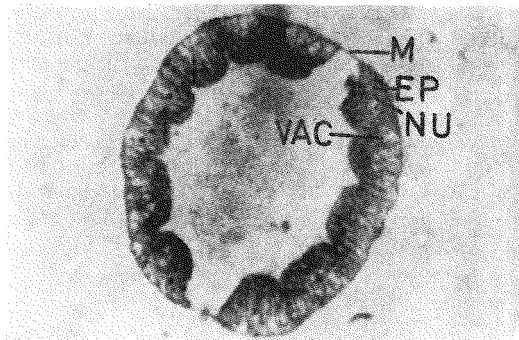


Fig. 6. Sevin treatment. T. S. of midgut showing vacuolation and dislocation of nuclei

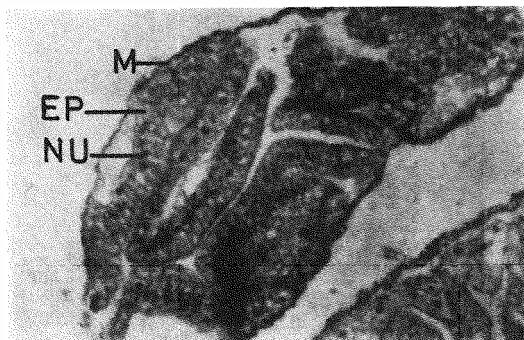


Fig. 7. Control. T. S. of hindgut showing muscles, epithelium and their nuclei

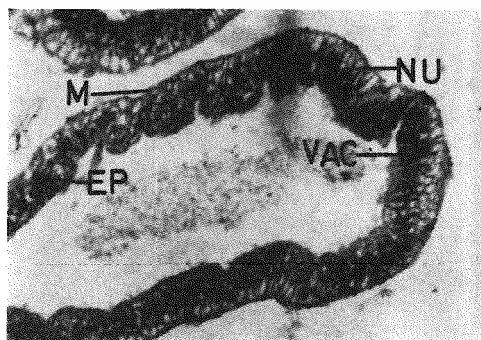


Fig. 8. DDT. treatment. T. S. of hindgut showing vacuolation in epithelium; and shrunk and dislocated nuclei

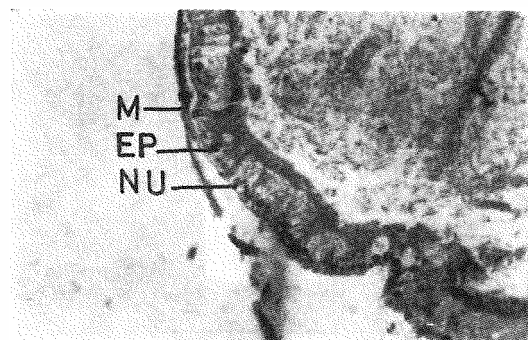


Fig. 9. Control. T. S. of rectum showing muscles, epithelium and their nuclei

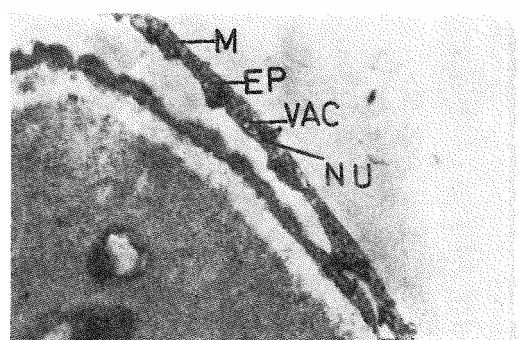


Fig. 10. Phosdrin treatment. T. S. of rectum showing uneven and marked shrinkage of epithelium; and distortion of nuclei

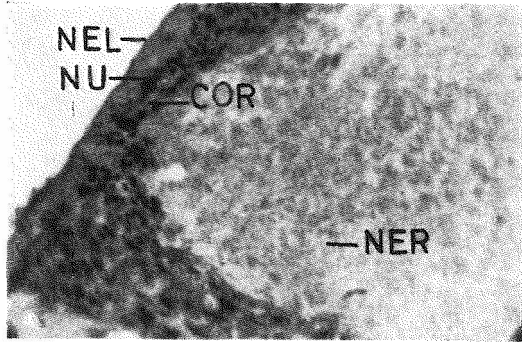


Fig. 11. Control. T. S. of brain showing neurilemma, cortex, nuclei and neurospongium

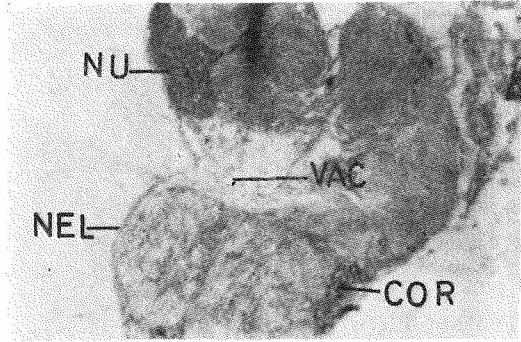


Fig. 12. Phosdrin treatment. T. S. of brain showing vacuolation in cortex and neurospongium and distortion of nuclei

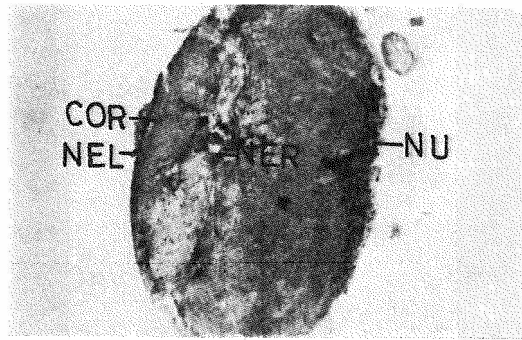

Fig. 13. Control. T. S. of thoracic ganglion showing neurilemma, cortex, nuclei, and neurospongium

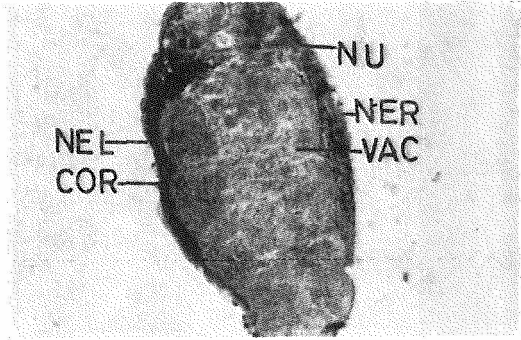


Fig. 14. DDT treatment. T. S. of thoracic ganglion showing vacuolation in cortex and neurospongium; and distortion in nuclei

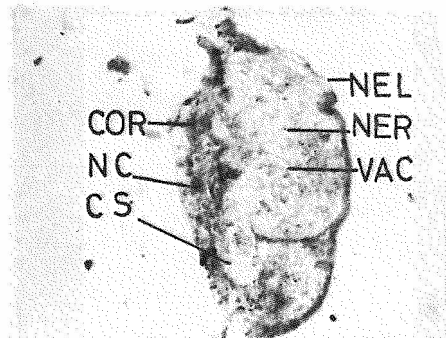


Fig. 15. Phosdrin treatment. T. S. of thoracic ganglion showing vacuolation in cortex and neurospongium, and distortion of nuclei

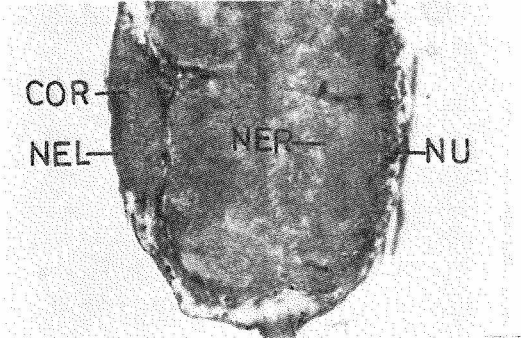


Fig. 16. Control. T. S. of thoracic - abdominal ganglion showing neurilemma, cortex, nuclei and neurospongium

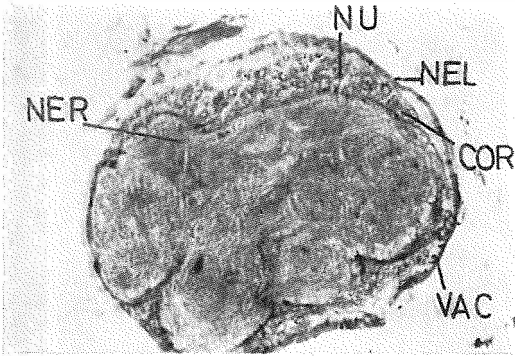


Fig. 17. DDT treatment. T. S. of thoraco-abdominal ganglion showing acute vacuolation in neurospongium

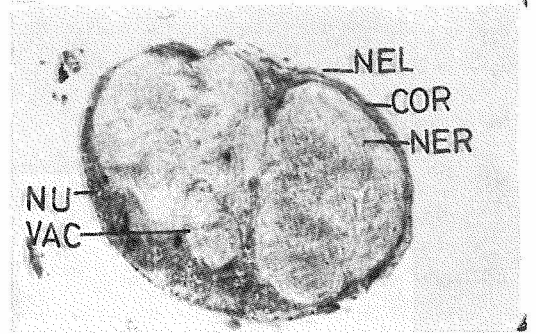


Fig. 18. Dimecron treatment. T. S. of thoraco-abdominal ganglion showing vacuolation in cortex and neurospongium, and distortion nuclei

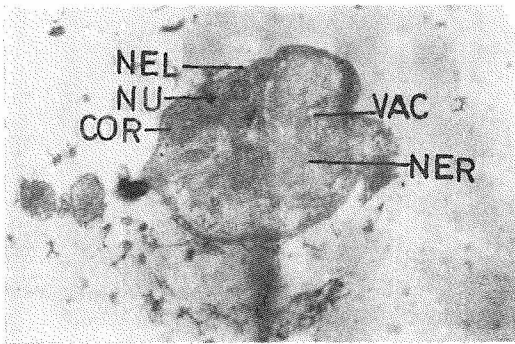


Fig. 19. Phosdrin treatment. T. S. of thoraco-abdominal ganglion showing acute vacuolation in cortex and neurospongium, and distortion of nuclei

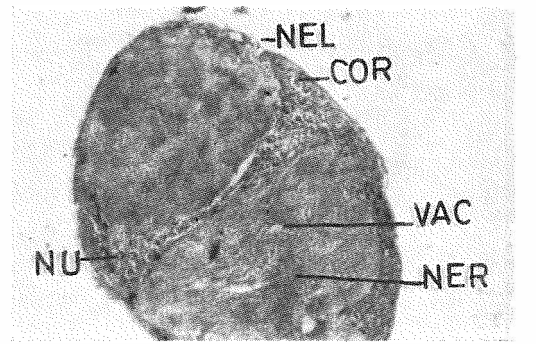


Fig. 20. Sevin treatment. T. S. of thoraco-abdominal ganglion showing vacuolation in cortex and neurospongium

ZOBODAT - www.zobodat.at

Zoologisch-Botanische Datenbank/Zoological-Botanical Database

Digitale Literatur/Digital Literature

Zeitschrift/Journal: [Beiträge zur Entomologie = Contributions to Entomology](#)

Jahr/Year: 1968

Band/Volume: [18](#)

Autor(en)/Author(s): Sharma Ved Parkash

Artikel/Article: [Induced pathology of certain insecticides in *Dysdercus koenigi* Fabricius. 703-710](#)