

# **Total Management of the Cleft Palate Child**

**Plastic Surgery Seminar Series  
University of Toronto  
November 2006  
Glyka Martou**

**Discussors:** Dr. Oley Antonyshyn  
Dr. David Fisher

## Table of Contents

<b>Introduction.....</b>	<b>3</b>
<b>Definitions.....</b>	<b>3</b>
<b>Epidemiology.....</b>	<b>3</b>
<b>Embryology.....</b>	<b>4</b>
<b>Normal Anatomy.....</b>	<b>6</b>
<b>Abnormal Anatomy in Cleft Palate.....</b>	<b>8</b>
<b>Classification systems.....</b>	<b>9</b>
<b>Aetiology.....</b>	<b>12</b>
<b>Multidisciplinary Team Approach.....</b>	<b>13</b>
<b>Issues to address with parents.....</b>	<b>14</b>
<b>Genetic Counseling.....</b>	<b>15</b>
<b>Psychological Issues.....</b>	<b>17</b>
<b>Surgical Repair of Cleft Palate.....</b>	<b>17</b>
<b>Palatal Fistula.....</b>	<b>21</b>
<b>Speech and Language in Cleft Palate Child.....</b>	<b>22</b>
<b>Velopharyngeal Insufficiency.....</b>	<b>23</b>
<b>Management of Alveolar Clefts.....</b>	<b>27</b>
<b>Orthodontics for the Cleft Palate Child.....</b>	<b>29</b>
<b>Orthognathic Surgery in Cleft Palate Child.....</b>	<b>30</b>
<b>Special Scenarios.....</b>	<b>31</b>
<b>References.....</b>	<b>32</b>

## Introduction:

This seminar deals with the major aspects of care (psychological/medical/surgical) of the child with cleft palate (CP) deformity. While the association with cleft lip is referred to in several areas, the surgical management focuses on CP.

## Definitions:

- § **Cleft Palate:** failure of the two palatal shelves to join in the midline and fuse; the cleft may involve the soft palate alone or both the soft and hard palate.
- § **Incisive foramen:** site where the lateral maxillary bones meet the midline premaxilla
- § **Premaxilla:** the alveolar segment of the maxilla that includes the nasal spine and four incisor teeth; located centrally and anterior to the incisive foramen
- § **Primary palate (prepalatal):** structures anterior to the incisive foramen, including nasal tip cartilages, nasal floor, lip and alveolus
- § **Secondary palate (palatal):** structures posterior to the incisive foramen including hard, soft palate and uvula

## Abbreviations:

- § **CP:** isolated cleft palate
- § **CL:** isolated cleft lip
- § **CL/P or CL(P):** cleft lip ± cleft palate

## Epidemiology

- § Overall orofacial clefts are the most common craniofacial birth defect (1:750 in live births; 3x more common in stillbirths and abortions)
- § **Incidence of CP:** overall: 1 in 2000 (live births)  
**F:M 2:1**  
Constant ratio of 0.4 -0.5 in 1000
- § **Incidence of CL/P:** overall: 1 in 1000  
**M:F 2:1**  
Native Americas 3.6 in 1000  
Asians: 2.1 in 1000  
Caucasians: 1 in 1000  
Blacks: 0.3 in 1000

Take-home messages:

- § Racial variation: CL/P > CP
- § The distribution of types of clefting expected in a cleft palate population is:
  - CL (15-20%); CL/P (50%); CP (30-35%)
- § Unilateral CL/P is the most common combination
  - L:R:Bilateral = 6:3:1
  - M > F
- § Most common cleft bifid uvula (2% pop); most are asymptomatic but up to 20% of patients may have some degree of velopharyngeal incompetence
- § Next most common: left unilateral complete cleft lip and palate

## Embryology

- § Palatogenesis (primary and secondary palate): wk 4-12
- § Involves 3 of the 5 embryonic facial primordia (Fig 1):
  - **Frontonasal prominence:** primary palate, forehead, supraorbital ridges, nose, philtrum
  - **Left and right maxillary prominences:** secondary palate, maxilla, zygomatic arches, lateral lip
- § Overall involves complex interaction of cell growth, differentiation and migration
- § For the secondary palate these processes occur b/w 7<sup>th</sup> and 12<sup>th</sup> week and differ significantly from those involved in the earlier development of the lip
- § **Secondary palate (hard and soft)**
  - 3 stages:
    - 1) Growth:** formation of the palatal shelves (proliferation and migration of mesenchymal cells) as medial extensions of the maxillary processes (1<sup>st</sup> branchial arch); initially shelves lie vertically by the tongue sides (FGF8 and SHH involved in growth and elevation); Figure 2
    - 2) Elevation:** with growth, the head extends and tongue drops downward, first posteriorly; shelves swing to horizontal position (posterior to anterior direction); proposed mechanisms include change in shelf vascularity, increased tissue fluid pressure and turgor, extra-cellular fluid accumulation (TGF-B), contractile elements and cranial base growth; right shelf becomes horizontal before left (Figure 2)
      - ü for the soft palate, it is proposed that this phase of elevation is more a phase of re-modelling (see Figure 3)
    - 3) Fusion:** true fusion of palatal shelves to each other (TGF-beta3 and N-cadherin):
      - ü 4 events: epithelial contact, epithelial adhesion, epithelial apoptosis, mesenchymal replacement of midline seams (incisive fissure, and midpalatal suture represent lines of fusion)
      - ü fusion begins initially at 1/3 of the way posteriorly (hard palate), then proceeds up to the incisive foramen and then back to the uvula (may explain rare incidence of congenital fistula/epithelial cyst of anterior hard palate)
- Intra-membranous ossification of the hard palate proceeds from the lateral palatal shelves and the premaxilla during 8<sup>th</sup> wk.
- Myogenic mesenchymal tissue from 1<sup>st</sup> and 4<sup>th</sup> pharyngeal arches migrates into the soft palate and fauces accounting for multiple innervation of regional musculature.

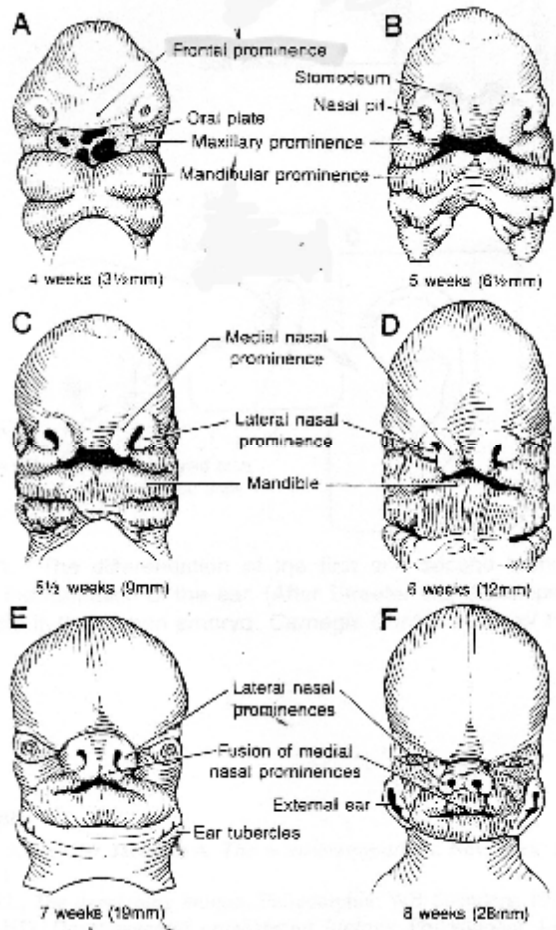


Figure 1. Development of the face

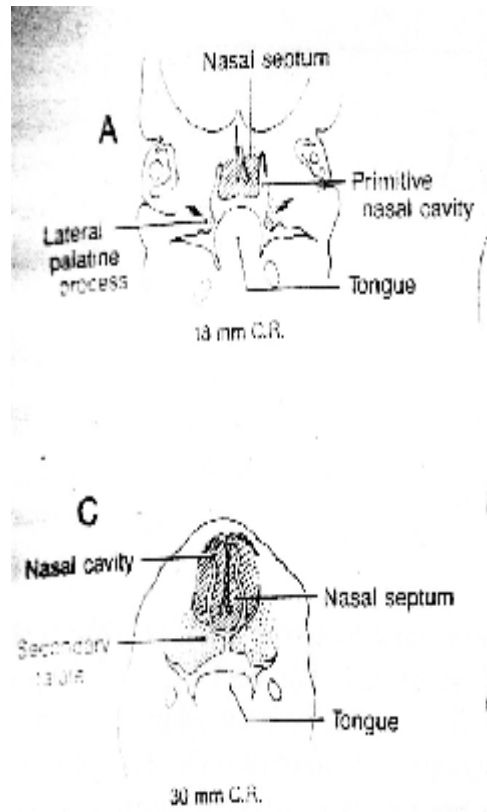


Figure 2. Development of secondary palate

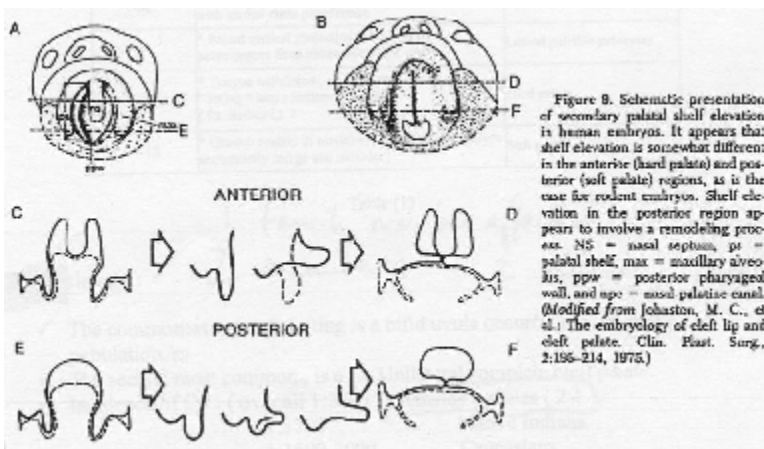


Figure 3. Elevation Vs. Remodeling for soft palate development

**Table 1. Timing of events in the development of the secondary palate**

Week	Occurrence	Formation
4	* Medial and lateral nasal prominences form from the frontonasal process	Nares
4-6	* Maxillary prominence grows medially to merge with medial nasal prominence	Upper lip and primary palate.
6	* Paired vertical projections of maxillary prominences from either side of the tongue	Lateral palatine processes
7	* Tongue withdraws , palatine process " swing " into a horizontal position ( Rt. Before l.t. )	Hard palate .
7-12	* Growth centers in caudal end of the palatal shelves sequentially merge and remodel .	Soft palate .

**Pathogenesis of the secondary palate**

- Clefting of the secondary palate results from:
  - Failure of elevation/contact/adhesion
    - insufficient mesoderm (reduction in shelf size) and delayed migration in the palatal shelf
    - abnormal craniofacial morphology, delayed achievement of mandibular prominence, head extension, increased tongue obstruction (Pierre Robin sequence)
  - Failure of fusion (different degrees result in complete Vs. incomplete clefts)
  - **Wide clefts** secondary to shelves remaining vertical; **narrow clefts** usually indicate elevated shelves that failed to contact/fuse or that failed to fuse even if contact was made

**Normal Anatomy**

**Hard Palate:**

- extends from incisive foramen (nasopalatine canal) to post. nasal spine (PNS)
- includes palatine bones, palatine process of maxilla, nasal and oral mucosa
- represents a static barrier between oral and nasal cavities
- **Artery:** greater palatine a. (br. of maxillary)
- **Nerve:** greater and lesser palatine n. (sensory fibers of maxillary n. via pterygopalatine ganglion)

**Soft palate:**

- extends from PNS to tip of uvula
- muscles sandwiched between oral and nasal mucosa
- acts in concert with superior pharyngeal constrictor to act as dynamic valve for separation of nasopharynx from oropharynx
- **Artery:** ascending palatine a. of facial a.; ascending pharyngeal a. of ext. carotid
- **Nerve:** motor: pharyngeal plexus (X, XI)  
sensory: lesser palatine V2 and IX

**Superior Pharyngeal Constrictor:**

- **Origin:** posterior pharyngeal raphe at cranial base
- **Insertion:** lateral pterygoid plate, hamulus, pterygomandibular raphe
- **Nerve:** pharyngeal plexus

**Table 2. Muscles of the Soft Palate**

Muscle	Origin	Insertion	Nerve supply	Function
1) Tensor Veli Palatini	* Spine of the sphenoid * Scaphoid fossa * Lateral side of auditory tube	* Around pterygoid hamulus to palatine aponeurosis.	* V3 , nerve to medial pterygoid muscle	* stabilizes ant. Soft palate and required for normal Eustachian tube opening .
2) Levator palatini	* Undersurface of the temporal bone . * Medial auditory canal	* Medial palatal aponeurosis .	* pharyngeal plexus .	* Creates a sling to pull superiorly and posteriorly on the soft palate . * May aid in lateral pharyngeal motion .
3) Palatopharyngeus ( longitudinal and circular portions )	* Post. Border of hard palate * Palatine aponeurosis.	* Via the posterior Tonsillar pillar to it fans out into a lateral and post. Pharyngeal wall , interweave with superior constrictor fibers .	* pharyngeal plexus .	* Pulls the wall of the pharynx superiorly * Depresses the soft palate .
4) Palatoglossus	* Undersurface of the palatine aponeurosis.	* Via anterior tonsillar pillar to the side of the tongue	* Pharyngeal plexus .	* Pulls the root of the tongue superior and posterior and narrows the palatoglossal arch .
5) Musculus Uvulae	* Posterior border of the hard palate & PNS . * Palatine aponeurosis	* Mucous membrane of the uvula ,	* Pharyngeal plexus .	* Provides bulk . * Pulls up the uvula . * Produces the levator eminentiae .

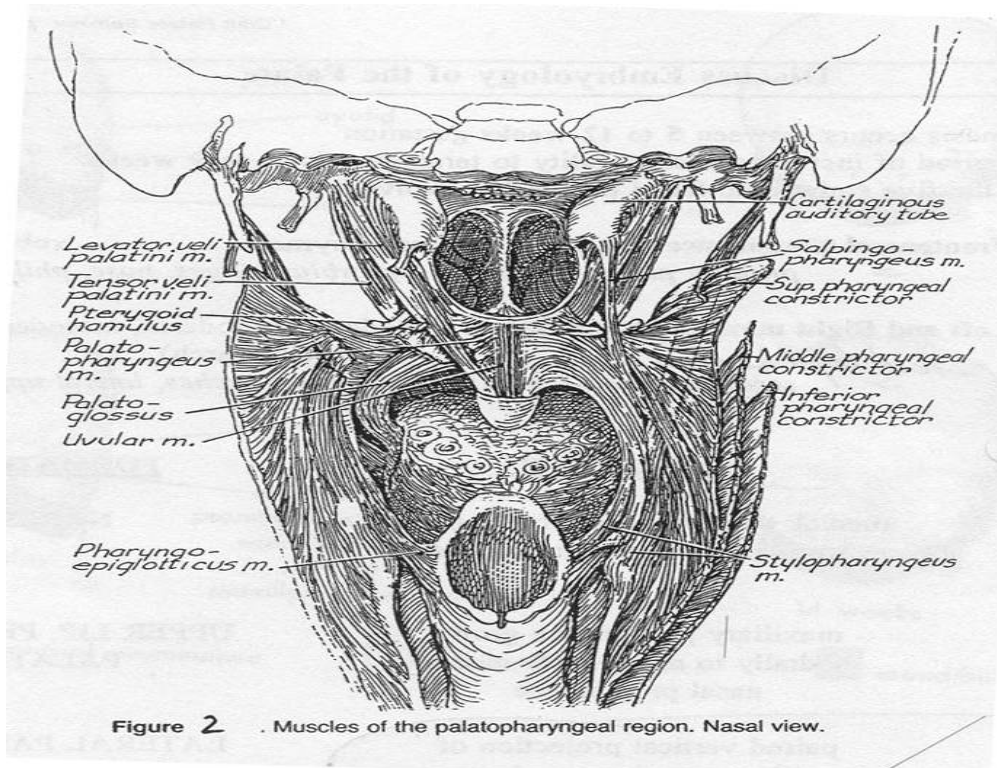


Figure 2 . Muscles of the palatopharyngeal region. Nasal view.

#### Figure 4. Musculature of the soft palate

##### Abnormal Anatomy in Cleft Palate

###### 1) Bone:

- failure of fusion of vomer and palatine shelves
- variable degree of bone and soft tissue loss
- in unilateral cleft of primary and secondary palate, vomer usually attached to palatal shelf on non-cleft side for its entire length
- in bilateral cleft or isolated cleft of secondary palate, vomer usually unattached laterally

###### 2) Muscle:

- levator palatini:**
- more longitudinal vs the normal inferior, medial, anterior
  - attaches to posterior edge of ipsilateral hard palate and medial edge of cleft
  - isometric contraction leads to hypertrophy
- tensor veli palatini:**
- hypoplastic
  - insert on post. edge of ipsilateral palatine bone
  - remains attached to pterygoid and buccal fascia
- palatopharyngeus:**
- longitudinal fibers join levator veli and palatoglossus fibers on ipsilateral side to form Veau's "cleft muscle"
  - circular fibers hypertrophy and contribute to Passavant's ridge
- palatoglossus:**
- becomes more slender than palatopharyngeus



### 3) Fascia:

- no palatal aponeurosis on cleft side

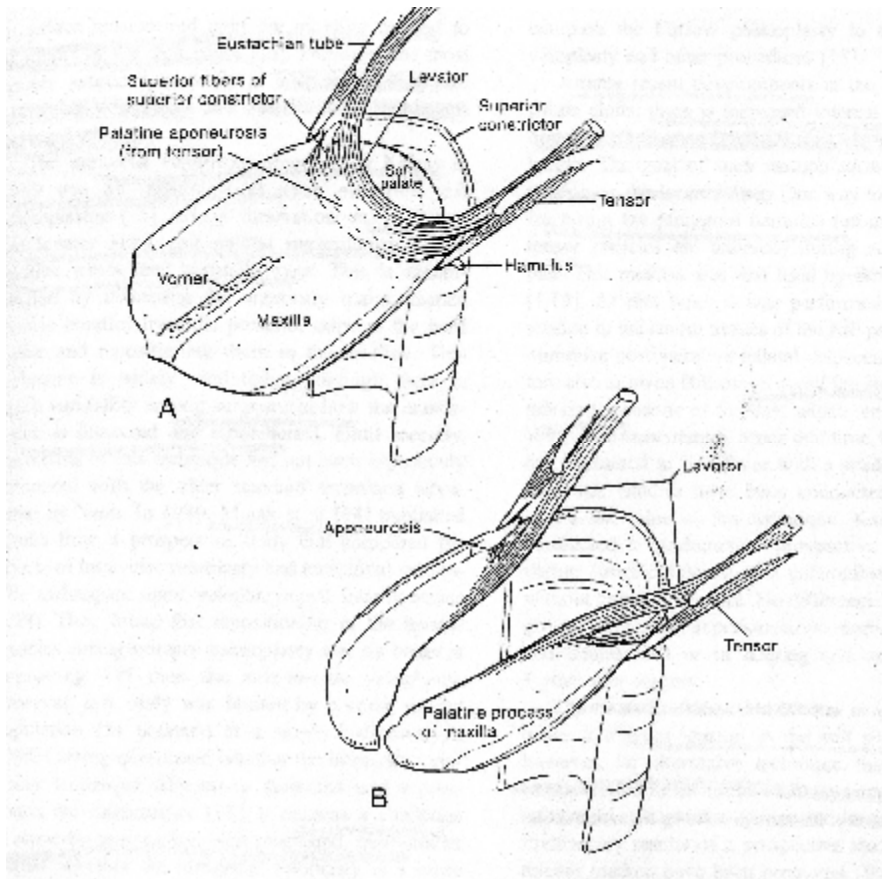
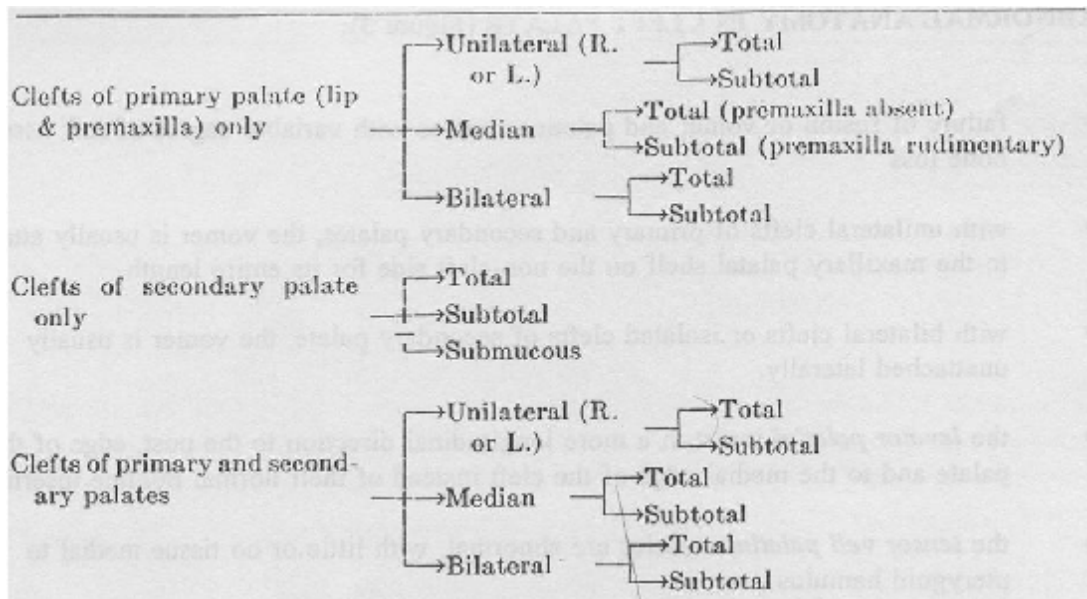


Figure 5. Abnormal anatomy in cleft palate

### Classification

#### 1) Anatomic (Kernahan and Stark 1958)

- 1<sup>st</sup> to use incisive foramen as dividing point
- basis for international classification



**Figure 6. Anatomic Classification of CL/P and CP**

**INTERNATIONALLY APPROVED CLASSIFICATION**

The subcommittee on cleft lip and palate nomenclature of the International Confederation for Plastic and Reconstructive Surgery announced in the newsletter following the 1967 Rome Congress the official Confederation cleft classification.

*Classification of Clefts of the Lip, Alveolus and Palate (classification based on embryological principles)*

Group 1: Clefts of anterior (primary) palate:

- (a) Lip: right and/or left.
- (b) Alveolus: right and/or left.

Group 2: Clefts of anterior and posterior (primary and secondary) palate:

- (a) Lip: right and/or left.
- (b) Alveolus: right and/or left.
- (c) Hard palate: right and/or left.

Group 3: Clefts of posterior (secondary) palate:

- (a) Hard palate: right and/or left.
- (b) Soft palate: medial.

(For further subdivisions the terms "total" and "partial" should be used.)

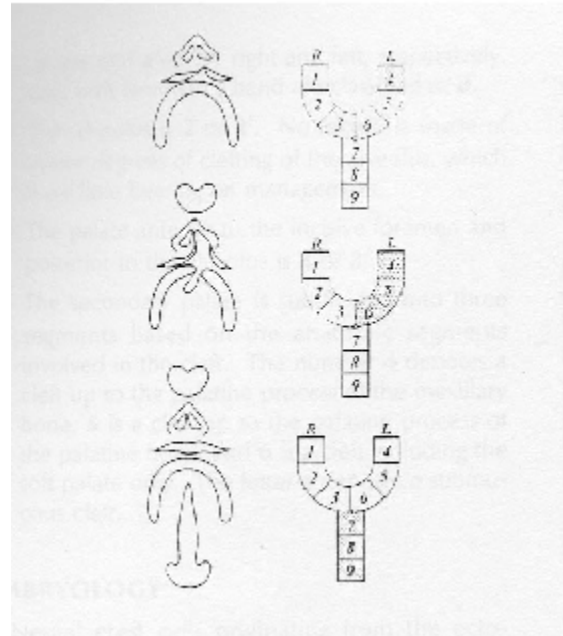
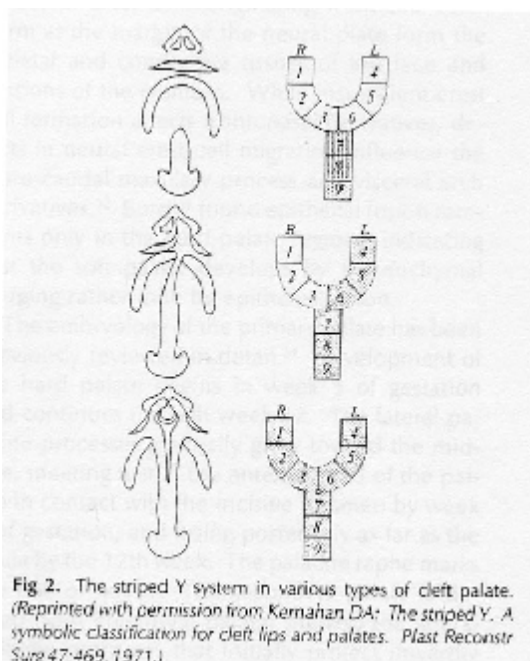
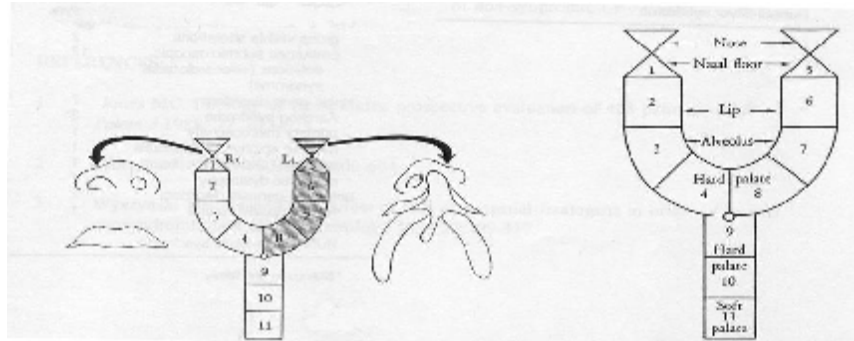
*Rare Facial Clefts*

(classification based on topographical findings)

- (a) Median clefts of upper lip with or without hypoplasia or aplasia of premaxilla.
- (b) Oblique clefts (oro-orbital).
- (c) Transverse clefts (oro-audicular).
- (d) Clefts of lower lip, nose and other very rare clefts

## 2) Symbolic “Y”

- 1<sup>st</sup> described by Kernahan (modified by others, including Millard)
- Stippling signifies a cleft and crosshatching indicates a submucous cleft



**Figure 7. Classification of CL/P**

## 3) Syndromic Vs. Non-syndromic (from an aetiologic perspective)

- **Syndromic:** more than 1 malformation complexes, involving more than 1 developmental field
  - 300 syndromes with some degree or type of orofacial clefting
  - 30 genes identified
  - **40% of CP and 15% of CL/P**
- **Non-syndromic:** single malformation complex involving multiple anomalies but limited to single developmental field
  - **60 % of CP and 85% of CL/P**

- **CL/P genetically different than CP**

### **Aetiology**

- **Embryological**
  - Unusually wide faces (Asian); tongue tie; macroglossia; small mandible; oligohydramnios
- **Chromosomal**
  - Trisomies, duplications, micro-deletions
  - Micro deletions of 22q11.2 responsible for 3 syndromes with CP (Di George, Velocardiofacial and Conotruncal anomaly face syndrome)
- **Syndromic (see Table 3)**
  - Also Fetal Alcohol Syndrome, Accutane dysmorphic syndrome
- **Non-syndromic (i.e., multi-factorial)**
  - Contribution of genes (20-50%) and environment; combination determines if threshold for deformity reached
- **Environmental**
  - Teratogens (non-syndromic):
    - Anti-convulsants (dilatant), steroids, diazepam, aminotrepin
  - Evidence for increased risk with smoking inconsistent
  - Nutrition (folate deficiency and retinoic acid excess); maternal factor
  - Illness during pregnancy (rubella, toxoplasmosis)

### **Table 3. Syndromes associated with CP**

Syndromes commonly associated with cleft palate

Syndromes	Clinical findings
Stickler	Pierre-Robin sequence, ocular malformations (progressive myopia, retinal detachment, secondary glaucoma, cataracts), hearing loss, and arthropathies
Velo-cardio-facial	Cardiovascular abnormalities (tetralogy of Fallot, ventricular septal defect, right-sided aortic arch, aberrant subclavian veins, tortuous and medially-displaced carotid arteries); abnormal facies (long face with maxillary excess and malar flatness, hypoplastic alar cartilages and thin upper lip with long philtrum); characteristic 22q11 "Catch 22" chromosomal deletion
Van der Woude Goldenhaar	Facial clefting, lower lip paramedian sinuses Ocular dermoid/coloboma, ear tags/atresia, facial hypoplasia, kidney/vertebral anomalies; mental retardation
Treacher-Collins	Lower eyelid colobomas, down-slanting palpebral fissures, hypoplastic zygomatic arch, low-set ears
Ectrodactyly-ectodermal dysplasia-clefting	Lobster-claw anomaly of all four extremities, typically bilateral cleft lip/palate
Oro-facial-digital	Oral clefting (lip, tongue, palate), mandibular hypoplasia, mental retardation

**Management of the CP child**

**Multidisciplinary Team Approach**

- CP, CL/P should be managed by teams with referral rate >30 new cases/yr
- **Justification:** early institution of neonatal care, may have associated multi-system anomalies, cleft has effect on number of facial structures/functions, requires multiple surgical procedures at different life stages
- **Composition** of team: at least one plastic/craniofacial surgeon, ENT, pediatrician, ophthalmologist, orthodontist, pediatric dentist, prosthodontist, audiologist, SLP, geneticist, social worker, clinical psychologist/psychiatrist, nursing staff experienced in cleft palate patients, clinical co-ordinator
- **Timing (HSC protocol): See Table 4 below**

1	antenatal care	prenatal care, genetic counselling
2	1 <sup>st</sup> evaluation (birth-4wks)	airway management, medical exam, feeding assessment, orthodontic assessment, family counselling, genetic

		counselling
3	primary lip ± nose	3-6 months
4	ENT	9 mo → pre-palate surgery
5	palate ± tubes	12-18 mo
6	speech evaluations	2.5 yrs → normal
7	± VPI surgery	5-6 yrs
8	± secondary lip/nose	5-6yrs
9	alveolar bone graft	9-11 yrs
10	orthodontia	mixed and permanent dentition
11	orthognathic ± secondary rhinoplasty	F>16, M>18yrs

No standard protocols exist. There is a variety of protocols used by different centers. Some of the trends noted following a survey done by Weinfeld et al (2004), (258 centers; response rate 55%):

- 60% of the centers use pre-operative orthopedic appliances (passive NAM > Latham)
- 43% of centres report lip adhesion but on small number of patients (10%)
- Indications included the following:
  - Wide cleft
  - Poor compliance with appliance
  - Prominent maxilla
  - Bilateral cleft
  - No appliance available
- Lip adhesion is becoming less popular.
- **For unilateral CL:** 66% of centres perform definitive repair b/w 3-6mo; most popular technique is the Millard rotation-advancement or some modification of it (the Mulliken technique most popular) followed by the straight line/Triangle flap
- Alar repositioning is done at the time of lip repair (88%); if not, it was done at 4-5yr. Age of septal maturity was reported at 14.4yr (M) and 13.4yr (F)
- **CP repair:** most popular technique is the Furlow Z-plasty; definite shift from push back techniques
- Speech therapy is started at an average age of 24mo; dx of VPI via nasopharyngoscopy (80%) and videofluoroscopy (20%); 80% of the surgeons reported the lateral wall motion being the single most determinant factor for surgical planning; minimum age for surgical correction reported at 4yr with palatoplasty used more frequently (65.5%) to pharyngeal flaps (34.5%)
- Myringotomy tubes placed at < 12mo (most at the same time as lip repair)

**Issues to address with the parents once a child with CP is born:**

- Feeding
- Maintenance of airway
- Middle ear disease
- Possibility of other abnormalities (syndromic Vs. non-syndromic)

- Sequelae of an unrepaired CP
- Treatment plan

### **Feeding**

- Challenging given inability of the baby to develop suction but swallowing is normal in most cases; weight gain must be closely monitored
- Hold baby head up at 45 degrees above the horizontal so that milk flows to the back of the mouth
- Use of a squeezable bottle with a preemie nipple that has additional cross-cuts in the end; avoid squeezing excessively (can cause choking)
- May breast-feed post-operatively but ensure baby is gaining weight
- Feeding takes longer and burping should be done more frequently
- Expect some degree of nasal regurgitation (pre-operatively)

### **Airway management**

- More of an issue in the presence of retrognathia/glossoptosis/CP (Pierre Robin)
- Conservative approach (appropriate feeding and positioning (prone))
- Surgical approaches (Denny, 2004)

### **Middle ear disease**

- Overall higher incidence of otitis media and/or hearing loss in CP patients with possible detrimental effect on speech development; ENT consult
- Close physiological relationship b/w tensor veli palatini, tensor tympani and auditory tube; interference with pressure equalization
- Rx with early myringotomy and silastic or grommet tube placement to aerate through the eardrum

### **Other congenital anomalies**

- In as many as 30-50% of CP cases
- Complete Hx (focus on pregnancy and family Hx) and PE with accompanying blood work
- High among associated anomalies are those affecting the circulator and skeletal systems

### **Sequelae of an unrepaired CP**

- Residual deformities in facial growth
- Speech problems

### **FAQ from parents**

- Is there a known cause?
- Could the condition have been prevented?
- What is the chance of a cleft occurring in future pregnancies?
- What and when can it be done for the deformity?
- Will the child be able to speak correctly?

These should be answered simply, directly, honestly and above all reassuringly (See psychological issues).

### **Genetic Counseling**

- Defined as “a communicative process which deals with the human problems associated with the occurrence, or risk of occurrence of a genetic disorder in a family”
- **For isolated CP:**
  - § mode of inheritance still unclear but data suggesting a recessive single major gene model
- Proposed oligogenic model with several interacting loci seems to fit data best
  - § Non-syndromic CP might consist of 2 etiologic subtypes: CP affecting soft palate only, and CP affecting both hard and soft palate
  - § Genes implicated thus far as playing a possible role: TGF-alpha, retinoic acid receptor gene, allelic variants of TGF-B and MSX1, subunit of GABA receptor, endothelin-1 gene and endothelin receptor gene
- Direct DNA diagnosis for single gene non-syndromic defects has shown linkage to locus on chrom. 6 and 19
- **Hx:** exposure to teratogens, gestational hx, FHx and consanguinity
- **P/E:** look for other anomalies/malformations
- If syndromic and not well defined syndrome (no known chromosomal anomaly), proceed with karyotype testing (will be positive in 15% CL/P, CP syndromes)
- From FHx can suspect mendelian syndromes and mode of transmission (present in 19% of CL/P, 30% CP; most are AD with variable penetrance)

### **Predicted Recurrence**

Affected relatives	CL(P)	CP
1 sibling	4.4	2.5
1 parent	3.2	6.8
1 sibling and 1 parent	15.8	14.9

### **Prenatal care for subsequent pregnancies:**

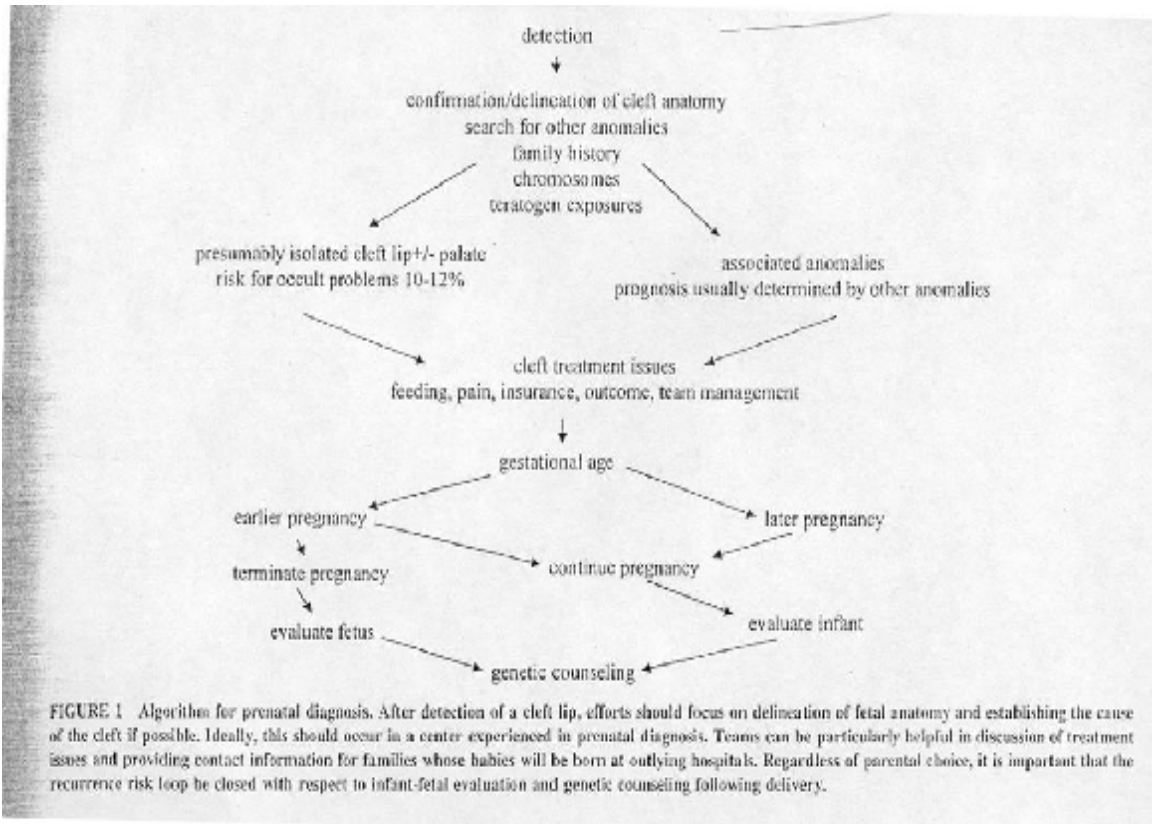
- If syndromic cytogenetic anomaly: consider amniocentesis or chorionic villi sampling
- If teratogen: avoid repeat exposure
- If Dx single gene mendelian disorder with known probe: DNA analysis

### **Role of U/S:**

- Fetal lip and nose can be visualized at 15wks (3.5MHz scanner); fetal face and palate can be seen at 12wks with a 6.5MHz transvaginal scanner
- Reported detection rates vary: CL/P (20-40%) > CL (25%) > CP (1.4%)
- Controversy regarding what to do with the information



- One obvious benefit is early contact with Cleft Team for information gathering, genetic counselling, and preparing for baby's special needs
- **Algorithm by Jones (2001), Figure 8**



### Psychological Issues

- Family adaptation, appearance, self-esteem, social interaction, emotional and behavioral adjustment and cognitive functioning
- Plastic surgeon in a unique position; first knowledgeable person about the condition; his/her attitude can shape that of the family and patient
- Parental adjustment
  - Coping with feelings of shock, loss, grief, worry, guilt
  - Referral to CL/P team and support network (<http://www.cleftline.org>, <http://www.aboutfaceusa.org>)
  - Early encouragement to think of their baby as normal, with potential for contributions to family and society, thus, helping them develop a positive mind-set
- Treatment issues
  - Confusion as parents realize that there are different approaches, they often feel the need to become experts so as to make the right decision
  - Explain that “many paths can lead to the same outcome”; outline the treatment plan (timing and frequency of surgical interventions); issues with speech, residual deformities

- Allow parents and patient (as he/she getting older) to be involved in the planning
- Warn the parents for potential learning disabilities, importance of individual personality/attitude of patient (tendency to blame their appearance for problems in their lives)
- Recognize the time a formal psychological/psychiatric intervention is needed.

### **Surgical Repair of Cleft Palate (Sadove et al., 2004)**

Two factors must be considered in CP surgery:

- Speech production
- Facial growth

when considering:

- Timing of operation
- Technique used (surgeon's preference, competence)

It is generally accepted that early palatal surgery results in a more normal speech pattern whereas it has potentially inhibitory effects on facial growth patterns.

In the view of Nguyen and Sullivan (1993):

“Normal speech should be the most important consideration in the therapeutic plan. Growth disturbance should be minimized but not at the expense of speech impairment, because the facial distortion can be satisfactorily managed with further surgery whereas speech impairment can often be irreversible”.

Also important to distinguish b/w CL/P and CP: While alveolar repair can restrict maxillary growth, repair of the isolated cleft palate has no effect on maxillary development (Selective Readings).

The surgical variables include: technique, pre- and post-operative molding of palatal segments, bone grafting of the alveolar cleft.

**Goals** of surgical repair of CP:

- i. Closure of cleft
- ii. Recreation of velopharyngeal sphincter (for normal speech and eating)
- iii. Improve eustachian tube function and decrease otitis media
- iv. Minimize effects on subsequent growth and dento-alveolar deformity

**Timing**

- **Early** (3-9mo)
  - Advantages: fewer speech problems, decreased need for pharyngoplasty
  - Disadvantages: higher risk for post-operative airway problems, technically more difficult

- **Midrange** (9-14mo)
  - Most common timing; followed at HSC (12mo)
  - Combined advantages and disadvantages of /disadvantages of early/late
- **Late** (6-14yrs); often two stage:
  - Closure of soft palate at 6-12 mo with use of obturator
  - Delayed hard palate closure
  - Advantages: Less midface growth disturbances
  - Disadvantages: high rate of speech problems, chronic otitis media and hearing deficits

Timing should not be determined by age but the particular anatomy and functional needs of the patient (additional needs in syndromic patients as well). In most centres, surgical repair is done by the age of 2 but the trend is moving towards a repair before 1yr of age (Sadove et al., 2004).

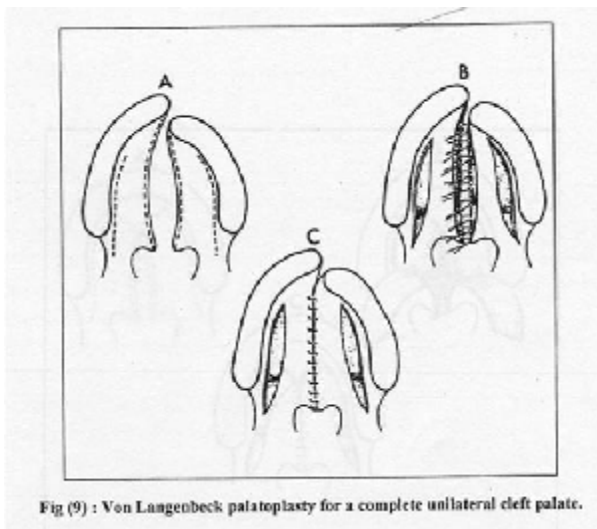
### **Techniques in CP repair**

Numerous techniques since first one described by LeMonnier (1760). One could group CP repairs in two basic types:

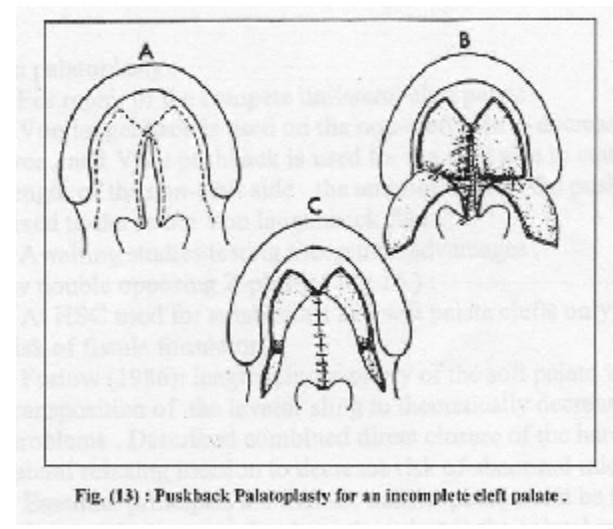
- Those involving primary closure of the entire palate usually with mucoperiosteal flaps
- Those consisting of initial veloplasty followed by subsequent hard palate closure

Most are modifications of 3 main designs (see figures):

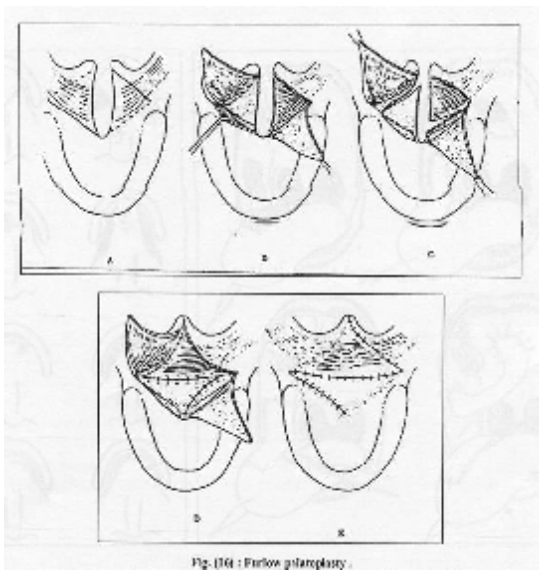
- **Von Langenbeck procedure (Figure 9)**
  - Simple closure; no attempt to lengthen the palate; criticism over inferior speech results
  - Multiple modifications (lateral and medial relaxing incisions)
- **Veau-Wardill-Kilner (Figure 10)**
  - V-Y advancement of the hard palate mucoperiosteum; designed to lengthen but as a result denuded bone that scars and contributes to subsequent maxillary growth disturbances
- **Double-opposing Z-plasties (Furlow) (Figure 11)**
  - Lengthening of palate; restores normal anatomy; no need for relaxing incisions
  - Problems with wide clefts; can tighten the velum in the transverse axis



**Figure 9. Von Langenbeck method**



**Figure 10. Veau-Wardill-Kilner method**



**Figure 11. Double-opposing Z-plasties**

**Choice of timing and technique according to type of cleft (non-syndromic) (Sadove et al., 2004):**

**Incomplete cleft of soft palate**

- Primary goal is to restore velopharyngeal competence which is achieved by lengthening the palate, properly apposing the palate and posterior pharyngeal wall and re-organizing the palatal musculature
- Techniques mostly carried out currently
  - Intra-velar veloplasty (Krien's technique to restore the sling and musculature at the midline)

- Furlow double-opposing Z-plasty (veloplasty of choice)
- Additional developments:
  - May have to use a pushback technique from the hard palate mucoperiosteum or lateral relaxing incisions in the soft palate to appose the edges
  - Alternative methods to gain tissue and length include fracturing the hamulus, tensor veli palatini tendon release or uvular transposition

### **Incomplete cleft of soft and hard palate**

- Goals in this repair are to realign the soft palate mucosa and musculature as well as to close the bony gap b/w edges of the hard palate to restore structural integrity and maintain growth
- Techniques used:
  - Von Langenbeck palatoplasty (with medial or lateral relaxing incisions)
  - Veau-Wardill-Kilner palatoplasty
  - Two flap palatoplasty (Baldach and Salyer; See Selective Readings)
- Pairing the above techniques with intra-vela palatoplasty/Furlow palatoplasty to minimize extent of mucoperiosteal undermining is common

### **Complete CP (primary and secondary)**

- Challenge because of the width and involvement of clefts in the lip and alveolus
- Two-flap palatoplasty for unilateral cases
- Two-flap palatoplasty with a vomer flap for bilateral cases (See Appendix)
- Bilateral buccal flaps with a Furlow repair (useful in gaining palatal length in wide clefts and provide better tissue coverage of denuded palate than previous methods (palatal island flap)

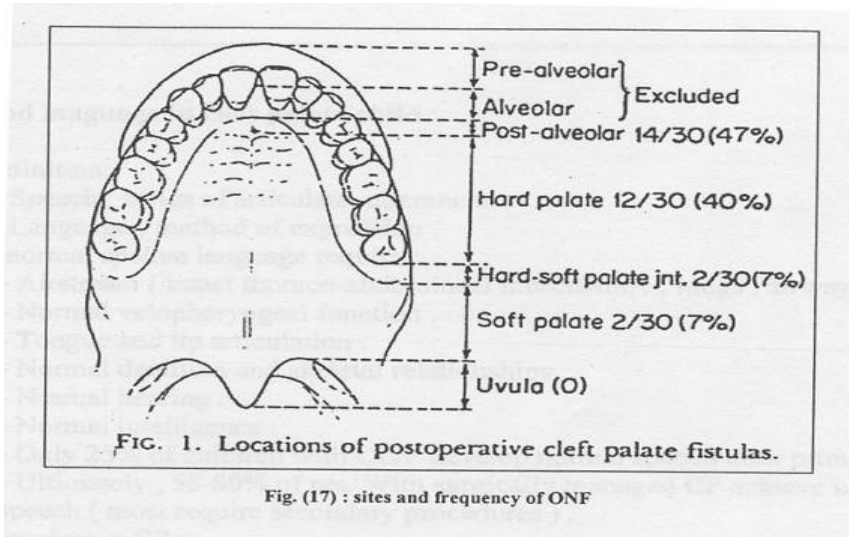
### **Complications**

- **Early**
  - Hemorrhage (V-W-K technique)
  - Respiratory obstruction (Von Langenbeck)
  - Flap dehiscence
  - Infection (oropharyngeal, upper respiratory, otitis media); <5%
  - Mortality (0.5%)
- **Late**
  - Palatal fistula
  - VPI (Velopharyngeal incompetence)

### **Palatal Fistula**

- Defined as persistent communication b/w oral and nasal cavity
- Can present as nasal air emission, nasal regurgitation, chronic crusting
- Great range in reported incidence between different centres (generally 5%, less at HSC)
- **Aetiology**

- May be in region of palate not yet repaired (eg. alveolus)
- May be post-operative due to poor technique, trauma, infection, hematoma
- Severity of the cleft is a determinant
  - § Bilateral CL/P (60%) > unilateral CLP (26%) > CP (15%)



**Figure 12. Sites of palatal fistulas**

### Treatment

- Issues with respect to which fistulas require operative intervention and when to repair them
- Even small anterior buccal fistulas can have large underlying bony defects
- Even in the presence of an obturator, in the case of pre-alveolar fistulas, inadequate seal
- Fistulas can reduce lateral wall motion significantly
- Closure advocated after orthodontic arch alignment
- Methods depend on size and location:
  - **Non-surgical** (obturators)
  - **Surgical**
    - § Tension free 2 layer closure
    - § Local palatal mucoperiosteal flap
    - § Local tongue flap (anteriorly or posteriorly based)
    - § Buccal flap
    - § Bone grafting (iliac crest)
    - § Free flap (radial forearm)

### Speech and Language in Cleft Palate Child

#### Definitions

- Speech: series of articulate utterances

- Language: method of expression

### **Requirements for “normal” speech**

- Airstream (lungs, airway, chest/abdominal musculature)
- Normal velopharyngeal function
  - Defined as ability to appropriately and rapidly open and close the velopharynx during conversation
- Tongue/lip articulation
- Normal dentition and skeletal relationships
- Normal hearing and intelligence (absence of developmental delay)
- 25% of children with CL/P develop normal speech after primary surgery; ultimately 55-80% with speech therapy +/- secondary surgeries ?

### **Disorders in CP (also seen in VPI)**

- Hypernasality: lack of separation b/w oral and nasal cavities
- Difficulty pronouncing pressure consonants and development of compensatory articulations (glottal/pharyngeal articulations)
- Imprecise tongue and lip articulation and placement error
- Nasal emission and turbulence during consonant production

**Pressure consonants:** Fricative consonants: F, V, Th, S, Z, Sh  
 Plosive consonants: P, B, T, D, K, G  
 Affricates: Ch, J

**Nasal consonants:** M, N, Ng

### **Evaluation and Treatment**

- Speech language pathologists play essential role; regular speech evaluations starting the first year of life before any surgery
- Important to distinguish speech abnormality due to CP from other structural problem
- Assessment by audiology to distinguish articulation problems from hearing problems
- Often need w/u for VPI

### **Early evaluation (during infancy)**

- History from parents on speech and swallowing, breathing, nasal regurgitation
- P/E is limited: perceptual (listening for audible nasal emission and hypernasality), mirror holding under the nose to assess for fogging
- This initial assessment often with pediatrician and plastic surgeon to assess overall risk for VPI, need for intense follow up, immediate surgical intervention

### **Evaluation of an older child (Information on Hx)**

- FHx of clefting and VPI
- Adenotonsillectomy or other orofacial/nasal procedures
- Feeding/swallowing problems (nasal regurgitation)
- Speech problems

- Frequent ear infections
- Past/current speech therapy, completion
- Nasal obstruction and associated symptoms (snoring, exercise intolerance, mouth breathing, hyponasal speech, daytime drowsiness, frequent awakenings at night)
- Important to educate and counsel both parents and patients

### **Evaluation of SLP expert**

- Speech (perceptual) assessment
  - Experienced SLP, standardized speech sound articulation testing, oral-nasal resonance balance
  - Provides info on patient's sound development and errors related to VPI/nasal obstruction
- Anatomic evaluation/Physical Exam
  - Intra-oral exam (palatal fistulas, submucous cleft, bifid uvula, contour of hard palate, dentition and occlusal relationships)
- Assessing velopharyngeal closure patterns using instrumentation
  - Endoscopy, radiography

### **Velopharyngeal Insufficiency/Incompetency/Inadequacy/Dysfunction**

- Defined as inadequate closure/opening of velopharyngeal valve during speech, breathing
- **Boundaries of Velopharynx:** anteriorly the soft palate (velum), posteriorly the posterior pharyngeal wall and laterally by lateral pharyngeal walls.
- **Velopharyngeal sphincter/valve:** dynamic valve (muscles in the tissues above) that closes for eating and speaking (oral consonants) and opens for breathing and nasal articulations
- **To close:** velum moves posteriorly, posterior pharyngeal wall move ventrally (diffusely or as a well defined ridge (Passavant's ridge) and lateral walls medially
- Adenoids (posteriorly) and pharyngeal tonsils (laterally) may augment or interfere with the function of the valve
- **Incidence:** 10-20% of children affected post-palatoplasty

- **Classification**

- **Structural:** 50-90% of cases
- **Functional:** 7-19%
- **Dynamic:** 15%

- **Symptoms**

- Nasal emission/Hypernasality
- Compensatory speech abnormalities

- § **Primary:** (due to VPI itself)

- Lack of voice projection/articulation



- Speaking with ++ intensity
- § **Secondary:** (due to attempted correction)
  - Glottic stops, pharyngeal stop/fricative/affricate, velar fricative, nasal substitution, etc...
- **Management (History/Physical/Ix)**
  - History
    - § Must be done by experienced SLP with expertise in VPI
    - § Perceptual assessment on spontaneous speech and provocative sample
    - § Q: Does the patient have sufficient articulatory integrity to allow reliable instrumental assessment of the VP sphincter
    - § Important to note that unless there is articulatory integrity for some of the oral consonants, instrumental assessment is unreliable; thus, patient may need speech therapy first before further Ix can be done
    - § P/E (See above)
  - Investigations
    - § Nasometry/ Pressure flow measurements
    - § Flexible nasal endoscopy
    - § Multiview videofluoroscopy
    - § TONAR: oral nasal acoustic ratio

**Table 5: VPI (Causes, mechanism and DDx)**

Cause	Mechanism	Congenital	Acquired
<b>Structural</b>	palatopharyngeal disproportion	short soft palate submucous cleft deep nasopharynx combination of above	repaired cleft palate post tonsil/adenoidectomy tumor ablation post infectious palatal

			slough
	abnormal anatomy of levator veli palatini	cleft palate: uni/bilat complete submucous isolated secondary palate	
	oro-nasal fistula	cleft palate	trauma, iatrogenic, post-palatoplasty
<b>Functional</b>	functional abnormalities	deafness developmental delay	persistent habit mimicry psychoneurosis hearing disorder
<b>Dynamic</b>	palatal paresis (CNS Ø muscle)	cerebral palsy dystonia	meningitis/encephalitis polio botulism ALS polyneuritis
	obstructive/restrictive	hamartomas neurofibromas	tonsillar/adenoid hypertrophy restrictive pharyngeal flap tonsillar pillar scarring
	non-specific	minor coordination problems	

**Table 6. Closure Patterns (See Figure in Appendix):**

<b>Pattern</b>	<b>Morphology</b>	<b>Incidence (N pop.)</b>	<b>Velum contribution</b>	<b>lateral pharyngeal wall contribution</b>
<b>Coronal</b>	horizontal closure of soft palate with PPW	55%	+++	+

	min. LPW movement			
<b>Circular</b>	all structures contribute (sphincter type)	20%	++	++
<b>Circular with Passavant's ridge</b>	some sphincteric action with contribution of PR	15-20%	++	++
<b>Sagittal</b>	vertical closure, medial movement of LPW's, little movement of velum or PPW	10-15% (most commonly seen in pts with persistent VPI after palatoplasty )	+	+++

**Treatment** (all receive speech therapy)

- **Non-operative**
  - Prosthetic appliance to:
    - § Elevate (lift) the velum (palatal lift)
    - § Fill the residual velopharyngeal gap (obturator)
  - Biofeedback techniques
- **Operative**
  - **Lengthen/reconstruct soft palate**
    - § Intravelar veloplasty
    - § V-Y pushback
    - § Furlow palatoplasty
  - **Narrow pharyngeal isthmus**
    - § Superior/inferior based pharyngeal flap
    - § Sphincter pharyngoplasty
    - § Posterior wall augmentation (autogenous (cartilage)/ allogeneic / synthetic implants (injectable collagen, Teflon, Silastic, Proplast, fat and petroleum jelly)

**Pharyngeal Flap**

- Proposed to be best for sagittal closure pattern
- Width: lateral edge should meet lateral excursion of LPW
- Superiorly based: more tissue, easier hemostasis, higher base
- Inferiorly based: technically easier (subjective)

**Sphincter Pharyngoplasty (Hynes, Orticochea, Jackson)**

- Proposed to be best for coronal type closure
- Advantages:

- Soft palate not violated
- Less tethering during later Lefort I advancement
- Secondary adjustments possible

**Timing:** 2-5yrs

**Complications:**

<b>Early:</b>	- post-op bleeding - airway obstruction - aspiration
<b>Late:</b>	- sleep apnea - nasal obstruction - hyponasality - take-down procedure

**HSC Data** (Fraulin 1998) on early complications:

- total rate: 6.3%
- airway obstruction: 3.2%
- bleeding 1.4%

**Note on Velocardiofacial Syndrome** (Shprintzen)

- 9% of those with VPI
- must evaluate for medially displaced carotid pulsations prior to VPI surgery
  - nasoendoscopy, CT, MRA

### **Management of the Alveolar Cleft**

- Alveolar clefts can exhibit a great deal of variability in their extent (mild notch to wide gaping space)
- In unilateral alveolar clefts:
  - The cleft side of the maxilla is referred to as the lesser segment
  - There is lack of transverse stability that can lead to medial collapse which, in turn, results in crossbite of dentition (canine/first premolar)
  - Premaxilla position can vary (normal to anterior projection towards the non-cleft side (application of presurgical orthopedics can correct this)
  - Central incisor is malrotated and angulated towards the cleft
  - Lateral incisor can be hypoplastic/malformed/malpositioned
  - Deficient periodontal attachments
  - Retrusive pyriform rim on cleft side; nasal floor is inferiorly displaced; transverse constriction of anterior bony nasal aperture; overall lack of support in the alar base
- In bilateral alveolar clefts:
  - Can vary in size or be symmetric
  - Anteriorly protruding premaxilla that can have an excessively inferior position and malrotation
- Goals in the treatment of alveolar clefts include:
  - Functional

§ Closure of fistula, creation of a stable and continuous maxillary dental arch, improved support of teeth on the cleft side, allowance for eruption into the cleft side, provision of orthodontic movement, facilitation of oral hygiene

○ Aesthetic

§ Augmentation of the pyriform region and creation of a cosmetically pleasing dental arch form and tooth position; also better support for the alar base of the nose, improving the asymmetry

**Presurgical alveolar molding followed by gingivoperiosteoplasty (at time of lip repair)**

- Goal is to approximate the alveolar cleft using the appliance (pre-surgical orthopedics) until passive contact of the gingival tissue is achieved
- This is followed by periosteoplasty which stimulates new bone growth into the cleft
- Can be part of NasoAlveolar Molding with the ultimate goal to reduce the severity of the initial cleft deformity; appliance consists of a molding plate (silicone), nasal stent and surgical tapes that bring the lip segments together; the device can be designed for the alveolus alone
- Weekly visits required to modify the plate and guide the alveolar cleft segments into the desired position
- Proponents site decreased need for subsequent ABG and improved positioning of the maxillary segments; not widely accepted as not certain what the effect on facial growth is.
- Complications: Ulceration of intra-oral, intra-nasal tissues, notching of the alar rim, irritation of the cheeks, airway obstruction from plate dislodgement

**Alveolar Bone Grafting**

- **Primary Bone Grafting (Early)**
  - B/w birth and 2yrs; either at same time as CL repair or as a separate operation before CP repair
  - Ideally, decreases time of orthodontic treatment in transitional and adult dentition periods and need for eventual orthognathic surgery
  - Cleft repair is done with bone grafting or gingivoperiosteoplasty
  - Early elimination of alveolar oronasal fistula
  - All complete clefts are fitted with obturators to align segments before surgery
  - Need good orthodontic care and close follow-up
  - Proponents of current techniques of primary bone grafting suggest no increased longterm mid-facial growth disturbance
- **Secondary Bone Grafting (late)**
  - Can be done b/w 2-5yr OR 6-12 (mixed dentition) OR late (after eruption of the permanent dentition)

- The most widely accepted timing is at mixed dentition (at HSC well) before eruption of the canine root (< 50% of root formed)
- Gold standard donor site is the iliac crest (other sources: calvarium, tibia, rib, mandible)
- Predictable production of ample viable bone for tooth eruption, orthodontic tooth movement, endosteal implant placement
- When carried out late, lower success rate given gradual loss of bone along distal side of incisor and mesial of canine; this can limit the bone-graft take

### **Lefort I osteotomy (2 piece)**

- At time of skeletal maturity (limited take of bone grafting)
- Goal is to correct midface retrusion as well as close the alveolar cleft in a single procedure
- Disadvantages include more difficult orthognathic procedure, as well as the possibility of tooth loss due to eruption of incisor/canine into area of poor bone stock

### **Innovations in repair of alveolar clefts:**

- Platelet rich plasma (PRP) is an autologous source of growth factors that can accelerate the rate and degree of bone formation in a bone graft; use from autologous blood; facilitates rapid healing and a shorter recovery period (less pain)
- Interdental distraction osteogenesis for large alveolar clefts: allows overcoming soft tissue deficiency and minimized volume of bone graft needed.
- Dental rehabilitation: fixed bridge, osseointegrated implants (at 6mo)

### **Orthodontics in CL/P and CP patients**

Roles of the orthodontist include: record keeping (facial moulages, dental models, height and weight, radiographs, 2D and 3D facial and intraoral imaging), planning and delivering treatment and monitoring growth and development

### **During infancy, presurgical orthopaedics and nasoalveolar molding (see above) via the use of palatal appliances to:**

- Expand the collapsed lesser segment
- Mold the anterior maxillary arch
- Reduce the alveolar gap
- Better align like tissues
- Malpositioned or extra teeth may be removed at time of CP repair

### **During mixed Dentition (before secondary bone grafting):**

Oral health care is of primary importance around this time:

- Visits to pediatric dentist starting at 2yr to ensure oral hygiene, healthy diet, evaluate oral habits and monitor tooth development and eruption

Orthodontic care:

- Focus on restricted maxillary arch width and resultant lateral crossbite
- May be due to surgical closure of cleft AND/OR intrinsic growth disturbance
- Treatment involves placement of fixed appliances on the maxillary arch
- Goal is to expand the posterior and anterior maxilla to develop a favourable arch form, eliminate crossbite, align or de-rotate malpositioned incisors, improve dental function and aesthetics
- Anticipation of 4-6mo of orthodontic treatment in preparation for ABG

#### **During Adult Dentition:**

- Maxillary expansion or repositioning of a protruded maxilla may be indicated for a second time; more difficult to achieve expansion
- Orthognathic surgery needed (See next section)
- May be necessary to undo previous orthodontic treatment

#### **Orthognathic Surgery for Cleft Palate**

- Cleft patient at risk for developing:
  - Residual ONF, bony defects
  - Maxillary hypoplasia (decreased maxillary vertical height/arch width)
  - Midface retrusion
  - Class III or II malocclusion
  - Increased lower face height
  - Nasal deformities, septal/turbinate abnormalities
- Suggested that these are possibly secondary to previous surgical repair (at least partly)
- Emphasis is placed on advancing the maxilla rather than setting back the mandible (cleft patients usually normal mandible growers)
- Timing: skeletal maturity: F > 16, M > 18
- Treatments may include:
  - Lefort I or segmental Lefort I
    - § Most popular technique; considered by many the gold standard
    - § Can allow for simultaneous closure of cleft gap, ONF, management of skeletal defects, stabilization of dentoalveolar segments and correction of jaw deformities
  - Lefort II, Lefort III
  - Distraction osteogenesis (not widely accepted)
  - Mandibular sagittal split osteotomy
  - Genioplasty, secondary rhinoplasty, lip revisions
- Advancements predetermined by orthodontic models
- Use of intermediate and final occlusal splints
- Pre-operative assessment for possible iatrogenic VPI
- May need to take down pharyngeal flap (should not be limiting factor)

## Special scenarios

### **Submucous Cleft Palate (SMCP)**

- **Classic Triad:** bifid uvula, zona pellucida (palatal muscle diastasis), bony notch on hard palate; do not need all three for Dx to be made
- **Pathogenesis:** Absence of merging following fusion of palatal shelves OR mesenchymal short supply
- **“Occult”:** isolated muscle defect visible only on nasal mucosal side as flattened area or groove in place of Musculus Uvula bulge (“seagull” sign)
- **Incidence**
  - Classic: 2-8/1000
  - Occult: unknown
  - Occult SMCP accounts for 10-20% of VPI causes whereas classic SMCP accounts for 17-40%
  - Of all SMCP cases only 10% have VPI
- **Investigations:** as for VPI
- **Treatment**
  - Only indication is documented VPI, therefore usually done 2-3yrs after speech assessment
  - Pharyngeal flap, palatoplasty (pushback, Furlow), or combination

### **Pierre Robin Sequence**

- **Classic Triad:** Retrognathia/micrognathia, glossoptosis, U shaped CP
- **Pathogenesis:**
  - Mechanical theory (mandibular hypoplasia → tongue remains high → CP)
- **Incidence**
  - 1:8500 live births
  - 1:1 M:F; Autosomal recessive; X-linked variant with cardiac abnormalities and clubfeet
  - Seen in syndromes: Strickler, trisomies, Shprintzen, Mobius
- VPI more pronounced than in CP alone
- Major issues guiding treatment: potential for respiratory obstruction
- Feeding can be an issue (at risk for FTT)
- **Treatment:** Tracheostomy, Glossopexy (Routledge or other tongue-lip adhesion); latter must release prior to dentition, mandibular distraction if OSA

## References

1. Beber, B. Total management of the cleft palate child. Resident seminar series, 2003.



2. Carinci et al. Recent developments in orofacial cleft genetics. *J of Craniofacial Surg.*, 14(2) March 2003.
3. Daw JL and Patel, PK. Management of alveolar clefts. *Clin Plastic Surg.* 2004 (31), 303-313.
4. Eppley et al. Management of alveolar cleft bone grafting-state of the art. *Cleft Palate-Craniofacial J*, 37, 2000
5. Evans CA. Orthodontic treatment for patients with clefts. *Clin Plastic Surg.* 2004 (31), 271-290.
6. Georgiade, GS, Riefkohl, R, Levin, LS. *Plastic, Maxillofacial and Reconstructive surgery.* 1997. 3<sup>rd</sup> edition. Chapters 24, 27
7. Gillet, and Clarke. The hybrid palatoplasty: a preliminary report. *Can J Pl Surg.*, 4(3), 1996.
8. Grabb and Smith. 1991. 4<sup>th</sup> edition. *Cleft palate.* Chapter 10 (pg 287).
9. Herber, SC. Orthognathic surgery in the cleft lip and palate patient. *Clin Plast Surg* 20(4), 1993.
10. Johnston, MC. Normal and abnormal development of the lip and palate. *Clin. Plast. Surg.* 12(4) Oct 1985.
11. Jones, MC. Prenatal diagnosis of cleft lip and palate:detection rates, accuracy of ultrasonography, associated anomalies and strategies for counselling. *Cleft Palate-Craniofacial J*, 2001.
12. Kapp-Simon KA. Psychological issues in cleft lip and palate. *Clin Plastic Surg.* 2004 (31), 347-352.
13. Krapels IP et al. Nutrition and Genes in the development of Orofacial clefting. 2006, 64(6), 280-288.
14. Mann RJ, Fisher DM. Bilateral buccal flaps with double opposing Z plasty for wider palatal clefts. *Plastic Reconstructive Surg.* 1997, 100 (1139-45)
15. Marazita ML and Mooney MP. Current concepts in the embryology and genetics of cleft lip and cleft palate. *Clin Plastic Surg.* 2004 (31), 125-140.
16. Marrinan et al. Velopharyngeal function in nonsyndromic cleft palate: relevance of surgical technique, age at repair, cleft type. *Cleft Palate-Craniofacial J*, 1997.
17. Marsh JL. The evaluation and management of velopharyngeal dysfunction. *Clin Plastic Surg.* 2004 (31), 261-269.
18. Mendoza M et al. Minimal Incision Palatoplasty. *Scand J Plastic Reconstructive Hand Surg.* 1994 (28) 199-205.
19. Pantaloni, M and Hollier L. *Cleft Palate and Velopharyngeal Insufficiency, Selected Readings in Plastic Surgery* 8(23) 2001.
20. Posnick JC and Ricalde P. Cleft-orthognathic surgery. *Clin Plastic Surg.* 2004 (31), 315-330.
21. Reisberg, DJ. Prosthetic habilitation of patients with clefts. *Clin Plastic Surg.* 2004 (31), 353-360.
22. Rohrich, RJ. Optimal timing of cleft palate closure. *PRS* 106(2) August 2000.
23. Sadove, AM, et al. Cleft palate repair: art and issues. *Clin Plastic Surg* 2004 (31), 231-241.
24. Sloan GM. Posterior pharyngeal flap and sphincter pharyngoplasty: state of the art. *Cleft Palate-Craniofacial J*, 37, 2000.

25. Smith B and Guyette TW. Evaluation of cleft palate speech. *Clin Plastic Surg.* 2004 (31) 251-260.
26. Weinfeld AB et al. International trends in the treatment of cleft lip and palate. *Clin Plastic Surg.* 2005 (32), 19-23.
27. Weinzwieg, J. *Plastic Surgery Secrets.* Chapters 13 & 14. 1999.
28. Witt, P and Marsh, JL. Advances in assessing outcome in cleft lip and cleft palate. *PRS* 100(7), Dec 1997.
29. Wood et al. Gingivoperiosteoplasty and midfacial growth. *Cleft Palate-Craniofacial J*, 1997.

