

# Angioscopy

JOSEPH I. ZARGE, M.D.  
SURGICAL RESEARCH FELLOW, DEPARTMENT OF SURGERY,  
TEMPLE UNIVERSITY SCHOOL OF MEDICINE  
PHILADELPHIA, PA

JOHN V. WHITE, M.D.  
PROFESSOR, DIRECTOR OF SURGICAL RESEARCH,  
DEPARTMENT OF SURGERY, TEMPLE UNIVERSITY SCHOOL OF MEDICINE  
PHILADELPHIA, PA

**A**ngiography currently is the principle diagnostic test for evaluation of the vasculature. Though this invasive radiologic procedure demonstrates vascular anatomy and areas of narrowing and blockage, it does not define the specific cause of the occlusion. This limitation may inhibit the appropriate treatment of vascular disease. Recently, a variety of endovascular tools designed for the treatment of specific disorders have been developed, such as lytic therapy for thrombotic occlusions, lasers for fibrotic occlusions, and atherectomy catheters for calcific atherosclerotic occlusions. For effective use of these tools, the specific cause of a vascular lesion must be determined. Angioscopy can enhance the use of these innovative therapies by providing a real-time panoramic view of the lumen, which permits both the diagnosis of luminal irregularities and visual guidance of specific luminal therapy.

## SYSTEM COMPONENTS

Currently, an intraoperative angioscopic system consists of the angioscope, light source, irrigation source, video camera, and monitor. Other than the angioscope, these pieces of equipment are generally available in the operating room for laparoscopic surgery. Available angioscopes currently range in diameter

from 0.6 mm to 7 mm and in length from 40 cm to 100 cm (Figure 1). These scopes are constructed from bundles of thin, flexible fiber optic fibers that carry light to, and the image from, the vessel lumen. The imaging bundles connect to a lens system and the eyepiece, which is the site of video camera coupling. The fiber optic bundles are wrapped with an outer coating designed to protect them,

yet permit flexion and a smooth surface that can glide over the intima without inducing injury.

Angioscopes have a variety of working characteristics. The scope may be guided by passive deflection or active steering. The soft distal tip of the angioscope allows it to follow the natural curve of the vasculature without damaging the endothelial surface. The angioscope may also be advanced over a guidewire inserted through its working channel. Steerable or manually deflecting scopes are available that have up to 170° of flexion. Scopes 1 mm or larger generally have working channels that permit coaxial irrigation and the use of coaxial instrumentation. Coaxial irrigation most effectively clears blood and debris from the field immediately in front of the scope. Guidewires and thromboembolectomy catheters can be used effectively through the working channel, however, this prevents both coaxial irrigation and instrument exchange.

### Light Source

Successful performance of angioscopy requires bright illumination. Most available light sources are either quartz-halogen or xenon-based, both of which produce a cold, safe light of 150 to 300 Watts. To clearly visualize the lumen of the vessel, sufficient light must be reflected off the target surface and onto the imaging bundles. Too little light creates a murky, hazy image, whereas too much light produces a blinding, white image. By using photosensors, the

newest generation of light sources can automatically adjust for image quality so that as reflection of the light increases, the output of the light source is automatically decreased to prevent washout of the image.

### Video Camera

Video transmission of the angioscopic image permits the entire surgical team to view the vessel lumen simultaneously. Small color video cameras are capable of capturing the image from the eyepiece, digitizing it, and transmitting it on a high-resolution, color video monitor. In the process of this video transmission, the image is magnified 15 to 20 times. The small, color video cameras have high resolution and, when coupled to an adequate light source, can produce vivid, true color pictures of the endovascular environment.

### Irrigation

Coaxial crystalloid irrigation is used to prevent backflow and eliminate blood from the vessel being evaluated. Inflow is controlled through standard open vascular techniques or with pneumatic cuffs. Occasionally, clear visualization requires large volumes of irrigation, and the anesthesiologist must be aware of the rate and volume of infusate. In a recent randomized, prospective study between completion angiography and angioscopy, no statistically significant difference was seen between the total amount of fluid received by the two groups.<sup>1</sup>

A variety of ways are available to irrigate and clear the vessel lumen.

Infusion pumps may be used that can deliver small or large volumes of saline under high pressure through the tip of the sheath or angioscope to clear the field.<sup>2</sup> They are able to provide flow rates from 10 to 400 ml/min at a pressure of up to 2000 mm Hg at the pump head. Simpler fluid delivery devices may also be used, such as pressurized bags of heparinized saline or hand syringe injection. Hand injection of irrigation fluid with a 60-ml syringe limits the amount of fluid that can be rapidly infused at one time and permits the use of a variety of irrigating solutions, such as heparinized saline and papaverine.

Recently, carbon dioxide (CO<sub>2</sub>) has been used to establish a clear working field for the angioscope. CO<sub>2</sub> angiography has been performed successfully and safely, without the adverse renal effects of contrast.<sup>3</sup> Silverman and colleagues experimented with the use of CO<sub>2</sub> for angioscopy, based upon the success of CO<sub>2</sub> angiography. In an animal model, the investigators found that CO<sub>2</sub> could more effectively clear the lumen of blood and maintain the field of visualization than could saline.<sup>4</sup> Gaseous embolic occlusion and persistent tissue ischemia have not been seen in these experiments. Although CO<sub>2</sub> angioscopy must still be considered experimental, it represents a promising advance in the application of this imaging modality, especially in patients in whom high volumes of crystalloid would be poorly tolerated.

### Endovascular Instrumentation

The angioscope can be used to guide endovascular intervention with a wide variety of endovascular instrumentation including thrombectomy catheters, guidewires, valvulotomes, forceps, and scissors. Endovascular instrumentation can be used in either a coaxial or parallel fashion. Coaxial deployment of instrumentation refers to introduction of the instrument through the working channel of the angioscope. The risk of injury to the intima is lowest when endovascular tools are inserted in this manner, but mobility of the instrument may be limited. Manipulation and removal of the instrument may cause movement of the angioscope tip and a change in the field of vision. Placing the tool alongside the angioscope, in parallel fashion, permits the greatest amount of movement of the instrument without disturbing the field of vision of the angioscope.

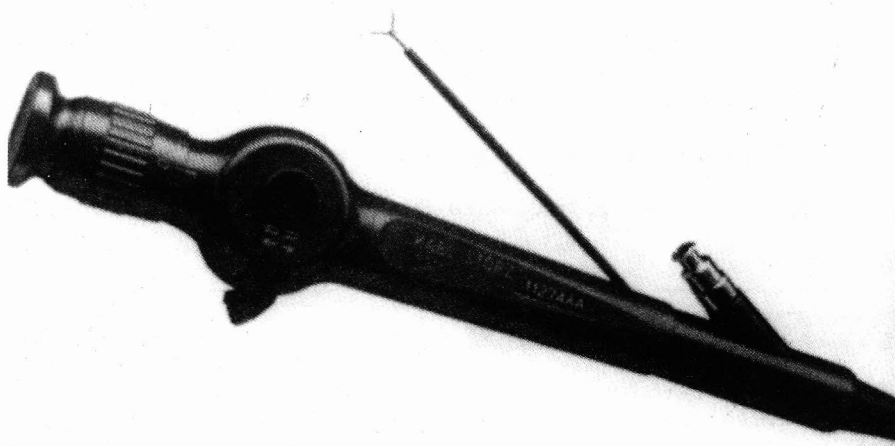


Figure 1. Angioscopes are available in diameters ranging from 1.6 mm to 7 mm. Similar to other flexible endoscopes, they are composed of varying numbers of optical fiber bundles wrapped in outer cladding.

Standard balloon thrombectomy catheters can be used in either a parallel or coaxial fashion. Three French (3Fr.) balloon catheters are capable of sliding through the working channel of most commonly used sizes of angioscopes and, if of appropriate length, will extend 2 cm or more beyond the end of the angioscope so they are clearly visualized. Placement of the catheter, inflation of the balloon, and clearance of debris can be clearly seen. A 0.038-inch guidewire can be used in a coaxial fashion to aid in passive steering of the angioscope into heavily diseased or distal vasculature. Intravascular ultrasound can also be inserted during angiography to provide information about subintimal pathologic findings.

A variety of forceps, graspers, and scissors have been adapted for angiographic intervention from the endobronchial instrumentation (Figure 2).<sup>5</sup> These tools are used in parallel with the angioscope and are sufficiently flexible to follow the course of the vessel, yet are stiff enough to be steered by torque into appropriate position. These instruments enable the surgeon to correct luminal defects visualized by the angioscope.

### Basic Intraoperative Arterial Angioscopy

Before beginning intraoperative angiography, all the equipment must be thoroughly checked, including the angioscope, video system, infusion pump, and all endovascular instrumentation. The type of fluid and an estimate of the amount to be used should be conveyed to the anesthesiologist at the beginning of the procedure so appropriate fluid management may be planned.

Control of inflow is crucial for successful angiography. This is routinely done intraoperatively by standard vascular surgical isolation of the proximal vessel and the placement of a vascular clamp, double-looped silastic band, or intraluminal occlusion device. A double-looped silastic band should be used for distal control to accommodate easy passage and withdrawal of the angioscope. After the arteriotomy is made, an introducer sheath can be used to prevent the tip of the angioscope from raising an intimal flap during placement. The sheath also permits infusion of irrigation fluid through the side port to maintain visualization. The angioscope is then inserted into the vessel. After the distal tip of the scope is advanced

just beyond the arteriotomy, a bolus of irrigation is administered to clear the field and a maintenance infusion begun to preserve visualization. The surgeon may choose to advance the scope carefully to the point of interest while inspecting the lumen, or to advance the scope rapidly and inspect the lumen upon withdrawal. After it is used, the angioscope and, in particular, the working channel should be cleaned immediately. When blood is allowed to solidify within this channel, it is difficult to remove and may form a permanent

obstruction. Similarly, the distal tip must be carefully cleaned of blood and debris.

### DIAGNOSTIC ANGIOSCOPY

Determination of the specific types of endoluminal disease has been helpful in a variety of circumstances, especially in the setting of acute ischemia, trauma, endarterectomy, and graft preparation and graft failure. Frequently, angiography can only confirm the level of arterial disease without demonstrating the cause

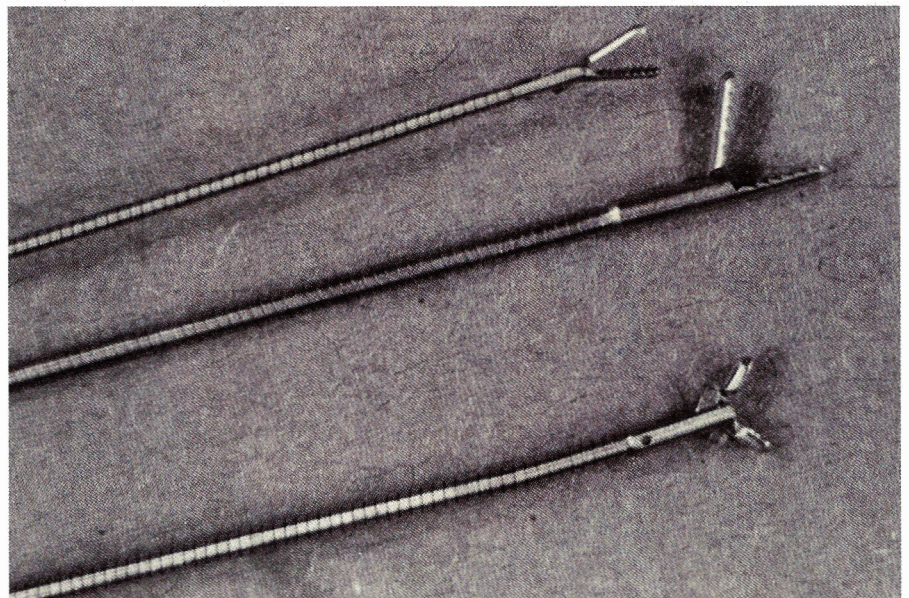


Figure 2. Endovascular instruments are based upon flexible shafts that permit torque steering. A variety of grasping and cutting tips are available. (Reprinted with permission of the C.V. Mosby Company from White JV, Haas KS, Comerota AJ. An alternative method of salvaging occluded suprainguinal bypass grafts with operative angiography and endovascular intervention. *J Vasc Surg* 1993; 18:922.)

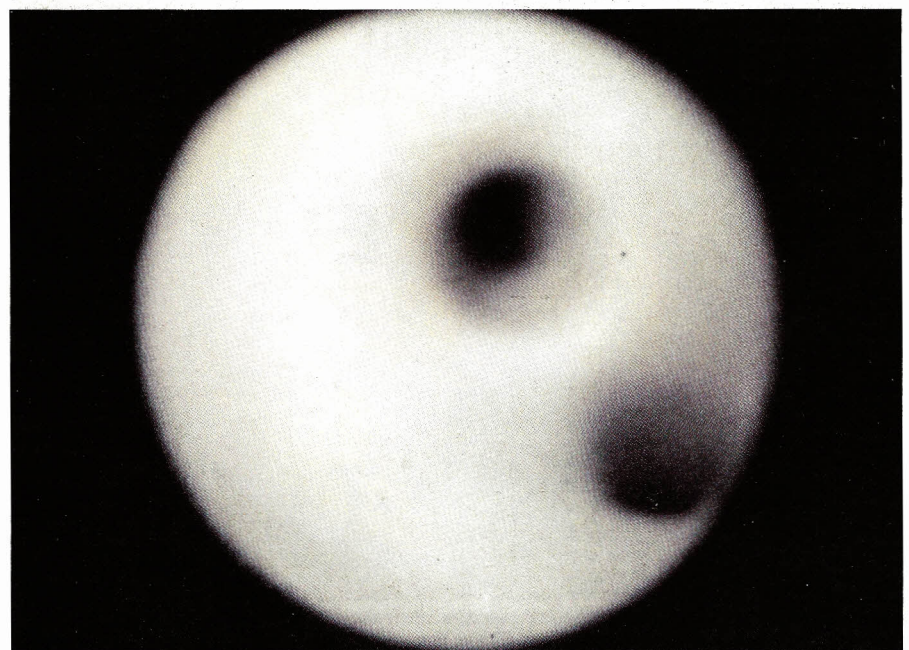


Figure 3. The appearance of normal arterial lumen. Note the smooth, glistening endothelial flow surface.

or extent of the radiographic abnormality. Thus, thrombotic, embolic, and atherosclerotic occlusions may all have the same appearance angiographically; however, their treatments may differ significantly at the time of surgery.

The flow surface of a normal blood vessel is typically smooth, white, and glistening. The ostia of tributaries are also smooth and well-defined (Figure 3). Atherosclerotic plaque appears yellow and irregular. Large plaques may

demonstrate small areas of ulceration and adherent thrombus. Loss of cross-sectional luminal area is easily detected (Figure 4). Emboli are found frequently in areas of bifurcation and are often seen as large exophytic luminal masses surrounded by otherwise normal endothelium (Figure 5). Thrombotic occlusions may be associated with relatively normal or grossly atherosclerotic intima. The thrombus is easily recognized as an adherent, red, jelly-like

mass obstructing most or all the lumen. In the setting of dissection, luminal flaps, intimal injury, and adherent thrombus can all be seen vividly on angioscopy (Figure 6).

### Bypass Grafts

Initially, vascular surgeons used the angioscope to inspect bypass grafts. Angioscopy is extremely helpful for evaluating the configuration of the distal anastomosis, the status of the outflow tract, and extrinsic problems such as twisting of the graft or compression in its tunnel. The scope is also useful in examining veins for bypass and the completeness of valve lysis.

Intraoperative angioscopic evaluation of lower-extremity bypass grafts can significantly reduce the immediate graft failure rate secondary to technical problems. Intraoperative completion angiography is the standard form of bypass graft evaluation used by many vascular surgeons. Completion angioscopy, however, has been proved equal or superior to angiographic evaluation of the newly implanted arterial bypass graft because of the ability of angioscopy to detect intraluminal abnormalities, including thrombus, atherosclerotic debris, and webs, which may not be evident on angiograms.<sup>6-9</sup> Other investigators have shown an increase in immediate vein graft patency rates after correction of angioscopically visualized lesions.<sup>10,11</sup> By virtue of its magnified image, the angioscope may detect even minor flow-surface defects. The ability to determine whether a visualized flow-surface abnormality mandates intervention is required from experience and may represent the most significant part of the learning curve.

### Trauma

Actual or threatened acute ischemia of the extremity associated with blunt trauma mandates identification of the causative lesion. Unfortunately, angiography usually demonstrates only an indistinct luminal irregularity or abrupt termination of the dye column. For example, patients with long-bone fractures or posterior knee dislocations may have a significant arterial injury without the signs or symptoms of acute ischemia.<sup>12</sup> Angiography and duplex imaging may detect the presence of a small luminal artifact of unknown significance. These patients are frequently taken to the operating room for inspection of the artery. Angioscopy may per-

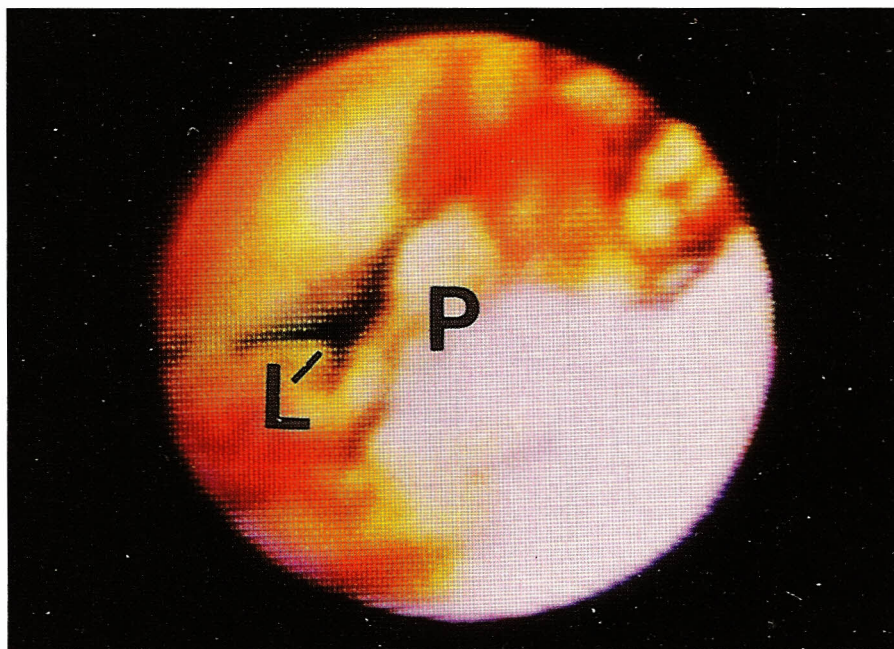


Figure 4. The angioscopic image of atherosclerotic plaque (P). Note the exophytic atherosclerotic lesion and the residual, slit-like lumen (L).

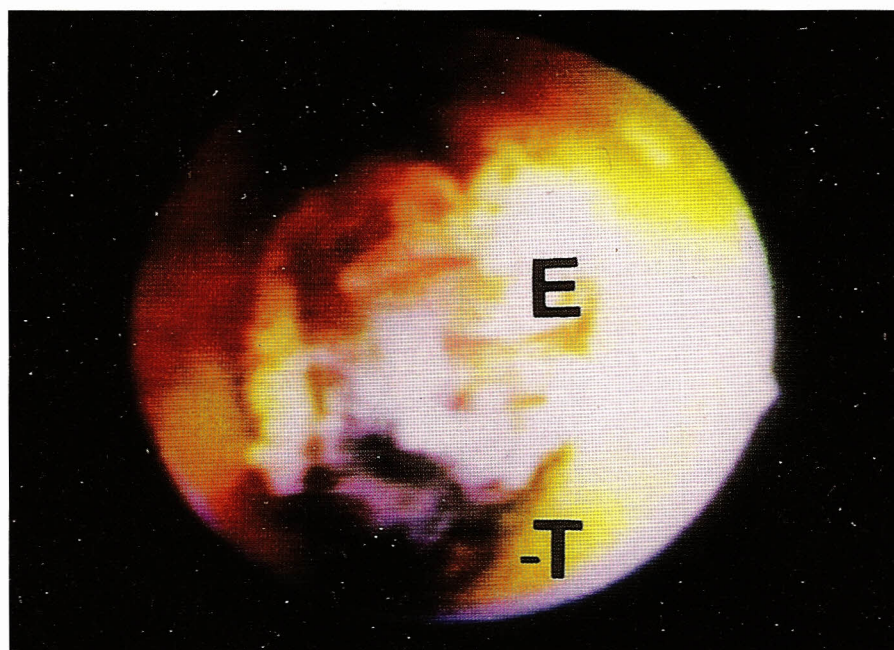


Figure 5. Embolic occlusions (E) have several characteristic features evident on angioscopy. These include a complex obstruction consisting of fronds of fibrous tissue intermingled with thrombus (T) generally not adherent to the arterial wall.

mit a smaller procedure for those without a lesion requiring surgical repair. Rather than direct exploration of the vessel in the region of the suspected injury and maximal soft-tissue damage, the surgeon may introduce the angioscope into a more proximal artery, such as the superficial femoral artery, and advance it down into the popliteal artery. If a major flow-surface defect is seen, surgical correction can be undertaken immediately. If the injury is less severe, a smaller, more appropriately sized scope can be advanced slowly beyond this area to determine the full extent and severity of the luminal defect. Surgical intervention can then be tailored according to the findings.

### Carotid Artery

Carotid endarterectomy reduces the stroke risk in selective patients. The effectiveness of this operation is dependent upon meticulous intraoperative technique and the restoration of a smooth, debris-free flow surface. Angioscopy can be performed safely before closure of the arteriotomy to examine the endarterectomized flow surface and the proximal and distal points of intimal transection while the vessel is appropriately distended with flowing crystalloid.<sup>15</sup> This procedure allows the surgeon an exceptional opportunity to identify and correct luminal defects that might otherwise compromise a well-performed procedure.

### Venoscopy

Angioscopic visualization of major veins is more difficult and, currently, less beneficial than in arteries. Venoscopy has proved useful in femoral vein valvuloplasty by enabling the surgeon to visualize and suture repair the valve cusps from outside of the vessel lumen.<sup>14,15</sup> The angioscope has also been used to evaluate the completeness of thrombectomy of the major deep veins of the lower extremity and in phlebectomy of varicose veins.<sup>16,17</sup>

### Coronary Artery

Cardiologists have used a variety of endovascular devices to image the cardiac valves, chambers, and coronary arteries. Intraoperative coronary angioscopy can identify coronary artery abnormalities and evaluate the technical adequacy of bypass grafting. Clinical trails have demonstrated the efficacy of intraoperative angioscopy in visualizing the distal anastomosis in patients undergoing bypass grafting.<sup>18</sup> At Temple

University Hospital, the angioscope has been used to evaluate the coronary arteries in donor hearts before cardiac transplantation.<sup>19</sup> A 1.4-mm scope can easily be inserted into this blood-free environment and can assess the severity of suspected coronary artery lesions.

## INTERVENTIONAL ANGIOSCOPY

A better understanding of vascular luminal disease and the development of endovascular instruments have facilitated the progression from diagnostic to interventional angioscopy. Many open vascular surgery techniques such as thromboembolectomy, graft thromboembolectomy, and *in situ* graft preparation can now be accomplished angioscopically.

### Thromboembolectomy

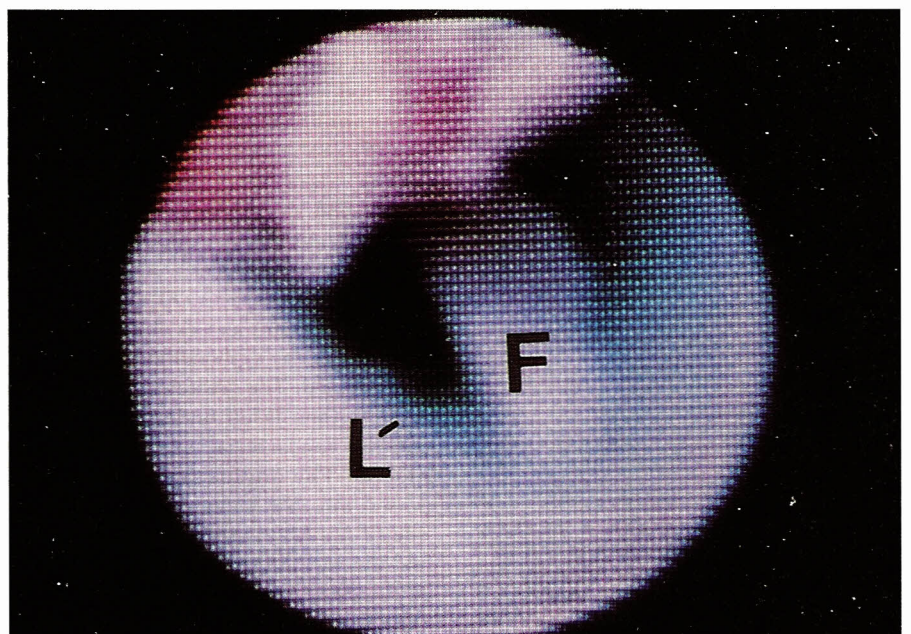
One of the basic procedures for the vascular surgeon is the extraction of clot and embolic debris from arteries. Traditionally, this has been accomplished by multiple blind passes of balloon catheters into occluded vessels. Unfortunately, potentially occlusive debris may be left behind. Angioscopy has been shown to successfully identify residual fragments after traditional balloon extraction.<sup>20</sup> The angioscope can further be used to guide thrombectomy catheters into areas of clot to enhance clot extraction.<sup>21,22</sup> Balloon inflation and thromboembolectomy can then be performed under direct vision to mini-

mize intimal injury.

Currently, several additional devices further enhance the endovascular surgeon's ability to remove vessel debris. Endovascular forceps are easily guided by the angioscope and permit the grasping and withdrawal of adherent clot. Fogarty and Hermann have designed an adherent clot catheter and a graft thrombectomy catheter for the performance of angioscopically guided clot extraction.<sup>23</sup> These catheters have aggressive structural designs that facilitate dislodgment and extraction of both clot and pseudointima from synthetic grafts.

### Suprainguinal Graft Thromboembolectomy

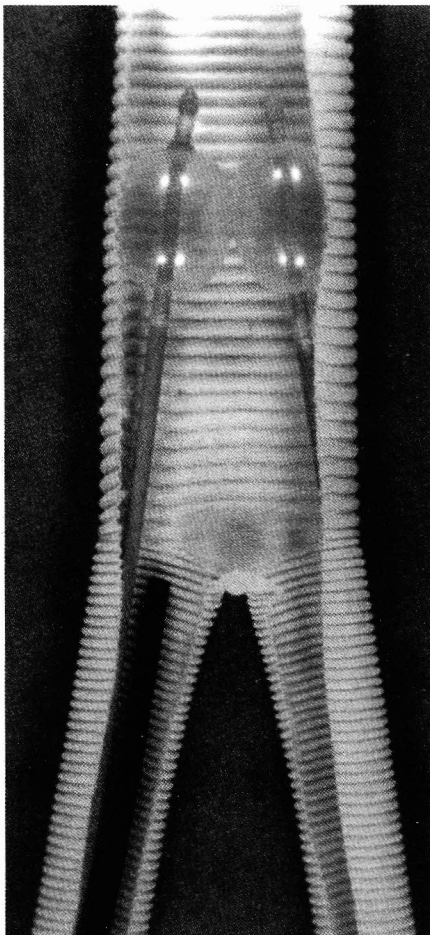
The angioscope can be an extremely valuable adjunct for the performance of suprainguinal graft thromboembolectomy. Completion angiography is rarely performed in these cases and blind retrograde balloon thrombectomy may leave residual clot and debris that can cause early thrombectomy failure.<sup>24</sup> Furthermore, the restoration of pulsatile blood flow is an inadequate test to detect residual flow-surface defects. The angioscope can easily identify suprainguinal graft defects. The removal of flaps, adherent clot, and fractured pseudointima may then be accomplished by repeated passages of balloon catheters or with other endovascular instruments. Recent studies investigating salvage of suprainguinal



**Figure 6.** The angioscopic appearance of an intimal flap (F) with subintimal dissection. Note the partially obstructed lumen (L) adjacent to the flap. These lesions are commonly seen after blunt trauma, endovascular instrumentation, and balloon angioplasty.

grafts have documented the feasibility of angioscopically guided endovascular luminal debridement of all visualized intraluminal defects and the restoration of a smooth flow surface to occluded graft limbs.<sup>25</sup>

An isolated graft limb thrombosis or aortic graft body thrombosis can be approached in a similar fashion. Distal control is obtained through standard groin incisions. A longitudinal graftotomy is then made after standard anticoagulation. Blind retrograde balloon thromboembolectomy is performed first to remove large debris. Two 6Fr. balloon catheters can be inflated in a "kissing balloon" fashion if preoperative angiography demonstrates luminal defects within the body of the aortic graft (Figure 7).<sup>5</sup> Angioscopic graft evaluation is then achieved by establishing inflow control with a balloon catheter at the origin of the graft or



**Figure 7.** Graphic representation of the deployment of endovascular instruments to perform a "kissing balloon" thrombectomy within the body of the graft. (Reprinted with permission of the C.V. Mosby Company from White JV, Haas KS, Comerota AJ. An alternative method of salvaging occluded suprainguinal bypass grafts with operative angioscopy and endovascular intervention. *J Vasc Surg* 1993; 18:922.)

graft limb. The thrombectomized graft surface is inspected carefully throughout its length for adherent thrombus, fractured pseudointima, or other pathologic findings. Special attention is paid to the hyperplastic pseudointima at the level of the bifurcation. When problematic areas of the graft lumen are identified, the endoluminal grasping forceps and biopsy scissors are inserted parallel to the angioscope and, under angioscopic guidance, the instruments are used to debride all luminal defects. Completion angioscopy should demonstrate a completely smooth flow surface. The distal anastomosis and outflow bed are then visualized with a 2.3-mm angioscope to identify any outflow tract disease that may be the cause of graft failure. Pseudointimal hyperplasia at the distal anastomosis can be resected under angioscopic guidance as detailed above, but care must be taken to avoid raising distal intimal flaps.

#### **In Situ Graft Preparation**

*In situ* bypass grafting requires a significant amount of endoluminal manipulation, including lysis of vein valves. Angioscopy enables the surgeon to visualize the valves and determine the efficacy of valve lysis. Studies comparing angioscopy with angiography and duplex imaging to determine the presence of intact valves and anastomotic problems have demonstrated that direct visualization of vein valves through angioscopy is the optimal method for identifying intact vein valves.<sup>6-9</sup>

Several techniques of angioscopically assisted vein graft preparation have been reported.<sup>25-28</sup> Preoperatively, the greater saphenous vein should be imaged to identify problematic areas and assess the vein's diameter. During surgery, papaverine should be injected into the subcutaneous tissue around the vein and intravenous nitroglycerin should be used to prevent vasospasm. After anticoagulating the patient and establishing vascular control, the saphenofemoral junction is transected. The greater saphenous vein valve is then lysed under direct vision and the venoarterial anastomosis completed. The angioscope can then be passed into the saphenous vein through one of the large proximal side branches and the valvulotome is inserted into one of the distal branches. All the valves are then lysed under angioscopic guidance. As the angioscope is withdrawn, the location of the tributaries is marked on the surface of the skin. When the distal

anastomosis is constructed, ligation of the tributaries is performed. Tributaries are ligated as much as possible using small, non-continuous skin incisions. An angioscope, placed in the subcutaneous space, can help identify the location of tributaries. Future technologic advances may allow the surgeon to embolize the major side branches under angioscopic guidance. After the distal anastomosis is completed, the angioscope is reinserted to carefully inspect it and the proximal outflow tract. Doppler interrogation of the graft should permit detection of any remaining tributaries. To visualize the distal outflow tract, the completion angiography is performed. Although the angioscope has not been shown to improve long-term patency rates of *in situ* grafts, multiple studies have demonstrated the efficacy of angioscopic-assisted vein graft preparation and have also shown a consistent reduction in wound complication rates.<sup>27,28</sup>

#### **COMPLICATIONS**

The most frequent complications of angioscopy include fluid overload, vascular spasm, and intimal injury.<sup>25,29</sup> Excessive volume administration occurs during inadequate inflow control with subsequent massive quantities of crystalloid irrigation to maintain clear visualization. Vascular spasm is an unpredictable event, but it can be alleviated by use of topical papaverine and intravenous nitroglycerine. The use of a smaller angioscope and gentle vessel manipulation will also help to preserve a workable luminal area. The most dangerous complication, although rare, is intimal damage. These injuries most frequently occur while using an oversized scope within the vessel lumen. Intimal injuries can progress to focal dissections and thrombotic events. By selecting an appropriately sized scope with a soft, flexible tip, intimal damage can be minimized.

#### **SUMMARY**

The improvement of angioscopic and endovascular technology has dramatically enlarged the potential applications of the angioscope. As the benefits of less-invasive surgery become more apparent, the angioscope will assume a greater role for the vascular surgeon. Angioscopic diagnostic and therapeutic capabilities will be limited only by the surgeon's experience and imagination. **STI**

REFERENCES

1. Kwolek CJ, Miller A, Stonebridge PA, et al. Safety of saline irrigation for angiography: Results of a prospective randomized trial. *Ann Vasc Surg* 1992; 6:62.
2. Miller A, Lipson WE, Isaacsohn JL, et al. Intraoperative angiography: Principles of irrigation and description of a new dedicated irrigation pump. *Am Heart J* 1989; 118:391.
3. Weaver FA, Pentecost MJ, Yellin AE. Carbon dioxide digital subtraction arteriography: A pilot study. *Ann Vasc Surg* 1990; 4(5):437.
4. Silverman SH, Mladinich CJ, Hawkins IF, et al. The use of carbon dioxide gas to displace flowing blood during angiography. *J Vasc Surg* 1989; 10(3):313.
5. White JV, Haas KS, Comerota AJ. An alternative method of salvaging occluded suprainguinal bypass grafts with operative angiography and endovascular intervention. *J Vasc Surg* 1993; 18:922.
6. Miller A, Marcaccio EJ, Tannenbaum GA, et al. Comparison of angiography and angiography for monitoring infrainguinal bypass vein grafts: Results of a prospective randomized trial. *J Vasc Surg* 1993; 17:382.
7. Van Steigmann G, Pearce WH, Bastie EJ, et al. Flexible angiography seems faster and more specific than arteriography. *Arch Surg* 1987; 122:279.
8. Baxter BT, Rizzo RF, Flinn WR, et al. A comparative study of intraoperative angiography and completion arteriography following femorodistal bypass. *Arch Surg* 1990; 125:997.
9. Gilbertson JJ, Walsh DB, Zwolak RM, et al. A blinded comparison of arteriography, angiography and duplex scanning in the intraoperative evaluation of *in situ* saphenous vein bypass grafts. *J Vasc Surg* 1992; 15:121.
10. Marcaccio EJ, Miller A, Tannenbaum GA, et al. Angioscopically directed interventions improve arm vein bypass grafts. *J Vasc Surg* 1993; 17:994.
11. Sales CM, Marin ML, Veith FJ, et al. Saphenous vein angiography: A valuable method to detect unsuspected venous disease. *J Vasc Surg* 1993; 18:199.
12. Kaufman SL, Martin LG. Arterial injuries associated with complete dislocation of the knee. *Radiology* 1992; 184:153.
13. Mehigan JT, DeCampli WM. Angioscopic control of carotid endarterectomy. In: Moore WS, Ahn S, eds. *Endovascular Surgery*. Philadelphia: WB Saunders Co, 1989:95.
14. Gloviczki P, Merrell SW, Bower TC. Femoral vein valve repair under direct vision without venotomy: A modified technique with use of angiography. *J Vasc Surg* 1991; 14:645.
15. Welch HJ, McLaughlin RL, O'Donnell TF. Long-term follow-up of femoral vein valvuloplasty: Does intraoperative angiographic evaluation improve the procedure? *J Vasc Surg* 1992; 16:694.
16. Woelfle KD, Bruijnen G, Zuegel N, et al. Technique and results of vascular endoscopy in arterial and venous reconstructions. *Ann Vasc Surg* 1992; 6:347.
17. Gradman WS, Segalowitz J, Grundfest W. Venoscopy in varicose vein surgery. Presented at Progress in Angioscopy, Interventional and Monitoring Techniques in Vascular Surgery, Harvard Medical School, December 6-8, 1993.
18. Bessou JP, Melki J, Bouchart F, et al. Intraoperative coronary angiography—technique and results: A study of 38 patients. *J Cardiovasc Surg* 1993; 8(4):483.
19. McClurken JB, White J, Deutsch E, et al. Donor heart angiography—increasing recovery from the existing donor pool. *J Heart Lung Transp* 1993; 12:1.
20. White GH, White RA, Kopchok GE, et al. Angioscopic thromboemblectomy: Preliminary observations with a recent technique. *J Vasc Surg* 1988; 7:318.
21. Grundfest WS, Litvack F, Glick D, et al. Intraoperative decisions based on angiography in peripheral vascular surgery. *Circulation* 1988; 78(Suppl I):1-13.
22. Segalowitz J, Grundfest WS, Treiman RL, et al. Angioscopy for intraoperative management of thromboemblectomy. *Arch Surg* 1990; 125:1357.
23. Fogarty TF, Hermann GD. New techniques for clot extraction and managing acute thromboembolic limb ischemia. In: Veith FJ, ed. *Current Critical Problems in Vascular Surgery, Volume 3*. St. Louis: Quality Medical Publishing Co, 1991:197.
24. Hyde GL, McCready RA, Schwartz RW, et al. Durability of thrombectomy of occluded aortofemoral graft limbs. *Surgery* 1983; 94:363.
25. Miller A, Stonebridge PA, Tsoukas AI, et al. Angioscopically directed valvulotomy: A new valvulotome and technique. *J Vasc Surg* 1991; 13:813.
26. Woelfle KD, Bruijnen H, Zuegel N, et al. *In situ* saphenous vein grafts for femorodistal bypass: Evaluation of endoscopically monitored valvulotomy on graft patency. *Cardiovasc Surg* 1993; 1(6):690.
27. Mehigan JT. Angioscopic control of *in situ* bypass: Technical considerations. *Semin Vasc Surg* 1993; 6(3):176.
28. Maini BS, Andrews L, Salimi T, et al. A modified, angioscopically assisted technique for *in situ* saphenous vein bypass: Impact on patency, complications, and length of stay. *J Vasc Surg* 1993; 17:1041.
29. Miller A, Campbell DR, Gibbons GW, et al. Routine intraoperative angiography in lower extremity revascularization. *Arch Surg* 1989; 124:604.