

# OCCIPITAL LOBE SYNDROME



**Course: Neuropsychology CC-6 (M.A PSYCHOLOGY SEM II); Unit 4**

**By**

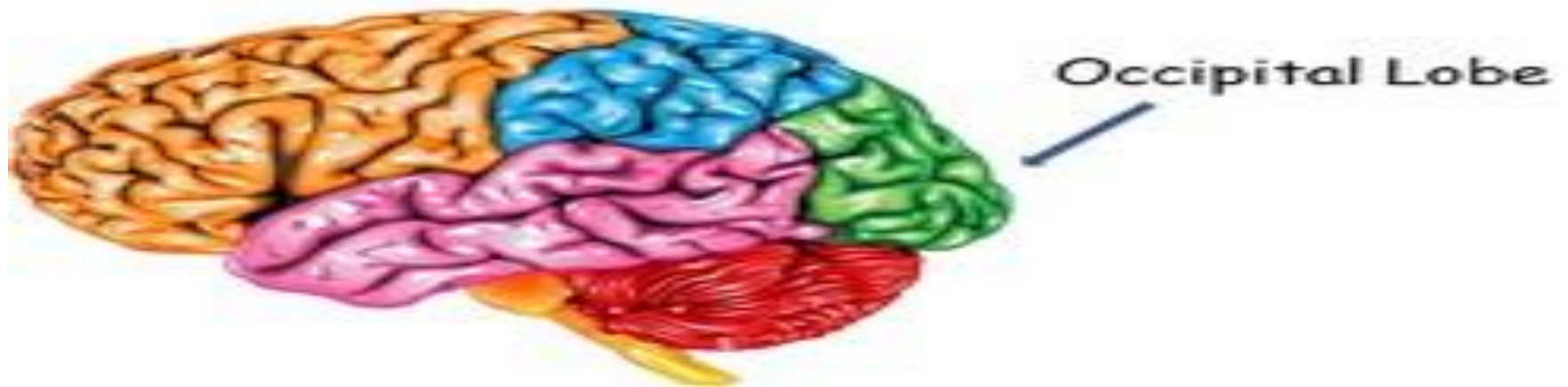**Dr. Priyanka Kumari**

**Assistant Professor**

**Institute of Psychological Research and Service**

**Patna University**

**Contact No.7654991023; E-mail- Priyankakumari1483@yahoo.com**



## Occipital Lobe

The occipital lobe is located at the rear-most area of each cerebral hemisphere; that is at the back of your head.

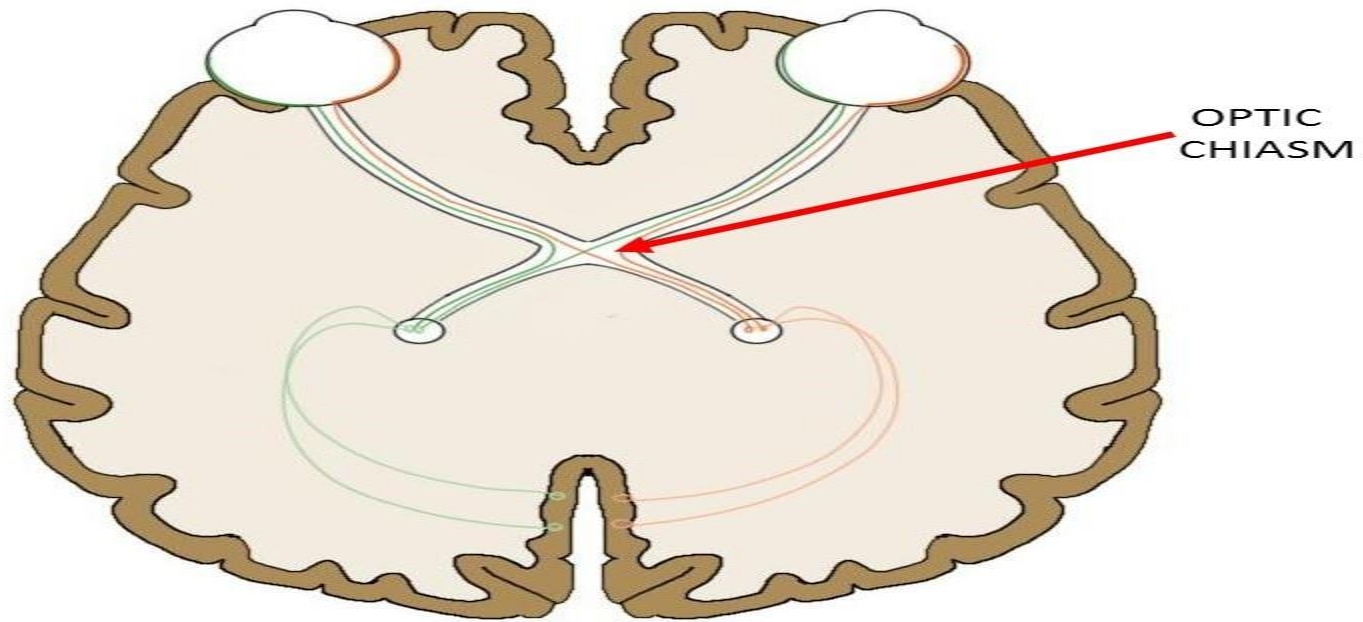
The **occipital lobe** is primarily involved in vision.

Damage to the occipital lobe can produce blindness, even if the eyes and their neural connections to the brain are normal.

The **primary visual cortex** is located at the base of each occipital lobe and this is where visual information from the two eyes is received and processed.

## OCCIPITAL LOBE SYNDROME

Occipital lobe is located at the back of the brain, the occipital lobe has both the visual association areas and the primary visual cortex. When information comes in through the eyes, it crosses the optic chiasm and goes to the primary visual cortex to be processed. Because of the crossover in the optic chiasm, information from the right eye is processed by the left occipital lobe, and vice versa.



# Symptoms of Occipital Lobe Stroke



Cortical Blindness



Visual Illusions



Visual Hallucinations



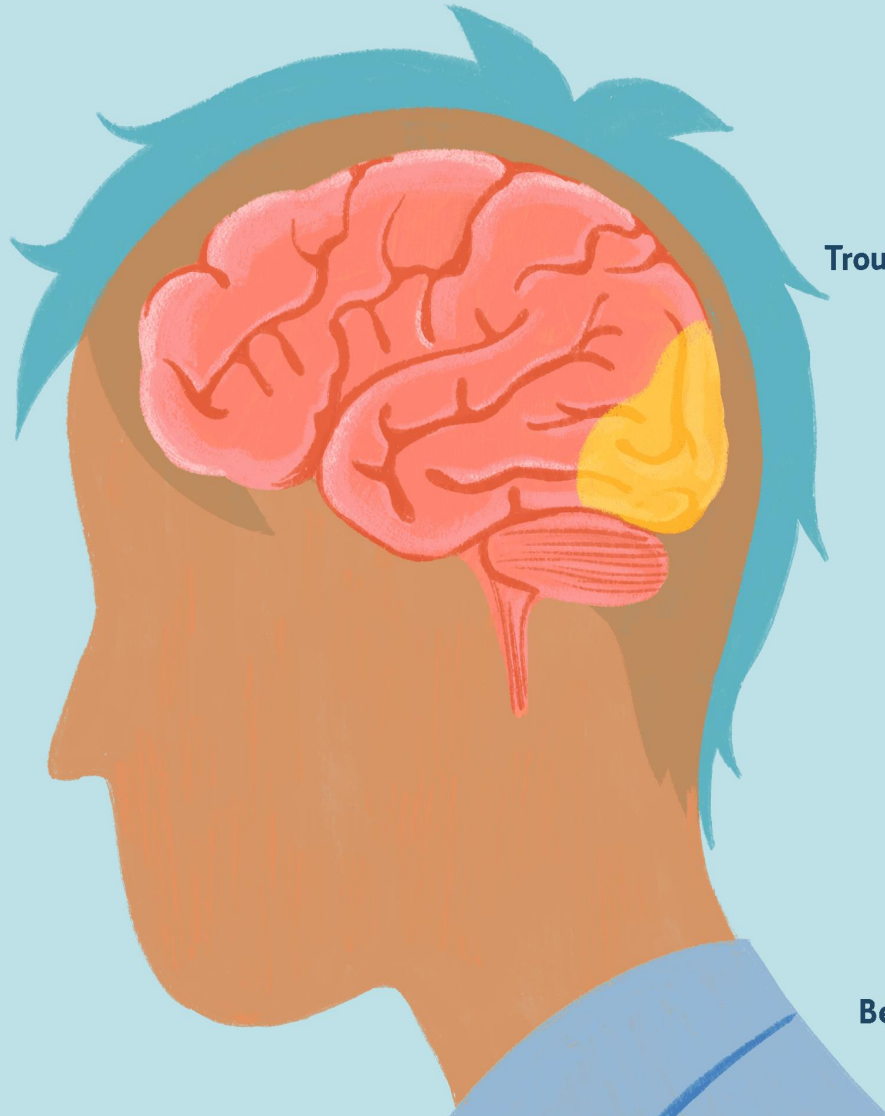
Trouble visually recognizing objects



Face Blindness



Being able to write but not read



**If the occipital lobe is damaged, a person can have different visual disorders, even if no damage occurs to the eyes.**

**1. Irregularities in visual perception**

- i. Disturbances in identification of visual location.**
- ii. Disturbance in visual orientation**
- iii. Irregularities in depth perception**
- iv. Disturbances in spatial orientation- cannot identify horizontal and vertical.( Hubel and Wiesel, 1959)**
- v. Achromatopsia- Perceive only grey (black and white color)**

**2. Cerebral blindness-** is the total or partial loss of vision in a normal appearing eye caused by damage to the brain's occipital cortex.

In most cases, the complete loss of vision is not permanent and the patient may recover some of their vision (cortical visual impairment).

**Anton Babinski syndrome-** Damage to the primary visual cortex causes Anton's syndrome which is a type of central blindness. The patient cannot usually recognize objects, but denies that he/she has a blindness problem. A patient may have little or no insight that they have lost vision, a phenomenon known as Anton- Babinski syndrome. In this memory defects are also found because the damage effect on inferomedial temporal lobe

## **Anton–Babinski syndrome** **(Visual anosognosia)**



- Denial of blindness who cannot see.
- The lesion extend beyond the striate cortex to involve visual association areas.
- Failing to accept being blind, the sufferer dismisses evidence of his condition and employs confabulation to fill in the missing sensory input.
- Lesion is in visual association areas superior to calcarine cortex.

## **Anton Syndrome**

A 48-year-old man with complete loss of vision following bilateral occipital cardioembolic strokes. He denied blindness and confabulated that he could see objects in front of him.

**Visual Agnosia**-a condition in which a person can see but cannot recognize or interpret visual information, due to a disorder in the parietal lobes.

An individual with visual object agnosia can see familiar objects, but when asked to identify the object, they cannot recognize them or interpret visual information.

**Visual agnosia**, for **example**, is an inability to name or describe the use for an object placed in front of an individual, when just looking at it. one still be able to reach for it and pick it up, can also use their sense of touch to identify what it is or its use once the person holds it.




There are **three different types of visual agnosia**

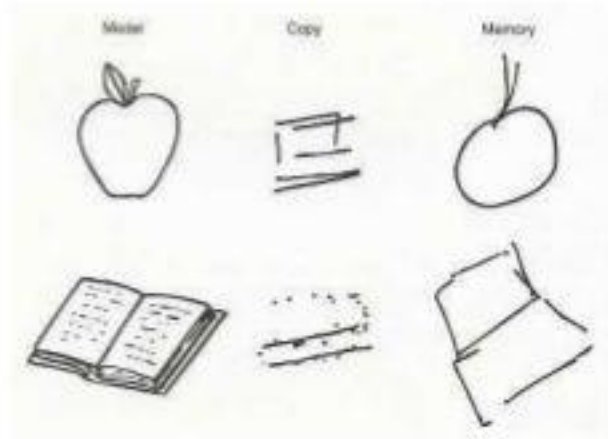
- i. Apperceptive visual agnosia**-affect the patient's ability to copy a picture of an object. The patient cannot tell the difference between shapes.
- ii. Associative visual agnosia**- the patient can copy the picture but cannot identify what the image is. For eg- can copy an image of a bike but cannot identify that it is a bike.
- iii. Integrative visual agnosia**- the patient can also copy an image but cannot integrate parts of an image into a whole.

# Visual Agnosia

- Apperceptive Visual Agnosia
  - Cannot recognize by shape
  - Cannot copy drawings
  - Often involves 'prosopagnosia'



- Associative Visual Agnosia
  - Can copy, but unaware what it is; cannot assign meaning to object
  - Difficulty in transferring visual info into words



**Visual object Agnosia-** Visual agnosia is an impairment in recognition of visually presented objects, cannot identify visual object but can identify by touch, sometimes even without recognizing objects, patient can use the object and when asked to name the uses, he is unable to do so.

### Object agnosia



**Simultaneous agnosia-** Also called simultanagnosia. It is a rare neurological disorder characterized by the **inability of an individual to perceive more than a single object at a time.**

The term simultanagnosia was first coined **in 1924 by Wolpert** to describe a condition where the affected individual could see individual details of a complex scene but failed to grasp the overall meaning of the image.

Simultanagnosia can be divided into two different categories:

1. dorsal
2. ventral.

Ventral occipito-temporal lesions cause a mild form of the disorder, while dorsal occipito-parietal lesions cause a more severe form of the disorder.

For instance, if presented with an image of a table containing both food and various utensils, a patient will report seeing only one item, such as a spoon. If the patient's attention is redirected to another object in the scene, such as a glass, the patient will report that they see the glass but no longer see the spoon. As a result of this impairment, simultanagnosic patients often fail to comprehend the overall meaning of a scene.

## Simultanagnosia



**Patients suffering from Simultanagnosia and Balint's syndrome will only report the features they are presently looking at but will not be able to understand the contents of the scene.**

Prosopagnosia (from Greek *prósōpon*, meaning "face", and *agnōsía*, meaning "non-knowledge"), also called face blindness, is a cognitive disorder of face perception in which the ability to recognize familiar faces, including one's own face (self-recognition), is impaired, while other aspects of visual processing (e.g., object discrimination) and intellectual functioning (e.g., decision-making ) remain intact.



## Apperceptive

*Apperceptive prosopagnosia* has typically been used to describe cases of acquired prosopagnosia with some of the earliest processes in the face perception system. The brain areas thought to play a critical role in apperceptive prosopagnosia are right occipital temporal regions. People with this disorder cannot make any sense of faces and are unable to make same–different judgments when they are presented with pictures of different faces. They are unable to recognize both familiar and unfamiliar faces. In addition, apperceptive sub-types of prosopagnosia struggle recognizing facial emotion. However, they may be able to recognize people based on non-face clues such as their clothing, hairstyle, skin colour, or voice.

## Associative

*Associative prosopagnosia* has typically been used to describe cases of acquired prosopagnosia with spared perceptual processes but impaired links between early face perception processes and the semantic information we hold about people in our memories. Right anterior temporal regions may also play a critical role in associative prosopagnosia. People with this form of the disorder may be able to see whether photos of people's faces are the same or different and derive the age and sex from a face (suggesting they can make sense of some face information) but may not be able to subsequently identify the person or provide any information about them such as their name, occupation, or when they were last encountered.



## Developmental

*Developmental prosopagnosia* (DP), also called *congenital prosopagnosia* (CP), is a face-recognition deficit that is lifelong, manifesting in early childhood, and that cannot be attributed to acquired brain damage. A number of studies have found functional deficits in DP both on the basis of EEG measures and fMRI. It has been suggested that a genetic factor is responsible for the condition. The term "hereditary prosopagnosia" was introduced if DP affected more than one family member, essentially accenting the possible genetic contribution of this condition.

**In pure colour agnosia**, patients have difficulty naming or pointing to named colours, despite relatively preserved colour perception (i.e., retaining the ability to match colours or to identify the numbers on the Ishihara plates). They also have difficulty matching colours, either verbally or visually, to familiar collared objects (e.g., identifying the colour normally associated with cherries, lettuce, or bananas).

Relatively rare, pure colour agnosia must be distinguished from other disturbances of colour perception and colour naming (*colour anomia*).

**In colour blindness**, the individual is unable to perceive or distinguish either certain colours or possibly all colour. In the latter case, the world is seen in shades of black and white. While colour blindness is usually congenital, it can also be acquired, a condition known as *central achromatopsia*.

# Color agnosia

- **Color agnosia:** loss the ability to retrieve color knowledge
- cannot name colors for objects but can sort
- Cant /Remembering the color of object “even by none verbal way” , like painting pumpkin orange or apple red
- Cant /Color composition

Left or bilateral occipitotemporal region  
Inferior temporal , fusiform and right lingual

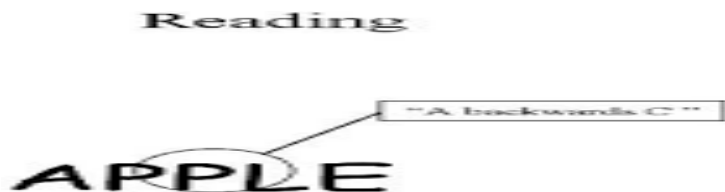
# Color Agnosia



- Tests for a colour agnosia showing patients incorrectly coloured objects.
- A patient who identifies an inappropriately coloured object as correct as to colour, may have colour agnosia.
- For example, a blue banana may seem quite normal to a colour agnostic

**Pure alexia**, also known as **agnosic alexia** or **alexia without agraphia** or **pure word blindness**, is one form of [alexia](#) which makes up "the peripheral dyslexia" group. Individuals who have pure alexia have severe reading problems while other language-related skills such as naming, oral repetition, auditory comprehension or writing are typically intact.

Pure alexia is also known as: "alexia without [agraphia](#)", "letter-by-letter dyslexia", "spelling dyslexia", or "word-form dyslexia". Another name for it is "Dejerine syndrome", after [Joseph Jules Dejerine](#), who described it in 1892.



## **REFERENCES**

**Kolb, B., & Whisaw, I.Q. (1990). Fundamentals of human Neuropsychology. New York: Freeman, W.H**

**Singh, A.K. Neuro Manovigyan, Patna: Motilal Banarsidas**

**Google images.**

**Thank you for your  
Attention**