

# Splenic rupture in a patient with pelvic abscess and sepsis

John AK<sup>1</sup>, MS, FRCS

**ABSTRACT** A 49-year-old man underwent appendicectomy through a Lanz incision for necrotic appendicitis. He subsequently developed pelvic abscess in the postoperative period, which was drained under computed tomography (CT) guidance. The bacteriology of pus swabs taken during appendicectomy and abscess drainage revealed coliforms. Six days after appendicectomy, the patient had an acute collapse due to rupture of the spleen, which was treated by splenectomy. CT of the abdomen at the time of abscess drainage had confirmed a normal spleen. Histopathological examination of the spleen revealed nonspecific acute splenitis – red pulp congested and infiltrated with neutrophils complicated by rupture. We postulate the abdominal source of sepsis and associated inflammatory response as the cause for the splenic pathology and rupture.

Keywords: abdomen, sepsis, splenic rupture  
Singapore Med J 2012; 53(1): e6–e8

## INTRODUCTION

We describe the case of a man who developed splenic rupture during the postoperative period following treatment of necrotic appendicitis and pelvic abscess. Computed tomography (CT) of the abdomen revealed haemoperitoneum and splenic rupture, which was treated by emergency splenectomy. Histopathological examination of the spleen revealed features of acute splenitis. This case illustrates a clinical entity where sepsis-associated splenitis and congestion precipitated acute splenic rupture.

## CASE REPORT

A 49-year-old Caucasian man presented with right lower quadrant abdominal pain and tenderness, which was suggestive of acute appendicitis. He did not have any comorbid illness. An appendicectomy was performed through a Lanz incision for necrotic purulent appendicitis associated with local peritonitis. The local area and pelvis were irrigated with warm normal saline in order to clear all purulent fluid. There were no immediate postoperative complications.

On postoperative Day 3, the patient had developed a temperature of 38°C, heart rate > 100/min, elevated white cell count and tenderness in the suprapubic area, which was suggestive of abdominal sepsis. He had been on cefuroxime and metronidazole as treatment for purulent appendicitis. Ultrasonography of the abdomen revealed a pelvic abscess. The abscess was subsequently drained under CT imaging guidance, which did not show any other intra-abdominal pathology. The bacteriology of the pus swab during appendicectomy and pelvic abscess revealed coliforms.

On the sixth day after appendicectomy, the patient had an acute collapse with abdominal distension, left shoulder tip pain, signs of hypovolaemia and drop in haemoglobin from 150 g/L before the operation to 32 g/L. Emergency CT of the abdomen after resuscitation revealed a ruptured spleen with haemoperitoneum

(Fig. 1). The patient underwent emergency laparotomy and splenectomy. Postoperatively, he developed acute respiratory distress syndrome (ARDS), and needed a period of ventilation before full recovery. Macroscopically, his spleen weighed 200 g; the capsule was stripped off the convex surface with an associated tear of the parenchyma at the hilum. The histopathology of the spleen was reported as nonspecific acute splenitis (Fig. 2) – red pulp congested and infiltrated by neutrophils, and complicated by rupture.

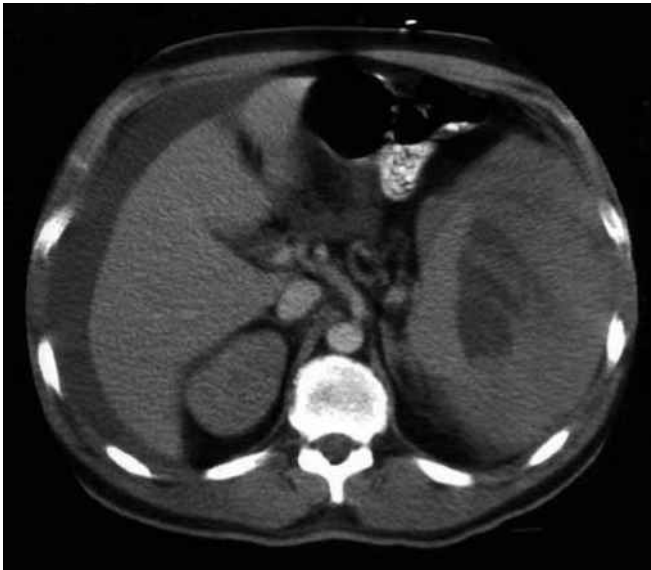## DISCUSSION

The most common cause of splenic rupture in clinical practice is trauma, which accounts for 30% of patients undergoing laparotomy for blunt injury of the abdomen. Other entities are rupture of the spleen with an intrinsic pathology (pathologic rupture) and spontaneous rupture of a macro- and microscopically normal spleen. Atraumatic rupture of the spleen is recognised as a serious and potentially life-threatening surgical condition that often causes diagnostic difficulties due to the nature of presentation. A presentation of acute abdomen in the absence of trauma and other clinical diagnoses, mostly perforated peptic ulcer, is made.<sup>(1)</sup> Occasionally, patients may have clinical features suggesting angina pectoris, myocardial infarction, pulmonary embolism, ruptured ectopic pregnancy, acute pancreatitis and acute appendicitis.<sup>(2,3)</sup> In the presence of symptoms and signs of an acute abdominal condition, especially pain and tenderness in the left upper quadrant, with features of hypovolaemic shock, a diagnostic CT, ultrasonography or laparotomy confirms the diagnosis. In cases of sudden unexpected deterioration of a patient with indistinct clinical features, the diagnosis is usually revealed at autopsy.<sup>(1)</sup>

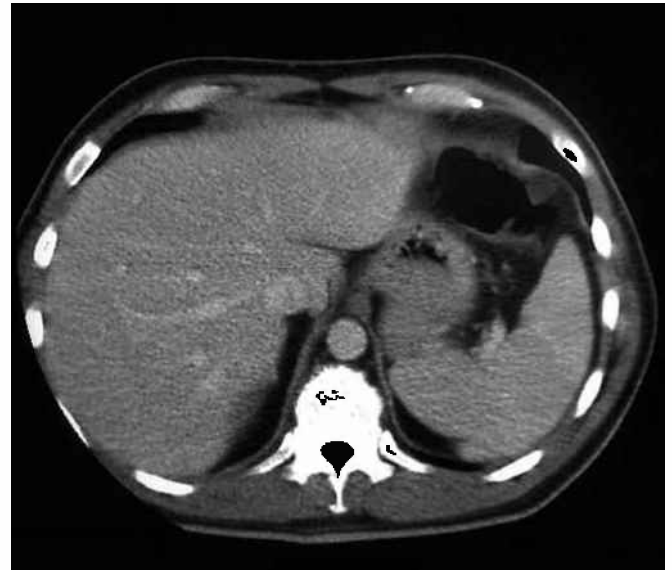Atraumatic rupture of a diseased spleen is considered analogous to pathologic fracture in a diseased bone, which had also been described as occult rupture.<sup>(4)</sup> In clinical practice, it is difficult to

<sup>1</sup>Department of Colorectal Surgery, Princess Alexandra Hospital, UK

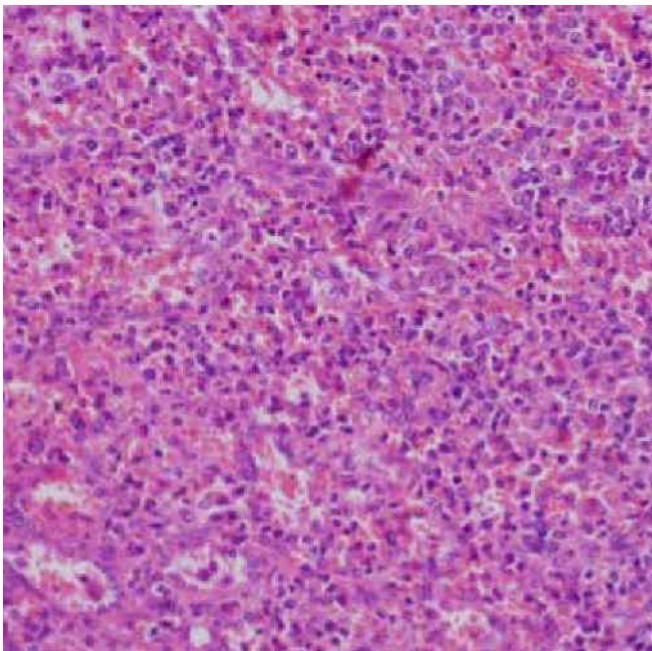
**Correspondence:** Dr Ajo K John, Registrar, Department of Colorectal Surgery, Princess Alexandra Hospital, Hamstel Road, Harlow, Essex CM20 1QX, UK. ajokjohn@yahoo.com



**Fig. 1** CT image of the abdomen shows the ruptured spleen and haemoperitoneum.



**Fig. 3** CT image of the abdomen shows the normal spleen.



**Fig. 2** Histopathology of the spleen shows red pulp congested and infiltrated by neutrophils (Haematoxylin & eosin, × 40).

identify and irrelevant to distinguish pathologic rupture and rupture of the spleen following trivial trauma and due to physiological activities such as coughing or sneezing. Therefore, spontaneous splenic rupture is defined as rupture of a normal spleen without identifiable trauma.<sup>(2)</sup>

Pathologic rupture of the spleen has been reported in numerous infectious, inflammatory, neoplastic, haematological and metabolic conditions. The commonly reported aetiologies for pathologic splenic rupture are infectious mononucleosis, malaria, kala-azar, viral hepatitis A, typhoid fever, legionellosis, rubella, cytomegalovirus, infective endocarditis, pregnancy, leukaemia, lymphoma, idiopathic thrombocytopenic purpura, amyloidosis, heparin therapy, splenic neoplasia, systemic lupus erythematosus and vasculitis.<sup>(2)</sup> Rupture of the spleen may occur in the course of acute infections – after appendicectomy, with a carbuncle

and marked toxæmia, with a septic hand and with a whitlow.<sup>(5)</sup> The mechanisms implicated in splenic rupture are increase in intrasplenic pressure due to oedema, cellular hyperplasia, or parenchymal or sub-capsular haematoma in altered haemostatic states; fragmentation and dissolution of the fibrous capsule by infiltrating cells; splenic thrombosis or infarction with consequent sub-capsular haemorrhage and rupture; traction or compression tear of the splenic capsule due to contraction of the diaphragm or abdominal musculature during coughing, sneezing, defecation and movements; and aneurysm formation in splenic vessels in necrotising vasculitis (polyarteritis nodosa).<sup>(2,3,6-8)</sup>

Spontaneous rupture of a normal spleen is a highly debated entity with various views on its pathogenesis. The condition is so unusual that its existence has been questioned, and some argue that these are cases of delayed traumatic rupture where the history is not properly elicited or the pathology may be completely destroyed by rupture originating in the diseased area.<sup>(1,2,5,9-12)</sup> Orloff and Peskin concluded that a small number of cases represent true instances of spontaneous rupture of the spleen.<sup>(1)</sup> To establish the above diagnosis, they defined the following criteria: absence of a history of trauma; absence of perisplenic adhesions and scarring; absence of any disease that adversely affects the spleen; and a macroscopically and microscopically normal spleen.<sup>(1)</sup> Crate and Payne suggested a fifth criterion – absence of a significant rise in viral antibody titre of types known to have splenic involvement in acute and convalescent sera.<sup>(9)</sup> In view of the current evidence, it would be difficult to confirm the diagnosis as spontaneous splenic rupture in an emergency clinical situation, and such a diagnosis is questionable.

This report describes pathologic splenic rupture following acute splenitis and congestion. Important features of the histopathology examination were congestion and neutrophil infiltration of the red pulp and fresh haemorrhage at the areas of capsular tear. The underlying pathophysiology of rupture is judged as an increase in intrasplenic pressure due to oedema and cellular

hyperplasia as part of an acute inflammatory response following bacteraemia from the pelvic abscess. CT of the abdomen at the time of drainage of the pelvic abscess showed a normal spleen (Fig. 3). The patient had clinical features of sepsis with documented source of infection. Bacteraemia and inflammatory response in the spleen following drainage procedure is the suggested mechanism for splenic pathology. Splenic rupture has been reported to be associated with bacterial infections: pneumonia (*Legionella (L.) pneumophila*, *Coxiella (C.) burnetii*, *Haemophilus influenzae*, *Streptococcus pneumoniae*), salmonellosis (*Salmonella typhi*, *Salmonella dublin*), and infective endocarditis (Streptococci); and sepsis (Meningococci).<sup>(3,6-8,13-15)</sup> Acute splenitis and splenic enlargement were described in cases of *L. pneumophila* and *C. burnetii* infections.<sup>(3)</sup> In this report, the microorganisms involved were coliforms, which had not been previously reported. A bacteriology assessment of splenic tissue would have been helpful in earlier and index cases for a complete understanding of the involved disease process.

The treatment for pathologic splenic rupture is splenectomy, although there have been reported instances of non-operative management. The merits of non-operative management have to be considered with respect to the clinical presentation. In cases of profound deterioration, splenectomy must be performed as a life-saving procedure. The most significant subject matter is the recognition of splenic rupture as the cause of sudden deterioration in a patient on treatment for a particular clinical condition. The value of high index of suspicion directed by thorough clinical

assessment and awareness of the reported type of clinical entity is important for appropriate treatment decisions.

## REFERENCES

1. Orloff MJ, Peskin GW. Spontaneous rupture of the normal spleen; a surgical enigma. *Int Abstr Surg* 1958; 106:1-11.
2. Debnath D, Valerio D. Atraumatic rupture of spleen in adults. *J R Coll Surg Edinb* 2002; 47:437-45.
3. Domingo P, Rodríguez P, López-Contreras J, et al. Spontaneous rupture of spleen associated with pneumonia. *Eur J Clin Microbiol Infect Dis* 1996; 15:733-6.
4. McMahon MJ, Lintott JD, Mair WS, Lee PW, Duthie JS. Occult rupture of the spleen. *Br J Surg* 1977; 64:641-3.
5. Susman MP. Spontaneous rupture of the spleen. *Br J Surg* 1927; 15:47-54.
6. Julià J, Canet JJ, Lacasa XM, González G, Garau J. Spontaneous spleen rupture during typhoid fever. *Int J Infect Dis* 2000; 4:108-9.
7. Buist MD, Power RG, Keeley SR, Matthews NT. Severe meningococcal septicaemia associated with splenic rupture. *Med J Aust* 1991; 155:713-4.
8. Vergne R, Selland B, Gobel FL, Hall WH. Rupture of the spleen in infective endocarditis. *Arch Int Med* 1975; 135:1265-7.
9. Crate ID, Payne MJ. Is the diagnosis of spontaneous rupture of a normal spleen valid? *J R Army Med Corps* 1991; 137:50-1.
10. Baillie RW. Delayed haemorrhage following traumatic rupture of the normal spleen simulating spontaneous rupture. *Postgrad Med J* 1952; 28:494-6.
11. Zukerman C, Jacobi M. Spontaneous rupture of the normal spleen. *Arch Surg* 1937; 34:917-28.
12. Coleman AH. Spontaneous rupture of the normal spleen. *Br J Surg* 1939; 27:173-5.
13. Kazemy AH. Spontaneous rupture of spleen due to Q fever. *South Med J* 2000; 93:609-10.
14. Holmes AH, Ng VW, Fogarty P. Spontaneous rupture of the spleen in Legionnaires' disease. *Postgrad Med J* 1990; 66:876-7.
15. Rest JG, Seid AS, Rogers D, Goldstein EJC. Pathologic rupture of the spleen due to *Salmonella dublin* infection. *J Trauma* 1985; 25:366-8.