

# High Resolution MRI Study of Circumlental Space in the Aging Eye

Susan A. Strenk, PhD; Lawrence M. Strenk, PhD; John L. Semmlow, PhD

The controversy and confusion regarding the mechanism of presbyopia results in large part from an inability to directly measure the anatomical structures in question. In this study, magnetic resonance imaging (MRI) has been used to directly detect age related changes in circumlental space of 47 emmetropes and mild myopes. MRI offers unparalleled soft tissue contrast, providing differentiation between muscle and other soft tissue, thus allowing the ciliary muscle to be visualized. Moreover, MRI produces undistorted images of the entire lens surface. As previously presented<sup>1</sup>, both the ciliary muscle ring diameter and the circumlental space decrease with age, the decrease in circumlental space is primarily the result of an age dependent decrease in the ciliary muscle ring diameter since the length of the lens equator is not significantly correlated with age.

Recently, investigators<sup>2</sup> found evidence that the lens is not symmetrically positioned in the ciliary ring of the rhesus monkey. Specifically, Croft and colleagues<sup>2</sup> reported that during resting accommodation, the temporal ciliary processes are 0.21 mm closer to the lens equator than to the nasal ciliary processes. Here, we present MRI based on data that demonstrate this asymmetry also occurs in the position of the human lens.

## METHODS

A 1.5 Tesla MR imager (1.5T-Signa, General Electric Medical Systems, Waukesha, WI) was used to obtain images from 47 subjects, ages 21 through

83. The soft tissue image contrast available with MRI is superior to that obtained with any other imaging modality. Moreover, by varying MR pulse sequences and timing parameters, desired contrast differences can be maximized. We used a T1 weighted spin-echo pulse sequence to differentiate between muscle and other soft tissue, while clearly delineating lens shape. A series of contiguous axial slices through the lens were acquired simultaneously, requiring 5 minutes. These images were collected with a 4 cm field-of-view and 256 x 256 pixel matrix, resulting in 0.156 mm in-plane resolution. The contiguous 3 mm thick axial slices ensured that the entire lens was captured and allowed the desired "center" slice as well as its flanking slices to be evaluated in order to determine the lens dimensions, as previously described.<sup>3</sup> A custom eye coil consisting of a three-turn solenoid with a 2.5 cm diameter, positioned directly around the eye, allowed high-resolution images of the accommodative structures to be acquired. An accommodative stimulus apparatus device was designed to present binocular (accommodative and disparity) stimuli and provided a fixation target to reduce eye movements during the scan. Details of the stimulus device are presented elsewhere.<sup>3</sup> Binocular targets were positioned at distance equivalent to 0.1 D, at which point resting accommodation is expected.

The images were analyzed using the NIH Image 1.61 software package; lens and ciliary muscle profiles were obtained from the images by digital filtering. The effect of the 3 mm slice thickness on the lens and ciliary muscle measurements was compensated for as previously described.<sup>3</sup> The ciliary muscle was identified as a roughly triangular pixel cluster, hypointense to the ciliary body, extending posteriorly from the iris root. The nasal circumlental space was calculated as the distance between the nasal muscle apex and the nasal lens equator. Corresponding measurements were made for the temporal circumlental space. Repeatability was established by running multiple imaging studies on two subjects ages 22 and 49; measurements varied less than 1 pixel (0.156 mm).

---

*From the Department of Surgery (Bioengineering), UMDNJ-Robert Wood Johnson Medical School, New Brunswick, NJ (SA Strenk, Semmlow), Diagnostics Instruments, Inc., Aurora, OH (LM Strenk), and the Department of Biomedical Engineering, Rutgers - The State University of New Jersey, Piscataway, NJ (Semmlow).*

*Published previously in the February, 2000 Technical Digest of the Optical Society of America, and reprinted here with permission of the Optical Society of America.*

*Correspondence: Susan A. Strenk, PhD, 201 Belcourt Lane, Aurora, OH 44202. Tel: 330.562.1278; E-mail: larrysdii@earthlink.net*

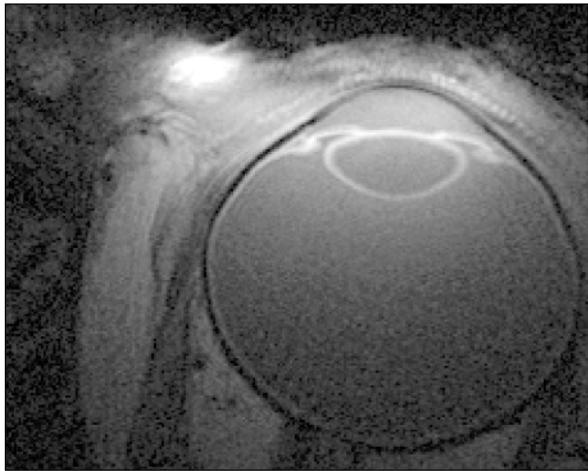


Figure 1. High resolution MR image; note reproduction results in some loss of image quality.

### RESULTS

Magnetic resonance images were obtained from each subject for relaxed accommodation. A representative image is shown in Figure 1. As previously described<sup>1</sup>, a decrease in lens diameter was weakly correlated with age, thus the age dependent decrease in circumferential space is primarily a result of the decrease in the ciliary ring inner diameter. Figure 2 demonstrates the asymmetry and age dependence of the circumferential space. At age 20, the temporal circumferential distance is approximately 0.37 mm less than the nasal. Both nasal and temporal circumferential space decrease at approximately the same rate with age; thus, the overall asymmetry remains essentially fixed with age. Both nasal and temporal circumferential spaces decrease by approximately 0.47 mm by age 80.

### DISCUSSION

Our findings on the asymmetrical lens position are consistent with the findings of Croft and coworkers.<sup>2</sup> In both studies, the temporal circumferential space was smaller than the nasal for accommodation at rest. Croft and coworkers<sup>2</sup> measured the distance from the ciliary processes to the lens equator in rhesus monkeys and found the difference to be 0.21 mm. Conversely, we measured the distance from the ciliary muscle apex to the lens equator in humans, and found a larger absolute difference

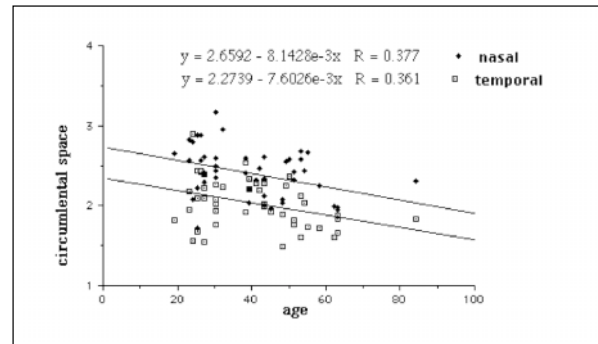


Figure 2. Asymmetry and age dependence of the circumferential space.

(.37 mm). These nasal/temporal asymmetries of the circumferential space may result from nasal/temporal differences in ciliary muscle dimensions; the temporal ciliary muscle is larger than the nasal, probably due to a difference in uveal tissue development caused by the asymmetrical placement of the optic nerve.<sup>4</sup> The implications of asymmetrical and reduced circumferential space on the zonular apparatus is under investigation.

High resolution MRI imaging of the eye was employed to examine the affect of aging on the circumferential space. As previously presented, we note that the observed decrease in the circumferential space with age is primarily a result of the inward movement of the ciliary muscle ring that occurs with advancing age. For the unaccommodated eye, the nasal circumferential space is greater than the temporal circumferential space in the pre-presbyope and remains so throughout life. We are currently evaluating the circumferential space in the accommodated eye.

### REFERENCES

1. Strenk SA, Semmlow JS, Strenk LS, Epstein D, Gronlund J, DeMarco JK. High resolution MRI of the zonular space in presbyopes. Proceedings of VSIA, OSA Proceeding Series, Optical Society of America, Washington DC, 1999.
2. Croft MA, Glasser A, Gabelt B, Ebbert T, Heatly GA, Kaufman PL. Lens and ciliary muscle function in young and old Rhesus monkeys. Invest Ophthalmol Vis Sci 1999;40(suppl); 361;1999.
3. Strenk SA, Semmlow JL, Strenk LM, Munoz P, DeMarco JK. High resolution MRI of the accommodated lens and ciliary muscle: A preliminary cross-sectional study. Invest Ophthalmol Vis Sci 1999;40(suppl); 1162-1169.
4. Wolf E. Anatomy of the Eye and Orbit, 6th ed. Philadelphia, PA; W.B. Saunders:1970.