

CDR

Columbia Dental Review

proper appliance in a
pediatric patient:

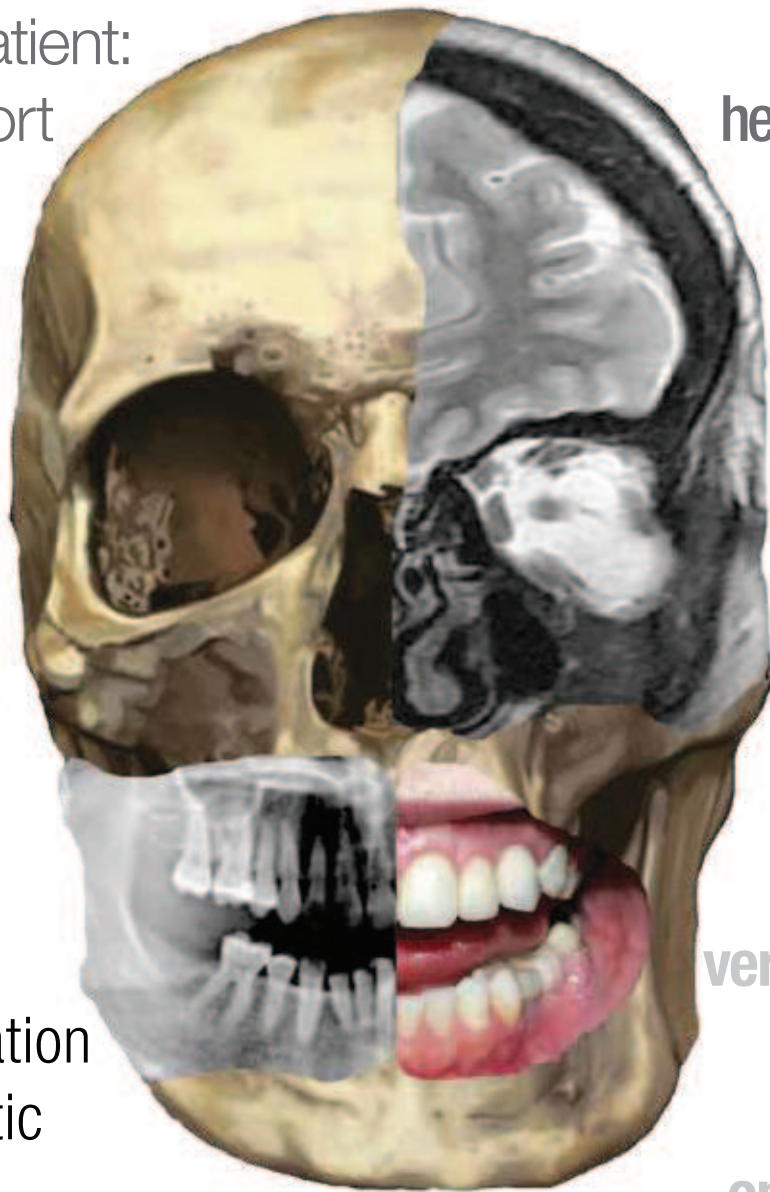a case report
and review

of the
literature

**periapical
cemental
dysplasia**

**and an
adjacent
compound
odontoma**

successful
osseointegration
and prosthetic
loading of a
temporomastoid



implant in the treatment
of congenital

**hemi-anotia: a case
presentation**

management of
tooth agenesis

by orthodontic
space closure:

a case study

**vander woude
syndrome:**

a case study

treating a

**vertically deficient
edentulous**

maxilla with

onlay bone grafts

and a maxillary overdenture



Treating a Vertically Deficient Edentulous Maxilla with Onlay Bone Grafts and a Maxillary Overdenture

Paul Jones Jr¹, Ray Jone DDS², Jason J. Psillakis DDS, MS³

¹Class of 2012, College of Dental Medicine, Columbia University, New York, NY

²General Practice Resident, San Francisco V.A. Hospital, San Francisco, CA

³Assistant Professor of Clinical Dentistry, Division of Prosthodontics, Columbia University College of Dental Medicine, New York, NY

Abstract

The edentulous atrophic maxilla poses several difficulties to prosthodontic rehabilitation. In the case presented here, reconstructive pre-prosthetic surgery with onlay bone block grafts was performed with subsequent implant placement after a delayed healing period. Bone grafts were harvested from the iliac crest. Five of seven implant fixtures integrated successfully. The patient was successfully rehabilitated with an implant-supported overdenture. Implants were splinted using a milled bar with ERA attachments cantilevered distally.

Introduction

The edentulous atrophic maxilla poses several difficulties to prosthodontic rehabilitation. Within the first year of edentulism, a patient's alveolar ridge can drastically change shape in both horizontal and vertical axes. The common progression outlined by Cawood follows from dentate (class 1), to immediate post-extraction (class 2), to an ideal well-rounded ridge form (class 3), to a narrower knife-edge ridge (class 4), to a flat ridge form (class 5), and ultimately to the worst-case scenario of a depressed ridge form involving the basilar bone level (class 6).¹

Alongside the morphologic changes to the alveolar ridge is the loss of key anatomic features needed to support a functional prosthesis including bone height, a class 1 maxillary-mandibular relationship, and ideal muscle attachments. The advent of dental implants has increased the success rate with which partially and fully edentulous patients with non-ideal bone structure can be rehabilitated. Placement of dental implants has become a common practice and there is an increasing amount of reliable data to support their utilization. While higher success rates are attributed to the length of dental implants, an alveolar ridge with a large vertical deficit reduces the success rate of dental implants due to insufficient bone volume housing the fixtures.^{2,4}

Patients with insufficient bone volume require reconstructive pre-prosthetic surgery to increase the bone volume and create an oral environment that allows the accompanying prosthesis to restore function to the patient. A successful prosthesis should be stable and retentive, preserve existing tissues and satisfy the patient's esthetic demands. According to evidence-based literature, current forms of treatment

to increase bone volume are onlay bone grafts³, nasal floor and sinus augmentation⁴, and interpositional graft with Le Fort 1 osteotomy⁵. Onlay bone grafts and interpositional graft with a Le Fort 1 osteotomy are the most commonly used methods, as they produce clinically acceptable results and do not significantly decrease implant survival rates.^{6,7} This case study presents a patient with an edentulous atrophic maxilla that was restored in a two-stage approach. First, the alveolar ridge was augmented with onlay bone block grafts harvested from the iliac crest. Second, implants were placed following an extended healing period.

Case Report

A 46-year old female patient presented to the Columbia-Presbyterian Eastside Dental Faculty Practice with the following chief complaint, "I want teeth to chew, eat, smile, and speak." A complete prosthodontic workup was done, which included radiographs, mounted diagnostic casts, and a review of the remaining teeth and surrounding soft tissues.

The patient presented with a severely resorbed, atrophic edentulous maxilla. The mandible had bilateral edentulous spans, with only #22-27 remaining. (*Figure 1*) Various treatment plans were discussed with the patient for the maxilla, including a complete denture and the possibility of implants. Since the maxilla was severely resorbed and flat, a maxillary complete denture would have a poor prognosis due

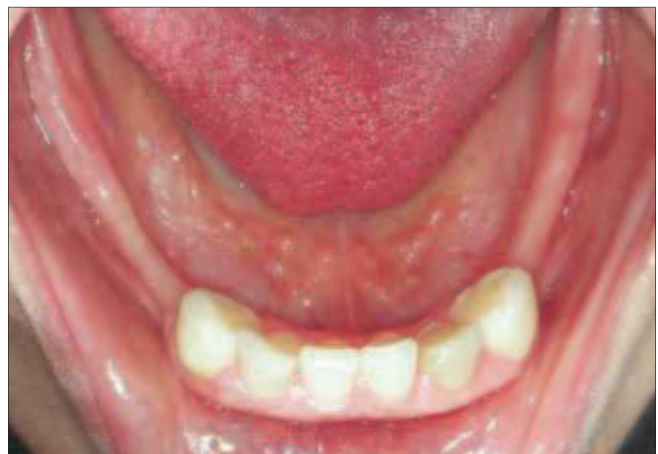

Figure 1 Occlusal view of mandible at initial presentation

Treating a Vertically Deficient Edentulous Maxilla with Onlay Bone Grafts and a Maxillary Overdenture

to insufficient retention, stability and function. Implants in conjunction with maxillary bone grafts were mentioned to the patient. It was explained that the graft would be necessary to augment the quantity of bone available for implant placement and to restore lost facial features, such as cheek and lip support, which had also collapsed due to atrophy. The patient consented and agreed to receive bone grafts and the implants.

The patient underwent pre-prosthetic surgery of the edentulous maxilla with bilateral onlay bone grafts from the iliac crest. This was followed by a two-stage approach for implant fixture placement more than six months after the initial bone graft procedure. The patient had a Cawood class 5 edentulous maxilla that necessitated a large volume of grafted bone to provide sufficient height for implant fixture placement. Five implants were initially placed into the maxilla with the treatment goal of making an overdenture. During stage 2 uncovering of the fixtures, two implants failed and were removed.

The failed sites were allowed to heal naturally and were re-evaluated in six months. Upon reevaluation, two new implant fixtures were placed which did eventually osseointegrate.

After the fixtures were uncovered and healing abutments were placed, new diagnostic cast were made and custom trays were fabricated for a fixture-level final impression. Wax records were made, the cast was mounted, and wax teeth try in was completed with the patient's approval for processing. During treatment, it was decided to splint the implants together with a gold bar since two fixtures had previously failed, and an open palate overdenture design was selected to restore facial contours and esthetics while allowing better speech. (Figure 2,3) The opposing arch was restored with a conventional distal extension removable partial denture. (Figure 4,5) The case was processed, completed, and delivered to the patient's satisfaction. (Figure 6,7) Only one post-op adjustment was necessary to adjust a sore spot noted on the mandibular prosthesis.

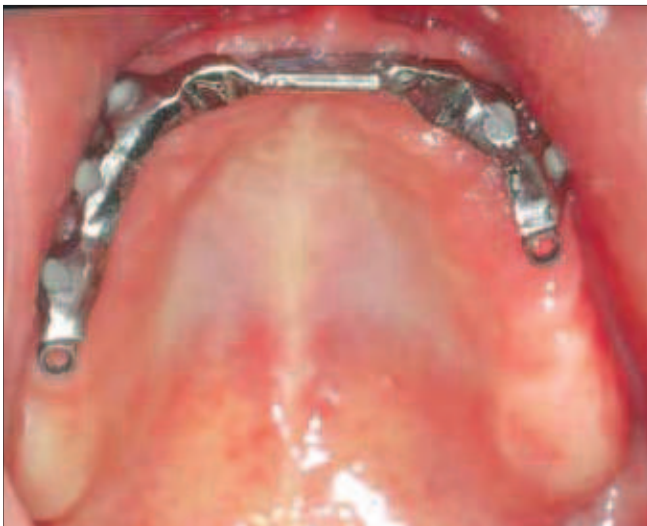

Figure 2 Palatal view of maxilla with splinted bar with ERA attachments

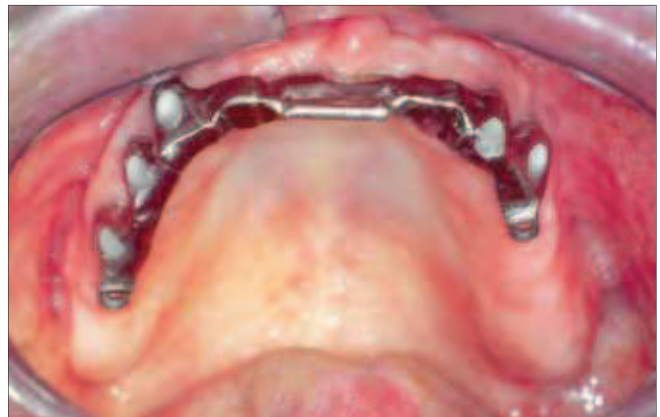

Figure 3 Frontal view of maxilla with splinted bar with ERA attachments

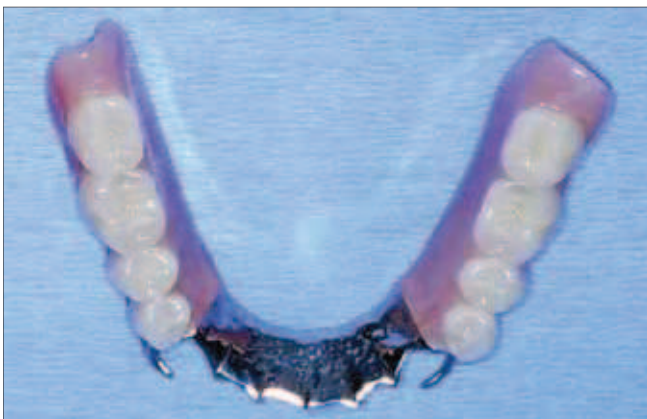

Figure 4 Occlusal view of mandibular RPD

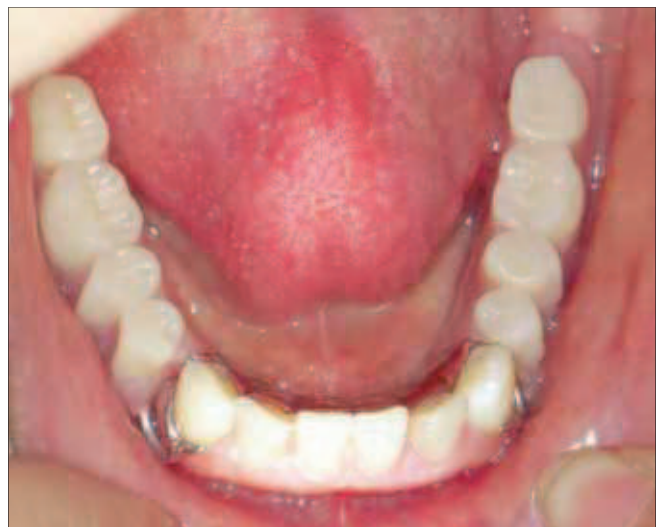

Figure 5 Occlusal view of seated mandibular RPD

Treating a Vertically Deficient Edentulous Maxilla with Onlay Bone Grafts and a Maxillary Overdenture

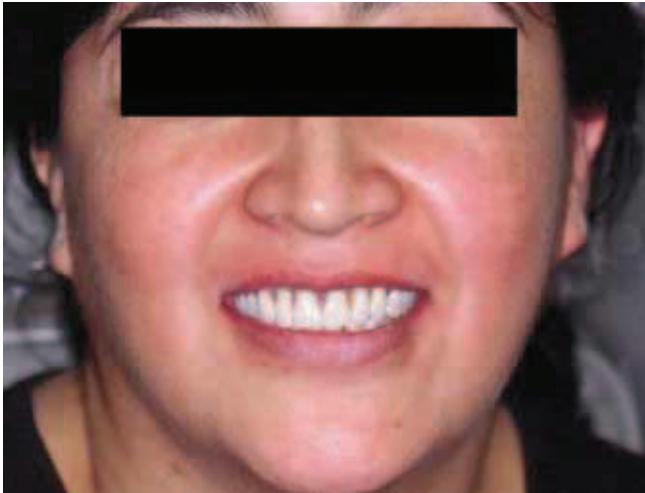

Figure 6 Esthetic photograph showing patient smiling while wearing maxillary prosthesis

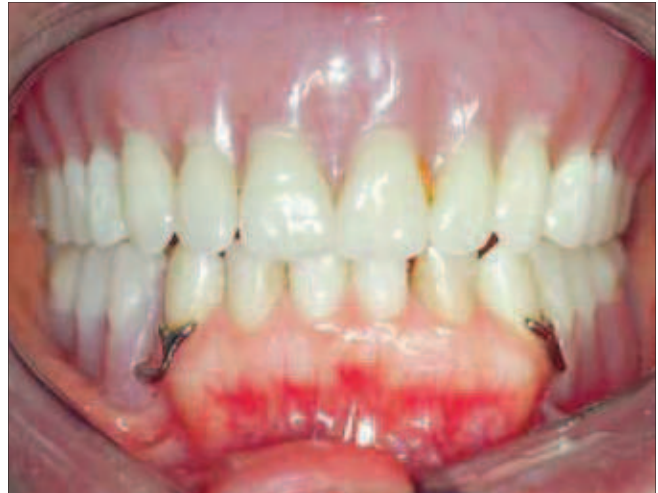

Figure 7 Frontal view of patient in maximum intercuspation while wearing maxillary overdenture and mandibular RPD

Discussion

As described by Cawood and Howell, there are various formations of the edentulous atrophic maxilla posing difficulty for its rehabilitation. In many cases, pre-prosthetic surgery is necessary to augment the maxillary ridge and provide sufficient volume of bone for rehabilitation, especially if an implant-supported prosthesis is planned.¹ As Nystrom and Nilson reviewed (2009), patients who develop a class VI resorption pattern and a poor intermaxillary relationship would benefit most from a Le Fort 1 osteotomy in parallel with an interpositional bone graft and a 4-6 month interval of healing prior to implant placement.^{5,11} However, patients presenting with a class V resorption pattern and acceptable intermaxillary relationship do not require forward re-positioning by a Le Fort 1 osteotomy and would benefit most from an onlay bone block graft. Such a procedure offers the largest volume of bone that can be recouped. However, it should be noted that the graft design has not been shown to affect implant survival rates.⁸

In this case, the iliac crest was chosen as the donor site. The iliac crest offers the greatest amount of corticated bone, the quantity of which determines the amount of graft that is resorbed as well as the quality of bone that remains for implant placement. Larger quantities of corticated bone leads to higher success rates for implant survival.⁹ A two-stage implant approach was chosen in lieu of a one-stage, which would have entailed simultaneous graft and implant placement. While the one-stage procedure does offer the benefit of less surgical intervention and decreased healing time, a two-stage procedure has been shown to be more successful because the graft has integrated; thus placement and angulation of the implant are better controlled.^{5,8} A review of the literature reveals that implant survival is higher when a two-stage approach is attempted (88%) as opposed to a single-stage approach (79%).¹⁰

A principal factor of concern when treating an atrophic maxilla with an onlay bone graft is the duration for which bone resorption occurs. Although grafts require six months to take to the site prior to initiating implant therapy, bone resorption continues to occur for 12 months following graft placement.¹¹ Thus grafted bone may still be undergoing re-modeling processes for an additional six months after implant placement. It is well documented that loss of ridge height can range from 20% to 31% at one year to 44% to 92% at three years.¹¹ Despite early bone loss, implant placement has also been shown to guard against bone resorption, due to the molecular signals initiated by loading feedback through the alveolar bone. Therefore, the possibility for initial resorption must be balanced by long-term stability for the case to be successful. In the case presented here, implants were not placed until over a year after the graft.

Five implants were initially placed as dictated by the patient's finances and the established recommendations by Eckert and Carr.¹² While a minimum of four implants is recommended for a favorable outcome, a higher number of implants allows for the potential failure of one to two implants while still maintaining the minimum number of implants for a successful prosthesis. Thus Eckert and Carr proposed the minimum limit to be six implants. Five implants were placed because maxillary implant overdentures have been documented to have a high implant loss relative to other treatment modalities.^{7,12} Over the course of six years, Narhi et al. reported a cumulative 90% implant survival.¹² Thus in the worst case scenario that one implant is lost during osseointegration or over the long-term, there are still sufficient implants for long-term success of an overdenture. Replacing the two failed implants in this case satisfies the minimum of four implants needed for a favorable outcome, while also compensating for the failure of one implant in the future.

Treating a Vertically Deficient Edentulous Maxilla with Onlay Bone Grafts and a Maxillary Overdenture

In this case, the implant survival rate after one year was 71.4%. There remains substantial variability in the predicted survival rates reported in the literature. In a 3-year longitudinal study, Astrand and Branemark reported an implant-in-graft survival rate of 75%, while Sjostrom and Sennerby reported implant-in-graft survivals of 90% at a 3-year follow up.^{13,8} The literature regarding failure rates and factors causing implant-in-graft failure remains controversial.

The role of patient gender in implant-in-graft survivals has been shown by Sjostrom to be a statistically significant variable (14% female fail rate, 3% male fail rate) while Laverick and Cawood found no statistical difference in the survival of implants placed in male and female patients.⁶

The reported timing of failed osseointegration in the literature is also not consistent. In the case presented, the two failures occurred prior to loading the implants. Esposito and Hirsch, along with Barone and Covani reported a higher rate of failure occurring prior to loading. Astrand and Branemark in their 1996 three-year longitudinal study reported contrasting data: 7 of 23 failures occurred prior to loading while 16 of 23 failures occurred after loading.^{14,15}

While further data relating implant survival to other variables needs to be gathered, Sjostrom brings up an interesting point: multiple implant failures are not uniformly distributed in a pool of patients but rather clustered around specific patients.⁸ In Sjostrom's 2007 article, while seven of ten patients lost one to two implants (not affecting the supra-structure of the overlying prosthesis), one patient lost five implants, accounting for close to half of the failures in their study. Similar distributions were reported by Lekholm and Johansson in separate studies. This could suggest a need for more research tailored to address patient factors that affect the local environment in which implants osseointegrate, as most literature has focused on characteristics of the implants themselves and the manner in which they are placed in relation to their success. Indeed it is the catastrophic loss of multiple implants in a single patient that threatens the long-term rehabilitation, rather than individual implant failure. In the case presented, implant sites that failed were allowed to heal naturally before replacing the implants lost.

For the design of the prosthesis, a milled-splinted bar was utilized as the understructure for the maxillary overdenture with two ERA attachments cantilevered distally. (Figure 8) Unsplinted anchorage designs require less space between the implant platform and the incisal edge, may be more hygienic, and are less technique sensitive to place.¹² However, splinted designs have been shown both in vivo and in vitro to provide more retention than unsplinted designs when subjected to vertical and oblique forces. Splinted designs also allow for correction of implant abutment angulations if

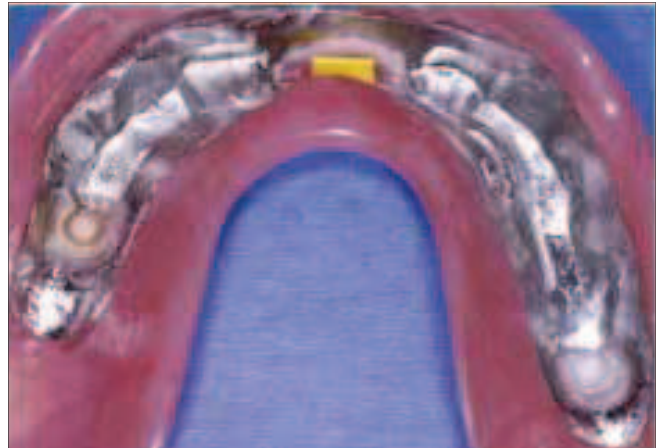


Figure 8 Close up image of maxillary overdenture understructure showing clip and distal ERA attachments

needed.¹² Thus a splinted design was utilized to maximize retention given that the implants were placed in grafted tissue and a palateless design was chosen to maximize patient comfort. (Figure 9,10) A milled bar was utilized because

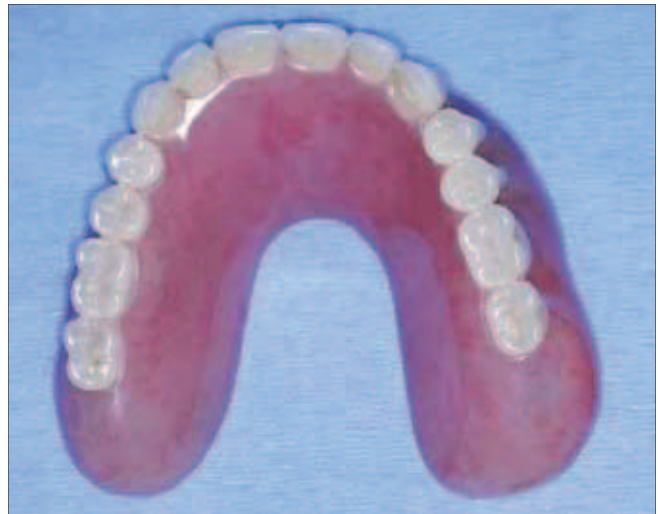

Figure 9 Cameo view of U-shaped palate-less maxillary overdenture

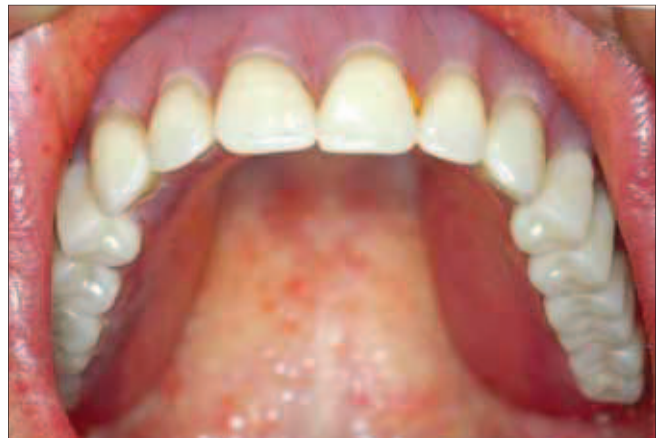

Figure 10 Palatal reflection of seated maxillary overdenture

Treating a Vertically Deficient Edentulous Maxilla with Onlay Bone Grafts and a Maxillary Overdenture

a relatively high number of non-symmetrical implants were to be connected. Distally placed ERA attachments have also been shown to increase retention of bar overdentures and thus were included in the design as well.¹² However, it should be noted that bars with distal cantilevers tend to increase the load on the terminal implants by a factor of greater than three.¹²

Conclusion

This article describes the management and treatment rationale for rehabilitating a patient with an atrophic edentulous maxilla. The treatment protocol of using an onlay bone graft harvested from the iliac crest and an implant-supported overdenture successfully restored the patient to function. In this case, five out of seven implant fixtures achieved integration to maintaining a minimum number of implants for a favorable prognosis. Overdentures with a milled bar and ERA attachments provided stability for a palateless design to maximize comfort and function.

References

1. Cawood JI, Howell RA (1988) A classification of the edentulous jaws. *Int J Oral Maxillofac Surg* 17: 232.
2. Chiapasco M, Zaniboni M, Rimondini L (2007) Autogenous onlay bone grafts vs. alveolar distraction osteogenesis for the correction of vertically deficient edentulous ridges: a 2-4 year prospective study on humans. *Clin Oral Impl Res* 18: 400- 432.
3. Nystrom E, Ahlqvist J, Legrell PE, Khanberg KE (2002) Bone graft remodeling and implant success rate in the treatment of the severely resorbed maxilla: a 5-year longitudinal study. *Int J Oral Maxillofac Surg* 31: 158-164
4. Lundgren S, Nystrom E, Nilson H, Gunne J, Lindhagan O (1997) Bone grafting to the maxillary sinuses, nasal floor and anterior maxilla in the atrophic edentulous maxilla: a two-stage technique. *Int J Oral Maxillofac Surg* 26: 428-434
5. Nystrom E, Lundgren S, Gunne J, Nilson H (1997) Interpositional bone grafting and Le fort 1 osteotomy for reconstruction of the atrophic edentulous maxilla: a two-stage technique. *Int J Oral Maxillofac Surg* 327- 423*****
6. Laverick S, Summerwill J, Cawood JI (2008) Ten years of experience with the anterior maxillary and mandibular osteoplasty (class IV ridges): a retrospective analysis of implant survival rates. *Int J Oral Maxillofac Surg* 37: 415-418
7. Clayman C (2006) Implant reconstruction of the bone-grafted maxilla: review of the literature and presentation of 8 cases. *J Oral Maxillofac Surg* 64: 674-682
8. Sjostrom M, Sennerby L, Nilson H, Lundgren S (2007) Reconstruction of the atrophic edentulous maxilla with free iliac crest grafts and implants: a 3-year report of a prospective clinical study. *Clin Implant Dent Relat Res* 9(1):46-59
9. Isaksson S, Alberius P (1992) Maxillary alveolar ridge augmentation with onlay-bone grafts and immediate endosseous implant *J of Cranio-Maxillo-facial Surgery* 20: 2-7
10. Blomqvist JE, Alberius P, Isaksson S (1997) Sinus inlay bone augmentation: comparison of implant positioning after one or two-staged procedures. *J Oral Maxillofac Surg* 55(8): 804-810
11. Nystrom E, Ahlqvist J, Gunne J, Johnberg KE (2004) 10-year follow up on onlay bone grafts and implants in severely resorbed maxillae. *Int J Oral Maxillofac Surg* 33: 258-262
12. Sadowsky S (1997) Treatment considerations for maxillary implant overdentures: a systematic review/ *J Prosthet Dent* 97(6): 340-348
13. Astrand P, Nord PG, Branemark PI (1996) Titanium implants and onlay bone graft to the atrophic edentulous maxilla: a 3 year longitudinal study. *Int J Oral Maxillofac Surg* 25: 25-29
14. Esposito M, Hirsch JM, Lekholm U, et al (1998) Biological factors contributing to failures of osseointegrated oral implants: success criteria and epidemiology. *Eur J Oral Sci* 106: 527
15. Barone A, Covant U (2007) Maxillary alveolar ridge reconstruction with nonvascularized autogenous block bone: clinical results. *J Oral Maxillofac Surg* 65: 2039-2046

The Columbia Dental Review seeks to address topics of clinical concern. The Editorial Board welcomes articles from students, faculty, and attendings from affiliated hospitals of the College of Dental Medicine of Columbia University.

The case report should be organized in the following manner:

Abstract

The abstract summarizes the principal points of the case report and specific conclusions that may have emerged in the discussion. It should be limited to less than 250 words.

Author Information

A description of each author's degrees, titles, department, and affiliation should be given.

Introduction

The introduction should provide a brief description of the topic, as well as any relevant epidemiology and current opinion as documented in the literature.

Case Report

A description of the case(s), including pertinent photographs.

Discussion

A thorough review of the literature, including other reported cases that are relevant to the case(s) presented or reported.

Conclusion

Based on the present case(s) and the discussion.

References

The authors should be listed in the order in which they appear in the articles. In the case of multiple authors, all authors' names must be given.

Within the text citations of these references should appear as follows:

(Valverde et al, 2005), (Cowin and Luo, 1997), and (Drake et al, 2005), or (Valverde et al, Cowin and Luo, Drake et al 1,2,3)

To cite a journal article:

Valverde P, Kawai T, Taubman MA (2005) Potassium channel-blockers as therapeutic agents to interfere with bone resorption of periodontal disease. J Dent Res 84: 488-499.

To cite a chapter in a book:

Cowin SC, Luo G (1997) Modeling of ingrowth into implant cavities along the bone implant surface. In: Osseointegration in Skeletal Reconstruction and Joint Replacement (PI Brånemark, BL Rydevik, R Skalak, Eds) Chicago, Quintessence Publishing Co, Inc, pp 57-72.

To cite a book:

Drake RL, Vogl W, Mitchell AWM (2005) Gray's Anatomy for Students. Philadelphia, Elsevier.

To cite a website:

American Dental Association. Estrogenic effects of Bisphenol A lacking in dental sealants. ADA Position Statement. 2000. Available at: "www.ada.org/prac/position/ seal-est.html". Accessed April 4, 2005.

Figures and Manuscripts

Image files and manuscripts will be accepted on CD with author's name printed on the CD. Image files should be of high-resolution quality and should be submitted in TIFF, TIF, TGA, GIF or JPEG format. A brief caption in the order in which they are mentioned should be submitted on a separate page. The manuscript should not exceed 20, letter size, double-spaced pages and should be written in a text editor, preferably Microsoft® Office Word. Both, the manuscript and figures, should be submitted in printed format as well as on CD.