

# Knee Disarticulation \*

## A NEW TECHNIQUE AND A NEW KNEE-JOINT MECHANISM\*\*

By ROBERT MAZET, JR., M.D.†, and CHARLES A. HENNESSY, C.P.O.‡  
*Los Angeles, California*

*From the Orthopaedic Service, Wadsworth Hospital, Veterans Administration Center, the University of California Medical Center, and the Orthopaedic Hospital, Los Angeles*

It is the purpose of this presentation to review published experience with disarticulation through the knee, to describe a new operative technique designed to produce a more serviceable stump, and to introduce a new type of prosthesis for this stump, including an innovation in the knee mechanism.

The primary requirements for a satisfactory amputation stump in the lower extremity are:

1. The stump must be covered by healthy, well nourished, full-thickness skin, that is free of painful scars and possesses good sensation;
2. Weight-bearing must be distributed over as large an area as possible, preferably an area that normally supports the body weight;
3. The stump should be as long as feasible;
4. There must be good muscle control;
5. There should be no bone prominences or severed nerve endings which might be traumatized by the prosthesis;
6. The knee joint should be preserved when possible.

Under certain conditions when it is not possible to do a below-the-knee amputation, definite benefits may sometimes be anticipated from knee disarticulation instead of amputation at a higher level.

Most surgeons in this country, because of the antipathy of limb makers to end-bearing stumps engendered by the fitting problems involved, showed little interest in end-bearing stumps until confronted by the large number of amputees incident to World War II. The resulting experience with the Syme amputation, and the development of a practical prosthesis for limbs amputated at this level, firmly established this amputation as a valuable surgical procedure. The advantages of knee disarticulation, however, have not been widely appreciated. Prosthetic considerations have been chiefly responsible. The bulbous stump caused by the flaring femoral condyles usually requires use of the cumbersome, unsightly, and unsanitary leather lace-up thigh socket and external knee joints. Existing standard joints lack the necessary strength to withstand the torque to which they may be subjected by a vigorous, husky man, and provide no friction.

If the stump is not particularly bulbous, prosthetists prefer to use the type of knee joints used with the standard above-the-knee socket. This type provides constant friction, but prolongs the socket about three inches, making the artificial knee protude in the sitting position.

\* Reprinted by permission of the authors and editors from *The Journal of Bone and Joint Surgery*, January 1966, Vol. 48-A, pp. 126-139.

\*\* Read at the Annual Meeting of the Western Orthopedic Association, Seattle, Washington, September 25, 1963.

† Veterans Administration Center, Wiltshire and Sawtelle Boulevards, Los Angeles, California 90025.

‡ School of Medicine, University of California, Los Angeles, California.

Many standard textbooks ignore the knee as a level of amputation 1, 6, 7, 16, 20, 25, 26, 29. Several mention, but do not recommend, this operation 5, 18, 21. DePalma and Verrall discouraged amputation through the knee. Colonna stated that a knee-disarticulation stump is difficult to fit with a prosthesis but that the procedure should not be condemned. Peterson remarked that disarticulation at the knee gives a good end-bearing stump. Kelham stressed the relative speed and absence of shock of the knee-disarticulation operation. He reported some success among patients with peripheral vascular disease. Slocum enumerated the advantages and disadvantages of knee disarticulation, quoting at length from Rogers. Gillis re-emphasized that, compared with an above-the-knee stump, knee disarticulation, particularly in older people, gives better control of the prosthesis and better balance. Slocum and Kirk decried the unsightliness of the usual bulbous stump, believing the thin skin over it subject to breakdown. Nathan Smith made the first report of knee disarticulation in the American literature in 1825. Velpeau described fourteen cases in 1830. Batch, Spittler, and McFaddin, in 1954, referred to two additional reports of knee disarticulation from this country, one by Stephen Smith in 1870, the other by Otis Huntington in 1883. Together these articles reported on 189 such disarticulations performed during our Civil War, and Batch and associates added twenty-eight cases of their own without follow-up data. They emphasized the better balance and gait after knee disarticulation compared with above-the-knee amputation.

The most enthusiastic contemporary protagonist of knee disarticulation is Rogers, who noted that it provided the largest horizontal end-bearing surface area available in the lower extremity; the bone, soft tissues, and skin at the end of the stump are normally adapted to weight-bearing; the terminal integuments of the stump are subjected to pressure but not to tension; muscle control of the stump is achieved by preserving the length and attachment of every muscle motivating the thigh; excellent leverage can be exerted on a prosthesis because the stump is long and its end is firm and relatively insensitive; muscle atrophy is minimized by preserving the function of most of the muscles left in the stump and by the early use of a permanent prosthesis; if the popliteal artery is ligated below its superior geniculate branches, the richest system of arterial anastomoses available in the extremity is preserved; the greater part of the terminal flap comes from in front of the joint space and therefore already has a blood supply independent of its underlying tissues; and preservation of the lower femoral epiphysis, accountable for 90 per cent of the growth of the femur, allows normal development of the stump following amputation in childhood. Rogers also stated that disarticulation should not be done in patients with peripheral vascular disease.

Quite recently Dederich and Mercer<sup>19</sup>, commenting on physiological considerations in amputation stumps, restated the desirability of good muscle control of the stump, advocating suture of severed muscles over bone ends.

Two undesirable features are present in the conventional knee-disarticulation prosthesis: its unsightliness and lack of satisfactory swing-phase control provided by the standard external knee joints used for below-the-knee prostheses. In addition, these joints sometimes break under the torque to which they are subjected in the knee-disarticulation prosthesis. Finally, insertion of a bulbous stump into the leather bucket is a rather awkward maneuver, and lacing up the long front of the cumbersome socket is time-consuming.

In view of these considerations it was decided to make a less bulbous and more cosmetically acceptable stump, which would permit replacement of the unsightly leather bucket with a more pleasing and more sanitary plastic type. To accomplish this, the standard knee disarticulation was modified and an improved prosthesis for the resulting stump was fabricated.

### OPERATIVE TECHNIQUE

The customary fish-mouth skin incision is made with a longer anterior flap that extends four and one-half inches below the level of the knee joint. The posterior flap is one and one-half inches in length. The skin flaps must be long enough to close without tension (Fig. 1). The skin and deep fascia are incised, dissected off the capsular structures of the knee, and reflected upward as one layer, well proximal to the femoral condyle. The patellar tendon is divided mid-way between patella and tibial tubercle. The knee is flexed and its capsule and various ligaments are severed. Then with the knee further flexed to 90 degrees, the popliteal vessels and nerves are tied and divided. No effort is made to preserve the inferior geniculate arteries. The hamstrings are detached from their insertions, and the patella is dissected from its tendon and discarded.

After removal of the leg, the medial one-half of the medial femoral condyle, the lateral one-third of the lateral condyle, and the protruding posterior surfaces of both condyles are removed with a wide osteotome. The corners are rounded with a rasp, preserving a fairly broad weight-bearing area on each condyle. The patellar tendon and hamstrings are sutured to one another in the intercondylar notch under slight tension. Hemostasis is se-

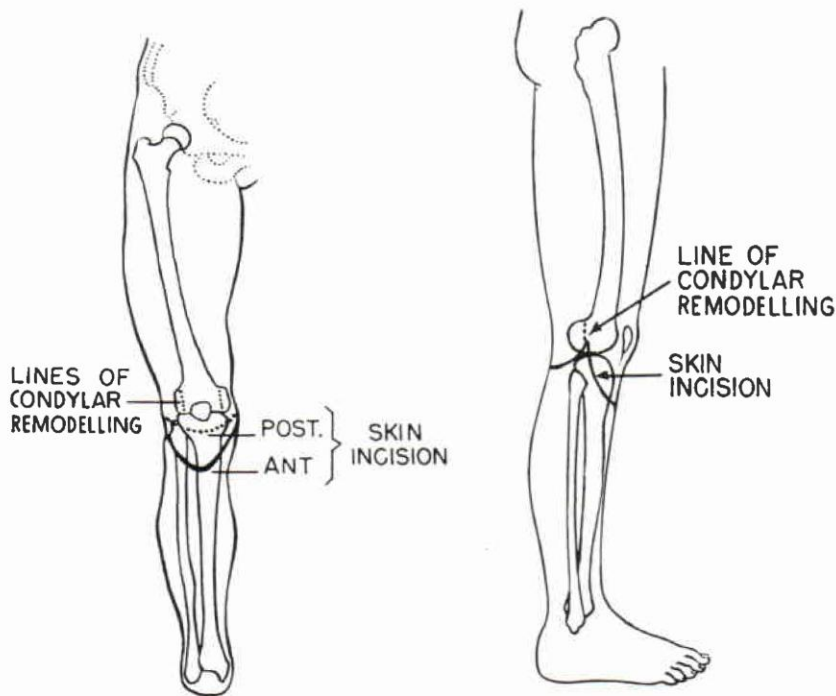


FIG. 1

Skin incisions and condylar modeling for knee disarticulation.

cured. The deep fascia and then the skin are closed separately in the usual manner. Drains are inserted in each end of the wound, and a compression dressing is applied. The resulting stump is truncated, with adequate weight-bearing surface on the femoral condyles.

Condylar trimming in children whose distal femoral epiphyses are not yet closed has not been done. In young children, growth of the condyles in length and width is slowed following knee disarticulation, and a conical stump develops without trimming of condyles.

### THE NEW PROSTHESIS

The prosthesis fabricated for this truncated stump differs in several details from the standard knee-disarticulation device.

The bulbousness of the conventional prosthesis for a knee-disarticulation stump is avoided, since the truncated stump permits use of a socket with a more pleasing contour.

With the conventional knee-disarticulation stump with full width of the condyles, it may be difficult to maintain evenly distributed weight-bearing over the broad surface of both condyles. If this even distribution is not achieved, breakdown of skin over the condyle bearing the most weight may occur. The problem is intensified if there is any flexion or abduction of the stump. If either or both of these contractures are present, the necessary socket alignment may cause uneven swing-through, stump rotation, and irritation of the stump end. The non-bulbous stump without flaring condyles allows more latitude in adjusting the alignment and permits needed stump adduction.

When there is a hip flexion contracture, the stump and socket must be set in flexion to accommodate this. If this adjustment is made with the conventional socket, the bulbous end of the bucket projects forward at the knee joint and is extremely unsightly. The necessary flexion is less noticeable with a non-bulbous socket.

In the new prosthesis, the foot appears to be outset owing to adduction of the stump to obtain lateral stability. The knee is located a little medial to the weight-bearing plumb line from ischium to heel. The foot is directly under the ischial tuberosity, in its proper place, permitting a narrower base (Fig. 4) in stance and gait.

The new socket is made of laminated plastic over Kemblo rubber and lined with thin horse hide that withstands perspiration well. The socket weighs a little less than the leather lace-up type and is easily cleaned. The non-bulbous stump can be inserted and withdrawn with ease. The life of the material in the plastic socket is appreciably longer than that of leather.

The need for external, friction knee joints has been recognized for some time. Several years ago the Amputee Research Group at the University of California, Berkeley, developed a practical constant friction outside knee joint of sufficient strength for use on a knee-disarticulation prosthesis. This joint provides better control of the prosthesis than the above-the-knee joint and produces a smoother gait by lessening excess heel rise and reducing terminal impact. We used these Berkeley hinges most successfully in Cases 1 and 4. Unfortunately, these joints are not commercially available and we could secure only two pairs.

Inability to procure additional Berkeley external joints necessitated reversion to the above-the-knee mechanism with the excessively long socket. One of us (C.A.H.), with Mortensen, evolved an application of the Hydra Nu-Matic variable swing-phase control mechanism for use with standard external knee joints. This control has been used on three amputees (Cases

4, 8, and 14). It permits use of a socket only three fourths of an inch longer than the normal thigh and reduces heel rise and terminal impact. This device has proved eminently satisfactory in the three cases in which it was used. Details of this mechanism are shown in the Appendix. End-bearing and control of the prosthesis are essentially the same in both the conventional and the new sockets.

The friction knee joint gives better control of the prosthesis, provides better proprioceptive sensation, obviates pendulum motion of the skin, and lasts longer. With the new prosthesis, the patient has a more natural gait and expends less energy in walking.

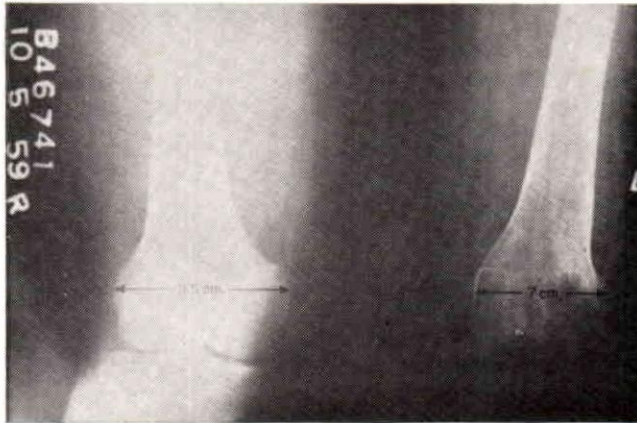


FIG. 2

Case 1. Ten months after left knee disarticulation; the condyles of the left femur have been trimmed to obviate bulbousness of stump.

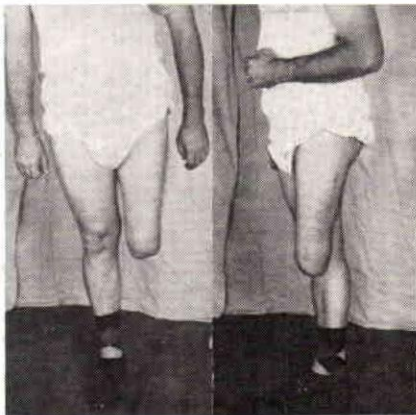


FIG. 3

FIG. 3—Case 1. Five years after disarticulation. Note absence of bulbousness.

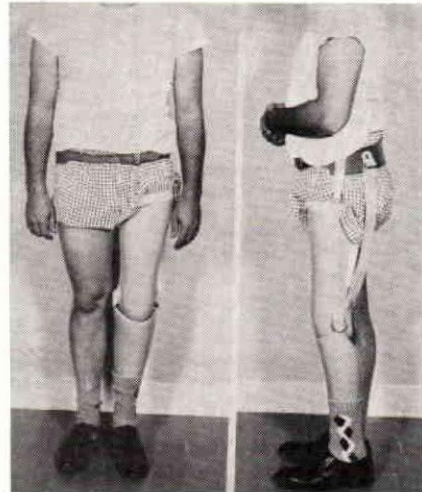


FIG. 4

FIG. 4—Case 1. Five years after disarticulation, with knee-bearing plastic prosthesis. Note appearance, absence of long thigh lacer, and the external knee joints.

TABLE I

Patient, Age at Amputation (Years), Sex	Cause of amputation	Type of Amputation	Age at Last Visit (Years)	Difference in Thigh Lengths (Inches)	Type of Prosthesis			Occupation and Activities	Complications and Comments
					Socket	Knee Joint	Suspension		
Case 1, C. P., 35, M	Chronic osteomyelitis, left tibia	Condyles trimmed	43	0	Modified suction	External Berkeley; later Hydra Nu-Matic	Pelvic belt	Commercial artist; much on feet	Returned to work five mos. after amputation; six yrs. later the knee joints were worn out and external Hy- dra Nu-Matic joints substi- tuted; doing well after eight years
Case 2, R. S., 46, M	Osteogenic sarcoma, left tibia	Condyles trimmed	47½	0	Modified suction	Standard below-the- knee	Pelvic belt	Laborer; did not return to work	Skin flaps too short and ne- crosis required plastic sur- gery; walked on peg leg seven mos. after operation and articulated leg one yr. after operation; died of pul- monary metastases nineteen mos. after operation
Case 3, E. J. A., 37, M	Chronic osteomyelitis, left tibia	Condyles trimmed	41	0	Modified suction	Standard below-the- knee	Pelvic belt	Athletic trainer; worked at auto- mobile assembly past year	Full weight-bearing five mos. after operation; on feet eight hrs. daily; no stump trouble four yrs. after oper- ation
Case 4, E. I., 41, M	Acute osteomyelitis, right tibia	Condyles trimmed	44	0	Modified suction	External Berkeley; later Hydra Nu-Matic	Suction	Painting contractor; drives truck, rides bicycle, climbs ladders three yrs. after operation	Osteomyelitis of medial con- dyle developed after stand- ard knee disarticulation; removal of patella and trim- ming of condyles produced hardy stump
Case 5, R. K., 28, M	Berger's disease	Condyles trimmed	46	½	Thigh lacer; later modified suction	Standard above-the- knee	Suction	Portrait painter; stream fishing as a hobby	Stump end not bulbous but prosthetic knee joint pro- trudes

Case 6, A. R. D., 26, M	Gangrene following tear of pop- liteal artery	Standard	45	0	Leather lacer	Standard below-the- knee	Lace-up socket	X-ray technician; on feet all day; gar- dens in spare time	Patella left in place; very bulbous stump; good walk- er
Case 7, B. L. A., 35, M	Chronic osteomyelitis of tibia	Standard	55	0	Leather lacer	Standard below-the- knee	Soft belt	Television announcer; no heavy work; on feet two-thirds of the time; gar- dens as a hobby	
Case 8, P. J. H., 14, F	Osteogenic sarcoma of tibia	Condyles trimmed	18½	0	Modified suction	Standard below-the- knee with Hydra Nu-Matic	Suction	Schoolgirl; works as hospital volunteer, dances	Has conical stump
Case 9, J. W. K., 2, M	Multiple congenital deformities	Standard	13	Bi- lateral	Modified suction	Standard above-the- knee	Soft belt	Extremely active in scouting	Femora thin, not bulbous, seem long for his age
Case 10, R. C., 3, F	Paraxial tibial hemimelia	Standard	20	2½	Suction	Standard above-the- knee	Suction	Married; does house- work	Has well truncated stump
Case 11, R. L. K., 7 days, M	Malignant tumor of tibia	Standard	13	½	Suction	Standard above-the- knee	Suction	Very active; plays baseball and skates	Femur is smaller than its op- posite; prosthetic knee pro- trudes
Case 12, D. D. D., 2, F	Congenital absence of leg and foot	Standard	15	½	Modified suction	Standard above-the- knee	Soft belt	Schoolgirl; dances	Femur is smaller than its op- posite; prosthetic knee pro- trudes
Case 13, K. C., 6, F	Paraxial fibular hemimelia	Standard	21	1	Total contact	Standard above-the- knee	Suction	College student; active on news- paper	Femur shorter and thinner than its opposite, not bul- bous
Case 14, J. deM., 52, M	Automobile accident; osteomyelitis, right tibia	Condyles trimmed	54	0	Total contact	Standard below-the- knee with Hydra Nu-Matic	Suction	Owens building maintenance business	Much on feet, working full time two yrs. after opera- tion

## CLINICAL MATERIAL

We reviewed all the cases of knee disarticulation that we could find. Fourteen patients who had been walking on knee-disarticulation prostheses for from one to twenty years were collected and carefully studied (Table I). Three had their disarticulations at the Los Angeles Veterans Hospital (Cases 1, 2, and 3), three were private patients (Cases 4, 8, and 14), three were seen at the Los Angeles Regional Office, having lost their extremities in World War II (Cases 5, 6, and 7), and five were patients at the Los Angeles Orthopaedic Hospital who had been amputees for eight to twenty years (Cases 9, 10, 11, 12, and 13). Each patient was examined by one of us (R. M., Jr.) and many were seen by both of us. Eight were adults at the time they became amputees; six were children. Three had become adults since loss of their extremity. In the adults amputation was necessitated by trauma in all but one with Berger's disease and one with osteosarcoma. Four of the children had disarticulation because of congenital deformities; two, because of malignant tumors. Stump difficulty occurred in only one of the seven patients treated by the method described. In Case 2, the skin flaps were made short and plastic surgery was required to cover the skin defect. Despite this complication, a good weight-bearing stump was achieved and the patient was able to begin walking on his knee seven months after operation. He continued to walk on it until shortly before he died of pulmonary metastases from his osteogenic sarcoma nineteen months after amputation. In Case 4, a standard knee disarticulation performed elsewhere was followed by stump breakdown. Revision with trimming of the condyles produced an excellent stump.

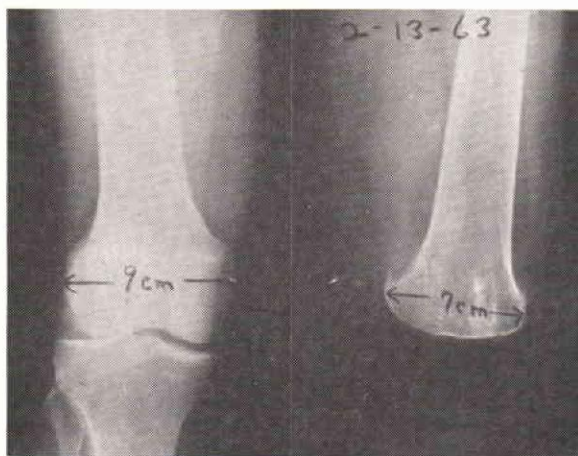


FIG. 5

Case 5. Modeling of condyles eighteen years after disarticulation of the knee and an unknown amount of trimming. The femur is one-half of an inch shorter.

In the six children, whose ages ranged from seven days to fourteen years at the time of amputation, conventional knee disarticulations were performed in all except Case 8, a girl, fourteen years old, whose femoral condyles were trimmed according to the method previously described. In all children the femur on the side of disarticulation continued to grow, but at a slower rate than on the normal side; but in the one child with bilateral amputation



(Case 9), the femora appeared to be longer than normal when the boy was thirteen years old, ten and a half years after bilateral knee disarticulation because of multiple congenital anomalies. In the three children who had completed their growth at follow-up (Cases 10, 12, and 13) the difference in femoral length ranged from one-half to two and a half inches, the average

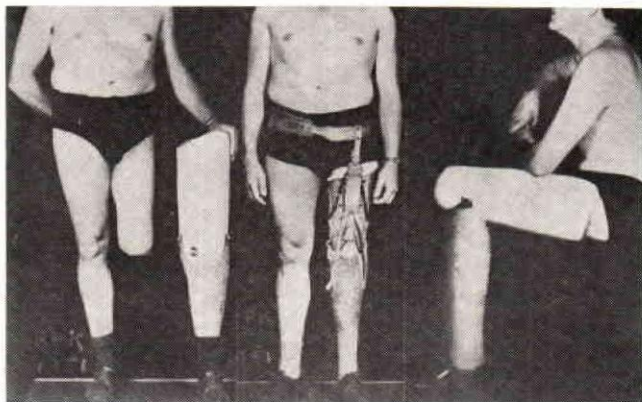


FIG. 6

Case 5. Left, the stump is nicely truncated; center, the original leather lace-up socket with external below-the-knee prosthetic joint; right, the present socket with an above-the-knee prosthetic joint and elongated socket.

being 1.67 inches. In two children, growth was not complete at the time of this study. One was Case 9, the bilateral amputee. The other was Case 11, a boy whose disarticulation was performed at the age of seven days. His femoral shortening at the age of thirteen years was one-half inch. In Case 10, that of a girl whose disarticulation was performed at three years, femoral shortening was two and one-half inches at the age of twenty years. In Case 8, that of a girl who had trimming of the femoral condyles when disarticulation was performed at fourteen years of age, the distal femoral epiphyseal plates were closed when operation was performed.

As the children with conventional knee disarticulation grew, growth in width of the femur on the side of disarticulation, especially at the distal end, was less than that on the normal side. As a result, none of the children's stumps were bulbous at follow-up (Fig. 10).

In six of the fourteen cases, the condyles were trimmed according to the technique recommended (Cases 1, 2, 3, 4, 8, and 14). In Case 5, a less radical trimming had been done elsewhere. In the remaining cases the condyles were not disturbed. In Case 6, the patella was left *in situ*, producing a very bulbous stump.

Not included in this series are five patients, fifty to sixty-one years old, who had knee disarticulations and trimming of the condyles for peripheral vascular arteriosclerotic disease. The anterior skin flap necrosed in all five. These were patients with advanced generalized arteriosclerosis. In each, the popliteal pulse was palapable but not strong. Two of them had gangrene of a toe. None had palpable pedal pulses. We agree with Rogers that generalized arteriosclerosis interdicts knee disarticulation.

## CASE REPORTS

CASE 1. C. P., a commercial artist, thirty-five years old, sustained an open fracture of the upper third of the left tibia from a mortar shell when he was twenty-one years old. Chronic infection necessitated many operations, and a cold, anesthetic foot with an equinovarus deformity developed. Knee motion was from full extension to 45 degrees of flexion. The knee and upper part of the leg ached constantly; pain was excruciating during acute exacerbations of his osteomyelitis. At the time of admission a draining sinus led to a cavity, two by two by three centimeters, in the upper end of the tibia.

On December 22, 1958, when the patient was thirty-five years old, left knee disarticulation was performed by the technique described (Fig. 2). Wound healing, stump shrinkage, and conditioning proceeded uneventfully (Fig. 3). The patient received a prosthesis with moulded plastic socket and the Berkeley knee joint four months after operation. He learned to walk easily and rapidly and returned to work five months after operation.

During the ensuing eight years after disarticulation he wore the prosthesis all day every day, doing considerable walking. There had been no irritation or discomfort, although a few minor adjustments of the prosthesis had been necessary. Fifteen months after amputation, because of a little shrinkage of distal end of the stump, he changed from a three-ply to a five-ply sock. The original Berkeley friction joints were used for six years (Fig. 4). They were then replaced by external below-the-knee joints with Hydra Nu-Matic control.

CASE 5. R. P. K., a portrait painter, forty-six years old, had a left knee disarticulation performed eighteen years previously for Berger's disease. Since then he had worn an end-bearing prosthesis using a belt and thigh lacer for eight years and recently a suction socket. He was active and did considerable walking and gardening as a hobby. He had had no trouble with his stump.

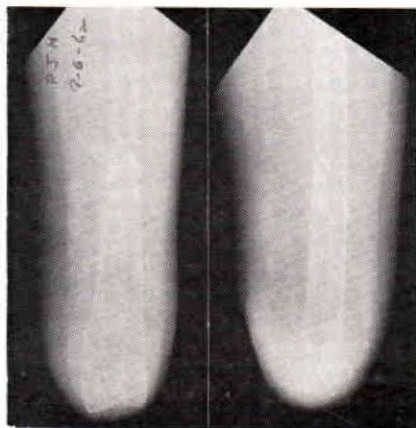


FIG. 7

FIG. 7—Case 8. The narrowed femoral condyles and the conical stump, 6 months after operation.

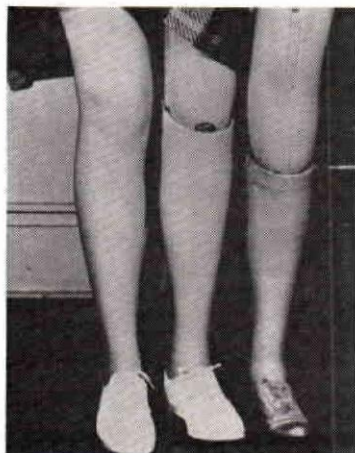


FIG. 8

FIG. 8—Case 8. Patient in the new suction-socket device with Hydra Nu-Matic knee mechanism. The socket is essentially the same length as her normal thigh. Shown also is her first prosthesis with the standard above-the-knee mechanism. Note long socket.

The stump was shaped like a truncated cone, without bulbousness. The circumference of the stump end was twelve inches; that of the opposite thigh at the level of the condyles was sixteen inches. The femur on the stump side was one-half inch shorter than the opposite femur.

A roentgenogram made on February 13, 1963, showed that the condyles had been trimmed to decrease the width of the distal end of the femur and to shorten it slightly (Fig. 5). Why the condyles were trimmed in this man is not known, but it appears that his surgeon anticipated our conviction that this procedure would produce a better stump long before the idea occurred to us.

The patient now wears a conventional above-the-knee type of knee joint with an elongated socket (Fig. 6). Absence of bulbousness permits use of suction for suspension.

CASE 8. P. J. H., a fourteen-year-old girl, was admitted to the hospital on February 8, 1962, with an osteogenic sarcoma of the left tibia, proved by biopsy. On February 16, the extremity was perfused with phenylalanine mustard. On March 23, when knee disarticulation with trimming of the

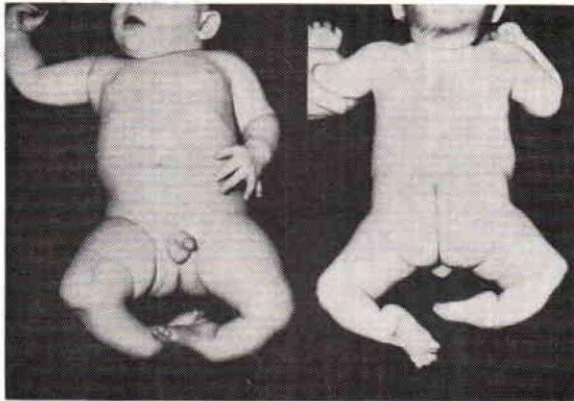


FIG. 9

Case 9. Shortly after birth. Note malformations of both lower extremities.

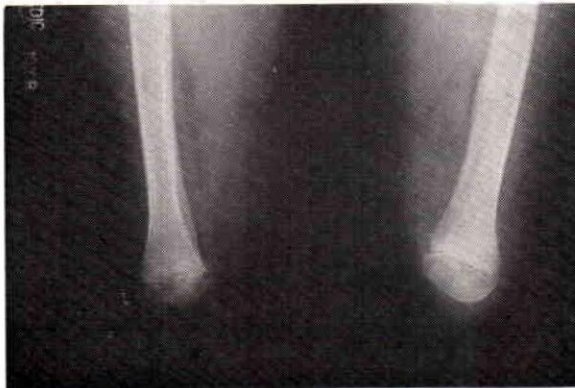

FIG. 10

Case 9. At age ten, the stumps are conical. The lower epiphyses are preserved, but the condylar flare is less pronounced than normally.

condyles was done, the distal femoral epiphyseal plate was closed. She received a total-contact, suction-socket, end-bearing prosthesis with a standard, constant-friction knee joint. The socket was three inches longer than the normal thigh. Three months after disarticulation she resumed her regular school activities. She also worked regularly as a volunteer hospital aid on a children's ward. Her conical stump (Fig. 7) slipped in and out of the socket readily. The circumference of the stump end was eleven inches compared to a circumference of fourteen inches on the opposite side.

A year after amputation she received a new prosthesis provided with a Mortensen Hydra Nu-Matic swing-phase control mechanism. The standard outside knee joint with this new device permitted fabrication of a socket only three-fourths of an inch longer than the normal thigh, a difference ordinarily not noticeable (Fig. 7).

Four and a half years after amputation she was very active. She had no stump trouble, and there was no evidence of recurrence or metastases of the tumor.

CASE 9. J. W. K., a boy, was first seen when he was two years and eight months old. He was born with bilateral dislocation of the hips and

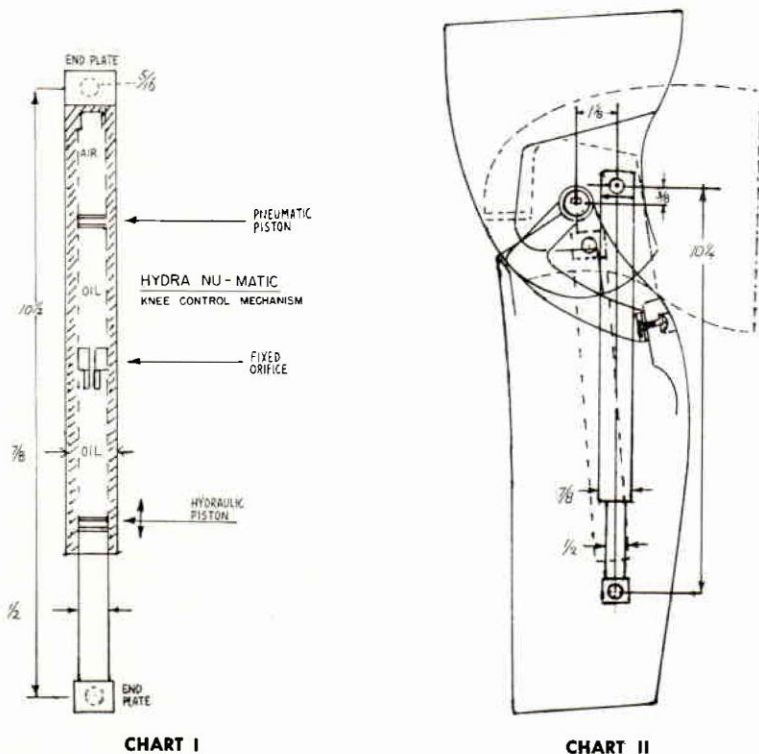


CHART I—The Hydra Nu-Matic knee control mechanism.

CHART II—Placement of device in the prosthesis. The upper end-plate is fixed to the socket one and one-eighth inches posterior to and three-eighths of an inch above the knee axis. Knee flexion forces the cylinder down over the hydraulic piston, forcing the oil through a fixed opening. This in turn compresses the air in the upper cylinder which exercises a braking action at both extremes of swing phase.

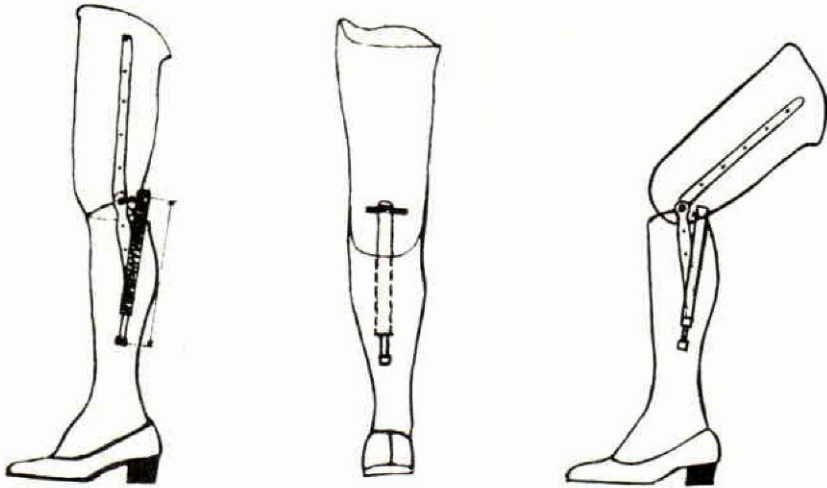


CHART III

Left, a schematic drawing of placement of device, lateral view, knee extended; center, posterior view; right, knee flexion forces cylinder down over piston.

knees, absence of the tibiae, and club feet with supernumerary digits (Fig. 9). These defects were treated in Akron, Ohio, by multiple plaster casts and heel-cord lengthenings. A long spur was removed from the right femur when he was two months old. When he was two years old, bilateral knee disarticulation was performed, with removal of the patellae and preservation of the lower femoral epiphyses. Prostheses were provided seven months after operation and he was seen by us soon thereafter.

Gait training was instituted and he quickly learned to use the devices well. When he was three and one-half years old, an osteochondroma was removed from the left femur.

At thirteen years of age, this boy was an active prosthesis-user and had worn out several sets of prostheses. He was keeping up with other Boy Scouts on overnight hikes, playing baseball, and the like. He had excellent end-bearing conical stumps and was wearing plastic sockets with a soft pelvic belt, single-bolt knees, two-way ankles, and wood and rubber feet. Roentgenograms made when he was ten (Fig. 10) showed preservation of the distal femoral condyles and epiphyseal plates. However, the condylar flare seen in normally developed femora was considerably reduced.

## DISCUSSION

Success after knee disarticulation depends largely on the viability of the skin flaps. Their blood supply must come from above, since there is no muscle bed beneath the flaps to nurture them. A satisfactory outcome can be anticipated only in extremities with vessels that are neither atheromatous nor scarred from trauma or infection. Rogers, in his discussion of the presentation of Batch, Spittler, and McFaddin, stated that he did not disarticulate the knees of patients with diabetes or arteriosclerosis, even though circulation appeared adequate.

## SUMMARY

Knee disarticulation provides an amputation stump that is stable, tough, and long lasting, and assures excellent muscle control of the prosthesis. The procedure is not indicated in the presence of peripheral vascular disease.

Fourteen cases are presented in which weight-bearing on the femoral condyles for from one to twenty years had not resulted in stump breakdown.

An operative technique designed to obviate the bulbousness of the lower end of the femur that is characteristic of the usual knee disarticulation is described. Six cases in which this technique was used are reported (in Case 5, partial trimming was done elsewhere).

Two types of external knee joints, the Berkeley and the Hydra Nu-Matic, incorporating friction and a swing-phase control mechanism, are described.

## APPENDIX

The Hydra Nu-Matic knee-control unit\* is composed of a three-chambered cylinder, a pneumatic piston, and a hydraulic piston with oil in the lower two chambers and air in the upper chamber (Chart I).

The unit's length is ten and one-half inches; its outside diameter, seven-eighths of an inch. The upper end of the cylinder is fixed to the socket a little above and behind the axis of the knee joints (Chart II). The lower end (the end of the hydraulic piston) is secured within the shin. Knee flexion moves the superior end of the device downward and forward. As a result, the cylinder slides over the hydraulic piston (Chart III) and oil is forced from the lower chamber through the fixed orifice in the cylinder into the middle chamber. This in turn elevates the pneumatic piston, compressing air in the upper chamber. The compressed air then acts as a kicker to trigger extension of the knee as the foot swings forward after push-off. This automatic knee extension eliminates excessive heel rise. As the knee extends and the hydraulic piston is pulled down, the oil flows back through the fixed orifice, restraining knee extension with decreasing force, and the pressure differential in the middle and lower chambers is decreased by the flow of oil through the fixed orifice as heel strike is approached. Terminal impact at heel strike is thereby softened. The linkage of the unit is such that when the wearer is seated the unit is inactive, and the feet are flat on the floor. As the standing position is resumed, the compressed air is ready and available to aid in extension of the leg.

## REFERENCES

1. Bancroft, F. W., and Marble, H. C.: *Surgical Treatment of the Motor-Skeletal System*. Ed. 2. Philadelphia, J. B. Lippincott Co., 1951.
2. Batch, J. W.; Spittler, A. W.; and McFaddin, J. G.: Advantages of the Knee Disarticulation Over Amputations Through the Thigh. *J. Bone and Joint Surg.*, 36-A: 921-930, Oct. 1954.
3. Bick, E. M.: *Source Book of Orthopaedics*. Ed. 2. Baltimore, The Williams and Wilkins Co., 1948.
4. Bowers, W. F.: *Surgery of Trauma*. Philadelphia, J. B. Lippincott Co., 1953.
5. *Campbell's Operative Orthopaedics*. Ed. 3, Edited by J. S. Speed. St. Louis, The C. V. Mosby Co., 1956.
6. Casagrande, P. A., and Frost, H. M., Jr.: *Fundamentals of Clinical Orthopaedics*. New York, Grune and Stratton, 1953.
7. Cave, E. F.: *Fractures and Other Injuries*. Chicago, Year Book Publishers, 1958.

\* Kingsley Manufacturing Company, 1984 Placentia, Costa Mesa, California.

8. Cleveland, Mather, and Hayward, O. S.: Nathan Smith (1762-1829) on Amputations. *J. Bone and Joint Surg.*, 43-A: 1246-1254, Dec. 1961.
9. Colonna, P. C.: Regional Orthopedic Surgery. Philadelphia, W. B. Saunders, 1950.
10. Dederich, Rolf: Plastic Treatment of the Muscles and Bone in Amputation Surgery. *J. Bone and Joint Surg.*, 45-B: 60-66, Feb. 1963.
11. DePalma, A. F.: Diseases of the Knee. Philadelphia, J. B. Lippincott Co., 1954.
12. Gallie, W. E.: The Experience of the Canadian Army and Pensions Board with Amputations of the Lower Extremity. *Ann. Surg.*, 113: 925-931, 1941.
13. Gillis, Leon: Amputations. London, William Heinemann, 1954.
14. Harris, R. I.: Amputations. *J. Bone and Joint Surgery*, 26: 626-634, Oct., 1944.
15. Kelham, R. L.: Artificial Limbs. London, Her Majesty's Stationery Office, 1957.
16. Key, J. A., and Conwell, H. E.: The Management of Fractures, Dislocations and Sprains. Ed. 7. St. Louis, The C. V. Mosby Co., 1961.
17. Kirk, N. T.: Amputations. Hagerstown, W. F. Prior, 1942.
18. Lewis' Practice of Surgery, Vol. III. Edited by Waltman Walters. Hagerstown, W. F. Prior, 1955.
19. Mercer, Walter: Reflections on Amputation Stumps. *J. Bone and Joint Surg.*, 45-B: 218-219, Feb. 1963.
20. Mercer, Walter: Orthopaedic Surgery. Ed. 5. Baltimore, The Williams and Wilkins Co., 1959.
21. Perkins, George: Orthopaedics. London, The Athlone Press, 1961.
22. Rogers, S. P.: Amputation at the Knee Joint. *J. Bone and Joint Surg.*, 22: 973-979, Oct. 1940.
23. Slocum, D. B.: An Atlas of Amputations. St. Louis, The C. V. Mosby Co., 1949.
24. Smith, Nathan: Amputation at the Knee Joint. *Am. Med. Rev.*, 2: 370-371, 1825.
25. Turek, S. L.: Orthopaedics. Philadelphia, J. B. Lippincott Co., 1959.
26. Vasconcelos, Edmondo: Modern Methods of Amputation. New York, The Philosophical Library, 1945.
27. Velpeau, A. A. L. M.: Mémoire sur l'amputation de la jambe dans l'articulation du genou, et description d'un nouveau procédé pour pratiquer cette opération. *Arch. Gén. de Méd.*, 24: 44-60, 1830.
28. Verrall, P. J.: Amputation Stumps and Artificial Limbs. *British Med. J.*: 1: 62-64, 1940.
29. Watson-Jones, Reginald: Fractures and Joint Injuries. Ed. 4. Baltimore, The Williams and Wilkins Co., 1952.

---

### IN MEMORIAM: MRS. SARAH MELLON SCAIFE

A TRIBUTE, by GEORGE R. KOWATIC  
President, Pennsylvania Orthopedic and Prosthetic Society

The death of Mrs. Sarah Mellon Scaife on December 28, 1965, was an irreparable loss, not only to the community where her charities were numerous, but to the Pennsylvania Orthopedic and Prosthetic Society.

Those of us in the profession will remember her bountiful appropriation through the Sarah Mellon Scaife Foundation a quarter of a century ago to the Mellon Institute to establish research into orthotics and prosthetics. Although that research was abandoned in 1960, its impetus was not in vain, and many other research programs were inaugurated as a result of it.

Mrs. Scaife's endowment was more than monetary: It gave our profession greater dignity and stature and we now have won greater respect from the medical profession.

We of the Pennsylvania Orthopedic and Prosthetic Society mourn her death because of her great love for people and her humanitarian cause.

She was Pittsburgh's Great Lady.