

The Enhancement of Prosthetics Through Xeroradiography®

by David Varnau, C.P.O.
Keith E. Vinnecour, C.P.O.
Monalee Luth
David F. Cooney, R.P.T., C.P.O.

INTRODUCTION

Today's prosthetist finds himself searching for new tools to enhance his fitting skills. With transparent test sockets, he is now able to visualize the residual limb inside the prosthetic socket. With Xeroradiography®, the contemporary prosthetist is able to identify his patient's unique bony anatomy before even commencing work on the prosthesis.

The concept of using x-ray images to improve prosthetic fit is by no means new. As early as 1963, King wrote of using x-rays as an adjunct to patellar tendon bearing (PTB) fittings.⁶ Much more recently, Haslam, C.P. and Wilson briefly cited some merits of x-rays and Xeroradiographs® for prosthetics.² Credit for introducing Xeroradiography® into the field of prosthetics, however, must be given to Jan Stokosa, C.P.†

DESCRIPTION

Xeroradiography® is a dry, photoelectric process‡ for recording x-ray images on paper. Although its usefulness today is

usually considered to be confined to the examination of the breast, Xeroradiography® is well-suited for any peripheral part of the body.¹⁴

Advantages of Xeroradiography®

The primary advantage that Xeroradiography® imaging offers the prosthetist over that of conventional film radiography (x-ray) is the clarity of the bone's boundary lines (Figure 1). This fact is due to the character of the Xeroradiographic® imaging process itself.¹⁵

Previously, when consulting x-rays of a residual limb, prosthetists either had to accept the blurred contours of the patient's bony anatomy, or were deprived of a lucid image of the soft tissue edges. Instead, each Xeroradiograph® can replace two x-ray film pictures (a bone picture and a soft tissue picture) and thus provide the prosthetist with more accurate and easily observable information at a glance.¹¹

The Xeroradiograph® is developed on opaque paper, usually on a blue format. Unlike x-rays, the Xeroradiograph® can be easily stored as a part of the patient's chart since there is no need for a viewing box. The rich blue color of the properly exposed negative mode Xeroradiograph® serves to enhance the clarity of the image. Further,

†Jan Stokosa, C.P. is director of the Institute for the Advancement of Prosthetics, Lansing, Michigan.

‡‡Whereas a photo chemical process is used in conventional film radiography.¹

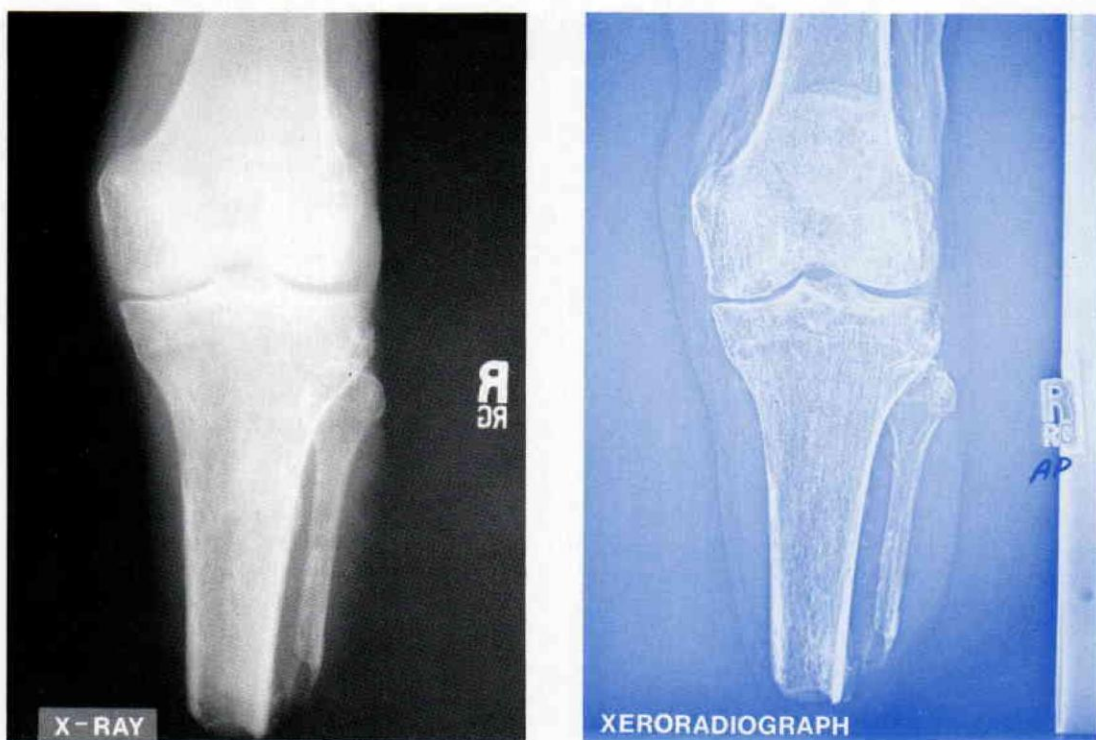


Figure 1. Comparison of bone detail and clarity of soft tissue margins on a conventional film radiograph versus a Xeroradiograph® of the same residual limb. Note magnification of the x-ray image.

DIFFERENT EXPOSURE CONDITIONS

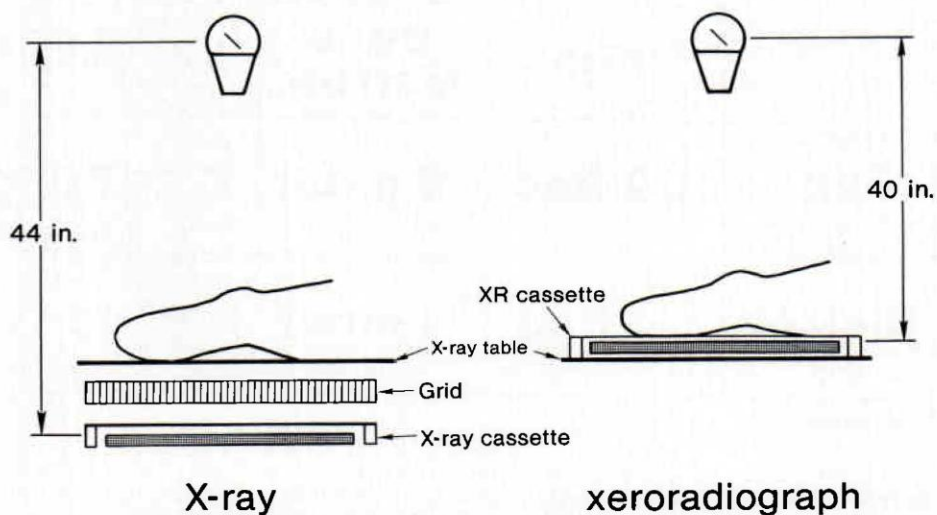


Figure 2. The x-ray cassette is approximately four inches (10 cm.) from the patient's residual limb, whereas the Xeroradiograph® cassette is in contact with the residual limb.

the usefulness of Xeroradiography® for prosthetics becomes even more obvious when it is pointed out that less magnification takes place in the procedure.¹¹ More magnification typically occurs on conventional film x-ray because the x-ray cassette is positioned further from the residual limb (Figure 2).

Disadvantages of Xeroradiography®

The Xeroradiographic plate is 9½" × 13⅝". As a result, it is not possible to photograph a long residual limb in its entirety. Symes level as well as long above knee residual limbs require two pictures merely to complete the image for one projection. To rectify this problem, the radiology technician must tape a radiographically opaque reference marker onto the midsection of the residual limb prior to imaging. The marker aids the prosthetist in piecing the two pictures together correctly. An alternative to this mosaic approach, of course,

is to obtain conventional radiographs of the longer residual limbs.

A second disadvantage of Xeroradiography® is that the image is backwards. As a result, when consulting the Xeroradiograph®, the prosthetist must recognize that the Xeroradiograph® is a mirror image of the object.

Finally, with Xeroradiography®, the patient is usually exposed to a greater radiation dose. The exact difference in radiation exposure between Xeroradiography® and x-ray varies, depending on the type of x-ray screen, film, filters, and resulting technique that is used for a comparison. Generally, using the Xeroradiography® technique that we suggest (see technical information in Figure 20), the local bone radiation dose appears to be as much as nine times that of conventional x-ray film technique† (Figure 3). Although this is undesirable, the amount of radiation both in terms of skin dose, as well as estimated bone marrow dose, is neither alarming nor

RADIATION DOSE COMPARISON

	Skin	Bone Marrow*	kV	mAs
XR	.09 Rad	.9 mrad	120	50
X-RAY	.01 Rad	.1 mrad	55	5

* estimated

Figure 3. Comparison of the radiation dose from Xeroradiograph® and x-ray. Typical entrance exposure (skin dose) and estimated local absorbed dose are listed for each process. Based on data from University of Wisconsin Medical Physics Lab. Thermo lumescent detectors (TLD's) were taped on a bilateral BK and exposed separately for Xeroradiographs® as well as conventional bone detail x-rays.

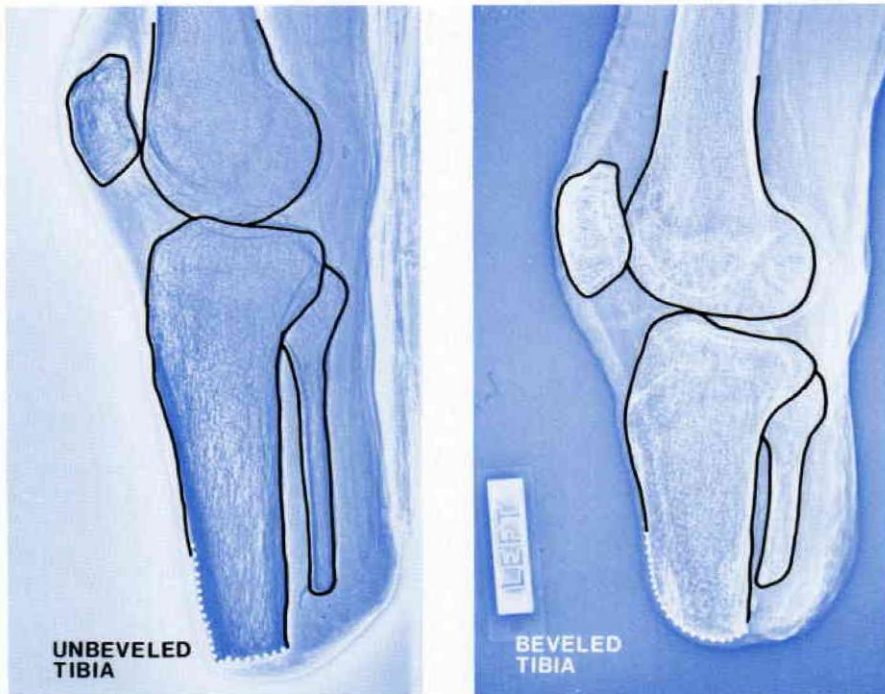


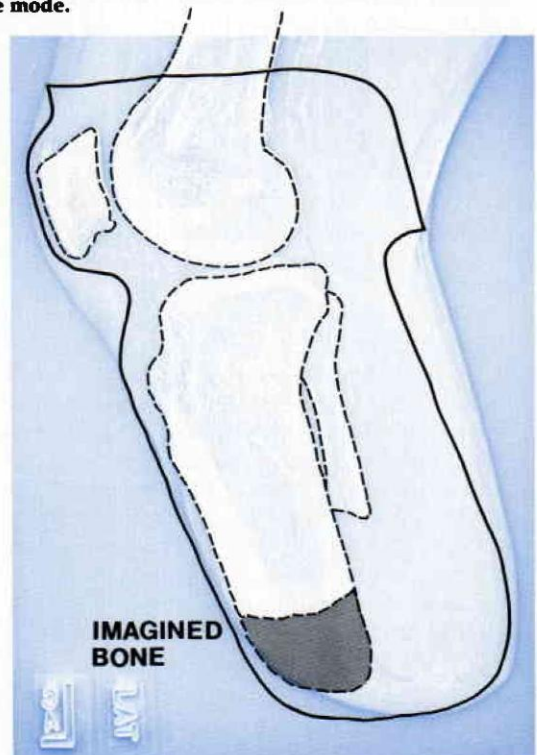
Figure 4. Lateral views of two Xeroradiographs® demonstrating the variety in below knee anterior distal tibial margins. Note: Development method of Xeroradiograph® on left was a positive mode and that on right was a negative mode.

considered dangerous to the patient, mainly because usually only one Xeroradiograph® series is necessary for the adult (see Method Section). Even so, for the juvenile patient, the benefits of Xeroradiography® must be weighed against the greater radiation dose.

USES OF THE XERORADIOGRAPH®

Because contours are intensified on Xeroradiographs®, the boundary lines between bone and soft tissue are pronounced.^{1, 11, 13} Thus, the Xeroradiograph® is well-suited for the prosthetist's interest in bony contours. Further, the Xeroradiograph® provides valuable and sometimes surprising information that is not readily apparent through clinical examination. Since the Xeroradiograph® is only slightly

Figure 5. Lateral view illustrating the usefulness of the Xeroradiograph® in assessing the thickness of the distal soft tissue, especially in cases of hard-packed edema.



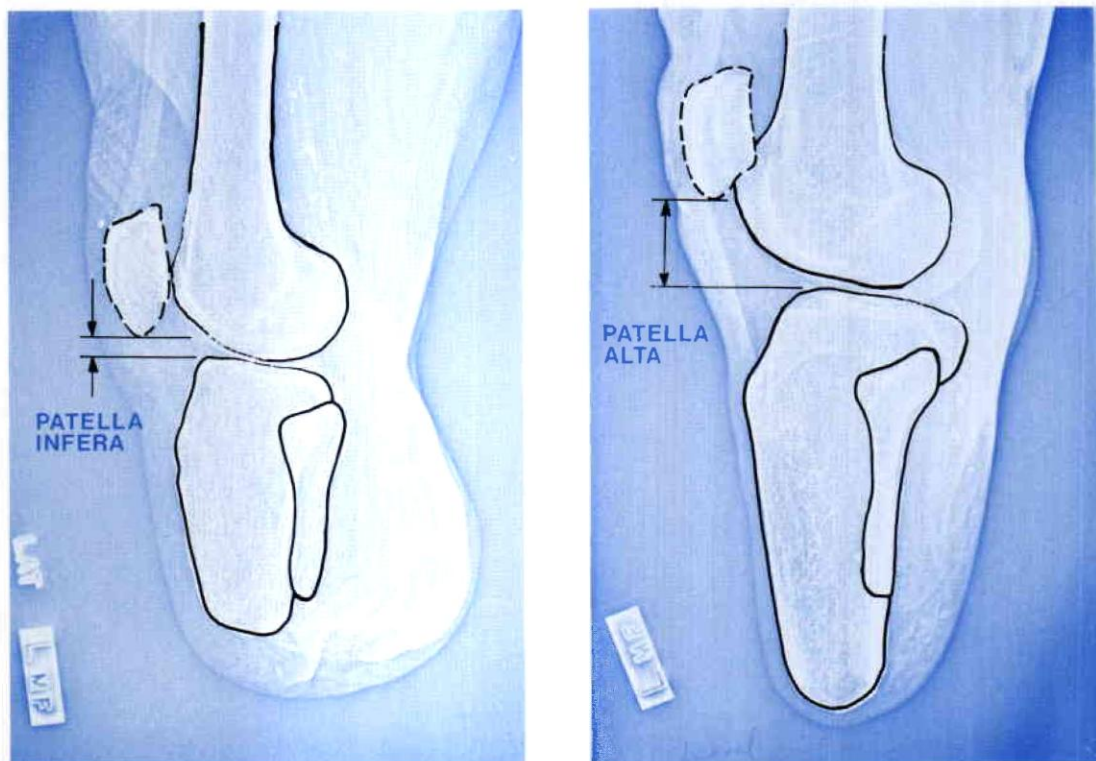


Figure 6. Lateral views which demonstrate the difference between patella alta and patella infera.

magnified,¹¹ numerous measurements can be obtained directly from it.

Although Xeroradiography[®] is valuable when fitting prostheses for all amputation levels, this paper will deal only with its use in the treatment of below knee amputations.

By inspecting the Xeroradiograph[®] of a given patient, the prosthetist can better appreciate the actual length of the tibia,[†] the contour of the anterior distal tibial margin (Figure 4), as well as the thickness of the distal soft tissue. Much of the guesswork is eliminated from this important aspect of the casting and cast modification procedures. Frequently, in cases of hard-packed distal edema, the prosthetist imagines that the length of the patient's tibia extends further distally than it actually does (Figure 5). The Xeroradiograph[®] then

enables the prosthetist to correctly locate the anterior distal tibial relief during cast modification.

The relative position of the inferior border of the patella to the tibial plateau also varies significantly from one individual to the next. Customarily, the so-called "patellar bar" is placed just below the inferior border of the patella. Yet many patients have a condition termed patellar alta or a high-riding patella, while still others have patella infera⁴ or a low-riding patella (Figure 6).

The existence of one condition versus the other has important ramifications for the prosthetist when he is identifying the proper position for the patellar bar. It is evident, then, that the placement of the patellar bar "midway between the lower edge of the patella and the tubercle of the tibia" as advocated by Radcliff and Foort¹⁰ is in fact incorrect for certain patients (Figure 7). The Xeroradiograph[®] thus, aids the

[†]In order to determine actual dimensions from the Xeroradiograph[®], the prosthetist must first account for the exact magnification of the image.

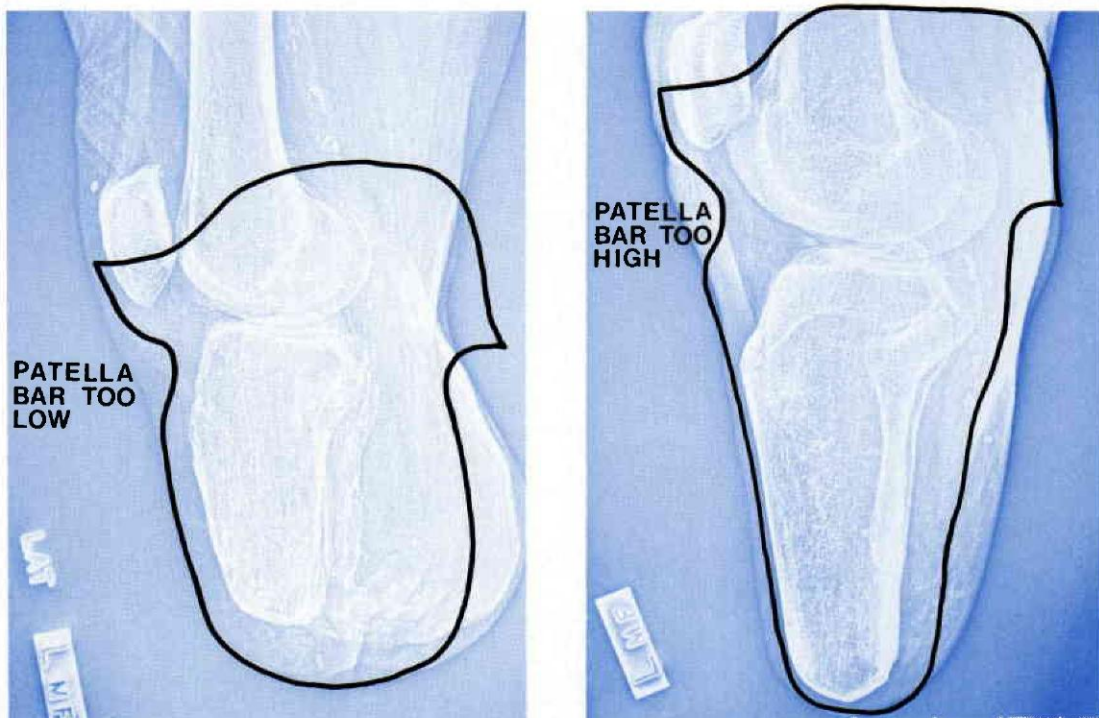


Figure 7. Lateral views with an overlay of the socket outlines. With patella alta, the prosthetist is mistakenly inclined to locate the patellar bar too high. The reverse is true with patella infera.

prosthetist in correctly positioning the patellar bar at the femorotibial joint space.

Prosthetists who routinely use transparent test sockets have noted the presence of an airspace just proximal to the tibial tubercle. This appears to be caused by the patellar bar forcing the patient's tissues posteriorly. Another contributing factor may be that the positive model does not reflect the patient's anatomical contours just proximal to the tibial tubercle. Contrary to popular notion, plaster may be removed and flared from the level of the tubercle into the patellar bar. The angle of the flare is dictated by the contour of the patient's proximal tibia as seen on the lateral Xeroradiograph.® The contour of the proximal tibias in Figure 4 are examples where the flare above the tubercle would be less dramatic than that shown in Figure 5.

The length of the fibula, like that of the tibia, is readily apparent on a Xeroradiograph.® Briefly consulting the anteroposterior (AP) projection will provide a quick

reference for the terminus of the fibular shaft. Guessing as to the shape, position, and size of the fibular head is unnecessary with the Xeroradiograph.® (Figure 8). Also, cases of absence of the fibula are obvious on a Xeroradiograph.® Problems of pressure on the cut end of the fibula and fibular head are diminished while medio-lateral (ML) stabilization on the fibular shaft can be maximized. The lateral projection, on the other hand, is useful for identifying whether the patient's fibula is positioned posterior to, or on, the midline.

The shape of the medial tibial metaphysis varies from one patient to the next (Figure 9). With an AP projection of a given patient's Xeroradiograph,® the prosthetist can anticipate the amount of flare possible in the tibial metaphyseal region. This information aids the prosthetist in creating an anatomically-shaped, weight-bearing area.

After reviewing the Xeroradiographs® of nearly 100 adult below knee residual limbs, we found in our practice that fully 13 per-

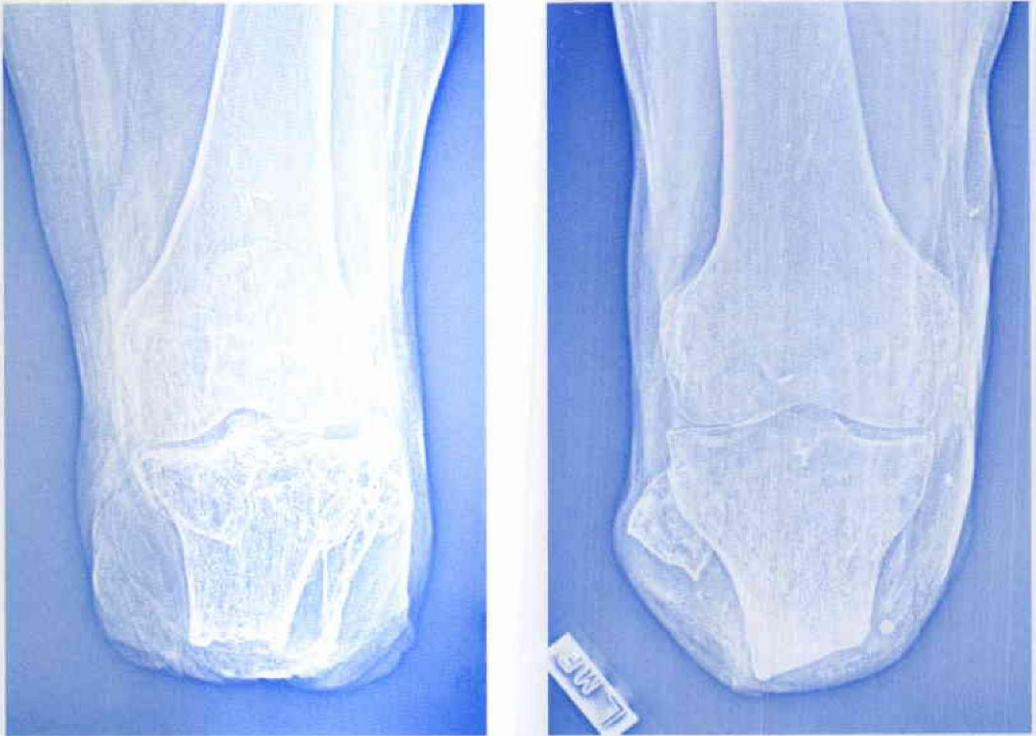

Figure 8. AP views illustrating the variety of bony anatomy that the prosthetist may encounter with two short below knee amputations.

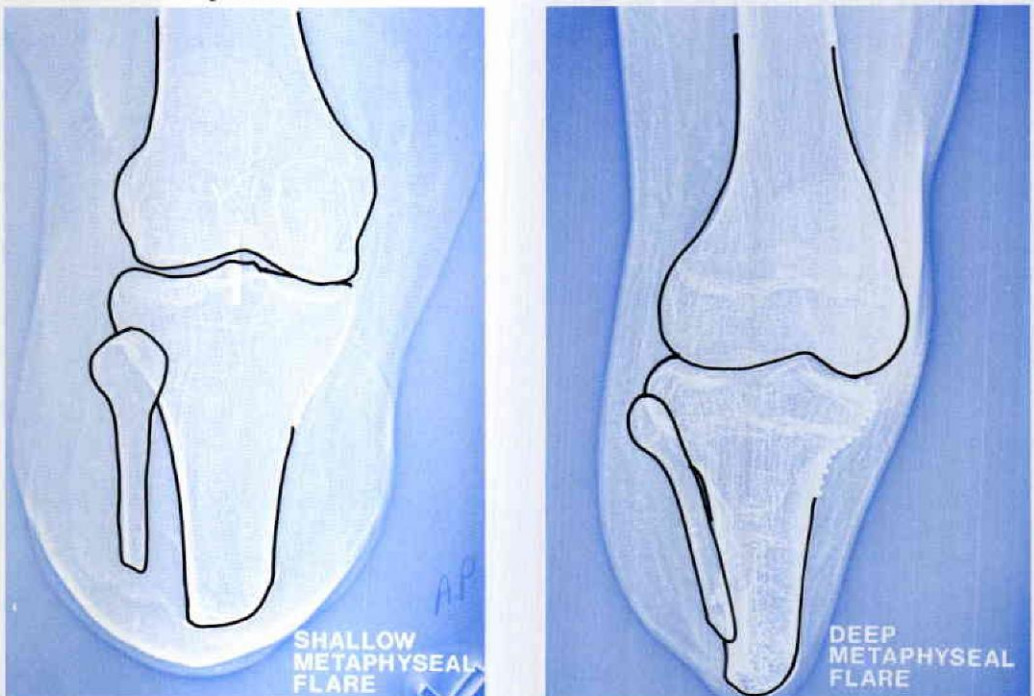


Figure 9. AP views exhibiting the variation in the contour of the medial tibial metaphyses.

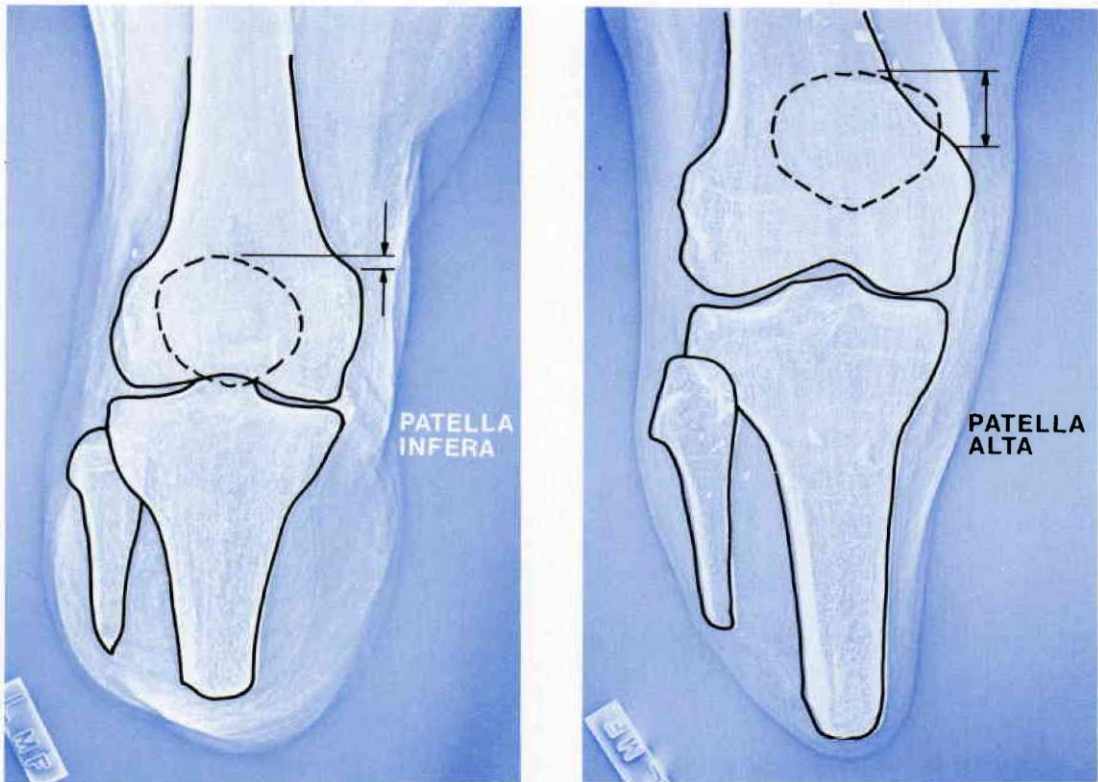


Figure 10. AP views demonstrating the relative distance between the proximal border of the patella and the adductor tubercle for cases of patellar alta and patella infera.

cent of our below knee amputees have tibias shorter than three inches and are PTS candidates. As pointed out by Marshall and Nitzchke, the patient with a four-inch length residual limb is a good candidate for the PTS socket.⁸ However, as they also point out, the PTS prosthesis requires "more skill and knowhow" of the prosthetist for successful fitting.⁷

One important anatomical consideration for the PTS socket, particularly the supra-patellar PTS, is the relative position of the proximal patella to the adductor tubercle. Here again, the existence of patella alta or patella infera is crucial (Figure 10). This information aids the prosthetist both during casting and cast modification to ensure optimum suspension and correct proximal PTS socket contours.

CLINICAL VERSUS XERORADIOGRAPH® MEASUREMENTS: SURVEY RESULTS

The Xeroradiographs® of 92 adult below knee amputees were reviewed and the following observation was made. It is virtually impossible to conclusively correlate the AP and ML diameter measurements on the Xeroradiograph® to the clinical measurement taken on the patient. That is, no formula could be devised that would reliably allow the prosthetist to predict the patient's clinical AP and ML measurements solely from the corresponding diameters measured on the Xeroradiograph®. This lack of correlation is attributable to three variables:

1. The methods that practitioners use to obtain their clinical diameter measurements vary, resulting in a var-

DISTANCE FROM CENTER OF BONE TO CASSETTE

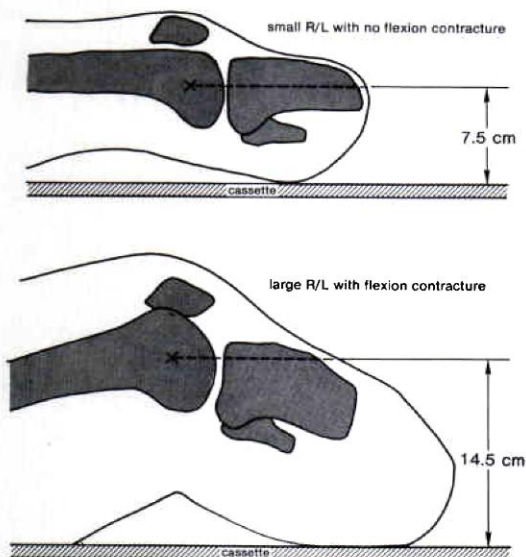


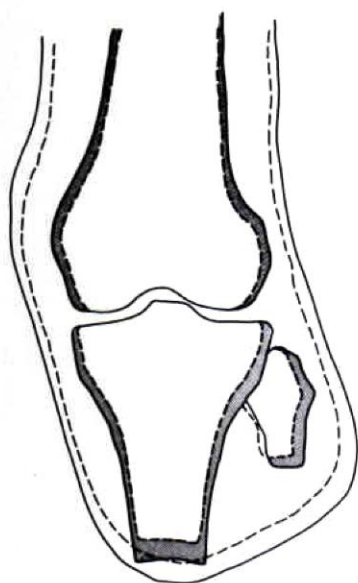
Figure 11. Variation in the distance possible from the center of the femoral condyles to the Xeroradiograph® cassette.

iance of as much as $\frac{3}{8}$ " in the clinically measured AP and ML dimensions of a given patient.

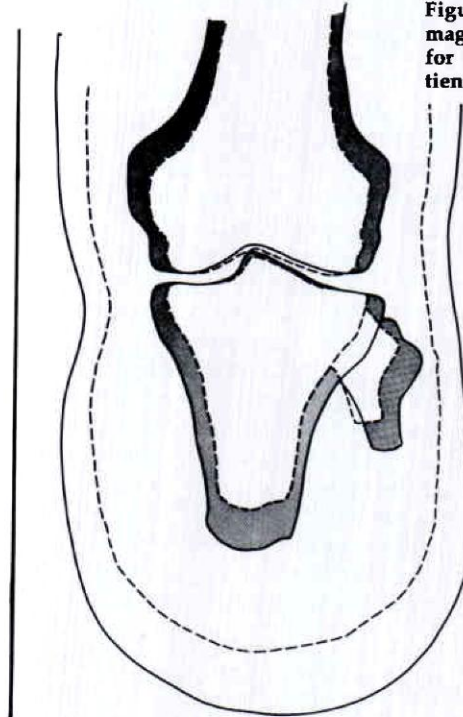
2. The amount of soft tissue thickness at the knee is quite different from one patient to the next.
3. The extent of magnification that occurs on the Xeroradiograph® varies among patients and is due to the vertical distance of the patient's knee from the Xeroradiography® cassette. That distance is determined by:
 - a. The size of the patient's residual limb.
 - b. Presence of a knee flexion contracture (Figure 11).
 - c. The amount of soft tissue compression of the residual limb where it contacts the cassette.

Thus, using identical radiographic technique, magnification of the image on the Xeroradiograph® may vary between six and 14.5 percent (Figure 12).

The amount of magnification and, hence, image dimensional distortion of the



6% MAGNIFICATION



14.5% MAGNIFICATION

Figure 12. Extent of magnification possible for two different patients.

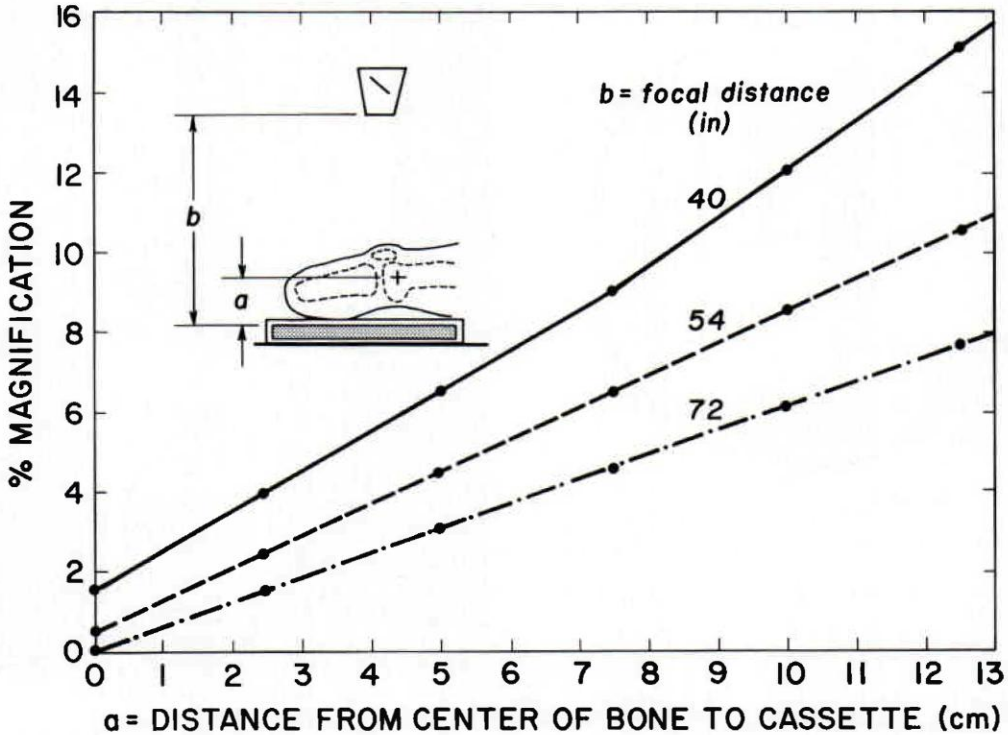
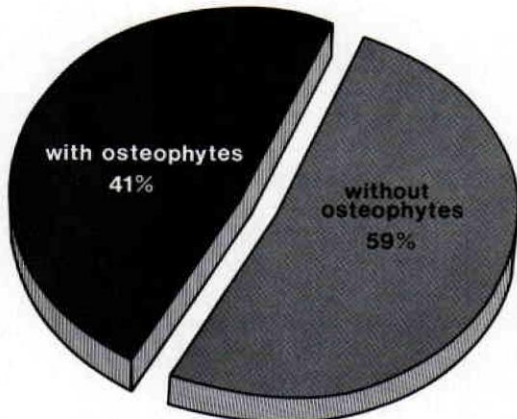


Figure 13. Graph showing the amount of magnification occurring on a Xeroradiograph® for focal tube distances of 40, 54 and 72 inches. Note that magnification is minimized with a small-boned patient (where $a = 5$ cm.) and the focal tube distance is large (where $b = 72$ inches). Even so, under such optimal conditions, the Xeroradiograph® will be magnified three percent.



PRESENCE OF OSTEOPHYTES

Figure 14. Graph illustrating the percentage of the surveyed adult below knee population who have osteophytes on their distal tibias and/or fibulas.

AP and ML diameters, also depends on the focal tube distance to the cassette† (Figure 13). Although most radiology offices can only accommodate 40-54 inches, a 72-inch focal tube distance will reduce magnification to a minimum.

In summary then, magnification is minimized with a small-boned patient who has no knee flexion contracture and some soft tissue compression (i.e., $a = 5$ cm). In addition, magnification is diminished when the focal tube distance is large (i.e., $b = 72$ in.). Even so, in such an instance, the Xeroradiograph® will be

†The authors obtained the data for (Figure 13) as follows:

A radiographic ruler was imaged on Xeroradiography® at 0cm, 2.5cm, 5cm, 7.5cm, 10cm and 12.5cm from the cassettes for each of three common focal tube distances—40 inches, 54 inches, and 72 inches. The linear magnification was then determined by measuring the ruler's image on each of eighteen Xeroradiographs® and computing the percentage enlargement.

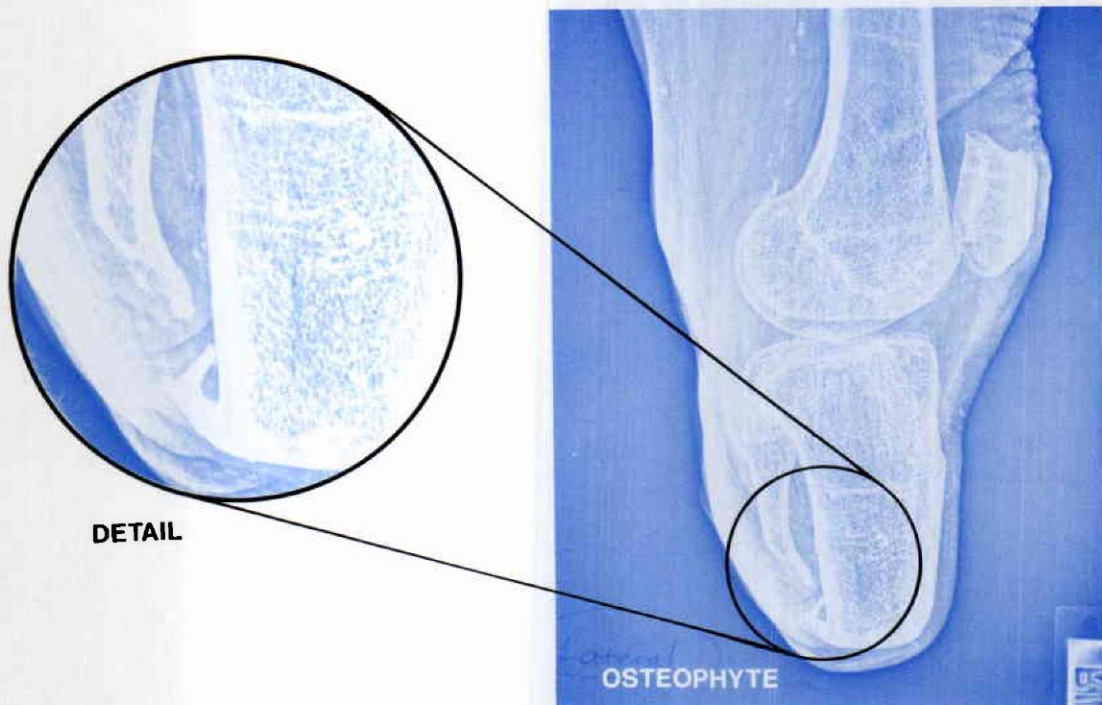
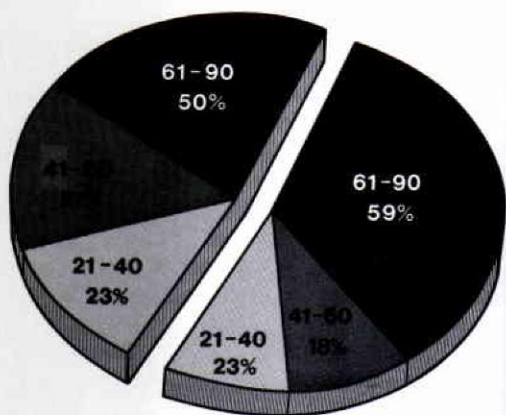
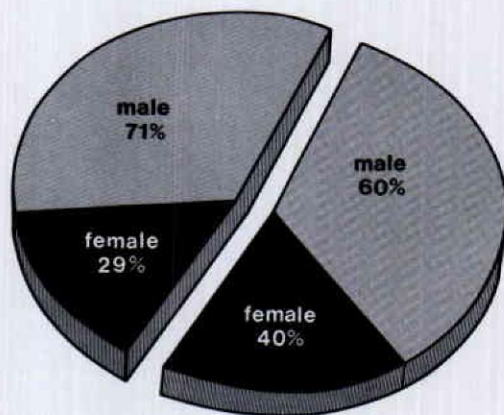


Figure 15. Xeroradiograph® with an osteophyte clearly present on the distal tibia and fibula. Inset: closeup of the osteophyte.



DISTRIBUTION BY AGE



DISTRIBUTION BY SEX

Figure 16. Breakdown of patients' ages for osteophyte population versus non-osteophyte population. Patients' age at amputation had little or no bearing on whether osteophyte formation would occur. Statistical profile of our patient population is comparable to that of 1974 amputee survey.⁵

Figure 17. Sex of the patient had no significant effect on the patient's tendency toward osteophyte formation.

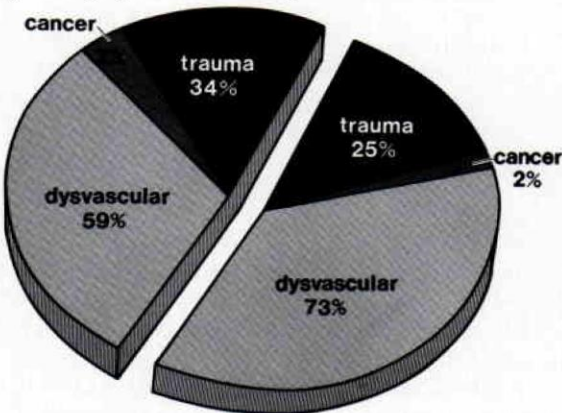
magnified three percent. Exact correlation of clinical and Xeroradiograph® measurements, therefore, is possible only with time-consuming computations.

INCIDENCE OF OSTEOPHYTE FORMATION

A review of the Xeroradiographs® for ninety-two adult below knee amputees bore out surprising information. Namely, on 41 percent of the patients, osteophytes were present on either the distal tibia and/or fibula (Figures 14 and 15). For many of these patients, the osteophytes seemed to pose no fitting problems. For others, the prosthetist used the Xeroradiograph® information together with test socket fittings, and, later, a gel liner, to avoid fitting problems. In two cases, patients required residual limb revisions to have the osteophyte resected. Without the use of Xeroradiographs®, prosthetists have no means of ascertaining the presence, location, and size of osteophyte formation on the patient's bony anatomy.

CAUSE OF OSTEOPHYTE FORMATION

A comprehensive statistical review of the charts for the surveyed below knee amputee population was performed to iden-



DISTRIBUTION BY CAUSE

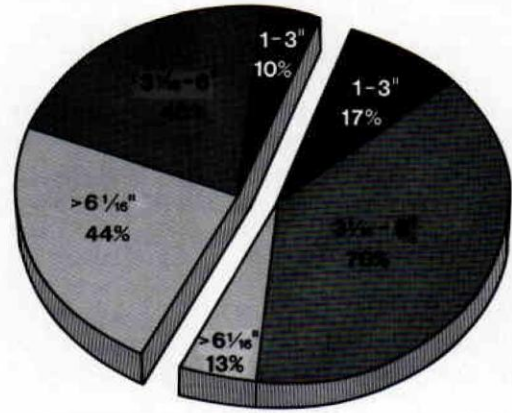
Figure 18. Cause of amputation had no significant effect on the patient's tendency toward osteophyte formation.

tify the cause(s) of osteophyte formation. Neither the patient's age (Figure 16), sex (Figure 17), cause of amputation (Figure 18), nor tibia length (Figure 19) seemed to be a reliable predictor of osteophyte formation. In fact, three bilateral below knee amputees exhibited osteophytes on one residual limb and none on the other.†

In the absence of any specific reference in the orthopedic literature to this phenomenon as a sequela to amputation surgery in adults, our impression is that osteophyte formation in adult amputees is decidedly not bony overgrowth as found in juveniles.⁹ Radiographically, osteophyte formation appears grossly similar to the heterotopic ossification seen as a complication following other types of surgical resection.¹² It is not clear whether osteophytes in residual limbs are an outgrowth from the periosteum or from the cortical bone. The authors feel that the unwanted ossification may result from the manner in which the bone is handled during amputation surgery.

Some orthopedists have expressed interest in conducting a retrospective study to assess the effect that myoplasty has in dis-

†The three bilateral below knee patients were male. Two of the patients' amputations were due to dysvascular causes and were performed at different times. Both amputations of one patient were performed by the same surgeon. The amputations for the other patient were performed by different surgeons. The third patient's amputations were due to trauma and were performed concurrently.



DISTRIBUTION BY TIBIAL LENGTH

Figure 19. Length of the patient's tibia was not an effective predictor of whether osteophyte formation would occur.

couraging osteophyte formation. Further investigation that conclusively identifies the cause of the osteophyte formation phenomenon is warranted in the interest of the amputee's comfort and of optimal amputation technique.

REQUESTING XERORADIOGRAPHS®

To obtain useful Xeroradiographs,® specific instructions must be provided to the radiology technician. We have found that the request form which is pictured (Figure 20) is useful and assures that the necessary projections will be provided to the prosthetist. Although only AP and lateral views are necessary, internal and external oblique views are useful for visualizing bony anomalies in additional planes.

It has proven to be difficult for some radiology technicians to obtain true lateral projections of the below knee residual limb. This can be attributed to the technician's failure to note inadvertent axial rotation of the knee when taking the picture. This oversight is obviously due to the absence of the foot on the extremity for axial rotational reference. A true lateral projection is also sometimes elusive since side-lying on the hard surface of an x-ray table can prove to be difficult for the unilateral patient and certainly is so for the bilateral below knee amputee.

Furthermore, exposure values are critical and must be specified to any radiology service if quality Xeroradiographs® are to be obtained. The exact selection of exposure may be modified for specific machines as well as for patients of varying sizes. The radiology technician must select a setting of 120 kilovolts (kV) but may vary the setting for milliamperes/seconds (mAs). Generally, however, the specifications in the technical information of the request form (Figure 20) usually assure maximum prosthetic usefulness of the Xeroradiographs®.

METHOD

In this prosthetic practice, standard protocol calls for all below knee patients

with mature residual limbs to obtain their Xeroradiographs® prior to casting. The prosthetist, then, has the best available anatomical information with which to commence his work.

If, following the fitting of at least two dynamic transparent test sockets, fitting problems persist, a weight-bearing Xeroradiograph® may be requested to identify the source of the problem. This order is indicated in the special instructions box on the request form (Figure 20). The inner surface of the socket or socket liner may be highlighted easily with self-adhesive copper foil tape, which is used for its radio-opacity. For maximum information regarding socket fit, the patient's residual limb may be imaged in the prosthesis full weight-bearing and partial weight-bearing. Of course, the weight-bearing Xeroradiograph® is also useful when evaluating an ill-fitting, definitive prosthesis of a patient new to the office.

The extent of the osteophyte formation appears to be well-defined six months past amputation, like that of heterotopic ossification following total hip replacement.³ Hence, subsequent Xeroradiographs® are unnecessary for purposes of identifying osteophyte formation if previous ones are on file.

CONCLUSION

The most important advantage of Xeroradiography® is patient management. Since the unique anatomy of a given patient is more observable, the prosthetist approaches his patient with more information and, therefore, greater confidence. That confidence is communicated to his patient.

With the addition of Xeroradiography® to the prosthetic armamentarium, the prosthetist can enhance as well as advance his skills. He becomes a better anatomist, noting the unique bony anatomy of each patient. Even the experienced prosthetist is often surprised by the Xeroradiograph®

³Copper foil tape 3/16" × 1 mil. Venture, Tape, 123 Moore Road, Weymouth, Massachusetts 02189. The copper foil is available in stores selling stained glass supplies.

Beverly Hills Prosthetics Orthotics, Inc.

Offices in Beverly Hills and Van Nuys

214 South Robertson Boulevard
Beverly Hills, California 90211
Phone (213) 657-3353

15230 Burbank Boulevard, Suite 103
Van Nuys, California 91411
Phone (213) 988-0033

PATIENT _____

DATE _____

TYPE OF X-RAY EXAMINATION

- Xeroradiograph
- Radiograph
 - Plain film (soft tissue technique)
 - Plain film (for bone detail)

REGION OF X-RAY EXAMINATION

- RT Below Knee Above Knee _____
- LT Residual Limb Residual Limb _____

VIEWS

- AP
- LATERAL
- INTERNAL OBLIQUE
- EXTERNAL OBLIQUE

- WRITTEN REPORT

SPECIAL INSTRUCTIONS

INSTRUCTIONS TO RADIOLOGIST

1. Use negative mode.
2. All views to include the entire amputation stump and the next proximal joint.
3. Have knee extended and hip in neutral position.
4. Try to prevent tissue distortion from leg resting on table.
5. It is important to have a *true* AP and Lateral view.
6. Label all views.
7. All films should be given patient to return to our office.

TECHNICAL INFORMATION

Development method: Negative Mode
 Focal cassette distance: 40 inches
 Average exposure:
 Single phase--50 MAS, 120 KV
 Three phase--25 MAS, 120 KV

Processor and conditioner should be the same settings as used in negative mode mammography.

PRESCRIBING PHYSICIAN

CERTIFIED PROSTHETIST

Figure 20. Xeroradiography® request form routinely used by the authors.

of a familiar patient and finds the new information beneficial. And while evaluating the patient who is new to him, the prosthetist will find himself groping less for information. With Xeroradiography,[®] he becomes a better informed professional. Still, Xeroradiographs[®] are no replacement for skill and experience. Like transparent test sockets, Xeroradiographs[®] should become an integral part of prosthetic practice.

REFERENCES

- ¹Campbell, C.J., J.F. Rach, and M. Jabbur, "Xero-roentgenography: An evaluation of its uses in disease of the bones and joints of the extremities," *J. Bone and Joint Surgery*, 41-A:2:271-277, March, 1959.
- ²Haslam, Thomas P., Michael T. Wilson, Martha J. Urlaub and Roy M. Borrell, "The Use of X-rays and Xerograms in Prosthetics," *Orthotics and Prosthetics*, 37:1:32-35, Spring, 1983.
- ³Hierion, Claes, Gudmund Blomgren, and Urban Lindgren, "Factors Associated with Heterotopic Bone Formation in Cemented Total Hip Prostheses," *Acta Orthopaedica Scand.*, 54:5:698-702, October 1983.
- ⁴Insall, John and Eduardo Salvati, "Patella Position in the Normal Knee Joint," *Radiology*, 101&101-104, October 1971.
- ⁵Kay, Hector W. and June D. Newman, "Amputee Survey, 1973-74," *Orthotics and Prosthetics*, 28:2:27-32, June 1974.
- ⁶King, Richard E., "X-rays as an adjunct to patellar-tendon-bearing fitting," *Inter-Clinic Information Bulletin*, New York University Research Division, College of Engineering, 2:6:1-8, April 1963.
- ⁷Marschall, Kurt and Robert Nitschke, "Principles of the Patellar Tendon Supra-Condylar Prosthesis," *Orthopedic and Prosthetic Appliance Journal*, 21:1:33-37, March 1967.
- ⁸Marschall, Kurt and Robert Nitschke, "The P.T.S. Prosthesis," *Orthopedic and Prosthetic Appliance Journal*, 20:2:123-126, June 1966.
- ⁹Pellicore, Raymond J., Jean Sciora, Claude N. Lambert, and Robert Hamilton, "Incidence of Bone Overgrowth in the Juvenile Amputee Population," *Inter-Clinic Information Bulletin*, 13:15:1-8, December 1974.

¹⁰Radcliff, C.W. and J. Foort, "The patellar-tendon-bearing below knee prosthesis," San Francisco and Univ. of California Publications, 1961.

¹¹Schertel, Lothar, Dietlof Puppe, Elmar Schnepfer, Helmut Witt, and Karl zum Winkel, *Atlas of Xeroradiography*. Philadelphia, W.B. Saunders Co., 1976.

¹²Soren, A. and Th. R. Waugh, "The Morphologic and Pathogenic Bases of Heterotopic Bone Formation in the Extremities," *Zentralblatt Fur Allgemeine Pathologie Und Pathologische Anatomie*, 127:1-2:91-6, 1983.

¹³Wolfe, John N., "Xeroradiography of the bones, joints and soft tissues," *Radiology*, 93:583-587, September 1969.

¹⁴Wolfe, John N., "Xeroradiography: Image Content and Comparison Film Roentgenograms," *American J. Roentgenol*, 117:690-695, 1973.

¹⁵Wolfe, John N., Kapdi, Chandra K. and Hedwig S. Murphy, *Atlas of Xeroradiographic Anatomy on Normal Skeletal Systems*, Springfield, IL, Charles C. Thomas, Publ., 1978.

AUTHORS

David Varnau, C.P.O., was formerly with Beverly Hills Prosthetics, and is now employed at American Artificial Limb, Seattle, Washington. Keith E. Vinnecour, C.P.O., Monalee Luth, and David F. Cooney, R.P.T., C.P.O. are with Beverly Hills Prosthetics-Orthotics, Beverly Hills, California.

ACKNOWLEDGMENTS

The authors are indebted to Jan Stokosa, C.P. for introducing Xeroradiography[®] to Keith E. Vinnecour. Also, they would like to express their gratitude to Marion Vertun of Xerox Medical System for her technical assistance.

Anthony Alter, M.D. and Yoshio Setaguchi, M.D. assisted the authors in their literature search. Myra Feffer, M.D., Rosa Green, Caren Antler and the entire staff of Beverly Radiology have demonstrated the importance of a competent and cooperative radiology service for the prosthetist using Xeroradiography.[®]

Finally, Monalee Luth's talents in both graphic arts and photography were indispensable.