

NEW SURGICAL APPROACH TO COMPLICATED RENAL ANOMALIES

J. M. GIL-VERNET

From the Department of Urology, School of Medicine, University of Barcelona, Barcelona, Spain

ABSTRACT

The procedures of bench surgery and autotransplantation have been extended to cases of complicated renal anomalies since conventional techniques do not always correct the multiple problems present. Complicated renal anomalies require techniques that will result in the simultaneous treatment of the renal pathological condition and of the urinary tract. In other words, the kidney must have normal anatomical orientation, allowing for ample resection of the dysplastic or dystrophic tract, good urinary drainage and no loss of renal parenchyma. A combination of nephrectomy, bench surgery and autotransplantation has been used successfully in 8 of 9 patients with various anomalies.

Few patients with anomalies of the genitourinary tract have normal renal function. Dysfunction usually is found in patients with renal anomalies such as malrotation, ectopia and horseshoe kidney because these conditions are associated with other urinary malformations. These anomalies frequently are found in the upper urinary tract level (pelvis, pyeloureteral junction and superior ureter) and cause hydronephrosis, pyelonephritis and lithiasis, all of which result in urinary dysfunction. Pathological complications are found more frequently and are more severe in the malformed than in the normal kidney. These anomalies also have a pathological condition of their own. This fact is especially true in cases of horseshoe kidney, which is derived from its topographic relationships and in which pain is the main clinical finding because of the prevertebral isthmus. It is the so-called nonpathological horseshoe but painful kidney¹ and requires surgical treatment (symphysiotomy or symphysiectomy). However, in most cases, complications in the upper urinary tract necessitate a surgical approach and the value of the techniques now in use is questionable.

HISTORICAL EVOLUTION

In 1943 Marion indicated that all dystopic kidneys should be removed because of the complications they can cause.² Then, a decade later this advice was revised since it became possible to treat these complications. However, the procedure used to correct hydronephrosis and lithiasis of the dystopic kidney was not always valid or applicable because it did not correct the pathogenetic factors responsible for the complications. Subsequently, it was found that the number of nephrectomies done greatly exceeded the number of conservative operations.

Urology has benefited greatly by the progress of renal transplantation and of the efficient hypothermia methods that can preserve a kidney for >30 hours. In addition, hypothermia has allowed for the development of autotransplantation³ and of extracorporeal renal bench surgery. Because of the reliability of these procedures and the good results obtained I decided to use them in cases of complicated renal anomalies when a conventional operation had failed or was not effective.

Despite the limited number of cases the long-term results justify this revised treatment of these problematic cases.

PATIENTS AND METHODS

From February 1972 to August 1980, 9 patients with complicated renal anomalies underwent nephrectomy, bench surgery and autotransplantation. Patients ranged in age from 10 to 59 years. Four patients presented with renal malrotation (figs. 1 to 4), 1 with crossed ectopia (fig. 5) and 4 with a horseshoe kidney (figs. 6 to 9). Of the 9 patients 5 had had a previous operation

(table 1). These 5 patients presented with recurring lithiasis or hydronephrosis and urinary infection and, therefore, the indication for this type of treatment was justified in view of the evident failure of conventional techniques and the fact that in some cases the only other possible treatment was nephrectomy. One of the 4 remaining patients (case 7) was a 22-year-old man with massive hydronephrosis in an ectopic kidney and extensive ureteral obstruction. Because of the age of this patient a conservative operation was attempted but results were poor and secondary nephrectomy was necessary. In the remaining 3 patients the contralateral kidney also was abnormal or pathological. It is known that in young patients, especially children, renal malformations are more grave the younger the child is and, therefore, a prompt solution is required.

In all cases extensive surgery was necessary to correct the anterior placement and high insertion of the pelvis, the angulation of the pyeloureteral junction and the dysplastic lesions of the ureter responsible for the obstruction. These aims can only be achieved with autotransplantation, allowing for ample excision of tissue and resulting in normal urinary drainage when the anomalous anatomical orientation of the kidney is rectified.

An excretory urogram (IVP) was done routinely in all cases, as was cystoureterography to eliminate the possibility of primary ureteral reflux. Angiography revealed that 1 patient had 4 arteries and 4 veins, 2 had 3 arteries and 3 veins, 2 had 3 arteries and 2 veins, 2 had 2 arteries and 2 veins, and 2 had 1 artery and 1 vein.

Systemic studies included creatinine clearances, plasma levels, blood acid-base balance, and urinary culture and sensitivity. Patients with lithiasis also underwent metabolic examination. Of the 9 patients 6 presented with urinary infection and received antibiotic therapy 2 days preoperatively and 3 days postoperatively. This therapy is administered even in the absence of systemic infection to avoid infection of the vascular anastomosis.

OPERATION

A paramedian retroperitoneal incision was done for heminephrectomy and autotransplantation of the horseshoe kidney. The malrotation required a classical lumbar incision for kidney removal, followed by a paramedian incision for reimplantation. A transperitoneal approach was used in cases of ectopia.

In patients with a horseshoe kidney the symphysis is divided and the opposite hemi-kidney is moved toward the lumbar fossa, keeping it in this position by suturing the 2 sheets of the renal fascia to the adventitia of the aorta. Therefore, the great vessels, the nervous plexus and the lymphatic vessels remain free of compression from the isthmus.

The pathological kidney is removed and placed on a work-

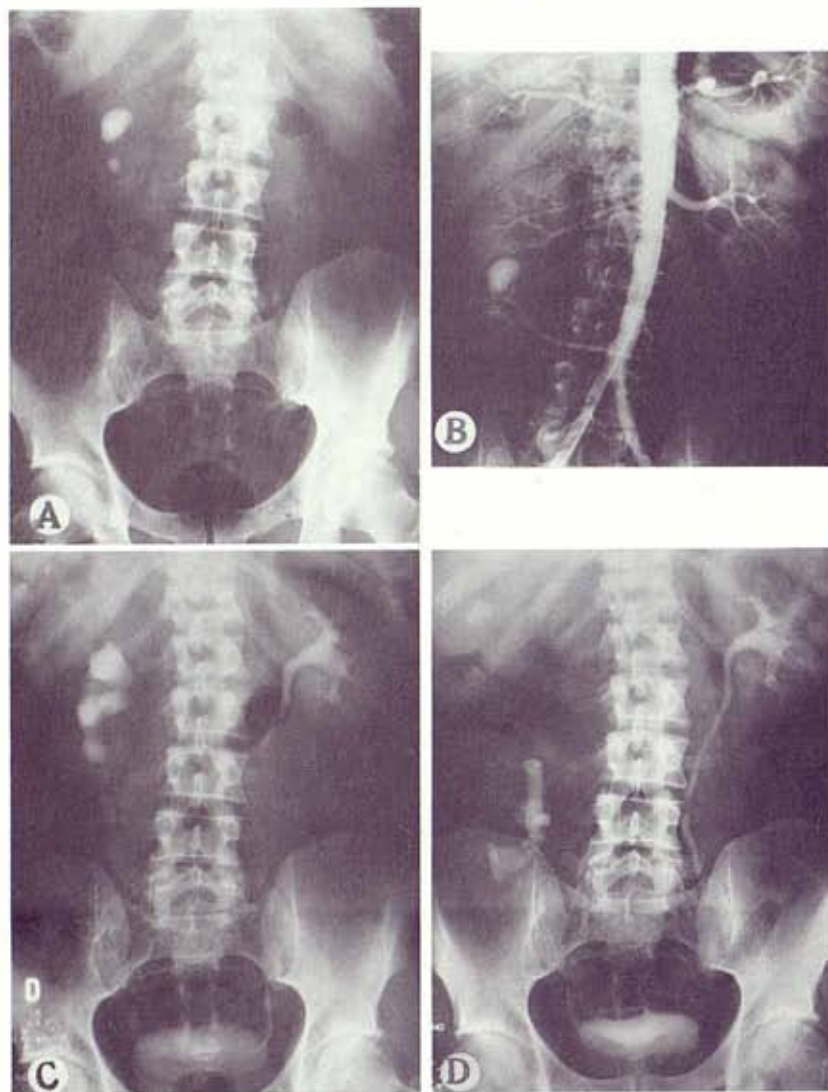


FIG. 1. Case 1. A, x-ray reveals relapsing lithiasis in malrotated kidney. B, aortography demonstrates anomalous kidney with 3 arteries. C, preoperative IVP shows dilatation of calices and pelvis of right kidney. D, IVP after nephrectomy, bench surgery and autotransplantation in inverted lumboiliac position.

bench for repair under constant hypothermia. It is then placed in the recipient, in whom 500 cc modified Collins' solution is perfused only once at 4C. After perfusion the kidney remains in the recipient and is bathed by the same solution. The temperature of this bath (7 to 9C) is maintained by adding ice to it and is controlled by a simple mercury thermometer. During extracorporeal surgery (macrosurgery or microsurgery) the kidney must be kept immersed constantly, while ample resection is done on the pyeloureteral junction and lumbar ureter, and calculi are removed with help from the 3-dimensional x-rays and the image amplifier.

In patients who have been operated on previously the most important procedure is the preparation of the anastomotic stoma that must be done on healthy tissue, far from cicatricial lesions and on the lowest portion of the pelvis. Also, vessels are prepared for reimplantation on the workbench. In patients with >1 vein the small ones are ligated or anastomosed together with microsurgical techniques. In patients with an anomalous kidney the technical problem that arises from the arteries is not the number but the shortness, which forced us in some cases to obtain them with the aortic ostium. In these cases arteries are far apart because the hilus is longer than normal and, therefore, they could not be anastomosed on the bench.

In cases of a horseshoe kidney the isthmic artery frequently irrigates a third of each hemi-kidney and, therefore, it must not

be ligated. In all cases it has been respected and used in the revascularization (fig. 10, A). As in reimplantation the kidney is systematically placed in an inverted position and the continuity of the isthmic artery is re-established by an end-to-end anastomosis of its own edges, the superior renal artery with the internal iliac and the median artery in a termino-lateral anastomosis with the external iliac (fig. 10, B).

When a kidney had 2 arteries of similar caliber they were anastomosed separately with the common iliac and the internal iliac. In 1 case the isthmic artery was not sectioned, only clamped, and the superior pole of the kidney made a 90-degree turn to place itself in an inferior position, that is the isthmic artery was used as a hinge.

Renal hypothermia by external refrigeration is maintained during the vascular anastomoses, which is obtained by placing a mattress of crushed ice between the kidney and the patient, and by irrigating the anterior surface of the kidney with normal saline at 4C. In this way the operative normothermia or premature over-heating of the organ is avoided and the surgeon is not pressed for time, allowing him to do multiple vascular anastomoses without haste and, therefore, with greater perfection. This simple method of hypothermia in situ does not bother the surgeon and protects the kidney during vascularization, which is particularly important because the pathological kidney is far more sensitive to anoxia than the normal kidney.

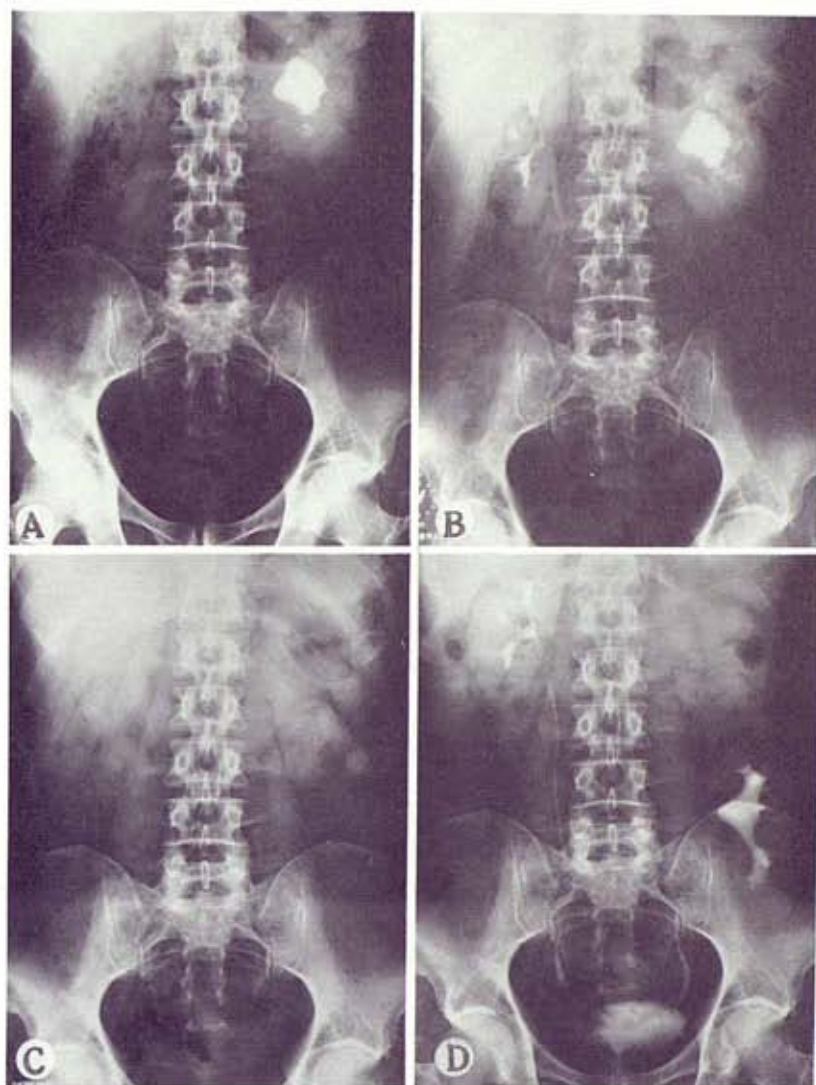


FIG. 2. Case 2. A, x-ray reveals multiple and relapsing renal lithiases. B, IVP reveals functional delay and noticeable pyeloectasia of malrotated left kidney. C, postoperative x-ray shows complete removal of calculi. D, postoperative IVP reveals autotransplanted kidney in left lumboiliac position.

The autotransplanted kidney remains in a lower iliac or lumbar position, according to the heterotopic renal allotransplant technique described in 1967.⁴ The renal vein or veins are anastomosed systematically to the common iliac vein on the left side or to the vena cava on the right side, providing the transplanted organ better hemodynamic conditions than anastomoses to the internal or external iliac veins, a more stable position for the kidney and a better anatomic orientation.⁴ The kidney remains systematically in an inverted position. In other words, the superior pole is placed at the bottom, thus, facilitating vascular anastomoses. Urinary continuity is re-established by anastomosing the cystoid of the iliac ureter to the renal pelvis, leaving a tube of nephroureterostomy. In other words, it is the same technique used in 45 other cases of extracorporeal renal surgery for different indications. The early and long-term results have been reported.^{5,6}

RESULTS

There was no mortality but 1 patient (case 5) lost the transplant 21 days postoperatively (table 2). The patient was a 22-year-old man with a history of urinary infection and a mass in the right iliac fossa. He had a crossed ectopic kidney with marked hydronephrosis, poor function and stenosis of the ure-

ter. Nephrectomy or autotransplantation was discussed. Because of the age of the patient and the good results obtained previously we decided to do a conservative operation and the kidney was removed. The ureteral stenosis and the pyelic bag were resected. Large areas of parenchymatous atrophy were noted. The kidney was transplanted to the opposite iliac fossa. There were no immediate complications and function improved. The patient was discharged from the hospital 15 days later but presented in 6 days with sepsis owing to pyonephrosis, necessitating a secondary nephrectomy. In all other cases there were no immediate or delayed postoperative complications. The 5 patients who had had a previous operation by conventional means involved more technical difficulties. The average operative time was 4 hours 35 minutes. The average hospitalization was 17 days.

In 6 patients some other type of structural lesion at the level of the pyeloureteral junction and the superior ureter was found, supposedly the causes of the uropathy. The most frequent lesion noted was rarefaction of the muscular layer in which the collagen tissue substituted partly for the muscular fibers. Only 1 case of dense parietal fibrosis of the ureter was noted. Renal function has been re-established or improved in 8 cases and urinary infection has disappeared. No recurrent lithiasis has been noted.

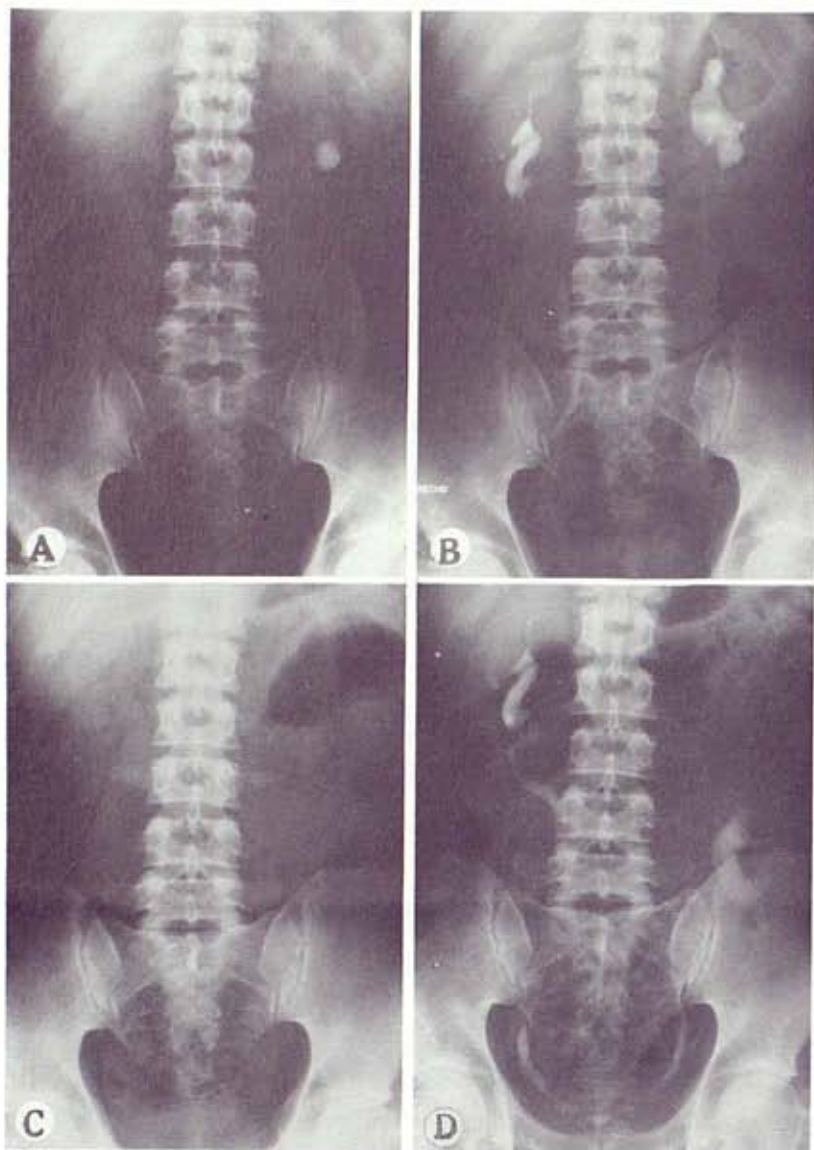


FIG. 3. Case 3. *A*, x-ray reveals relapsing left renal lithiasis. *B*, preoperative IVP shows bilateral renal malrotation and discrete left pyelocaliceal ectasia. *C*, postoperative x-ray. *D*, postoperative IVP.

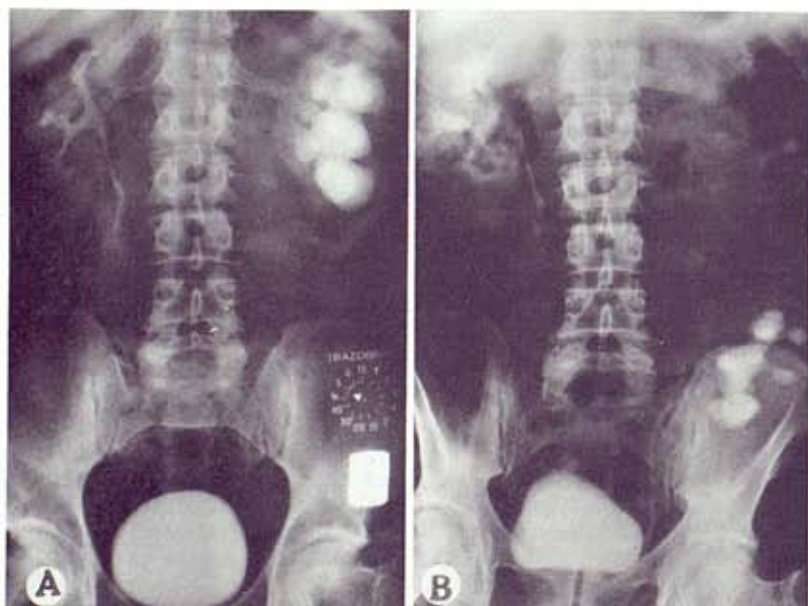


FIG. 4. Case 4. *A*, preoperative IVP reveals malrotation and iatrogenic ureteral stenosis. *B*, postoperative IVP

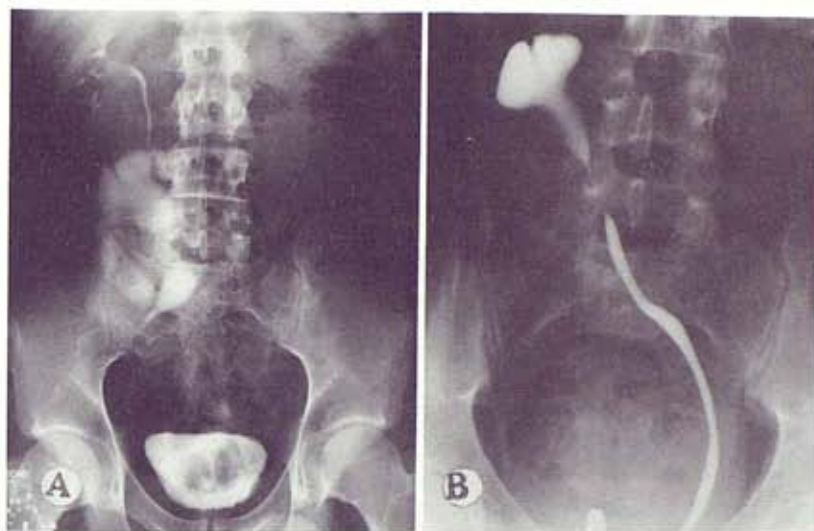


FIG. 5. Case 5. *A*, preoperative IVP reveals crossed renal ectopia and malrotation without fusion, cake shape kidney, great pyelocaliceal ectasia and multiple intrarenal partitioning. *B*, preoperative retrograde ureteropyelography shows large hypoplasia of pyeloureteral junction. This kidney was removed 21 days postoperatively because of pyonephrosis.

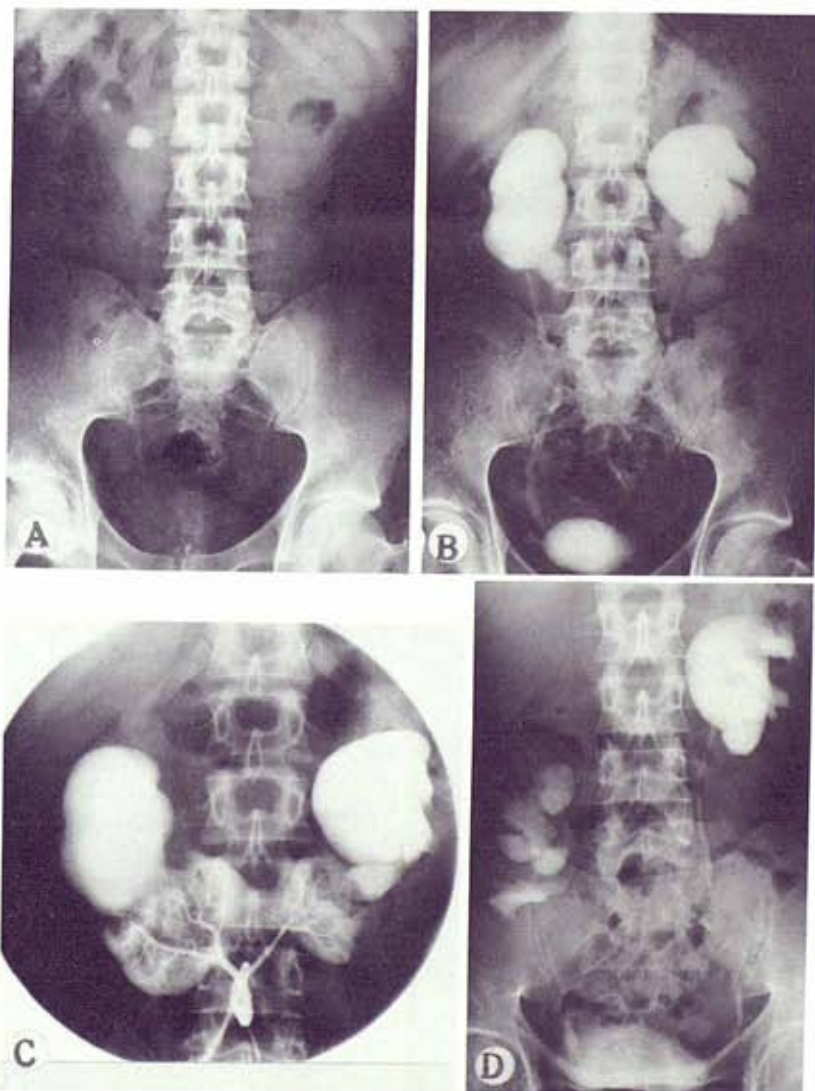


FIG. 6. Case 6. *A*, x-ray reveals lithiasis in horseshoe kidney. *B*, marked bilateral pyelocaliceal dilatation. *C*, aortography and selective arteriography of artery of renal isthmus are of great interest in this operation. *D*, IVP after right heminephrectomy, bench surgery and autotransplantation.

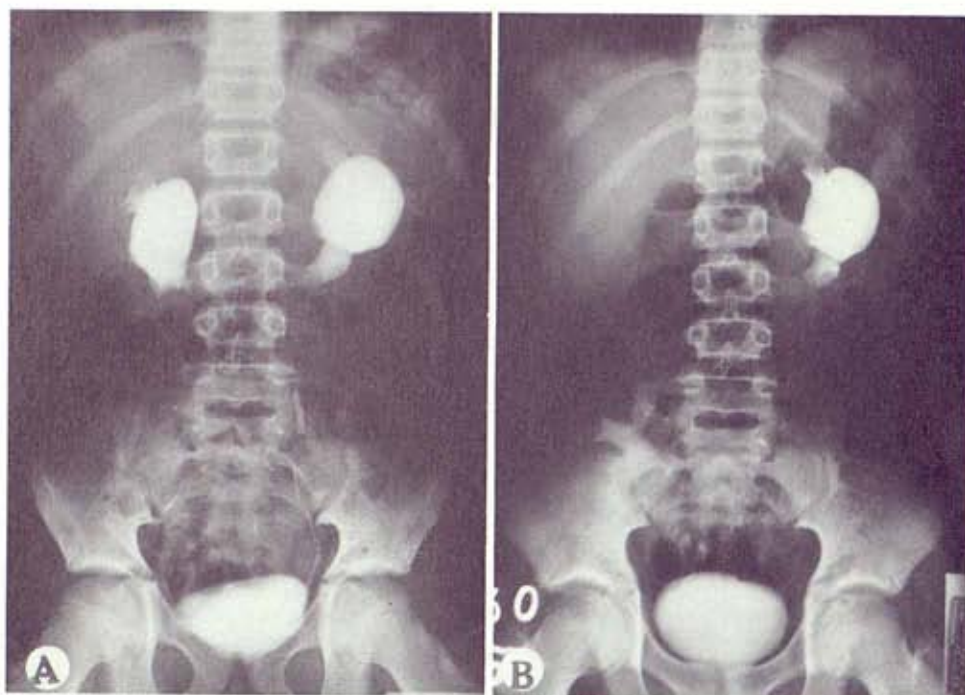


FIG. 7. Case 7. *A*, preoperative IVP reveals horseshoe kidney in 10-year-old child. Bilateral hydronephrosis and painful pathological condition were outstanding. *B*, postoperative IVP reveals right kidney morphologically and functionally normal. Same procedure to be performed on left kidney if needed.

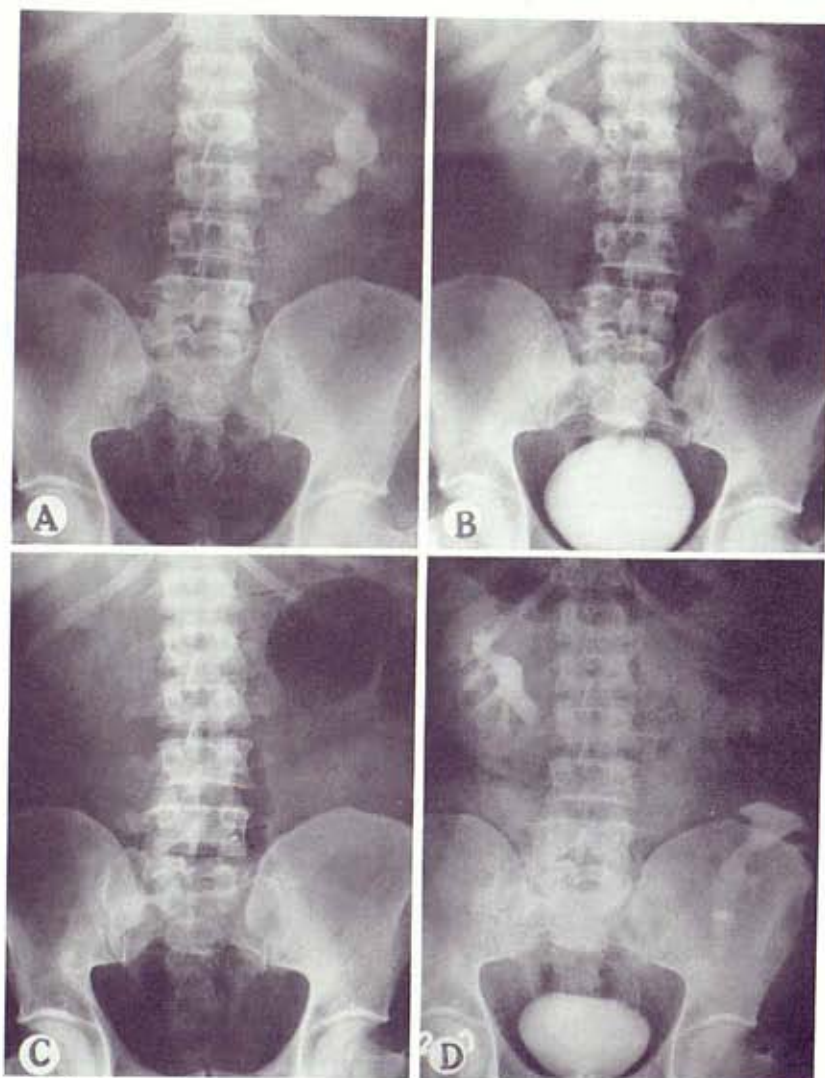


FIG. 8. Case 8. *A*, x-ray reveals relapsing staghorn lithiasis in horseshoe kidney of 130 kg. patient. *B*, preoperative IVP reveals malfunction of left kidney, carrier of urocutaneous fistula. *C*, postoperative x-ray shows complete removal of staghorn calculus. *D*, postoperative IVP.

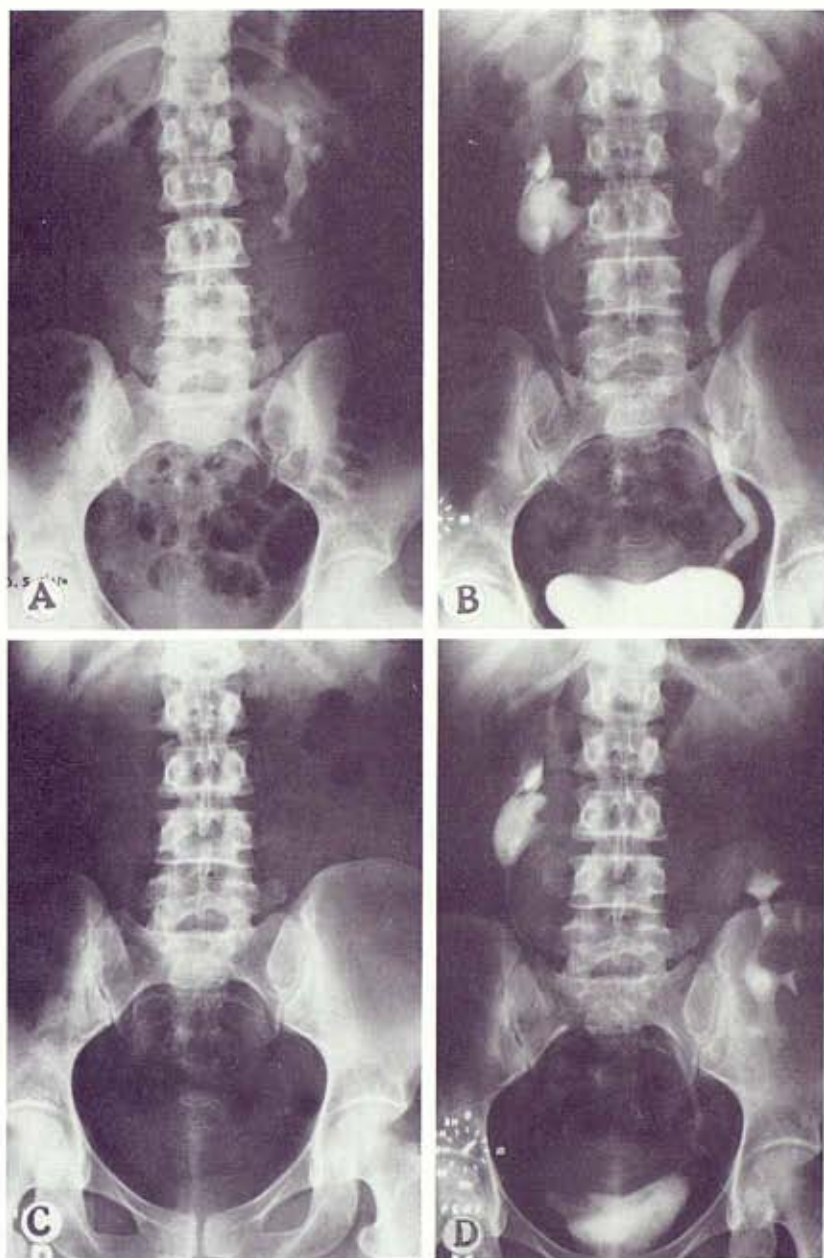


FIG. 9. Case 9. *A*, x-ray shows staghorn calculus in horseshoe kidney. *B*, preoperative x-ray. *C*, postoperative x-ray shows complete removal of calculus. *D*, postoperative IVP.

Followup for these patients has been for a maximum of 8 years and a minimum of 4 months. All patients have returned to normal activities. With these procedures we have achieved the elimination of the large dysplastic or dystropic pyeloureteral segment, a normal anatomical orientation of the organ and better urinary drainage. In addition, we have avoided ureter rides upon the isthmus, removed all calculi without a nephrotomy, eliminated all pain related to the anomaly and retained all renal parenchyma. In conclusion, the renal anomaly and the associated lesions responsible for the complications have been corrected.

DISCUSSION

Until now complicated renal anomalies have not been treated logically, partly because of ignorance of the etiopathogenic factors and partly because of lack of surgical solutions. A conventional operation does not correct the associated lesions nor the anomaly itself, because it does not take into account

the multiple malformations responsible for the complications. Therefore, the high and ventral position of the pelvis, the course of the ureter over the isthmus in cases of a horseshoe kidney or upon the parenchymatous edge in cases of malrotation, the high insertion and the shape of the pyeloureteral junction and so forth cannot be corrected adequately by symphysiectomy, symphysiotomy or partial nephrectomy, because some of the causes related to the morphological problems of the kidney will remain as long as the anomaly of orientation is not corrected.

However, the major problem in using conventional procedures on the anomalous kidney is in the extension of the malformation of its excretory tract above, below or at the level of the pyeloureteral junction. This area frequently exceeds 4 or 6 cm. and has lesions, such as segmental aplasia or hypoplasia of the muscular layer, parietal fibrosis, substitution of the muscle fibers by collagenous tissue, anomalous orientation of the muscular spiral or stenosis. These structural alterations and their extension in the hydronephrotic nonmalformed kidney

TABLE 1

| Case No. | Pt. Age (yrs.) | Previous Renal Surgery | Preop. Pathology | Urinary Infection |
|----------|----------------|---|--|-------------------|
| 1 | 49 | Pyelolithotomy, nephrotomy, symphysiotomy | Staghorn calculus, urocutaneous fistula, pyeloureteral obstruction | Yes |
| 2 | 45 | Pyelolithotomy, ureteropyeloplasty | Pyelocaliceal lithiasis, hydronephrosis, pyeloureteral obstruction | Yes |
| 3 | 29 | Pyelolithotomy | Simple lithiasis | No |
| 4 | 38 | — | Staghorn calculus | Yes |
| 5 | 33 | — | Bilat. hydronephrosis, lithiasis, painful pathological condition | Yes |
| 6 | 43 | Pyelolithotomy | Multiple lithiasis, pyeloureteral obstruction | Yes |
| 7 | 22 | — | Large hydronephrosis, ureteral obstruction | No |
| 8 | 10 | — | Bilat. hydronephrosis, painful pathological condition | No |
| 9 | 59 | Pyelolithotomy and pyelolithotomy plus ureteropyeloplasty | Pyelocaliceal ectasia | Yes |

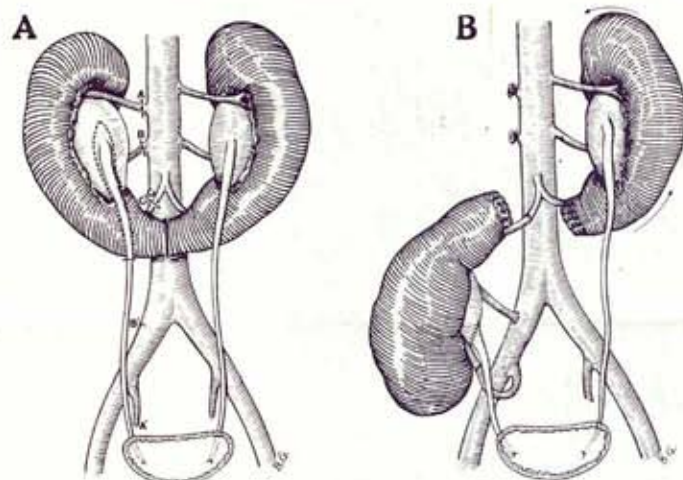


FIG. 10. A, heminephrectomy of horseshoe kidney at level of vascular and ureteral sections, and of symphysis. B, autotransplanted kidney remains in inverted position.

have been described to a variable degree.⁷ As indicated in 6 cases in this series they can represent an obstacle to the physiological filling of the ureteral cone and to the normal urodynamics, and they are the starting point of the evolution towards hydronephrosis and lithiasis. No obstruction was found at the junction level in 3 patients, the caliber being normal or increased.

In these cases the most rational solution is ample resection of the junction but this cannot be accomplished because of anatomicopathological considerations. Conventional ureteropyeloplasty does not solve the problem since these lesions are extensive and there is insufficient ureter left after ample resection for an anastomosis without tension. In addition, the kidney cannot be moved because of its multiple vascular attachments. To replace the resected superior ureter it is preferable to lower the kidney since there is no substitute for the ureter better than the kidney's own ureter.

Surgery for complicated renal anomalies requires simultaneous correction of the anomaly itself and the pathological condition of its urinary tract. In other words, we must eliminate the symphysis, free the nervous and vascular prevertebral structures, do an ample resection of the pyeloureteral junction and

TABLE 2. Anomalies

| | No. Cases | Results | Complications* | Followup |
|------------------------------|-----------|-------------|----------------|---------------------------------------|
| Symphysis (horseshoe kidney) | 4 | Good | 0 | 8 yrs. 6½ yrs. 4 yrs. 6 mos. |
| Malrotation | 4 | Good | 0 | 8 yrs. 7½ yrs. 3 yrs. 4 mos. |
| Ectopia | 1 | Nephrectomy | Pyonephrosis | 21 days |

* No mortality.

facilitate normal urinary drainage, with conservation of all renal parenchyma. These objectives can be achieved now with extracorporeal surgery, microsurgery and autotransplantation. Although it would appear to be surgical acrobatics to extend these procedures to anomalous kidneys I have not had great technical difficulty and the problems have been solved. Bench surgery allows the surgeon to work with the kidney under constant and controlled hypothermia for hours. Therefore, the kidney experiences fewer functional alterations than in cases of a nephrotomy with clamping of the pedicle. All kidneys in this series recovered full function immediately. Although the operations are long (average 4 hours 30 minutes) they are not traumatic because the patient remains in another room under superficial anesthesia while the kidney is being repaired. There has been no mortality in this series. The possibility of infection of the vascular anastomoses cannot be discarded but it has been minimal. Although the majority of patients presented with urinary infection only 1 kidney was lost to infection of the arterial anastomosis 5 days postoperatively.

The results in 8 of the 9 cases are satisfactory. The only failure has been attributed to incorrect surgical indication, the patient requiring nephrectomy. Although this is a small series the results indicate that bench surgery and autotransplantation represent a new solution for problems involving complicated renal anomalies, in which case a conservative conventional operation has failed or is impossible to perform. Nevertheless, this new surgical attitude does not mean that it must be followed systematically in all anomalies. When lithiasis complicates an anomaly, at a later stage and for the first time, a conventional in situ procedure must be done. However, when these procedures fail or when the complications are important and appear at an early stage, and the contralateral kidney is abnormal these procedures are justified.

REFERENCES

- Macquet, P. and Wemeau, L.: *La Chirurgie du Rein en fer a Cheval*. Paris: Masson Publishing, Inc., 1952.
- Marion, M. H.: Un cas de rein ectopique pelvien. *J. d'Urol.*, 52: 42, 1943.
- Gil-Vernet, J. M., Caralps, A., Revert, L., Vidal, M. T. and Carretero, P.: Autotransplantation du rein pour hypertension artérielle de cause vasculaire. *Memoirs and discussions of the 64th session of the French Association of Urology, Paris, France, 1969.*
- Gil-Vernet, J. M.: Homotransplantation rénale humaine avec rein de cadavre. *Aperçu technique. Resultats. Acta Urol. Belg.*, 35: 86, 1967.
- Gil-Vernet, J. M., Caralps, A., Revert, L., Andreu, J., Carretero, P. and Figuls, J.: Extracorporeal renal surgery. *Work bench surgery. Urology*, 5: 444, 1975.
- Gil-Vernet, J. M.: Extracorporeal surgery of the kidney. *Round Table. Read at the XVIII Congress of the International Society of Urology, Paris, France, 1979.*
- Carbone, G., Giuliani, L. and Rocca Rossetti, S.: *Fisiopatologica e clinica delle lesioni proprie del giunto pielo-ureterale*. Official XLVI Congress of the Italian Society of Urology, Genova, Italy, September 1973.