

The emerging syndrome of envenoming by the New Guinea small-eyed snake *Micropechis ikaheka*

D.A. WARRELL^{1,9}, B.J. HUDSON², D.G. LALLOO^{1,3}, A.J. TREVETT^{1,3}, P. WHITEHEAD^{4*}, P.R. BAMLER^{5**}, MAMY RANAIVOSON^{5***}, A. WIYONO⁶, T.L. RICHIE⁷, D.J. FRYAUFF⁷, M.T. O'SHEA^{1,8}, A.M. RICHARDS⁹ and R.D.G. THEAKSTON⁹

From the ¹Centre for Tropical Medicine, University of Oxford, UK, ²Royal North Shore Hospital, St Leonards, NSW, Australia, ³Department of Medicine, University of Papua New Guinea, ⁴Bulolo Health Centre, PNG, ⁵Gaubin Lutheran Mission Hospital, Kar Kar Island, PNG, ⁶Intensive Care Unit, Provincial Hospital, Jayapura, Irian Jaya, Indonesia, ⁷US Naval Medical Research Unit No. 2, Jakarta, Indonesia, ⁸Christensen Research Institute, Madang, PNG, and ⁹Alistair Reid Venom Research Unit, Liverpool School of Tropical Medicine, UK

Received 21 February 1996 and in revised form 25 March 1996

Summary

The New Guinea small-eyed or Ikaheka snake, *Micropechis ikaheka*, which occurs throughout New Guinea and some adjacent islands, is feared by the indigenes. The first proven human fatality was in the 1950s and this species has since been implicated in many other cases of severe and fatal envenoming. Reliable attribution of envenoming to this species in victims unable to capture or kill the snake recently became possible by the use of enzyme immunoassay. Eleven cases of proven envenoming by *M. ikaheka*, with two fatalities, were identified in Papua New Guinea and Irian Jaya. Five patients showed no clinical signs of envenoming. The other six patients showed symptoms typical of envenoming by other Australasian elapids: mild local swelling, local lymphadenopathy, neurotoxicity, generalized myal-

gia, spontaneous systemic bleeding, incoagulable blood and passage of dark urine (haemoglobinuria or myoglobinuria). Two patients developed hypotension and two died of respiratory paralysis 19 and 38 h after being bitten. *In vitro* studies indicate that the venom is rich in phospholipase A₂, is indirectly haemolytic, anticoagulant and inhibits platelets, but is not procoagulant or fibrinolytic. It shows predominantly post-synaptic neurotoxic and myotoxic activity. Anecdotally, Commonwealth Serum Laboratories' (CSL) death adder antivenom has proved ineffective whereas CSL polyvalent antivenom may be beneficial. Anticholinesterase drugs might prove effective in improving neuromuscular transmission and should be tested in patients with neurotoxic envenoming.

Introduction

The New Guinea small-eyed snake or Ikaheka snake (*Micropechis ikaheka*) was first described by Lesson in 1830 from a specimen collected at Doréry (now known as Doré or Manokwari) in former Dutch New Guinea¹ (Figures 1 and 4). The generic name, which

means small-eyed snake, should be pronounced 'microp-echis' not 'micro-pechis'. The specific name 'ikaheka' was from the local name for the snake, meaning 'land eel', referring, no doubt, to its predilection for semi-aquatic habitats, including creeks.

Address correspondence to Professor D.A. Warrell, Centre for Tropical Medicine, John Radcliffe Hospital, Headington, Oxford OX3 9DU.

*Present address: Public Health Dept, Nottingham Health Authority, Forest Rise, Berkeley Avenue, Nottingham, UK

**Present address: Tropenlinik Paul-Lechler-Krankenhaus, D72076 Tübingen, Germany

***Present address: Yagaum Health Centre, PO Box 107, Madang, PNG

© Oxford University Press 1996




Figure 1. New Guinea small-eyed snake as originally depicted by R.P. Lesson as 'Couleuvre Ikaheque (*Coluber ikaheka*)' in Duperrey's 'Voyage autour du monde', 1830.¹



Figure 2. New Guinea small-eyed snake (*Micropechis ikaheka*): living specimens from Kar Kar Island, Papua New Guinea. **a** specimen 1.5 m long—note the small eye; **b** specimen 1.0 m long—note the generally pale colour ('white snake') and circumferential stripes ('tiger snake').



Figure 3. Husk piles in a coconut plantation on Kar Kar Island, Papua New Guinea, a favourite refuge for *Micropechis ikaheka*.

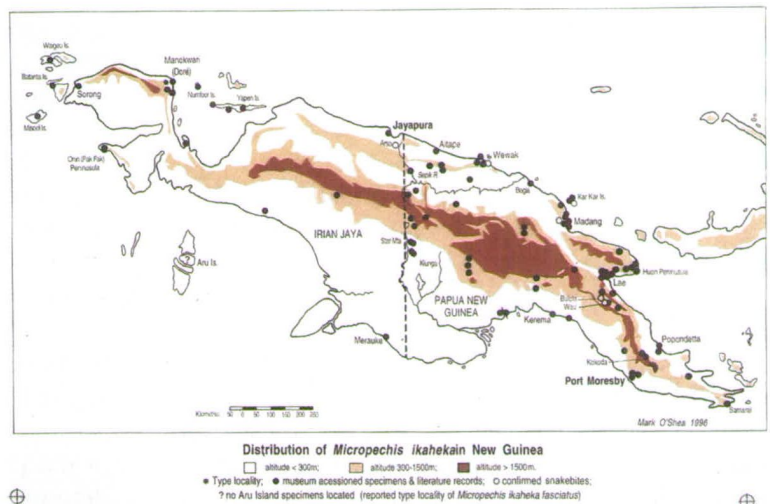


Figure 4. Distribution of *Micropechis ikaheka*.



Figure 5. Male specimen of *Micropechis ikaheka*, 1.69 m long, responsible for biting patient 3 at Arso, Irian Jaya. This species is known locally as 'tiger snake' because of its stripes.

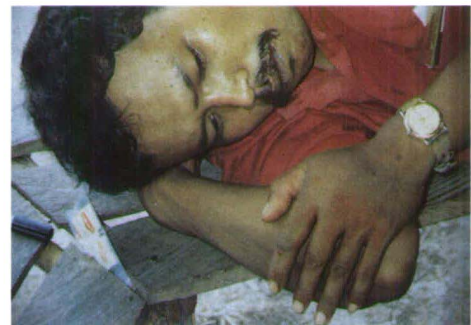

Figure 6. Patient 3, 2 h after the bite, showing the bite near the knuckle of his index finger, swelling of the hand and possible early bilateral ptosis. He was unable to stand up at this stage.

This distinctive snake (Figure 2), which can grow up to 2 m in length, is now known to be widely distributed in monsoon forest, rainforest, swamps and worked coconut palm plantations² (Figure 3) throughout New Guinea and some adjacent islands, from sea level up to 1500 metres³ (Figure 4). *Loveridgelaps elapoides* (Boulenger 1890) which is found in the Solomon Islands, was formerly referred to as *M. elapoides*. The New Guinea small-eyed snake (*M. ikaheka*) should not be confused with the Australian small-eyed snake (*Rhinoplocephalus nigrescens* formerly *Cryptophis nigrescens*) which is not closely related. The lethal potency of stored *M. ikaheka* venom was found to be several hundred times less than that of the taipan (*Oxyuranus scutellatus*); the subcutaneous lethal doses per 25 g mouse were 0.5–1.0 and 0.0034 mg, respectively.⁴ However, the potential danger of *M. ikaheka* bites in humans was established by H.G. Cogger, who identified heads of two specimens sent to the Australian Museum.⁵ These snakes had been responsible for a fatal bite at Wau, Papua New Guinea (PNG), in 1958 and the death of a young man 36 h after being bitten at the base of the thumb while playing with the snake at Wewak, PNG.⁵ K.R. Slater developed nausea, severe headache and weakness persisting for 2 days after being bitten by *M. ikaheka*.⁴ As well as these three cases of proven envenoming, a number of other cases of severe or fatal envenoming have been reported in which the diagnosis of *M. ikaheka* bite was inferred from descriptions by the victims of a 'long white snake' sometimes said to 'shine in the dark'.^{5–7} A young man vomited and died of respiratory paralysis 6 h after being bitten on Kar Kar Island, Madang Province, PNG, where six cases, two of them fatal, had been seen at Gaubin Dispensary by E. Tschärke over a number of years.⁵ Two patients bitten in Madang Province, PNG, developed generalized myalgia, neurotoxicity and haemoglobinuria/myoglobinuria, and one of them died 18 h after the bite.⁷ Recently, six snake bites, including two fatalities attributable to this species, were reported in the space of 4 months at Higatura oil palm plantation near Kokoda, Oro Province, PNG (G. Williamson, personal communication, 1994). The growing suspicion that *M. ikaheka* was a species of medical importance was hard to confirm because of the problem of identifying snakes responsible for bites in PNG.^{4,8} However, it has now been possible to develop a sensitive and specific enzyme immunoassay that has allowed the confirmation of *M. ikaheka* envenoming in eleven new human cases in PNG and Irian Jaya.

Methods

As part of a prospective national survey of snakebites in PNG (Lalloo *et al.*, in preparation), medical officers

and nursing staff in health centres and hospitals all over the country were requested to record clinical details on a standard proforma and to store admission serum samples from patients who developed severe envenoming after snake bite. Studies were also carried out in Madang General Hospital (BJH) and at Gaubin Hospital, Kar Kar Island (PB and JRM).

Enzyme immunoassay method

Samples of serum, wound aspirate, bite site swab eluate and urine were tested by enzyme immunoassay (EIA) for the presence of *Micropechis ikaheka* venom using the method of Theakston *et al.*⁹ with the modifications described by Ho *et al.*¹⁰ Briefly, microtitre plates were coated with IgG raised in rabbits against *M. ikaheka* venom and the venom in the samples was detected using an anti-*M. ikaheka* IgG alkaline phosphatase conjugate. The venom pool used for immunization was obtained from 15 specimens of *M. ikaheka* captured on Kar Kar Island from 1990–4 (by MTO'S). Samples in the study were all assayed for Papuan death adder (*Acanthophis* sp.) venom, as some degree of cross reactivity with *M. ikaheka* venom was occasionally recorded. Most samples were also assayed for the venoms of the Papuan taipan (*Oxyuranus scutellatus canni*), the Papuan black snake (*Pseudechis papuanus*) and the common brown snake (*Pseudonaja textilis*) using specific antisera and conjugates as described by Lalloo *et al.*⁸ Baseline levels from 122 non-bitten individuals originating from the same general socio-economic group as the patients were used to establish the baseline level for the assay.

Other laboratory assays

In addition, where possible, blood coagulability was tested, on admission to hospital, by the 20-min whole blood clotting test^{11,12} and urine samples were tested for the presence of pigment (haemoglobin/myoglobin) by dipsticks.

Results

Enzyme immunoassays

In the Port Moresby study, 933 samples from patients bitten in Central Province and the National Capital District were assayed (Table 1). In only four serum samples were low levels of *M. ikaheka* venom antigen detected, and in all of these there were also high levels of death adder (*Acanthophis* sp.) venom antigen. These were regarded as false positive results caused by cross-reactivity of *Acanthophis* sp. venom antigen with anti-*M. ikaheka* venom antibody. In the Madang study, 4/46 (8.7%) were positive for

Table 1 Number of enzyme immunoassays carried out on PNG* snake bite victims

	Serum	Wound aspirate	Swab eluate	Urine
Samples from individual patients (Port Moresby study)	320	129	142	135
Additional multiple assays on single patients (Port Moresby study)	58	–	–	149
Madang samples	38	–	–	34
Kar Kar Island samples	13	–	–	1
Bulolo sample	1	1	–	–
Irian Jaya sample	1	–	–	–
Totals	431	130	142	319

*Includes one case from Irian Jaya.

M. ikaheka venom and in Kar Kar Island, 5/13 (38%) positive. In these cases and in the positive results from Bulolo and Irian Jaya, there was no cross-reaction with *Acanthophis* sp. venom antibody.

Clinical features of eleven proven cases of envenoming by *M. ikaheka*

All the patients in this series (Table 2) were bitten in the northern coastal region of New Guinea from Arso, Irian Jaya in the west to Bulolo, PNG in the east. Six of the patients trod on the snake; in the case of patient 4 this was while chasing a pig in the bush. Two patients were handling the snake when they were bitten. Patient 1 had killed the snake in the bush and brought it into the village. While

demonstrating the head of the 'dead' snake to his neighbours, he was bitten on the left thumb. Several of the patients describe a 'long white snake' that had bitten them, but only in the case of patient 3 was the snake available for examination (Figure 5). Bites occurred during the day and night. The range of symptoms in the six patients with clinical evidence of envenoming is summarized in Table 3. Early symptoms, experienced within one hour of the bite, included local pain in the bitten limb, vomiting and dizziness. In the four patients who developed neurotoxicity, ptosis was the earliest neurotoxic symptom which developed between 6 and 12 h after the bite. Two patients died with respiratory paralysis 19 and 38 h after the bite, and a third patient developed bulbar paralysis but recovered. Other neurotoxic/

Table 2 Clinical details of eleven patients with proven bites by *Micropechis ikaheka*

Patient	Sex	Age	Where bitten	Time of bite	Bite site	Serum venom concentration (ng/ml)	Clinical outcome
1	M	30	Marup Kar Kar Island*	1200	Thumb	5.5	Died after 19 h
2	M	40	Bulolo	2030	Foot	55.0 (wound aspirate)	Died after 38 h
3	M	25	Arso Irian Jaya	1200	Finger	31.6	Severe envenoming, recovered
4	M	34	Patilo Kar Kar island	1400	Toe	10.7	Severe envenoming, absconded
5	F	10	Transgogol	1500	Toe	3.3	Mild envenoming
6	F	32	Marup Kar Kar Island	2000	—	15 (urine)	Mild envenoming
7	F	22	Transgogol	–	Foot	27.5	No clinical evidence of envenoming
8	F	18	Madang	–	Foot	12.5	As above
9	M	Ad	Madang	0115	Foot	2.2	As above
10	M	29	Dumad Kar Kar Island	–	–	1.1	As above
11	M	39	Buson Kar Kar Island	–	–	0.3	As above

Diagnosis by enzyme immunoassay except patient 3 in which the snake was brought.

*All locations in Papua New Guinea, except patient 3.

Table 3 Symptoms and signs in six patients envenomed by *Micropechis ikaheka*

Neurotoxicity	4
ptosis	4
bulbar	3
limbs	3
Dark urine	3
Fever	3
Generalized muscle pain/tenderness	3
trismus	1
Painful local lymph nodes draining bitten limb	2
Incoagulable blood	2
Hypotension	2
Local swelling at the site of the bite	2
Abdominal pain	2
Dizziness	2
Spontaneous bleeding, vomiting, local pain in bitten limb, headache, tachycardia, bradycardia	1 (each)

myotoxic symptoms included dysarthria, trismus, pain on swallowing and weakness of limbs.

Treatment

Pre-hospital treatment consisted of local razor cuts (patients 2, 5 and 7) and vine tourniquets (patients 5 and 9). Commonwealth Serum Laboratories (CSL) polyvalent and/or death adder antivenom was used in patients 1–5, starting between 6 and 20 h after the bite. Patient 1 reacted to death adder antivenom with shortness of breath and wheezing. There were no dramatic signs of efficacy, but patient 3 showed slow improvement after receiving one 50 ml ampoule of polyvalent antivenom 4 h after the bite, and the minor symptoms in patient 5 resolved within 1 or 2 h of receiving one ampoule of polyvalent antivenom 7 h after the bite. Patient 1 died 19 h after the bite, despite receiving death adder antivenom 6 h after the accident. Patient 2 died in spite of being treated with two ampoules of polyvalent antivenom 20 and 26 h after the bite. Patient 4 showed no response to death adder antivenom given 18 h after the bite but recovered the use of his limbs 3 h after being given an ampoule of polyvalent antivenom 26 h after the accident.

Patient 2 was intubated about 27 h after the bite but no mechanical ventilator was available for him or for patient 1; both of them died with respiratory paralysis.

Symptoms were persistent in some of the surviving patients. Patient 3 was still passing dark urine 5 days after the bite and Patient 4 still had marked bilateral ptosis when he absconded home 5 days after the bite.

Case histories

Patient 2: fatal envenoming in PNG

A 40-year-old man was bitten on the dorsum of the left foot at 2030 h on 3.4.92 at Bailis on the outskirts of Bulolo, a town near Wau in Morobe Province, PNG. The patient trod on the snake which was on the steps leading to his verandah. It was described as being 1 m long, thin with a black head, spots of various colours and black, yellow and white stripes on the body. The snake was aggressive, rearing up and striking at nearby people. This is unusual behaviour for *M. ikaheka* which generally tries to escape by burrowing under debris or strikes to the side. It hung on after the bite. The relatives tried to excise the bite and suck out the venom. He was admitted to Bulolo Hospital 45 min after the bite. Within 10 h he had developed some swelling of the foot and, after 12 h, ptosis and pain on swallowing, but there was no bleeding and his blood clotted normally. He was transferred to Angau Hospital, Lae, on 4.4.92 at 1100 h, arriving there at 1536 h. He was fully conscious and alert but unable to talk, cough, swallow saliva or open his mouth fully. He complained that his limbs felt heavy. He was given one ampoule of CSL polyvalent antivenom intravenously over 30 min about 20 h after the bite, after prophylaxis with promethazine and adrenaline and antibiotics. At 2100 h on 4.4.92 he was still conscious but distressed and showed an abdominal pattern of respiration. No mechanical ventilator was available but he was intubated at 2300 h and given a second ampoule of polyvalent antivenom 26 h after the bite. He had not passed urine since the previous day and so was catheterized, releasing 400 ml of dark-coloured urine (strongly positive for haemoglobin/myoglobin). His blood clotted in less than 15 min, FDP < 10 µg/ml; bilirubin 102 mmol/l, urea 19 mg/dl; sodium 141, potassium 4.5 (both in mmol/l); haemoglobin 13.7 g/dl, leucocytes $7.8 \times 10^9/l$. At 0900 h on 5.4.92 he was reported to be sedated, afebrile, breathing spontaneously with clear lungs and a non-tender abdomen, but his blood pressure, which had been 120/80 mmHg on admission, had fallen to 90/60 at 0800 h and to 70/50 at 0900 h. At 1055 h, 38 h after the bite, he was certified dead.

M. ikaheka venom antigen (55.0 ng/ml) was detected in a wound aspirate sample taken on admission to Bulolo Hospital.

Patient 3: severe envenoming with recovery in Irian Jaya

A 25-year-old immigrant from south Sulawesi was bitten by a snake on his left index finger at the Arso XI Transmigration Settlement in northeastern Irian

Jaya at about 1200 h on 18.12.93. He was bitten while playing with a snake which had been caught in a bird trap slung up in the trees of the forest. It was later identified as a male specimen of *M. ikaheka*, total length 1690 mm including tail 165 mm (now deposited at the British Museum of Natural History London, accession number BMNH 1994.525), known locally as 'tiger snake' because of its circumferential stripes (Figure 5). At a nearby military post he was reassured by some soldiers, who were not locals, that the snake was non-venomous but he felt increasing pain in the bitten finger. He arrived at the NAMRU2 field laboratory/clinic at about 1300 h. There were two small puncture wounds on the bitten finger which were bleeding slightly. Within the next hour he vomited, began to salivate copiously, became dysarthric and was unable to stand up (Figure 6). There was increasing pain in the left hand, arm and joints with progressive moderate swelling. Because of decreasing consciousness, reduced strength in his limbs, a weakening pulse and falling blood pressure, he was treated with intramuscular injections of diphenhydramine and dexamethasone and transferred via a local hospital at Abepura to the regional hospital in Jayapura. During the 2 h drive to Jayapura, copious mucus was running from his nose which became heavily bloodstained about 3 h after the bite. On admission to the emergency room at Jayapura Hospital at 1615 h, about 4 h after the bite, he was found to be apathetic, in respiratory distress and with continuing hypersalivation requiring frequent suction. His temperature and blood pressure (110/70 mmHg) were normal. Blood taken at this time was found to be incoagulable; the plasma contained 31.6 ng/ml *M. ikaheka* venom antigen. At 1630 h, an intravenous infusion of one ampoule of CSL polyvalent antivenom was begun and he was transferred to one of the hospital wards. However, by 2230 h, his condition had deteriorated and he was transferred to the intensive care unit. His eyes were closed, he was able to open his mouth but had difficulty swallowing and protruding his tongue. There was evidence of paresis of respiratory muscles and those innervated by VII, III, IV, VI, IX and XI cranial nerves. Urethral catheterization yielded 100 ml of black urine. Myoglobin was detected by differential ammonium sulphate solubility and 'Haemastix' testing.¹³ The ECG monitor showed occasional sinus bradycardia of 60 per min. On the following day, there was no improvement in his neurological signs and he was complaining of abdominal pain. He had passed 300 ml of urine which was less dark but contained numerous erythrocytes. Forty-eight hours after the bite his cranial nerve palsies had improved; the ptosis had decreased but he still had diplopia. There was no evidence of paresis of IX, X, XI or XII cranial

nerves. He was still complaining of abdominal pain and pain and swelling of the left arm. Haemoglobin 12.8 mg/dl, leucocytes $9.6 \times 10^9/l$, whole blood clotting time and bleeding times normal at 6 min 30 s and 4 min 7 s, respectively. The urine still contained protein, myoglobin and some erythrocytes. Over the next 3 days, his symptoms continued to improve although there was persistent swelling of the bitten arm, proteinuria, haematuria and myoglobinuria. Blood biochemistry, including creatinine and urea, remained normal throughout. He was transferred back to the general wards on the sixth day after the bite with a swollen face and bitten arm, trismus and myoglobinuria. Two weeks after the bite his speech was still slurred.

Discussion

These new observations establish the clinical syndrome of envenoming by *M. ikaheka*. Descriptions of neurotoxic symptoms, generalized myalgia, muscle tenderness and the passage of very dark urine in cases of suspected *M. ikaheka* envenoming^{5,7} are confirmed as features of this syndrome. *In vitro*, *M. ikaheka* venom impaired neuromuscular transmission and showed direct myotoxicity which was identified with phospholipase A₂ activity.¹³ The venom inhibited binding of ¹²⁵I- ω -CgTx and, to a lesser extent, ¹²⁵I- ω -CmTx to human frontal cortex and cerebellum but had no effect on binding of ¹²⁵I- ω -Agatoxin IVA or ¹²⁵I- α -DndTx binding. These studies suggested that the main effect of the venom on neuromuscular transmission in humans was on post-synaptic acetylcholine receptors rather than on pre-synaptic voltage-gated calcium channels.¹⁴ The latter activity is probably due to phospholipase A₂ which could explain rhabdomyolysis, manifest in these patients as generalized myalgia, muscle tenderness, trismus and probable myoglobinuria.

The neurotoxic features observed in four of our patients were similar to those reported in cases of suspected, but not proven, *M. ikaheka* bites in Kar Kar Island and Madang region by Blasco and Hornabrook⁵ and Hudson.⁷ In three of these cases, bulbar and/or respiratory paralysis developed which was fatal in two of them. Three of our patients passed dark urine, persistently in the case of patient 3, a feature mentioned in several of the suspected cases.⁷ Unfortunately, the urinary pigment was demonstrated to be myoglobin rather than haemoglobin in only one case (patient 3) using a test which is not completely reliable but, taken with the accompanying symptom of generalized muscle pain and tenderness, with trismus in one patient, there was a strong suggestion that these patients had myoglobinuria resulting from generalized rhabdomyolysis. This

is an effect of venoms of other Australasian elapids and, in PNG, myoglobinuria has been confirmed in patients bitten by taipans (*Oxyuranus scutellatus canni*) (B. Currie, personal communication) and increases in serum creatinine kinase or muscle tenderness have been found in victims of death adder bites (*Acanthophis* sp.).¹⁵

Two of the three patients tested had incoagulable blood and, in one of them (patient 3), there was spontaneous bleeding from the nose and microscopic haematuria. Haemostatic abnormalities have not been described in any of the suspected cases of *M. ikaheka* envenoming. *In vitro* studies showed no evidence of procoagulant activity but a marked anticoagulant effect, probably attributable to phospholipase A₂ inhibition of platelet aggregation.¹⁶ Detailed studies of haemostasis are needed in human victims of *M. ikaheka* envenoming. The venom anticoagulant effect could result in incoagulable blood in the absence of hypofibrinogenaemia and without associated increase in fibrin(ogen) degradation products. *M. ikaheka* venom has also been shown to be indirectly haemolytic and to inhibit neutrophil function.¹⁶

Two of our patients (patients 2 and 3) developed hypotension. In patient 2, it was associated with terminal respiratory paralysis, but in patient 3 it was associated with bradycardia and may indicate a direct effect of the venom on the myocardium as has been inferred in patients envenomed by taipans.¹⁷

For first aid treatment of *M. ikaheka* bites, the compression immobilization method¹⁸ is recommended, since the venom, although causing some local swelling, does not cause necrosis. No antivenom with specific activity against *M. ikaheka* venom is available and, in view of the difficulties of obtaining this venom, or living specimens of *M. ikaheka*, from New Guinea, it is unlikely that such an antivenom will be produced in the near future. Our experience with the patients described in this paper, and other reports,⁷ indicates that CSL death adder antivenom is useless, and that CSL polyvalent antivenom may be effective when given within a few hours of the bite. In patients with progressive neurotoxicity, accumulation of secretions in the pharynx is a warning to guard the airway by careful positioning or placement of a cuffed endotracheal tube and to provide mechanical ventilation where this is available. In view of the predominantly post-synaptic site of action of *M. ikaheka* venom neurotoxins,¹⁴ anticholinesterases might well produce a clinically useful improvement in neuromuscular transmission, perhaps preventing the need for mechanical ventilation, as in the case of victims of death adder bites in PNG¹⁵ and Asian cobras.¹⁹ Use of the 'Tensilon test', as in patients with suspected

myasthenia gravis, will indicate which patients may benefit from longer term anticholinesterase treatment.

More clinical studies are needed to clarify the incidence and pathophysiology of life-threatening envenoming by *M. ikaheka* and to establish effective methods of treatment in the remote areas where bites by this interesting, mysterious and elusive species occur. The inhabitants of Kar Kar Island realise the importance of bites by this species, but elsewhere in New Guinea they are an unrecognized medical hazard.

Acknowledgements

DGL received financial support from the UNDP/World Bank/WHO Special Programme for Research and Training in Tropical Diseases and the Rockefeller Foundation, AJT was supported by the Wellcome Trust and MTO'S by a Christensen Research Fellowship, Christensen Fund, Palo Alto, California, and by Therapeutic Antibodies (UK) Ltd. PW was employed by Voluntary Service Overseas. AMR was supported by the Leverhulme Trust and the Ax:son Johnson Foundation for Nature Medicine Dr YR Krishnaswamy (Angau Memorial Hospital, Lae) and Dr Ian Laurenson provided valuable clinical details about patient 2. We are very grateful to Mr Roger Middleton and his family of Kulili Estates, Kar Kar Island for their help with collection of snakes on Kar Kar Island, to Dr Matthew Jebb, Director of the Christensen Research Institute, Madang, and to Professors Sirus Naragi and Isi Kevau, University of Papua New Guinea for help and encouragement, and to Miss Eunice Berry for preparing the manuscript.

References

1. Lesson RP. Reptiles. In: Duperrey MLI, ed. *Voyage autour du monde*. Arthus Bertrand, Paris, 1830: Zoologie II p 54.
2. O'Shea MT. *A Guide to the Snakes of Papua New Guinea*. Independent Publishing, Port Moresby, 1996.
3. Parker F. The snakes of Western Province. PNG Dept of Lands and Environment: Konedobu 1982; *Wildlife in Papua New Guinea* No 82/1; 54–5.
4. Campbell CH. *A clinical study of venomous snake bite in Papua*. Thesis submitted for the degree of Doctor of Medicine, University of Sydney, 1969.
5. Blasco P, Hornabrook RW. A neglected but potentially dangerous New Guinea snake—the small eyed snake (*Micropechis ikaheka*). *Papua New Guinea Med J* 1972; 15:155–6.
6. Hudson BJ, Pomat K. Ten years of snake bite in Madang Province, Papua New Guinea. *Trans Roy Soc Trop Med Hyg* 1988; 82:506–8.
7. Hudson BJ. The small-eyed snake (*Micropechis ikaheka*): a review of current knowledge. *Papua New Guinea Med J* 1988; 31:173–8.

8. Lalloo DG, Trevett AJ, Korinhona A, Nwokolo N, Laurenson I, Paul M, Black J, Naraqi S, Mavo B, Saweri A, Hutton RA, Theakston RDG, Warrell DA. Snakebites by the Papuan taipan (*Oxyuranus scutellatus canni*): paralysis, haemostatic and electrocardiographic abnormalities and effects of antivenom. *Am J Trop Med Hyg* 1995; **52**(6):515–31.
9. Theakston RDG, Lloyd-Jones MJ, Reid HA. Micro-Elisa for detecting and assaying snake venom and venom-antibody. *Lancet* 1977; **ii**:639–41.
10. Ho M, Warrell MJ, Warrell DA, Bidwell D, Voller A. Review. A critical reappraisal of the use of enzyme-linked immunosorbent assays in the study of snake bite. *Toxicon* 1986; **24**(3):211–21.
11. Warrell DA, Davidson NMCD, Greenwood BM, Ormerod LD, Pope HM, Watkins BJ, Prentice CRM. Poisoning by bites of the saw-scaled or carpet viper (*Echis carinatus*) in Nigeria. *Q J Med* 1977; **46**:33–62.
12. Sano-Martins IS, Fan HW, Castro SCB, Tomy SC, França FOS, Jorge MT, Kamiguti AS, Theakston RDG, Warrell DA, BIASG. Reliability of the simple 20 minute whole blood clotting test (WBCT20) as an indicator of low plasma fibrinogen concentration in patients envenomed by *Bothrops* snakes. *Toxicon* 1994; **32**(9): 1045–50.
13. Frankel S, Reitman S, Sonnenwirth AC (eds). *Gradwohl's Clinical Laboratory Methods and Diagnosis*, 7th edn, vol. II. Mosby, London, 1970:603.
14. Geh S-L, Vincent A, Rang S, Abrahams T, Jacobson L, Lang B, Warrell D. Identification of phospholipase A₂ and neurotoxic activities in the venom of the New Guinea small-eyed snake (*Micropechis ikaheka*). *Toxicon* (in press).
15. Lalloo DG, Trevett AJ, Black J, Mapa OJ, Saweri A, Naraqi S, Owens D, Kamiguti AS, Hutton RA, Theakston RDG, Warrell DA. Neurotoxicity, anticoagulant activity and evidence of rhabdomyolysis in patients bitten by death adders (*Acanthophis* sp) in southern Papua New Guinea. *Q J Med* 1996; **89**:25–35.
16. Kamiguti AS, Treweeke AT, Lowe GM, Laing GD, Theakston RDG, Warrell DA, Zuzel M. Platelet and neutrophil function inhibition by *Micropechis ikaheka* (small-eyed snake) venom: role of phospholipase A₂. *Toxicon* 1995; **33**(3):275.
17. Lalloo DG, Trevett AJ, Nwokolo N, Laurenson IF, Naraqi S, Kevau I, Kemp MW, Hooper RJL, Theakston RDG, Warrell DA. Electrocardiographic abnormalities in patients bitten by taipans (*Oxyuranus scutellatus canni*) and other elapid snakes in Papua New Guinea. *Trans Roy Soc Trop Med Hyg* (in press).
18. Sutherland SK, Coulter AR, Harris RD. Rationalisation of first aid measures for elapid snakebite. *Lancet* 1979; **i**:183–6.
19. Watt G, Theakston RDG, Hayes CG, Yambao ML, Sangalang R, Ranoa CP, Alquizalas E, Warrell DA. Positive response to edrophonium in patients with neurotoxic envenoming by cobras (*Naja naja philippinensis*). A placebo-controlled study. *N Engl J Med* 1986; **315**:1444–8.