



AgEcon SEARCH
RESEARCH IN AGRICULTURAL & APPLIED ECONOMICS

The World's Largest Open Access Agricultural & Applied Economics Digital Library

This document is discoverable and free to researchers across the globe due to the work of AgEcon Search.

Help ensure our sustainability.

Give to AgEcon Search

AgEcon Search
<http://ageconsearch.umn.edu>
aesearch@umn.edu

*Papers downloaded from **AgEcon Search** may be used for non-commercial purposes and personal study only. No other use, including posting to another Internet site, is permitted without permission from the copyright owner (not AgEcon Search), or as allowed under the provisions of Fair Use, U.S. Copyright Act, Title 17 U.S.C.*

Gastro-intestinal helminths of ducks: Some Epidemiologic and pathologic aspects

M. A. Yousuf, P. M. Das, Anisuzzaman¹ and B. Banowary

Department of Pathology, Bangladesh Agricultural University, Mymensingh-2202, Bangladesh

¹Department of Parasitology, Bangladesh Agricultural University, Mymensingh-2202, Bangladesh

Abstract

A total of 206 ducks were subjected to routine postmortem examinations from July 2007 to June 2008. Of the ducks examined, 167 (81.1 %) were infected by one/more species of gastro-intestinal helminths. A total of ten species of helminth parasites were recovered from gastrointestinal tract, of which four species were trematodes namely: *Echinostoma revolutum*, *Notocotylus attenuatus*, *Hypoderaeum conoideum* and *Echinoparyphium recurvatum*; two were nematodes, namely, *Amidostomum anseris*, *Capillaria contorta*; two were cestodes, viz, *Hymenolepis coronula* and *Fimbriaria fasciolaris* and two species belonged to acanthocephala such as, *Arythmorhynchus anser* and *Filicollis anatis*. Single double and mixed infections were found in 78 (46.7%), 46 (27.5%) and 43 (25.8%) ducks, respectively. Prevalence of gastrointestinal helminth was significantly ($P < 0.05$) higher in female ducks (82.7 %) than male ducks (77.6%). Ducks above six month to one year of age were more affected (53.9%) than the ducks < 6 month (15.0%) and > 1 year of age (31.1%). Helminth infection was significantly ($P < 0.05$) lower in rainy season (64.9%) in contrast to summer (75.7 %) and winter season (91.1 %). In heavy infections of *E. revolutum* haemorrhagic enteritis were noticed and parasites were firmly attached with the mucosa. *E. recurvatum* caused thickening of the serosal surface of intestinal wall. *N. attenuatus* produced catarrhal typhlitis characterized by thickening of the villi and formation of eosinophilic granulomas. Massive infections with *H. coronula* produced inflammatory changes in the small intestine. Grossly petechial haemorrhages to ulcerative lesions were produced by *A. anseris*. In proventriculus circular ulcerative and necrotic areas with degeneration of the glandular tissues were seen. *A. anser* was also found in between the horny and muscular layer of the gizzard where they produced pin pointed haemorrhagic lesions and in severe case parasites were embedded into the mucosal layers of gizzard. For the control of helminths infections mass deworming is necessary.

Keywords: Gastro-intestinal helminths, Ducks, Epidemiology, Pathology

Introduction

The duck population in Bangladesh is 35 million, which comprises about 10% of the total poultry. Ducks are commonly used for dual purpose (meat and egg) and mostly reared under traditional system (FAO, 1990). Parasitic infection is one of the major constraints in duck rearing in Bangladesh of which helminth infection is common. In fact, ducks are affected by different types of helminths (Anisuzzaman *et al.*, 2005, Farjana *et al.*, 2004, Islam *et al.*, 1988), but very little attention has been paid to study the epidemiologic and pathologic aspects of helminth infections in ducks. Anisuzzaman *et al.* (2005) observed chronic active liver cirrhosis in ducks due to avian liver flukes infection. Das *et al.* (2008) observed sign of asphyxia due to tracheal fluke infection. The knowledge about the epidemiology of a disease/infection is essentially necessary to execute a control program successfully. Knowledge about the pathogenesis and pathology of a particular disease is a prerequisite in proper diagnosis of a disease. Considering these points, the present work was planned to study some epidemiology and pathology of gastro-intestinal helminths of ducks in Bangladesh.

Materials and Methods

A total of 206 indigenous ducks were examined during the period between July 2007 and June 2008. The ducks brought for diagnosis in a diagnostic centre or purchased from the households and local markets of Mymensingh district were examined. Before slaughtering, the vent area of the ducks was carefully examined to detect any soiling or other signs of diarrhoea. The slaughtered ducks were subjected to routine post-mortem examination following the procedure as described by Fowler (1990). Different parts of the gastro-intestinal tracts were cut and kept in separate petri dishes. Then the different parts of the gastro-intestinal tracts were opened to collect parasites and to detect gross

pathological lesions produced by them. Collected trematodes, cestodes and acanthocephalan were fixed in alcohol-formol-acetic acid (AFA), stained with Semichon's carmine, dehydrated in graded alcohol, cleared in aniline oil, cleaned in xylene and mounted with Canada balsam. But nematodes were preserved in glycerin alcohol and morphology was studied by preparing temporary slides adding one drop of lacto phenol (Cable, 1957). The parasites were identified according to the keys and description given by Yamaguti (1961) and Soulsby (1982).

The gross pathological lesions were recorded and the affected organs were collected and preserved in 10% buffered neutral formalin. For histopathological study, suspected tissues were processed, embedded in wax, sectioned at six μ thickness and stained with haematoxylin and eosin (Luna, 1968). To study the effects of the season on the prevalence of gastro-intestinal helminths, the year was divided into three seasons such as monsoon (July–October), winter (November–February) and summer (March–June) seasons. The ducks were divided into three age categories such as less than 6 months, 6 months to 1 year and more than 1 year of age. In ducklings, sexes were identified by the digital palpation of penis. The data were analyzed statistically by using chi-square test (Mostafa, 1989). Odds ratio and confidence interval were obtained by the formula according to the Schlesselman (1982).

Results and Discussion

Epidemiological aspects of gastrointestinal helminth infection in ducks

Exactly 167 (81.1%) ducks were found infected by one/more species of gastrointestinal helminths, which conformed to the findings of Ahmed (1969) who recorded 66% prevalence of *H. lanceolata* and *E. revolutum* infection. But the prevalence rate was much lower than that of Islam *et al.* (1988); Farjan *et al.* (2004) and Anisuzzaman *et al.* (2005) who reported 97%, 96.7% and 98.3% helminth infection. This disparity might be due to variations in the method of study, geo-climatic condition and husbandry practices. Farmers are now more conscious about the deleterious effects of parasites. So, most of them deworm the birds regularly.

A total of ten species of helminth parasites were recovered from gastrointestinal tract of ducks, of which four species were trematodes: *Echinostoma revolutum*, *Hypoderaeum conoideum*, *Echinoparyphium recurvatum* and *Notocotylus attenuatus*; two were nematodes, namely, *Amidostomum anseris*, *Capillaria contorta*; two were cestodes, viz, *Hymenolepis coronula* and *Fimbriaria fasciolaris* and two species belonged to acanthocephala, *Arythmorhynchus anser* and *Filicollis anatis*. Among 10 species, single, double and mixed (1-5 parasites) infections were found in 78 (46.7%), 46(27.5%) and 43(25.8%) ducks, respectively.

During the study 67 male and 139 female ducks were examined. Among them 52 male (77.61%) and 115 female (82.7%) ducks were infected. Higher prevalence of helminth infection in female ducks (Farjana *et al.*, 2004) may be due to their laying and eating habit. Due to lack of balance ration their immune status is questionable. Islam *et al.* (1988) reported that the prevalence of *Tetrameres fisispina* was higher in male than female. Betlejewska and Kalisinska (2001) did not find any difference in the prevalence of helminths in two sex groups.

Out of 167 ducks, 25(15.0%); 90(53.9%); and 52(31.1%) ducks found infected in the age < 6 months, 6 months to 1 year and > 1 year, respectively. Higher prevalence of infection and density of helminths in older ducks were observed by Farjana *et al.* (2004). Islam *et al.* (1988) reported that *Echinostoma robustum* was higher in younger ducks (2 to 20 weeks old). Pham *et al.* (2002) recorded that ducks of 2-4 months ages were mostly infected (80.7%) by worms. Prevalence of gastrointestinal helminths in adult ducks may be due to their free ranging system and loose management. Generally ducklings are kept confined to protect them from the predators. As a result they have relatively less chance to be exposed to the source of infections like various terrestrial and aquatic vectors/intermediate hosts of parasites.

The seasonal variation of helminths infection were observed and recorded in different seasons. The highest rate of infection was observed in winter season (91.1%) followed by summer (75.7%) and rainy season (64.9%). Seasonal fluctuation of helminth infection also observed by the earlier scientist. Anisuzzaman *et al.* (2005) observed relatively higher infection rate in rainy season (100%) followed by

summer (98.1%) and winter (98.0%). Junkin *et al.* (2003) reported high prevalence of infection in rainy season but low in fall and winter. The highest rate of infection in winter may be due to pre-patent period and ability of parasites to remain in the host. On the other hand, in winter season ducks are reared in the stagnant water resulting the intermediate hosts like frogs, beetle, earth worms to get chance to infected the hosts.

Pathologic lesions produced by gastro-intestinal helminths

E. revolutum produced haemorrhagic enteritis and parasites were firmly attached with the mucosa (Fig. 1). In histopathological examination, cross section of parasites were seen in the lumen of intestine along with some eosinophilic and lymphocytic infiltrations in the lamina propria of large intestine (Fig. 5). This finding conformed the observations of Forester *et al.* (1994) who observed haemorrhagic enteritis and thickened intestinal mucosa. They also detected extensive destruction and degeneration of the villi caused by the attachment and pressure of the flukes. *E. recurvatum* produces pathologic lesions as thickening of the intestinal wall, which was noticed from the serosal surface. After longitudinal incision, catarrhal inflammation was observed on the mucosal surface with many anchored parasites. Bhowmik *et al.* (1987) observed severe enteritis in turkeys due to *E. recurvatum*. Both the *E. revolutum* and *E. recurvatum* have spiny head collar and scaly cuticle (Soulsby, 1982). They remain firmly attached to the site of attachment and give irritation. *Hypoderma conoideum* produced catarrhal to haemorrhagic spots and in heavy infections it produced haemorrhagic enteritis. Parasites were firmly attached with the mucosa of small intestine. *N. attenuatus* produced catarrhal typhilitis characterized by thickening of the villi and formation of eosinophilic granulomas (Fig. 8). This finding is in the agreements of the observation by Permin and Hensen (1998). Massive infections with *H. coronula* produced inflammatory changes in the small intestine which varied from catarrhal to haemorrhagic enteritis. Microscopically cross-section of scolex of parasite was seen in the mucosa of the intestine (Fig. 7). Permin and Hensen (1998) studied pathogenicity of *H. lanceolata* and found catarrhal enteritis, diarrhoea and death in chickens. Soulsby (1965) observed catarrhal enteritis leading to wasting, emaciation and death in geese. This parasite has rostellum armed with hooks and a large species measuring up to 130 mm (Soulsby, 1982). Possibly they induced inflammatory response by giving irritations. Grossly petechial haemorrhages to ulcerative lesions were produced by *A. anseris*. In most cases, they remained firmly attached under the horny cornified layer of gizzard (Fig. 2). In proventriculus, circular ulcerative and necrotic areas with considerable tissue reactions and degeneration of the glandular tissues were seen (Fig. 3.). Extensive leukocytic infiltrations and congested blood vessels were the common features. Petechial haemorrhages in the gizzard and ulcerative lesions in the proventriculus in *A. anseris* are reported by Anisuzzaman *et al.* (2006); Soulsby (1982) and Lapage (1962) in ducks. These parasites deeply penetrate the horny layer of the gizzard and probably during penetration they cause haemorrhages. On the other hand, *A. anser* was found in between the horny and muscular layer of the gizzard. They causing thickening of the horny layer of the gizzard. In some cases, pin pointed raised dark haemorrhagic lesions were seen. The parasites were embedded into the mucosal layers of gizzard (Fig. 6) as observed by longitudinal sections. Anisuzzaman *et al.* (2005) first reported this acanthocephalan parasite from the gizzards of indigenous ducks in Bangladesh. However, its pathogenicity and pathology were not mentioned in earlier reports. This parasite possesses thorny proboscis (Yamaguti, 1961), as they remain in between the horny and muscular layer of the gizzard that produces continuous irritation causing thickening of this layer.

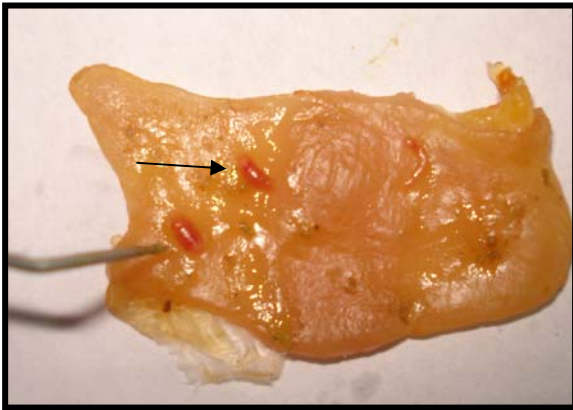


Fig. 1. *E. revolutum* firmly attached to the mucosa of the large intestine

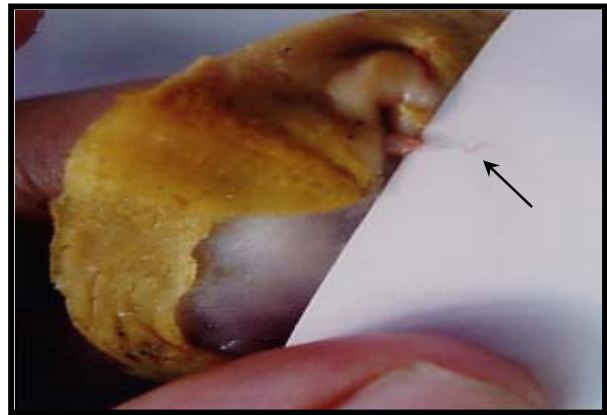


Fig. 2. *A. anseris* firmly attached under the horny cornified layer of gizzard

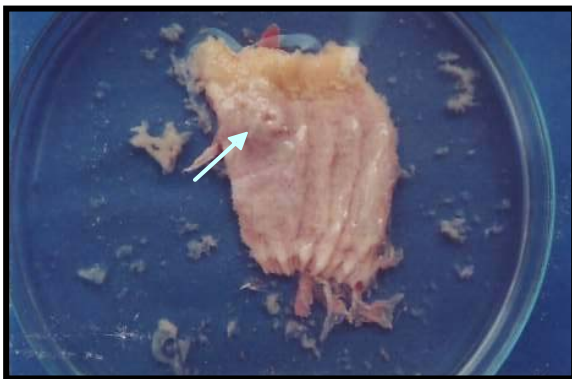


Fig. 3. Circular ulcerative and necrotic areas in the proventriculus in *A. anseris* infection

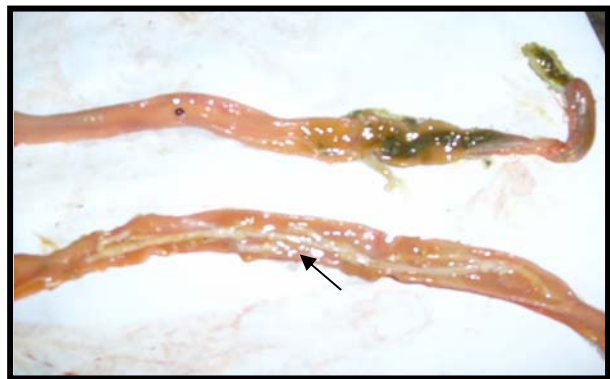


Fig. 4. Catarrhal enteritis in the lumen of intestine and is filled with *H. coronula*

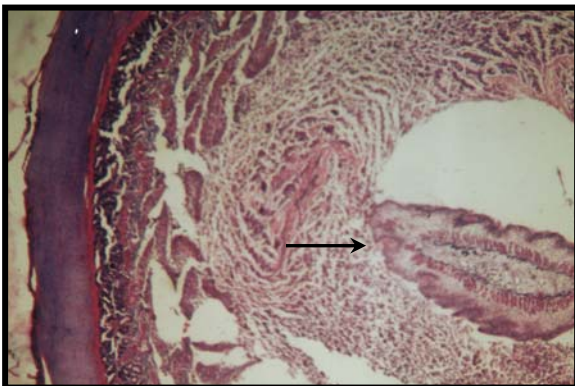


Fig. 5. Cross section of parasite in the lumen of large intestine in *E. revolutum* infection

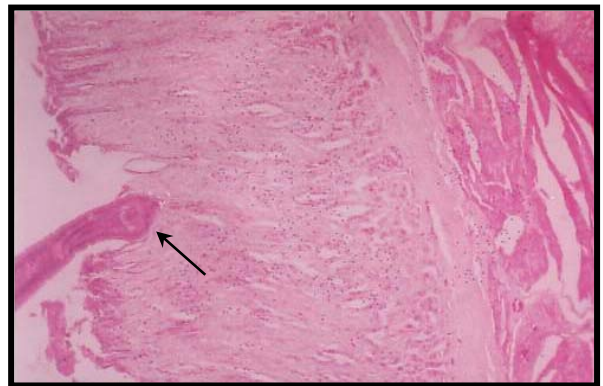


Fig. 6. *A. anseris* is embedded into the mucosal layer of the gizzard

Table 1. Prevalence (age-wise) of single and mixed infections of gastro-intestinal helminths in ducks

| S/N | Class/ phylum | Prevalence of single and mixed infection | No of ducks < 6 months of age (%) | No of ducks 6 months to 1 year of age (%) | No of ducks > 1 of age (%) | Total | Overall incidence (%) |
|-----------|------------------|---|-----------------------------------|---|----------------------------|-------|-----------------------|
| 1 | Trematoda | <i>Echinostoma revolutum</i> (Froelich 1802) Loss 1899 | 3(1.8) | 8(4.8) | 4(2.4) | 15 | 8.9 |
| 2 | | <i>Hypoderaeum conoideum</i> (Blocch 1782) Dietz 1909 | 1(0.6) | 2(1.2) | 0.0 | 3 | 1.8 |
| 3 | | <i>Echinoparyphium recurvatum</i> Listow, 1873 | 0.0 | 3(1.8) | 0.0 | 3 | 1.8 |
| 4 | | <i>Notocotylus attenuatus</i> (Rus 1809) Szidat 1933 | 0.0 | 2(1.2) | 1(0.6) | 3 | 1.8 |
| 5 | Nematoda | <i>Amidostomum anseris</i> | 0.0 | 4(2.4) | 3(1.8) | 7 | 4.2 |
| 6 | | <i>Capillaria contorta</i> | 0.0 | 2(1.2) | 1(0.6) | 3 | 1.8 |
| 7 | Cestoda | <i>Hymenolepis coronula</i> (Duj, 1845) Railliet 1892 | 6(3.6) | 13(7.8) | 10(6.0) | 29 | 17.4 |
| 8 | | <i>Fimbriaria fasciolaris</i> Pallas 1781 | 3(1.8) | 1(0.6) | 0.0 | 4 | 2.4 |
| 9 | Acanthocephala | <i>Arythmorhynchus anser</i> Flurescu 1941 | 2(1.2) | 3(1.8) | 2(1.2) | 7 | 5.2 |
| 10 | | <i>Filicollis anatis</i> (Shrank 1788) Petrotschenko 1956 | 0.00 | 2(1.2) | 2(1.2) | 4 | 2.4 |
| Sub total | | | 15(9.0) | 40(24.0) | 23(13.8) | 78 | 46.7 |
| 11 | Double infection | <i>Echinostoma revolutum</i> with <i>Hymenolepis coronula</i> | 1(0.6) | 3(1.8) | 2(1.2) | 6 | 3.6 |
| 12 | | <i>Echinostoma revolutum</i> with <i>Fimbriaria fasciolaris</i> | 2(1.2) | 1(0.6) | 0.0 | 3 | 1.8 |
| 13 | | <i>Echinostoma revolutum</i> with <i>Arythmorhynchus anser</i> | 1(0.6) | 1(0.6) | 1(0.6) | 3 | 1.8 |
| 14 | | <i>Echinoparyphium recurvatum</i> with <i>Hymenolepis coronula</i> | 0.0 | 3(1.8) | 0.0 | 3 | 1.8 |
| 15 | | <i>Amidostomum anseri</i> with <i>Hymenolepis coronula</i> | 3(1.8) | 2(1.2) | 2(1.2) | 7 | 4.2 |
| 16 | | <i>Amidostomum anseri</i> with <i>Fimbriaria fasciolaris</i> | 0.0 | 0.0 | 1(0.6) | 1 | 0.6 |
| 17 | | <i>Amidostomum anseri</i> with <i>Arythmorhynchus anser</i> | 1(0.6) | 2(1.2) | 3(1.8) | 6 | 3.6 |
| 18 | | <i>Hymenolepis coronula</i> with <i>Fimbriaria fasciolaris</i> | 0.0 | 6(3.6) | 3(1.8) | 9 | 5.4 |
| 19 | | <i>Hymenolepis coronula</i> with <i>Arythmorhynchus anser</i> | 0.0 | 7(4.2) | 0.0 | 7 | 4.2 |
| 20 | | <i>Hymenolepis coronula</i> with <i>Filicollis anatis</i> | 0.0 | 0.0 | 1(0.6) | 1 | 0.6 |
| Sub total | | | 8(4.8) | 25(15.0) | 13(7.8) | 46 | 27.5 |
| 21 | Mixed infection | <i>Echinostoma revolutum</i> , <i>Hypoderaeum conoideum</i> and <i>Amidostomum anseri</i> | 0.00 | 2(1.20) | 1(0.6) | 3 | 1.8 |
| 22 | | <i>Echinostoma revolutum</i> , <i>Hypoderaeum conoideum</i> and <i>Capillaria contorta</i> | 0.0 | 3(1.8) | 0.0 | 2 | 1.2 |
| 23 | | <i>Echinostoma revolutum</i> , <i>Echinoparyphium recurvatum</i> and <i>Capillaria contorta</i> | 0.0 | 1(0.6) | 1(0.6) | 4 | 2.4 |
| 24 | | <i>Echinostoma revolutum</i> , <i>Notocotylus attenuatus</i> and <i>Amidostomum anseri</i> | 0.0 | 1(0.6) | 3(1.8) | 4 | 2.4 |
| 25 | | <i>Echinostoma revolutum</i> , <i>Notocotylus attenuatus</i> and <i>Hymenolepis coronula</i> | 0.0 | 1(0.6) | 1(0.6) | 2 | 1.2 |
| 26 | | <i>Echinostoma revolutum</i> , <i>Amidostomum anseri</i> and <i>Capillaria contorta</i> | 0.0 | 5(3.0) | 3(1.8) | 8 | 4.8 |
| 27 | | <i>Echinostoma revolutum</i> , <i>Amidostomum anseri</i> and <i>Hymenolepis coronula</i> | 0.0 | 2(1.20) | 1 | 3 | 1.8 |
| 28 | | <i>Echinostoma revolutum</i> , <i>Amidostomum anseri</i> and <i>Arythmorhynchus anser</i> | 1(0.6) | 1(0.6) | 2(1.2) | 4 | 2.4 |
| 29 | | <i>Amidostomum anseri</i> , <i>Capillaria contorta</i> and <i>Hymenolepis coronula</i> | 0.0 | 2(1.2) | 0.00 | 2 | 1.2 |
| 30 | | <i>Amidostomum anseri</i> , <i>Hymenolepis coronula</i> and <i>Arythmorhynchus anser</i> | 0.0 | 1(0.6) | 1(0.6) | 2 | 1.2 |
| 31 | | <i>Capillaria contorta</i> , <i>Hymenolepis coronula</i> and <i>Arythmorhynchus anser</i> | 0.0 | 2(1.2) | 0.0 | 2 | 1.2 |
| 32 | | <i>Echinostoma revolutum</i> , <i>Amidostomum anseri</i> , <i>Fimbriaria fasciolaris</i> and <i>Arythmorhynchus anser</i> | 1(0.6) | 2(1.2) | 0.0 | 3 | 1.8 |
| 33 | | <i>Notocotylus attenuatus</i> , <i>Amidostomum anseri</i> , <i>Hymenolepis coronula</i> and <i>Arythmorhynchus anser</i> | 0.0 | 0.0 | 1(0.6) | 1 | 0.6 |
| 34 | | <i>Echinostoma revolutum</i> , <i>Hypoderaeum conoideum</i> , <i>Amidostomum anseri</i> , <i>Hymenolepis coronula</i> and <i>Arythmorhynchus anser</i> | 0.0 | 1(0.6) | 0.0 | 1 | 0.6 |
| 35 | | <i>Echinostoma revolutum</i> , <i>Echinoparyphium recurvatum</i> , <i>Notocotylus attenuatus</i> , <i>Capillaria contorta</i> and <i>Hymenolepis coronula</i> | 0.0 | 0.0 | 2(1.2) | 2 | 1.2 |
| Sub total | | | 2(1.2) | 25(15.0) | 16(9.6) | 43 | 25.8 |
| Total | | | 25(15.0) | 90(53.9) | 52(31.1) | 167 | 10 |

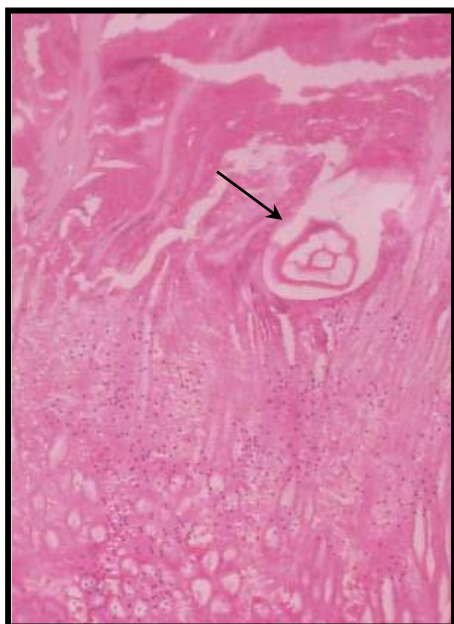


Fig . 7. Cross section of scolex of parasite in the mucosa of the intestine

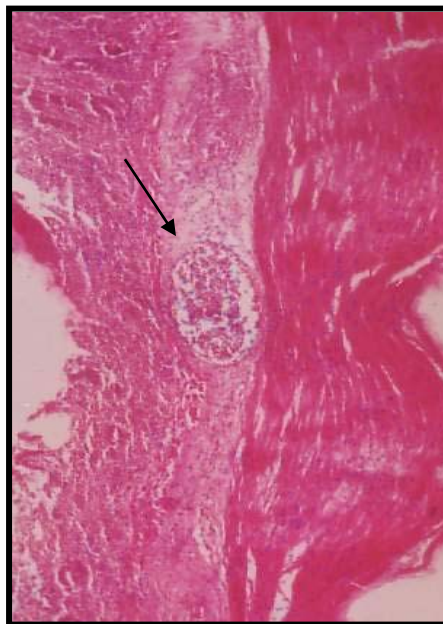


Fig . 8. Eosinophilic granuloma in the submucosa of caecum due to *N. attenuatus* infection

Table 2. Prevalence of gastro-intestinal helminths in ducks in different ages, sexes, breeds and seasons

| Determinant | Parameters | Ducks examined (N=206) | Ducks infected (%) (N=167) | Incidence (%) | Chi-square value | Probabilities associated with value |
|-------------|-----------------------|------------------------|----------------------------|---------------|------------------|-------------------------------------|
| Sex | Male | 67 | 52 | 77.6 | 0.7727 | 0.3794 ^{NS} |
| | Female | 139 | 115 | 82.7 | | |
| Age | Up to 6 months | 30 | 25 | 15.0 | 0.3642 | 0.8335 ^{NS} |
| | 6 months up to 1 year | 110 | 90 | 54.0 | | |
| | Above 1 year | 66 | 52 | 31.1 | | |
| Season | Rainy (July- Oct.) | 57 | 37 | 64.9 | 17.6969 | 0.0001 [*] |
| | Winter (Nov.-Feb.) | 112 | 102 | 91.1 | | |
| | Summer (March-June) | 37 | 28 | 75.7 | | |

N= Total ducks examined

Conclusion

It is suggested that ducks commonly reared in Bangladesh (Indigenous, Khaki Campbell, Jindin) are susceptible to gastrointestinal helminth infection irrespective to age and sex of ducks and seasons of the year. Pathological change due to *Hypoderma conoideum* infections are described, which are not reported before. Mass deworming is essential routinely at definite interval with safety spectrum of anthelmintic.

Acknowledgements

This work was funded by Bangladesh Agricultural University Research System (BAURES). So the authors are grateful to BAURES and that are greatly acknowledged.

References

- Ahmed, S. 1969. Survey on the types of helminths commonly found in the country ducks. *Pakistan J. Vet. Sci.*, 3: 110-112.
- Anisuzzaman; Alim, M.A.; Rahman, M.H. and Mondal, M.M.H. 2005. Helminth parasites in indigenous ducks: Seasonal dynamics and effects on production performance, *J. of the Bangladesh Agricultural University*, 3 (2): 283-290.
- Anisuzzaman; Farjana, T.; Alim, M.A.; Khan, M.A.H.N.A.; Mondal, M.M.H. 2006. Amidostomiasis in indigenous Ducks of Bangladesh: Prevalence and pathology. *Bangladesh Vet. J.* 40 (4): 1-9.
- Baki, M.A., Dewan, M.L. and Mondal, M.M.H. 1993. An investigation on the causes of mortality of ducks in Bangladesh. *Progress. Agric.* 4: 27-33.
- Betlejewska, K. M. and Kalisinska, E. 2001. Preliminary survey of echinuriasis of mallard (*Anas platyrhynchos*) from North-western Poland, *Folia Universitatis Agriculturae Stetinensis, Zootchnica*, 41: 5-10.
- Bhowmik, M.K. and Roy, M.M. 1987. Enteric diseases in ducks (*Anas platyrhynchos domesticus*). *Indian Vet. Med. J.* 11: 209-214.
- Cable R.M. 1957. *An Illustrated Laboratory Manual of Parasitology*, Burgess Publishing Co., 426, South Sixth Street, Minneapolis 15, Minnesota, pp 105-131.
- Das, P.M. and Anisuzzaman. 2008. Pathological and Parasitological investigation of an emerging tracheal fluke infection in ducks. *Bangladesh Agricultural University research progress*. Vol. 18 pp. 5.
- FAO, (Food and Agricultural Organization of the United Nations). 1990. *The State of World Fisheries and Aquaculture (SOFIA)*, seventeenth session FAO, Rome.
- Farjana, T., Alim, M.A., Das, P.M. and Mondal, M.M.H. 2004 Helminth infection in ducks at free-range and semi intensive farming in two districts of Bangladesh, *Bangladesh Vet. J.* 38:125-134.
- Forester, D.J., Kinsella, J.M., Mertins, J.W., Price, R.D. and Turnbull, R.E. 1994. Parasitic helminthes and arthropods of fulvous whistling-ducks in Southern Florida. *J. Helminthol. Soci. Washinton*, 61(1): 84-88.
- Fowler, N.G. 1990. How to carry out a field investigation, In: *Poultry diseases*, FTW (ed) Bailliere Tindall, London, pp370-400.
- Islam, M.R., Shaikh, H. and Baki, M.A. 1988. Prevalence and pathology of helminth parasites in domestic ducks of Bangladesh. *Vet. Parasitol.*, 29: 73-77.
- Luna, L.G. 1968. *Manual of Histologic Staining Methods of the Armed Forces Institute of Pathology*, 3rd edition. McGraw Hill Book Co. New York.
- Mostafa, M.G. 1989. *Methods of statistics*. Fourth edn. Karim Press and Publications, Dhaka, pp. 296-298.
- Permin, A. and Hasen, J.W. 1998. *Epidemiology, diagnosis and control of poultry parasites*, Food and agricultural organization of the United Nations, Rome, pp15-46.
- Schlesselman, J.J. 1982. *Case Control Studies*. Oxford University Press, Oxford. pp. 354.
- Soulsby, E.J.L. 1965. *Textbook of Veterinary Clinical Parasitology*, Vol. I. Helminths. Blackwell Scientific Publications, Oxford.
- Soulsby, E.J.L. 1982. *Textbook of Veterinary Clinical Parasitology*, Vol. I. Helminths. Blackwell Scientific Publications, Oxford.
- Yamaguti, S. 1961. *Systema Helminthum*. Vol. I, Part I, Interscience Publishers, Inc. New York, pp 782-785.