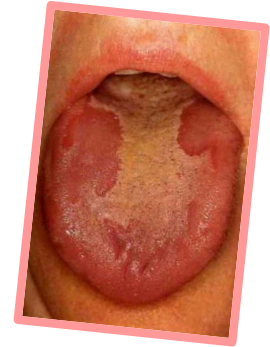
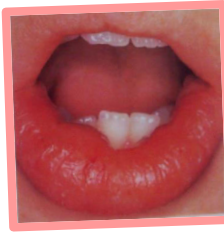
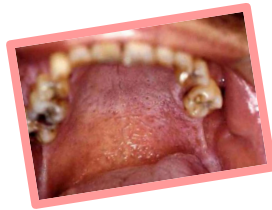# ***ORAL MEDICINE***



## **Definition:**

Oral medicine is that part of dentistry which is concerned with the diagnosis and nonsurgical management of diseases affecting the oral and maxillofacial region and with the oral health care of medically compromised patients.

or

oral medicine is defined as "the dental specialty placed at the interface between medicine and dentistry and is concerned with the diagnosis and management of (non-dental) pathology affecting the oral and maxillofacial region.

Is that part of dentistry which is involved in the diagnosis and treatment of the oral diseases of a non-surgical in nature which may be localized to the mouth or which may be an oral manifestation of systemic diseases.

OR

It is an art and science of recognition and treatment of various oral lesions.

## **Oral diagnosis:**

Definition: It is a systematic method of recognition and treatment of various oral lesions.

### Diagnostic process or Sequence:

1. Taking and recording patient history.
2. Examining the patient and performing laboratory studies.
3. Establishing a diagnosis by evaluation of the history and physical examination and laboratory studies.
4. Formulating a treatment plan of action (including dental treatment modifications and necessary medical referrals).

# 1 Taking and recording patient history:

## Components:

1. Routine data
2. Chief complaint
3. History of present illness
4. Past and present medical history
5. Past dental history
6. Family history.
7. Social history.

1. Identification of systemic disease that could require modification of dental treatment
2. Identification of systemic disease that could be treated by dental services
3. Identification of systemic disease that could be treated by dental services
4. Establishment of a relationship with the physician.
5. Facilitation of the patient's care by the physician.
6. Provision of information to the physician.
- Medical history composed of:
1. Serious Illnesses.
  2. Hospitalizations.
  3. Transfusions.
  4. Allergies.
  5. Medications.
  6. Childhood disease.
  7. Pregnancy.
  8. Review of systems

## Taking and recording patient history:

### A- Routine data or identification data

which include The Patient's Name, Telephone Number, Sex, Address, Age And Race

#### The age of the patient

is important in the following major problem including chronic and recurrent condition from the earlier adult stages

#### Sex.

Malignant melanoma the incidence is increasing in male

Mucous membrane pemphigoid, cicatricial pemphigoid more in female

Epulis and pregnancy epulis occur in female because of the circulating estrogen are highest

S.C.C more in males

mucocele more in female

### B- Chief complaints

recorded by the patient's own words. It is usually the reason for the patient visits. The CC is subjective in nature and is related to an uncomfortable abnormal sensation. The most successful treatment is achieved if the CC is managed and corrected properly.

#### History of presenting complaint (HPC)

The dentist should gain as much information about the specific complaint.

#### C- History of present illness

Is a chronologic account of the CC and associated symptom from the time of onset to the time of history's taken (onset, course, duration, severity, promoting factors and relieving factors).

### D-Past and present medical history

### E- Past dental history ;

It is important to know what had been done in the outcome of previous treatment. Restoration, prosthodontics, orthodontics, endodontic periodontics and complication of anesthesia. Also, any difficulties with dental care and recent dental radiography.

### Family history (FH)

A family health history

(also referred to as a family medical history or medical family tree)

Should include

\* The health of the patient's parents and siblings.

\*The cause of the death of relative may be an important clue to the presence of an inherited disorder.

\*The record of an illness with hereditary familial tendency such as (hypertension , hemophilia, diabetes, allergies, some form of cancer, migraine and psychiatric neurogenic disorder).

\*Should be used to discover communicable diseases that may infect members of that household (TB, hepatitis).

Social history (SH) This is the opportunity to find out a bit more about the patient's background.

Which include?

Marital state, number of children, habits. \*

Education and job- information [occupation]. \*

Drinking of alcohol, smoking and drug taken as caffeine and heroin. \*

Smoking:- There are lesions related to the smoking like leukoplakia ,nicotinic stomatitis

Alcohol History:- The elevated of mean corpuscular volume (MCV) in the absence of vitamin B 12 or folate deficiency or unexplained abnormal liver function test

### Examination Of The Patient

Outlines for clinical examination

1-Principles

2-General

3-Oral

A number of examination techniques are helpful in evaluating a patient, an organ and a tissue.

The basic examination techniques are

1. Visual inspection:

2. Palpation

3. Probing

4. Percussion

5. Auscultation

6. Aspiration

7. Diascopy

8. Evaluation of function

# Visual Inspection

It is a systemic observation of the patient •

# Palpation

it is a procedure wherein the examiner feels or presses upon the structures being examined •

Palpation give information about; •

**Texture;** is best determined through light palpation with finger tips. The texture of surface or mass may be (smooth, rough or pebbly {lobulated} ). •

**Dimension;** cannot always be assessed by the eye alone, some nodules may have very little dimension in terms of depth. •

**Consistency;** it is described usually in term of compressibility, so the mass may describe as (soft, rubbery or indurated {hard}). •

**Temperature;** Are best evaluated by using the dorsal or extensor surface of the finger since the skin here is thin and well innervated. E.g. inflamed area or soft tissue overlying vascular lesion may be warmer owing to increased blood flow to the area. •

**Functional event;** any movement that can be detected with palpating hand. •  
E.g. the pulsatility or thrill of a vascular lesion and movement of the tooth in its socket. •

**Types of palpation :** •

**1-Bidigital palpation;** •

Consistency may be evaluated by pressing the structure with examiner thumb and index figure. •

**2-Bimanual palpation;** •

Manipulation of structure with the fingers of one hand and thump of other hand. •



## Probing

it is palpation with an instrument •

## Percussion

it is the technique of striking the tissues •  
with the fingers or an instrument.

The examiner listens to the resulting sound •  
and observes the response of the patient.

# Auscultation

It is the act of listening for sounds within the body.

The stethoscope is a useful aid to auscultation.

The examiner may listen for sound such as wheezing, popping of the T.M.J or clicking. The flat diaphragm is used to detect high frequency sound, whereas the bell collects low-pitched sounds.

# Aspiration

Is withdrawal of fluids from a body cavity? The area being aspirated may be limited to soft tissue or may be central in bone.

The aspiration is the material that is withdrawn; when nothing can be withdrawn the needle tip should remove to adjacent area.

**In solid lesion such as neoplasm with minimal vascular content, nothing may be aspirated.**

**Traumatic bony cyst has no aspirate or only small blood –tinted fluid.**

**Aspiration of pus indicates an inflammatory process.**

**If several milliners of blood are aspirated easily indicate a vascular lesion such as hemangioma.**

**Straw colored or blood tinted fluid may indicate a cyst.**

The aspiration may be used for culture and sensitivity test to identify the pathogen and its best treatment.

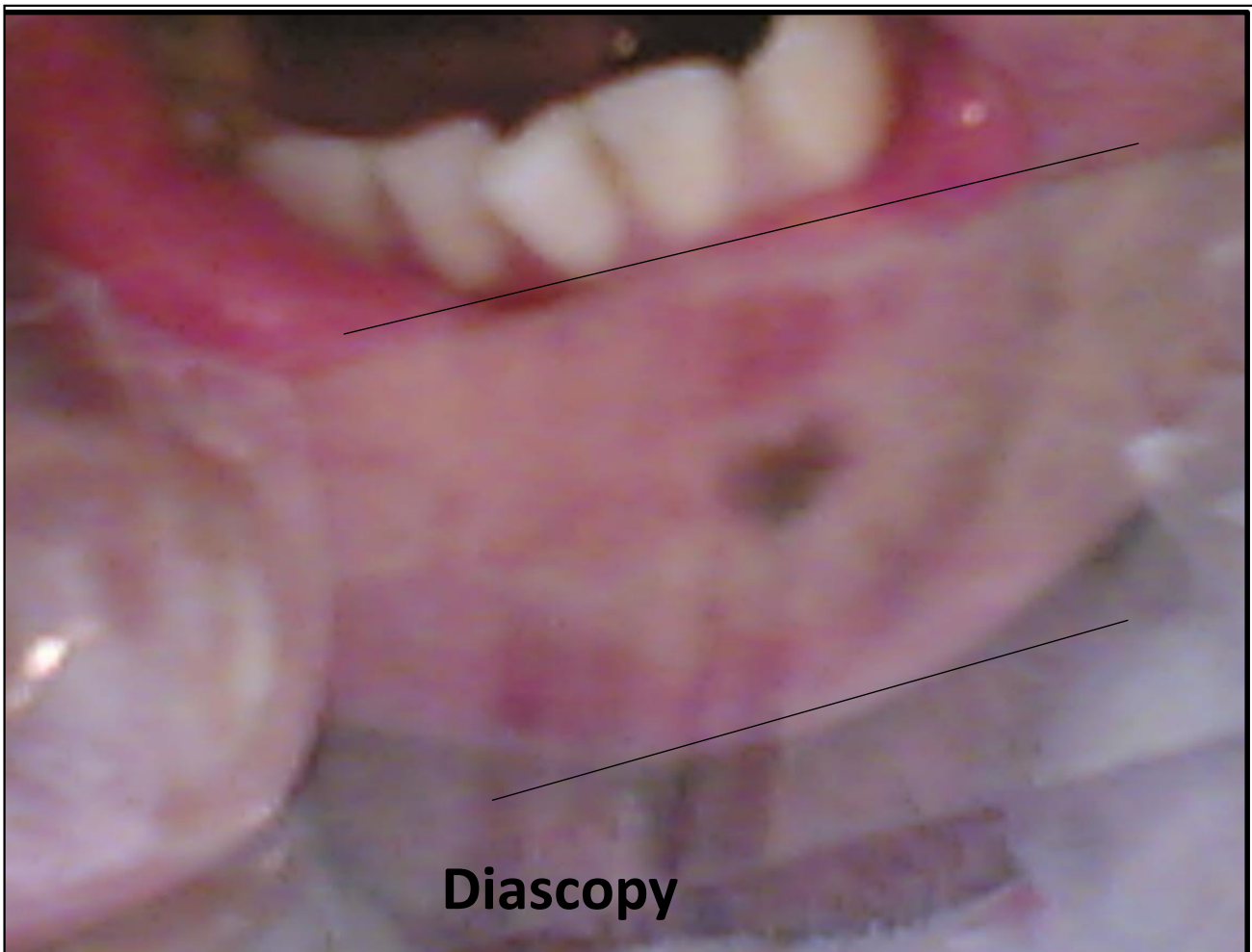
# Diascopy

it is a specific examination technique whereby the tissue being examined is compressed by a glass slide.

The primary objective of the test is to determine whether a reddish or bluish-purple lesion is vascular in nature or due other cause .

Vascular lesion such as varies, telangiectasia and hemangioma are blanched upon diascopy .

If the area dose not blanched it may be due to other causes such as (amalgam tattoo, ink tattoo, nevi, localized pigmentation and extravasated blood {petechial, ecchymosis and hematoma})



### 3. Evaluation of function :

There are several functions that need to be assessed in examination of the head and neck.

**\*Tear production and tear drainage, by Schirmer tear test.**

**\*The function of the salivary glands can be assessed by palpating or milking the glands.**

**\*Taste; the tongue is the organ of the taste and its function can be assessed with the use of saturated salt solution, quinine and fructose or other sugars.**

**\*Mastication; can be evaluated by masticatory symptoms like (*limited jaw opening, inability to move the jaw, pain, difficulty with swallowing and pain with chewing*).**

**\*Neurologic function; A number of conditions involve the head and neck such as bell's palsy, adenoid cystic carcinoma of the parotid gland and tumor of the jaw, these conditions may produce neurologic symptoms such as paresthesia or paralysis .**

## General examination

The objective of general appraisal is to obtain a general idea of the patient's physical status. The examiner should note

\*The patient gait

\*The patient stature      \*Nutritional status      \*Posture      \* Facial form      \*Vital signs

**Vital Signs:**

### **1 RESPIRATORY RATE**

Normal 14–16 breaths/min  
Tachypnea < 20 breaths/min

### **2. TEMPERATURE**

Oral 37.0 C  
Axillary 36.3 C  
Rectal 37.7 C

### **3. PULSE RATE AND RHYTHM**

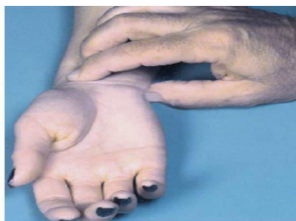Brady cardia < 60 beats/minute  
Normal 60-100 beats/minute  
Tachycardia < 100 beats/minute

### **4. BLOOD PRESSURE**

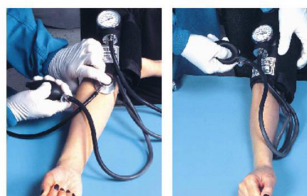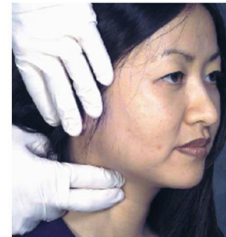*Is taken by using a sphygmomanometer and a stethoscope.*

*It is generally accepted that a patient is considered hypertensive when the systolic /diastolic blood pressure exceed a measurement of 150/90.*

**Radial pulse**



**Carotid pulse**



## Examination of the head

This examination includes an evaluation of all structures associated with the head. The following areas are included in the examination

*face,*

*hair,*

*skin,*

*eye,*

*ear,*

*pre & post auricular lymph node,*

*nasal & para nasal sinus,*

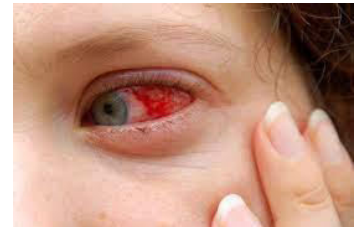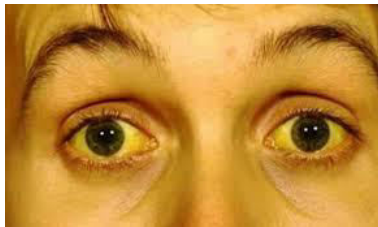*TMJ*

*and parotid gland.*

\*The face form; the examiner should note the position of the eye, nose, mouth and ear as well as their size and symmetry.

\*The skin is examined by observation and palpation in order to know the color, texture, elasticity, presence or absence of edema.

## Examination of the head



## **Eyes examination**

The eye is composed of different types of tissues, this unique feature makes the eye susceptible to a wide variety of diseases and provides insights into many systemic problems. Almost any part of the eye can give important clues to the diagnosis of systemic diseases which may be evident on a routine eye examination.

**Redness** ☐ Allergy

**Yellowish** ☐ Jaundice

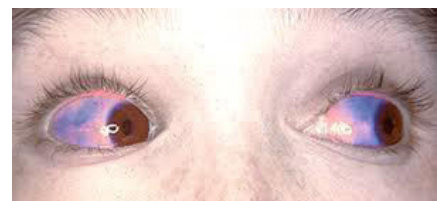**Bluish** ☐ Osteogenic Imperfecta

**Eyelids** Conjectival lesion

**C. Ear**

**D. Post and pre auricular lymphnode**

**E. Skin of the face**



## The common terminology which are used in the oral medicine for skin examination

**Macule**: A macule is a change in surface color, without elevation or depression and, therefore, nonpalpable, well or ill-defined, variously sized, but generally considered less than either 5 or 10 mm in diameter at the widest point.

**Patch**: A patch is a large macule equal to or greater than either 5 or 10 mm across, depending on one's definition of a macule. Patches may have some subtle surface change, such as a fine scale or wrinkling, but although the consistency of the surface is changed, the lesion itself is not palpable.

**Papule**: A papule is a circumscribed, solid elevation of skin with no visible fluid, varying in size from a pinhead to less than either 5 or 10 mm in diameter at the widest point.

**Plaque**: A plaque has been described as a broad papule, or confluence of papules equal to or greater than 1 cm or alternatively as an elevated, plateaulike lesion that is greater in its diameter than in its depth.

**Nodule**: A nodule is morphologically similar to a papule in that it is also a palpable spherical lesion less than 1 cm in diameter. However, it is differentiated by being centered deeper in the dermis or subcutis.

**Tumour**: Similar to a nodule but larger than 1 cm in diameter.

**Vesicle**: A vesicle is small blister, a circumscribed, fluid-containing, epidermal elevation generally considered less than either 5 or 10 mm in diameter at the widest point. The fluid is clear serous fluid.

**Bulla**: A bulla is a large blister, a rounded or irregularly shaped blister containing serous or seropurulent fluid, equal to or greater than either 5 or 10 mm, depending on one's definition of a vesicle.

**Pustule**: A pustule is a small elevation of the skin containing cloudy or purulent material (pus) usually consisting of necrotic inflammatory cells. These can be either white or red.

**Cyst**: A cyst is an epithelial-lined cavity containing liquid, semi-solid, or solid material.

**Erosion**: An erosion is a discontinuity of the skin exhibiting incomplete loss of the epidermis, a lesion that is moist, circumscribed, and usually depressed.

**Ulcer**: An ulcer is a discontinuity of the skin exhibiting complete loss of the epidermis and often portions of the dermis and even subcutaneous fat.

**Wheal**: A wheal is a rounded or flat-topped, pale red papule or plaque that is characteristically evanescent, disappearing within 24 to 48 hours. The temporary raised bubble of taut skin on the site of a properly-delivered intradermal injection is also called a welt, with the ID injection process itself frequently referred to as simply "raising a wheal" in medical texts.

**Telangiectasia**: A telangiectasia represents an enlargement of superficial blood vessels to the point of being visible.

### Abnormal Color of The Skin

# Examination of the neck

The structures in the neck to be evaluated are

- \*The muscles (*sternocleidomastoid, trapezius muscle*).
- \*Submandibular and sublingual salivary gland.
- \*Lymph node.
- \*Thyroid gland.
- \*Trachea and carotid artery.

## The lymph node examination

### Consistency

**Soft**----(insignificant),

**Rubbery** -----(classically lymphoma),

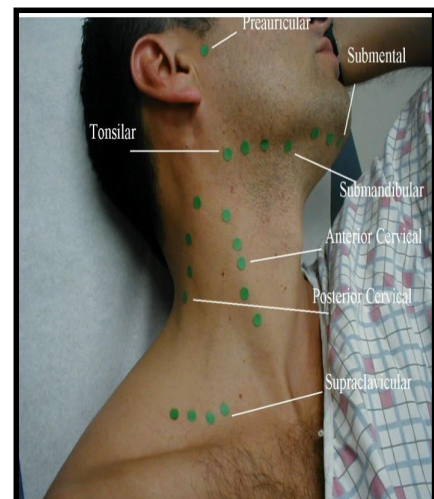
**Hard** -----(classically malignancy & granulomatous infection).

**Tender**---- (classically infection) vs. **Non-tender** (classically malignancy)

### Lymph node exam technique

Always evaluate for symmetry: clinically significant nodes classically

Asymmetric.



## **Physical Examination of The Thyroid Gland**

Accurate physical examination of the thyroid gland and the neck can easily make a correct pathological diagnosis in the majority of cases.

Physical examination, however, to be useful in the evaluation of thyroid diseases, It must be accurate in determining the size of the thyroid gland, whether it is enlarged or not. It must be accurate in detecting nodules in the thyroid gland whether solitary or multiple. It must be accurate in determining the consistency of an enlarged thyroid gland as well as the consistency of the nodules, whether cystic, soft, firm, or hard. Lastly, it must be accurate in determining the presence of enlarged cervical lymph nodes, their size, and their consistency. Together with the other physical findings outside the neck area, like tachycardia and exophthalmos, and together with the history, one can readily make an accurate assessment of the patient's apparent thyroid complaint as to:

- 1) whether the patient has no enlarged thyroid gland,
- 2) whether the patient is hyperthyroid,
- 3) whether the patient has a benign or malignant thyroid condition.

The thyroid scan, the serum T4 and T3 determination, and the ultrasound improve the diagnosis of thyroid gland disease.

## **THE ORAL CLINICAL EXAMINATION**

The complete examination of the mouth include evaluation of

\*The soft tissues such as

lip,  
buccal mucosa,  
palate,  
oropharynx  
floor of the mouth  
and tongue.

\*Periodontium.

\*Teeth.

\*Occlusion.

\*Edentulous and partially edentulous mouth .



## Laboratories Study (Investigations)

A wide variety of investigations are available. The most frequently utilized in oral medicine are.

1. Radiographic examination.
2. Supplementary diagnostic aids.

### **Radiographic examination:**

The interpretative of radiograph requires knowledge of radiographic appearance of normal anatomy and of pathologic conditions as well as ability to correlate this appearance with clinical findings.

There are different types of radiographic examination

1-Intraoral (periapical, occlusal)

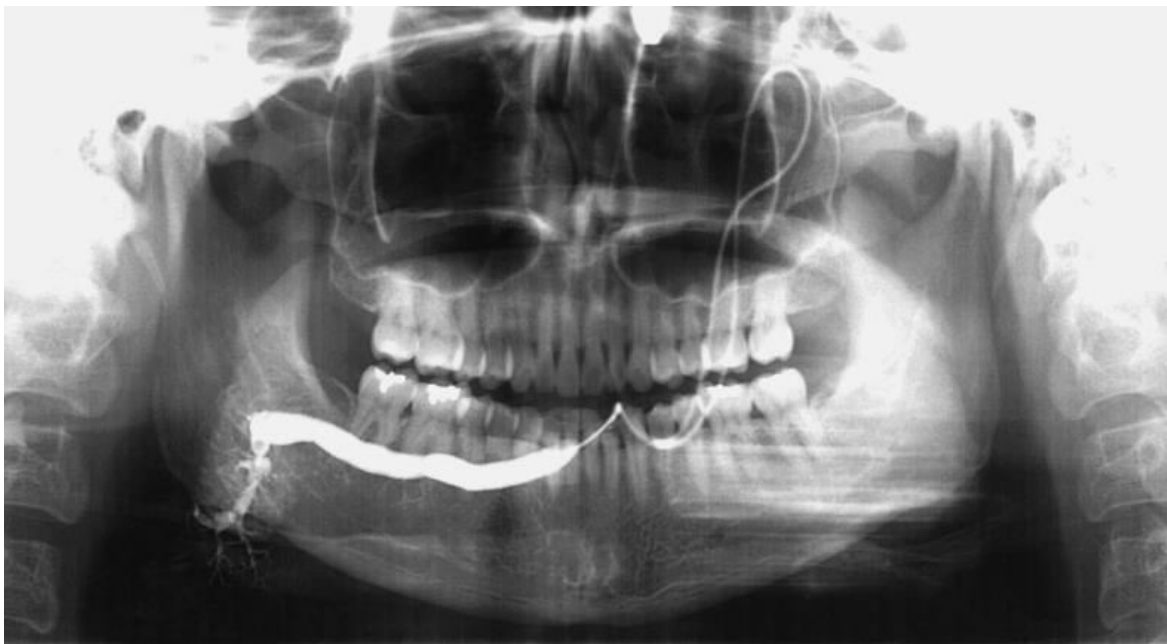2-Extraoral

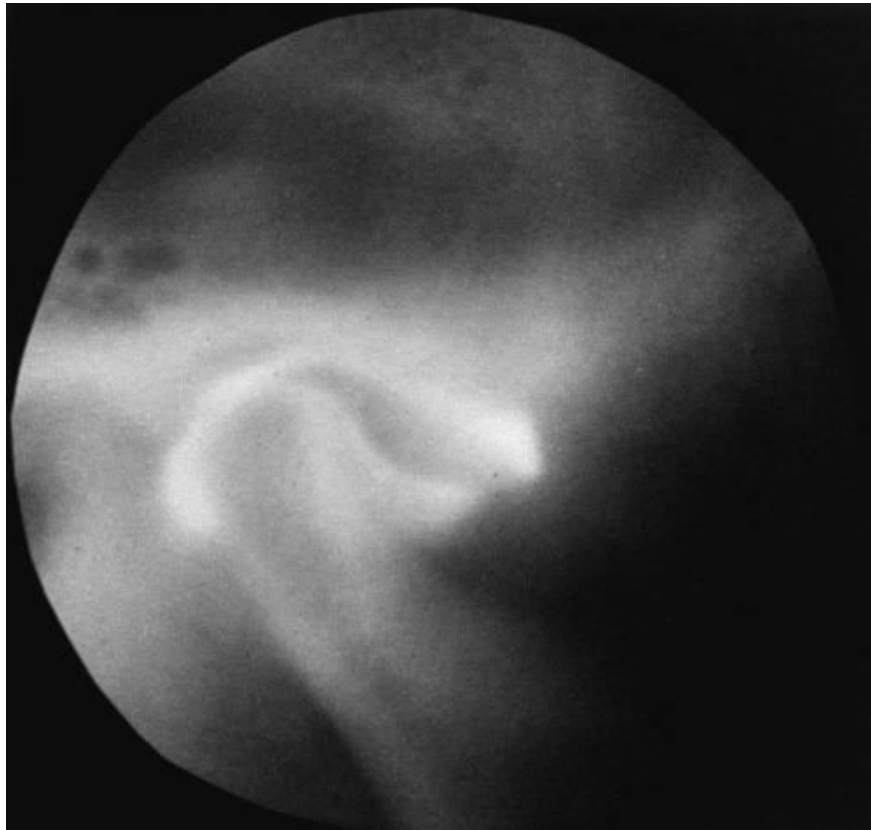
- \*Trans- cranial& Trans pharyngeal to see the head and neck of the condyle.
- \*Lateral oblique view to see the ramus and body of mandible
- \*Cephalometric projection
- \*Anterio-posterior projection for mandible
- \*Water view or sinus view

### **Computed tomography**

in CT the dense bone is white , soft tissue is present mid gray ,fat is dark gray and air is black and the dental filling may cause artifact  
**CBCT.**

**Magnetic resonance imaging (MRI) :** for the soft tissue, salivary gland and TMJ





## Benign lesions of the oral cavity and the jaws

### Variants Of Normal

Structural variations of the oral cavity and the jaws are sometimes mistakenly identified as pathologic, but they are usually easily recognized as being within the range of normal findings, and biopsy is rarely indicated.

One cannot appreciate the abnormal before understanding the range of normal.

### Examples of such structural variants are

- Tori,
- Enlarged Papillae Associated With The Opening Of Stensen's Duct,
- Fordyce Spots,
- Sublingual Varicosities In Older Individuals

### Tori and exostoses :

are considered to be normal structural variants.

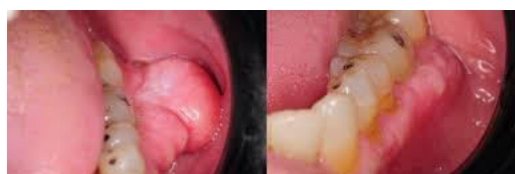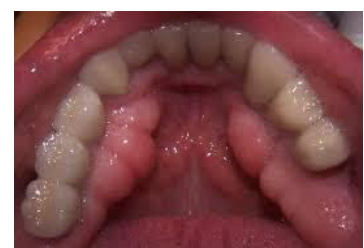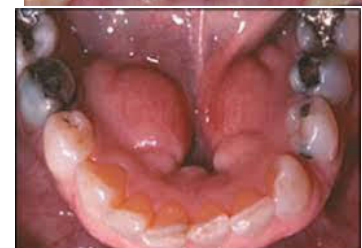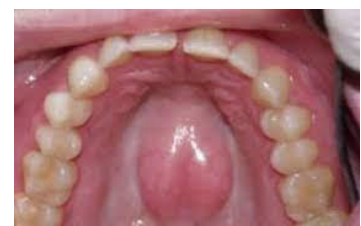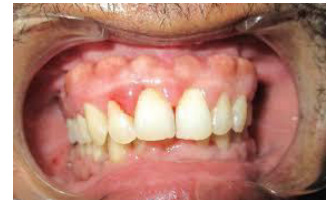There is no strong evidence to either support or bruxism or other parafunctional habits as causes.

- Exostoses manifest as Localized Nodular Enlargements of the
  - Cortical Bone Of The Midline Of The Palate (Torus Palatinus),
  - The Lingual Aspect Of The Mandible (Torus Mandibularis),
  - The Buccal Aspects Of Either Jaws.

### Management

No management is required unless tori pose a functional problem such as a mechanical problem in the construction of dentures, or if they become frequently traumatized as a result of their prominent position and the resulting traumatic ulcers are slow to heal.

In such cases, surgical removal is indicated.

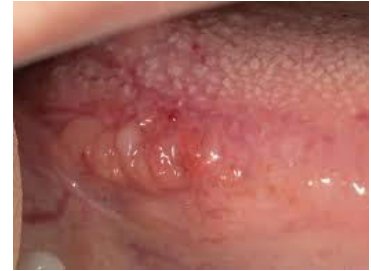

## Unencapsulated Lymphoid Aggregates

- These are normal structures, distinct from the palatine and lingual tonsils, and comprise part of Waldeyer's ring,
- They may increase in size as a result of **Benign (Reactive) Processes** or due to **Lymphoid Neoplasms (I.E., Lymphomas)**.

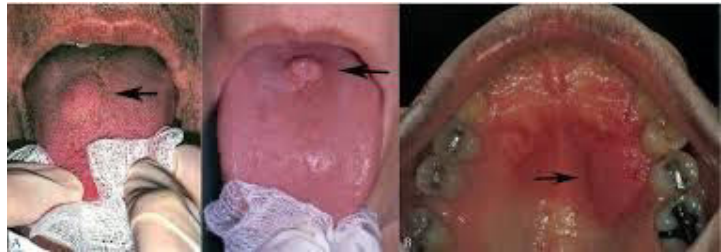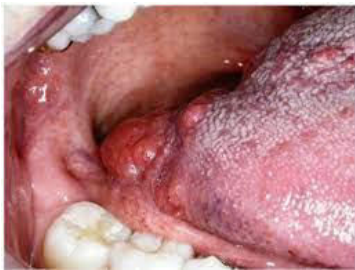### They may be located on

- The Postero-lateral aspects of the tongue,
- Anterior tonsillar pillar,
- Posterior pharyngeal wall,
- Soft palate,
- And dorsal tongue.



### Management

- No management is required unless these aggregates demonstrate unilateral and progressive enlargement, in which case a biopsy is indicated to rule out malignancy.

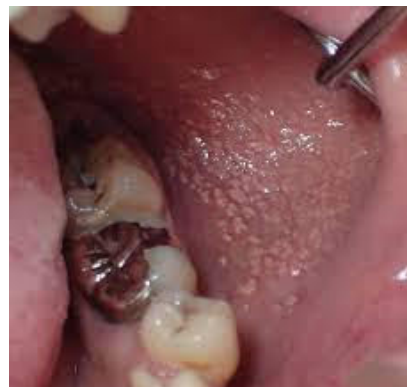
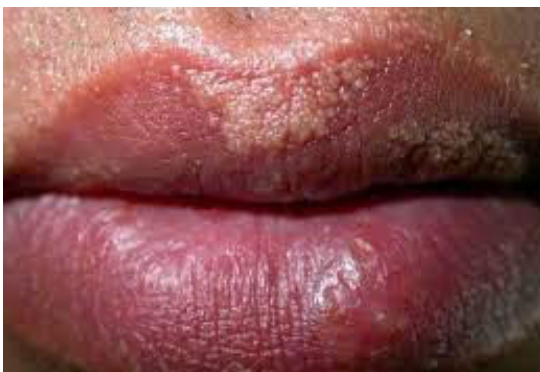
## Fordyce Spots

- These are Ectopic Sebaceous Glands and it is unclear why some individuals develop them.
- The most common locations for Fordyce spots are  
**The Buccal Mucosae**  
**Lip Vermillion.**

### Management

Typically no treatment is required. There are surgical options for patients with a high concentration of labial Fordyce spots deemed esthetically obtrusive.



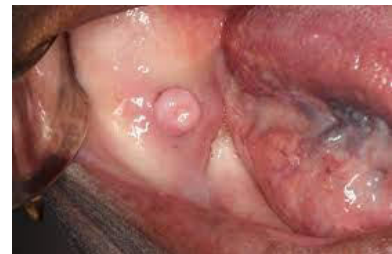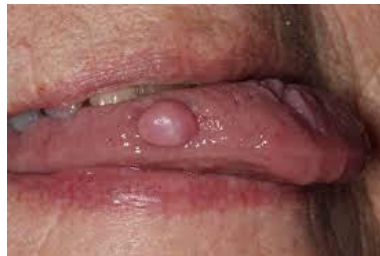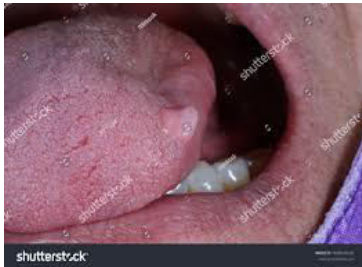## Benign soft tissue lesions

### Irritation Fibroma

- Irritation fibromas develop following trauma, such as a cheek or lip bite.
- Irritation fibromas are usually asymptomatic and may occur as either (Pedunculated Or Sessile (Broad-based) Pink Nodules) on any surface of the oral mucosa, but most commonly involving the buccal or labial mucosae.
- The majority are rarely >1 cm in diameter.

#### Management

- An excisional biopsy is indicated except when the procedure would produce marked deformity; in such a case, incisional biopsy to establish the diagnosis is mandatory.
- The irritant, if present, should also be eliminated when the lesion is excised to reduce the risk for recurrence.



### Fibrous Inflammatory Hyperplasia/ Epulis Fissuratum

- These are **Reactive Inflammatory Lesions** associated with the Periphery Of Ill-fitting Dentures.
- The growth is often split by the edge of the denture, resulting in a fissure, one part of the lesion lying under the denture and the other part lying between the lip or cheek and the outer denture surface.
- **Management**
- Many such hyperplastic growths will become less edematous and inflamed following the removal of the associated chronic irritant, but they rarely resolve entirely.
- In the preparation of the mouth to receive dentures, these lesions are excised (i.e., by Conventional Scalpel Or Laser Excision) to prevent further irritation and to ensure a soft tissue seal for the denture periphery.

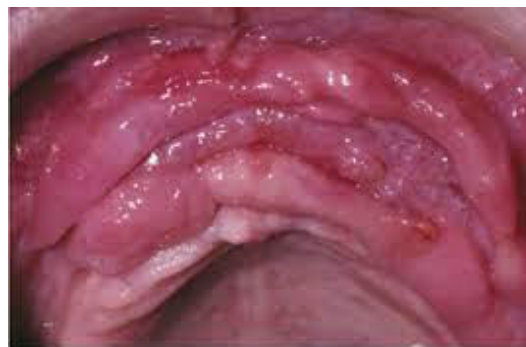
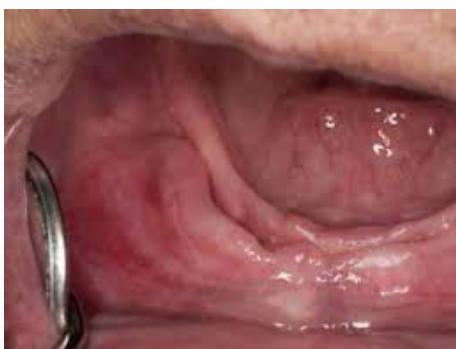
Fig. 12-11 Epulis fissuratum. Hyperplastic folds of tissue in the anterior maxillary vestibule.

Copyright © 2005 by Saunders, an imprint of Elsevier Inc.



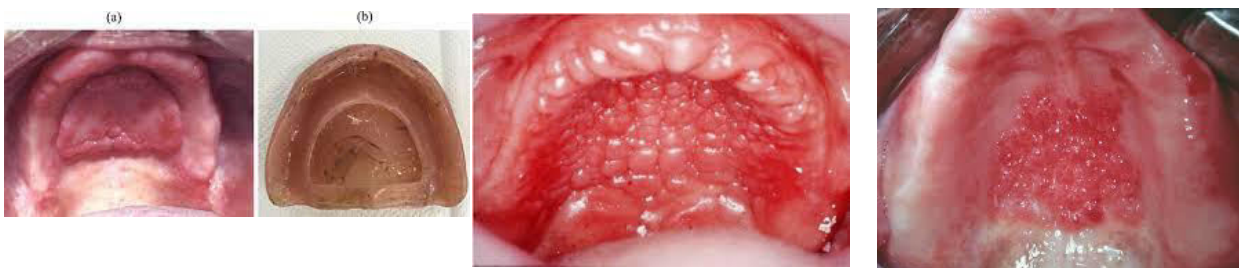### Inflammatory Papillary Hyperplasia

- This condition is usually associated with chronic denture irritation and denture stomatitis due to chronic candidal infection.
- This condition develops on the central hard palate, with a characteristic red to scarlet lesion demonstrating swollen and tightly packed projections resembling the surface of an overripe berry.

### Management

Mild cases may be treated successfully by **Topical Or Systemic Antifungals Alone.** Otherwise, **Papillary Hyperplasia May Be Surgically Excised Or Removed By Electrocautery, Cryosurgery, Laser Surgery.**

- The old denture or a palatal splint can be used as a postoperative surgical dressing, followed by fabrication of a new denture.

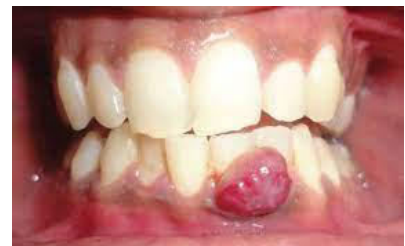
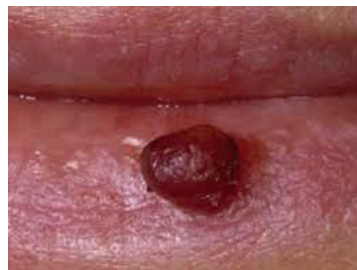
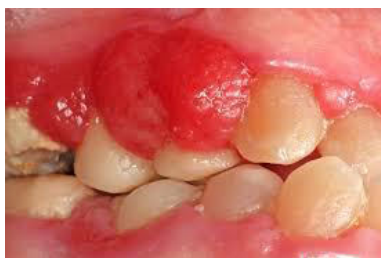### Pyogenic Granuloma and Pregnancy Tumor

- The etiology of pyogenic granulomas is thought to be in response to chronic irritation.
- Hormones play a role in the etiology of the lesion in the setting of pregnancy (where the lesion is named a pregnancy tumor).
- Pyogenic granulomas typically present as **Solitary Hemorrhagic, Often Pedunculated, Nodules** of variable size that occur most frequently on the gingiva, although they may occur on any mucosal surface.

### Management

- Surgical excision and successful removal of the associated irritant are associated with a low rate of recurrence.
- Scrupulous oral hygiene can prevent pregnancy tumors.

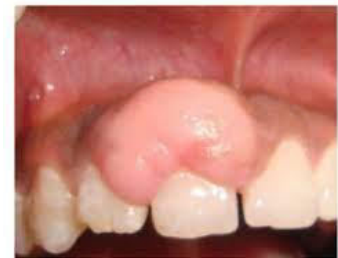
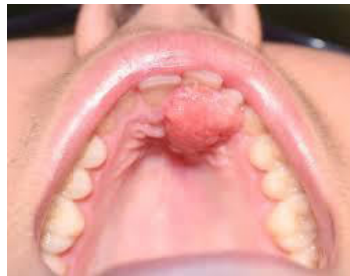
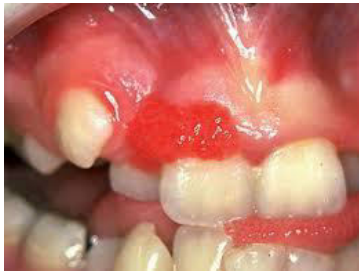- **Peripheral Ossifying or Cementifying Fibroma**

- This is a reactive lesion of unclear etiology, most likely related to local trauma/irritation.
- They occur exclusively on the gingiva, typically located in the interdental papilla region, and vary in presentation from pale pink to cherry red.

**Management**

- Treatment should include the elimination of subgingival irritants and periodontal pockets, as well as excision of the gingival growth.



**Peripheral Giant Cell Granuloma**

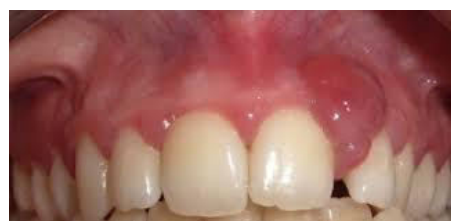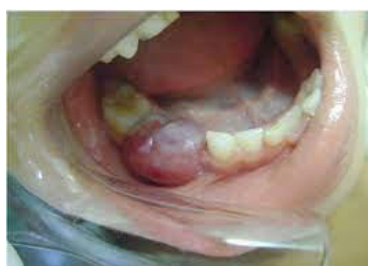- This is a reactive lesion of unclear etiology, most likely related to local trauma/irritation.

**Giant cell granulomas** are solitary and occur either as a

- **Peripheral Exophytic Lesion** found exclusively on the gingiva or as a **Centrally Located** lesion within the jaw, skull, or other facial bones.

**Management**

- Peripheral giant cell granuloma is treated identically to the other reactive gingival lesions, by surgical excision and the elimination of local factors contributing to gingival/periodontal disease.

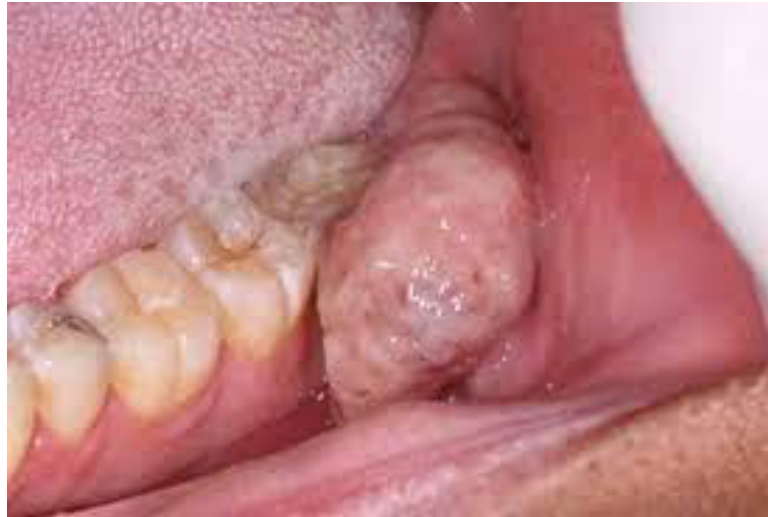

## **Nodular Fasciitis**

- This is a reactive proliferation of myofibroblasts and although the etiology is unknown, trauma is a likely factor.
- The most common oral site is the buccal mucosa and most have an exophytic presentation.

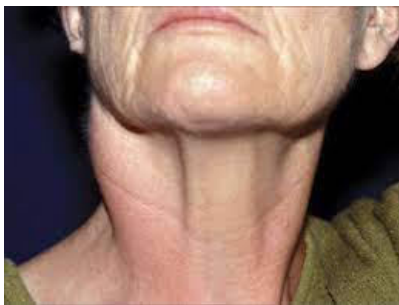
### **Management**

Conservative surgical excision and submission for histology.



## **Proliferative Myositis and Focal Myositis**

- These entities are reactive fibroblastic lesions that infiltrate around individual muscle fibers.
- Lesions most frequently involve the tongue and other neck and jaw muscles.



### **Management**

Conservative surgical excision and submission for histopathology



# Reactive Gingival Enlargement

Gingival enlargement or overgrowth is usually caused by

➤ Local Inflammatory Conditions Such As

- Poor Oral Hygiene,
- Food Impaction,
- Or Mouth Breathing.

➤ Systemic conditions such as

- Hormonal Changes
- Drug Therapy

may also cause or contribute to the severity of gingival enlargement.

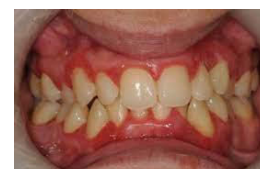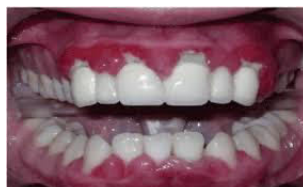## Inflammatory Gingival Enlargement

Inflammatory Gingival Enlargement occurs in sites where there has been

- Chronic Suboptimal Oral Hygiene With Heavy Biofilm Accumulation, Supra-gingival Calculus Formation, Impaction Of Food, The Presence Of Aggravating Factors Such As Orthodontic Appliances, Mouth Breathing, Hormonal Changes, Or Other Systemic Diseases.
- Gingival enlargement primarily affecting the maxillary anterior region may be observed in mouth breathers, and hormonal changes (such as during pregnancy or puberty) may exaggerate the local immune response to local factors and contribute to gingival enlargement.
- The clinical diagnosis of inflammatory gingival enlargement is
  - Glossy edematous bright red or purplish color, pitting edema, and A tendency to hemorrhage on slight provocation.
  - A malodor may result from the decomposition of food debris and accumulation of bacteria.
  - Pseudo-pockets formed by gingival enlargement.

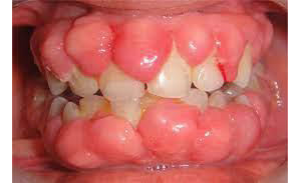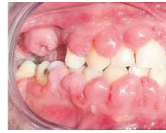### Management

Treatment of inflammatory gingival enlargement begins with the establishment of excellent oral hygiene, together with the elimination of all local and/or systemic predisposing factors if possible. This includes a professional debridement (supragingival scaling or subgingival root planing) and prophylaxis, and correction of faulty restorations, carious lesions, or food impaction sites. Close follow-up after initial therapy is required to assess improvements in home care and tissue response that will dictate subsequent treatment options.



## • Drug-Induced Gingival Enlargement

- Drug-induced gingival enlargement is most commonly associated with the administration of
  - ❑ Anticonvulsants (Principally Phenytoin),
  - ❑ Cyclosporine,
  - ❑ And Calcium Channel Blocking Agents (Principally Nifedipine).
  - ❑ Although rare, gingival enlargement has also been reported in patients taking other anticonvulsants, namely valproic acid, phenobarbital, and vigabatrin.
- The extent of inflammation and fibrosis is largely influenced by the drug type, dosing, and duration.
- There is a characteristic clinical appearance of drug-induced gingival enlargement.
- After approximately one month of use of the drug, interdental papillae enlargement begins, usually in the anterior regions, and enlargement may become more extensive, leading to gingival disfigurement and associated esthetic and functional complications.



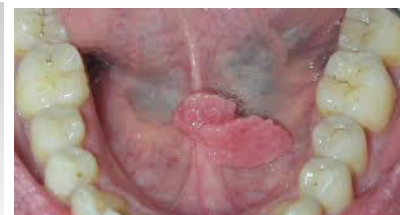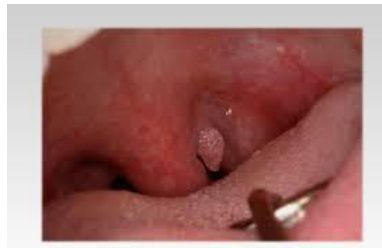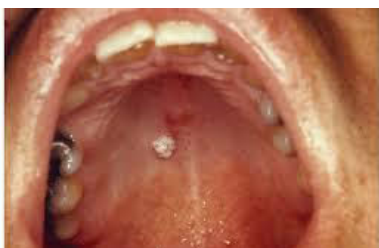### Management

- Prevention through optimal oral hygiene is essential to minimize the severity of enlargement.
- Nonsurgical treatments such as professional gingival debridement and topical or systemic antimicrobials may ameliorate gingival enlargement.
- Surgical management is reserved for severe cases, although recurrence is common.
- Conventional gingivectomy is commonly performed.
- Laser ablation gingivectomy may offer an advantage over conventional surgery since procedures are faster and there is improved hemostasis and more rapid healing.

## Epithelial Tumors

### Human Papillomavirus-Induced Growths

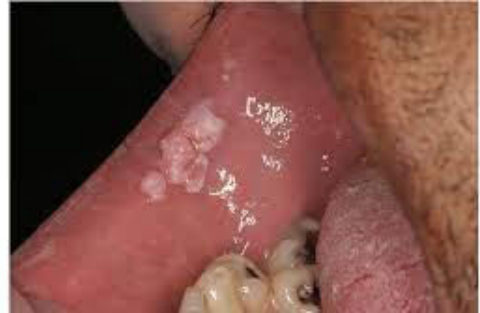- These growths are not true neoplasms, but rather virally induced tissue proliferations. There are almost 200 human papillomavirus (HPV) genotypes, of which at least 30 have been detected in oral lesions.
- The virus infects the basal cell layer of the epithelium following mucosal trauma. Lesions associated with sexual contact (referred to as condyloma acuminatum).
- Viral papillomas most commonly present as an isolated small growth (<1 cm diameter) on the palate, ranging in color from white to pink, their surface is papillary/verrucous, and they are pedunculated more often than sessile.
- Condyloma acuminata are typically larger in size than viral papillomas, are often flat-topped, and may present as a single main growth associated with smaller satellite lesions.
- The common wart, verruca vulgaris, is generally found on the skin (sometimes in association with similar skin lesions, often on the fingers). When involving the oral cavity, these warts are similar in appearance to viral papillomas and they tend to involve the lips, gingivae, and hard palate
- Focal epithelial hyperplasia (Heck's disease) is characterized by numerous soft, well-circumscribed, comparatively flat, and sessile papules distributed throughout the oral mucosa.



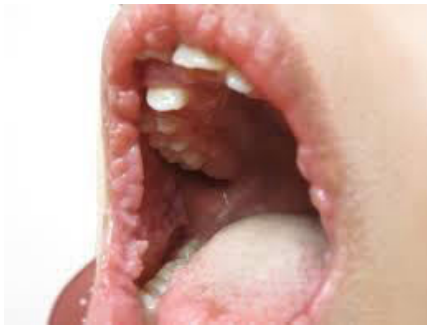### Management of Human Papillomavirus-Induced Growths

Oral viral papillomas and warts are clinically similar, and **Local Excision** is desirable.

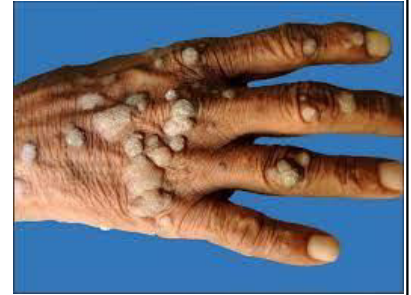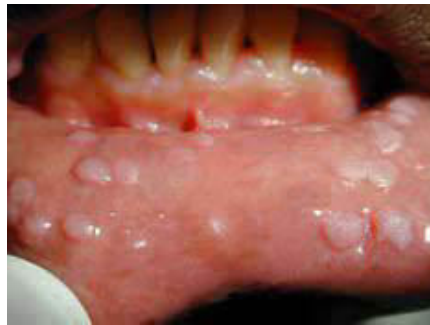Care should be exercised when removing HPV-induced oral growths with **Electrocautery Or Laser**, as there exists the possibility of aerosolizing viral particles.



**Condyloma Acuminatum**



**Focal Epithelial Hyperplasia (Heck's Disease)**



**Wart, Verruca Vulgaris of the skin**

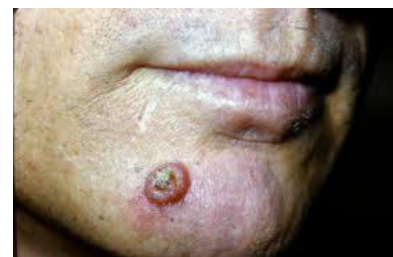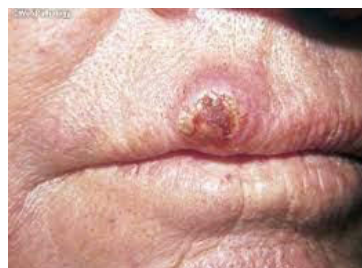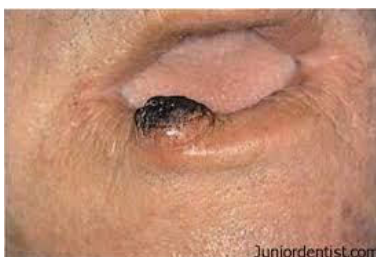### Keratoacanthoma (KA)

is a common low-grade (unlikely to metastasize or invade) rapidly-growing skin tumor that is believed to originate from the hair follicle (pilosebaceous unit) and can resemble squamous cell carcinoma

- The usual location is on the upper lip, where they are dome-like, sharply demarcated, appear fixed to the surrounding tissue, and are usually capped by thick keratin.

### Management

- Occasionally, the lesion matures, exfoliates, and heals spontaneously.
- In most cases, however, treatment of this lesion is conservative excision, although some believe that it is not clearly separable from squamous cell carcinoma and advocate wide excision to prevent recurrence.

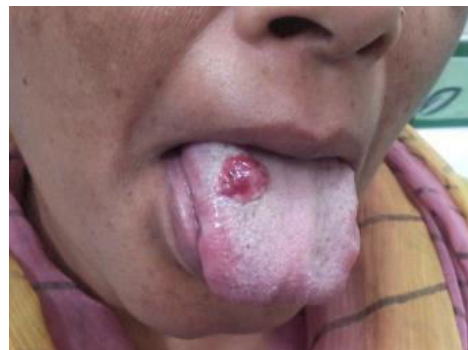
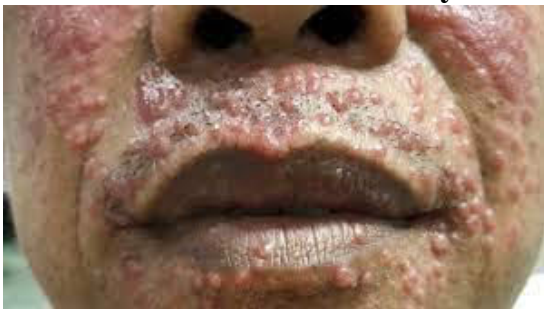
## Other Benign Epithelial Growths

### Molluscum contagiosum

is a dermatologic infection caused by a pox-virus that is acquired by direct skin contact.

- It produces benign, raised bumps, or lesions, on the upper layers of your skin. The small bumps are usually painless.
- Both intraoral and labial lesions of molluscum contagiosum occur, predominantly in HIV-infected patients, and these are characterized by clusters of tiny firm papules.
- They resolve without treatment and rarely leave scars.
- The length of time the virus lasts varies for each person, but the bumps can remain from 2 months to 4 years.

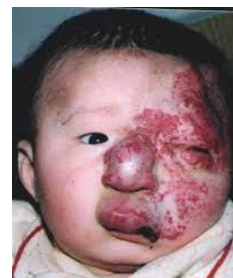
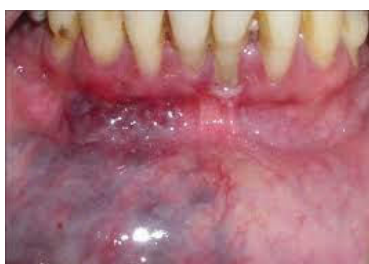
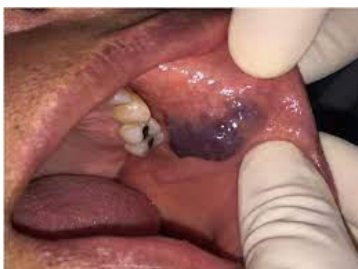### Vascular Anomalies

These entities have been classified using standardized terminology developed by the International Society for the Study of Vascular Anomalies and may be subdivided into vascular tumors and vascular malformations.

### Hemangiomas

- Hemangiomas of the head and neck are vascular tumors and true endothelial cell neoplasms.
- They appear a few weeks after birth and grow rapidly, and in most cases undergo involution over time.
- They have been described in almost all head and neck locations in a variety of presentations: superficial and deep, small and large, most commonly as solitary lesions but also as multiple lesions.
- Small lesions may be clinically and histologically indistinguishable from pyogenic granulomas and superficial venous varicosities.



# Capillary, Venous, and Arterial/Arteriovenous Vascular Malformations

- These malformations are classified depending on
  - The Vessel Type Involved**
  - Or Flow Types:**
    - **Arterial And Arteriovenous (High Flow),**
    - **Capillary, Or Venous (Low Flow).**
    - **Arterial or arteriovenous malformations** may be
      - **Firm,**
      - **Pulsatile,**
      - **Warm.**
    - **Venous malformations are**
      - **Soft**
      - **Easily Compressible.**

**Diascopy is the technique of applying pressure to a suspected vascular lesion to visualize the evacuation of coloration and may facilitate the differentiation of a small vascular lesion from non-blanchable red or pigmented lesions.**

## Management of Capillary, Venous, and Arterial/Arteriovenous Vascular Malformations

Care should be taken in performing biopsies or excising all vascular lesions, as they have a tendency for uncontrolled hemorrhage and the extent of the lesion is unknown, since only a small portion may be evident in the mouth.

Therefore, identification of the precise anatomic location and depth of tissue extent is warranted before treatment, particularly for the high-flow lesions.

### A Number Of Imaging Modalities May Be Indicated, Including

- **Ultrasound,**
- **Contrast-enhanced Magnetic Resonance Imaging**
- **Computed Tomography (CT),**
- **Dynamic MR Angiography.**

### Treatment modalities

- (alone or in combination) for peripheral vascular malformations depend on the type of malformation and include
  - Sirolimus,**
  - Sclerotherapy,**
  - Embolization,**
  - Or Surgical Excision/Resection Using Electrocoagulation.**

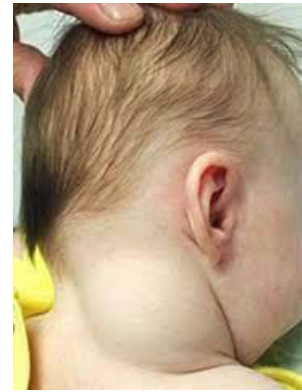
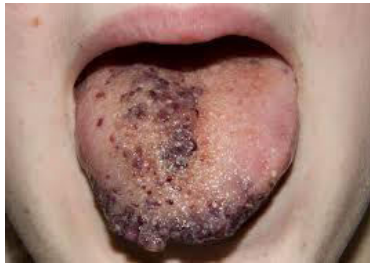
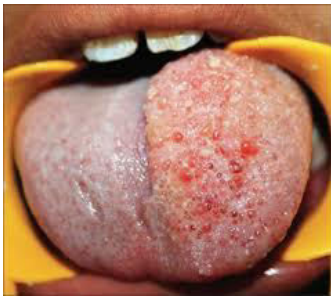## Lymphatic Malformations

- **Macrocystic, Microcystic, Or Mixed Cystic Lymphatic Malformations May Be**
- **Localized**
- **Regional,**

**They Are Characterized by an abnormal proliferation of lymphatic vessels.**

- **The most common extra-oral and intra-oral sites are**
- **Neck (Predominantly In The Posterior Triangle)**
- **Tongue, Respectively.**
- Clinically, lymph-angiomas are a slow-growing and painless soft tissue mass.
- Frequently they are without a clear anatomic outline, dissecting tissue planes, and can be more extensive than anticipated.



### Management of lymphatic malformations

The treatment of lymphatic malformations is dictated by their type, anatomic site, and extent of infiltration into surrounding structures.

Sclerotherapy (with chemotherapeutic agents such as picabiniil [OK-432], bleomycin, or doxycycline) is advocated over surgical excision in most cases.

Recurrence of oral lymphangiomas has been reported, presumably because the lesion is interwoven between muscle fibers, preventing complete removal.

## **Neurogenic Tumors**

### **Traumatic Neuroma**

- is a reactive lesion caused by injury to a peripheral nerve.
- When a nerve and its sheath are damaged, the proximal end of the damaged nerve proliferates into a mass of nerve and Schwann cells mixed with dense fibrous scar tissue.
- In the oral cavity, injury to a nerve may occur from injection of local anesthesia, surgery, or other sources of trauma.
- Traumatic neuromas in the oral cavity may occur in any location where a nerve is damaged, and **Mental Foramen Area, Tongue, Lower Lip** are the most common sites.
- **Traumatic neuromas may lead to either**
  - Reduced Sensation**
  - 20% Of Cases, Elicit Discomfort.**
  - The discomfort may range from pain on palpation or pressure from an overlying denture (in the case of a neuroma involving the mental foramen area) to severe and constant pain.**

#### **Management**

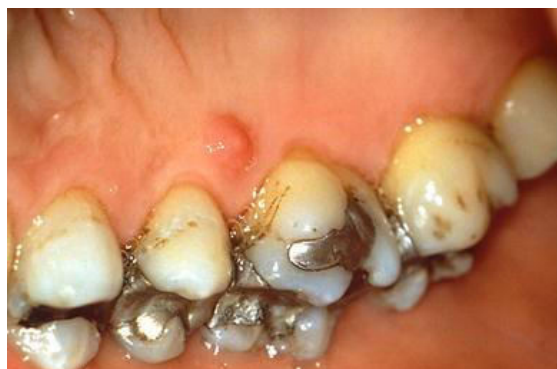- Traumatic neuromas are treated by surgical excision and recurrence is rare.**

## **Palisaded Encapsulated Neuroma**

- This is considered a reactive neoplasm, likely in response to trauma.
- This lesion is rare and most often occurs in older adults.
- The lesions are solitary, a feature that distinguishes them from the neuromas in (MEN syndrome). They are typically painless and the most common location is the hard palate.

#### **Management**

- Palisaded encapsulated neuromas are treated by surgical excision and recurrence is rare.

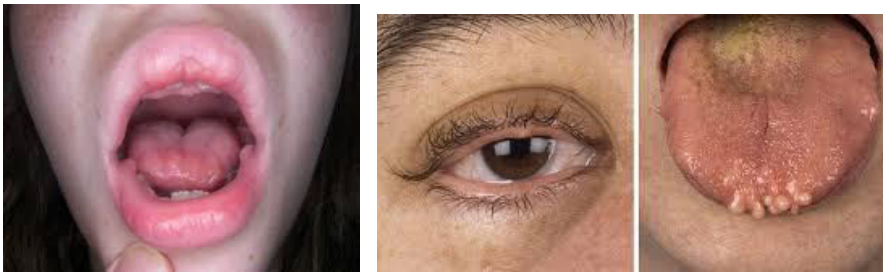

## Oral Mucosal Neuromas and Multiple Endocrine Neoplasia Syndrome 2B (MEN 2B)

- MEN 2B is caused by inherited mutations and characterized by tumors or hyperplasia of neuroendocrine tissues.
- Patients with MEN 2B present with a characteristic phenotype that includes medullary thyroid carcinoma, pheochromocytoma, prominent corneal nerve fibers, enlarged lips, and neuromas on the eyelids and oral mucosal tissues.

### Management

**Prophylactic Total Thyroidectomy**, ideally before the age of 1 year.

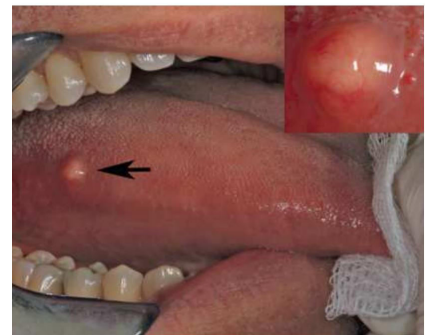
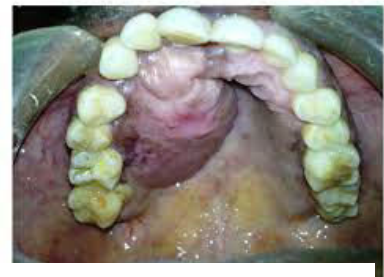


## Neurofibroma and Schwannoma (aka Neurilemmoma)

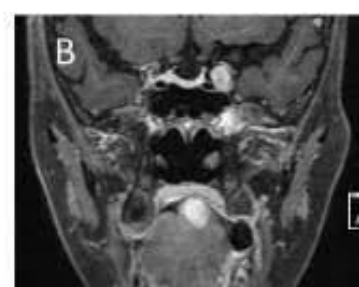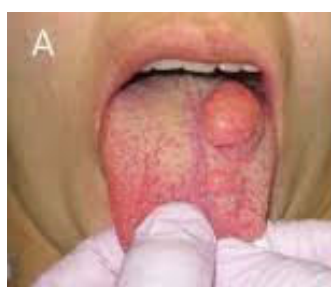- These are benign tumors derived from the tissue that envelops nerves and includes Schwann cells and fibroblasts.
- They are typically asymptomatic and the tongue is the most common intraoral location.

### Management

- The treatment for a neurofibroma or schwannoma is surgical excision. They generally do not recur



Neurogenic tumor involving the right lateral tongue.



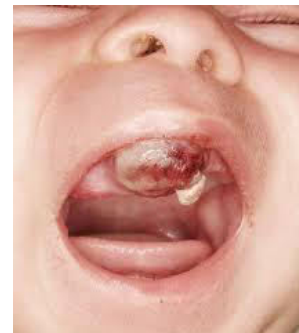

## **Melanotic Neuroectodermal Tumor of Infancy**

- Melanotic neuro-ectodermal tumor of infancy is a benign neoplasm originating from neural crest cells that almost always occurs during the first year of life.
- The tumor most commonly occurs in the maxilla, followed by the skull, mandible, and brain.
- The tumor presents as a rapidly enlarging mass that destroys bone and may exhibit blue-black pigmentation.

### **Management**

- Conservative surgical removal is usually adequate, but this tumor has a high recurrence rate and malignant transformation has been reported rarely.

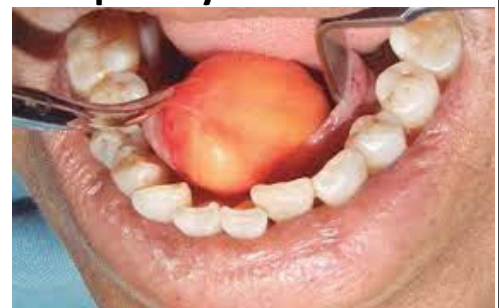
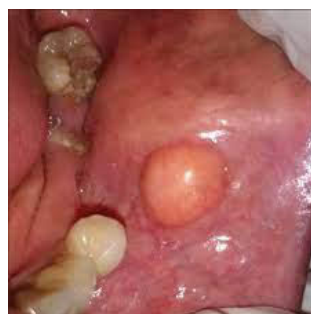
## **Lipoma**

- is a benign mesenchymal tumor of mature adipocytes.
- They occur in individuals over 40 years of age, and without any sex predilection
- The majority of oral lipomas are found on the buccal mucosa and tongue.
- lipoma appears as a yellow/orange mass with a thin epithelial surface, demonstrating a delicate pattern of blood vessels.

### **Management**

- The lipoma is treated by conservative surgical excision and generally does not recur.
- Intramuscular lipomas have a somewhat higher recurrence rate because they are more difficult to remove completely.



# Benign Fibro-osseous Lesions

- **Fibrous dysplasia**

is a condition that is characterized by the replacement of normal bone with fibro-osseous tissue.

The pathogenesis is related to *GNAS* (guanine nucleotide binding protein, alpha stimulating) gene mutation.

- **The most widely accepted theory is that fibrous dysplasia results from an abnormality in the development of bone-forming mesenchyme.**
- Fibrous dysplasia presents in childhood, typically with a slowly progressive enlargement of bone that generally slows or ceases with puberty.
- **Radiographically, fibrous dysplasia classically presents with a “ground glass” appearance and may have varying degrees of radiopacity and radiolucency depending on the amount of calcified material present.**
- Plain film imaging and CT are useful in the diagnosis of fibrous dysplasia.

## **Laboratory Findings**

- An elevation in serum alkaline phosphatase may be seen in patients with extensive polyostotic disease.
- Biopsy of involved bone.

## **Several forms of fibrous dysplasia have been described.**

- **The monostotic form, characterized by the involvement of a single bone, is the most common form.**
- **Polyostotic forms are characterized by the involvement of more than one bone and include different types:**
  - (1) **Craniofacial Fibrous Dysplasia**, in which the maxilla and adjacent bones are involved;
  - (2) **Jaffe’s Type (Or Jaffe–Lichtenstein Type)**, in which there is multiple bone involvement along with an irregular macular melanin pigmentation of the skin (café au lait spots);
  - (3) **Rare Cases In Children (McCune–Albright Syndrome Or Albright Syndrome)**, in which there is severe, progressive bone involvement with café au lait skin pigmentation and endocrine abnormalities such as precocious puberty.

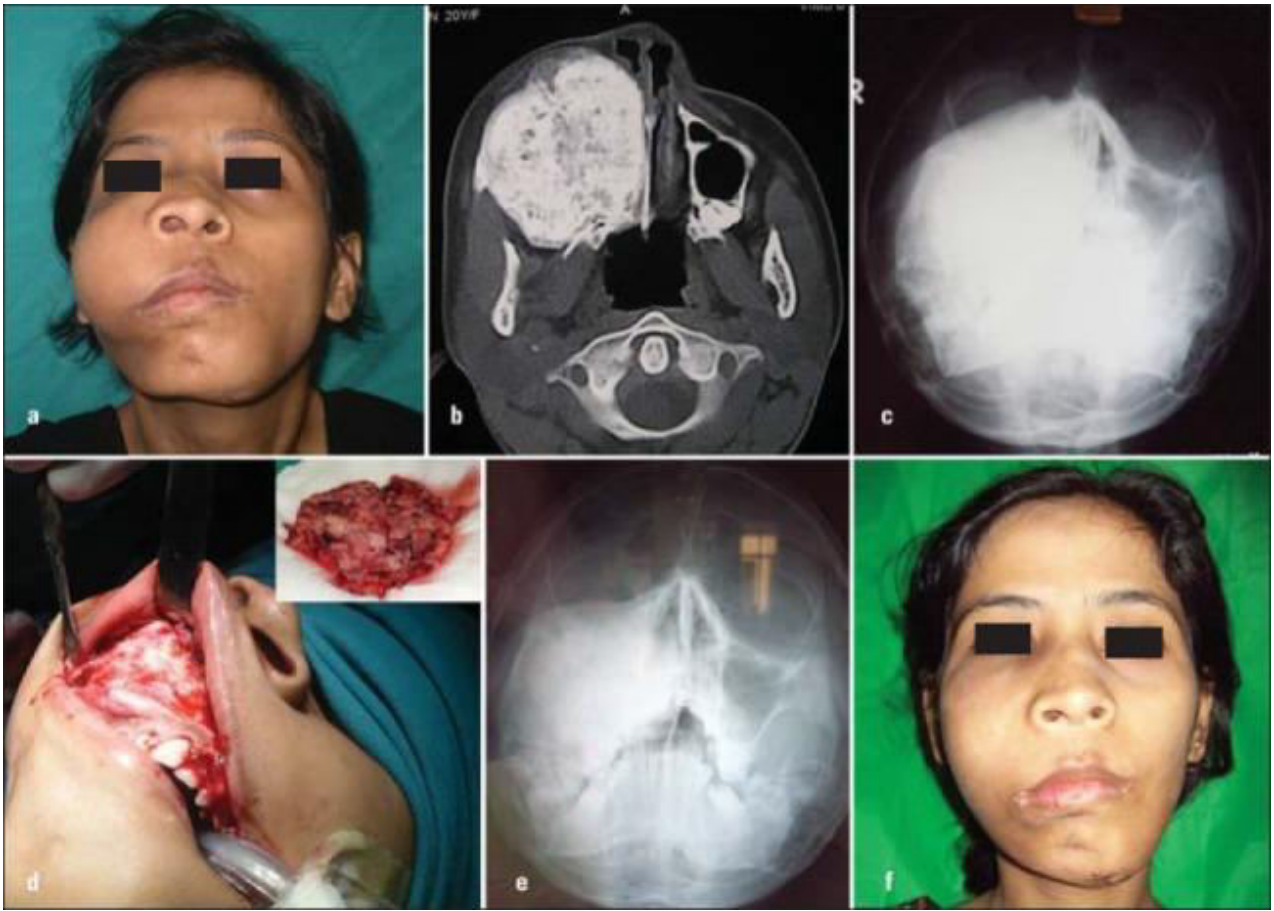## **Management**

In most cases, once diagnosis has been confirmed, management with close monitoring or with superficial recontouring of the lesion is sufficient.

Curettage is sometimes used for large radiolucent lesions.

Radiotherapy is contraindicated in the treatment of fibrous dysplasia.

More Recently use of **bisphosphonates** has had some use in limiting bone loss.



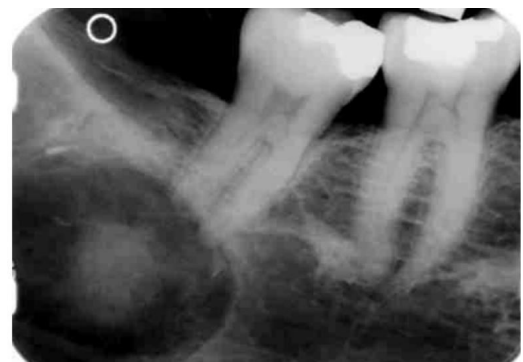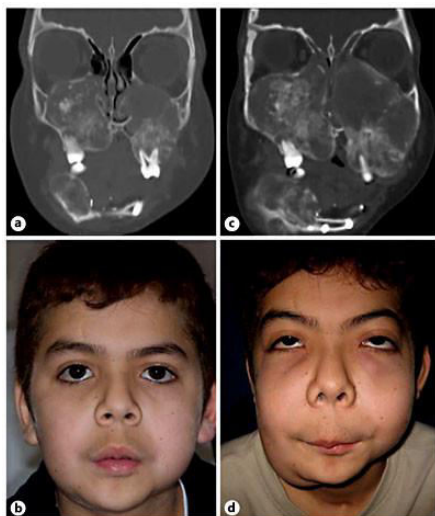
### **Ossifying fibroma**

is a slow-growing, well-circumscribed, benign tumor of bone that probably arises from cells of the periodontal ligament.

This benign tumor occurs in the mandible more frequently than the maxilla.

It is usually diagnosed in the third to fourth decades of age

- Radio-graphically, the tumor has a well-circumscribed margin.



### **Management**

- Treatment involves conservative surgical excision of the tumor

### Cemento-osseous Dysplasia

- The lesions begin as radiolucencies that become more radiopaque with time; large calcified masses become a characteristic histologic feature.

Three forms of this dysplastic process involving bone of the jaws are described:

- ❑ **Periapical Cemento-osseous Dysplasia,**
- ❑ **Focal Cemento-osseous Dysplasia,**
- ❑ **And Florid Cemento-osseous Dysplasia.**

Periapical Cemento-osseous dysplasia and florid osseous dysplasia are most commonly reported in black women over the age of 40 years.

Focal Cemento-osseous dysplasia is also reported to occur frequently in middle-aged white women.

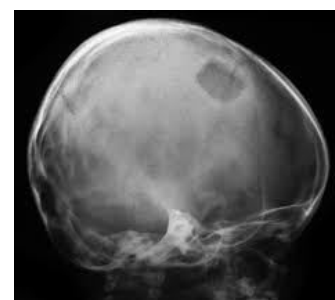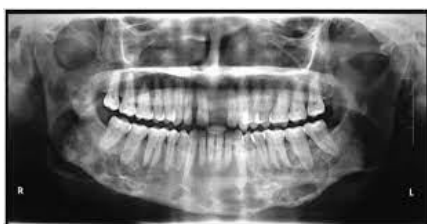### Management

Surgery (e.g., extractions, placement of implants) should be avoided due to potential poor healing and the increased risk of osteomyelitis associated with the affected bone, especially once the bone is sclerotic.

Asymptomatic patients should be counseled and followed regularly for prophylactic dental care. This will help to eliminate odontogenic or periodontal disease and any associated surgical intervention.

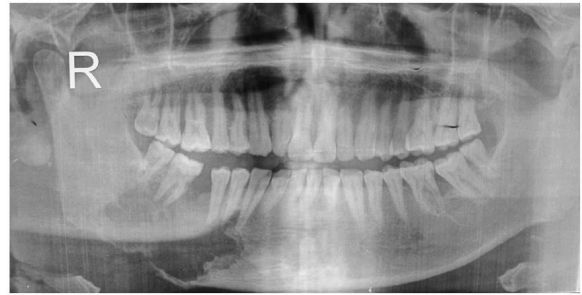
### **Langerhans Cell Histiocytosis (Histiocytosis X)**

- Langerhans cell histiocytosis, formerly called histiocytosis X, comprises a group of conditions includes
- (1) **Single Or Multiple Bone Lesions with no visceral involvement (Eosinophilic Granuloma);**
- (2) **Chronic Disseminated Form** that includes the classic **Hand–Schuller–Christian triad** of skull lesions, exophthalmos, and diabetes insipidus;
- (3) **Acute Disseminated Form (Letterer–Siwe disease)** that affects multiple organs and has a poor prognosis.
- Single or multiple eosinophilic granulomas with no systemic or visceral involvement are the most common presentation.
- Both the maxilla and the mandible may be affected in Langerhans cell histiocytosis, both with and without systemic involvement.





**Langerhan's histiocytosis**, can cause a significant destruction of bone around the teeth, leading to a radiographic appearance of **"teeth floating in air."**



### **Management**

The treatment varies, based on the clinical presentation of the disease.

Solitary eosinophilic granuloma may be treated by surgical curettage.

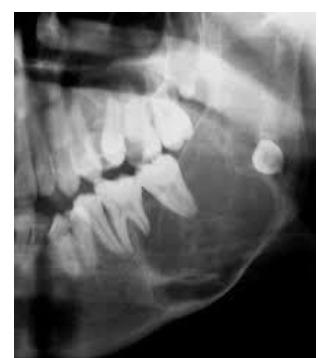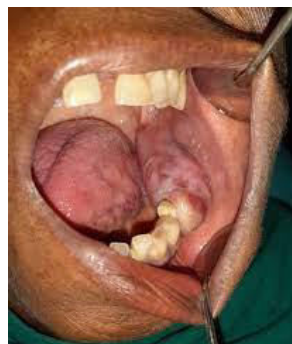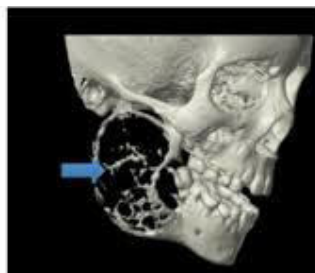
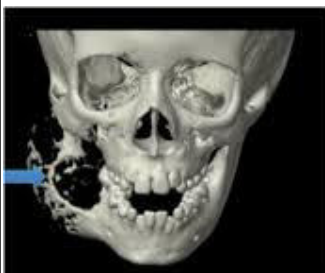Low-dose radiation therapy has been used successfully for lesions that are multiple, less accessible, or persistent

The older the patient with Langerhans cell histiocytosis and the less visceral involvement, the better the prognosis.

Langerhans cell histiocytosis is a life-threatening disease in infants and very young children.

## **Central Giant Cell Granuloma (Central Giant Cell Lesion)**

- **Central giant cell granuloma occurs more frequently in the mandible than the maxilla, generally anterior to the first molar, and often crossing the midline.**
- **Most central giant cell granulomas are diagnosed before age 30 years.**
- **The lesions have been reported to perforate the cortical plate and extend into the soft tissue adjacent to the bone.**
- **Complaint of pain is an inconsistent feature of these lesions.**



## Aneurysmal Bone Cyst

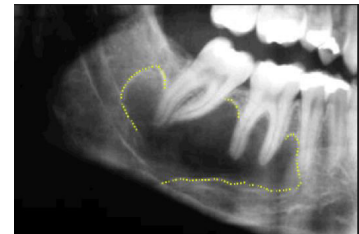
- An Aneurysmal Bone Cyst (ABC) is a benign cystic lesion of bone, composed of blood-filled spaces separated by connective tissue septa (walls) containing fibroblasts, osteoclast-type giant cells and reactive woven bone.
- It is found more frequently in the mandible (lower jaw) than the maxilla (upper jaw) (3:1) with preponderance for the body, ramus and angle of the mandible.
- It affects young persons under 20 years of age with no gender predilection.
- The clinical signs and symptoms are nonspecific. Pain has been reported (although not consistently) and enlargement of the involved bone is common.
- The radiographic appearance varies from unilocular to multilocular

### Management

Treatment depends on the size of the lesions and includes

- **Curettage,**
- **Enucleation,**
- **Resection.**

- Recurrence is attributed to incomplete removal.



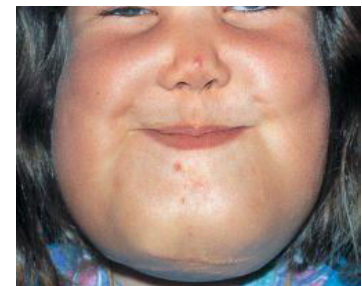### Cherubism

is inherited as an autosomal dominant trait, with a penetrance of nearly 100% in males and 50–75% in females.

- Cherubism is a rare disease that usually presents in early childhood.
- Cherubism is characterized by bilateral painless swellings (mandible and maxilla) that cause fullness of the cheeks; firm, protuberant, intraoral, alveolar masses; and missing or displaced teeth.
- Maxillary involvement can often produce a slightly upward turning of the child's eyes

### Laboratory Findings

- Serum calcium and phosphorus are within normal limits,
- but serum alkaline phosphatase may be elevated.



### Management

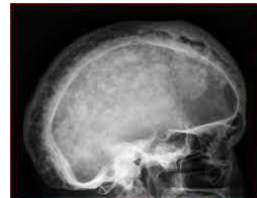- A variety of treatments have been recommended: no active treatment and regular follow-up, extraction of teeth in the involved areas, surgical contouring of expanded lesions, or complete curettage. Long-term longitudinal investigations have reported that the childhood lesions become partially or completely resolved in the adult.

## Paget's Disease Of Bone (Osteitis Deformans)

- Paget's disease of bone is a chronic disease of the adult skeleton characterized by focal areas of excessive bone resorption followed by bone formation.
- Histologically, the involved bone demonstrates prominent reversal lines that result from the resorption and deposition of bone.
- There is also replacement of the normal bone marrow by vascular fibrous connective tissue. Although some patients with Paget's disease have no symptoms, many experience considerable pain and deformity.
- The narrowing of skull foramina can cause
  - ill-defined neuralgic pains,
  - severe headache,
  - dizziness,
  - and deafness.
- The bony lesions of Paget's disease produce characteristic deformities of the skull, jaw, back, pelvis, and legs that are readily recognized both clinically and radiographically.

### Radiographically,

- There are patchy radiolucent and radiopaque changes that have been described as a "cotton wool" appearance.
- Other radiographic findings of the jaw bones include loss of the lamina dura, root resorption, and hypercementosis.
- CT and Tc 99m diphosphonate bone scanning are used to define the extent of bone involvement.



### Laboratory Findings

- Urinary levels of calcium and hydroxyproline (a measure of collagen metabolism)
- Serum Alkaline Phosphatase Levels (a measure of osteoblastic activity) are useful for diagnosing Paget's disease and for monitoring bone resorption and deposition during treatment.

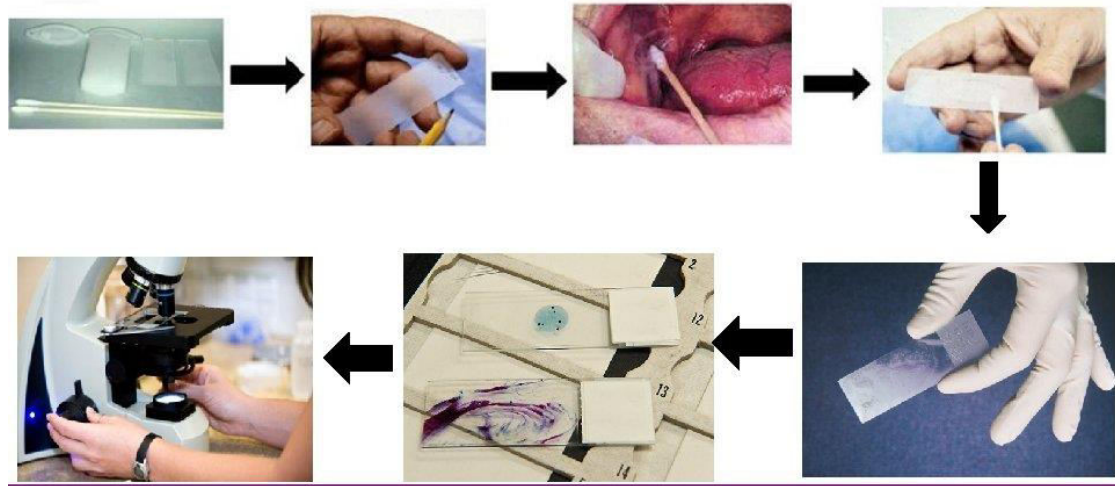
### Management

- ❑ **Antibiotics** (i.e., **intravenous mithramycin**, an effective inhibitor of osteoclastic activity),
- ❑ **Hormones** of human and animal origin (high- dose glucocorticoids and porcine, salmon, and human calcitonin administered subcutaneously or by nasal spray or suppository),
- ❑ **salts** such as the diphosphonate etidronate (which effectively reduces bone resorption),
- ❑ **Cytotoxic Agents** such as plicamycin and dactinomycin.

## C. Oral Exfoliative Cytology:

The microscopic examination of surface cells that have been removed from oral mucosa by scraping. The cells collected are smear on a glass slide and fixed.

### EXFOLIATIVE CYTOLOGY:



### Routine blood test of kidney function

The usual blood test which checks that the kidneys are working properly measures the level of urea, creatinine and certain dissolved salts.

**1. Urea:** - is a waste product formed from the breakdown of proteins. Urea is usually passed out in the urine. A high blood level of urea ('uraemia') indicates that the kidneys may not be working properly, or that you have a low body water content (are dehydrated).

**2. Creatinine :** - is a waste product made by the muscles. Creatinine passes into the bloodstream, and is usually passed out in urine. A high blood level of creatinine indicates that the kidneys may not be working properly. Creatinine is usually a more accurate marker of kidney function than urea.

**3. Estimated glomerular filtration rate (eGFR) :** - provides a guide to kidney function. Although the level of creatinine in the blood is a useful guide to kidney function, the eGFR is a more accurate measure. Blood creatinine can be used to estimate the eGFR using age, sex and race. The normal value for eGFR is 90-120 ml/min. An eGFR below 60 ml/min suggests that some kidney damage has occurred. The value becomes lower with increasing severity of kidney damage.

**4. Dissolved Salts:** - that are routinely measured are sodium, potassium, chloride and bicarbonate. They are sometimes referred to as 'electrolytes'. Abnormal blood levels of any of these may be due to a kidney problem. (Some other conditions may also alter the salt balance in the blood)



## Tests for the liver:

- **Alanine transaminase (ALT) test.** ALT is an enzyme that helps break down proteins and is found mainly in the liver. High levels in blood could mean liver damage. another name for ALT is serum glutamic pyruvic transaminase (SGPT).

- **Alkaline phosphatase (ALP) test.**

ALP is an enzyme have in the liver, bile ducts, and bone. the patient might have high levels if have liver damage or disease, a blocked bile duct, or bone disease.

- **Albumin and total protein test.**

Two main proteins: albumin and globulin. Low levels can mean damage or disease.

- **Aspartate transaminase (AST) test.**

AST is another enzyme found in the liver. High blood levels could be a sign of damage or disease. Another name for AST is serum glutamic oxaloacetic transaminase (SGOT).

- **Bilirubin test.**

Bilirubin is made when red blood cells break down. Usually, the liver cleans bilirubin out of the body. If high levels in blood, a problem called jaundice, mean liver damage.

- **Gamma-glutamyltransferase (GGT) test.**

High levels of the GGT enzyme could point to liver or bile duct damage.

- **L-lactate dehydrogenase (LD) test.**

LD is another enzyme that's high when have liver damage, but other conditions can raise its level, as well.

- **Prothrombin time (PT) test.**

This test measures how long it takes blood to clot. If it takes a long time, that could be a sign of liver damage. Medications that thin blood, such as warfarin, can also lead to a longer PT.

## The test of the thyroid gland

The major thyroid hormone secreted by the thyroid gland is thyroxine, also called T4 because it contains four iodine atoms. To exert its effects, T4 is converted to triiodothyronine (T3) by the removal of an iodine atom.

The amount of T4 produced by the thyroid gland is controlled by another hormone, which is made in the pituitary gland located at the base of the brain, called thyroid stimulating hormone (abbreviated TSH).

T4 and T3 circulate almost entirely bound to specific transport proteins, and there

are some situations which these proteins could change their level in the blood, producing also changes in the T4 and T3 levels (it happens frequently during pregnancy, women who take control birth pills, etc.)

Blood tests to measure TSH, T4, T3 and Free T4 are readily available and widely used.

**Tests to evaluate thyroid function include the following:**

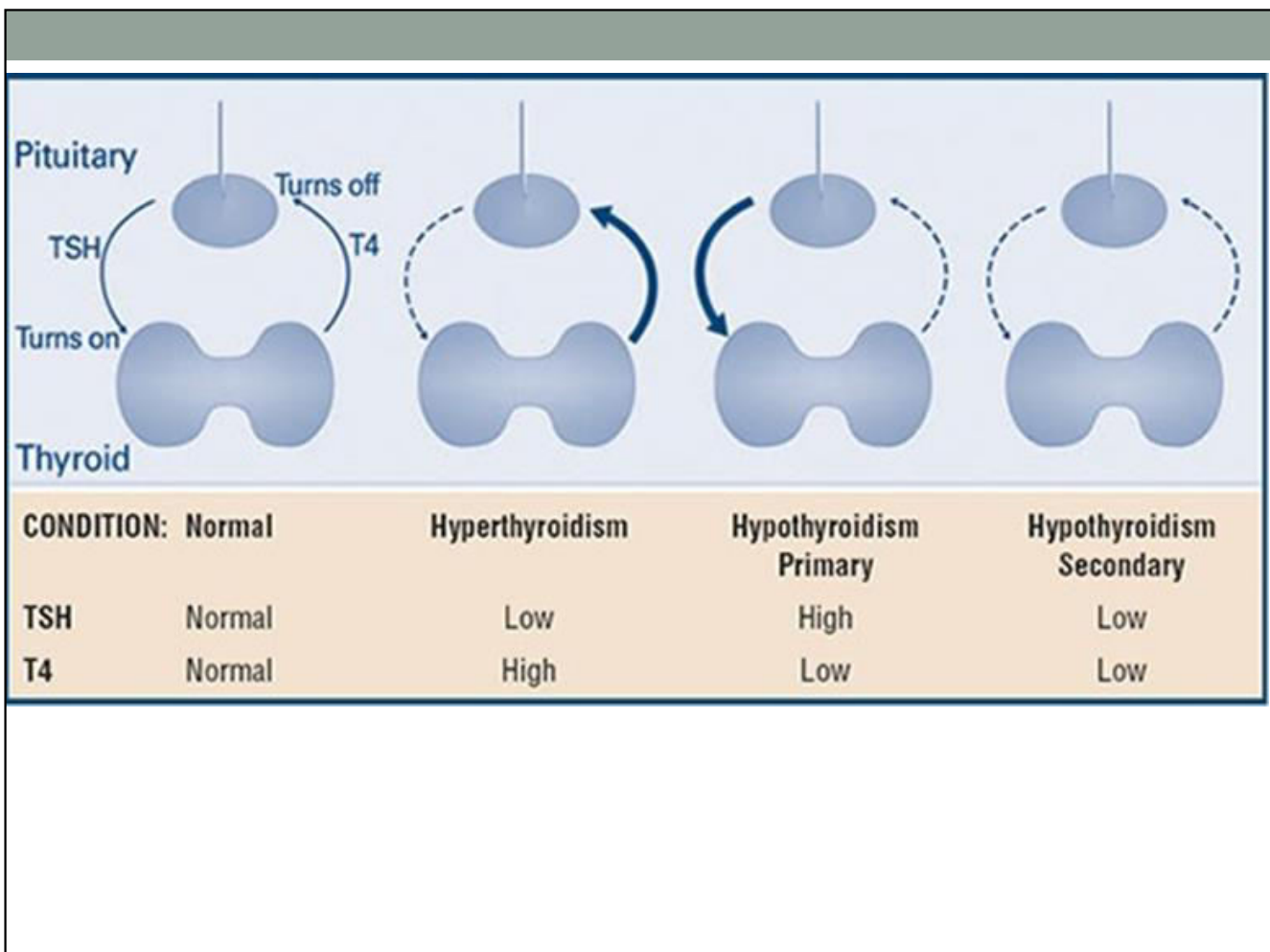
**1.TSH TESTS**

**2.T4 TESTS**

**3.T3 TESTS**

**4.THYROID ANTIBODY TESTS.**

**NON-BLOOD TESTS ----- RADIOACTIVE IODINE UPTAKE**



## Serological test:

Measurement of antibodies and other substance that increase in concentration in serum or saliva or other body fluid following infection.

Hepatitis B surface antibody (anti-HBs):

Hepatitis B surface antigen (HBsAg):

Australia antigen:

## Interpretation of Individual Test Results in the Diagnosis of Acute and Chronic Viral Hepatitis

### Marker Interpretation

#### HAV

##### HAV IgM •

Presence indicates current or recent infection.  
A negative result indicates absence of infect

##### HAV total Ab •

Presence of total (IgM and IgG) HAV antibody in the absence of HAV IgM antibody indicates immunity against HAV infection

### HBV

HBsAg • Presence indicates that a person has HBV infection and is infectious.

HBcAb, total • Presence indicates past or current HBV infection.

HBcAbIgM • Presence usually indicates HBV infection within the preceding 4 to 6 months (i.e., acute infection).

HBeAb • Presence indicates resolving infection or response to therapy.

HBeAg • Presence indicates active viral replication and high infectivity.

HBsAb • Presence indicates resolution and immunity against HBV infection or response to vaccination.

HBV DNA • Presence indicates current infection.

## **HDV**

**HDV Ab, total** • Presence coincident with the presence of HBsAg indicates past or current HBV/ HDV coinfection or superinfection.

**HDV IgM** • **Presence coincident with the presence of HBsAg indicates past or current HBV/ HDV coinfection or superinfection. A negative result coincident with the presence of HDV total antibody indicates resolved infection.**

-

## **HCV**

**HCV Ab** • Presence (with detectable HCV RNA) indicates current infection. A positive result coincident with a negative HCV RNA test may indicate a resolved infection or a false positive antibody screening test.

**HCV RNA** • Presence indicates current infection. A negative result indicates absence of current infection.

## **Immunofluorescence Technique**

These tests are important adjunct to histological studies of tissue.

**1. Direct Immunofluorescence technique:**

**2. Indirect Immunofluorescence technique:**

### **Immunofluorescence:**

Fluorescence dye can be conjugated to antibodies and such labeled antibodies can be used to locate and identify antigen in tissue. There are three type of immunofluorescence technique

#### **\*Direct immunofluorescent technique;**

The antibody is conjugated with fluorescein and applied directly to the tissue on a slide. In testing for pemphigus and pemphigoid, IgG isolated from the patient`s serum is labeled with fluorescein and incubated with tissue from a biopsy specimen of the patient oral mucosa or skin.

In pemphigus, the fluorescence is located to the intercellular spaces between epithelial cells of the mucosa or skin.

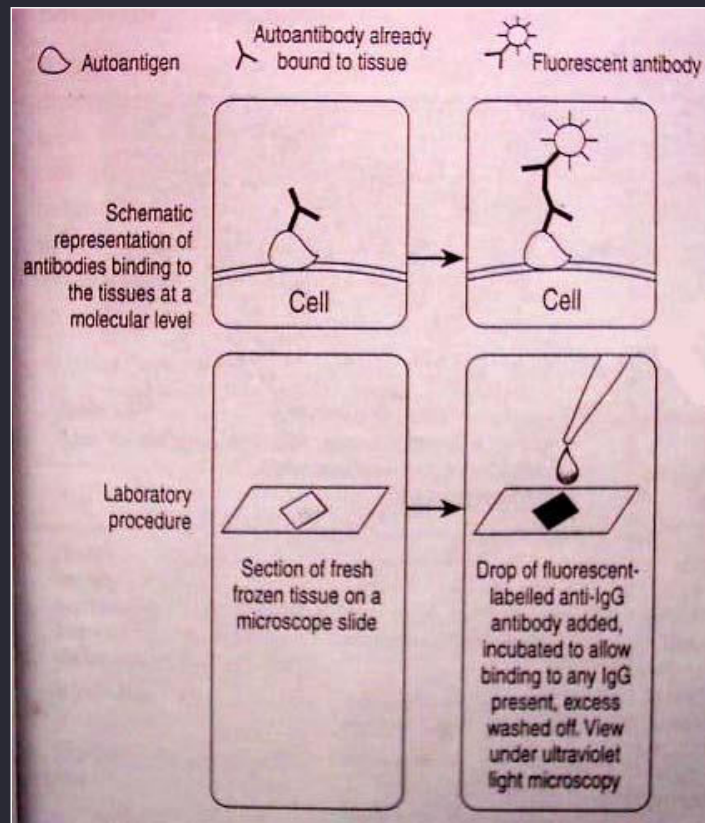
In pemphigoid, the fluorescence is located to the basement membrane zone separating epithelium from underlining connective tissue.

#### **\*indirect immunofluorescent technique;**

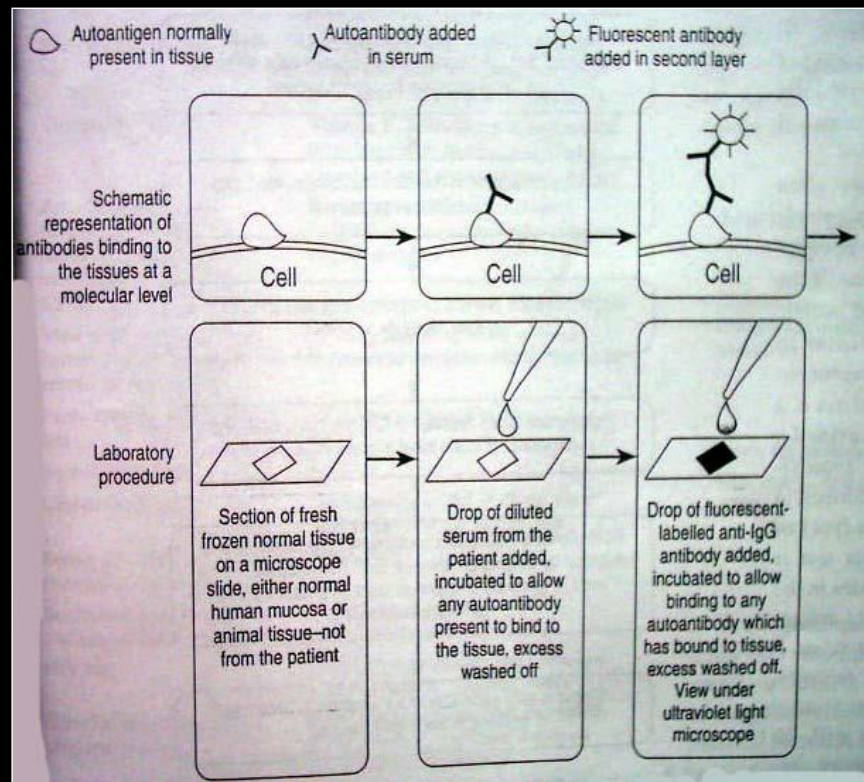
Secondary (indirect) immunofluorescence uses two antibodies; the unlabeled first (primary) antibody specifically binds the target molecule, and the secondary antibody, which carries the fluorophore, recognizes the primary antibody and binds to it. Multiple secondary antibodies can bind a single primary antibody. This provides signal amplification by increasing the number of fluorophore molecules per antigen.



# 1. Direct Immunofluorescence technique:

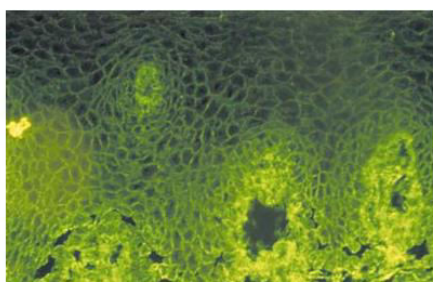


# 2. Indirect Immunofluorescence technique:

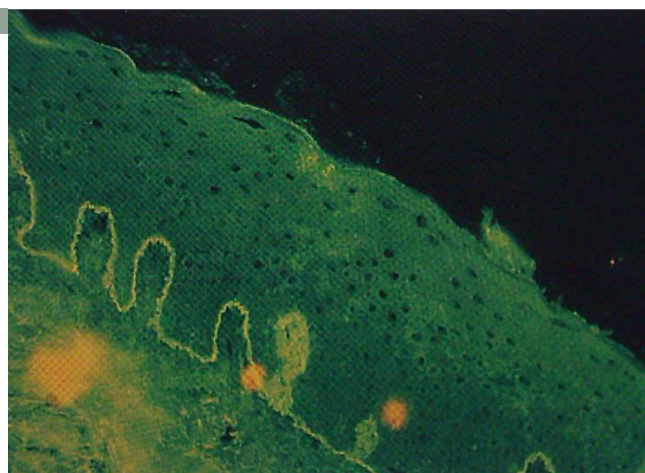


Disease	Direct IF	Location	Indirect IF	Type of AB
<b>Pemphigus Vulgaris</b>	+	<b>Inter Cellular</b>	<b>+ If Disease Widely Spread</b>	<b>Igg</b>
<b>Bullous Pemphigoid</b>	+	<b>Basement Membrane</b>	<b>+ If Disease Widely Spread</b>	<b>Igg</b>
<b>MM Pemphigoid</b>	<b>In Sever Case +</b>	<b>Basement Membrane</b>	<b>Usually,</b>	<b>Igg</b>
<b>Systemic LE</b>	+	<b>Basement Membrane</b>	+	<b>Antinuclear AB</b>
<b>Sjogren's Syndrome</b>	+	<b>Salivary Duct Cell</b>	<b>Usually,</b>	<b>Antinuclear AB</b>

#### Immunofluorescence Technique



pericellular, desmosomal localization of IgG in pemphigus vulgaris.



## Molecular –Biological Test

- ❑ Chromosome Studies.
- ❑ Comparative Genomic Hybridization.
- ❑ DNA Microarrays.
- ❑ Fluorescence In Situ Hybridization (FISH).
- ❑ Polymerase Chain Reaction (PCR).
- ❑ Gene Map.

### ●IMMUNOLOGICAL TESTS

Immunoglobulin's

Rheumatoid factor

HLA(Human leukocyte antigens) type

Antinuclear antibody

Anti-DNA-antibody

Anti double strand DNA Test

Anti-Ro-ssa and Anti-La-ssb

## **Diagnosis**

It means the identification of a disease by an investigation of the signs and symptoms.

## **Differential diagnosis**

It is the determination by systematic comparison and contrast of symptoms of the one of several diseases from which a patient is suffering.

## **Treatment planning:**

Successful dental treatment is always based on careful planning.

The objective of dental treatment planning is to devise the best dental treatment for each patient.

**The what to do and when to do it constitute the treatment planning.**

## **General format of the treatment planning :**

Most treatment plans follow the same general pattern and several authors have developed format for treatment plans. A format that works effectively in both private practice & institutional dentistry is

**\*Phase I:** Priority Treatment

**\*Phase II:** Disease Control

**\*Phase III:** Restoration Of Function & Esthetic

**\*Phase IV:** Re-evaluation

Is usually re-examination to evaluate the treatment plan & to determine additional therapy necessary before the patient is placed on recall state?

**\*Phase V:** Re-call

Is usually occurs many years after treatment.

## **Prognosis :**

Is a forecast of the probable result of treatment?

## Salivary gland diseases

The most common presenting complaints of a patient with salivary gland disease are

- ✓ Oral Dryness (Xerostomia)
- ✓ Glandular Swelling Or Mass.

There are Major and Minor groups of Salivary Glands:

The Major groups of salivary glands which are consisting of three major glands,  
The Parotid Submandibular And Sublingual Glands.

The parotid and submandibular glands each drain into the mouth in a single long duct.

The sublingual glands drain via many small ducts.

The major salivary glands can also be classified based on the dominant saliva producing acinar cell type:

Serous, Mucous, Mixed Of Serous And Mucous Cells.

Serous cells produce a more watery, enzyme-rich saliva.

Mucous cells secrete a more viscous fluid with plentiful salivary glycoproteins known as mucins.

The Parotid Gland is composed primarily of serous cells.

Submandibular Gland are a mix of mucous and serous types ,

Sublingual and Minor Salivary Glands are of the mucous type.

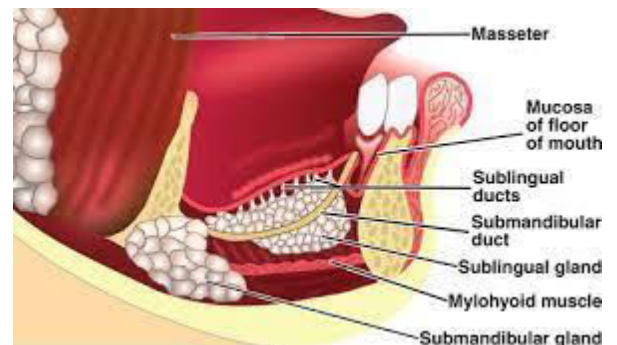
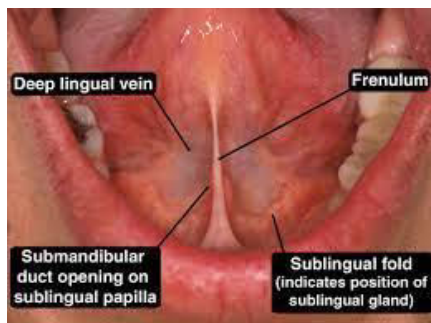
There are also between 600 and 1000 minor salivary glands named for the sites which they occupy (i.e., Labial, Buccal, Lingual, Palatal, Retromolar).

In addition, there are three sets of minor salivary glands of the tongue:

1. The glands of weber, found along the border of the lateral tongue
- 2- The Glands Of Von Ebner, surrounding the circumvallate papillae
- 3- The Glands of Blandin And Nuhn, also known as the anterior lingual glands, found in the anterior ventral tongue.

Parotid saliva is secreted through Stensen's ducts, the orifices of which are visible on the buccal mucosa in the vicinity of the maxillary first or second molar.

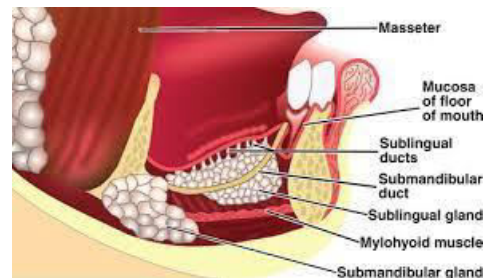
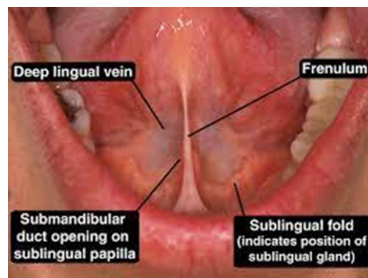
Submandibular gland saliva is secreted through the submandibular duct (Wharton's duct), which drains saliva from each submandibular gland and exits at the sublingual caruncles on either side of the lingual frenulum .





The sublingual glands are drained by 8-20 excretory ducts called the ducts of Rivinus.

The largest of all, the sublingual duct of Bartholin joins the submandibular duct to drain through the sublingual caruncle. The sublingual caruncle is a small papilla near the midline of the floor of the mouth on each side of the lingual frenulum. Most of the remaining small sublingual ducts open separately into the mouth on an elevated crest of mucous membrane. Both sublingual glands unite anteriorly and form a single mass through a horseshoe configuration around the lingual frenulum. The superior aspect of this U-shape forms an elevated, elongate crest of mucous membrane called the sublingual fold (plica sublingualis). Each sublingual fold extends from a posterolateral position and traverses anteriorly to join the sublingual papillae at the midline bilateral to the lingual frenulum.



Whole saliva (WS; the mixed fluid contents of the oral cavity) is a hypotonic fluid relative to blood plasma and is composed of secretions from the major and minor salivary glands.

It is composed of greater than 99% water and less than 1% proteins and salts.

WS may also contain variable amounts of gingival crevicular fluid, microorganisms, food debris, exfoliated mucosal cells, and mucus.

The most common presentation of salivary gland disease is

**xerostomia** which is a subjective complaint of dry mouth.

Hyposalivation refers to a quantified reduced salivary flow rate and may or may not be accompanied by xerostomia.

Similarly, xerostomia may or may not be associated with hyposalivation and can be a result of, for example, a change in salivary composition to a greater mucous content.

**Hypersalivation (ptyalism)**

Refers to an increase in production of saliva and/or a decrease in oral clearance of saliva.

Salivary gland dysfunction is commonly used to indicate decreased salivary flow or another quantifiable alteration in salivary performance

Causes of salivary gland hypofunction include:-

1- Medications

xerogenic medications (including many antidepressants, Anticholinergics, antispasmodics, antihistamines, antihypertensives, sedatives, diuretics, and bronchodilators)

2- Other agents (e.g., caffeine, alcohol, cigarette smoking) irradiation to the head and neck (i.e., external and internal beam radiation therapy)

3- Systemic disease e.g., diabetes mellitus, salivary gland masses

4- Psychological conditions (e.g., depression)

5- Malnutrition (e.g., bulimia, dehydration)

6- Autoimmune disease (e.g., Sjogren's syndrome SS)

7- Other unspecified or undiagnosed conditions. (Anxiety)



### List of Differential Diagnosis for Salivary Gland Hypofunction

- Autoimmune:- Chronic graft-versus-host disease ,Sjogren's syndrome
- Developmental :- Salivary gland aplasia
- Iatrogenic:- External beam radiation, Internal beam radiation Postsurgical :- (adenectomy, ductal ligation), Botox injection
- Inflammatory:- IgG4-related disease (Mikulicz's disease)
- Infectious:- Viral: CMV, HIV, hepatitis C
- Granulomatous: - Tuberculosis
- Medication associated
- Neoplastic :- Benign and malignant salivary gland tumors
- Nonneoplastic :- Sialolithiasis
- Systemic :- Anorexia nervosa, diabetes mellitus, chronic alcoholism, sarcoidosis.

### Symptoms of Salivary Gland Dysfunction

Symptoms of salivary gland hypofunction are related to

- 1- **Decreased fluid in the oral cavity** and this may have an effect on mucosal hydration and oral functions.
- 2- **Patients may complain of dryness of all the oral mucosal surfaces**, including the lips and throat, and **difficulty chewing, swallowing, and speaking.**
- 3- Other associated complaints may include **oral pain, an oral burning sensation, chronic sore throat and pain with swallowing.**
- 4- **The mucosa** may be **sensitive to spicy or coarse foods**, limiting the patient's enjoyment of meals, which may compromise nutrition.
- 5- The need to **sip liquids to swallow food, or difficulties in swallowing dry food** have all been highly correlated with measurable decreases in secretory capacity.

### Past and Present Medical History

Over 400 drugs are reported to have dry mouth as a side effect.

( individual that has recently started taking a tricyclic antidepressant.)

A thorough history is essential.

If the past and present medical history reveals medical conditions like a patient who has received radiotherapy for a head and the neck malignancy.

A patient's report of eye, throat, nasal, skin, or a vaginal dryness, in addition to xerostomia, may be a significant indication of a systemic condition, such as Sjogren's syndrome.

## **Clinical Examination**

### **Extra and intra oral examination: -**

#### **1- Signs of mucosal dryness:-**

Candidiasis, Enlargement of salivary gland. Viscous or scant secretions.

**2- Enlargement can be associated with a variety of inflammatory, infectious, or neoplastic and other conditions**

**3- A cloudy exudates may be a sign of bacterial infection.** The exudates should be cultured if it does not appear clear, particularly in the case of an enlarged gland.

**4- Function of the facial nerve** when evaluating parotid tumors.

**5- Tumors of the minor salivary glands** are usually smooth masses located on the hard or soft palate.

**6- Ulceration of the overlying mucosa** should raise suspicion of malignancy.

## **The parotid glands**

Is the largest of the salivary glands, are positioned on the lateral aspect of the face overlying the posterior surface of the mandible, antero-inferiorly to the auricle.

Superficial and deep lobe based on the course of the facial nerve as it traverses the gland.

Most benign tumors of the parotid gland are located within the superficial lobe and therefore are amenable to resection by superficial parotidectomy.

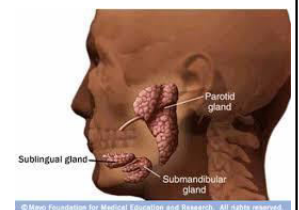
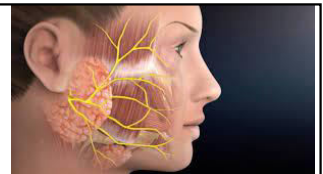Because of its relationship to the parotid gland, it is important to document function of the facial nerve when evaluating parotid masses.

Facial nerve paralysis is usually indicative of malignancy.

Rarely, infection or rapidly growing benign tumors may cause facial nerve paralysis.

### **Other findings suggesting malignancy include**

- o **Hardness.**
- o **Fixation.**
- o **Tenderness.**
- o **Infiltration of surrounding structures – e.g. facial nerve, local lymph nodes.**
- o **Overlying skin ulceration.**
- o **Cranial nerve palsy**



©May Foundation for Medical Education and Research. All rights reserved.

**Bilateral parotid gland masses are usually due to:-**

- Lymphadenopathy
- Warthin's Tumors
- Lymphoepithelial Cysts (Lecs)
- Enlarged Lymph Nodes In The Setting Of HIV
- Ss
- Rarely Other Salivary Gland Tumors Such As The Acinic Cell Adenocarcinoma

**Multiple painless masses within a single parotid gland may be due to:-**

- Warthin's tumors
- Lymph nodes
- Metastatic disease

**Other Benign And Malignant Tumors.**

Tumors in the submandibular or sublingual glands usually present as painless, solitary, slow-growing mobile masses. Bimanual palpation, with one hand intraorally on the floor of the mouth and the other extra-orally below the mandible, is necessary to evaluate the glands adequately.

Tumors of the minor salivary glands are usually smooth masses located most commonly on the hard or soft palate but may present anywhere minor salivary glands are present.

Salivary gland neoplasms arise most commonly in the parotid glands followed by the submandibular, sublingual, and minor salivary glands. The relative proportion of malignant neoplasms is greater the smaller the gland: that is, a neoplasm in the parotid gland is more likely to be benign than one arising in a minor salivary gland.

**Methods of diagnosis**

**Radiography**

lateral oblique

anteroposterior (AP) projections are used to visualize the parotid glands.

standard occlusal film can be placed intraorally adjacent to the parotid duct to visualize a stone close to the gland orifice.

It is useful particularly for the visualization of radiopaque sialoliths and the evaluation of bony destruction associated with malignant neoplasms and it can provide a background for interpretation of the sialogram.

**Sialography:-**

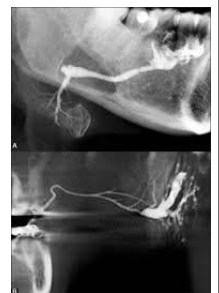is the radiographic visualization of the parotid and submandibular salivary glands and ducts following retrograde instillation of soluble contrast material into the Stensen's or Wharton's ducts .

**The ducts of the sublingual glands are too small for reliable injection of contrast medium.**

Sialography provides the clearest visualization of the branching ducts and acinar end pieces.

It is the recommended method for evaluating intrinsic and acquired abnormalities of the ductal system:-

- 1- Ductal Stricture,
- 2- Obstruction,
- 3- Dilatation,
- 4- Ruptures
- 5- For Identifying And Localizing Sialoliths



The two contraindications to sialography are:-

- 1- Active infection.
- 2- Allergy to contrast media

Oil-and water-based contrast media are available.

(both containing iodine and therefore contraindicated in patients with iodine sensitivity) are available

Radiographic views for sialography include panoramic, lateral oblique, AP.

Following the sialographic procedure, the patient should be instructed to massage the gland and/or to suck on lemon drops to promote the flow of saliva and contrast material out of the gland.

After approximately one hour. If a substantial amount of contrast material remains in the salivary gland, follow-up visits should be scheduled until the contrast material elutes or is fully resorbed.

Incomplete clearing can be due to:-

- 1. Obstruction of salivary outflow,
- 2. Extraductal or extravasated contrast medium,
- 3. Collection of contrast material in abscess cavities
- 4. Impaired secretory function.

Sialography performed during active infection may lead to :

- 1- Further irritate and potentially rupture the already inflamed gland.
- 2- The injection of contrast material might force bacteria throughout the ductal structure and worsen an infection.

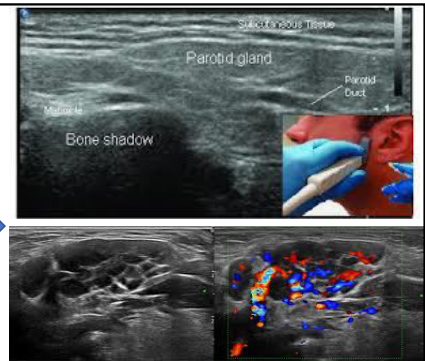
The iodine in the contrast media may induce an allergic reaction and can also interfere with thyroid function tests and with thyroid cancer evaluation by nuclear medicine if these are done

## Ultrasonography (us)

Advantages,

- 1- Initial evaluation of the salivary glands, especially in children and pregnant women
- 2- Evaluating for suspected sialolithiasis and salivary gland abscesses.
- 3- Differentiating between intra- and extra-glandular masses
- 4- Used to distinguish focal from diffuse disease,
- 5- Assess adjacent vascular structures and vascularity
- 6- Distinguish solid from cystic lesions,
- 7- Guide fine needle aspiration biopsy (FNAB)
- 8- Perform nodal staging
- 9- It can correctly differentiate malignant lesions from benign in most of the cases.

Ultrasonography



## Radionuclide Salivary Imaging

Scintigraphy with technetium (Tc) 99m pertechnetate is a dynamic and minimally invasive diagnostic test to assess salivary gland function and to determine abnormalities in gland uptake and excretion

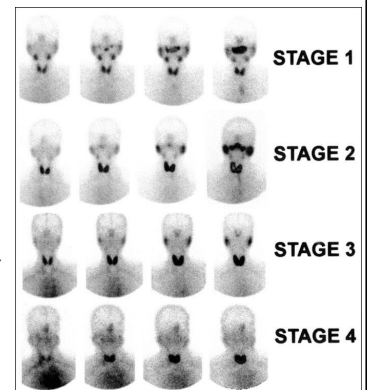
It is taken up by the salivary glands (following intravenous injection), transported through the glands, and then secreted into the oral cavity.

Only the parotid and submandibular glands are visualized distinctly, as well as the thyroid gland.

It has been used to aid in the diagnosis of:-

- 1- Ductal Obstruction,
- 2- Sialolithiasis,
- 3- Gland Aplasia,
- 4- Bell's Palsy,
- 5- Sjogren's Syndrome.

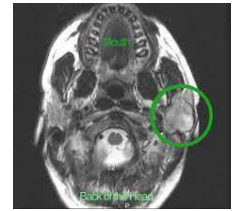
Scintigraphy



### Computed Tomography (CT)

is the method of choice in patients suspicious for inflammatory disease (abscess, calculi, major salivary duct dilatation, and acute inflammation) or in patients with contraindication for MR imaging

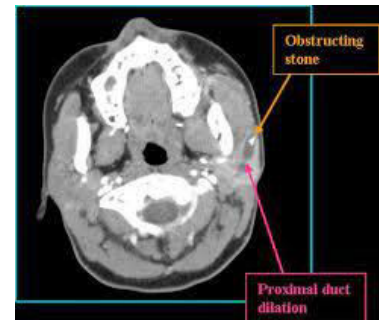
- Superior to plain radiographs and US in detection of sialolithiasis
- Allows detection and assessment of extent of salivary gland tumors
- Helpful in the differential diagnosis of salivary gland tumors
- Helpful in assessment of deep lobe of parotid gland and the minor salivary glands
- calcifications (pre-contrast) and enhancement pattern (post-contrast)
- Malignant tumor may mimic a benign tumor on CT scan
- Moderate accuracy (60-70%) in predicting the histological diagnosis of a lesion



- ❖ CT provides definition of cystic walls, making it possible to distinguish fluid-filled masses from abscess.
- ❖ For visualizing masses that are poorly defined on MRI.
- ❖ For patients who are unable to lie still long enough for adequate MRI (pediatric, geriatric, claustrophobic, and mentally or physically challenged patients).
- ❖ For patients for whom MRI is contraindicated.

### The disadvantage of CT include:-

- Radiation exposure.
- Administration of iodine-containing contrast media for enhancement.
- Potential scatter from dental restoration.



### Magnetic resonance imaging (MRI)

provides images for evaluation salivary gland pathology, adjacent structure, and proximity to the facial nerve

- Non-invasive alternative to conventional/digital sialography
- Allows accurate assessment of salivary gland calculi and stenoses

#### Advantages

- Non-invasive
- No exposure to ionizing radiation
- Does not require use of contrast material

False negative readings may occur in patients with very small calculi that are causing no ductal dilatation

- Inability to distinguish solid calculi from inspissated mucus and/or debris
- Distortion artefacts caused by dental amalgam may impair visualization of calculi or stenoses near the main ductal orifice.

#### Disadvantages

Expensive

Limited availability.

#### MRI is contraindicated for:

1. Patients with pacemakers or implants such as aneurismal bone clips. If the implant contains magnetic metal, an MRI can not be performed; however, dental implants are not magnetic and so are not contraindicated.
2. Patients who have difficulty maintaining a still position.
3. Patients with claustrophobia.

### Positron Emission Tomography (PET)

PET has been used recently for evaluation of the salivary glands. this may be a useful technique for measuring regional salivary gland function and recognizing inflammatory changes.



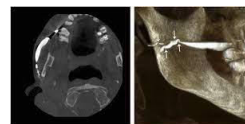### Cone Beam CT

Cone beam CT (CBCT) is increasingly being employed in dento-maxillo facial imaging since it provides high spatial resolution of osseous structures at a lower dose of radiation than conventional CT.

Using a cone-shaped x-ray beam and two-dimensional detectors, the CBCT scanner collects volume data by means of a single rotation taking 9-40 seconds.

CBCT sialography provides several advantages over conventional sialography including:-

- 1- Three-dimensional reconstruction.
- 2- allowing for manipulation of image rotation,
- 3- Slice thickness,
- 4- generation of various cross-sectional slices.



Overall, CBCT sialography appears to offer an improvement in imaging of salivary gland ductal system over conventional sialography.

### Salivary gland biopsy

The labial minor salivary glands are most commonly biopsied since they provide the most accessible source of tissue, especially where SS is suspected.

Fine-needle aspiration (FNA). When major gland biopsy is indicated for the evaluation of a distinct salivary mass.

Sialometry: Flow rate studies.

Sialo-chemistry: Saliva is a complex exocrine secretion containing more than 60 constituents.

Numerous changes in salivary chemistries have been described with a variety of salivary gland disorders.

### Serologic evaluation

No single definitive laboratory test for the diagnosis of Sjogren syndrome, a Combination of abnormal test results is frequently observed:

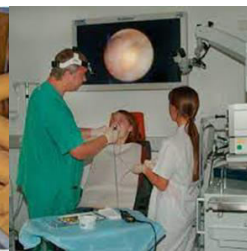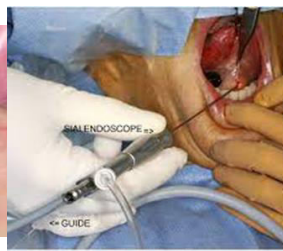
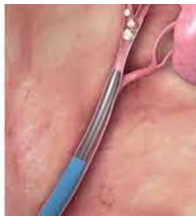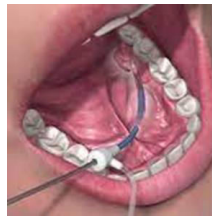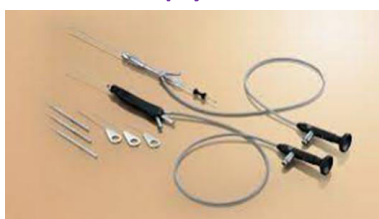
Elevated (ESR), Mild normocytic anemia, Leukopenia.

Autoantibodies are present in the majority of ss cases:-

Elevated immunoglobulins (particularly IgG), : Rheumatoid factor (RF), antinuclear Antibodies (ANAS), and anti-ssa/ro and anti-ssb/la are strongly indicative of SS.

The most proposed classification criteria for ss by the American college of Rheumatology (ACR) requires at least two of three criteria for case definition; one of which is a positive serum anti-ssa/ro and/or anti-ssb/la or positive Rf and ANA

Sialendoscopy : Sialendoscopy has emerged as a valuable diagnostic and therapeutic technique for many salivary gland disorders affecting the submandibular and parotid glands. Using a small camera, it allows visualization of intraductal anatomy and strictures or other pathoses within the ducts. Insertion of surgical instruments or lasers through the endoscope may permit simultaneous fragmentation and removal of calcified material, biopsy, or stricture dilation.



### Disorder of the salivary gland( Developmental Abnormalities)

#### ●Complete absence (aplasia or agenesis ) of salivary gland

which is rare, although it may occur together with other developmental defects.

●Accessory ducts are common and do not require treatment.

●Aberrant salivary glands are salivary tissues that develop at unusual anatomic sites.

Ectopic salivary glands have been reported in a variety of locations, including the middle-ear, external auditory canal, neck, posterior mandible, anterior mandible, pituitary gland, and cerebellopontine angle. These are usually incidental findings and do not require intervention.

●The Stafne's bone defect (SBD; also known as Stafne bone cyst):- is an asymptomatic depression of the lingual surface of the mandible often associated with ectopic salivary gland tissue. However, it is not a true cyst as there is no epithelial lining. The most common location of the SBD is in the region of the third molar inferior to the mandibular canal.

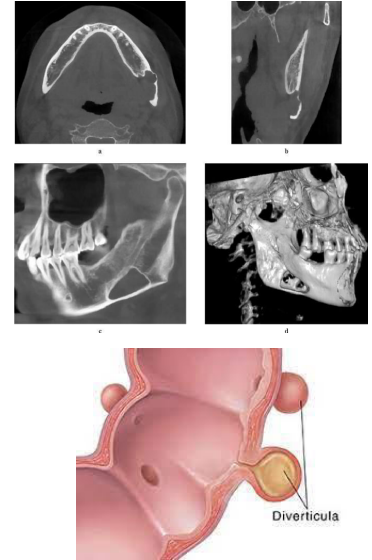
#### ●Diverticula

By definition, a diverticulum is a pouch or sac protruding from the wall of a duct.

Diverticula in the ducts of the major salivary glands often lead to pooling of saliva and recurrent sialadenitis. Diagnosis by sialography. Patients with diverticula are encouraged to regularly milk the involved salivary gland and to promote salivary flow through the duct.

#### ●Darier's Disease

Salivary duct abnormalities have been reported in Darier's disease (also known as dyskeratosis follicularis). Sialography of parotid glands in this condition revealed duct dilation, with periodic stricture affecting the main ducts. Symptoms of occasional obstructive sialadenitis have been reported.



### Sialolithiasis (Salivary Stones)

Sialoliths (also termed salivary calculi or salivary stones) are typically Calcified Organic Masses that form within the secretory system of the major salivary glands.

The etiologic factors favoring salivary stone formation may be classified into two groups:

#### 1. factors favoring saliva retention:

- Irregularities in the duct system
- Local inflammation
- Dehydration
- Medications such as anticholinergics and diuretics

#### 2.saliva composition

- Calcium saturation
- Deficit of crystallization inhibitors such as phytate.
- Bacterial infection also promotes sialolith formation due to an associated increase in salivary pH favoring calcium phosphate supersaturation.

Although no causal relationship between tobacco smoking and an increased risk of sialolithiasis has been definitively shown,

Smoking is known to adversely affect the cytotoxic activity of saliva and salivary amylase.

Salivary stones occur most commonly in the submandibular glands (80%-90%), followed by the parotid (5%-15%) and sublingual (2%-5%) and only very rarely occur in the minor salivary glands.

**The higher rate of sialolith formation in the submandibular gland is due to:**

- (1) The torturous course of Wharton's duct,
- (2) the higher calcium and phosphate levels of the secretion contained within
- (3) the dependent position of the submandibular glands that leaves them prone to stasis
- (4) the increased mucoid nature of the secretion.
- (5) Since the submandibular and parotid glands' secretion is dependent on nervous stimulation, when there is an absence of stimulation, secretory inactivity increases the risk of Stone development.

**Clinical Presentation**

Patients with sialoliths most commonly present with a history of **acute colicky pain and intermittent swelling** of the affected major salivary gland **during meals**.

The degree of symptoms is dependent on the extent of salivary duct obstruction and the presence of secondary infection.

Salivary gland swelling will be evident upon eating since the stone completely or partially blocks the flow of saliva resulting in salivary pooling within the gland ductal system.

Since the glands are encapsulated and there is little space for expansion, enlargement causes pain.

Swelling will subside when salivary stimulation ceases and output decreases.

Stasis of saliva may lead to infection, fibrosis, and gland atrophy.

If there is concurrent infection, there may be expressible suppurative or nonsuppurative drainage and erythema or warmth in the overlying skin.

**Complications from sialoliths include:-**

- ✓ Acute Sialadenitis
- ✓ Ductal Stricture
- ✓ Ductal Dilatation
- ✓ Fistula And A Sinus Tract
- ✓ Ulceration In The Tissue Covering The Stone In Chronic Cases.

**Diagnosis**

**Plain film** radiographs are helpful to visualize sialoliths; they, readily available, and result in minimal radiation exposure.

Since small and poorly calcified stones may not be readily identifiable, this modality is most useful in cases of suspected submandibular sialolithiasis, where an **occlusal radiograph** taken at 90° from the floor of the mouth is recommended.

However, other calcified entities such as phleboliths (stones that lie within a blood vessel), calcified cervical lymphadenopathy, and arterial atherosclerosis of the lingual artery can also appear on these films.

Stones in the parotid gland can be more difficult to visualize due to the Superimposition of other anatomic structures. **An AP view** of the face or an **occlusal film placed intraorally** adjacent to the duct may be useful in these cases.

Contrast sialography using iodinated contrast media may be used to visualize the parotid and submandibular ductal systems.

Sialography can also aid in differentiating calcified phleboliths from sialoliths since the former lie within a blood vessel, whereas the latter occur within the ductal structure.

Limitations of this modality include

The use of ionizing radiation.

Dependence on successful ductal cannulation.

Pain during and after the procedure.

Potential allergy to the contrast medium.

The use of contrast sialography is also contraindicated in the presence of acute sialadenitis.

Ultrasound (US) is widely used as a first-line imaging modality to assess the presence of salivary gland calculi.

Transoral sonography using an intraoral approach has been employed in suspected sialolithiasis.

Ultrasound (US) is

- ❖ **Noninvasive.**
- ❖ **Less Costly.**
- ❖ **Able To Visualize Radiolucent Calculi.**

Treatment

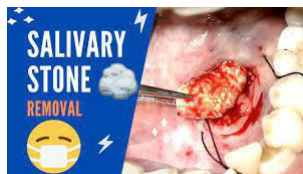
During the acute phase of sialolithiasis, therapy is primarily supportive.

Standard treatment during this phase often involves the

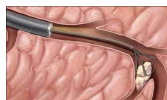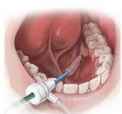- Analgesics.
- Hydration.
- Antibiotics.
- Antipyretics.
- Use Sialogogues is a drug or substance that increases the flow rate of saliva e.g. **Chewing Gum, Pilocarpine, And Cevimeline**
- Massage And Heat Applied** to the affected area may also be beneficial.
- Stones At Or Near The Orifice of the duct can often be removed**

Trans-orally By Milking The Gland

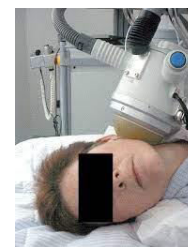
- Deeper Stones Require intervention with
  - Conventional Surgery



- **Or Sialendoscopy Placed To Maintain Patency Of The Duct.**



- Extracorporeal Shock Wave Lithotripsy (ESWL)** also allows for fragmentation of large sialoliths of any size or location.



## Extravasation and Retention Mucoceles and Ranulas Mucocele

**Mucocele** is a clinical term that describes swelling caused by the accumulation of saliva at the site of a traumatized or obstructed minor salivary gland duct.

Mucoceles can be classified histologically as

- ❑ Extravasation Types.
- ❑ Retention Types.

**The extravasation mucocele does not have an Epithelial Lining Or A Distinct Border.**

The formation of an extravasation mucocele is believed to be the result of trauma to a minor salivary gland excretory duct.

Laceration of the duct results in pooling of saliva in the adjacent submucosal tissue and consequent swelling.

**The retention type mucocele is caused by**

- ❑ Obstruction of a minor salivary gland duct often by sialolith.
- ❑ Periductal scarring.
- ❑ Tumor.

The blockage of salivary flow results in the accumulation of saliva and dilation of the duct.

### **Clinical Presentation**

Mucoceles often present as discrete, painless, smooth-surfaced swellings that can range from a few millimeters to a few centimeters in diameter.

Superficial lesions frequently have a characteristic blue mass.

Deeper lesions can be more diffuse, covered by normal appearing mucosa without the distinctive blue color.

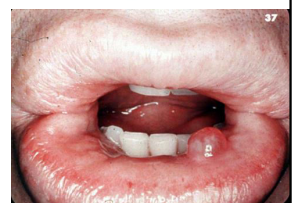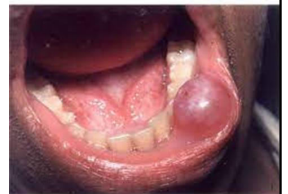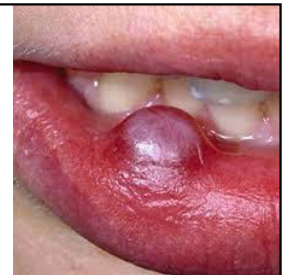The lesions vary in size over time;

Superficial Mucoceles are frequently traumatized, causing them to drain and deflate.

Mucoceles that continue to be traumatized are most likely to recur and may develop surface Ulceration.

**The differential diagnosis of a bluish lesion after trauma is highly suggestive of**

- Mucocele.
- Salivary Gland Neoplasms.
- Soft Tissue Neoplasms.
- Vascular Malformations.
- Vesiculobullous Diseases



**Extravasation mucoceles most frequently occur on the lower lip, where trauma is common.**

The buccal mucosa, tongue, floor of the mouth, and retromolar region are other commonly traumatized areas where mucous extravasation may be found.

These types of mucoceles are most commonly seen in children and teenagers.

### **Treatment**

Conventional definitive surgical treatment of mucoceles involves removal of the entire lesion along with the feeder salivary glands and duct.

**Incomplete removal of the mucocele may result in recurrence.**

Surgical management can be challenging since it can cause trauma to adjacent minor salivary glands and lead to the development of a new mucocele.

**Alternative treatments that have been explored with varying degrees of success include**

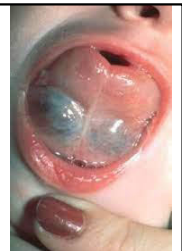- Electrosurgery.
- Cryosurgery Using Liquid Nitrogen.
- Laser Surgery
- Micro-marsupialization.
- Intralesional Injections Of Corticosteroids.
- And Sclerotherapy.

### **Ranula**

A form of mucocele located in the floor of the mouth is known as a ranula .

**Ranulas are believed to arise from the sublingual gland Possible causes include:-**

- 1- Mechanical trauma to its ducts of Rivinus, resulting in extravasation of saliva.
- 2- An obstructed salivary duct or a ductal aneurysm.



The predilection of ranulas in the sublingual glands has been thought to be due to the gland's continuous salivary secretion that precludes effective sealing of the mucous extravasation via fibrosis, in contrast to salivary secretion in the parotid and submandibular glands, which is dependent on gustatory stimulation.

**Ranulas are most common in the second decade of life and in females.**

Oral ranula remains confined to the sublingual space.

A congenital predisposition toward development of ranulas has been suggested, particularly in those of Asian descent.

**In addition, particular anatomic variations of the ductal system of the sublingual gland may contribute to the formation of ranulas.**



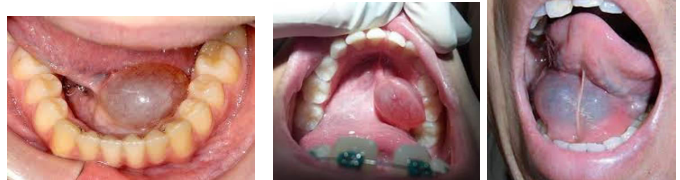### Clinical Presentation of Ranula:

The most common presentation of the “oral” ranula is a **painless, slow-growing, fluctuant, movable mass located in the floor of the mouth**.

Usually, the lesion forms to one side of the lingual frenulum; however, if the lesion extends deep into the soft tissue, it can cross the midline.

As observed with mucoceles, **superficial ranulas can have a typical bluish mass, but when the lesion is deeply seated, the overlying mucosa may have a normal appearance.**

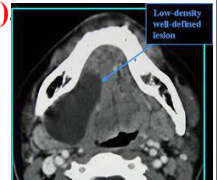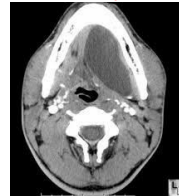The size of the lesions can vary, and larger lesions can cause deviation of the tongue.



### Diagnosis

Imaging to diagnose an oral ranula may not be necessary due to its characteristic clinical appearance, but to rule out other cystic lesions (e.g., **Thyroglossal Duct Cyst, Epidermoid Cyst, Cystic Hygroma**)

- ✓ FNA.
- ✓ Ultrasound.
- ✓ CT with contrast.
- ✓ MRI
- ✓ Ultrasound has been recommended for oral ranulas.



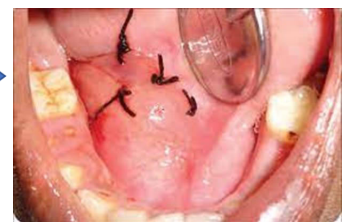### Treatment

The most predictable method of eradicating both oral and plunging ranulas is to remove the associated sublingual gland because this will almost certainly eliminate recurrences.

Sublingual gland adenectomy combined with intraoral excision of the ranula is suggested for the simple ranula.

### Other procedures used for the treatment of ranulas have included

- Simple Excision,
- Marsupialization. 
- Injection Of The Sclerosing Agent, Silver Nitrate, And Botulinum Toxin (Bont)  
All With Varying Rates Of Success.



### Postsurgical complications include:-

- ❖ Lesion recurrence.
- ❖ Sensory deficits of the tongue.
- ❖ Damage to Wharton's duct.

### Frequency of recurrence is related to the surgical technique selected and has been reported as

- 67% with marsupialization,
- 58% with excision alone,
- 1% with sublingual gland excision.

## Autoimmune diseases

Autoimmune diseases represent a diverse family of conditions characterized by an immune-mediated response against self.

Over 100 distinct autoimmune diseases have been described, showing a wide spectrum of manifestations from organ-specific autoimmunity (such as primary biliary cirrhosis) to organ-specific with systemic manifestations (such as Sjogren syndrome) to multiorgan systemic disease (such as SLE).

**A common pathogenetic mechanism in all these disorders is the breakdown of immune tolerance.**

Following a break in tolerance, autoreactive T lymphocytes and/or autoantibodies trigger autoimmunity in one target organ or in multiple tissues. However, while a combination of genetic susceptibility and environmental triggering is thought to underlie the pathogenesis of all autoimmune disorders, triggering and pathogenesis of specific autoimmune diseases are generally incompletely understood.

Some disorders lead to organ specific damage, others exhibit widespread systemic autoimmunity.

Similarly, while disease is mediated by autoantibodies with well-defined specific roles in some cases (such as pemphigus), others may be characterized by diverse autoantibodies with unclear roles and/or T cell-mediated immune damage.

The orofacial area, and in particular the oral mucosa and the salivary glands, is affected by multiple autoimmune diseases, either

- Directly as a manifestation of their clinical phenotype,
- Indirectly due to possible comorbidities
- Adverse effects of the medications used for treatment.

Disease	Target Organ(s)	Main Autoantibodies	Histopathologic Findings (in the Orofacial Area)	Other Laboratory Findings	Orofacial Manifestations
Lupus erythematosus	SLE: Multiple organs	SLE: ANA (>95%) anti-ds-DNA (43-92%) anti-nucleosome (59-62%) anti-Sm (15-55%) anti-Ro (36-64%) anti-La (8-33%) anti-U1-RNP (23-49%) anti-phospholipids (30-40%)	Subepithelial and perivascular lymphocytic infiltrate with degeneration of the basal cell layer Direct immunofluorescence shows IgG, IgM, and complement deposition in the basement membrane SLE: Positive lupus band test	SLE: Anemia, leukopenia, thrombocytopenia, elevated ESR, hypocomplementemia	Ulcerative, atrophic/erythematous and/or white striated/radiating lesions of the oral mucosa (discoid lesions) Lupus cheilitis (rare malignant transformation) Butterfly rash or other erythematous lesions affecting the facial skin
Systemic sclerosis	Multiple organs, including skin	ANA (up to 96%) anti-Scl70 (up to 41%) ACA (up to 37%) anti-RNA polymerase III (up to 19%) anti-Th/To (up to 3%) anti-Pm/Scl (up to 13%)	Extensive dense collagen deposition in connective tissue	Various hematologic abnormalities (e.g., elevated ESR, hypergammaglobulinemia)	Mask-like face, reduced mouth opening (microstomia), telangiectasias, temporomandibular disorders, resorption of posterior mandible, diffuse widening of periodontal membrane, other comorbidities (periodontal disease, xerostomia)
Rheumatoid arthritis	Joints	Anti-CCPs (ACPs) (up to 70%) RF (up to 70%) ANA (up to 60%)	Hyperplasia of the synovial cell lining Dense subacute inflammation of the synovial membrane Rheumatoid granulomas in skin lesions	Elevated ESR and CRP	TMD, TMJ radiographic abnormalities, periodontal disease, xerostomia (in cases of secondary Sjögren syndrome)
Dermatomyositis	Skeletal muscles and skin	ANA (up to 80%) Anti-Mi2 anti-NXP2 anti-TIF1 anti-Jo1	Perifascicular atrophy Interface mucositis/dermatitis in mucocutaneous lesions	Elevated creatine kinase, aldolase, alanine aminotransferase, aspartate aminotransferase, lactate dehydrogenase	Dental and periodontal disease, TMD, telangiectasias, lichenoid lesions
Mixed connective tissue disease	Multiple organs	ANA (up to 100%) anti-U1 RNP (up to 100%) RF (up to 50%)	Overlapping with other connective tissue diseases	Anemia, leukopenia, thrombocytopenia	Trigeminal neuropathy and other overlapping manifestations
Granulomatosis with polyangiitis	Multiple organs (mainly upper and lower aerodigestive tract and kidneys)	ANCA including: PR3-ANCA (c-ANCA) (up to 95%) MPO-ANCA (p-ANCA)	Small-vessel necrotizing vasculitis with granulomatous features	Anemia, leukocytosis, eosinophilia, elevated ESR and CRP	Oral ulcerations, gingival involvement ("strawberry gingivitis"), destructive lesions (palatal perforation), salivary gland enlargement

## Sjogren Syndrome (SS)

is an **Autoimmune Disorder** in which immunocytes damage the **Salivary, Lacrimal, And Other Exocrine Glands** and is thus termed an autoimmune exocrinopathy.

**Dry Mouth And Dry Eyes** are seen with **Lymphoid Infiltrates** in these and **other Exocrine Glands and Serum Autoantibodies**.

**Sjogren syndrome has two major clinical forms:**

❑ **Primary Sjogren Syndrome (SS1)**, in which dry eyes and dry mouth are seen in the absence of a connective tissue disease.

❑ **Secondary Sjogren Syndrome (SS-2)**, which is more common, in which **Eyes And Dry Mouth** are seen together **With Other Autoimmune Diseases**, usually of **connective tissue**—most usually **Rheumatoid Arthritis (RA), SLE, Polymyositis, Scleroderma, Or Mixed Connective Tissue Disease**.

However, Sjogren syndrome shows a wide spectrum of clinical manifestations and new diagnostic criteria tend not to distinguish between the two clinical forms.

**SS is now considered the 2<sup>nd</sup> most common autoimmune disease after Rheumatoid Arthritis.**

**Dryness may also affect other mucosal areas** such as the **skin, nasopharynx, throat, trachea, and vagina**.

**Signs of systemic autoimmune disease** with **musculoskeletal, pulmonary, gastric, hematologic, dermatologic, renal, hepatic, and neurologic manifestations** may also be evident in patients with SS.

SS patients also frequently experience **Fatigue, Arthralgias, Myalgias, Peripheral Neuropathies, And Dermatoses**.

### Oral manifestation of Sjogren's syndrome

- **Xerostomia is A major complaint.**
- **Unpleasant taste**
- **Difficulty in eating .**
- **Pus may be emitted from the duct .**
- **Angular stomatitis and denture stomatitis also occur .**
- **Unilateral or bilateral enlargement of parotid gland.**
- **In advanced cases , the mucosa is glazed , dry and tends to form fine wrinkles .**

### • The tongue typically develops a characteristic

**Lobulated**

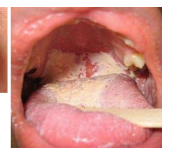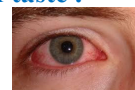
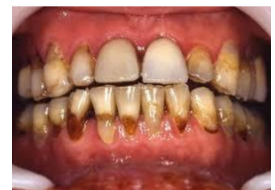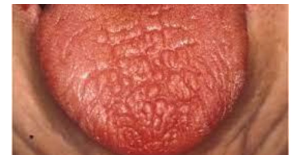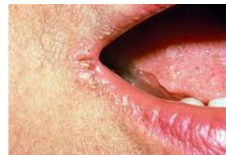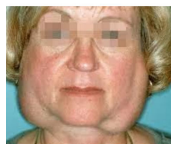**Red Surface With Partial Or Complete Depapillation .**

- **There is also decrease in number of taste buds , which leads to an impaired sense of taste .**
- **Dental caries is sever and gross accumulation of plaque .**
- **Periodontal disease can also occur .**

- **The Regional lymph node may be enlarged and tender .**

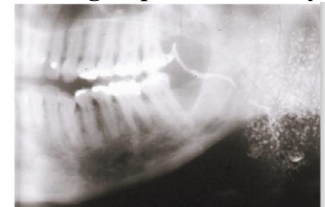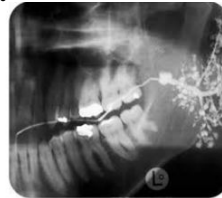**Retrograde salivary gland infection due to stasis, inflammation, or obstruction due to sialolithiasis or mucus plugging can all result in glandular swelling.**

Finally, glandular swelling may represent a lymphoma; 5–10% of patients with SS will develop this malignancy, most commonly a mucosa-associated lymphoid tissue (MALT) lymphoma.



### Diagnosis of Sjogren's syndrome

- ◆ By measuring lacrimal function, Schirmer's test.
- ◆ Quantifying salivary function.
- ◆ Labial minor salivary gland biopsy.
- ◆ The presence of **Autoantibodies Against anti-ss-a (or) and anti-ss-b.**
- ◆ Sialography the most typical finding is a **Snowstorm Appearance** as a result of leakage of contrast medium.
- ◆ Salivary scintiscanning with technetium pertechnetate may be useful in demonstrating impaired salivary function.



### Management of Sjogren's syndrome

- \*Ocular Lubricant, (artificial tear drops).
- \*Salivary Stimulant ( Bromhexine , Pilocarpine And Cevimeline )
- \*Topical nonsteroidal anti-inflammatory drugs.
- \*Hydroxychloroquine.
- \*Immuno- suppressive agents:-  
(cyclophosphamide, azathioprine, methotrexate, leflunomide, mycophenolate mofetil).
- \*Biological Therapies (rituximab, abatacept, belimumab).
- \*Oral Hygiene Maintenance.
- \*Salivary Substitute (Artificial Saliva).
- \*Topical corticosteroids,
- \*Topical cyclosporine .
- \*Oral glucocorticoids.

### Systemic Sclerosis (SSC) or Scleroderma

The word "**scleroderma,**" originating from the Greek **Scleros And Derma** meaning **Hard Skin**, is considered an umbrella term characterizing a diverse group of disorders that **exhibit excessive cutaneous fibrosis.**

#### Major disease subsets

- Localized Scleroderma (LSC), which is **Limited To Skin Involvement.**
- Systemic Sclerosis (SSC), a heterogenous disease, which affects a wide range of organs in addition to the skin, leading to significant morbidity.

SSC presents with diverse manifestations and is subclassified into multiple subsets of disease.

In contrast, diffuse cutaneous SSC involves the proximal limbs or trunk, with a short history of Raynaud's phenomenon and frequent renal or cardiac involvement as well as lung fibrosis.

In both entities, **women are more commonly involved** than men and a racial predisposition for Caucasian populations has been reported.

#### Pathogenesis

The pathogenesis of SSC is incompletely understood.

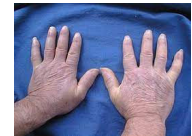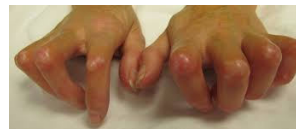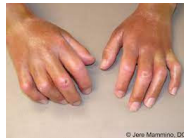- Immune Activation,
- Vascular Damage,
- Excessive Synthesis Of Extracellular Matrix are all well-appreciated features of the condition.

(Most hypotheses of the pathogenesis of SSC focus on the **interplay between early immunologic events and vascular changes, which result in the generation of a population of activated fibroblasts generally considered to be the **effector cell in the disease.****

## Clinical Features

### Cutaneous Manifestations

- **Skin Thickening** Is the hallmark of cutaneous involvement in SSC.
- **Skin involvement** may be of acute onset in diffuse SSc or more slowly growing in limited SSc.
- **The Extremities And Especially The Fingers** may be affected, causing a **“Puffy” Appearance**; progressively, the thin overlying skin becomes prone to **Ulceration** and, in advanced stages, **deformities may occur (“sclerodactyly”)**
- On rare occasions, **Calcifications Of The Skin** may occur with the clinical presentation of **Multiple Subcutaneous Nodules**.
- **Hypo- Or Hyperpigmented Areas**
- **Telangiectasias** may be observed.



### Other Manifestations

SSc is characterized by multiorgan involvement manifesting with various signs and symptoms and occasionally significant morbidities.

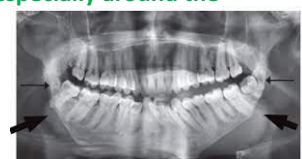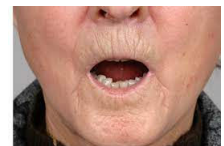- **Raynaud’s phenomenon** is the most common initial sign, developing simultaneously or prior to cutaneous involvement.
- **Musculoskeletal Involvement** takes the form of **Generalized Arthralgias And Morning Stiffness** resembling RA.
- **Myopathy** is also common and is accompanied by elevated serum muscle enzymes.
- The upper or lower gastrointestinal tract may be affected with **Dysfunction In Motility** or **Gastroesophageal Reflux**, while, during late stages, **Fibrosis Of The Gastrointestinal Tract** may result in **Malabsorption**.
- **Pulmonary Complications** Including **Interstitial Lung Disease** and **Pulmonary Hypertension** are also common and associated with morbidity and mortality.

- **Inflammatory Processes May Involve The Heart**, causing **arrhythmias, hypertension, pericardial effusions, conduction defects, or “patchy fibrosis” of the myocardium**.
- **Finally, Renal Involvement Is Common and, before the initiation of angiotensin-converting enzyme inhibitors, was the most common cause of death in SSc patients.**
- **Renal Crisis is most commonly encountered in patients with early onset of diffuse scleroderma.**

### Oral Manifestations

The orofacial area may be involved in a similar pattern to other anatomic areas of SSc patients.

- **The Lips Become Rigid**, which, in addition to the generalized skin sclerosis, results in a **mask-like appearance of the face** .
- **Mouth Opening is significantly Decreased (Microstomia)**
- **The Tongue Becomes Hard**, leading to **Difficulties In Speech And Swallowing**.
- **Telangiectasias** are also frequently present.
- **Temporomandibular Disorders** are also commonly encountered.
- ❑ **Mandibular movement may be limited secondary to muscular fibrosis.**
- ❑ **Myofascial pain, especially involving the masseter and posterior belly of the digastric muscle, feeling of locked jaw, and arthralgia are common symptoms in SSc patients.**
- **The jaw bones exhibit clinical and radiographic findings in SSc patients.**
  - ❖ **Mandibular Resorption, either at the Angle Of The Mandible, Condyles, Coronoid Processes, or Digastric Region, is a result of masticatory muscle involvement .**
  - ❖ **Additional radiographic signs include widespread Widening Of The Periodontal Membrane, especially around the posterior teeth , or soft tissue calcifications mimicking intraosseous lesions.**
- **Periodontal Disease, Xerostomia, And Susceptibility To Local Infections.**





### **Laboratory Findings**

The following routine laboratory tests are recommended in patients with suspected SSC:

- **CBC and differential, which may reveal anemia due to malabsorption of iron or gastrointestinal blood loss.**
- **Serum creatinine level, which may indicate renal dysfunction.**
- **Creatine kinase (CK), which may be elevated in patients with myopathy or myositis.**
- **Urinalysis.**

**The following serologic tests may support the diagnosis if positive:**

- **Anti-Nuclear antibody (ANA).**
- **Anti-Topoisomerase I (Anti-SCL-70) Antibody.**
- **Anticentromere antibody (ACA).**
- **Anti-RNA polymerase III antibody.**

### **Diagnosis**

Diagnosis is made upon exclusion of similar entities that could justify the clinical manifestations.

Skin sclerosis of the fingers of both hands extending proximal to the metacarpophalangeal joints is by itself sufficient for classification as SSC, while other clinical or serologic features are helpful classification criteria.

### **Management**

Treatment of SSC aims at limiting the inflammatory process that characterizes its clinical phenotype as well as managing the distinct clinical manifestations involving separate organs.

**The selected treatment is also based on the stage of disease and possible morbidities.**

**Based on the most recent recommendations,**

- **Immunosuppressants Including Methotrexate** have been used for SSC treatment, especially for Diffuse Skin Manifestations Or Lung Disease.
- **Additionally, Hematopoietic Stem-cell Transplantation** may be the treatment of choice in selected patients with Progressive Disease.

Even though oral complications of SSC may respond to systemic therapy, especially with early intervention, management of specific manifestations may be essential.

- **Limited Mouth Opening should undergo Several Stretching Exercises** that have been reported to be effective.
- **Periodontitis Or Dry Mouth And Its Sequelae or adverse effects of treatment** should be managed appropriately.

SSC exhibits a variable prognosis that depends on the extent and severity of organ involvement.



## Dermatomyositis (DM) and Other Inflammatory Myopathies (IMS)

are a complex group of diseases falling under the term “myositis,” generally characterized by **Inflammatory Processes Involving The Muscles ,In Addition To Extra-muscular Manifestations.**

Myositis may involve

- **Adults**
- **Or Juveniles** and may present heterogeneous manifestations, justifying its subclassification into various separate entities.

Dermatomyositis (DM) is one of the main disease subsets characterized by

- **Skin Involvement**
- **Progressive Muscle Weakness.**

DM is also the most prevalent myopathy in young patients (juvenile DM), while occasionally amyopathic forms may develop, which are considered by some authors as separate disorders (amyopathic DM).

IMS presenting distinct demographic, clinical, or pathologic features are

- **Inclusion Body Myositis**
- **Immune-mediated Necrotizing Myositis.**

As observed in other autoimmune diseases, IMS may also exhibit accompanying features shared with other connective tissue diseases, for which the term overlap myositis is used.

**Myositis may be associated with malignant neoplasms (cancer-related myositis),** as supported by the high incidence of cancer in DM patients.

Other uncommon types of myopathy have also been described, while cases of muscle involvement that do not exhibit specific features observed in other myopathies fall under the term polymyositis (PM).

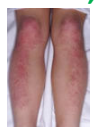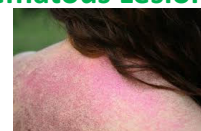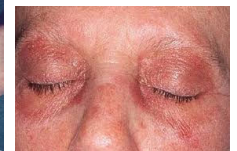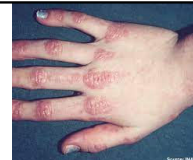### Clinical Features Dermatomyositis

is characterized by varying amounts of

- **Muscle Weakness**
- **With Symmetric Distribution And Cutaneous Involvement.**
- ❖ **Muscle involvement** may range from **Mild To Severe** causing serious disabilities.

The most pathognomonic clinical sign in DM is the presence of a

- **Papular Violaceous Rash Affecting** the **Metacarpophalangeal And Interphalangeal Joints,** Also Known As **Gottron’s Papules.**
- A highly characteristic **Cutaneous Manifestation** is the so called **Heliotrope Rash (Discoloration Of The Periorbital Area),**
- while other typical lesions include the **Gottron Sign (Erythematous Lesions Of The Elbows, Knees, Or Ankles),**
- **The V Sign (Erythema In The Face, Neck, And Chest Area),**
- **The Shawl Sign (Affecting The Neck And Shoulders).**



**Juveniles** more commonly develop **febrile illness as well as calcinosis of the skin.**

Besides other more uncommon cutaneous signs,

**DM may develop Extra-muscular And Extra-cutaneous Manifestations,** especially **Cardiac Involvement As Well As Interstitial Lung Disease.**

## Oral Manifestations Of Patients With IMS.

- ❑ An increased number of decayed, missing, or filled teeth has been attributed to poor oral hygiene.
- ❑ Decrease in masticatory forces and increased incidence of temporomandibular disorders (TMDs) has been reported.
- ❑ Mucosal involvement is also reported in patients with PM and DM, most frequently in the form of **Telangiectasia**.
- ❑ **Specific gingival lesions** have been described in patients with juvenile DM, described as having a "Bushy Loop"

### Appearance.

- ❑ **Lichenoid lesions** have also been reported to affect patients with DM.
- ❑ **Malignant neoplasms** may be associated with DM and **oral cancer cases** have been reported in patients with DM, even though an exact causal relationship cannot be established.
- ❑ **Fibrosis of the salivary glands** is a common finding, while **calcinosis of the soft tissues in juveniles** can affect the head and neck region and be radiographically detectable.

### Pathologic Features

- **Histopathologic examination of muscular tissue** in patients with IMs may be helpful in establishing the diagnosis
- **Direct immunofluorescence** could facilitate diagnosis in equivocal cases exhibiting a granular deposition of immunoglobulins and complement in the dermo-epidermal junction.

### Laboratory and Other Findings

The main laboratory feature in IMS is the presence of

- ❑ **Elevated Muscle Enzymes, Especially CK**, which also helps determine disease activity in individual patients.
- ❑ **Electromyographic examination** is a routine test that facilitates diagnosis, showing features of myopathy.
- ❑ **Autoantibodies** (e.g., DM associated with **anti-MI2** as well as **anti-NXP2 antibodies**, while **anti-JO1** antibodies are found in overlap myositis) and specific manifestations (e.g., **anti-TIF1** in DM is strongly associated with cancer involvement).

### Diagnosis

- **Clinical, Laboratory, Histopathologic Manifestations.**

## Management

- **Corticosteroids**
- **Physical exercise,**
- **Steroid-sparing immunosuppressive agents (including Azathioprine And Methotrexate).**
- **Intravenous Immunoglobulins**
- **Biologic Agents may be used in severe cases,**
- **while in patients exhibiting dysphagia invasive management or Injection Of Botulinum Toxin is proposed.**
- **Plasmapheresis may also be performed in patients with interstitial lung disease.**
- **Oral manifestations of DM should also be managed accordingly.**
- **Dental, periodontal conditions, and TMD require appropriate treatment, while appointments should be short for patients with muscle weakness of the neck.**
- **Follow-up of these patients is essential to control dental and periodontal health as well as to identify early signs of cancer.**

## Prognosis

Depends on the

- ❑ **Onset Of Treatment**
- ❑ **Severity Of Organ Involvement.**

Patients with cancer development, esophageal involvement, cardiovascular disease, or pulmonary dysfunction have a poor prognosis, while the main causes of death include respiratory or cardiac complications, infections, and cancer.

**Granulomatosis with polyangiitis (GPA),  
Wegener's Granulomatosis**

is an autoimmune disease classified under the broad category of **ANCA-associated Vasculitis (AAV)** due to the pathogenetic association with **Antineutrophil Cytoplasmic Antibodies (ANCA)**s).

- The hallmark of the disease is the presence of **small-vessel necrotizing vasculitis with granulomatous features**, resulting in **multisystemic manifestations** with significant morbidity and mortality.
- Older patients with a mean age of more than 60 years are typically affected,
- Caucasians are more susceptible
- Equal distribution between the two sexes is observed.

**Pathogenesis**

The exact etiology of GPA development has not yet been fully elucidated. As observed in other

- Autoimmune diseases,
- Environmental
- Genetic factors
- Exposure to external triggers, such as dust or silica
- Infectious agents, such as *staphylococcus aureus* of the upper aerodigestive tract.
- Drugs may also cause AAV-like phenomena with distinct features.

**Responsible agents for drug-induced AAV include**

- Antibiotics,
- Antithyroid Medications,
- Anti-TNF Agents

## Clinical Features

❑ A wide spectrum of manifestations has been described in GPA with varying degrees of organ involvement.

✓ Limited Disease

The upper aerodigestive tract is the site of involvement.

✓ Generalized Forms

have been associated with major organ dysfunction as well as deteriorating general health.

Additionally, nonspecific constitutional signs and symptoms including **Fever, Fatigue, And Weight Loss** are commonly encountered (in approximately half of cases) in generalized GPA. **The Ear, Nose, And Throat (ENT) Region Is Considered The Most Commonly Involved, Especially In Limited Disease.**

Signs may include **Rhinorrhea With Hemorrhagic Crusts, Deformities Of The Nose (Scooped-out Or Depressed Appearance), Perforation Of The Nasal Septum, Sinusitis, Chronic Otitis Media, And Tracheal Or Subglottic Stenosis.**

**Nasal-sinus Involvement** is very characteristic of GPA and may be the only sign, while **Nasal Obstruction With Olfactory Dysfunction** is commonly the first manifestation.

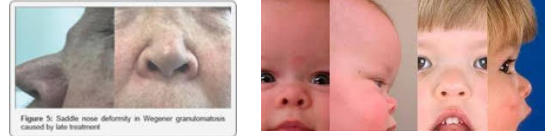

Figure 5: Saddle nose deformity in Wegener granulomatosis caused by late treatment

## Other target organs are commonly affected.

More specifically,

- **The Lungs** are frequently involved, with alveolar hemorrhage as well as parenchymatous nodules being the most significant pulmonary lesions in GPA.
- **Necrotizing Glomerulonephritis** is a characteristic renal sign that is associated with microhematuria and proteinuria; noticeably,
- **The Nervous System** may also be affected
- **Necrotizing Nodular Episcleritis** is considered the most common **Ocular Sign** in GPA, while corneal ulcerations, scleritis, and retinal vasculitis may also be observed.
- **Cardiac Manifestations** may be a result of the necrotizing vascular changes.
- **Finally, the Gastrointestinal Tract** is commonly affected by ulcerative lesions, often resulting in **Perforation.**

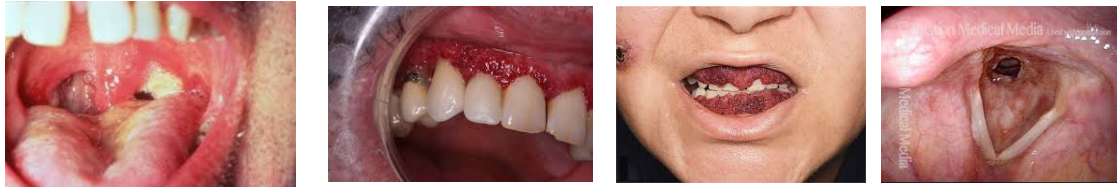## Mucocutaneous manifestations

- Purpura
- Cutaneous Ulcerations,
- Subcutaneous Nodules,
- Pyoderma Gangrenosum Are Common Cutaneous Manifestations,

Oral mucosal involvement also exhibits heterogeneous manifestations that may vary depending on the clinical course of the disease.

Acute and rapidly progressing lesions are observed in widespread disease, including

- Oral Ulcerations With Occasional Necrotic Features,
- Chronic lesions with gradual deterioration and destruction of hard and soft tissues are observed in localized disease.
- Perforation of the palate may be observed,
- Involvement Of The Gingiva may exhibit a characteristic Vegetating Or Granular Appearance, Called "Strawberry Gingivitis,"
- The salivary glands may be involved in GPA showing enlargement, with the parotid being the most commonly affected major salivary gland, sometimes preceding involvement of other organs.



## Laboratory Findings

Anemia, Leukocytosis, And Eosinophilia may be observed in GPA.

ESR and CRP may also be elevated, especially in active disease, while involvement of specific organs may be associated with respective laboratory findings (e.g., urine Proteinuria In Kidney Involvement).

The most important serologic marker for GPA is ANCA, although it is not necessary for diagnosis, which is primarily based on Clinicopathologic Correlation.

Both Indirect Immunofluorescence, which may identify cytoplasmic c-ANCA (most common in GPA) or perinuclear p-ANCA, and Enzyme Immunosorbent Assays (ELISA), which measure PR3-ANCA and MPO-ANCA titers, have been traditionally used with significant sensitivity and specificity.

## Diagnosis

- Clinical Include Oral, Nasal, Pulmonary, And Renal Manifestations,
- Histopathologic Features,
- ANCA Serology May Be Indicative.

## Management

The major aim of treatment for patients with GPA is to achieve remission and survival by minimizing recurrences and fatal outcomes.

The First Phase Of Treatment, consisting of

- Immunosuppressive Therapy (Including Cyclophosphamide And Rituximab)
- In Addition To Glucocorticoids,

The Second Phase (Remission Maintenance).

The initial therapeutic approach is usually individualized and depends upon the severity of disease and patient's general health.

Although the aforementioned therapeutic approaches have minimized morbidity and mortality, GPA may be associated with relapses and life threatening complications.

Limited ENT involvement and granulomatous inflammation upon biopsy have been associated with recurrences, while the severity of renal involvement is a major prognostic factor.

The most common causes of death are infections and kidney failure.

## Mixed Connective Tissue Disease

This Term is used for cases presenting clinical manifestations in the spectrum of SLE, Sjögren syndrome, as well as inflammatory myopathies (IMS).

### Pathogenesis

The cornerstone in the pathogenesis of MCTD is the presence of the anti-ribonucleoprotein (RNP) antibodies. A proposed hypothesis is that a genetic predisposition and especially the presence of distinct subsets of HLAs may play a key role.

More specifically, several studies have linked MCTD with the presence of HLA DRB1\*04, which seems to generate anti-U1-RNP expression.

### Clinical Features

Clinical manifestations identical to various connective tissue diseases are present, including

Raynaud's Phenomenon, And "Puffy" Or Swollen Hands, Myositis, Arthritis, Interstitial Lung Disease, Pulmonary Hypertension, Cutaneous Lesions And Alopecia, Esophageal Dysmotility, Neurologic Symptoms, As Well As Renal Disease.

Orofacial involvements of MCTD have rarely been reported.

Trigeminal Neuropathy is the most common manifestation.

signs or symptoms characterizing the phenotype, including Xerostomia, Lymphadenopathy, Or Lichenoid Lesions, may be observed.

Additionally, patients receiving high-dose immunosuppression could develop oral mucosal lesions as an adverse effect.



### Laboratory Findings

- Autoantibodies against the U1 small nuclear ribonucleoprotein autoantigen (U1-snRNP) are considered specific markers for an MCTD diagnosis
- ANAs are also expressed in almost every case.
- Other hematologic findings include anemia, leukopenia, and thrombocytopenia.

### Diagnosis

- Immunologic (Anti-u1-rnp Detection)
- Clinical Parameters.

### Management

- ✓ Immunosuppressants, Especially Corticosteroids,
- ✓ As Well As Steroid-sparing Medications, Such As Methotrexate, Cyclosporine, And Azathioprine.
- ✓ Further, specific manifestations (including Raynaud's phenomenon) should be treated accordingly (e.g., with calcium-channel blockers).

### Prognosis

MCTD presents a measured mortality rate of 8–36%, with common causes of death being related to pulmonary hypertension and interstitial lung disease.

### Rheumatoid Arthritis

RA is a chronic inflammatory autoimmune disease that is characterized by symmetric involvement of joints in a progressively destructive manner, which can cause significant disability if not properly treated.

Besides musculoskeletal disease, other extra-skeletal manifestations, as well as constitutional symptoms, may be observed.

RA involves patients in their Middle Age With A Female predominance (2:1 to 3:1).

### Pathogenesis

#### (Genetics and Environment)

- The cause of RA remains unknown. As with other autoimmune diseases,
- A combination of host genetic and environmental factors is thought to underlie disease triggering.
- In RA immune cell infiltration of the synovial membranes of joints with T cells, B cells, monocytes, and neutrophils leads to inflammation of synovial membranes, "Pannus" Formation, and Subsequent Bone And Cartilage Erosion.
- Inflammatory mediators such as tumor necrosis factor (TNF) and IL-6 as well as Janus kinase (JAK)-STAT cytokine mediated immune responses are clearly involved in disease activity.
- A genetic predisposition has clearly been defined in RA. Most significantly associated with RA are HLA class II antigens, such as HLA-DRB1\*01 and HLA-DRB1\*04.
- Epigenetic modifications may be observed including modified DNA methylations, histone acetylation, as well as microRNA differential expression.
- Finally, Environmental Triggers including smoking, alcohol consumption, socioeconomic level, and infectious agents, such as periodontal pathogens, have been associated with the development of RA.

## Clinical Presentation

The most common and significant manifestation of RA is the development of **Symmetric Polyarthritis With A Migratory Character** and **Gradual Increase Of Disease**.

The inflammatory process primarily involves

the **Wrists And Metacarpophalangeal, Metatarsophalangeal, And Proximal Interphalangeal Articulations**.

Accompanying **Morning Stiffness Lasting From 30 Minutes To Several Hours** is also common.

The fingers are affected in a fusiform pattern, mainly around the joints, in contrast to psoriatic arthritis where the **Whole Digit Is Swollen ("Sausage Digit")**.

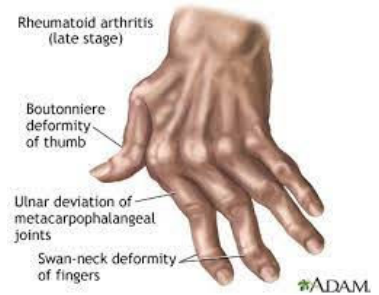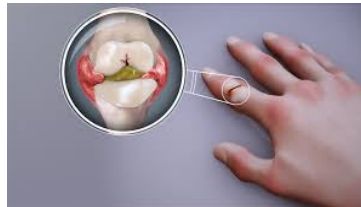If RA is insufficiently treated, extra-skeletal manifestations may develop.

The Occurrence Of Firm Masses Called Rheumatoid Nodules, especially in

**Subcutaneous areas in proximity to bony prominences**, is the most frequent finding.

Severe complications may also develop, such as

- **Necrotizing Vasculitis Of The Small And Medium-sized Arteries.**
- **Interstitial Lung Disease.**
- **Cardiovascular Disease.**



## Intra- and Extraoral Manifestations

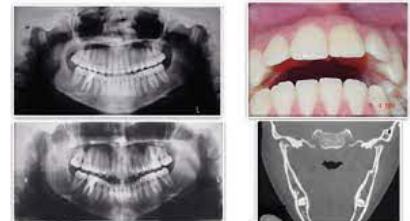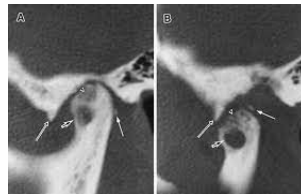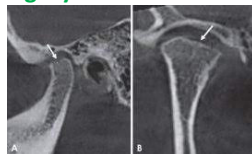
The **TMJ** is involved in almost every patient with RA according to the **Helkimo-index**.

Various clinical signs or symptoms of TMJ involvement, such as

- ❑ **Pain (Frequently elicited by pressure on the joint),**
- ❑ **Creptitation,**
- ❑ **Reduced mouth opening,**
- ❑ **Impaired movement, have been described in ra patients.**
- ❑ **In Advanced Stages**, progressive **condylar destruction** may cause **malocclusion and anterior open bite, joint ankylosis, and facial asymmetry.**

Additionally, Radiographic Signs may be observed (on Routine TMJ Radiographs, CT or Cone-beam CT (CBCT) Scans, And Other Imaging Modalities), including

- **Modifications In Cortical Integrity.**
- **Erosions.**
- **Diminished Joint Spaces.**
- **Condylar Asymmetry.**
- **Flat Condyles.**
- **and Subcortical Cysts.**



Finally, oral side effects of systemic medications used to treat RA have been reported.

Besides affecting the TMJ, RA may show several other manifestations in the orofacial area.

**Cases of simultaneous (Secondary) Sjögren Syndrome** are associated with **hyposalivation**, causing the subjective symptom of **xerostomia** and susceptibility to local infections (**primary dental caries** and **candidiasis**).

The relationship of RA with dental and periodontal disease has been widely studied.

**Increased prevalence and severity of periodontal disease** have been documented in RA patients, even in those newly diagnosed.

## Diagnosis

Diagnosis is primarily made by evaluation of

- **Clinical**
- **Immunologic Findings.**

### Laboratory Findings

Typically, the main laboratory findings in patients with RA include acute-phase reactants and autoantibodies.

**CRP and ESR are the most significant markers used to detect inflammatory responses**, with the former being more specific in measuring disease activity due to its association with inflammatory cytokines expressed in RA.

The main autoantibodies used for diagnosis of RA are

- **Cyclic Citrullinated Peptides (Anti-CCP)**
- **And Rheumatoid Factor.**
- Additionally, antibodies that may be detected in other autoimmune diseases, including
- **ANA**
- **Anti-DSDNA**, may also be positive in RA.

## Management

- Initial-phase treatment for RA typically involves

**Methotrexate** (used as monotherapy or in combination with **Corticosteroids**), which is considered an efficient treatment for RA and is associated with few and easily controllable adverse effects.

- Symptomatology may also be improved by other drugs including **Nonsteroidal Anti-inflammatory Drugs (NSAIDs)**, should be used as supplementary therapy before a definite diagnosis of RA is established.

- Disease-modifying Antirheumatic Drugs (DMARDs), Such As **TNF Inhibitors, IL-6 Inhibitors**, and **Small-molecule Inhibitors Of Jaks** involved in cytokine signaling.

- Oral manifestations of RA should also be treated accordingly. Even though oral manifestations may respond to the aforementioned systemic treatments, management of specific disorders is essential.

- When the TMJ is affected, treatment ranges from

### ✓ Conservative

❖ **NSAIDs.**

❖ **Physiotherapy.**

❖ **Occlusal Splints.**

❖ **Local Injections of Corticosteroids Or Anesthetics.**

✓ **Surgical Reconstructive Therapy** in cases with significant defects.

- Finally, (Sjogren Syndrome, Periodontal Disease, Or Oral Complications Of Systemic Therapy) Should Be Managed Appropriately.

## Systemic Lupus Erythematosus

SLE is considered a prototypic **autoimmune disease** characterized by a **wide spectrum of clinical manifestations** and an often unpredictable **relapsing–remitting course**.

Patients can present with variable clinical features ranging from **mild joint and skin disease to multiorgan life-threatening renal, hematologic, and CNS involvement**.

### The etiology and pathogenesis of SLE

- **Unknown.**
- **Genetic predisposition, combined with environmental**
- **Hormonal factors ultimately predisposes to disease.**
- **Immune dysregulation** is thought to result from the breakdown in tolerance to self-antigens, leading to excessive inflammation, autoantibody production, and destruction of end organs.

In fact, **Immunologic Anomalies**, particularly production of **Antinuclear Antibodies (ANA)** such as those against **double-stranded (DS) DNA**, are a **hallmark of lupus**.

Diagnosis and management of lupus are particularly complex.

Oral manifestations are a prominent feature that can aid in the diagnosis and should be taken into consideration during management of SLE.

There is unequal distribution between sexes (females are affected **1.2–15** times more than males)

The peak ages of prevalence are

**45–69 For Females**

**40–89 For Males.**

## Clinical Features

### Constitutional symptoms such as

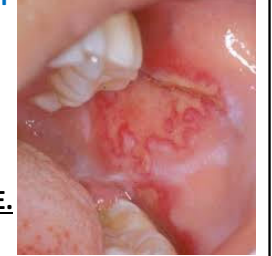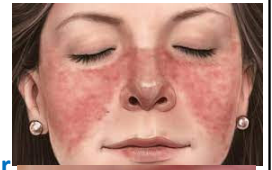- **Fatigue, Headache, Arthralgias, Lymph Node Enlargement, Fever, And Significant Weight Loss,**

### SLE may be characterized by the involvement of various specific organs.

- ❖ **Renal disease, which affects 40–70% of patients.**
- ❖ **The musculoskeletal system is also commonly affected in 93% of SLE cases.**
- ❖ **Arthritis and arthralgias are a dominant feature of SLE. Arthritis, with demonstrable inflammation, occurs in 65–70% of patients and tends to be migratory, polyarticular, and symmetric.**
- ❖ **Cardiovascular manifestations are also common in SLE.**
- ❖ **Atherosclerosis, valvular heart disease, and defective coagulation mechanisms.**
- ❖ **Involvement of the central or peripheral nervous system in SLE.**
- ❖ **Anxiety, mood disorders, psychosis, seizures, headaches, and myelin defects are examples of CNS manifestations in SLE, while various types of peripheral neuropathies have also been described.**
- ❖ **Pulmonary Involvement.**
- ❖ **Gastrointestinal Disease.**
- ❖ **Genitourinary Disorders.**
- ❖ **Ocular Manifestations.**

## Mucocutaneous Manifestations

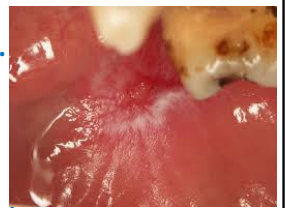- Most lupus patients will develop Cutaneous And Mucosal Lesions during their disease.
- The most common lesion is a facial eruption that characterizes acute cutaneous lupus erythema (also known as the "butterfly rash"), presenting as erythema in A malar distribution over the cheeks and nose (but sparing the nasolabial folds) that appears after sun exposure.
- Some patients may develop discoid lesions, which are more inflammatory, and tend to scar.
- Photosensitivity is also a common theme for skin lesions associated with SLE .



## Oral Manifestations

The oral cavity is commonly affected during both systemic and cutaneous involvement in SLE.

- Typically, Nonspecific Ulcerations And Erythematous Or Discoid Lesions, and predominantly affect the Palatal Mucosa, Buccal Mucosa, And Gingiva
- The vermillion border of the lower lip can be characteristically involved (Lupus Cheilitis).
- The temporomandibular joint (TMJ) can also be affected.
- The oral manifestations of the cutaneous forms of lupus erythematosus (CLE) closely mimic those of Oral Lichen Planus, with characteristic Central Erythematous (Erosive Or Atrophic) areas surrounded by White Radiating Striations
- The most common sites of involvement are the lips (vermillion border and labial mucosa) and the buccal mucosa.
- As well as gingival telangiectasias in SLE, and systemic inflammation.
- On rare occasions, squamous cell carcinoma may arise in discoid lesions affecting the lips.



## ➤ Laboratory findings

- Complete blood count (CBC)
- main manifestations include anemia (mainly related to chronic disease, iron deficiency, or hemolysis),
- Leukopenia (lymphopenia and/or neutropenia), and thrombocytopenia
- ❑ ESR is usually elevated along with normal CRP.

Several autoantibodies have been studied as biomarkers for diagnosis of the disease.

- ❑ ANAS are positive in more than 95% of SLE patients
- ❑ Anti-double-stranded DNA (anti-DSDNA) in approximately 50–70% and anti-smith antigen (anti-SM) in 30–40% antibodies are positive.
- ❑ Antiphospholipid antibodies are associated with thrombocytopenia, thrombosis, atherosclerosis, and abortions.
- ❑ While antiphospholipid syndrome and anti-SM are associated with higher mortality and morbidity).
- ❑ Another serologic finding is the decrease in complement markers (hypocomplementemia), especially CH50, C3, AND C4.

## Diagnosis

Disease Classification.

Clinical Manifestations.

Laboratory findings and histopathological study.

## **Management**

Treating SLE is challenging and depends on the **extent of manifestations**, the **type of target organ(s)**, and the **severity of disease** as well as possible morbidities.

As a result, medications used to treat lupus may range from topical therapy for exclusive cutaneous lesions or nonsteroidal anti-inflammatory drugs for mild musculoskeletal involvement to systemic immunosuppressive therapy.

In addition, possible side effects of the selected medications should be prevented accordingly.

- **Corticosteroids remain the main choice** during management of SLE, due to their effectiveness in limiting disease and flares. However, because of common complications after their long-term use (such as **Diabetes, Infections, Osteoporosis, Hypertension, And Avascular Necrosis Of Bone**), other immunosuppressants have been proposed.
- **Alternative options include Cyclophosphamide, Mycophenolate Mofetil, And Azathioprine**, which should also be used with caution due to their toxic effects.  
Less commonly used immunosuppressive drugs for SLE include **tacrolimus, cyclosporine, and methotrexate**.
- **Hydroxychloroquine, an antimalarial** used in a variety of autoimmune diseases, has demonstrated effectiveness in managing cutaneous lesions as well as constitutional manifestations.
- **Finally, Biologic Agents affecting the B-cell component** of the immune system, including **Belimumab, Rituximab, Ofatumumab, And Atacicept**, are recently used drugs that present efficacy in limiting disease activity.
- **Topical or intralesional administration of corticosteroids** seems to be the first treatment option.



# Facial Pain

**Primary**

**Secondary**

**Atypical**

## Facial Pain

### **Definition of Pain**

**It is unpleasant sensory & emotional experience associated with actual or potential tissue damage.**

**Pain: - is a sensation of suffering resulting from a**

- Noxious Stimulus**
- Physical Disorder**
- Mental Derangement.**

**Pain is a personal experience.**

**\*Communication depended on the  
Expression & Vocabulary of the  
patients.**

**\*Interpretation depended on the  
Experience Of The Clinician.**

**So the pain serve as useful precaution.**

**The pain receptors** is known as **nociceptor** &

The fibers that carrying pain impulses are:

1- A delta fiber → ( 1-4 micrometers, 5-15 m/sec. )

2- C fibers → ( 0.5 -1 micrometer, 0.5-2 m/sec. )

**Pain threshold:**

minimal amount of stimulus require to provoke a painful sensation.

**Pain sensation involve two processes**

**Pain perception:**

is response of the nerve ending organ to stimulus.

**Pain reaction:**

is the response of individual to the painful stimulus & it vary between individuals & vary in the same individual from time to time .

Pain reaction → appreciation in CNS

**in cortex and posterior thalamus.**

### **How to describe pain**

**Examination of pain include questions about the following**

- Character of pain.** → Sharp, Dull, Throbbing, Burning, Electrical shock.
- Severity of pain.** → Mild, Moderate, Sever.
- Date of Onset.** → To see whether the condition is acute or chronic condition.
- Duration of pain.**
- Frequency.**
- Area of radiation.**
- Referred pain.**
- Factor relieving the pain.**
- Factor aggravating the pain.**
- Presence of any associated symptoms.**

**Swelling, Discharge , Bad Taste , Change In Taste (Dysgausa) , Halitosis , Discomfort On Swallowing (Dysphagia) , Any Interference With Mastication.**

**All previous details should be taken, together with through clinical examination to reach the perfect diagnosis.**

Pain is known in medical & dental field as **Neuralgia**

## Neuralgia

is defined as pain corresponding to known anatomical distribution of the nerve.

**There are 3 types of neuralgia**

**1- Primary**

**2- Secondary ( Symptomatic)**

**3- Atypical Facial Pain.**

### **Symptomatic Or Secondary Facial Pain**

Usually a pathological changes can always be found, although with a difficulty in some cases . Examples of changes are:

- \*Infection
- \*Inflammation
- \*Injury
- \*Scar
- \*Allergy
- \*New Growth.

Symptomatic neuralgia has 3 features that differentiate it from primary neuralgia:-

**1 Pain is a mixture of deep and superficial pain which varies in intensity and it's usually continuous but rarely there are remissions periods and frequent exacerbation as well.**

**2There are associated objective signs of interruption of continuity of the nerve such as anesthesia, paresis, muscle wasting, absent reflexes or atrophic changes.**

**3 These signs tend gradually to spread to contiguous area.**

# Secondary neuralgia

Symptomatic neuralgia can be divided into:-

A- Extra cranial.

B- Intra cranial.

## A- Extra cranial

1- Localized facial pain

2- Disease of the sinuses.

3- Disease of the ear.

4- Disease of the TMJ & muscles.

5- Referred & radiating pain.

A- Anginal Pain.

B- Cervical Spondolosis.

C- Cardiac End Of Stomach.

E- Trapezius Muscle Spasm.

6 vascular pain.

A- Giant Cell Arteritis.

B- Migraine Headache.

C- Cluster Headache.

7 Trotters` Syndrome. Cluster Headache ,Migranous Neuralgia , Histamine Cephalgia.

8 Frey's Syndrome.

9 Tension Headache.

## B- Intra cranial

Tumor Of Pituitary Gland, Aneurysm Of Carotid Artery In Cavernous Sinus,  
Vascular Malformation.

Cranial Base Lesion, Paget's Disease.

Clinically Chronic Orofacial Pain may be subdivided into three main symptomatic classes

**1- Musculoskeletal**

**2- neuropathic**

**3- Neurovascular**

Musculoskeletal entities are dealt with Temporomandibular Disorders.

Possible causes of Facial Pain:

- Dental pain
- TMJ
- Neuropathic pain (neuralgias)
- Pathology in related structure .  
(salivary gland , sinus ,eyes , cervical spine, nasopharynx)
- Vascular disorder (headaches)
- Intracranial lesions (neoplasm, Multiple Sclerosis)
- Referred pain (angina pectoris.)
- Psychogenic facial pain.

## A- Extra cranial

### 1- Localized facial pain:-

**Include diseases of the teeth and their supporting structures such as:-**

**A- Focal Reversible Pulpitis.**

**B- Acute Pulpitis.**

**C- Chronic Pulpitis.**

**E- Acute Peri-apical Abscess.**

**F- Chronic Peri-apical Abscess.**

## 2- Disease of the sinuses.

### Sinusitis and orofacial pain

Acute sinusitis, also called acute rhinosinusitis, is a short-term infection or inflammation of the membranes that line sinuses. It prevents mucus from draining from nose.

#### Symptoms of acute sinusitis include

- Nasal Congestion
- Thick, Yellow, Or Green Mucus Discharge From The Nose
- Sore Throat
- A Cough (Usually Worse At Night)
- Drainage Of Mucus In The Back Throat (Post Nasal Drip)
- Headache
- Pain, Pressure, Or Tenderness Behind Eyes, Nose, Cheeks, Or Forehead
- Earache
- Toothache
- Bad Breath
- Reduced Sense Of Smell • Reduced Sense Of Taste
- Fever.

Dull pain, aching or throbbing in several upper teeth, associated with pressure below the eyes and worsen by bending down, applying pressure in the sinuses, coughing, sneezing, Chewing, cold, percussion, worsen the pain, with history of upper respiratory infection, nasal congestion, or sinus problem.

Acute maxillary sinusitis and acute allergic sinusitis cause actual toothache pain in the maxillary teeth particularly when the roots of the teeth extend into or near the anteroom.

When fluid pressure caused by infection or inflammation builds up, the patient will experience tenderness in the cheekbone, facial swelling, throbbing headache, fatigue, runny nose and/or increased pain when the patient tilts his or her head in a downward position.

It rarely involves just one tooth, and should be suspected when multiple teeth test positive to biting and percussion tests.

## Cardiac Toothache (referred pain)

**Angina pectoris or acute myocardial infarction**, refer pain to the

Shoulder,

Arm,

The Jaw And To The Teeth.

Associated With Chest Pain (Substernal),

Toothache increases with exercises and decreased with medication specific for the heart (nitroglycerin).

Treatment is directed to the underlying heart problem, after dental evaluation.

When pain occurs after exertion, cardiogenic etiology should be suspected.

If patients are experiencing a cardiogenic toothache give them an aspirin, and make sure they get to a hospital emergency room immediately.



## 6. Vascular Pain

### A- Giant Cell Arteritis

**Temporal Arteritis** occur most frequently in older persons usually between the ages of (55-80).

It is usually affect women more than men .

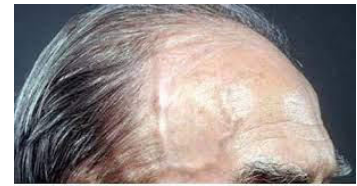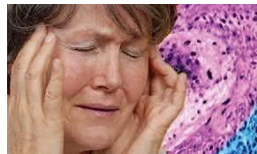**The pain** may be **localized first in teeth, TMJ, scalp or occipital.**

One half of the patients complain of

- Tiredness & Fatigue.
- Pain On Repetitive Chewing (Jaw Claudication -Stopping Of The Mandible )
- Usually there is **localized inflammation** over the swollen ,nodular ,tortuous artery .

#### Diagnosis

- Arterial Biopsy
- ESR & CRP Level
- Ultrasonography
- MRI



Early diagnosis is essential to prevent sever consequence (blindness).

#### Treatment

- Corticosteroid...Prednisolone
- Immunosuppressant Agents ..Azathioprine, Methotrexate & Cyclosporine.
- Interleukin Inhibitors....Tocilizumab (Actemra) Interleukin-6 Receptor Antagonist.
- Antiplatelet Agents ...Aspirin.

## B- Migraine Syndrome

pain characterized by

the sudden onset of recurrent violent unilateral but sometime bilateral ,

Paroxysmal Attack Of Cephalgia Preceded By Visual Disturbance , Irritability , Nausea & Vomiting ( Pre-headache Phase )

### The Different Types of Migraine

- **Migraine With Aura. Classic Migraine.**  
*{prodromal sensory & visual symptom }*
- **Migraine Without Aura. Common Migraine.**  
*{no prodromal sensory & visual symptom }*
- **Chronic Migraine.**
- **Abdominal Migraine.**
- **Acephalgic or Silent Migraine. Migraine Without Head Pain.**
- **Migraine With Brainstem Aura.**
- **Hemiplegic Migraine.**
- **Retinal Migraine. Ocular Migraine**

## ➤ **Migraine With Aura. Classic Migraine.**

starts with a prodromal aura that is usually

- ❖ Visual
  - ❖ Sensory
  - ❖ Motor
- which commonly lasts from 20 to 30 minutes.

**The visual aura** ( commonly precedes classic migraine includes )

- flashing lights
- or a localized area of depressed vision (scotoma).
- Sensitivity to light

**Other Neurologic Symptoms**

- ✓ Aphasia (Impairment Of Language)
- ✓ Vertigo
- ✓ Numbness
- ✓ Weakness

**The aura is followed by**

- Severe Unilateral Throbbing Headache
- Accompanied By Nausea And Vomiting.

The patient characteristically lies down in a dark room and tries to fall asleep.

Headaches characteristically last for hours up to 2 or 3 days

## **Common migraine (Migraine without Aura)**

- ❖ Is not preceded by an aura
- ❖ Patients may experience irritability or other mood changes.
- ❖ The pain of common migraine resembles the pain of classic migraine and is usually unilateral, and associated with Sensitivity to light and noise.
- ❖ Nausea and vomiting are also common.

## The Classic Theory For Migraine

Migraine is caused by vasoconstriction of intracranial vessels followed by vasodilation .

## Newer research techniques

suggest a series of factors, including the triggering of neurons in the midbrain that activate the trigeminal nerve system in the medulla, resulting in the release of neuropeptides such as substance P. These neurotransmitters activate receptors on the cerebral vessel walls, causing vasodilation and vasoconstriction.

## Etiology and Pathogenesis

1 - There appears to be a genetic and familial risk

2- Vascular Theory

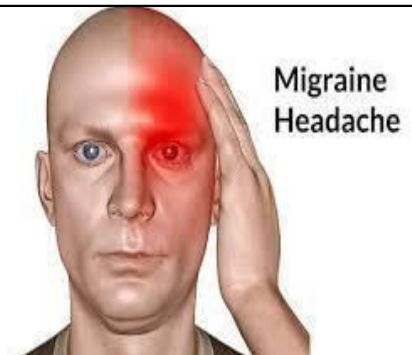The aura of migraine was once thought to be caused by cerebral vasoconstriction and the headache by reactive vasodilation

3- **Neuronal Theory and the Trigeminovascular System**

4- **Role of Serotonin and Dopamine**

Pharmacologic data point to a strong role of the neurotransmitter serotonin in migraine

Most migraine symptoms can be induced by dopamine



## The attack

- begins during the second decade of life
- +ve family history
- Common in professional person .
- It may be triggered by
  - Foods** such as **nuts, chocolate, and red wine**  
(which is rich in tyramine which is the precursor of the serotonin )
  - Stress**
  - Sleep Deprivation Hunger.**
- Migraine is more common in women.
- The headache phase consist of sever pain in the
- **Temporal ,Frontal & Retro-orbital Areas**

## Treatment

The preheadache phase usually respond to

\* **Aspirin (300-900mg).**

\* **Paracetamol (1g)**

\* With or without **antiemetic** such as

Metoclopramide (Plasil 10mg) or Prochlorperazine (Stemetil 5mg).

If migraine attacks occur frequently enough to disturb work & social life

Prophylactic Drugs are indicated such as

Propranolol ( Inderal 40-80mg tid)

Pizotifen (Sandomigran 1.5-3 mg)

Antidepressant Such As Amitriptyline ( Tryptizol 25-100 Mg).

All these agent have some blocking activity on 5 hydroxy-tyramine .

Drugs that are useful in aborting migraine

**Ergotamine Tartrate (Cafergot 1mg).**

The maximum daily does (6mg) & up to(10 mg) per week .

In resistance cases

**Methysergide (1-2mg)**

is often effective but should be given for course of three months & renal function should be monitored.

The Classes Of Medications That Are Effective For Migraine Prevention Include

\*Antihypertensive

Propranolol

Timolol

\*Antiepileptic

Topiramate

Valproic Acid

\*Antidepressants

Tricyclic antidepressant

SSRIs

\*Botulinum Toxin A(Botox)

\*Calcitonin Gene-related Peptide Inhibitors(CGRP)

\*Transcutaneous Electrical Stimulation Device(TENS)

### 3- Horten`s Syndrome , Cluster Headache ,Migranous Neuralgia , Histamine Cephalgia

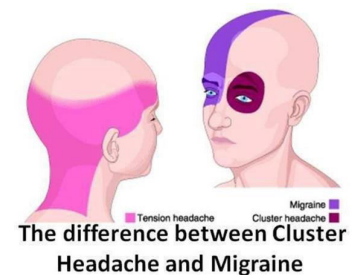
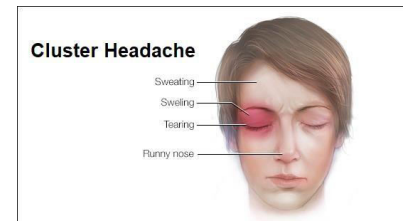
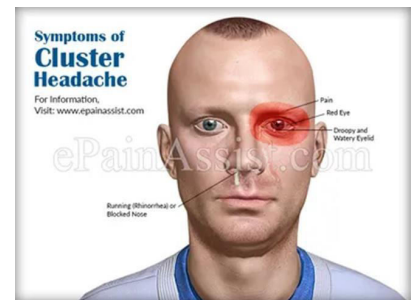The **attack occur in cluster**

**The pain** is unilateral ,**sever** , **knife like** which may **last from 10 mint to 3 hours** .The recurrent attack of knife like pain effect the temporal area unilaterally passing into the **forehead , the side of the head & the shoulder** , it may radiate to the **mandible but not to the tongue or lip** .

The intensity of the pain is so sever that during which the patient can not laying down but prefer to seat or walk.

This **symptoms** occur chiefly in **male over 40 year of age** , it is usually **nocturnal in nature** .

The attack may be precipitated by **alcohol beverages or histamine injection** , these material induce autonomic effects manifested as nasal congestion , lacrimation.



#### Pain in Cluster Headache

is usually periorbital or ocular described as throbbing or burning, stabbing Orofacial Pain or a “stabbing” feeling in the eye. Individuals with CH frequently describe the pain as a **hot metal rod in or around the eye.**

**Pain is most usually accompanied by at least one ipsilateral Autonomic Sign**

- Conjunctival Lacrimation
- Nasal Congestion/Rhinorrhea
- Eyelid Edema
- Forehead/Facial Sweating
- Miosis (constricted pupil)
- Ptosis (droopy eyelid)

## Treatment

There is no cure for cluster headache. The goal of treatment is to

1. Decrease The Severity 2. Shorten The Headache Period 3. Prevent The Attacks.

### Fast acting treatment

\*Oxygen(8L/min for 10 minutes) or 100% by mask

\*Triptans (5-hydroxytryptamine-1 receptor agonists)

Sumatriptan( 6mg subcutaneous or nasal spray 20 mg)

Zolmitriptan

\*Local Anesthesia (intranasal of lidocaine drops)

Lidocaine(intranasal)

\*Dihydroergotamine( IV or IM or 0.5mg intranasal)

\*Indomethacin .

### Preventive treatments

\*Calcium Channel Blocking

Verapamil

\*Corticosteroid

Prednisone

\*Lithium Carbonate.

(Lithobid)

\*Electrical Stimulation Of The Vagus Nerve(VNS)

\*Nerve Block → (Anesthesia & Corticosteroid)

\*Surgical Intervention Have Been Tried , It Includes

→ Trigeminal Sensory Rhizotomy, → Gamma Knife Radio Surgery

→ Decompression Of The Nervus Intermedius .

## **Nasopharyngeal Tumor , Retropharyngeal Tumor , Trotter`s Syndrome**

+Pain is experienced in the

\*Mandible ,

\*Side of the tongue ,

**+With headache in the affected side**

**+Unilateral deafness ,**

**+Deviation of the palate ,**

**+Defective mobility of the soft palate.**

**+There are cervical lymphadenopathy.**

**It is a carcinoma** situated in the **lateral pharyngeal fossa** , they grow beneath the mucosa & extend below the skull involving the maxillary nerve ( at early stage ), other 5th cranial nerve division , 9th nerve , 10th nerve & upper cervical root .

These tumor are highly radiosensitive .



## \* Frey's Syndrome ( Aurico Temporal Syndrome )

This syndrome is associated with

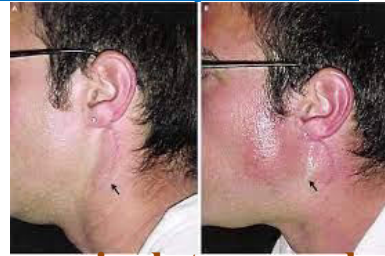**\*Chronic Parotitis.**

**\*Surgery In The Parotid Gland.**

The condition is thought to arise following damage to auriculotemporal nerve which contains postganglionic parasympathetic fiber from otic ganglion , this damaged fiber become united to the sympathetic nerve from the superior cervical ganglion which supply the sweat gland .

### Clinically

there are sweating & flushing of the skin over the distribution of the auriculotemporal nerve take place following stimulation of salivary secretion .



### Symptoms

- **Redness (Erythema)**
- **Sweating in the cutaneous distribution of the auriculotemporal nerve** usually in response to gustatory stimuli.
- **Pain in the same area**, often of a burning nature.
- **“Gustatory Neuralgia”**.

## Causes of Frey`s syndrome

It is generally due to the side effects of a surgery of or near parotid glands or may be due to injury to the auriculotemporal nerve, which passes through the parotid gland.

## Diagnosis of Frey`s syndrome

Diagnosis can be done by the doctor based on symptoms.

## Management

There is no effective treatment, but various options are available :

- **Injection of Botulinum Toxin A**
- **Surgical transection of misdirected nerve fibers (only a temporary treatment)**
- **Application of an ointment containing an anticholinergic drug such as scopolamine**

## Complications

Frey`s syndrome causes hyperhidrosis, excessive perspiration from the skin.

Features include:

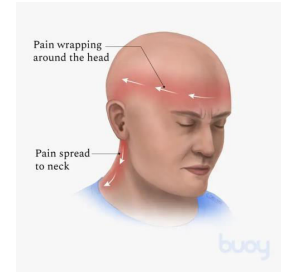
- **Sweating**
- **Skin maceration**
- **Fissuring**

## **Tension Headache**

It is the most common type of headache & is often associated with anxiety state, the pain is constant, dull felt in frontal & occipital like a tight band around the head. The etiology of this headache is muscle tension.

Diagnosis : History & Evidence Of Anxiety State

Treatment : **Reassurance & Simple Analgesia Like Aspirin & Paracetamol.**



## **B- Intracranial**

\*This group consist of **tumors** including **those Of Pituitary.**

\* **Aneurysms As Of The Carotid In The Cavernous Sinus**

\* **Brain Stem Lesions ( Multiple Sclerosis , Vascular Malformation )**

In such cases **pain is intermittent** at first & then become **sever** . later on it is accompanied by other manifestation such as **disturbance of vision , restricted movement of the eye balls , defective hearing & cervical lymph node enlargement**

\***This Group Also Includes Cranial Base Lesion ( Injury To The Cranium , Paget's Disease )** in this group the **pain continues & may be bilateral & associated with loss of hearing & disturbance of vision .**

# Facial Pain

And

## Burning Mouth Syndrome

### Primary neuralgia

is associated with **paroxysmal pain ( shock like or stabbing )** which **last seconds with complete or almost complete remission between spasms** . The pain is usually so sever that the face is distorted with anguish , the eye fixed , speech & mastication are involuntarily arrested

**There are areas which will precipitate a paroxysmal of pain when superficially stimulated by brushing or touching (Trigger zones )**.

**Trigger zones are commonly well localized & less likely to be stimulated during sleep (Nocturnal Freedom Of Pain) .**

**Pain is usually limited to the distribution of one nerve or branch of it .**

**Spontaneous remission for months or years is a feature of primary neuralgia .**

**The cranial nerves in which primary neuralgia are found**

- \* **Trigeminal Nerve ( Trigeminal Neuralgia – Tic Douloureux )**
- \* **Glossopharyngeal Nerve**
- \* **Facial (Geniculate Neuralgia )**
- \* **Superior Laryngeal**
- \* **Greater Auricular**

All of these have sensory ganglion , the frequency of occurrence of neuralgia is directly proportion to the size of the ganglia .

## **Etiology:**

The etiology of neuralgia is unclear and 10% of cases have detectable underlying pathology such as:

- 1- Tumors of the cerebellar pontine angle,
- 2- Demyelinating plaque of multiple sclerosis
- 3- Vascular malformation.

The remainder of cases of TN is classified as idiopathic.

A majority of cases of TN are caused by an atherosclerotic blood vessel (usually the superior cerebellar artery) pressing on and grooving the root of the trigeminal nerve. This pressure results in focal demyelination and hyper excitability of nerve fibers, which will then fire in response to light touch, resulting in brief episodes of intense pain.

There are no known pathology for the primary neuralgia .

however there are (2) exception

1. Tic like pain of primary neuralgia may occur in the **early stage of progressive lesion which involve , invade or compress the ganglion for example** ( tumor , inflammation or aneurysm) but this stage is transient & it soon followed by destruction of the ganglionic cell which lead to sensory & motor paralysis .

2, Primary neuralgia may persist for a long period with slowly progressive lesion for example ( **Multiple Sclerosis , Tapes Dorsalis , Paget's Disease**)

### The characteristic of primary neuralgia :

1. Nature Of The Pain Is Sudden Attack Of Bright Pain

2. Presence Of Trigger Zone

3. The Presence Of Refractory Period , an interval of( 2-3 ) minutes must elapse before a further paroxysmal pain can be induced by stimulation of the same area .

4- Only temporary relief is obtained by interrupting the peripheral nerve pathway either surgically or by injection of alcohol .

5Destruction of the ganglion itself by hot water or alcohol may effectively cure the pain , but if the destruction is incomplete , regeneration occur &the pain will be return .

6Preganglionic root section cure the vast majority of cases , but if the operation is delayed (2-3) years higher station will become unstable by repeated bombardment from the lower cell station & thus preganglionic root section may be ineffective .

7 It has been shown that 10% of patients with trigeminal neuralgia are found with vascular abnormality. (90% idiopathic )

8There are evidence that primary neuralgia are benefited by anticonvulsant drugs , the patient may need (200-1200) mg \ day then dose should be reduced gradually until reach the maintenance dose , which is usually range between (400-800) mg \ day.

All primary neuralgia have the above characteristic.

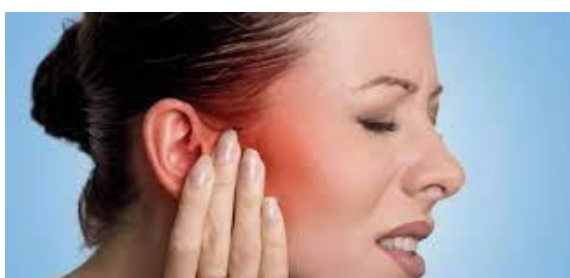**Note:** only the **pain distribution & site of trigger zone are different.**

### Trigeminal neuralgia (TN)

also called tic douloureux, is the most common of the cranial neuralgias and chiefly affects individuals older than 50 years of age. When younger individuals are involved, suspicion of a detectable underlying lesion such as a tumor, an aneurysm, or multiple sclerosis must be expected in D.D.

An elderly patient are affected by primary neuralgia & the maxillary or mandibular division usually involved but rarely the ophthalmic nerve.

10% of cases have detectable underlying pathology.



The pain of t.n may be precipitate by

- \*Touching The Trigger Zone ,
- \*Washing The Face ,
- \*Cold Wind Blowing On The Face,
- \*Chewing Or Even Talking .

The majority of patients with TN present with characteristic clinical features, which include episodes of **intense shooting stabbing pain** that lasts for a few seconds and then completely disappears. The pain characteristically has an **electric shock–like quality and is unilateral.**

### Treatment Trigeminal Neuralgia

#### Medical

#### Membrane-stabilizing medications

- \*Carbamazepine (Tegretol). in small dose 200 mg \ day & gradually increase the dose over 2-3 weeks to 200-400 mg twice daily .
- \*Phenytoin. 200-400 Mg \ Day
- \*Clonazepam. 1-2 Mg Tid
- \*Gabapentin
- \*Pregabalin. -----Lyrice
- \*Valproic acid.
- \*Baclofen.
- \*Topical Capsaicin Cream.

#### Surgical

- \*Alcohol injection  
Injection of pure alcohol in the affected ganglion lead to temporary relief of pain for about 6 months to 2 years.
- \*5 % Phenol in glycerin
- \*Surgical sectioning of the affected nerve  
However permanent cure could be achieved by surgical sectioning of the affected nerve but this should be done in the early stage
- \*Micro-vascular decompression.
- \*Percutaneous surgical procedure Balloon compression.
- \*Radiofrequency rhizotomy.
- \*Stereotactic radiation therapy .  
Gama Knife or Linear accelerator- based radiation therapy ( Trilogy, Novalis, CyberKnife).



## Glossopharyngeal neuralgia :

The trigger zones are

- Tonsillar Fauces
- Posterior 1\3 Of The Tongue
- Side Of The Soft Palate
- Posterior Part Of The Conches
- Auditory Canal

The pain precipitated by :

- ❖ Swallowing.
- ❖ Yawning.
- ❖ Coughing.
- ❖ Food Touch The Tonsillar Area.

**Treatment**

is similar TN, with a good response to carbamazepine and baclofen.

Refractory cases are treated surgically by

- ✓ Intracranial Or Extracranial Section Of CN IX.
- ✓ Microvascular Decompression In The Posterior Cranial Fossa.

## Post herptic neuralgia (PHN)

\*It is usually felt deep in the ear.

\*it may be mistaken with TMJ pain & pain from teeth .

\*However the severity of pain & the association of previously with herpes zoster infection could be help in diagnosis of PHN.

\*If the Pain persists for longer than one month it is classified as postherpetic neuralgia .

\*PHN may occur at any age, mostly in immunocompromised old patient.

Treatment of PHN

The use of antiviral drugs, particularly famciclovir, along with a short course of systemic corticosteroids during the acute phase of the disease may decrease the incidence and severity of PHN.

### **Superior laryngeal neuralgia :**

This is usually **felt deep in the throat** occasionally in the **lower part of the face & gum**

### **Great auricular neuralgia :**

It is often **felt at the angle of the jaw** , this may be differentiated from dental pain by giving inferior alveolar nerve block to exclude the dental pain .

### **Nervous intermedius (geniculate) neuralgia**

is an uncommon paroxysmal neuralgia of CN VII resulting from herpes zoster infection of geniculate ganglion and nervous intermedius of CN VII characterized by pain in the ear and (less frequently) the anterior tongue or soft palate.

GN may also develop following herpes zoster oticus (Ramsay Hunt syndrome), where cold sores occur on the ear drum or ear. This may also be associated with facial paresis (weakness), tinnitus, vertigo and deafness. Disorders of lacrimation, salivation and/or taste sometimes accompany the pain. There is a common association with herpes zoster

#### **Treatment**

- 1- Short course (2 to 3 weeks of high-dose steroid therapy is beneficial).
  - 2- Acyclovir significantly reduces the duration of the pain 200mg 5 times daily for 10-14 days.
  - 3- Patients with geniculate neuralgia are also treated with carbamazepine and antidepressants.
- Patients who do not respond to these medications may undergo surgery to section the Nervus Intermedius.

### **Atypical facial pain:**

It refers to a mixed group of condition, which are defined & diagnosed by exclusion of the other typical patterns of facial pain .

It is usually psychogenic & occurs in patients who suffer from depressive reaction , hysteria or schizophrenia .

It is more common in women in sixth decade .

#### **The pain is**

**\*Deep**

**\*Poorly Localized**

**\*Vaguely Described By The Patient**

**\*Often Spread not only to the other side of the face but to the neck & mastoid region**

#### **Treatment:**

**\* Tricyclic Antidepressant ( Amitriptyline , Nortriptyline)**

# Burning Mouth Syndrome

## Definition

It is a chronic, painful condition characterized by burning sensations in the tongue, lips, palate, gums, buccal mucosa and the back of the mouth or throat.

- The discomfort cannot be easily attributed to any physical abnormalities in the mouth or any underlying medical disorder.
- There are many oral mucosal diseases that cause burning sensations as a result of observable local pathology.
- However, Burning Mouth Syndrome (BMS) refers specifically to burning pain involving the oral mucosa in the absence of either local pathology or underlying medical causes.

- Other names sometimes used for burning mouth syndrome include
- Scalded Mouth Syndrome, Burning Tongue Syndrome, burning lips syndrome, glossodynia and stomatodynia, glossopyrosis , stomatopyrosis.

## Symptoms

### A. Pain

1. is the main symptom of BMS ,Spontaneous , Approximately one third of patients relate time of onset to a dental procedure, recent illness or medication course (including antibiotic therapy), it often persists for many years.
2. For many people, the burning sensation begins in late morning, builds to a peak by evening, and often subsides at night. Some feel constant pain; for others, pain comes and goes.
3. the anterior two thirds of the tongue, the anterior hard palate and the mucosa of the lower lip most frequently involved.

B. Tingling Or Numbness on the tip of the tongue or in the mouth

C. Bitter Or Metallic changes in taste or changes in the intensity of taste perception

D. Dry Or Sore Mouth.

F. Anxiety And Depression

# Etiologic Factors

1. Systemic causes

2. Local Cause

3. Idiopathic

## 1. Systemic Factor

### A. Psychologic Dysfunction:

Personality and mood changes (especially anxiety and depression) have been consistently demonstrated in patients with burning mouth syndrome and have been used to suggest that the disorder is a psychogenic problem. However, psychological dysfunction is common in patients with chronic pain and may be the result of the pain rather than its cause.

### B. Diabetes

1. Peripheral Neuropathy
2. Xerostomia
3. ↑ Catabolic Activity
4. Candidal Infection.
5. Vascular Changes



C. Use of broad spectrum antibiotics that will cause alteration of oral micro flora.

D. Gastro-esophageal Reflux. (GERD)

E. Vitamin B Complex Deficiency.

F. Endocrine And Immunologic Disorders Such As Hypothyroidism

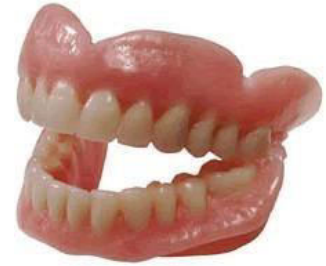G. Hormonal Change {Menopause}

H. Angiotensin-converting Enzyme (ACE) Inhibitors....Captopril,...Benazepril

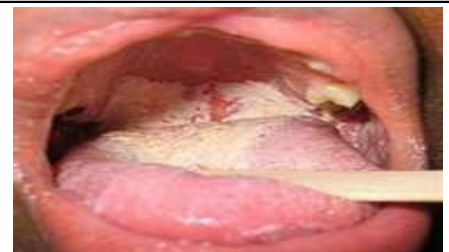## Local Factors

### **1. Denture causes:**

- \* Ill fitted denture.
- \* Lack of retention and stability and support.
- \* ↑vertical dimension .
- \* Unpolished surface
- \* Presence of residual monomer.
- \* Allergic reaction to dental material as cold or hot cured resin.
- \* Presence of candidal growth either in the form of leukoplakia, erythroplakia, or speckled leukoplakia.



## Local Factors



### **2. Oral Candidiasis (Oral Thrush):**

A symptom of this oral fungal infection is a burning sensation in the mouth, particularly when consuming acidic or spicy foods, or when the white lesions are scraped from the inside of the mouth

### **3. Hypersensitivity To Mercury Or Other Dental Materials.**

### **4. Prolong use of CHX mouth wash.**

### **5. Median rhomboidal glossitis ,geographic tongue, fissured tongue, lichen planus, submucous fibrosis.**

### **6. Pemphigus and pemphigoid.**

### **7. Lichan planus & Lupus Erythematosus.**

### **8. Habit.**



# Tests And Diagnosis

1. History of the patient.
2. Examination
  - Blood tests .
    - Complete Blood Count
    - Glucose Level
    - Thyroid Function
    - Nutritional Factors
    - Immune Functioning.
  - Other Blood Tests. Because nutritional deficiencies are one cause of a burning mouth, your doctor may collect blood samples to check blood levels of
    - Iron
    - Zinc
    - Folate (Vitamin B-9)
    - Thiamin (Vitamin B-1)
    - Riboflavin (Vitamin B-2)
    - Pyridoxine (Vitamin B-6)
    - Cobalamin (Vitamin B-12).
  - Also, because diabetes may cause a burning mouth, your doctor may check your **fasting blood sugar level**.
  - Oral cultures .Taking samples from mouth can tell whether its a fungal, bacterial or viral infection .
  - Allergy tests.
    - if patient may be allergic to certain foods, additives or even substances in dentures
    - Patch-Test**
  - Salivary measurements.
  - Psychological questionnaires. depression, anxiety or other mental health conditions.
  - Gastric reflux tests. These can determine if patient has gastroesophageal reflux disease

# Treatment

- Depend on cause !!!
- \* Dry mouth (e.g., in Sjögren's syndrome) High fluid intake, art saliva ,med. Increase salivation.
- \*Denture irritation :replace denture.
- \*Nutritional deficiency (e.g., vitamins B1, B2 or B6, zinc, others): Oral supplementation.
- \*medication:. for dry mouth, Rx oral candidacies, control pain caused by nerve damage.
- \*Menopause :Hormone replacement therapy
- \*Change medication: if Medication effect.
- \*Relief anxiety and depression

# Idiopathic BMS

## Medication

- Tricyclic antidepressants:

1..Amitriptyline ; 10 to 150 mg per day. 10 mg at bedtime; increase dosage by 10 mg every 4 to 7 days until oral burning is relieved or side effects occur

2..Nortriptyline :10 to 150mg one/two time daily

- Anticonvulsants:

1. Gabapentin : 300 To 1,600 Mg Per Day.

2. Tegretol: 100-1000mg Daily

- Benzodiazepines:

1.Clonazepam 0.5-2mg/Day.

2.Chlordiazepoxide 5-10mg1-2 Daily.

- Capsaicin: Rinse mouth with 1 teaspoon of a 1:2 dilution (or higher)

## Nonpharmacologic management strategies

**The most commonly recommended is**

### **Cognitive Behavioral Therapy (CBT)**

in which a trained counselor uses **relaxation, exposure, and cognitive restructuring** among other modalities to redefine the patient's pain experience. This is effective in finding coping strategies and improving mood disorders.

### **Other defocusing strategies including**

❖ **Psychotherapy**

❖ **Exercise Regimens**

❖ **Yoga**

❖ **Acupuncture**

❖ **Tongue Protectors And Other Appliances Can Address Any Parafunctional Habit.**

## **D-Past and present medical history**

It is very important for the following reasons

1. Identification of systemic disease that could require modification of dental treatment
2. Identification of contagious disease that pose a threat to dental staff or other patients.
3. Identification of drugs that could interact with treatment administered by the dentist.
4. Establishment of good patient-dentist relationship.
5. Facilitate effective communication with patient physician.
6. Provision of medico legal protection.

## **Medical history composed of:**

1. Serious Illnesses.
2. Hospitalizations.
3. Transfusions.
4. Allergies.
5. Medications.
6. Childhood disease.
7. Pregnancy.
8. Review of systems

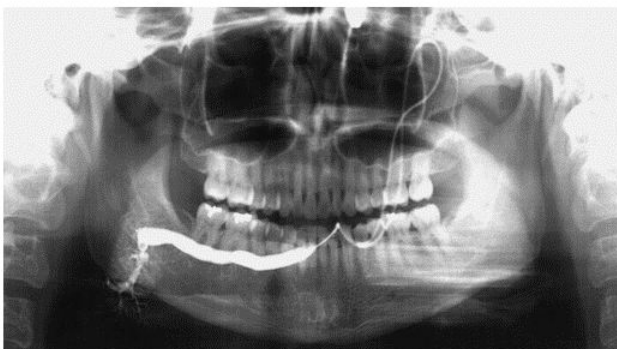
## **CBCT:**

**Magnetic resonance imaging (MRI) :** for the soft tissue, salivary gland and TMJ

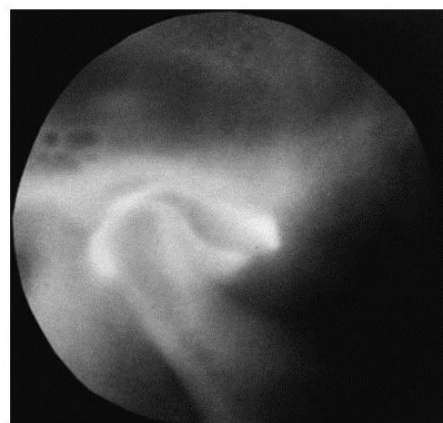
**Radioisotope imaging (nuclear scanning )**

very small quantities of radioactive materials called radioisotopes to image parts of the body may be used in salivary gland scanning like in the Sjogren's or in the bone scanning.

**Sialography of salivary gland**



**CT of TMJ**



## 2. Laboratory investigations

Supplementary diagnostic aids:

After termination of all clinical and radiographical examination of the patient, sometime further investigation are needed.

This may be either to

- \*Confirm a suspected disorder.
- \*Obtain more information before diagnosis is made.

There are many other histopathological, bacteriological, hematological, biochemical, serological and immunological tests which might occasionally be needed in the diagnosis of oral condition.

### A. Bacteriological study:

#### I. Preparation of Stain Smear from the oral cavity:

#### II. Culture and sensitivity test:

### A-Preparation of stained smear;

Smear of the oral mucosal cells and exudate are usually studied in detail for the following reason.

- \*To determine the morphology of the micro-organism. The smear is usually air dried, heat, fixed and gram stained.
- \*To determine premalignant and malignant changes in the oral mucosa. The smear may be immediately fixed with 95% alcohol and stained by the Papanicolaou stain.
- \* To determine giant cells and other unusual cells that occurs in vesicular virus infection (herpes simplex, varicella zoster) and pemphigus. The smear may also be air dried fixed with methanol and Giemsa stained.

## **B-Bacterial culture and sensitivity testing;**

Are used to isolate and identify causative micro-organism. After isolation, the micro-organism is exposed to a number of antibiotic agents to determine which affect growth. It is helpful in evaluating (throat infection, exudate from sinus infection, root canal infection and bone infection)

### **Indication of sensitivity test :**

- \*1. When patient dose not respond to therapy.
- \*2. When patient relapses.
- \*3. Identification of M.O is uncertain.
- \*4. When the disease is sever

### **Sensitivity testing is done in one of several way ;**

- \*Disk diffusion
- \*Test tube dilution
- \*Agar diffusion.

## **B. Biopsy**

**It is defined as surgical removal of a part or the whole lesion of living tissue for microscopical examination.**

### **Indication**

- 1. To confirm diagnosis of malignancy in clinically suspicious lesion.**
- 2. As diagnostic aids in evaluation of non diagnosed lesion.**
- 3. To evaluate the exact histological nature of any soft tissue or intraosseous lesion.**

### **Types**

- A. Excisional**
- B. Incisional**
- C. Fine Needle aspiration cytology**
- D. Intraosseous biopsy**
- E. Punch biopsy**
- F. Frozen Section biopsy**
- G. Exfoliative Cytology**
- H. ORALCDX Test**

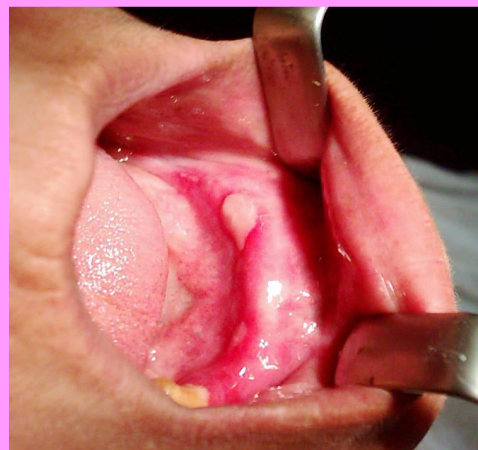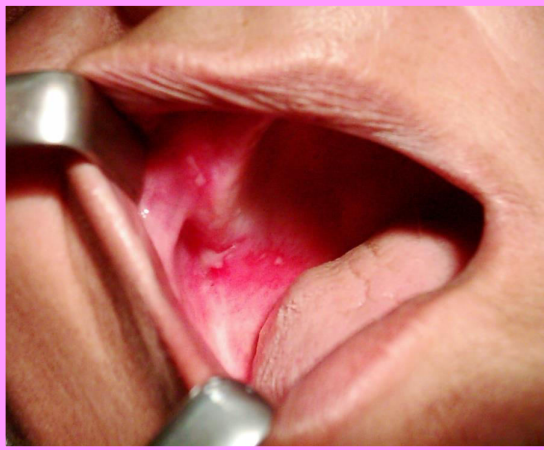## **Types of biopsies:**

### **\*Excisional biopsy:**

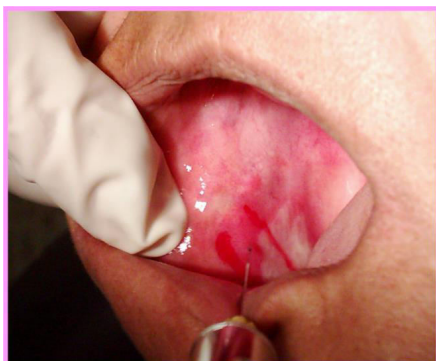**Remove the entire lesion and send to the lab.  
It is considered as diagnostic treatment as in  
small lesion.**

### **\*Incisional biopsy:**

**In which a segment of the lesion is removed mostly  
wedge shape from diseased and normal tissue in  
certain depth to see the reaction of the tissue.**

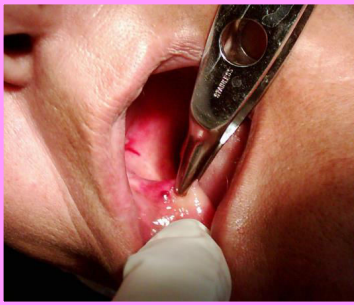

**This patient complaining of multiple bullous lesion in the oral mucosa.**

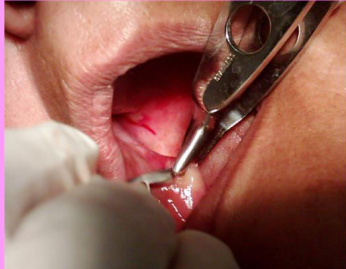

**Give local anesthesia (not into the lesion).**

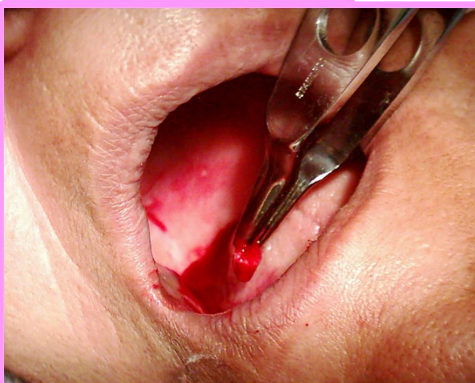



Hold the specimen by tissue forceps or pass a suture through it to prevent the specimen being swallowed or aspirated by the suction.



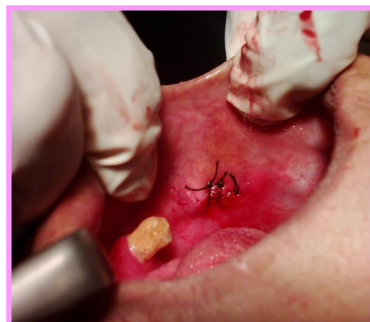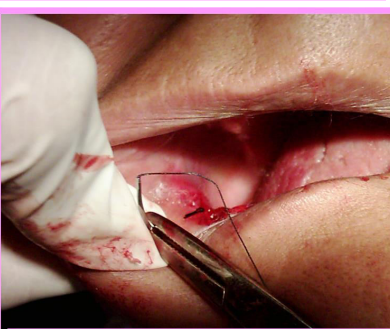
Include normal tissue margin.  
Specimen edges should be vertical not beveled.



For large lesions, several areas may need to be sampled.



Specimen should preferably be at least 1x0.6 cm by 2mm deep.



Suture and control any bleeding.



The specimen should be preserved in 10% Formalin  solution.

Label specimen bottle with patient's name, age, and date.

Clinical report of the case.

## Fine Needle aspiration cytology

- It is the microscopic examination of an aspirate obtained by inserting a fine needle into lesion. It is a painless & a save procedure for rapid diagnosis.

### Indications

- 1-Salivary gland pathology.
- 2- Suspicious lymph nodes
- 3- Detection of metastatic squamous cell carcinoma within cervical nodes.

## Intra-osseous biopsy

It is less frequently performed. It may be in the form of exploratory curettage in which the representative tissue is obtained to determined the nature of large radiological alterations.

# Frozen Section biopsy

It is performed in order to get an immediate histological report of a lesion.

## Indications

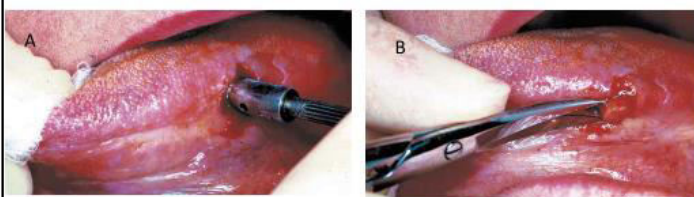
- To determine whether a lesion is malignant or not.
- To evaluate the margins of an excised cancer.
- To ascertain that the entire lesion is removed at the time of surgery.

## Procedure

The tissue is obtained from lesion & it is kept in deep freeze & then frozen tissue is sectioned & stained to get a prompt diagnosis.

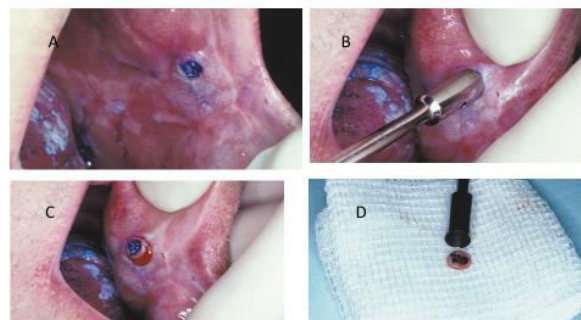
## Punch biopsy

In this technique, a sharpened hollow tube of several millimeters in diameter is rotated until underlying bone or muscle is reached.



Punch biopsy

- A. Obtaining a core with a 5-mm punch instrument  
B. Removing the punch biopsy tissue fragment with curved scissors  
C. Placing the tissue in formalin.



Punch biopsy technique in a patient being seen on a routine recall for widespread oral leukoplakia  
A. Routine toluidine blue application revealed dye binding in the commissure.  
B. Incision with a 5-mm punch instrument.  
C. Specimen to be removed by scissors or scalpel.  
D. Specimen and punch instrument.  
The biopsy showed early squamous cell carcinoma.

## **Oral CDx system**

It is highly specialized computer assisted analysis of an oral brush biopsy performed on oral tissue.

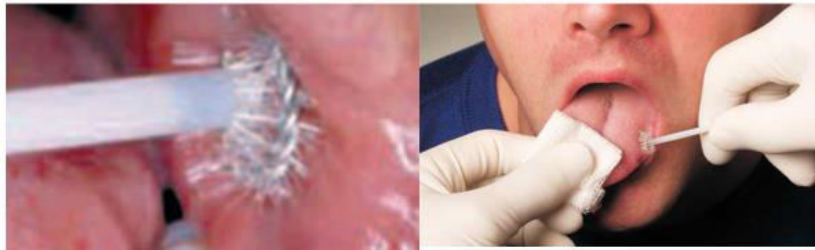It is the most recent development in oral biology technique.

This technique is ideal for determining the need for scalpel biopsy in benign appearing oral mucosal leukoplakia.

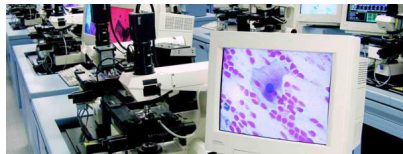### **Procedure**

#### **Collection of sample cells**

This technique utilizes a disposable brush to collect a trans epithelial sampling of cells.



### **Oral CDx system**



### ***Computer screening***

**The sample is screened by computer which is programmed to detect cytological changes associated with premalignant & squamous cell carcinoma. The computer consists of neural network based image processing system specially designed to detect oral epithelial precancerous & cancerous cells.**

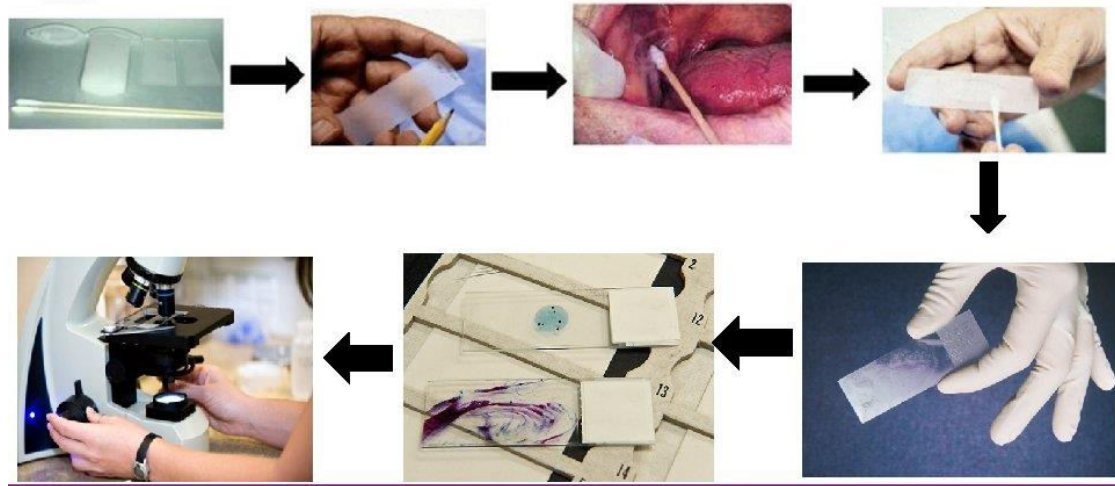
### **Image processor**

This is specially designed to detect as few as two abnormal epithelial cells scattered among more than thousand cells on each biopsy specimen.

## C. Oral Exfoliative Cytology:

The microscopic examination of surface cells that have been removed from oral mucosa by scraping. The cells collected are smear on a glass slide and fixed.

### EXFOLIATIVE CYTOLOGY:



### Indication of exfoliative cytology;

1. Diffuse lesion covering large area in mucosa, when many incisional biopsy is needed to determine the range of pathologic changes in tissues.
2. Surface lesion in patient receiving radiation in which biopsy may cause persistent ulceration or osteoradionecrosis.
3. Patient who decline biopsy for certain psychological reason.
4. It is helpful in the evaluated of, vesicles and bulla.

### The exfoliative cytology is contraindicated in;

1. Lesion covered with normal mucosa.
2. Keratotic lesion.
3. Lesion with grossly necrotic surface.

Note; definitive treatment can't be based on exfoliative cytological smear for serious diseases.



## **4- Routine Hematology Screening :**

The Formed Elements Of The Blood Consist Of (*RBC, WBC And Platelets*)

\* **Complete Blood Picture:** Usually Includes The Following:

A- RBC Count.

B- Hematocrit (Hct).

C- Hemoglobin (Hgb).

D- WBC Count & Differential WBC Count.

The Differential WBC is

Neutrophil,

Basophil,

Eosinophil,

Lymphocyte

Monocyte.

E- Blood Smear For Cell Morphology.

F- Platelet Or Thrombocyte Count.

\* **Complete Hematologic Examination; Include:**

A- Mean Corpuscular Volume (MCV).

B- Mean Corpuscular Hemoglobin (Mch).

C- Mean Corpuscular Hemoglobin Concentration (Mchc).

D- Erythrocyte Sedimentation Rate (Esr).

## **Normal Values:**

**Hematocrit (PCV):** Is the volume of packed erythrocyte per 100 ml of blood, the erythrocyte are packed by centrifuge.

**Hemoglobin:**

Is the oxygen carrying component of RBC.

<b>Tests</b>	<b>Normal value</b>	<b>Significance</b>
Total RBC count	♂ 4.6- 6.2 million cell/mm <sup>3</sup> ♀ 4.2- 5.4 million cell/mm <sup>3</sup>	+ polycythemia - anemia
Hematocrit (Packed cell volume) (PCV)	♂ 40-54% ♀ 37-47%	+ polycythemia - anemia
Hemoglobin (Hgb)	♂ 13-18 g/dl ♀ 12-16 g/dl	+ polycythemia - anemia



Tests	Normal value	Significance
Total WBC count	4500-11000 cell/mm <sup>3</sup>	+ Bacterial infection, Polycythemia, Tissue-destructive disease and some Leukemias - Aplastic anemia, Bone marrow depression, Drug induced myelosuppression, Viral infection
Neutrophils	50-70 %	+ Bacterial infection, Steroid therapy, following Acute Hemorrhage - Aplastic anemia, Cyclic neutropenia, Cancer chemotherapy, Viral infection.
Lymphocyte	30-40 %	+ Certain viral infection (mononucleosis)
Monocyte	3-7 %	+ Bacterial endocarditis, T.B, Typhoid fever
Eosinophils	0-5 %	+ Allergy, Parasitic infection, Hodgkin's disease, Sarcoidosis, Metastatic CA, Chronic skin disease (autoimmune)
Basophil	0-1 %	

**Mean cell volume (MCV):**

is the ratio of the hematocrit to the RBC count.

**Mean cell hemoglobin (MCH):**

is the ratio of Hgb to RBC and expressed in picogram .

**Mean cell hemoglobin concentration (MCHC):**

This index is a ratio of the hemoglobin to hematocrit.

The value is expressed in percentage of volume of RBC, the MCHC measure the concentration of Hgb in gram /100ml of packed erythrocytes

**Erythrocyte sedimentation rate (ESR):** It is nonspecific test for evidence of tissue destruction due to infection, infarction, trauma and malignancy

Tests	Normal value	Significance
Mean Corpuscular Volume (MCV)	82-98 micron <sup>3</sup>	+ Macrocytic anemia - Microcytic anemia
Mean Corpuscular Hemoglobin (MCH)	30 µg picogram	+ Macrocytic anemia - Microcytic anemia
Mean Corpuscular Hemoglobin Concentration (MCHC)	35%	- Microcytic anemia
ESR	♂ <10 mm/hr ♀ <20 mm/hr	+ In tissue destructive disorder e.g trauma, infections, & malignancy.

**There are many types of anemia, including :**

## **1- Iron deficiency anemia**

Is a very common cause of anemia . This is because iron is major component of hemoglobin and essential for its proper function.

Interpretation of CBC may lead to clues to suggest this type of anemia. For instance, iron deficiency anemia usually presents with low mean corpuscular volume (microcytic anemia) in addition to low hemoglobin (microcytic hypochromic anemia).

## **2- Pernicious Anemia**

Pernicious anemia is a condition in which the body can't make enough healthy red blood

cells because it doesn't have enough vitamin B12.

People who have pernicious anemia can't absorb enough vitamin B12 due to a lack of

intrinsic factor (a protein made in the stomach)..

This typically causes of macrocytic (large blood cell volume) anemia.

## **3- Aplastic Anemia**

Aplastic anemia is a blood disorder in which the body's bone marrow doesn't make enough new blood cells.

## **4- Hemolytic Anemia**

Hemolytic anemia is a condition in which red blood cells are destroyed and removed from the blood stream before their normal lifespan is up.

There are many types of hemolytic anemia's – some of which are inherited and others that are acquired.

### **1- Inherited hemolytic anemia's include:**

**Sickle Cell Anemia,  
Thalassemia,  
Hereditary Spherocytosis,  
Glucose-6-phosphate Dehydrogenase (G6PD) Deficiency,  
Pyruvate Kinase Deficiency**

### **2- Acquired hemolytic anemia include:**

**Autoimmune hemolytic anemia,  
Drug-induced hemolytic anemia**

## Diagnosis of iron deficiency anemia

**1- CBC :** Red blood cell size and color (blood film) .In iron deficiency anemia, red blood cells are smaller and paler in color than normal( .Microcytic,hypochromic) Hematocrit( PCV). This is the percentage of blood volume made up by red blood cells. Normal levels are generally between 36-47 percent for adult women and 40-50 percent for adult men. These values may change depending on age . Hemoglobin .Lower than normal hemoglobin levels indicate anemia.

**2- Ferritin** This protein helps store iron in the body, and a low level of ferritin usually indicates a low level of stored iron .

### 3- Total iron binding capacity (TIBC)

is a blood test to see if there is too much or too little iron in blood. Iron moves through the blood attached to a protein called transferrin.

### **4- Serum iron test •**

Normal value range is: • Iron: 60 to 170 micrograms per deciliter (mcg/dL) •  
TIBC: 240 to 450 mcg/dL,  
Transferrin saturation: 20% to 50%

## Test for bleeding disorders

Tests	Normal Values	Significance
Platelets count	150000-400000 cells/mm <sup>3</sup>	+ Hemolytic anemia, Polycythemia, - Thrombocytopenic purpura, Leukemia, Pernicious anemia, Hemolytic jaundice, Infective endocarditis
Bleeding time Duk's method Ivy method	3-9 min <4 min	+ Thrombocytopenia purpura, prolong aspirin intake, von Willebrand's disease.
Prothrombin Time (PT)	12-14 sec	+ Deficiency in factor (I, II, VII, X), Anticoagulant therapy (Warfarin), Liver disease.
Partial thromboplastin time (PTT)	35 sec	+ deficiency of intrinsic factor (VIII, X, XI, XII), Heparin therapy

## Screening Laboratory Tests for the Detection of a Potential "Bleeder" Person:

### Activated Partial Thromboplastin Time (APTT):

- Tests intrinsic and common pathways.
- Normal (25 to 35 seconds, depending on laboratory).
- It is increased in the following cases:
  - ★ Deficiency in the factor VIII, X, XI, XII.
  - ★ Patient with heparin therapy.

## Screening Laboratory Tests for the Detection of a Potential "Bleeder" Person:

### Prothrombin Time (PT):

- It is activated by tissue thromboplastin.
- Tests extrinsic and common pathways.
- Control should be run.
- Normal (11 to 15 seconds, depending on laboratory).
- It is increased in the following cases:
  - ★ Anticoagulant drug.
  - ★ Deficiency of the Vit.K associated factors.
  - ★ Patient with liver disease.

## Screening Laboratory Tests for the Detection of a Potential "Bleeder" Person:

### Thrombin Time (Clotting Time):

- Tests ability to form initial clot from fibrinogen.
- Normal (9 to 13 seconds).
- It is increased in the following cases:
  - ★ Fibrinogen deficiency or abnormality
  - ★ Lack of prothrombin accelerator.
  - ★ Hemophilia.

## Screening Laboratory Tests for the Detection of a Potential "Bleeder" Person:

### Platelets Function Analyzer (PFA-100\*):

- Tests platelet function.
- It is normal if adequate number of platelets of good quality present.
- Normal value (60 to 120 seconds).

### Platelet count:

- Tests platelet phase for adequate number of platelets.
- Normal value (140,000 to 400,000/mm<sup>3</sup>).
- Clinical bleeding problem (spontaneous) can occur if less than 50,000/mm<sup>3</sup> of the platelets.

## **Screening Laboratory Tests for the Detection of a Potential "Bleeder" Person:**

**Bleeding Time (BT):**

**It will tests platelet function and vascular phase.**

**There are two methods:**

**1. Duke's method: from (3-9) minutes.**

**2. Ivy's method: more than (4) minutes.**

**● It is increased in the following cases:**

**When there are defect in the vessels or platelets count and/or function.**

## **Screening Laboratory Tests for the Detection of a Potential "Bleeder" Person:**

**❧ Specific factor assays demonstrate**

**❧ reduced factor VIII: in hemophilia A**

**factor IX: in hemophilia B.**

**❧ VWF multimeric analysis.**

**❧ Detection of the antigen in the serum of the patient against the VWF and / or VIII.**



# Blood chemistry

## 1. Glucose:

Fasting blood sugar : 80-120 mg/dl.

## 2. HbA1C Test

measures average blood sugar level over the past 2 or 3 months.

Below 5.7% normal

6.5% or higher indicates diabetes

Increased	Decreased
1. Diabetes mellitus.	1. Pancreatic tumor.
2. Cushing's disease.	2. Metabolic defect.
3. Acromegaly.	3. Advanced cirrhosis.
4. Stress.	4. Hepatitis.
	5. Insulin over dose.

## Test for the diabetes Diagnostic Test

1.Fasting plasma glucose (FPG) test

2.A1C test

The A1C test is a blood test that provides average levels of blood glucose over the past 3 months. Other names for the A1C test are hemoglobin A1C, HbA1C, glycated hemoglobin, and glycosylated hemoglobin test

3.Random plasma glucose (RPG) test

Diagnosis	C 1 A (percent)	Fasting plasma glucose (FPG) <sup>a</sup>	Oral glucose tolerance test (OGTT) <sup>ab</sup>	Random plasma glucose test (RPG) <sup>a</sup>
Normal	below 5.7	99 or below	139 or below	
Prediabetes	5.7 to 6.4	100 to 125	140 to 199	
Diabetes	or 6.5 above	126 or above	200 or above	200 or above

## **2. Serum Calcium:**

Result from mobilization of bone Ca into the blood.  
8.5-10.5 mg/dl.

<b>Increased</b>	<b>Decreased</b>
<ol style="list-style-type: none"><li>1. Hyperparathyroidism.</li><li>2. Vitamin D toxicity.</li><li>3. Bone malignancy.</li><li>4. Dietary and absorption disturbances</li></ol>	<ol style="list-style-type: none"><li>1. Hypoparathyroidism.</li><li>2. Vitamin D deficiency.</li><li>3. Renal failure.</li></ol>

## **3. Phosphorus Level:**

Parathyroid hormone regulates Phosphate excretion by the kidney.  
2.5- 4.5 mg/dl.

<b>Increased</b>	<b>Decreased</b>
<ol style="list-style-type: none"><li>1. Hypoparathyroidism.</li><li>2. Renal disease.</li><li>3. Cushing's syndrome</li></ol>	<ol style="list-style-type: none"><li>1. Rickets (Vitamin D Deficiency).</li><li>2. Hyperparathyroidism.</li><li>3. Malabsorption syndrome.</li></ol>

#### **4. Alkaline Phosphatase Enzyme:**

Found in many organs but especially in liver and bone.

Bodansky units 1.5- 4.5.

King armistrong units 4- 13.

<b>Increased</b>	<b>Decreased</b>
<ol style="list-style-type: none"><li>1. Hyperparathyroidism.</li><li>2. Paget's disease.</li><li>3. Hepatic disease.</li><li>4. Tumor of the bone.</li><li>5. Osteogenesis imperfecta.</li></ol>	<ol style="list-style-type: none"><li>1. Hypophosphatasia.</li><li>2. Hypoparathyroidism.</li><li>3. Malnutrition.</li></ol>

#### **7. Lactate Dehydrogenase (LDH):**

Intracellular enzyme found in kidney, liver, heart, skeletal muscle, blood cells & skin.

90-200 U/ml.

Increased in:

Tissue destructive disease.

#### **8. Bilirubin:**

0.8 mg/dl.

Increased in:

Liver disease.

#### **9. Creatinine:**

0.7-1.4 mg/dl.

Increased in:

Kidney failure.

## **5. Serum Glutamic-Oxaloacetic Transaminase (SGOT):**

Found in brain, liver, heart, skeletal muscle, & pancreas.  
10-150 U/ml.

Increased in:

1. Tissue destructive disease (MI).
2. Hepatitis.

## **6. Serum Glutamic-pyruvic Transaminase (SGPT):**

Intracellular enzyme of hepatocytes.  
6-36 U/ml.

Increased in:

Hepatitis

### **\*Uric acid:**

In male (2.1-7.8 mg/100ml)

In female (2-6.4 mg/100ml)

### **\*Cholesterol:**

150-250 mg/100ml

it has little value in dentistry , increased in CVS disease , biliary obstruction , hypothyroidism and chronic hepatitis.

### **\*Total protein:**

6-7.8mg/100ml

### **\*Albumin /globulin ratio:**

Ab (3.2-5.6 mg/100ml)

Gb (2.3-3.5mg/1ooml)

### **\*Blood urea nitrogen:**

8-18mg/100ml

### **\*Various electrolyte: Na, K, Cl, Co<sub>2</sub>**

# White And Red Lesions Of Oral Mucosa

The oral cavity is lined by oral mucosa which is composed of

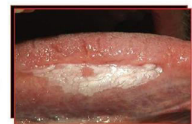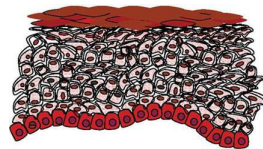
- Oral Epithelium
- Sub mucosa

Oral mucosa is divided according to the function into:-

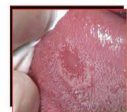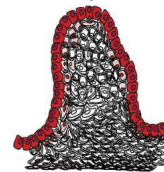
- ❖ Masticatory mucosa
- ❖ Lining mucosa
- ❖ Specialized mucosa

## A white appearance of the oral mucosa may be caused by a variety of factors

- The oral epithelium may be stimulated to an increased production of keratin (hyperkeratosis).

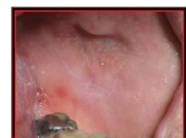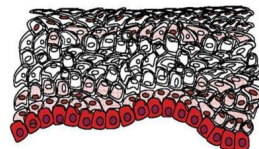


- or an abnormal but benign thickening of stratum spinosum (acanthosis).

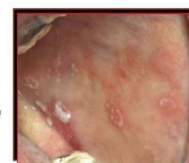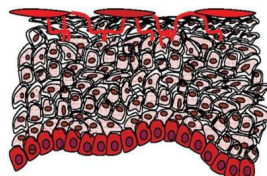


- Intra- and extracellular accumulation of fluid in the epithelium may also result in clinical whitening.

- Example : Leukoderma
- Intra oral skin graft

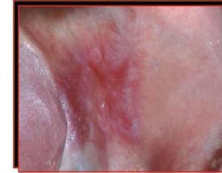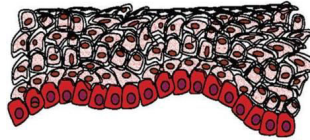


- Microbes, particularly fungi, can produce whitish pseudomembranes consisting of sloughed epithelial cells, fungal mycelium, and neutrophils, which are loosely attached to the oral mucosa.

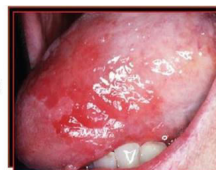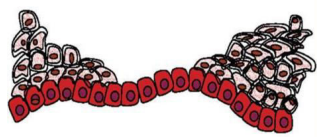


# A Red Lesion Of The Oral Mucosa May Develop As A Result Of

- 1. **Atrophic Epithelium** characterized by a reduction in the number of epithelial cells



- 2. **Or Increased Vascularization** that is dilatation of vessels and/ or proliferation of vessels.



## Reduction In The Number Of Epithelial Cells Or Increased Vascularization

Oral mucosal lesions may be classified according to different characteristics

### ☐ Infectious Diseases

Oral Candidiasis  
Hairy Leukoplakia

### ☐ Oral Potentially Malignant Disorders

Oral Leukoplakia  
Oral Erythroplakia  
Oral Submucous Fibrosis

### ☐ Immunopathologic Diseases

Oral Lichen Planus  
Drug-Induced Lichenoid Reactions  
Lichenoid Reactions of Graft-versus-Host Disease  
Lupus Erythematosus

### ☐ Allergic Reactions

Lichenoid Contact Reactions  
Reactions to Dentifrice and Chlorhexidine

### ☐ Toxic Reactions

Reactions to Smokeless Tobacco  
Smoker's Palate

### ☐ Reactions To Mechanical Trauma

Morsicatio

### ☐ Other Red And White Lesions

Benign Migratory Glossitis (Geographic Tongue)  
Leukoedema  
White Sponge Nevus  
Hairy Tongue

### 1. Normal

Leukodema  
Fordyce's Granules  
Lina Alba

### 2. Developmental

White Spongy Nevus  
Median Rhomboid Glossitis

### 3. Infective

Candidiasis  
Syphilis  
Measles Or Rubella

### 4- Traumatic

Traumatic Keratosis  
Nicotinic Stomatitis  
Papillary Hyperplasia Of The Palate

### 5. Blood Dyscrasia

Anemia  
Plummer Vinson Syndrome Vitamin A Deficiency

### 6. Drugs

Chemical Burn  
Aspirin  
Medications  
Drug Reactions Lichenoid Drug Eruption

### 7. Dermatological

Lichen Planus  
Lupus Erythematosus  
Psoriasis

### 8. Premalignant

Leukoplakia  
Erythroplakia  
Submucous Fibrosis

### 9. Squamous Cell Carcinoma

### 10. Miscellaneous

Oral Skin Graft Geographic Tongue Hairy Tongue



# Infectious Diseases

## Oral Candidiasis

Oral candidiasis is the most prevalent opportunistic infection affecting the oral mucosa. In the vast majority of cases, the lesions are caused by *Candida albicans*.

The pathogenesis is not fully understood, but a number of predisposing factors have been shown to convert *C. albicans* from the normal commensal flora (saprophytic stage) to a pathogenic organism (parasitic stage).

*C. albicans* is usually a weak pathogen, affecting the very young, the very old, the very sick.

Most candidal infections only affect mucosal linings, but rare systemic manifestations may have a fatal course.

### Oral candidiasis is divided into

Primary

Secondary

The primary infections are restricted to the oral and perioral sites,

The secondary infections are accompanied by systemic mucocutaneous manifestations.

## Predisposing Factors for Oral Candidiasis and Candida-Associated Lesions

### Local

Denture Wearing

Smoking

Atopic Constitution

Inhalation Steroids

Topical Steroids

Hyperkeratosis

Imbalance Of The Oral

Microflora Quality And Quantity Of Saliva

### General

Immunosuppressive diseases

Impaired health status

Immunosuppressive drugs

Chemotherapy

Endocrine disorders

Hematinic deficiencies

## Candidiasis

*Candida albicans* is a commensal organism within the oral cavity that becomes pathogenic when appropriate predisposing factors exist such as

\* Acid saliva...

\* Xerostomia..

\*Endocrine abnormality..

\*Vitamins deficiency

\*Mal nutrition..

\*Radiation therapy..

\*Mal absorption syndrome

\*Diabetes mellitus..

\*Chemotherapy..

\*HIV infection..

\*Age..... Old Infancy

\*Nocturnal denture wearing

\*Heavy smoker...

\*Mal absorption..

\*Antibiotics therapy

\*Steroid therapy..

## Primary Oral Candidiasis

## Secondary Oral Candidiasis

### Acute

Pseudomembranous

Erythematous

### Chronic

Pseudomembranous

Erythematous Plaque-like

### Nodular

Candida-associated lesions

Denture stomatitis

Angular cheilitis

Median rhomboid glossitis

- ❖ Familial chronic mucocutaneous candidiasis.
- ❖ Diffuse chronic mucocutaneous candidiasis.
- ❖ Candidiasis endocrinopathy syndrome.
- ❖ Familial mucocutaneous candidiasis.
- ❖ Severe combined immunodeficiency.
- ❖ DiGeorge syndrome.
- ❖ Chronic granulomatous disease.
- ❖ Acquired immune deficiency syndrome. (AIDS).

## Classification of oral candidiasis.

### Type

### Examples

Pseudomembranous—acute

Pseudomembranous—chronic

Erythematous—acute atrophic

Erythematous—chronic atrophic

Chronic hyperplastic (nodular and plaque-like subtypes)

Candida-associated lesions

Thrush

With inhalers

After antibiotic therapy

Denture stomatitis; in HIV

Candidal leukoplakia, median rhomboid glossitis

Denture stomatitis; angular cheilitis

## Candidiasis affecting extraoral sites and conditions predisposing to candidiasis.

- Familial chronic mucocutaneous candidiasis
- Diffuse chronic mucocutaneous candidiasis
- Erythematous candidiasis endocrinopathy syndrome
- Chronic severe combined immunodeficiency
- DiGeorge syndrome
- Chronic granulomatous disease
- HIV disease

## Epidemiology

The prevalence of candidal strains, as part of the commensal oral flora, shows

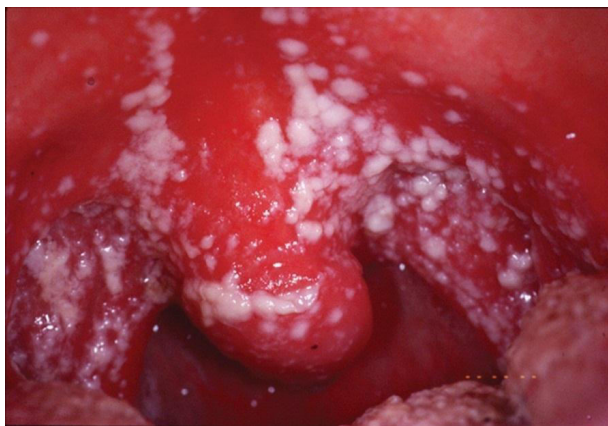- ❑ Large geographic variations.
- ❑ Candidal strains are more frequently isolated from women.
- ❑ A seasonal variation has been observed, with an increase during summer.
- ❑ Hospitalized patients have a higher prevalence of the yeasts.
- ❑ In healthy individuals, blood group O
- ❑ In complete denture-wearers, the prevalence of denture stomatitis has been reported variously from 11–67%.

## Clinical Findings

### Pseudomembranous Candidiasis

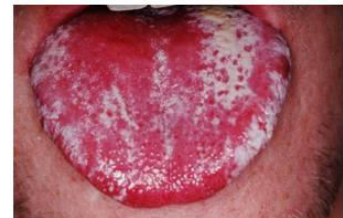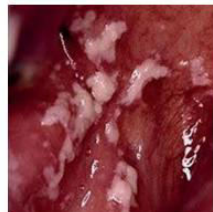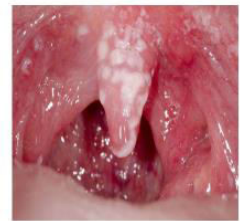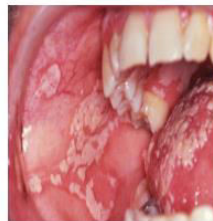Acute form of pseudomembranous candidiasis (thrush) is grouped with the primary oral candidiasis and is recognized as the classic candidal infection.

The infection predominantly affects patients taking antibiotics, immunosuppressant drugs, or having a disease that suppresses the immune system.



Pseudomembranous Candidiasis

Or Thrush



## A. Pseudomembranous candidiasis (Thrush)

It's characterized by the development of adherent white plaques on the oral mucosa. These plaques can be removed easily by scrapping them with a tongue blade.

### Symptoms...

Burning Sensation....Abnormal Taste..

### Site..

Buccal Mucosa..

Tongue..

Palate..

### Diagnosis:-

Clinically .....Removed by scrapping.

Positive (+ve) swab and culture on Sabouraud's dextrose agar to see the colonies.

**PAS** stain (Periodic Acid Shuff Reagents).

### Treatment:

Corrections of systemic background

Nystatin tablet...lozenges

Amphotericin B

Miconazole

Mycostatin drops

Gentian violet

## Erythematous Candidiasis

Was previously referred to as **atrophic oral candidiasis** or **Antibiotic Sore Mouth**. **erythematous surface may not just reflect atrophy** but can also be explained by **increased vascularization**.

The lesion has a diffuse border which helps distinguish it from **Erythroplakia** which usually has a **sharper demarcation**

The infection is predominantly seen in the

**Palate**

**Dorsum Of The Tongue**

of patients who are using **inhalation steroids**.

Other predisposing factors are

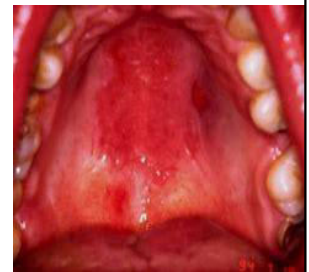
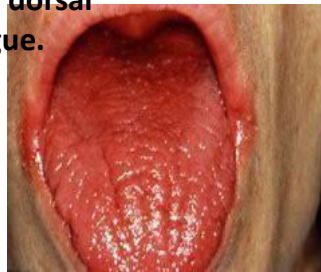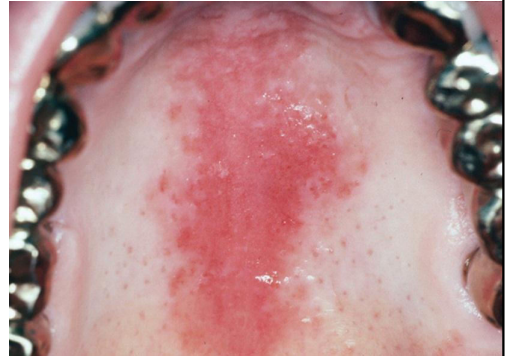**Smoking**

**Treatment with broad-spectrum antibiotics.**

It follows a course of broad spectrum antibiotics.

**Clinically:**

Burning sensation may be accompanied by a diffuse loss of the filiform Papillae of the dorsal tongue resulting in a reddened bald tongue.



## Chronic Plaque-Type and Nodular Candidiasis

Replaces the older term, candidal leukoplakia.

- A white irremovable plaque
- Characterizes the typical clinical presentation, which may be indistinguishable from oral leukoplakia
- A + correlation between oral candidiasis and **moderate to severe epithelial dysplasia**.
- Both the chronic plaque-type and the nodular type of oral candidiasis have been associated with malignant transformation.
- The possible role of yeasts in oral carcinogenesis is unclear.

**Diagnosis:-**

**Clinically**

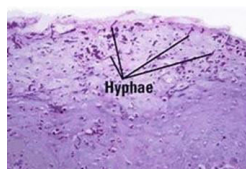
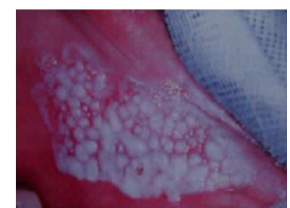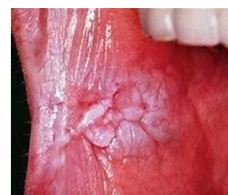None scrapped lesion.

**Biopsy**

**Treatment**

**Antifungal**

**Surgical excision and graft is needed for unresponsive lesion.**





# Denture Stomatitis

The denture serves as a vehicle that accumulates sloughed epithelial cells and protects the microorganisms from physical influences such as salivary flow.

The microflora is complex of

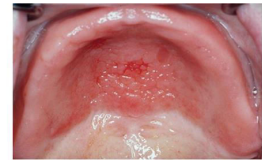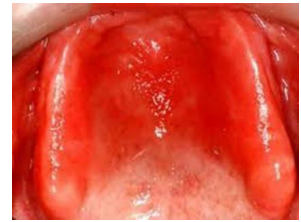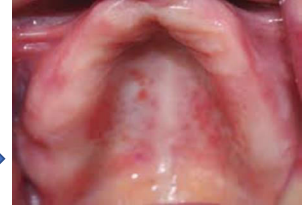- C. Albicans
- Bacteria from several generation, such as Streptococcus-, Actinomyces-strains.

Denture stomatitis is classified into three different types.

●● **Type I**  is limited to erythematous sites caused by trauma from the denture.

●● **Type II**  affects a major part of the denture-covered mucosa.

●● **Type III**  has a granular mucosa (reactive proliferation of underlying fibrous tissue) in addition to the features of type II..



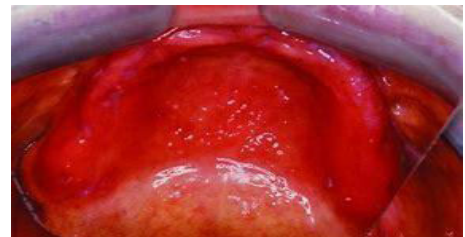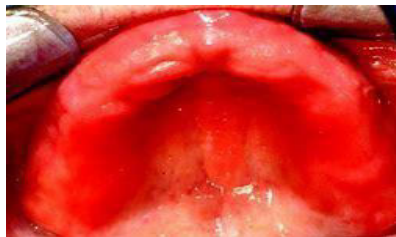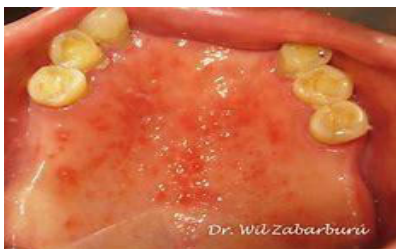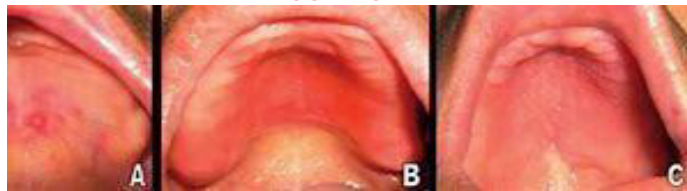Chronic atrophic candidiasis (denture stomatitis) type III with a granular mucosa in the central part of the palate

## Neoten classification of Denture stomatitis 1972

**A. Pin point hyperemia or pin point Denture Stomatitis.**

**B. Diffuse simple Denture Stomatitis**

**C. Granular Denture Stomatitis Or Denture hyperplasia.**



Dr. Wil Zabarburu



# **Denture Stomatitis**

## **Diagnosis**

1. Smear from denture base.
2. Swab and culture.

## **Treatment**

- ❖ Leave denture out for 2weeks
- ❖ Construction of new denture in case of ill fitting ,old or poor denture.
- ❖ Antifungal
- ❖ Check for iron deficiency in persistent case

# **Angular Cheilitis or Perleche**

**It presents as infected fissures of the commissures of the mouth, often surrounded by erythema.**

The lesions are frequently infected with both

**Candida Albicans**  
**And Staphylococcus Aureus.**

**Vitamin B12 deficiency**

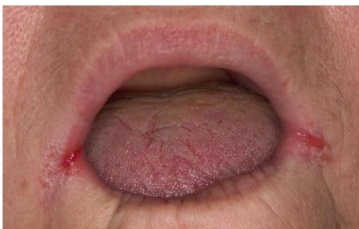**Iron Deficiency**

**Loss Of Vertical Dimension**

} have been associated with this disorder.

**Dry skin** may promote the development of fissures in the commissures, allowing invasion by the microorganisms.

30% of patients with denture stomatitis also have angular cheilitis,

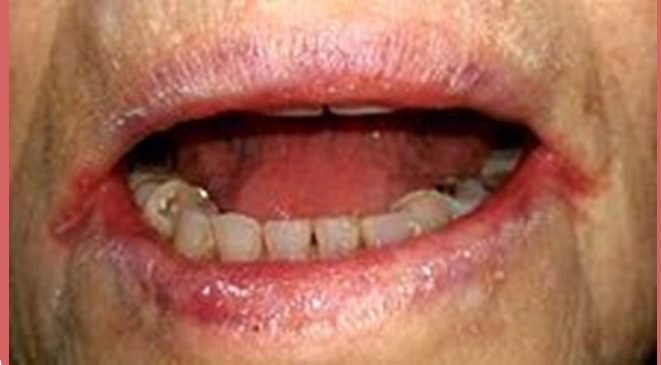

Candida-induced bilateral angular cheilitis.  
Treatment must include the intraoral Candida reservoir.

# Erythematous candidiasis

## 4. Angular chelities or Perleche

- It's a bilateral chronic inflammation of the corner of the mouth, characterized by erythema, fissuring and scaling.
- Typically seen in older person with reduced vertical dimension.
- Microbiological studies have indicated that the lesion caused by candida albicans and staphylococcus aureus.

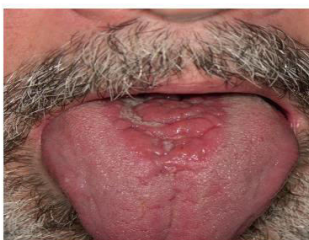


### Treatment:

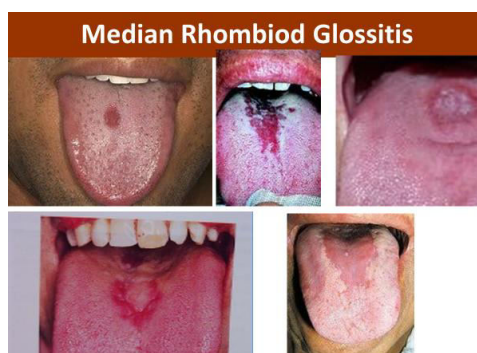
- Antifungal.
- Increasing vertical dimension.
- Identifying the predisposing factors.

## Median Rhomboid Glossitis

- ❖ Clinically characterized by an erythematous lesion in the center of the dorsum of the tongue; an oval configuration. This area of erythema results from atrophy of the filiform papillae and the surface may be lobulated.
- ❖ The etiology is not fully clarified, but the lesion frequently shows a mixed bacterial/fungal microflora.
- ❖ Biopsies yield candidal hyphae in more than 85% of the lesions.
- ❖ Smokers and denture-wearers have an increase risk of developing median rhomboid glossitis
- ❖ Patients using inhalation steroids.
- ❖ Sometimes a concurrent erythematous lesion may be observed in the palatal mucosa (kissing lesions).
- ❖ Median rhomboid glossitis is asymptomatic, and management is restricted to a reduction of predisposing factors.
- ❖ The lesion does not entail any increased risk for malignant transformation



Median rhomboid glossitis apparently arising from the junction of the posterior third and anterior two-thirds of the tongue.  
Histology confirmed chronic hyperplastic candidiasis.



# Oral Candidiasis Associated with HIV

More than 90% of acquired immune deficiency syndrome (AIDS) patients have had oral candidiasis during the course of their HIV infection.

The most common types of oral candidiasis in conjunction with HIV are Pseudomembranous Candidiasis.

**Erythematous Candidiasis.**

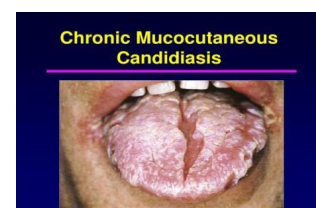
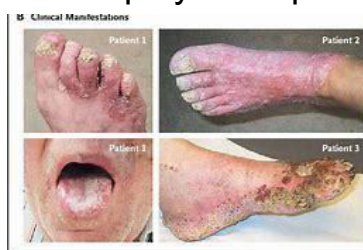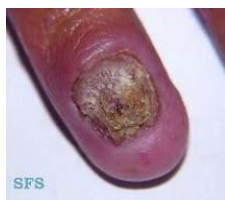**Angular Cheilitis.**

**Chronic Plaque-like Candidiasis.**

As a result of the highly active antiretroviral therapy (HAART), the prevalence of oral candidiasis has decreased substantially.

## Chronic mucocutaneous candidiasis (CMC)

- Involves a heterogeneous group of disorders, which, in addition to **oral candidiasis**, also affect the **skin**, typically the **nail** and **other mucosal linings**, such as the **genital mucosa**.
- The **face and scalp** may be involved.
- Approximately 90% of the patients with CMC also present with oral candidiasis.
- The oral manifestations may involve the **tongue**, and lesions are seen in conjunction with fissures.
- CMC can occur as part of **Endocrine Disorders**, including **hyperparathyroidism** and **Addison's disease**.
- Recent studies revealed that an impairment of interleukin- 17 (IL-17) immunity underlies the development of CMC
- T-helper 17 cells produce IL-17 and play an important role in host mucosal immunity to Candida.



## Management

Treatment for fungal infections, which usually include antifungal regimens, will not always be successful unless the clinician addresses predisposing factors that may cause recurrence.

Local factors are often easy to identify but sometimes not possible to reduce or eradicate

- In smokers, cessation of the habit may result in disappearance of the infection even without antifungal treatment
- Antifungal drugs belong to the groups of **Polyenes or azoles**
- **Polyenes such as nystatin and amphotericin B** are usually the first choices in treatment of primary oral candidiasis and are both well tolerated.
- Elimination or reduction of predisposing factors should always be the first goal for treatment
- This involves improved denture hygiene, not to use the denture while sleeping.
- The denture hygiene is important to remove nutrients, including desquamated epithelial cells, which may serve as a source of nitrogen essential for the growth of the yeasts
- Denture cleaning also disturbs the maturity of a microbial environment established under the denture.
- Porosities in the denture can harbor microorganisms, which may not be removed by physical cleaning, the denture should be stored in antimicrobial solutions during the night

### 1. Polyenes

<b>Nystatin (Mycostatin , Nystat )</b>	<b>Nystatin 100000. IU 200000. IU 500000. IU Pastilles, Drop 1x4. daily.</b>
<b>Amphotericin B (Fungizon)</b>	<b>Amphotericin B 100mg/20ml suspension. 50mg...powder for injection 1x4 daily</b>

### 2. Azoles

#### Imidazole Derivative

#### Topical

**Clotrimazole...(Mycelex)**

**Clotrimazole**

**Miconazole (Micogel)**

**Gel Lotion Solution**

**Econazole**

**Troche..100mg..200mg..500mg**

#### Systemic

**Ketoconazole (Nizoral)**

**Ketoconazole**

**200mg tab 50mg 100mg 150mg 200mg tab**

### 3. Triazole

**IV. once daily**

#### Systemic

**Fluconazole**

**Itraconazole**

**Itraconazole**

### 4. Other

**100mg 200mg cap**

**Gentian violet 1%**

- **Systemic azoles** may be used for deeply seated primary candidiasis, such as **chronic hyperplastic candidiasis**, **denture stomatitis**, and **median rhomboid glossitis** with a granular appearance,

**There are several disadvantages with the use of azoles.**

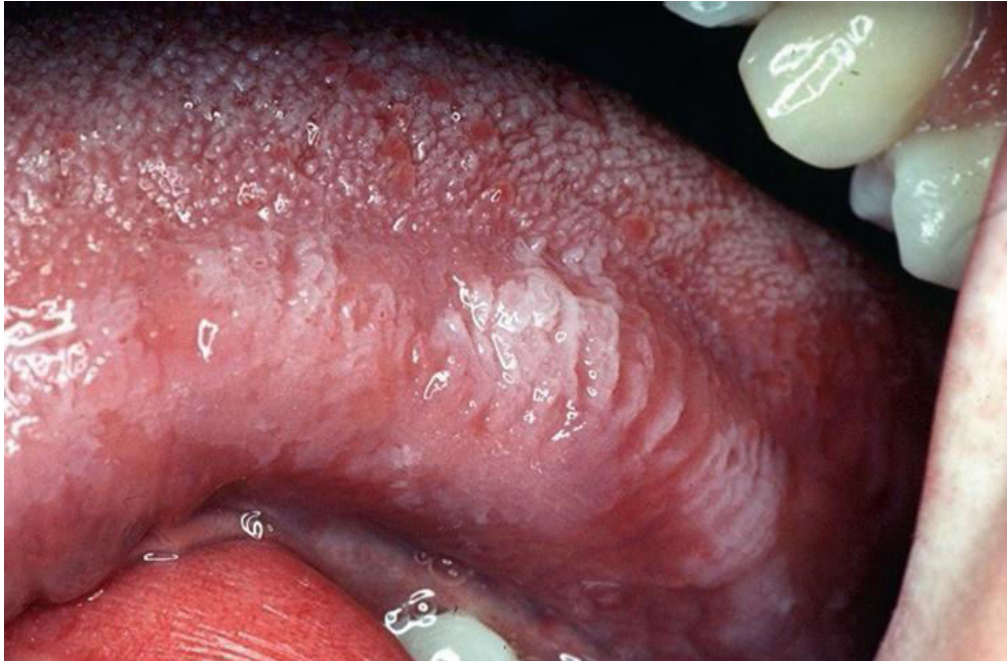- They are known to interact with warfarin, leading to an increased bleeding propensity.
- Topical application as the azoles **are fully or partly resorbed from the GIT.**
- **Development of resistance** is particularly compelling for **fluconazole** in individuals with HIV disease. In such cases, **ketoconazole and itraconazole** have been recommended as alternatives.
- The **azoles** are also used in the treatment of secondary oral candidiasis associated with systemic predisposing factors and for systemic candidiasis.

**Prognosis of oral candidiasis** is good when predisposing factors are reduced or eliminated.

**Persistent chronic plaque-type** and **nodular candidiasis** have been suggested to be associated with an increased risk for **malignant transformation** compared with leukoplakia, not infected by candidal strains.

## **Oral Hairy Leukoplakia**

- ❖ Is the second most common HIV-associated oral mucosal lesion. HL has been used as a marker of disease activity since the lesion is associated with low CD4+ T-lymphocyte counts.
- ❖ The lesion is not pathognomonic for HIV disease since other states of immune deficiencies, such as caused by immunosuppressive drugs and cancer chemotherapy
- ❑ Is strongly associated with Epstein-Barr virus (EBV) and with low levels of CD4+ T lymphocytes.
- ❖ Antiviral medication, which prevents EBV replication, is curative
- ❑ In AIDS, the prevalence may be as high as 80%.
- ❑ In children the prevalence is lower compared with adults (2%).
- ❑ Is more frequently in men.
- ❑ A correlation between smoking and OHL has also been observed



Hairy leukoplakia at the left lateral border of tongue in an AIDS patient showing vertical keratotic corrugations.



## Clinical Findings

- ✓ Is frequently encountered on the lateral borders of the tongue but may also be observed on the dorsum and in the buccal mucosa
- ✓ is asymptomatic, although symptoms may be present when the lesion is superinfected with candidal strain.

## Diagnosis

A diagnosis of OHL is usually based on clinical characteristics, but histopathologic examination and detection of EBV can be performed to confirm the clinical diagnosis.

## Management

- It can be treated successfully with antiviral medication.
- The disorder may show spontaneous regression.

## Measles or Rubeola

It's an acute contagious viral disease affecting children.

This disease shows rash on skin and oral mucosa with fever and lymphadenopathy.

Rash appears first on face, hair line, behind ear, neck, chest, back and extremities. It starts with fever, headache, nausea, cough, conjunctivitis, photophobia and lacrimation and followed by the oral and skin lesions.

Oral lesions appear as small specks (bluish-white) with red erythematous border on **buccal mucosa called Koplik's spot.**

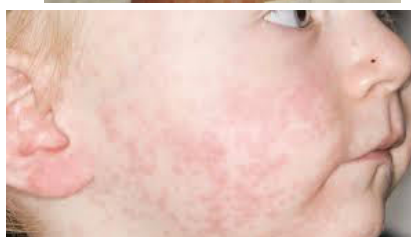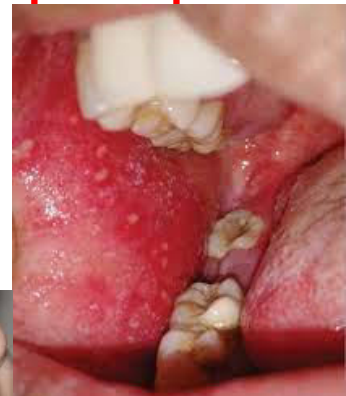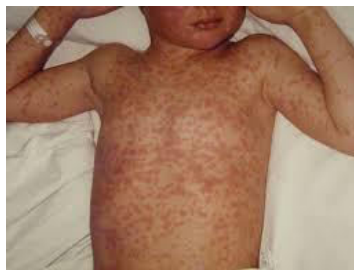Its pathognomonic in 97% of cases.

## Diagnosis

- Clinically
- laboratory

## Treatment:

- ❖ Bed rest
- ❖ Good diet
- ❖ Symptomatic treatment.





# Red & White Lesions

## Lecture 2

### Oral Potentially Malignant Disorders (PMD)

Potentially malignant lesions involves different genetic events. This concept is supported by the fact that markers of genetic defects are differently expressed in different leukoplakias and erythroplakias.

Activation of oncogenes

Deletion And Injuries to Suppressor Genes and Genes Responsible For DNA Repair will all contribute to a defective functioning of the genome that governs cell division.

- ❖ Following a series of mutations, a malignant transformation may occur.
- ❖ Carcinogens such as tobacco may induce hyperkeratinization, tobacco-associated leukoplakia; which is reversible following cessation, but at some stage, mutations will lead to an unrestrained proliferation and cell division.

### Leukoplakia

is currently defined as “a white patch or plaque that cannot be characterized clinically or pathologically as any other any other disease” WHOdisease” WHO.

### Clinical Features

Leukoplakia is associated with a middle-aged and older adults, with the vast majority of cases occurring in persons over the age of 40 years.

### Sites of Leukoplakia

The floor of the mouth and the lateral borders of the tongue have been considered high-risk sites for malignant transformation

- \* The tongue ,buccal mucosa, account for almost half of leukoplakias today.
- \* The palate, maxillary ridge, and lower lip less frequently involved,
- \* The floor of the mouth and retromolar sites are involved infrequently, however, any site can be involved on occasion.

## Etiology of leukoplakia

### ✓ Local factors

- ☐ Tobacco
  - Smokeless tobacco
    - Chewable
    - Snuff
  - Smoking tobacco
    - ❖ Cigar
    - ❖ Cigarette
    - ❖ Pipe
- ☐ Alcohol.
- ☐ Chronic irritation.
- ☐ Candidiasis.
- ☐ Galvanism or Electromagnetic reaction.

### ✓ Regional and systemic factors

- ❖ Syphilis.
- ❖ Vitamin deficiency. A. B-complex.
- ❖ Nutritional deficiency. Sideropenic anemia.
- ❖ Xerostomia.
- ❖ Drugs. Anticholinergic. anti-metabolic.
- ❖ Virus. Herpes Simplex V. Human Papilloma V.
- ❖ Hormones.
- ❖ Idiopathic.

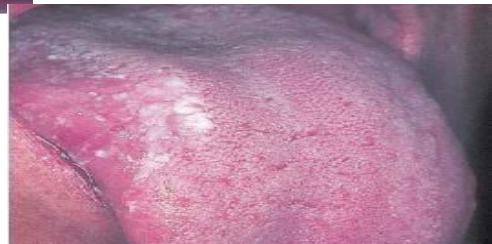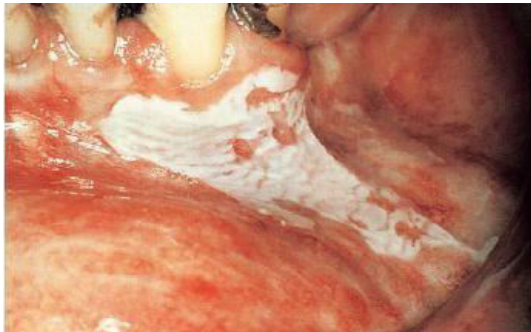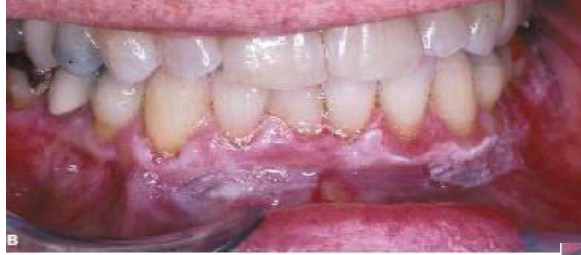## Subtypes of leukoplakia

Many varieties of leukoplakia have been identified.

- ☐ Homogeneous Leukoplakia Or “Thick Leukoplakia”
- ☐ Nodular (Speckled) Leukoplakia
- ☐ Verrucous Leukoplakia Or “Verruciform Leukoplakia”
- ☐ Proliferative Verrucous Leukoplakia (PVL)

## ***Homogeneous leukoplakia” or “thick leukoplakia***

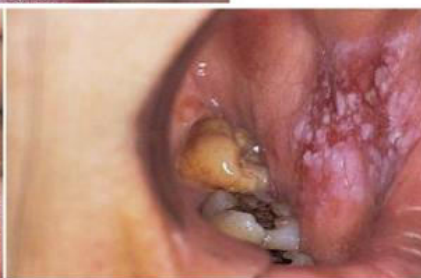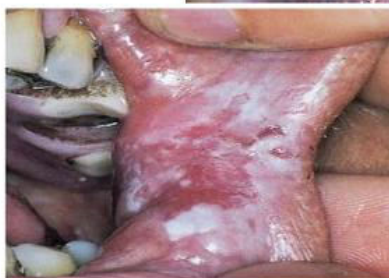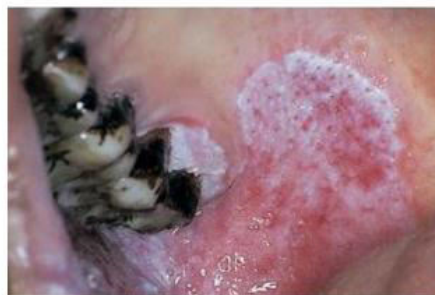Refers to a usually well- defined white patch, localized or extensive that is slightly elevated and that has a fissured, wrinkled, or corrugated surface.



## ***Nodular (speckled) leukoplakia is granular or nonhomo-geneous***

***The name refers to a mixed red and white lesions in which keratotic white nodules or patches are distributed over an atrophic erythematous background.***

***This type of leukoplakia is associated with a higher malignant transformation rate, with up to two -thirds of the cases in some series showing epithelial dysplasia or carcinoma.***



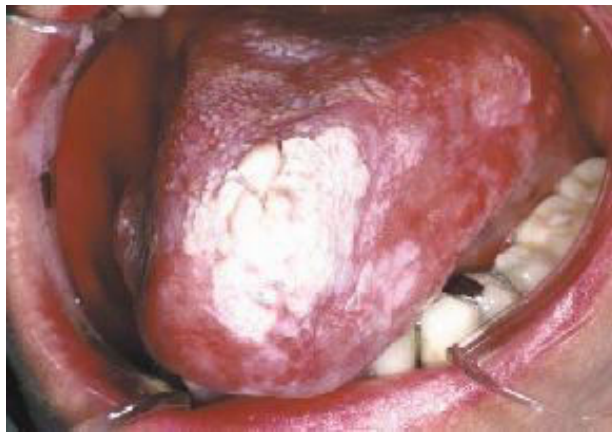

## *“Verrucous leukoplakia or “verruciform leukoplakia*

**Verrucous leukoplakia** is a term used to describe the presence of **thick white lesions with papillary surfaces** in the oral cavity.

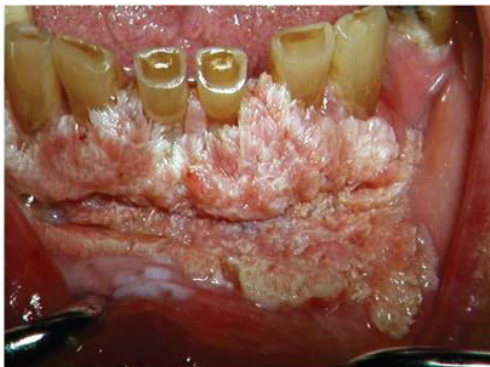
These lesions are usually heavily keratinized and are most often seen in older adults in the sixth to eighth decades of life.

Some of these lesions may exhibit an exophytic growth pattern

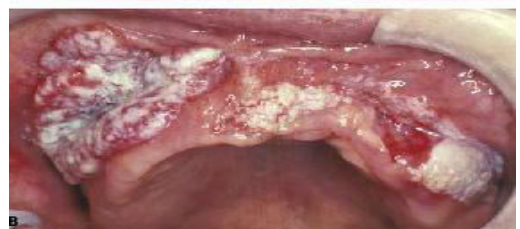
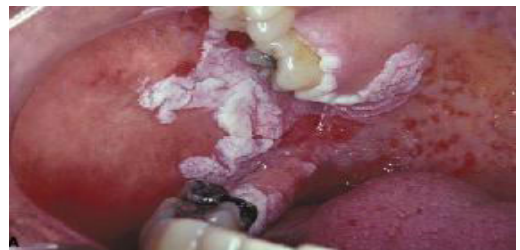
## *Proliferative verrucous leukoplakia*

- The lesions of this special type of leukoplakia have been described as extensive papillary or verrucoid white plaques that tend to slowly involve multiple mucosal sites in the oral cavity and transform into squamous cell carcinomas over a period of many years.
- PVL has a very high risk for transformation to dysplasia, squamous cell carcinoma or verrucous carcinoma.



A proliferative verrucous leukoplakia in an 80-year-old woman





# Diagnosis of leukoplakia

1. Clinical diagnosis

2. Biopsy.

## Treatment of leukoplakia

\* Elimination of etiological factors.

\* Vitamin therapy.

Vitamin A, E and B complex.

\* Conventional surgery.

\* Cryosurgery.

\* Laser ablation.

### Oral erythroplakia

Erythroplakia is a red patch that cannot be characterized clinically or pathologically as any other definable disease.

Oral erythroplakia is not as common as oral leukoplakia, and the prevalence has been estimated to be in the range of 0.02 – 0.1%.

❖ The gender distribution is reported to be equal

**Erythroplakia** is defined as a red lesion of the oral mucosa that excludes other known pathologies.

Erythroplakia is usually asymptomatic, although some patients may experience a burning sensation with food intake.

A special form of erythroplakia has been reported that is related to reverse smoking of chutta, predominantly practiced in India

Both those diagnoses thus require exclusion of other similar-looking lesions of known causes or mechanisms before being applied.

## *Erythroplakia (Erythroplasia)*

*Has been defined as a "bright red velvety plaque or patch which can not be characterized clinically or pathologically as being due to any other condition."*

*It is uncommon in the mouth but carries the highest risk of malignant transformation and lesions are often already malignant on first biopsy.*

*Erythroplakia occurs predominantly in older men, in the sixth and seventh decades of life.*

*Erythroplakias are more commonly seen on the floor of the mouth  
the ventral tongue  
the soft palate, and  
the tonsillar fauces,*

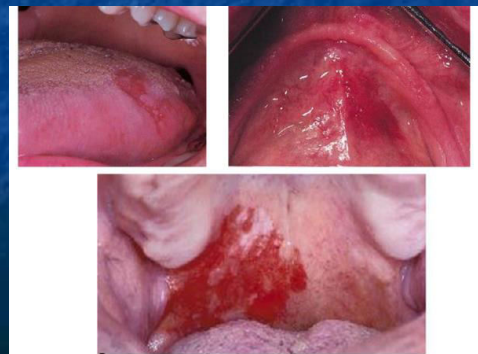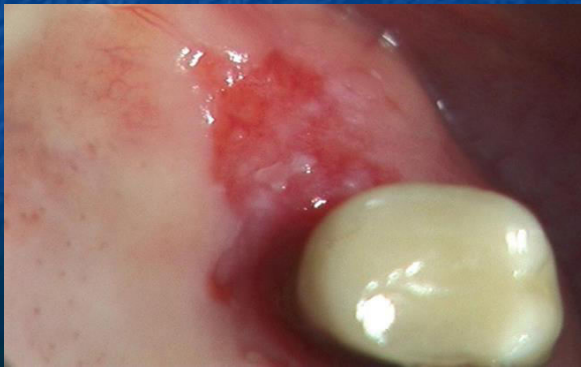## Clinical Features

Several clinical variants of erythroplakia have been described, but there is no generally accepted classification.

### Homogeneous erythroplakia

Erythroplakia interspersed with patches of leukoplakia

### Granular or speckled erythroplakia



“

### Diagnosis of erythroplakia

1. Clinical diagnosis.
2. Toluidine blue test.
3. Laboratory diagnosis.

### Treatment of erythroplakia

1. Removal of the a suspected irritants.
  2. Surgical excision.
  3. Laser ablation.
  4. Cryotherapy.
  5. Clinical follow up.
- Every 3months..for 1st postoperative year.  
Every 6months for an additional 4 yrs.

- ❖ **Oral leukoplakia may be found at all sites of the oral cavity**
- ❖ **Non-smokers have a higher percentage of leukoplakias at the border of the tongue compared with smokers.**

The relative importance of one versus the other is that leukoplakia is very common and can sometimes transform into cancer, whereas erythroplakia is rather uncommon but frequently represents a precursor to cancer.

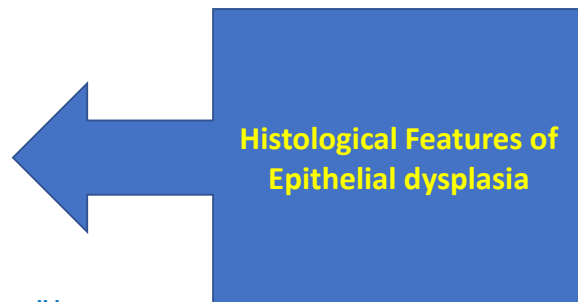It has been reported that 91% of histologically assessed erythroplakias showed invasive carcinoma or carcinoma in situ, and in 9% there was moderate to severe dysplasia.

Another study showed that severe dysplasia and frank carcinoma in 75% and mild to moderate dysplasia in 25%.

**Dysplasia** may be found in homogeneous leukoplakias but is much more frequently in non-homogeneous leukoplakias and in erythroplakias.

**Epithelial dysplasia** is defined in general terms as a precancerous lesion of stratified squamous epithelium characterized by cellular atypia and loss of normal maturation.

- Loss of polarity of basal cells.
- Basaloid appearance in more than one layer of cells
- An increased nuclear-cytoplasmic ratio
- Drop-shaped rete pegs
- Irregular epithelial stratification
- Increased number of mitotic figures
- Mitotic figures in the superficial half of the epithelium
- Cellular polymorphism
- Nuclear hyperchromatism
- Enlarged nucleoli
- Reduction of cellular cohesion
- Keratinization of single cells or cell groups in the prickle cell layer



**Carcinoma in situ** is defined as a lesion in which the full thickness of squamous epithelium shows the cellular features of carcinoma without stromal invasion.

Since **alcohol and smoking** are well-established risk factors for the development of oral squamous cell carcinomas, measures should be taken to influence the patients to discontinue such habits.

surgical excision, as well as laser surgery, is widely used to eradicate leukoplakias and erythroplakias but will not prevent all premalignant lesions from malignant development.

-

However, in the absence of evidenced-based treatment strategies, **Surgery** will remain the treatment of choice for oral leukoplakias and erythroplakias.

### **Malignant transformation of oral leukoplakias; 1–20% over 1 - 30 years**

**Homogeneous leukoplakias are associated with a decreased risk for malignant transformation than nonhomogeneous and erythroplakia.**

## Oral Submucous Fibrosis (OSF)

Is a chronic disease affecting the

- Oral Mucosa,
- Pharynx
- Upper Two-thirds Of The Esophagus

### Etiology of OSF

The use of chilies have been thought to play an etiological role in OSF.

- ✓ Tobacco
- ✓ Betel nut
- ✓ Nutritional deficiency

**Areca nuts** in the etiology behind oral submucous fibrosis.

Areca nut–derived products are commonly used in India & other Asian people. It is widespread in India, Pakistan, Bangladesh, and Sri Lanka and in immigrants coming from these regions.

- There is dose dependence between **areca quid chewing habit** and the development of this oral mucosal disorder.

Areca nuts **contain alkaloids. coline** seems to be a primary etiologic factor. **Arecoline** has the capacity to modulate **matrix metalloproteinases, lysyl oxidases, and collagenases**, all affecting the **metabolism of collagen**, which leads to an **increased fibrosis**.

- During the development of fibrosis, a **decrease** in **water-retaining proteoglycans** will occur in favor of **increased** collagen type I production.

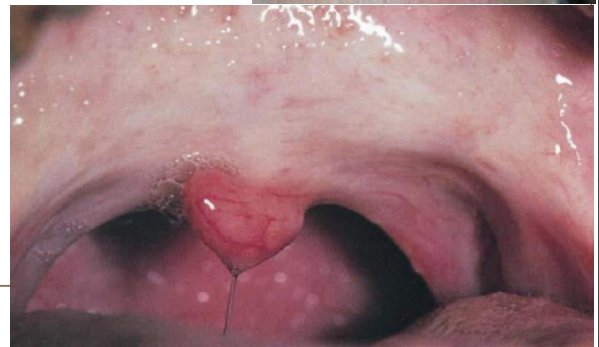
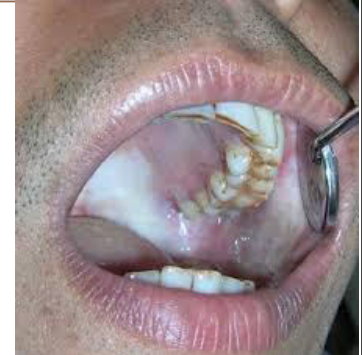

Oral complications are most commonly observed: on the lips, buccal mucosa, retromolar area, and soft palatal mucosa.

- The global incidence estimated at 2.5 million individuals.
- The prevalence in Indian populations is 5% for women and 2% for men.
- Individuals in less than 20 years old seem to be affected more commonly.

## **Clinical Findings**

- The **First Signs** are erythematous lesions, sometimes in conjunction with petechiae, pigmentations, and vesicles.
- Followed by a paler mucosa, (white)
- The most prominent clinical characteristics include fibrotic bands located beneath an atrophic epithelium.
- Increased fibrosis eventually interferes with speech, tongue mobility, and a decreased ability to open the mouth.
- The atrophic epithelium may cause inability to eat hot and spicy food.



## **Diagnosis**

The diagnosis of oral submucous fibrosis is based on the

- **Clinical Characteristics**
- **The Patient's Report Of A Habit Of Betel Chewing.**
- **An international consensus** has been reached where at **least one** of the following characteristics should be present :
  - **Palpable fibrous bands**
  - **Mucosal texture feels tough and leathery**
  - **Blanching of mucosa together with histopathologic features consistent with oral submucous fibrosis.**(atrophic epithelium with loss of rete ridges.)



## **Management**

Treatment of oral submucous fibrosis should be focused on

➤ **cessation of the chewing habits.**

If this is successfully implemented, early lesions have a good prognosis as they may regress.

**Several treatment strategies have been tried, such as:**

- **Topical and systemic steroids,**
- **Hyaluronidase.**
- **interferon-γ,**
- **Supplement of vitamins and nutrients,**
- **Repeated dilatation with physical devices,**
- **Surgery.**
- **Restriction of habits.**
- **Placental extract.**
- **Laser.**

None of these treatments have reached general acceptance and the long-term results are uncertain.

Malignant transformation of oral submucous fibrosis has 0.7–1.3% and the incidence over a 10-year period at approximately 8%.

## **Immunopathologic Diseases Lichen Planus**

It's a chronic Mucocutaneous disorder that involve the skin and mucous membranes.

It is a family of lesions with different etiologies with a common clinical and histologic appearance.

Neither clinical nor histopathologic features enable discrimination between different lichenoid reactions but may be used to distinguish them from other pathologic conditions of the oral mucosa.

This group include the following disorders:

- **Oral lichen planus**
- **Lichenoid contact reactions**
- **Lichenoid drug eruptions**
- **Oral Lichenoid reactions of graft-versus-host disease (GVHD)**

These lesions represent a delayed hypersensitivity reaction to constituents derived from dental materials or flavoring agents in foods and other ingested substances

## Oral Lichen Planus

- ✓ The etiology is not known
- ✓ it has become evident that the **immune system** has a primary role in the development of this disease.
- ✓ This is supported by the histopathologic characteristics of a subepithelial band–formed infiltrate dominated by **T lymphocytes** and **macrophages**, and **the degeneration of basal cells** known as **liquefaction degeneration**

**Cytotoxic CD8+ T lymphocytes** are responsible for **apoptosis of the keratinocytes in the basal cell layer**. These lymphocytes are a major component of the subepithelial inflammatory infiltrate in the mucosal lamina propria.

- ✓ These features can be interpreted as an expression of the cell-mediated arm of the immune system being involved in the pathogenesis of OLP through **T-lymphocyte cytotoxicity directed against antigens expressed by the basal cell layer**.
- ✓ It is not possible to identify a single etiologic factor behind OLP.

**Other factors, such as stress**, may also be of importance to establish this inflammatory process.

Altogether, this makes the etiology behind OLP a multifactorial process

### Lichen planus Relation to systemic diseases

- During recent years, an association between OLP and hepatitis C virus (HCV) has been described in populations from Japan and some Mediterranean countries. This association has not been observed in northern European countries or the United States. Arabic countries.
- Diabetes mellitus
- Vascular hypertension
- Lupus erythematosus

**Diabetes mellitus + Vascular hypertension + OLP**  
is called (Grinspan's syndrome.)

- **Prevalence** ---- 0.5 – 2.2%
- **Gender** ---- women is higher than that of men,
- **Age** ----The condition usually occurs in people **older than 40 years**.

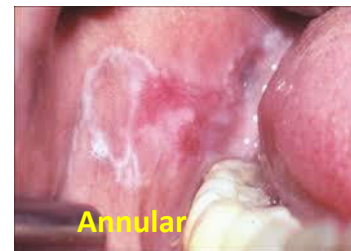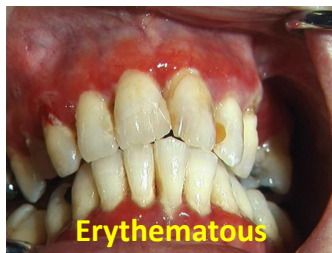
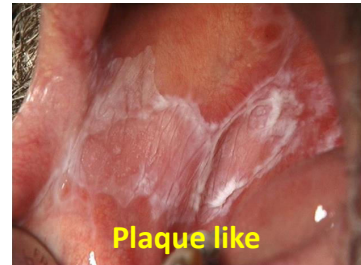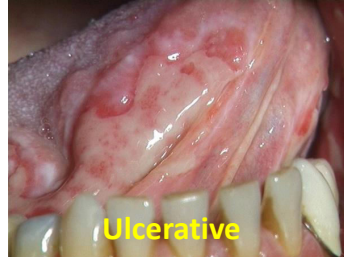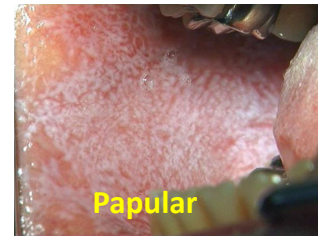
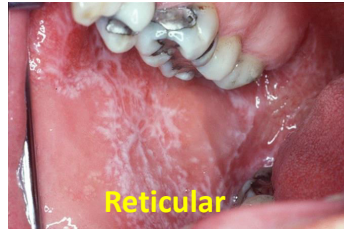
It is very rarely encountered in children,

Does not seem to have a hereditary predisposition.

## Clinical Findings

OLP may contain both red and white elements which can be a part of the following clinical types:

- Reticular form
- Papular
- Plaques or leukoplakia like
- Erosive or ulcerative
- Linear
- Annular
- Desquamative gingivitis
- Bullous
- Erythematous or Atrophic
- Atrophic glossitis

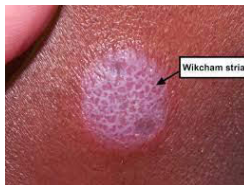

OLP confined to the gingiva may be entirely erythematous, with no reticular or papular elements present, and this type of lesion has to be confirmed by a biopsy.

The explanation of the different clinical manifestations of OLP is related to the magnitude of the subepithelial inflammation.

A mild degree of inflammation provoke the epithelium to produce hyperkeratosis, whereas more intense inflammation will lead to partial or complete deterioration of the epithelium.

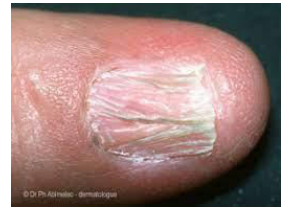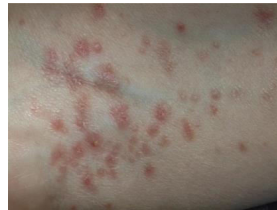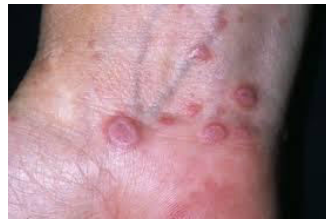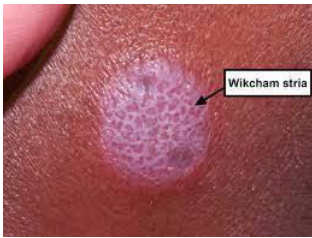- Typically, OLP is bilateral (symmetric) and can appear both white and red, depending on disease activity
- Hyperkeratotic white striations **Wickham's striae**, which are a hallmark of the condition.



- Typically, the **reticular, papular, and plaque-like** are **asymptomatic**, although the patient may experience a **feeling of roughness**.
- The **bullous** form is very unusual but may appear as bullous structures surrounded by a reticular network.
- Erythematous**. (atrophic) OLP is characterized by a homogeneous red area. when this type of OLP is present in the buccal mucosa or in the palate, striae are frequently seen in the periphery of the lesion.
- Ulcerative**. lesions are the most disabling form of OLP  
Clinically, the fibrin-coated ulcers are surrounded by an erythematous zone with white striae in the periphery.

## Clinical Manifestation

❖ Cutaneous lesions may be seen in approximately 15% of patients with OLP.



The classic appearance of **skin lesions** consists of

**Pruritic Erythematous Flat Topped Papules.**

The predilection sites are the trunk and flexor surfaces of arms and legs.

following intense scratching of the lesions, trauma may aggravate the disease, which is referred to as a Koebner phenomenon (appearance of new skin lesions on previously unaffected skin secondary to trauma).

This phenomenon may also be of relevance for OLP, which is continuously exposed to physical trauma during mastication and brushing

❖ The most frequent **extra-oral mucosal** site involved is the **genital mucosa**; 20% of women presenting with OLP also have genital involvement.

Symptoms including burning, pain, vaginal discharge.

❖ **Esophageal lichen planus** has been described to occur simultaneously with OLP in some patients, the main complaint being dysphagia

**Nail lesion** is rare when it occurs there is longitudinal grooving of the nail plate and in few cases destruction of the nail.

## Diagnosis of OLP

- History
- Clinical examination
- Biopsy
- I.F. Techniques.

Direct      Indirect.

Shaggy band of fibrinogen in basement membrane zone.

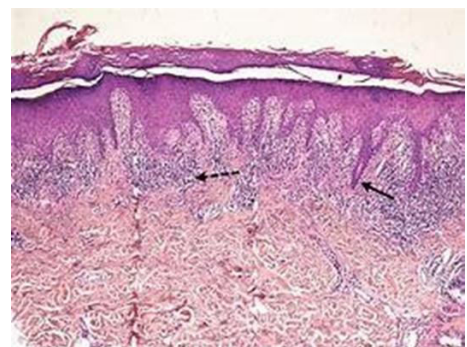
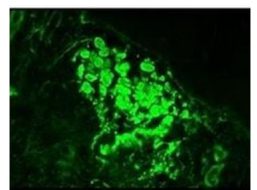
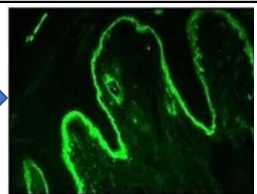
**Multiple IgM staining cytoid bodies usually located in the dermal papilla or in the peribasilar area**

Papules or reticular components have to be present in order to establish a correct clinical diagnosis.

These pathognomonic components may exist together with plaque-like, erythematous, bullous, or ulcerative lesions

In patients with gingival erythematous lesions, it may be difficult to find striae or papules.

A biopsy is usually required for an accurate diagnosis of this type of OLP.



## **Oral lichenoid drug eruptions (OLDE )**

have the same clinical and histopathologic characteristics as OLP.

- The patient's history may give some indication as to which **drug** is involved, **but lichenoid drug eruptions may not start when the drug was first introduced.**
- **Withdrawal** of the drug are the most reliable ways to diagnose lichenoid drug eruptions
- An OLDE may not develop for several months after a new drug is started.
- It may also take **several weeks** before an OLDE disappears following withdrawal

**Oral GVHD** has the same clinical appearance as OLP, but the lesion is usually more generalized.

- The **lichenoid reactions** are frequently seen with other characteristics, such as  
**Xerostomia.**  
**Localized Skin Involvement.**  
**Liver Dysfunction.**

## **Examples of drugs which have been associated with lichenoid reactions.**

- ✓ Angiotensin-converting enzyme inhibitors
- ✓ **Antimalarials**
- ✓ Barbiturates
- ✓ Colchicine
- ✓ Dapsone
- ✓ Gold
- ✓ Hydroxychloroquine
- ✓ **Metformin**
- ✓ Nonsteroidal anti-inflammatory drugs
- ✓ Penicillamine
- ✓ Phenothiazines
- ✓ Phenytoin
- ✓ Sulfonamide
- ✓ Tetracyclines



Oral mucosal lesions that do not belong to the group of lichenoid reactions may sometimes comprise a differential diagnostic problem

**1. Discoid Lupus Erythematosus (DLE)**

shows white radiating striae sometimes resembling those of **OLP**.

The striae present in DLE are typically more prominent, with a more marked hyperkeratinization, and the striae may abruptly terminate against a sharp demarcation.

**2. Plaque-like OLP** is discriminated from **Homogeneous Oral Leukoplakia** as the latter is not featured with papular or reticular elements.

**3. Erythematous OLP of the gingiva exhibits** a similar clinical presentation as **Mucous Membrane Pemphigoid**.

In pemphigoid lesions, the epithelium is easily detached from the connective tissue by a probe or a gentle searing force (Nikolsky's phenomenon).

A biopsy for routine histology and direct immunofluorescence are required for an accurate differential diagnosis.

**4. Ulcerating conditions** such as **Erythema Multiforme** and **adverse reactions to non-steroidal anti-inflammatory drugs (NSAIDs)** may be difficult to distinguish from **ulcerative OLP**.

The former lesions, however, do not typically appear with reticular or papular elements in the periphery of the ulcerations.

## Management

Since the etiology behind OLP is unknown, basic conditions for development of preventive therapies are lacking.

Current therapies are directed against

- (1) Immune mechanisms using immunosuppressives.
- (2) The cellular inflammatory response using anti-inflammatories.
- (3) Reducing or eliminating symptoms.

➤ Careful oral hygiene to reduce biofilm-associated supplementary inflammation is extremely important in OLP patients with symptoms

➤ **Several topical drugs have been suggested, including**

➤ **Steroids**

➤ **Retinoids**

➤ **Ultraviolet Phototherapy**

➤ **topical steroids** are widely used and accepted as the primary treatment of choice

➤ **Potent Steroids** as **Clobetasol Propionate**

➤ **Intermediate Steroids** such as **Triamcinolone Acetonide**.

➤ **Cyclosporine** may be considered a second choice.

➤ **Tacrolimus** should only be used when symptomatic OLP lesions are recalcitrant to topical steroids.



## Topical steroids

- Mouth Rinse Or Gel.

2 - 4 times a day for 1 -2 months, followed by tapering during the following 8 weeks until a maintenance dose of 2 -3 times a week is reached.

- When potent topical steroids are used, a fungal infection may emerge, and antifungal treatment may be used before treatment with steroids.
- **Widespread Lesions,**
  - **Betamethasone mouthwash** is more useful.
  - **Dexamethasone 0.5 mg/5 ml** rinse can be applied 3 times a day for 3 minutes, gradually decreasing the number of applications following the improvement.
- Adhesive pastes consisting of **pectin, gelatin, and carboxymethyl cellulose (Orabase)** containing **topical steroids** (e.g., **triamcinolone**) have been formulated for use on moist oral mucosal surfaces (**Kenalog in orabase**).
- Ointments containing steroids can also be effective (require drying of the mucosal surface before application).
- Topical application of Cyclosporine and Tacrolimus has been suggested as a substitute topical therapy in OLP patients who develop candidiasis

However, before switching to systemic steroids, the use of peri- or intralesional steroids should be considered.

Usually,

0.2–0.5 mL of 40 mg/mL methyl prednisolone

or triamcinolone suspension is injected around and under the erosive lesion.

### Systemic Therapy

Systemic Steroids used to control symptoms from recalcitrant lesions. A dose of 0.5–1 mg/kg prednisolone daily for 7 days has been suggested, followed by a reduction of 5 mg each subsequent day. Maintenance dose with topical steroids may be commenced during tapering of systemic steroids.

#### Erythematous OLP of the gingiva

Remove both sub- and supragingival plaque and calculus.

Thus, oral hygiene should be optimized prior to the beginning of steroid treatment.

If symptoms persist, steroid gels in prefabricated plastic trays may be used for 30 minutes at each application to increase the concentration of steroids in the gingival tissue.

# Management

## Drug-Induced Lichenoid Reactions

- ✓ Discontinuance of the drug and symptomatic treatment with topical steroids are often sufficient.
- ✓ The patient should be properly educated about the responsible drug to prevent future reaction.

## Lichenoid Reactions of GVHD

- ❑ The major cause of GVHD is **allogeneic hematopoietic cell**
- ❑ Oral lichenoid reactions as part of GVHD may be seen both in
  - ❑ acute
  - ❑ chronic GVHD transplantation
  - ❑ Clinically

are indistinguishable from OLP, that is, reticulum, erythema, and ulcerations, but lichenoid reactions associated with GVHD are typically associated with a more widespread involvement.

- ❑ It is not possible to distinguish between OLP and oral GVHD based on clinical and histopathologic features.
- ❑ **Topical Steroid Preparations**, such as **fluocinonide and clobetasol gel**.
- ❑ Opportunistic infections such as candidiasis should always be considered in immunosuppressed patients.
- ❑ The development of secondary malignancies has been recognized as a potentially serious complication of GVHD.
- ❑ Patients with a history of oral GVHD should therefore be examined for oral malignancies as part of the medical follow-up

## Malignant transformation of OLP

- A recent systematic review pooled 7806 OLP patients from 16 follow-up studies on the risk of malignant transformation showed a wide variations of ( **0.03% to 1.3%**).

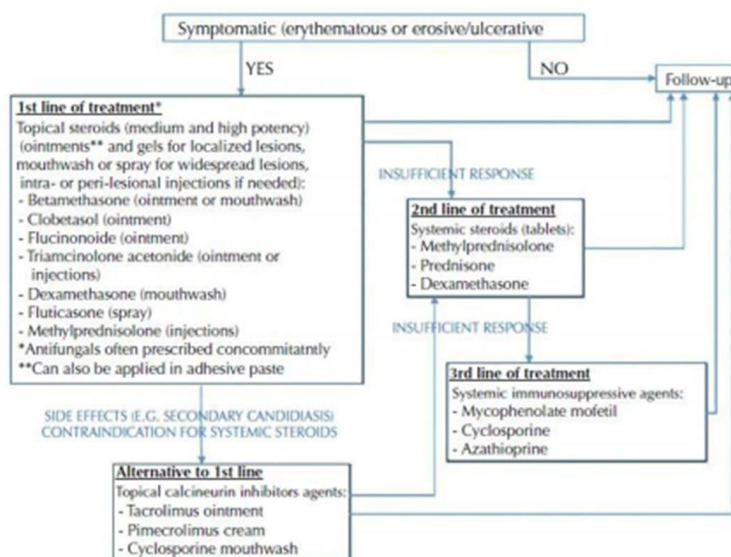


Figure 4-43 Algorithm for the management of oral lichen planus. Treatment is dependent on symptoms, the oral disease severity score, and previous response to therapy.

## Lupus erythematosus

It's a chronic immunologically mediated inflammatory condition of skin, c.t and specific internal organs. It occurs in **3 clinical form** that represent the severity and distribution of involvement.

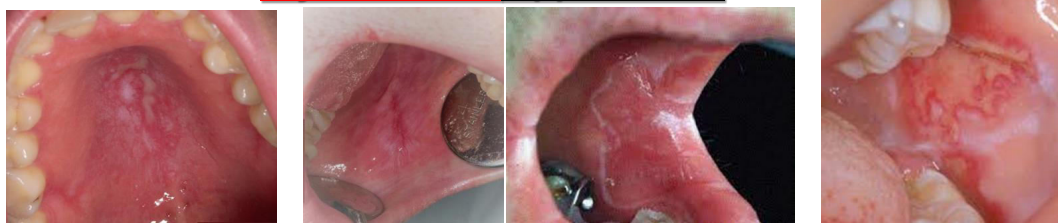- ✓ **The mildest form is called Discoid L.E.** & it's chronic lesions confined to the sun exposed skin of the face scalp, ears & oral mucosa.
- ✓ **The intermediate form is called acute cutaneous L.E.** & it's more wide spread & affects the head, neck, upper trunk & extensor surfaces of the arm.
- ✓ **The severest form is called systemic L.E** & it involves many organs such as kidneys, heart, lung & bone marrow.
- ❖ **Both the natural and the adaptive parts of the immune system** are participating, with the latter involving both **B and T lymphocytes**
- ❖ **Environmental factors** as **sun exposure, drugs, chemical substances, and hormones** which all have been reported to aggravate the disease.
- ❖ **A genetic predisposition** is supported by an elevated risk for siblings to develop LE
- ❖ **More than 80 different drugs** have been associated with the onset of SLE, including **hydralazine, methyldopa, chlorpromazine, isoniazid, quinidine, and procainamide**
- ❖ SLE predominantly affects **women of reproductive age**, and **decreases during the menopause.**
- ❖ In the interval of **20–40 years**, as much as 80% of cases have been reported to be **women.**

## Lupus Erythematosus (LE)

### The oral lesions

observed in SLE and discoid lupus erythematosus are similar in their characteristics, both clinically & histopathologically.

- The typical clinical lesion comprises **white striae with a radiating orientation**, and these may **sharply terminate toward the center of the lesions**, which has a more **erythematous appearance.**

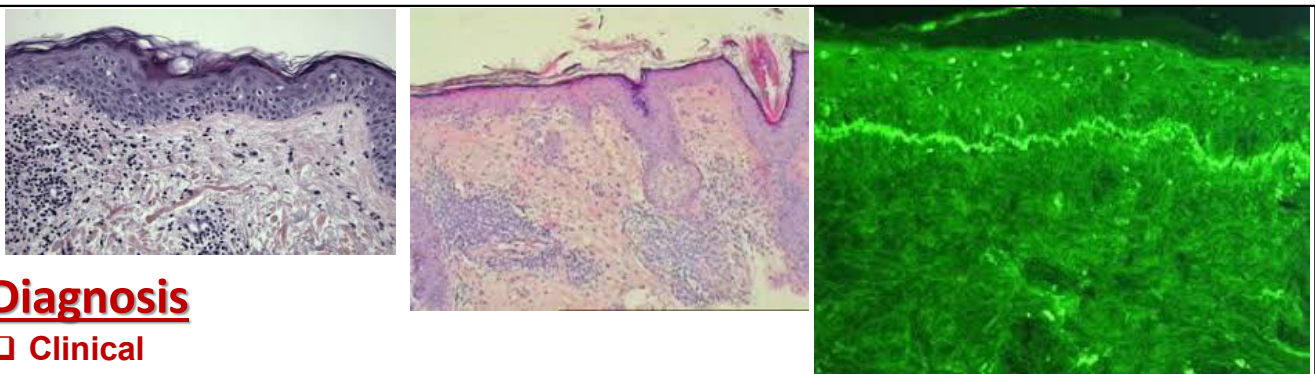
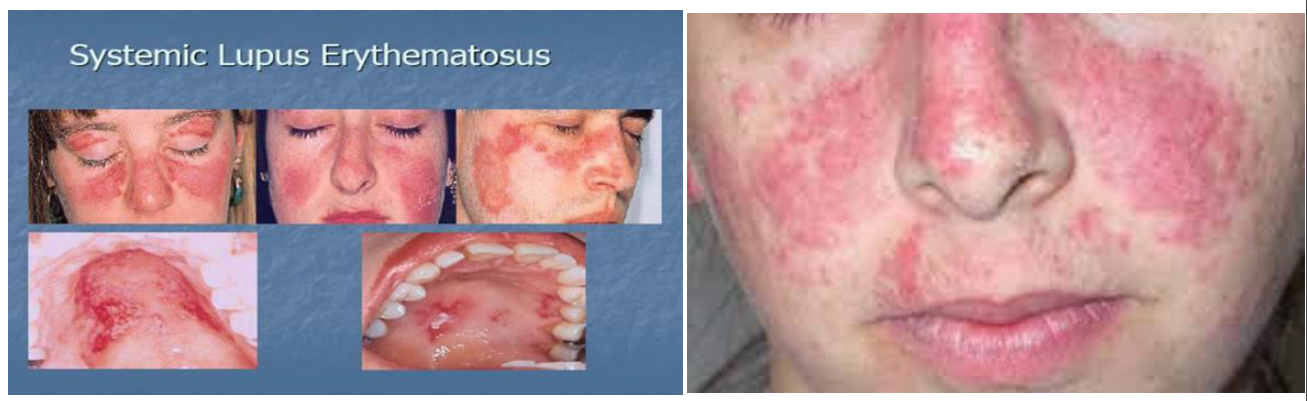

- The most affected sites are the **hard palate, buccal mucosa, and gingiva.** **The tongue** also can be involved.
- The typical oral DLE lesion is a well-demarcated lesion with a mixed center and with a brush border of fine striae around the Lesion. They are usually asymmetric or scattered, in contrast to OLP.
- **Oral mucosa lesions compatible with LE may be the first sign of the disease.**
- Oral mucosal lesions seen in conjunction with different types of Lupus Erythematosus are clinically and histopathologically indistinguishable.

## Cutaneous Lesions Of Lupus

The typical DLE diagnosis comprises well-demarcated cutaneous lesions with round or oval erythematous plaques with scales.

The typical skin lesion of discoid L.E is Butterfly like rashes(malar rash ) distributed on the malar regions and across the bridge of the nose.



## Diagnosis

Clinical

Histopathology

Liquefaction degeneration may also be present, which may result in diagnostic problems in relation to OLP.

I.F... Deposition of antibodies at B.M zone.

Laboratory findings

\*Antinuclear antibodies is positive.

\*Moderate to high titers of anti-DNA and anti-Smith antibodies are almost pathognomonic of SLE.

\*Direct immunohistochemistry to reveal granular deposition of IgM, IgG, IgA, and C3 (lupus band test)

\*Rh factor is positive.

\*Anemia

\*Leukopenia.

\*Thrombocytopenia.

\*ESR is increased

\*False positive serological test for syphilis



## Diagnosis

An SLE diagnosis requires that **Four or more** of the diagnostic criteria should be present at each time point of the disease.

### American college of rheumatology criteria for SLE

1. Malar rash
2. Discoid lesions
3. Photosensitivity
4. Presence of oral ulcers
5. Non-erosive arthritis of two joints or more
6. Serositis
7. Renal disorder
8. Neurologic disorder (seizures or psychosis)
9. Hematologic disorder
  - Hemolytic Anemia
  - Leukopenia,
  - Lymphopenia
  - Thrombocytopenia
10. Immunologic disorder
  - ❖ Anti-DNA
  - ❖ Anti-smith
  - ❖ Antiphospholipid antibodies

## Management

- ✓ Drug of choice is **Corticosteroid**.
- ✓ **Antimalarial drugs**
  - Chloroquine.** 250mg tab twice daily
  - Hydroxy Chloroquine.** 200mg tab twice daily
- ✓ **Retinoids... isotretinoin.**
- ✓ **Laser.**
  
- ✓ The oral lesions may respond to **Systematic Treatment** used to for the disease.
- ✓ When symptomatic intraoral lesions are present, **Topical Steroids** should be considered.
- ✓ The treatment may begin with applications **2-3 times** a day followed by a tapering during the **next 6-9 weeks such as**
  - Clobetasol Propionate Gel 0.05%,**
  - Betamethasone Dipropionate 0.05%,**
  - Fluticasone Propionate Spray 50 µg aqueous solution** are usually require.

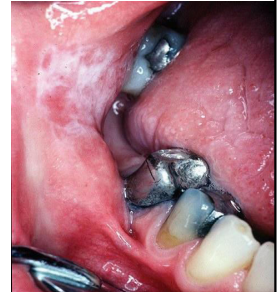**Oral mucosal lesions often mirror the disease activity.**

**They may regress spontaneously but can also persist for months or even years.**

## **ALLERGIC REACTIONS**

### **Oral Lichenoid Contact Reactions**

- Due to a **delayed hypersensitivity reaction** to constituents derived from **dental materials**.
- The majority of patients are **patch test positive to mercury (Hg)**, which lends support to LCR being an allergic reaction.
- Although **Hg** is usually considered the primary etiologic factor, other amalgam constituents may also initiate LCR.
- **Other filling materials such as**
  - **Gold,**
  - **Composites,**
  - **Glass Ionomers may also generate reactions**



### **Clinically**

LCRs display the same reaction patterns as seen in OLP, that is,

**Reticular, Papules, Plaque, Erythematous and Ulcers.**

The most apparent clinical difference between OLP and LCR is the extension of the lesions. The majority of LCRs are confined to sites that are regularly in contact with dental materials, such as the **buccal mucosa and the border of the tongue**. The majority of this type of LCR resolve following treatment with chlorhexidine.

## **Diagnosis**

The diagnosis is primarily based on the topical relationship to dental materials

### **Management Oral Lichenoid Contact Reactions**

Replacement of dental materials in direct contact with LCR will result in cure or considerable improvement in at least 90% of the cases.

**Most lesions should be expected** to heal within **1-2 months**.

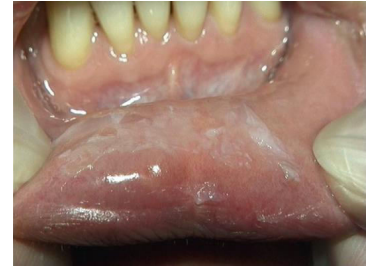There is no need for replacement of restorative materials that are not in direct contact with the LCR.

**Healing does not seem to depend** on what type of dental material is used for replacement.



## Reactions to Dentifrice and Chlorhexidine

- ❑ Delayed hypersensitivity reactions to **toothpastes and mouthwashes** have been reported, but such reactions are rare.
- ❑ **The compounds responsible for the allergic reactions may include**
  - ❖ **Cinnamon**
  - ❖ **Preservatives flavor additives such as carvone**
  - ❖ **Flavoring constituents in chewing gum**
- ❑ **The clinical manifestations include**  
**Red Edematous Gingiva with Ulcerations and White Lesions.**
- ❑ **Similar lesions may involve the**  
**Labial**  
**Buccal**  
**Tongue Mucosa.**
- ❑ The clinical manifestation are characteristic and form the basis of the diagnosis, which is supported by healing of the lesions after withdrawal of the allergen-containing agent.
- ❑ Dentifrice may also cause a **disturbed desquamation**, which clinically can be observed as **thin scaling keratin**.



**Desquamation of the superficial epithelial layers**

## TOXIC REACTIONS

### Reactions to Smokeless Tobacco (ST)

Smokeless tobacco represents a nonhomogeneous group of compounds used with different intraoral application methods.

Three different geographic areas are of special interest:

**South Asia, United States, Scandinavia**

### **In India,**

Tobacco is often used in combination with betel leaf, sliced areca nut, which increases the toxicity of the compound.

**There is a definitive association between this form of smokeless tobacco and oral cancer**

### In the US and Scandinavia

ST can be divided into three different groups:

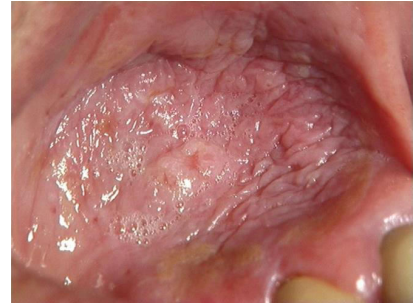- **Chewing Tobacco**
- **Moist Snuff**
- **Dry Snuff**

All three are different regarding composition, manufacturing procedures, and type of consumers

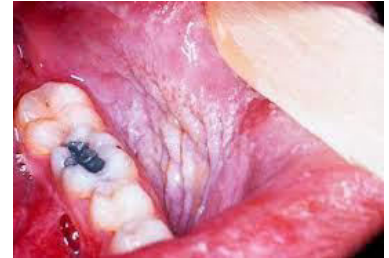

The clinical picture varies in relation to the type, brand, frequency, and duration of use of moist snuff

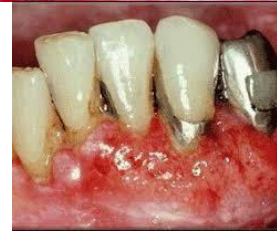- **The mildest form, of the lesion wrinkles at the site of application**
- whereas **high consumers** may display a
  - White lesion with ulcerations
  - Hyperkeratinization
  - Acanthosis
  - Different degrees of subepithelial inflammation.



**Gingival retractions** are the most common adverse reaction with a smokeless tobacco habit. These retractions are irreversible, whereas the mucosal lesion usually regresses within a couple of months.



- Oral mucosal lesions are less frequently observed in association with chewing tobacco compared with moist snuff.



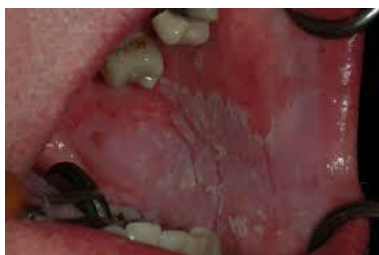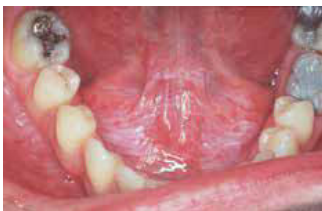**The carcinogenic potential** of smokeless tobacco has been a subject of considerable debate, however, no doubt that smokeless tobacco products contain nitrosamines, polycyclic hydrocarbons, aldehydes heavy metals which all have a potential to cause harm.

**The World Health Organization International Agency for Research on Cancer** established in its report from 2004 that “overall, there is sufficient evidence that smokeless tobacco causes **oral cancer and pancreatic cancer in humans, and sufficient evidence of carcinogenicity from animal studies.**”

In a recent comprehensive review, it is concluded that the use of **moist snuff and chewing tobacco** imposes **minimal risks for cancers** of the oral cavity and other upper respiratory sites, with relative risks ranging from **0.6 to 1.7**

## **Smoker's Keratosis**

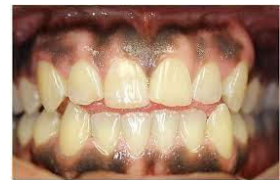- Moderate to heavy tobacco smoking, especially cigarettes but also cannabis, can give rise to reactive keratosis anywhere in the oral cavity, but especially in the palate and sublingually
- Persistence of the lesion after cessation of smoking confirms a sublingual leukoplakia, which must be biopsied due to the high risk of malignant transformation



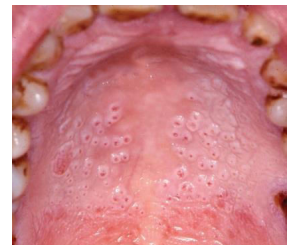## Smoker's Palate

The most common effects of smoking are presented clinically as

- **Dark Brown Pigmentations (Smoker's Melanosis)**
- **White Lesions (Nicotine Stomatitis) Or Smoker's Palate.**



In smoker's palate, an erythematous irritation is initially ---followed by a whitish palatal mucosa reflecting a hyperkeratosis ---As part of this lesion, red dots can be observed representing orifices of accessory salivary glands, which can be enlarged and display metaplasia.

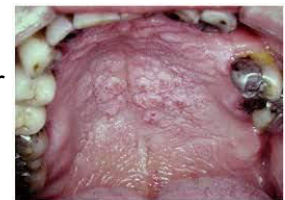

The prevalence of smoker's palate has been reported in the range of 0.1%–2.5%.

Smoker's palate is more prevalent in men  
is a common clinical feature in high consumers of

- Pipe Tobacco**
- Cigarettes**
- Among Individuals Who Practice Inverse Smoking.**

Smoker's palate with pronounced orifices of the salivary glands



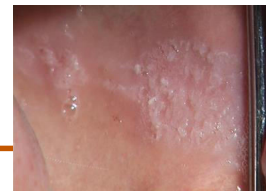The etiology is probably more related to the high temperature rather than the chemical composition of the smoke, although there is a synergistic effect of the two.

## Reactions To Mechanical Trauma Morsicatio (Mucosal Nibbling)

- ❖ Parafunctional behavior (habitual chewing) is done unconsciously and is therefore difficult to bring to an end.
- ❖ Morsicatio is most frequently seen in the buccal and lip mucosa and never encountered in areas that are not possible to traumatize by habitual chewing.
- ❖ Typically, morsicatio does not entail ulcerations but encompasses an asymptomatic shredded area.
- ❖ In cases of more extensive destruction of oral tissues by habitual chewing, a psychiatric disorder should be suspected.
- ❖ The prevalence has been reported to be in the range of 0.5%- 1%
- ❖ Morsicatio is 3 times more common among **women**.

### Diagnosis

is usually made on the clinical appearance alone.

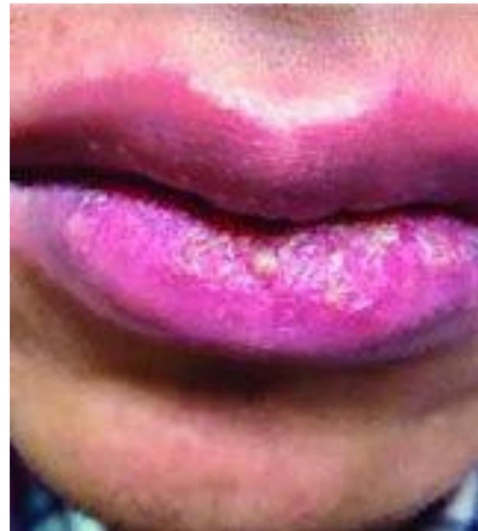
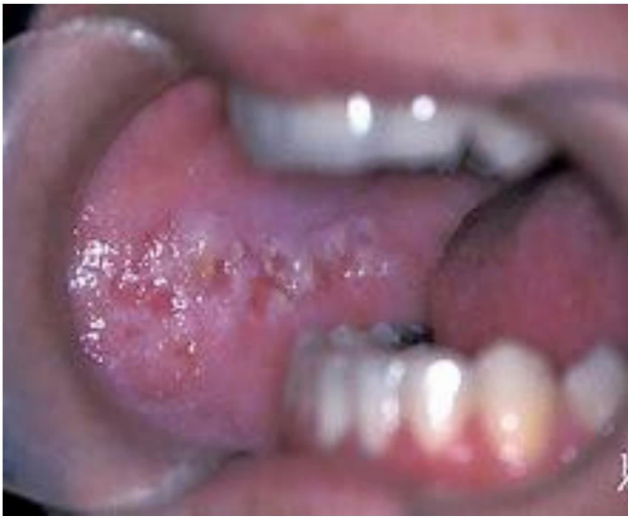
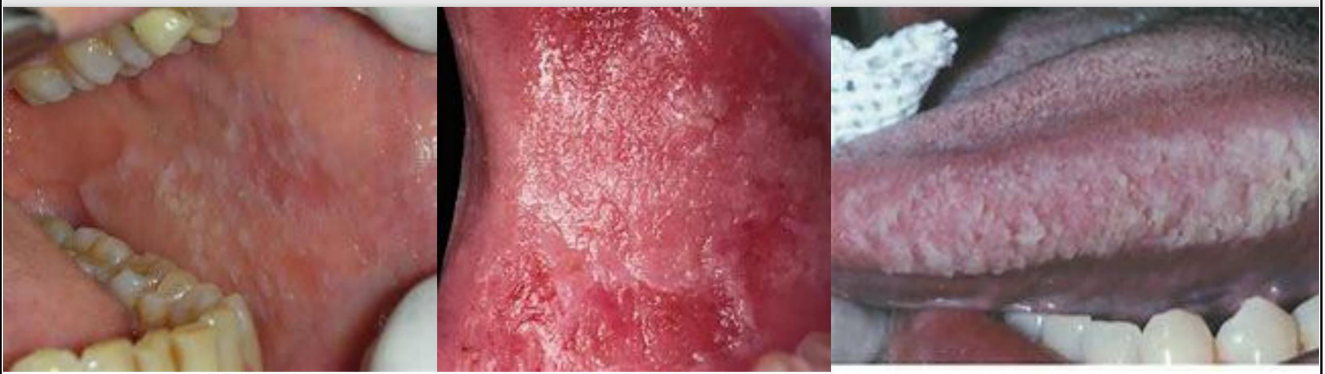
### Management

The lesions are harmless, and no treatment is indicated beyond reassurance, unless the person requests it. The most common and simple treatment is construction of a specially made acrylic prosthesis that covers the biting surfaces of the teeth and protects the cheek, tongue and labial mucosa (an occlusal splint).

The condition does not involve malignant potential





## Frictional Hyperkeratosis

Oral frictional hyperkeratosis is typically clinically characterized by a white lesion without any red elements.

➤ The lesion is observed in areas of the oral mucosa subjected to **increased friction** caused by, for example, food intake

➤ Observed in areas subjected to **increased abrasion**, which **stimulates the epithelium to respond with an increased production of keratin**

➤ The reaction can be regarded as a **physiologic response** to minor trauma

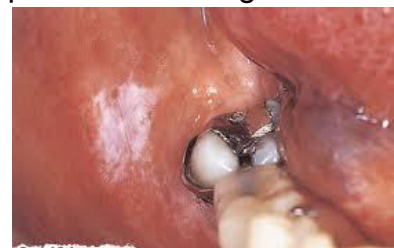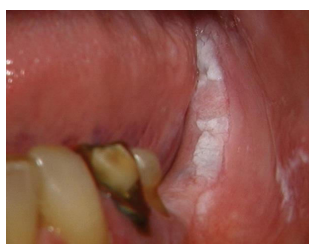➤ **Smoking and alcohol consumption** have been reported as predisposing factors.

- prevalence has been reported to be in the range of 2%–7%.

❑ Frictional hyperkeratosis is often seen in **edentulous areas** of the alveolar ridge.

➤ Asymptomatic but can cause **anxiety** to the patient (supposed as a malignant or premalignant lesion)

Frictional keratosis of the edentulous alveolar ridge.



## The diagnosis

Based on clinical features, frictional hyperkeratosis does not carry any symptoms

If the diagnosis is doubtful, **biopsy** is mandatory to exclude premalignant

The ultimate way to differentiate between **frictional keratosis** and **Leukoplakia** is to reduce or eliminate predisposing factors and await remedy

## **Management**

- ❖ No surgical intervention is indicated.
- ❖ No malignant nature of the lesions
- ❖ attempts to reduce predisposing factors are sufficient

## **Other Red And White Lesions**

- **Benign Migratory Glossitis (Geographic Tongue)**
- **Hairy Tongue**
- **White Sponge Nevus**
- **Leukoedema**

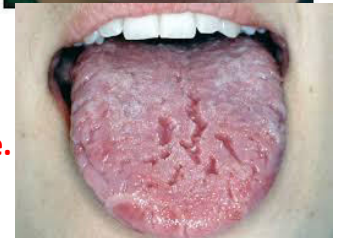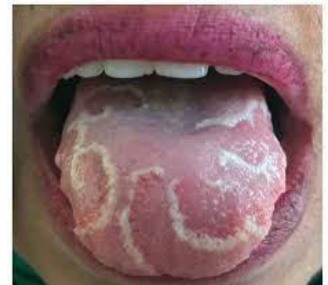**Geographic Tongue (Erythema Migrans) Benign Migratory Glossitis Or Wandering Rash Or Glossitis Areata Exfoliativa**

- **Is an annular lesion affecting the dorsum and margin of the tongue.**
- The typical clinical presentation comprises a white, yellow, or gray slightly peripheral zone
- ✓ Circumferentially migrating and leaves an erythematous area behind, reflecting atrophy of the filiform papillae.

Depending on the **activity** of the lesion, the clinical appearance may vary from **single to multiple** lesions occupying the entire dorsum of the tongue.

Geographic tongue and fissured tongue may be observed simultaneously. Most likely, **fissured tongue** should be interpreted as an **end stage** of geographic tongue in some patients

- **ONE of the most prevalent oral mucosal lesions,**



## The etiology

- ❖ Remains obscure,
- ❖ Immunologic reaction has been proposed on the basis of the associated inflammatory infiltrate.
- ❖ Some cases occur due to zinc deficiency.
- Heredity has been reported, suggesting the involvement of genetic factors in the etiology.
- The most frequently reported **prevalence** is in the range of 1%–2.5%.
- The gender distribution equal.
- The prevalence of the disease seems to decrease with age

### D.D:

1. Pustular psoriatic dermatitis. +ve skin lesion
2. Reiter's syndrome. skin , ocular , urethral & arthritis.
3. Dermatitis herpetiformis.
4. Lichen planus. Annular type
5. Anemia.

## Treatment

There is no specific curative treatment for this self-limiting condition.

Treatment are attempted for the control of chronic burning pain by:

- \***Most patients learn to avoid foodstuffs that irritate their tongue.**
- \***Application of topical local anesthetic agents.**
- \***Mouth rinse by aqueous antihistamine**
- \***Topical corticosteroid**
- \***Topical application of Tretinoin.**
- \***Some authorities have suggested the use of zinc supplement.**

# Psoriasis

*It is a common chronic inflammatory skin disorder.*

*Prevalence ..... 1----3 % of the word population.*

*Causes:- multifactorial*

- 1- Strong genetic influences. 1 \ 3 relatives & HLA*
- 2- Psychological stress.*
- 3- Infection.*
- 4- Alcohol abuse.*
- 5- Certain drugs... Lithium &  $\beta$  blockers.*
- 6- Strong association with AIDs.*

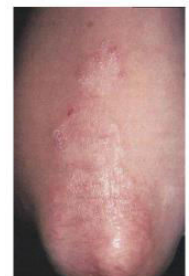
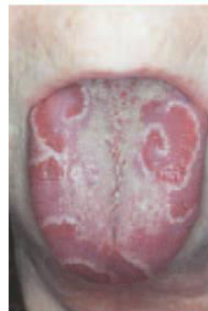
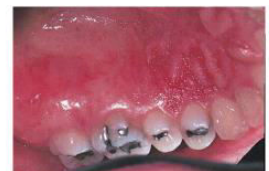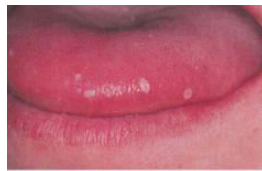## *Clinical features*

**Onset** ----- **during 2<sup>nd</sup> & 3<sup>rd</sup> decades of life.**

**It characterized by development of erythematous papules & plaques that are covered by a silvery scale . If scales are scraped off --- Tiny pin point areas of bleeding ( **Auspitz sign** ) .**

**Lesions are often bilaterally symmetrical & most commonly affect Scalp ,elbows ,knees & site of local trauma (Koebner phenomenon).**



## *Treatment*

**For mild form of psoriasis.**

**No treatment**

**For moderate cases .**

**Topical corticosteroid may be used**

**For sever cases ----- UV Light Or systemic drug therapy**

**Methotrexate , Retinoid or Cyclosporine**

**Symptomatic oral lesion. Treated with warm salty rinse or topical anesthesia , antihistamine or corticosteroid.**

## Leukoedema

Leukoedema is defined as edematous mucosa with a whitish, often apparently translucent appearance

The etiology of leukoedema is not clear

- Leukoedema is a white alteration of the oral mucosa that is merely considered a normal variant.
- The condition is often bilaterally in the buccal mucosa and sometimes at the borders of the tongue.
- Leukoedema is less clinically evident after stretching the mucosa but reappears after this manipulation is discontinued.

The prevalence in Caucasians has been estimated at 50%.

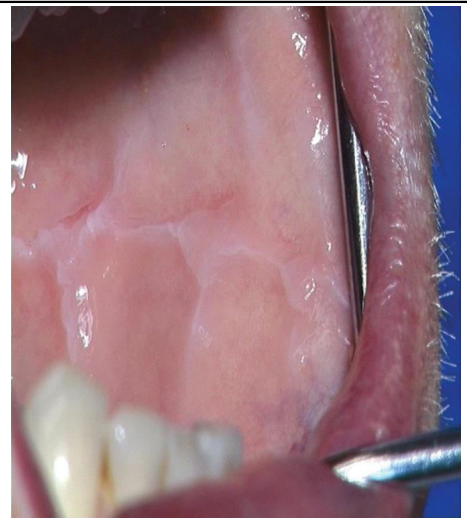
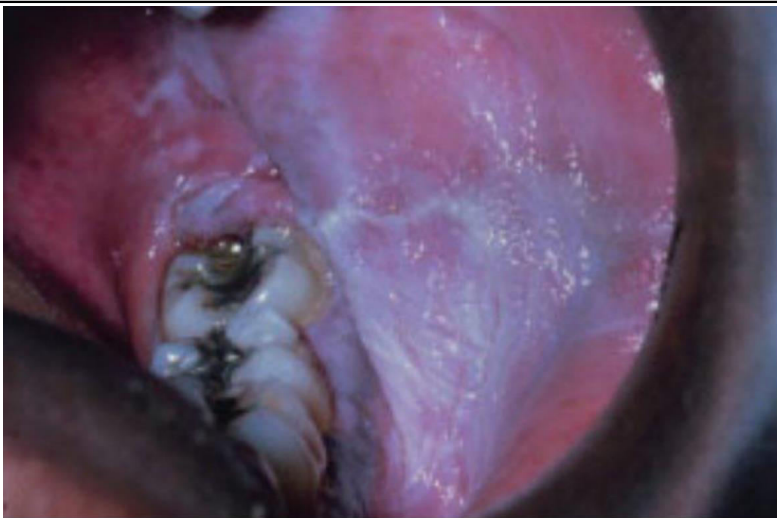
The lesion is even more prevalent in the black population.

In more pronounced cases, leukoedema is accompanied by mucosal folds. The condition is asymptomatic and has no malignant potential.

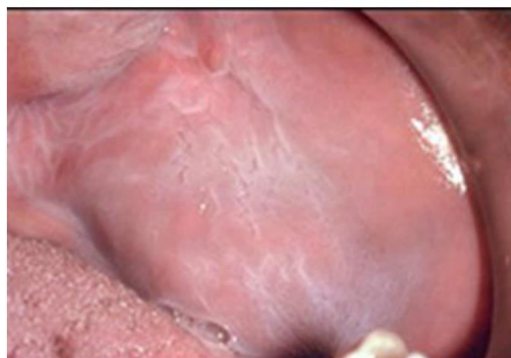The clinical features of leukoedema are quite different from oral keratosis, such as leukoplakia, as the demarcation is diffuse and gentle stretching results in a temporary disappearance

### Treatment

There is no demand for TT as the condition is non-symptomatic and has no complications, including premalignant features



### Leukoedema



The distribution between sexes has been found to be equal.

## White Sponge Nevus

- ❖ It is initiated following mutations in those genes that are coding for epithelial keratin of the types K4 and K13
- ❖ It has been listed as a **autosomal dominant disorder (rare disorder)** by the National Institutes of Health, a prevalence below 1 in 200,000
- ❖ The clinical appearance usually commences during **adolescence**
- ❖ gender distribution, **equal**.

The typical clinical appearance is a white lesion with an elevated and irregular surface comprising fissures or plaque formations

The most affected sites are the buccal mucosa, but the lesion may also be encountered in other areas of the oral cavity covered by parakeratinized or non-keratinized epithelium.

The disorder may also involve extraoral sites,  
esophagus  
and anogenital mucosa.

Although the lesion does not entail any symptoms, it may cause dysphagia when the esophagus is involved

### **Diagnosis**

A differential diagnostic problem for other oral dyskeratoses, such as **oral leukoplakia** and **plaque-type candidiasis**

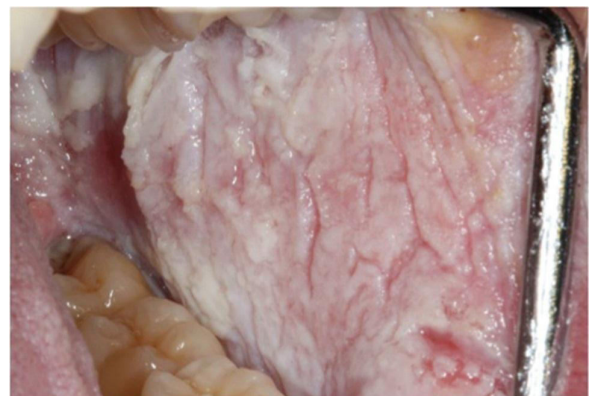The hallmark microscopic feature of this disorder is pronounced

### **Management**

White sponge nevus does not entail any symptoms, and no treatment is therefore required.

**Systemic antibiotics** have been used in an attempt to resolve the disorder, but with non-consistent results. When a positive effect is obtained, the recurrence rate is considerable.

**White sponge nevus is a totally benign condition.**



## **Hairy Tongue**

The etiology of hairy tongue is unknown in most cases.

A number of **predisposing factors** have been related to this disorder

- neglected oral hygiene,
- a shift in the microflora,
- antibiotics and
- immunosuppressive drugs,
- oral candidiasis,
- excessive alcohol consumption,
- oral inactivity,
- and therapeutic radiation.
- also associated with smoking habits

in hospitalized patients

The **reported prevalence** varies between different geographic areas, diagnostic criteria, and the frequencies of predisposing factors.

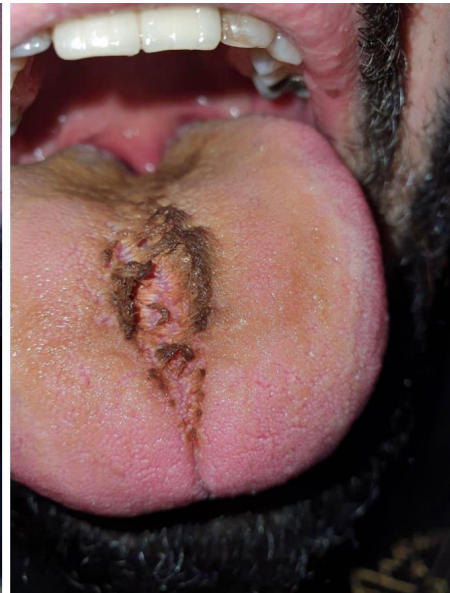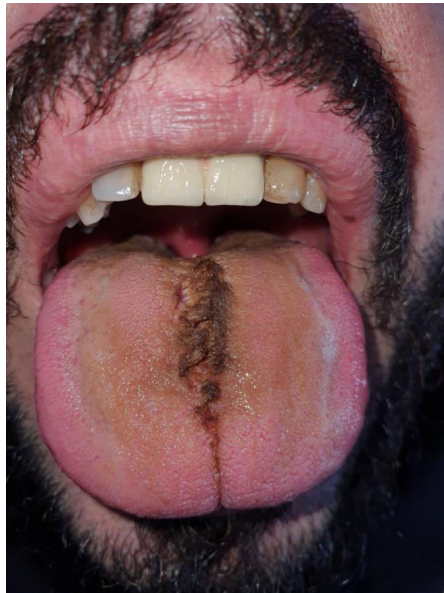
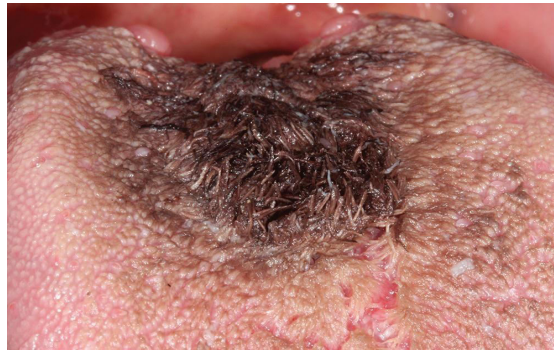## **Clinically**

- Hairy tongue is characterized by an **impaired desquamation of the filiform papilla**, which leads to the hairy-like
- The elongated papillae have to reach lengths in **excess** of 3 mm to be classified as “hairy,” although lengths of more **than just 15 mm** have been reported in hairy tongue.
- The lesion is commonly found in the **posterior one-third of the tongue** but may involve the entire dorsum.
- Hairy tongue may adopt colors from **white to black** depending on food constituents and the composition of the oral microflora.
- Patients experience both **physical discomfort and esthetic embarrassment** related to the lengths of the filiform papillae

### ***Diagnosis***

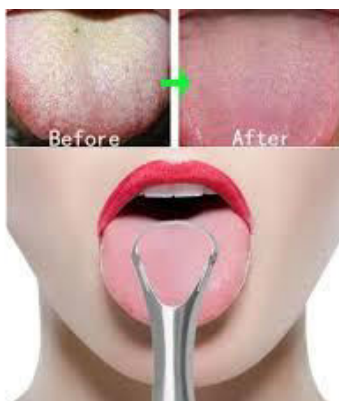The diagnosis is based on the clinical appearance





## Management

- The treatment of hairy tongue is focused on reduction or elimination of predisposing factors and removal of the elongated filiform papillae.
- The patients should be instructed on how to use **devices developed to scrape the tongue**.
- The use of **food** constituents with an **abrasive effect** may also be used to prevent recurrences.
- Attempts have been made with **tretinoin (retinoin acid- vitamin A)**, but this treatment has not reached any widespread acceptance.
- Patients should be informed about the benign and noncontagious nature of hairy tongue



## Ulcerative, Vesicular, and Bullous Lesions Lecture 1

**Oral ulceration** An ulcer is defined as an area of discontinuity of an epithelial surface.

**Erosion** is a shallow defect with loss of epithelial layers down to and sometimes including the basal layer.

Before carrying out any local examination of an ulcer, ascertain whether there is any known exciting factor such as trauma, etc., and also establish the duration of the ulcer.

### 1. The Situation of the Ulcer

- The rodent ulcer at the side of the nose and beneath the eye.
- The carcinoma of the tongue at the side of the tongue.
- The gummatous ulcer often occurs at the junction of the hard and soft palates.

### 2. Is the Ulcer Single or Multiple

### 3. Note the Size of the Ulcer.

### 4. Examine the Shape of the Ulcer

Ulcers may be round, oval, crescentic, serpiginous. Irregular etc.

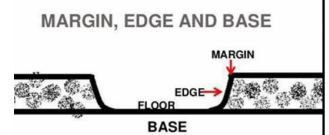
### 5. Note the Base of the Ulcer:

The base of an ulcer may be **indurated**, **soft**, or **fixed to deeper structures**.

Marked induration or fixation to deeper structures may be indicative of malignancy.

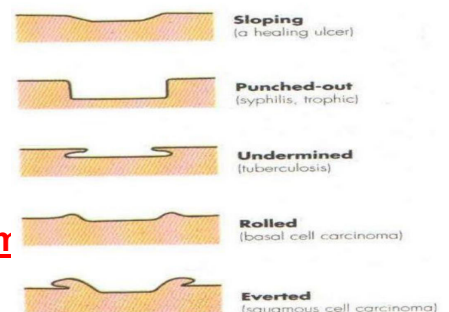
### 6. The floor of the Ulcer may be covered by:-

- Granulations. These may be red, pale, or flabby and may or may not bleed.
- The floor may be smooth.
- It may be covered with slough, membrane, scab, etc.
- The floor may be adherent to soft parts or bone.
- The floor may be fungating as seen in some clinical varieties of malignant disease.



### 7. The Edge of the ulcer may be:-

- Sloping (as seen in healing ulcer)
- Undermined (as seen in tubercular ulcers).
- Punched-out (as found in Gummatous ulcers).
- Rolled, raised, and everted (as squamous cell carcinoma).
- Rolled & raised (as in rodent ulcers <basal cell carcinoma>).



### 8. condition of the parts surrounding the ulcers

They may be inflamed, healthy, edematous, pigmented.

### 9. If there is a discharge from the ulcer, its color, and sr

should be noted and a bacteriological smear taken for culture.

### 10. Is the Ulcer Painful

**Inflammatory and traumatic ulcers** are usually painful while tuberculous ulcers in the mouth are often extremely painful, but in the early stages most malignant ulcers are painless. However, when the malignant ulcer becomes established and increases in size it may cause extreme discomfort.



it can be classified into

- Primary O U Start as an ulcer from beginning
- Secondary O U Secondarily to primary lesion or preceded by vesicle or bullae

**Ulcerative, Vesicular, and Bullous Lesions Classified into :**

1. The Patient with Acute Multiple Ulcers
2. The Patient with Recurring Oral Ulcers
3. The Patient with Chronic Multiple Ulcers
4. The Patient with Single Ulcers

### **1. The Patient with Acute Multiple Ulcers**

1. Herpes Simplex Virus Infections
2. Varicella-Zoster Virus Infections
3. Cytomegalovirus Infections
4. Coxsackievirus Infection - CV Infections
5. Necrotizing Ulcerative Gingivitis and Necrotizing Ulcerative Periodontitis
6. Erythema Multiforme
7. Stevens–Johnson Syndrome and Toxic Epidermal Necrolysis
8. Plasma Cell Stomatitis and Oral Hypersensitivity Reaction

## **1. Herpes Simplex Virus Infection Etiology and Pathogenesis**

### **Herpes virus Infections:**

The Herpes family of viruses contains 9 different viruses that are pathogenic in humans .

In general

Infections above the waist are caused by HSV-1

Those below the waist by HSV-2

Although with changing sexual practices, it is not uncommon to culture HSV-2 from oral lesions and vice versa.

The primary infection, which occurs on initial contact with the virus, is acquired by inoculation of the mucosa, skin, and eye with infected secretions.

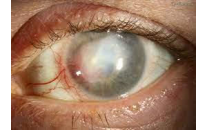The virus then travels along the sensory nerve axons and establishes chronic, latent infection in the sensory ganglion (such as the trigeminal ganglion).

Extra neuronal latency ( HSV remaining latent in cells other than neurons such as the epithelium) may play a role in recurrent lesions of the lips

## Recurrent HSV

results when HSV-1 reactivates at latent sites and travels to the mucosa or the skin, where it is directly cytopathic to epithelial cells, causing recurrent HSV infection in the form of localized vesicles or ulcers.

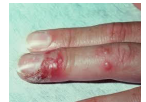The most common sites of infection are the oral and genital mucosa and the eye.



HSV infection of the **cornea (keratitis)** is a major cause of blindness in the world.

HSV-1 or -2 may cause **Herpes Whitlow**, an infection of the fingers when virus is inoculated into the fingers through a break in the skin.

This was a common occupational hazard (including within the dental profession)



HSV is an important etiologic agent in **Erythema Multiform**,

**HSV has been recovered in the endoneurial fluid of patients with Bell palsy. (endoneurium a layer of delicate connective tissue around the myelin sheath of each myelinated nerve fiber. Its component cells are called endoneurial) However, varicella-zoster virus (VZV) has also been strongly implicated in the development of Bell palsy.**

HSV1, HSV2, Are viruses that are known to cause oral mucosal disease .

Classically HSV1 causes a majority of cases of oral ,pharyngeal infection , meningo-encephalitis, & dermatitis above the waist

HSV2 is implicated in most genital infections.

Both types can cause Primary Or Recurrent Infection of either the oral or the genital area and both may cause recurrent disease at either site. recent study showed that approximately 60% of cases of Bell palsy were associated with Human herpesvirus (HHV6), and only 13% with HSV.

## Latency

A characteristic of all herpes viruses, occurs when the virus is transported from mucosal or cutaneous nerve endings by neurons to ganglia where the HSV viral genome remains present in a non-replicating state.

Reactivation of the latent virus occurs when HSV switches to a replicative state

This can occur as a result of a number of factors

\*Peripheral Tissue Injury From Trauma

\*Sunburn

\*Fever

\*Immunosuppression

\*Menstruation

## Carcinogenesis

There is evidence linking HSV to carcinogenesis.

Epidemiologic studies have demonstrated an increased incidence of HSV2 serum antibodies or positive HSV2 cultures in patients with cervical carcinoma.

## **Primary herpetic stomatitis**

This is a common viral infection caused by HSV1.

It affects the mouth, pharynx & skin .

It is most often seen in children, although young adults are sometimes affected but rarely occur before 6 month due to maternal antibodies .

### **Clinical manifestations:**

Primary herpes manifests as an acute illness with fever, irritability, headache & lymphadenopathy .

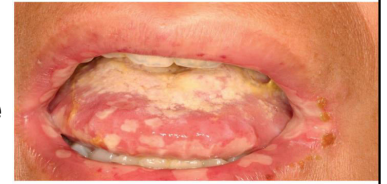Typically, there are initial symptoms of malaise associated with aches & a sore throat followed after (2-3) days by multiple small oral vesicles which rapidly breakdown to form well defined yellow base ulcer with a red margin .

They may affect hard palate, tongue, lips & circumoral skin.

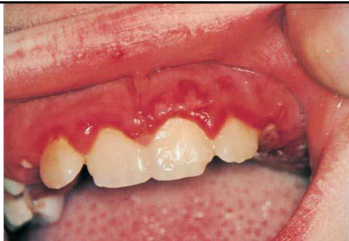In addition to the ulcerations, the whole mucosa is bright-red & painful with a marked edematous gingivitis .

The lesions are self-limiting & usually disappear in (10 -14) days .

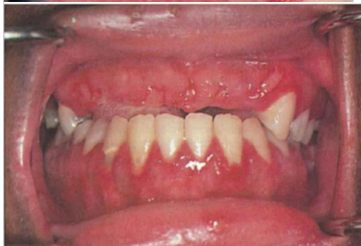Primary HSV infection in adults follows a similar pattern



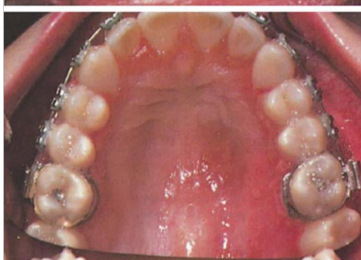
Primary herpetic gingivostomatitis



**Primary Herpetic Gingivostomatitis:  
Erythema And Multiple Ulcers On The**



**Multifactorial Ulceration Present On Movable &  
Bound Mucosa .  
Note The Intensely Erythematous Gingiva  
Without Significant Plaque**



**Palatal mucosa demonstrating numerous  
small ulceration that tend to cluster .  
Note the significant erythema & ulceration  
of the palatal gingiva**

### Recrudescent (renewing) Oral HSV Infection

☒ Reactivation of HSV may lead to asymptomatic shedding of HSV, in the saliva and other secretions, an important risk factor for transmission.

- Asymptomatic shedding of HSV is not associated with systemic signs and symptoms and occurs in 8-10% of patients following dental treatment.

☒ Reactivation of HSV-1 on the oral mucosa is common and usually asymptomatic. However, HSV-1 is rarely found in tears and nasal mucosa. Frequent oral shedding of HSV-1 may increase the risk for transmitting the virus to both oral and genital mucosa of sexual partners

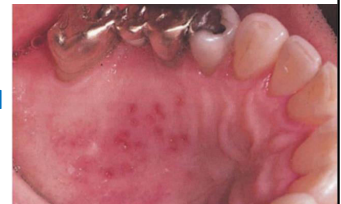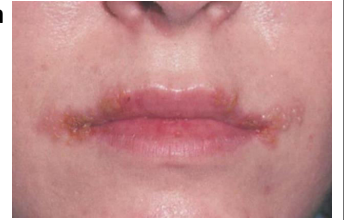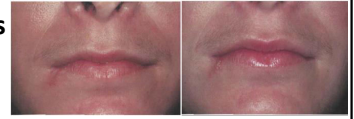☒ The term recrudescent HSV should be used to refer to the actual ulcerations caused by reactivated virus.

☒ Fever, ultraviolet radiation, trauma, stress, and menstruation are important triggers for reactivation of HSV.

☒ Recrudescent HSV on the lips is called recurrent herpes labialis (RHL) and occurs in 20- 40% of the young adult population

☒ These are associated with a prodrome of itching, tingling, or burning approximately 50% of the time, followed by the appearance of papules, vesicles, ulcers, crusting, and then resolution of lesions

☒ Pain is generally present only within the first two days.



### Recrudescent intraoral HSV (RIH) in the immunocompetent host •

Occurs chiefly on the keratinized mucosa of the hard palatal mucosa, attached gingiva, and dorsum of the Tongue • They present as 1–5 mm single or clustered painful ulcers with a bright erythematous border .

### HSV in Immunocompromised Patients

- In immunocompromised patients such as

- Those undergoing chemotherapy,
  - Who have undergone organ transplantation,
  - Who have acquired immune deficiency syndrome [AIDS]

- May occur at any site intraorally

May form ulcers that may be **several centimeters** in size and may **last several weeks or months** if undiagnosed and untreated. They appear **slightly depressed with raised borders**.

- The presence of **1–2 mm vesicles** at the edges of the main ulcer is a helpful sign.

If undiagnosed and left untreated

RIH infection may disseminate to other sites and cause severe infections in the immunocompromised population. This is a particular problem in patients undergoing stem cell transplantation, where reactivation of HSV occurs in approximately 70% of patients.

## Laboratory Diagnosis

- ❑ HSV isolation by cell culture is the gold standard test for the diagnosis since it grows readily in tissue culture. A single swab of the oral ulcers is performed.
- ❑ More recently, Polymerase Chain Reaction (PCR) from swabs has been shown to detect HSV antigen 3-4 times more often than culture.
- ❑ Real-time PCR has also been shown to be highly sensitive and specific.
- ❑ Primary HSV infection is associated with elevated immunoglobulin (IgM) titers that occur within days, followed several weeks later by permanent IgG titers, that indicate previous infection but confer no protection against reactivation.
- ❑ Recurrent infection is associated with a rise in IgG antibody titer.
- ❑ HSV lesions are not generally biopsied because the clinical appearance and history are characteristic, and infection is readily confirmed with a culture or cytology specimen when necessary.

## Primary HSV Infection Management

1. Pain control,
2. Supportive care,
3. Definitive treatment.

In the past, healthy patients with primary herpetic gingivostomatitis were treated only with **Hydration And Supportive Measures**. However, since the **Acyclovir Family** of drugs is inexpensive, safe, and readily available, it is appropriate to treat even primary infections definitively because it reduces viral shedding and infectivity. Acyclovir inhibits viral replication and is activated by virally produced thymidine kinase. As such, it has little activity against non-virally infected cells. The use of acyclovir at 15 mg/kg five times a day in children reduces the duration of fever, reduces HSV shedding, stops the progress of lesions, improves oral intake, and reduces the incidence of hospital admissions.

**Valacyclovir**, has 3-5 times the bioavailability of acyclovir

**Famciclovir**, is now widely used.

## Recrudescence HSV

Recurrent herpes labialis can often be suppressed by reducing tissue damage, such as using

**Sunscreen**.

Although RHL is self-limiting, the use of topical antiviral medications reduces shedding, infectivity, pain, and the size and duration of lesions.

**Topical Antiviral Medications Such As 5% Acyclovir Cream, 1% Penciclovir Cream, And 10% Docosanol Cream** are efficacious if applied 5-8 times a day at the first prodrome or sign of a lesion.

**Systemic Therapy With Valacyclovir (2 G Every 12 Hours For One Day) Or Famciclovir (1500 Mg Single Dose) Are Both Effective In Treating Active Lesions Of RHL**

## Management

is directed toward

### **For intraoral lesions,**

treatment is with

500–1000 mg **Valacyclovir** three times a day  
or 400–800 mg of **Acyclovir** for 7–10 days.

Suppression of HSV infection in patients who develop Frequent Episodes, Large Lesions, Or Erythema Multiforme is effected with variable doses of acyclovir, valacyclovir, and famciclovir.

Similar suppressive regimens can be used for patients susceptible to recrudescing HSV after dental procedures.

### **HSV in Immunocompromised Patients**

- HSV infections should be treated with **Systemic Antivirals** to prevent dissemination to other sites (e.g., HSV esophagitis) or systemically.
- The primary pathogen for herpes encephalitis & herpes pneumonitis is HSV-1.
- For patients undergoing **Hematopoietic Cell Transplantation**, antiviral therapy such as **Acyclovir Or Valacyclovir** at suppressive doses should be initiated for all patients who are HSV seropositive (acyclovir 400 mg three times a day or 500 mg valacyclovir twice a day).
- Acyclovir-resistant HSV** is most frequently seen in this group of patients, where the virally derived thymidine kinase that activates acyclovir is mutated.  In such cases, **Foscarnet Or Cidofovir** is effective.

**A number of vaccines and new therapies against HSV are currently under development**

## **2. Varicella-Zoster Virus Infection** **Etiology and Pathogenesis**

**Primary infection with varicella zoster virus (VZV) leads to varicella (chicken pox).**

**The virus then becomes latent, usually in the dorsal root ganglia or ganglia of the cranial nerves.**

**Reactivation produces herpes zoster infection (HZI), commonly called shingles.**

• **The incidence of HZI increases with age and the degree of immunosuppression.**

**this increases to 10 per 1000 in those older than the age of 75 years.**

**Therefore, it is not uncommon to see HZI**

- ✓ **in the elderly,**
- ✓ **in patients undergoing cancer chemotherapy,**
- ✓ **in patients on chronic immunosuppressive drug therapy**
- ✓ **in patients with AIDS.**

**As with HSV, this virus is cytopathic to the epithelial cells of the skin and mucosa, causing blisters and ulcers.**

**Transmission is usually by the respiratory route, with an incubation period of 2 to 3 weeks.**

**Post herpetic neuralgia, a morbid sequela of HZI, is a neuropathy resulting from peripheral and central nervous system injury and altered central nervous system processing**



## Clinical Findings

Primary VZV infection generally occurs in the first two decades of life.

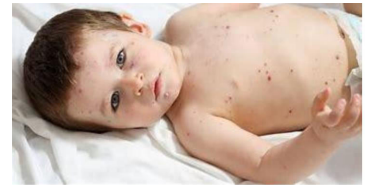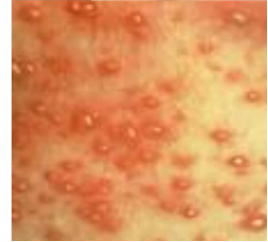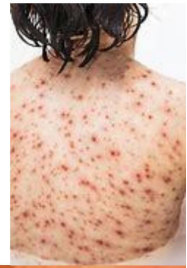The disease begins with a **low-grade fever, malaise, and the development of an intensely pruritic, maculopapular rash, followed by vesicles that have been described as “dewdrop-like.”**

These vesicles turn cloudy and pustular, burst, and scab, with the crusts falling off after one to two weeks.

Lesions begin on the trunk and face.

Immunocompromised hosts usually experience more severe disease with more blisters, a prolonged course, and, not infrequently, involvement of the lungs, central nervous system, and liver; there is a significantly higher mortality rate.

Secondary bacterial infection by gram-positive cocci may have severe septic consequence



## HZI of the skin (shingles)

occurs in adults and starts with a prodrome of deep, aching, or burning pain.

There is usually little to no fever or lymphadenopathy.

This is followed within 2-4 days by the appearance of **vesicles in a dermatomal or “zosteriform” pattern.**

This pattern describes the **unilateral, linear, and clustered distribution of the vesicles, ulcers, and scabs in a dermatome supplied by one nerve.**

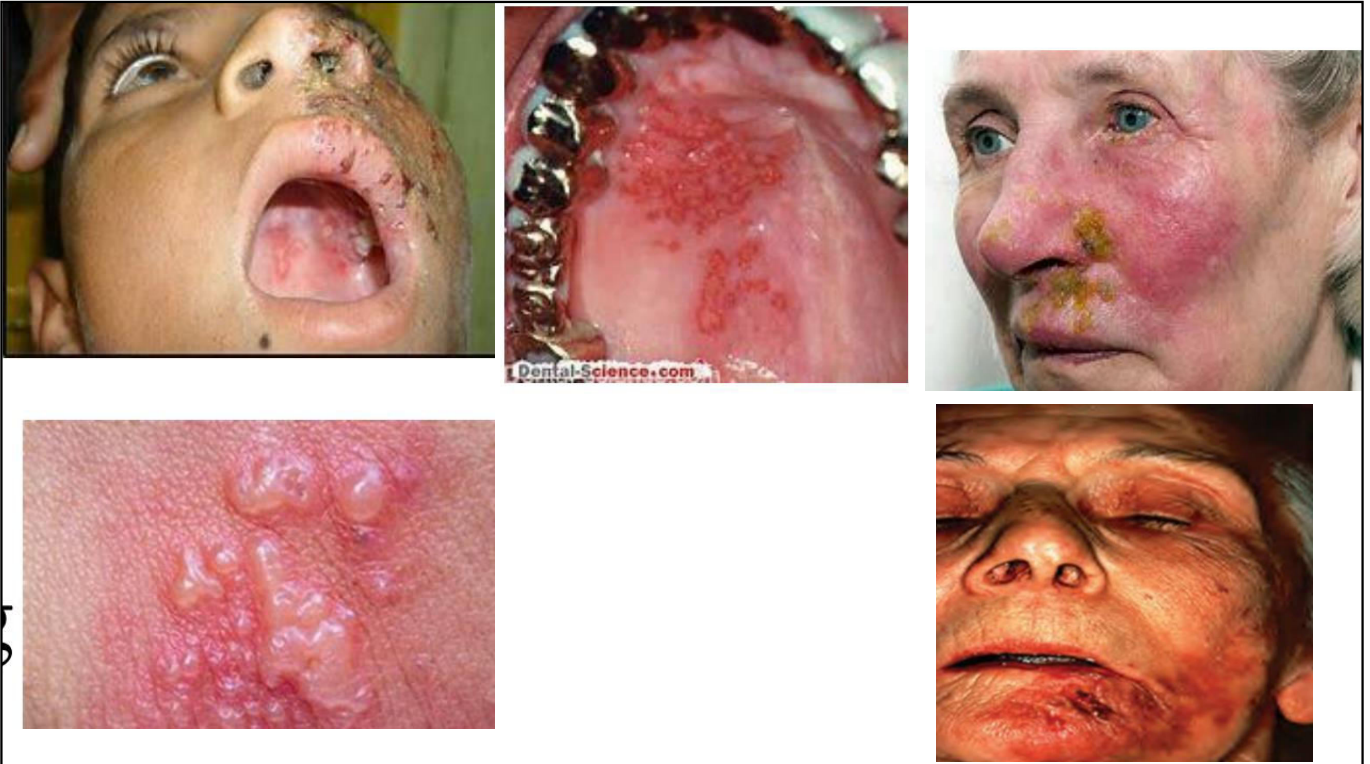Thoracic/lumbar dermatomes are the most frequently involved, followed by the craniofacial area.

Lesions heal within 2-4 weeks, often with scarring and hypopigmentation.

**Occasionally, HZI may occur without the appearance of dermatomal lesions (Zoster Sine Eruption Or Zoster Sine Herpete),** which makes the diagnosis of this condition challenging; these patients often present with facial palsy.

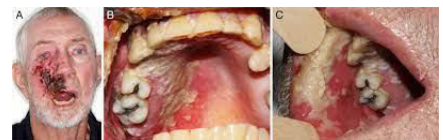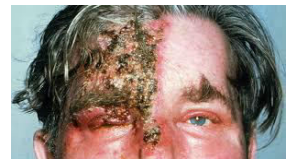- VZV has been detected in up to 20% of patients with Bell palsy.
- A serious and occasional side effect of HZI is **Acute Retinal Necrosis.**
- ✓ One of the most important complications of HZI is **Postherpetic Neuralgia,** defined as pain that remains for 120 days after the onset of the acute rash
- patients older than age 50, up to 70% developed postherpetic neuralgia and up to 50% have debilitating pain, usually of a sharp, stabbing, burning lasting more than one month.
- Some unfortunate patients experience pain for years.
- Predisposing factors include older age, prodromal pain, and more severe clinical disease during the acute rash phase. Immunocompromised patients often experience more severe VZI that may appear atypical, be bilateral, and involve multiple dermatomes; retinitis, pneumonitis, and encephalitis have been reported as complications in this patient population.

On rare occasions, HZI may involve not just the dorsal root ganglion but also the anterior horn cells, leading to paralysis.

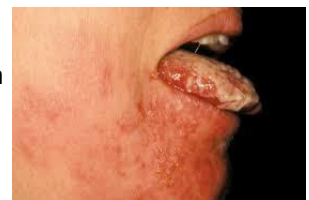

## Oral Manifestations

- ❑ Primary VZV infection presents as acute-onset ulcerations in the mouth that often pale
- ❑ In recurrent VZV infection, the ophthalmic division of the trigeminal (V) nerve is the cranial nerve most often affected (**Herpes Zoster Ophthalmicus**);
- ❑ Corneal involvement may lead to blindness.
- ❑ Involvement of this nerve (V) leads to lesions on
  - The upper eyelid, forehead, and scalp with V1;
  - Midface and upper lip with V2;
  - Lower face and lower lip with V3.



With the involvement of V2, patients experience a prodrome of pain, burning, and tenderness, usually on the palate on one side. This is followed several days later by the appearance of painful, clustered 1–5 mm ulcers (rarely vesicles, which break down quickly) on the hard palatal mucosa or even buccal gingiva, in a distinctive unilateral distribution. These ulcers heal within 10–14 days. Involvement of V3 results in blisters and ulcers on the mandibular gingiva and tongue.



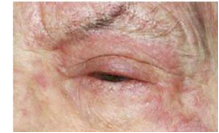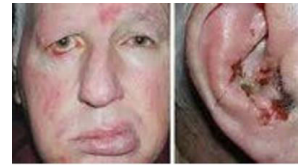**An uncommon complication of HZI involving the geniculate ganglion:**

- is **Ramsay Hunt syndrome.**

**Patients Develop Bell Palsy.**

**Vesicles Of The External Ear.**

**Loss Of Taste Sensation In The Anterior Two-thirds Of The Tongue.**



- **HZI has been reported to cause**

**Resorption And Exfoliation Of Teeth**

**Osteonecrosis Of The Jawbones, especially in patients with HIV disease.**

**Laboratory Findings**

- **Oral swab for viral isolation** using cell culture is still the best way to confirm a diagnosis of VZV infection, although VZV is more difficult to culture.
- **Direct fluorescent antibody testing** using a smear has greater sensitivity. This test uses a smear obtained by scraping the lesion and staining it with antibody against VZV conjugated to a fluorescent compound.
- **The use of PCR and real-time PCR** to detect viral antigen is expensive and highly sensitive, but the presence of VZV antigen does not always equate with active infection.

**Management of oral lesions of varicella and HZI is directed toward**

- **Pain Control** (particularly, the prevention of postherpetic neuralgia),
- **Supportive Care,**
- **Hydration**
- **Definitive Treatment** to minimize the risk for dissemination in immunocompromised patients.
- **Aspirin use**, especially in children with VZV infection or influenza, may be associated with the development of **Reye syndrome**, which is potentially fatal, and is contraindicated; characterized by **fatty degeneration of the liver and encephalopathy.**
- **Ibuprofen** is the preferred analgesic.

**Treatment of primary VZV infection includes the use of :**

- ❖ **Acyclovir (800 mg five times a day).**
- ❖ This reduces infectivity, severity of lesions, and hospitalization for complications. However, acyclovir has poor bioavailability.
- ❖ **Valacyclovir (1000 mg 3 times a day)**
- ❖ **Famciclovir (500 mg) 3 times a day) for 7 days** is effective in treating HZI and should be started within 72 hours of disease onset.

These drugs also reduce the incidence of postherpetic neuralgia compared with acyclovir.

**The first line of treatment for postherpetic neuralgia is**

- Gabapentin,
- 5% Lidocaine Patch,
- 0.025%–0.8% Topical Capsaicin.

**The second line of treatment is with**

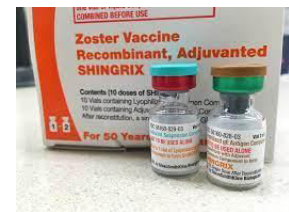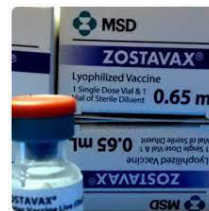- ❖ Tricyclic Antidepressants
- ❖ Corticosteroids

The use of corticosteroids and antiviral therapy together in an attempt to reduce post herpetic neuralgia has not proved effective,

- ❖ Although early treatment with famciclovir or valacyclovir may prevent it.

**Other modalities of treatment in Case reports suggest that**

- Botulinum toxin may provide relief.
- Attenuated vaccine for the prevention of VZV infection has been shown to reduce the incidence of varicella outbreaks.



**Vaccination of older adults using:**

- Zostavax (Live, Attenuated Virus), since 2006
- Shingrix (Recombinant VZV Antigen) reduces incidence of HZI significantly and the latter, post-herpetic neuralgia.

The use of recombinant virus in a vaccine is more appropriate for use in immunocompromised hosts.

## Ulcerative, Vesicular, and Bullous Lesions (Lecture 2)

### 3. Cytomegalovirus Infection Etiology and Pathogenesis

- ✓ CMV is a herpesvirus, and 50-100% of the population world-wide and has been exposed.
- ✓ Risk for exposure increases with
  - Age,
  - Low socio-economic status,
  - Crowded living conditions.
- ✓ Primary infection may be asymptomatic or cause an infectious mononucleosis-like disease.
- ✓ CMV establishes latency within the connective tissue cells, such as the endothelium of blood vessels, mononuclear cells, and white blood cells in the connective tissue.
- ✓ CMV within endothelial cells may contribute to vascular inflammation, vascular occlusion, and end-organ damage.
- ✓ Transmission is by direct transfer of infected white blood cells through intimate contact, vertical transmission, blood products, and transplanted organs.
- ✓ Manifestations of infection and disease are most evident in the immunocompromised population
- ✓ It is the most common cause of pneumonia within the first 120 days after hematopoietic stem cell transplantation.
  
- ✓ In organ transplant recipients, CMV in the donor organ leads to CMV infection in the recipient.

### Clinical Findings

Primary CMV infection presents similarly to other viral infections with fever, malaise, and leucopenia and gastroenteritis (most common), pneumonitis, retinitis and hepatitis, and even thromboembolism.

### Primary CMV infection

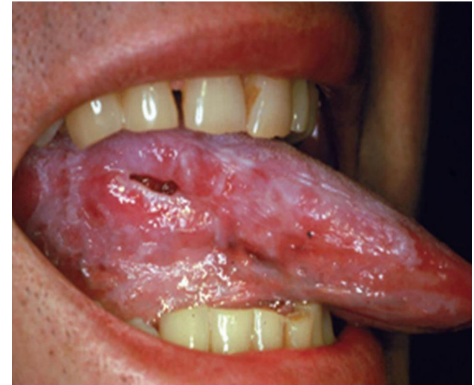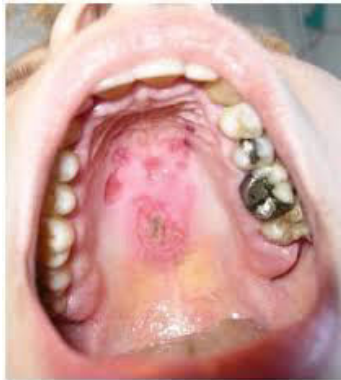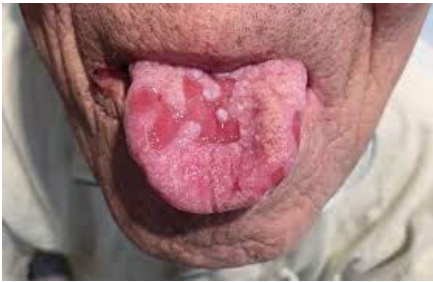- Presents similarly to **infectious mononucleosis** with marked lymphocytosis;
  - Unlike the more common EBV-associated infectious mononucleosis, there is fever but little lymphadenopathy or splenomegaly.
  - Serious complications** include **meningoencephalitis, myocarditis, and thrombocytopenia.**
- Approximately 90% of patients with AIDS have circulating antibodies against CMV.
- In these patients, CMV tends to involve the eye (CMV retinitis that may result in blindness if untreated), gastrointestinal tract (CMV enteritis), and mucocutaneous sites, especially peri-anal and peri-genital areas.



### Oral Manifestations

CMV infection in the mouth in the immunocompromised patient tends to present as

- **a single large ulcer and less often as multiple ulcers.** They are usually **painful** and may have been **present for weeks or months.** Any site may be involved.
- Up to one-third of such ulcers are coinfecting with other viruses of the herpes family, especially HSV and VZV.
- **There have been occasional reports of mandibular osteomyelitis and tooth exfoliation associated with CMV and VZV infection.**
- Both viruses are associated with vasculopathy and thrombosis, which may be the underlying etiopathogenesis.



### Management

- ✓ Pain is managed with topical anesthetics and systemic analgesics as needed, with appropriate dietary modifications and good hydration.
- ✓ **CMV infection is treated with**
  - ☐ Ganciclovir 5 mg/kg IV twice daily,
  - ☐ Valganciclovir 900 mg twice daily.
- ✓ A CMV **vaccine** is currently under development stage, with expectation that it will be available in the next 5 to 10 year



#### **4. Coxsackievirus Infection**

Coxsackie (CV), a ribonucleic acid (RNA) virus, has several sero-types including enterovirus **A, B, C, or D, Coxsackievirus A and B virus, are the most** The viruses replicate extensively in the lower gastrointestinal tract, and less so in the oropharynx, from where they shed.

- Transmission is therefore primarily by the fecal-oral route, although some shedding occurs in the upper respiratory tract.
- Enterovirus infection is implicated in aseptic meningitis, acute encephalitis, acute paralysis, ocular infections, myopericarditis, and respiratory illness.
- Enteroviruses in particular B1, has been implicated in the pathogenesis of type 1 insulin-dependent diabetes mellitus

#### **In the oral cavity**

CV infections lead to three disease entities:

1. **Hand, Foot And Mouth Disease (HFM Disease),**
2. **Herpangina**
3. **Lympho-nodular Pharyngitis.**

#### **Herpangina**

CVA (serotypes 1–10, 16, and 22) are the most common viruses isolated from this disease

Unlike herpes simplex infections, which occur at a constant rate, Herpangina frequently occurs in epidemics that have their highest incidence from June to October (summer).

The majority of cases affect young children ages 3 through, but infection of adolescents and adults is not uncommon.

##### **Clinical Manifestations:**

After a 2- to 10-day incubation period, the infection begins with generalized symptoms of fever, chills, and anorexia.

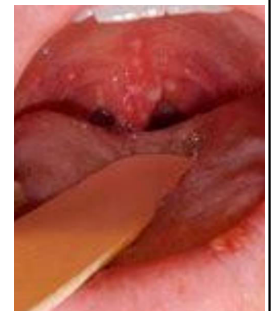
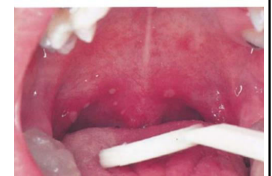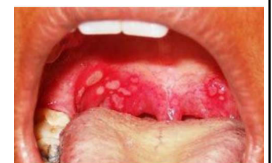The patient complains of sore throat, dysphagia, and occasionally sore mouth. Lesions start as macules, which quickly evolve into papules and vesicles involving the posterior pharynx, tonsils, faucial pillars, and soft palate. Within 24 to 48 hours, the vesicles rupture, forming small 1 to 2 mm ulcers.

##### **Diagnosis :**

Clinical diagnosis , lesion are summed in posterior part of the oral mucosa . . CV infections may be diagnosed by culture (usually from the throat or stools), but real-time PCR is now employed for typing.

##### **Treatment**

The disease is usually mild and heals without treatment in 1 week. It is self-limiting only supportive care is indicated.



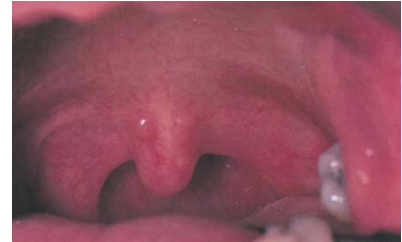## Lympho-nodular Pharyngitis

This is a variant of Herpangina caused by **coxsackie virus A10**.

The distribution of the lesions is the same as in Herpangina, but **yellow white nodules** appear that do **not progress to vesicles or ulcers**.

The disease is self-limiting,  
only supportive care is indicated.

Symptomatic treatment directed toward antipyretic & topical anesthetic ,  
also patient should be given proper hydration .



## Hand-Foot-And-Mouth Disease

Is caused by infection with coxsackie virus A16 .

In a majority of cases, the disease is characterized by

Low-Grade Fever

Oral Vesicles And Ulcers

Non pruritic Macules & Papules

Vesicles, Particularly On The Extensor Surfaces Of The Hands and Feet. mainly the palm of the hand & sole of the feet

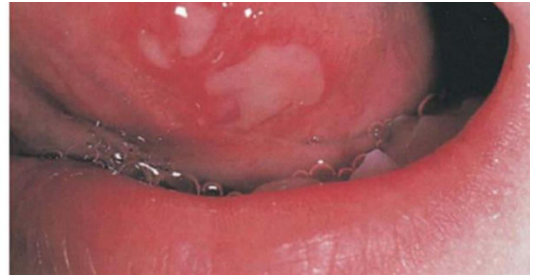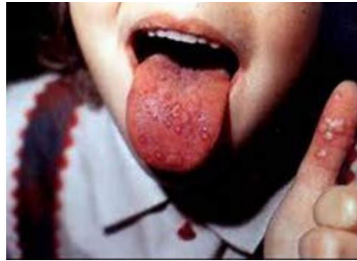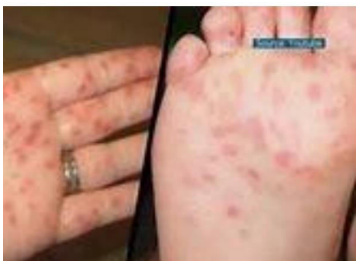The oral lesions are more extensive than are those described for Herpangina, and lesions of the hard palate, tongue, and buccal mucosa are common .

### Treatment:

Self-limiting Disease

Supportive Care

Effective antiviral agents for CV are not available, but vaccines are under development.



## **5. Necrotizing Ulcerative Gingivitis (NUG)& Periodontitis(NUP)**

- Formerly known as acute necrotizing ulcerative gingivitis and its more severe counterpart, NUP, were reclassified in 2017 by the American Academy of Periodontics under the category of (Necrotizing Periodontal Disease)
- Acute ulcerative-inflammatory conditions of the gingiva and periodontium that are associated with polymicrobial infection □ Was called —Trench Mouth since it was frequent among the soldiers in the trenches.
- Both with strong associations with
  - Immune Suppression (AIDs)
  - Debilitation
  - Smoking
  - Stress
  - Poor Oral Hygiene
  - Local Trauma
  - Contaminated food supply
  - Diabetes may also be a risk factor.
- It is unclear if NUG is an indication of NUP, but they are often seen in patients with AIDS.
- Both NUP and Noma thrive in communities characterized by a large low-socioeconomic class and extreme poverty.

### **Etiology and Pathogenesis**

Treponema species, Prevotella intermedia, Fusobacterium nucleatum, are the most common.

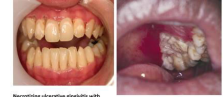### **The tissue destruction**

- Gingiva and adjacent tissues is most probably a result of the production of endotoxins and/or immunologic activation
  - Patients show reduced neutrophil chemotaxis and phagocytosis, resulting in poor control of infection.
  - If there is underlying systemic illness, NUG and NUP can spread rapidly from the gingiva to the periodontium and into the soft tissues, giving rise to **Cancrum Oris, Noma, Or Orofacial Gangrene.**
  - This is particularly devastating in children who are malnourished and live in poverty and is seen not infrequently in Africa.
- Fusobacterium necrophorum is likely to play an important role in the progression of NUP to cancrum oris because this organism produces a
- Dermonecrotic Toxin,
  - Hemolysin,
  - Leukotoxin,
  - Proteolytic Enzymes,
- all leading to extensive tissue destruction.  
It may also stimulate the growth of P. Intermedia.

### Clinical Findings

• NUG and NUP may or may not be associated with fever and malaise, although submandibular lymphadenopathy is usually present.

□ Noma generally is accompanied by fever, marked anemia, high white cell count, general debilitation, and a recent history of some other systemic illness, such as measles.



### Oral Manifestations

□ NUG has a rapid and acute onset.

□ The first symptoms include excessive salivation, a metallic taste, and sensitivity of the gingiva.

□ This rapidly develops into extremely painful and erythematous gingiva with scattered punched-out ulcerations, usually on the interdental papillae, although any part are of the marginal gingiva may be affected. . □ There is accompanying malodor, and gingival bleeding.

### Risk factors

□ immunocompromised and neutropenic are prone to developing such lesions.

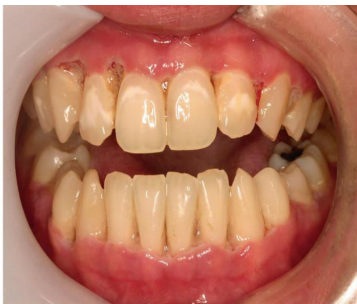□ In patients with AIDS, the prevalence of NUP is approximately 6% and is strongly predictive of a CD4 count less than 200 cell/mm, leading to osteonecrosis or necrosis of the soft tissues.

□ In patients who have severe immunodeficiency or are malnourished, NUG and NUP may progress to Noma. The overlying skin becomes discolored, and perforation of the skin follows.

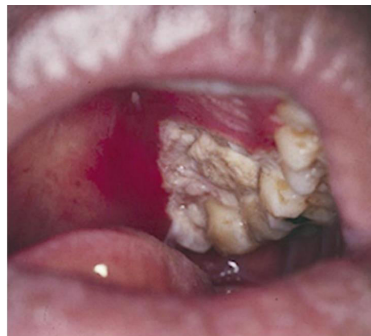□ The orofacial lesions cone shaped, with the base of the cone within the oral cavity and the tip at the skin aspect.

□ There is sloughing of the oral mucosa followed by sequestration of the exposed, necrotic bone and teeth.

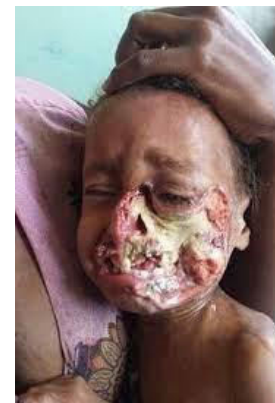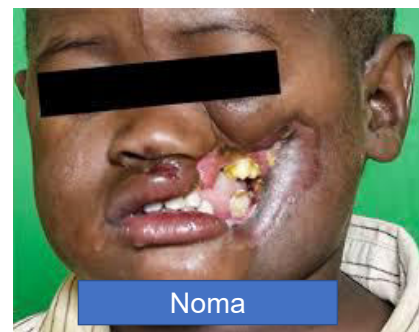□ Without treatment, the mortality rate is 70 –90%.



Necrotizing ulcerative gingivitis with typical punched out, necrotic and ulcerated interdental papillae.



Necrotizing ulcerative periodontitis with osteonecrosis in a patient with AIDS.



### Laboratory Testing

Secretions from the gingival sulcus grow mixed flora but in particular will be positive by culture or PCR for Treponema species, Prevotella intermedia, Fusobacterium nucleatum, and other bacteria.

### Management

#### Definitive treatment of NUG and NUP consists of

- **Gentle Debridement** to remove as much of the debris and plaque as possible; this is best accomplished with topical anesthesia during the first few visits.
- **Chlorhexidine Mouth** rinse led to resolution in >90% of cases.
- Patients with more extensive disease and/or systemic symptoms may require **Antibiotics** active against gram-negative anaerobes, such as  **$\beta$ -lactams; such as penicillin derivatives, cephalosporins.** Interestingly, **metronidazole**, which has little activity against spirochetes, also is effective.
- Once the acutely painful episodes have resolved, **Scaling And Root Planning** to completely remove all residual plaque and calculus are indicated.
- **Periodontal Surgery** may be necessary to correct gingival and periodontal defects.
- It may be appropriate to test the patient for HIV or other immunosuppressive conditions, such as blood dyscrasia.
- Cases of Noma need **Aggressive Treatment** with **Nutritional Supplementation, Antibiotics, Tissue Debridement.**

## 6. Erythema Multiforme

Is an **acute, self-limited, inflammatory mucocutaneous disease** that manifests on the **skin** and often **oral mucosa**, although other mucosal surfaces, such as the **genitalia**, may also be involved.

It represents a **hypersensitivity reaction to infectious agents or medications.**

- EM is classified as **EM minor** if there is less than 10% of skin involvement and there is minimal to no mucous membrane involvement.
- whereas **EM major** has more extensive but still characteristic **skin involvement, with the oral mucosa and other mucous membranes** affected.
- However, there is likely a subset of EM that affects the oral mucosa only without skin involvement. Historically, **fulminant forms EM** were labeled **Stevens–Johnson syndrome (SJS) and toxic epidermal necrolysis (TEN [Lyell disease])**.

### Etiology and Pathogenesis

- EM is a hypersensitivity reaction, and the most common inciting factors are infection, particularly with HSV.
- Drug reactions to NSAIDs, anticonvulsants, or other drugs play a smaller role.
- Cases of oral EM precipitated by benzoic acid, a food preservative, have been reported.
- Studies show that recurrent EM is associated with HSV infection in 65–70% of cases, both by history of HSV infection 1-3 weeks before onset of EM,
- Using PCR techniques, HSV gene products have been identified in 71–81% of cases of recurrent EM. For non-recurrent EM, this falls to 27%.
- Cytotoxic T cells, natural killer cells, and/or cytokines destroy the epithelial cells.
- More recently, it has been suggested that CD34+ cells, Langerhans cell precursors, carry fragments of HSV DNA to the skin where it incites EM.

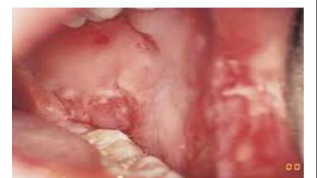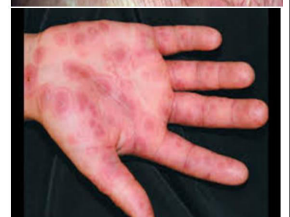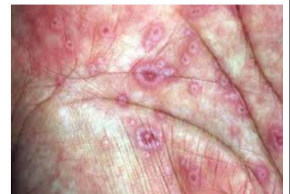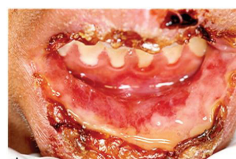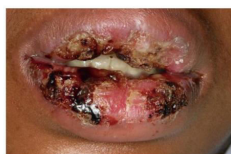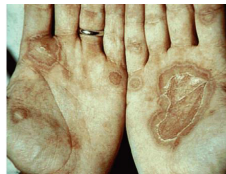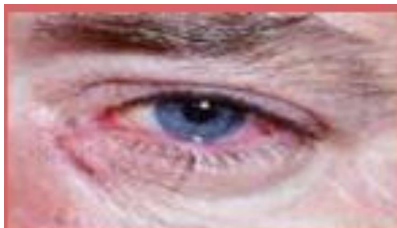


## Clinical Findings

- ❑ EM affects ages 20 and 40 years, with 20% occurring in children.
- ❑ Episodes usually last several weeks.
- ❑ There may be a prodrome of fever, malaise, headache, sore throat, rhinorrhea, and cough.
- ❑ Skin lesions appear rapidly over a few days and begin as red macules that become papular, starting primarily in the hands and moving toward the trunk in a symmetric distribution.
- ❑ The most common sites of involvement are the upper extremities, face, & neck.
- ❑ The skin lesions may take several forms—hence the term multiforme.
- ❑ The classic skin lesion consists called typical —target or —iris lesion that is pathognomonic of EM; variants are called —atypical target lesions.
- ❑ The skin may feel itchy and burnt.
- ❑ Post inflammatory hyperpigmentation is common in dark-skinned individuals and may be worsened by sun exposure

## Oral Findings of E.M

- ❑ The oral findings in EM range from mild erythema and erosion to large painful ulcerations,
- ❑ Severe, large ulcers, causing difficulty in eating, drinking, and swallowing,
- ❑ patients with severe EM may drool blood-tinged saliva.
- ❑ Extensive lip involvement with inflammation, ulceration, and crusting is common.
- ❑ Oral lesions are present in 23–70% of patients with recurrent EM.
- ❑ The most commonly affected sites are the lips (36%), buccal mucosa (31%), tongue (22%), and labial mucosa (19%), Genital 25% and ocular sites are 17%.
- ❑ Crusting and bleeding of the lips are common, but not always present





## **Management**

- Mild oral EM can be managed with [systemic or topical analgesics](#) for pain and supportive care since the disease is self-limiting and resolves within a few weeks.
- More severe cases are usually managed with [systemic corticosteroids](#)
  - [Topical steroids](#) may also help resolve lesions.
- Cases suspected of having HSV-associated EM should be treated with [antiviral medications \(acyclovir\)](#).
- Treatment with acyclovir at the first sign of disease in recurrent EM controls disease in approximately half of patients
- Other treatment modalities include [dapsone, hydroxychloroquine, mycophenolate mofetil, azathioprine, colchicine, methotrexate, and intravenous immunoglobulin](#).
- [Continuous acyclovir at 400 mg twice a day](#) prevents development of EM in most patients with HSV-associated disease, whereas EM not related to HSV responded well to azathioprine (100–150 mg/d).
- Other studies have also shown good suppression of recurrent Associated EM using [500 mg of valacyclovir twice a day or 250 mg of famciclovir twice daily](#).
- [Dapsone \(100–150 mg/d\) and antimalarials](#) are partially successful in suppressing recurrent outbreaks

## **7. Stevens-Johnson Syndrome and Toxic Epidermal Necrolysis**

SJS and TEN are both rare severe necrolytic mucocutaneous disorders resulting from hypersensitivity to medications and are clinically and pathologically distinct from EM.

- Although all three are hypersensitivity reactions and give rise to [Oral Bullae, Erosions, Ulcers, And Crusted Lips](#),

**The Skin lesions of SJS and TEN are different from EM**

□ They are more severe and tend to arise on the chest rather than the extremities on erythematous and purpuric macules; these lesions are called —atypical targets.

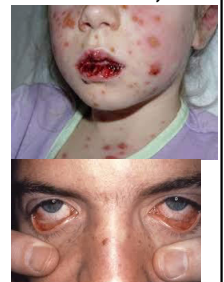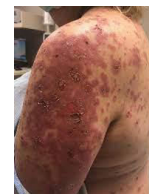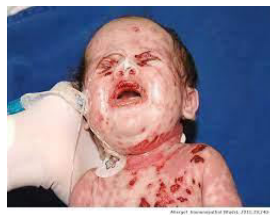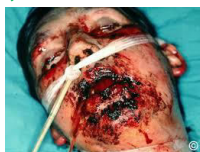- SJS is much more likely to be associated with medication use

Mycoplasma pneumoniae infection (especially in children) and rarely with HSV infection, whereas EM is much more likely to be associated with HSV infection.

- Some cases of Mycoplasma pneumoniae are associated with EM.

- [The more common inciting drugs include](#)

[Antibacterial Sulfonamides, Penicillin](#)  
[Anticonvulsants,](#)  
[NSAIDs in children,](#)  
[Allopurinol,](#)  
[Oxicams,](#)  
[Nevirapine In Adults.](#)



In Han Chinese, development due to the aromatic anticonvulsants; [Carbamazepine, Phenytoin](#).

- The mucosal surfaces of the eye, genitalia, and mouth are almost always severely affected by SJS/TEN, always with skin involvement.

- The typical oral manifestation is extensive oral ulceration with hemorrhagic crusts on the vermillion and

### Diagnosis of

**SJS** is made if there is less than 10% of body surface involvement,  
**SJS-TEN overlap syndrome** if 10–30% of body surface is involved  
**TEN** if >30% is involved.

### The mortality rate of

SJS is 1–5%

TEN are 25–35%.

### Treatment

- Because of the severity of this condition, treatment is generally with  
**Intensive supportive care** because of loss of skin barrier,  
**Intravenous immunoglobulin,**  
**Systemic steroids,**  
**Cyclosporine,**  
**Plasmapheresis,**  
**Cyclophosphamide,**  
**TNF- $\alpha$  inhibitor.**

## 8. Plasma Cell Stomatitis & Oral Hypersensitivity Reactions

### Etiology and Pathogenesis

### Oral hypersensitivity reactions may take the following forms:

1. Acute onset of ulcers such as in oral EM
2. Red and white reticulated lesions of a lichenoid hypersensitivity reaction
3. Fixed drug eruption
4. Marked erosions and erythema especially on the gingiva with or without ulceration called plasma cell stomatitis (PCS).
5. Swelling of the lips/angioedema
6. Oral allergy syndrome that presents mainly with symptoms of itching with or without swelling of the oral structures and oropharynx

PCS is a hypersensitivity reaction that was first described in the late 1960s and early 1970s and was likely a contact stomatitis to a component of chewing gum.

Since then, cases have continued to be reported, and these are all likely caused by a sensitizing contactant, whether or not the contactant is identified.

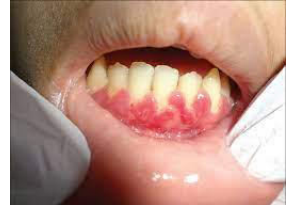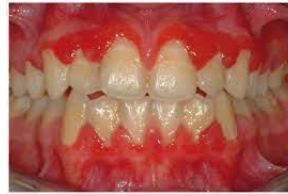These include khat (*Catha edulis*), components of toothpaste, mint candies, and household cleaners.

Because of the intense plasma cell infiltration, it is believed that this is a B cell-mediated disorder, with T cells augmenting the response.

- The terms mucous membrane plasmacytosis and plasma cell orificial mucositis are used because there may be involvement of the upper respiratory tract.
- Some believe that this is caused by components of plaque bacteria, although this is not a universally accepted concept.

## Clinical Findings

- PCS occurs within days of exposure to the contactant, with most signs and symptoms limited to the oral cavity.
- Some lesions may affect the periorificial tissues or the oropharynx, leading to upper airway symptoms of hoarseness, dysphagia, and mild airway obstruction.
- Endoscopy may reveal erythematous and thickened mucosa, often with a cobble stoning pattern from the edema.
- An obvious allergen/contactant is not always identified.



## Oral Manifestations

- PCS occurs within a few days of exposure.
- It presents as brightly erythematous macular areas of the oral cavity, almost always involving the marginal and attached gingiva or alveolar mucosa and often involving other soft tissues, such as the maxillary and mandibular sulcus or buccal mucosa.
- Ulcers may be present & there may be epithelial sloughing and desquamation.
- The gingiva may also be swollen and edematous.
- Patients may complain of pain and sensitivity & bleeding of the gingiva on brushing.
- Angular cheilitis with fissuring and dry atrophic lips have been reported.
- Some cases reported as PCS consisted of a very localized area of erythematous gingiva, usually around a single tooth and measuring usually <1 cm..

## Laboratory Findings

- A biopsy is the most useful diagnostic test for this condition. Followed by
- Patch testing to identify an allergen.

A biopsy of the gingiva in PCS shows parakeratosis, epithelial hyperplasia, neutrophilic exocytosis, and numerous spongiotic pustules in the absence of Candida.

- The most significant finding is dense sheets of plasma cells in the lamina propria; many dilated capillaries lie close to the surface, accounting for the marked erythema.
- Eosinophils are not seen usually.

## Management

- PCS is self-limiting and will generally, but not always, regress if the contactant is identified and removed.
- Pain control and anti-inflammatory agents may be helpful during the healing process .
- Topical steroids may help reduce inflammation and speed healing.
- Some lesions have resolved with intralesional triamcinolone injections, although the gingiva is a particularly difficult location for such injections.
- Cases have also responded well to prednisone.
- Gingivectomies may be needed to recontour lesions that are long-standing and more fibrotic.
- Improvement with 2% fusidic acid may be seen

## Ulcerative, Vesicular, and Bullous Lesions Lecture 3

### The Patient with Recurring Oral Ulcers

- Recurring oral ulcers are among the most common problems seen by clinicians who manage diseases of the oral mucosa.
- Several diseases that should be included in the differential diagnosis of a patient with a history of recurring ulcers of the mouth, including:
  1. Recurrent aphthous stomatitis( RAS)
  2. Behçet Disease( Behçet syndrome)
  3. Recrudescence HSV infection.
  4. Recurrent Oral Erythema Multiforme.

### Recurrent aphthous stomatitis

RAS is a common disease in humans.

The reported prevalence in the general population varies from 15% to 20% .

It is probably the most common ulceration affecting the oral mucosa.

RAS is defined as

a recurrent oral necrotizing ulceration which is characterized by the periodic appearance of painful small, round or oval ulcer on the mucosa of the cheek, lips, tongue, soft palate, floor of the mouth and the pharynx with a bright-red circular inflammatory zone around the ulcer with a pseudo membrane ranging from gray to yellow in color.

The causes of RAS remains idiopathic or as a result of a variety of predisposing factors.

#### 1. Local factors

Trauma has been often identified as precipitating factor including

- Local anesthetic injection
- Sharp food
- Tooth brush

## 2-Systemic factors

RAS has been observed in several systemic disorders.

- \*Behcet's syndrome
- \*Cyclic neutropenia
- \*MAGIC syndrome( mouth and genital ulcer with inflamed cartilage).
- \*FAPA syndrome( periodic fever, aphthous ulcer, pharyngitis and cervical adenitis).
- \*Nutritional deficiencies of iron, folic acid, B-complex vitamins deficiency and zinc.
- \*Gastrointestinal disorders as Coeliac disease ,Ulcerative colitis & Crohn's disease
- \*HIV associated aphthous stomatitis
- \*Relative IgA Def
- \*Drugs as  
NSAIDs,                      Nicorandil                      & Methotrexate.

## 3-Microbial factors

It is also thought that Streptococcus Sangius and L-form Microorganism which were found to be predominant in cases of RAS ,but it can't produce RAS in experimental animals.

## 4-Psychological factors,

Stress and anxiety could play a significant role in the initiation of RAS.

## 5 -Hormonal factors,

It has been suggested to be an important etiological factor

## 6 -Genetic predisposition

An inherited predisposition to the RAS has also been described further evidence for the inherited nature of this disorder. It is supported by several investigators who have associated certain histocompatibility antigen(HLA)types with RAS such as HLA B12, HLA B51 and HLA CW7.

## 7 -Immunologic factors

Early work suggested either an autoimmune disorder or hypersensitivity to oral organisms such as Streptococcus sangius. Investigations using more sophisticated immune assays have not supported the early work and suggest a role of lymphocytotoxicity, antibody-dependent cell mediated cytotoxicity, and defects in lymphocyte cell subpopulation.

## 8 -Allergic factors

allergy to foods such as Milk, Cheese, Wheat, And Flour.

## Coeliac disease ( Gluten sensitive enteropathy)

is a permanent intolerance to gliadin( Fraction of gluten) the protein component of wheat.

It is inflammatory condition of the GIT that affect the small intestine in generally susceptible individuals.

Oral manifestations of Coeliac disease are

Oral Ulcer    Glossitis    Angular Cheilitis    Enamel Hypoplasia

A detergent present in toothpaste, sodium lauryl sulfate(SLS), was suspected as an etiologic factor in RAS development.

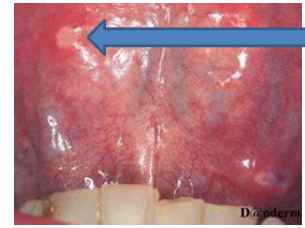
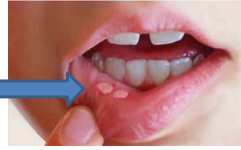## 9 -Smoking factor

It is well documented that cessation of smoking increases the frequency and severity of RAS.

## RAS is classified according to clinical characteristics

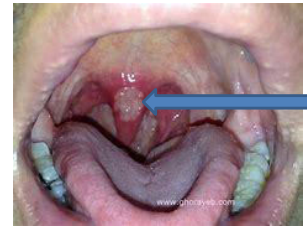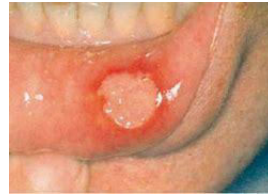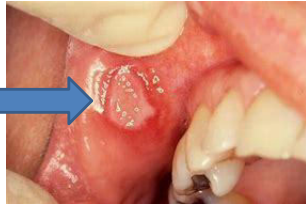### 1-Minor ulcers:

which comprise over 80% of RAS cases, are less than 1 cm in diameter and heal without scars.



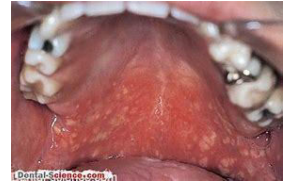### 2-Major Ulcers (Sutton's Disease, Periapical Mucosa Necrotica Recurrens);

are over 1 cm in diameter and take longer to heal and often scar.



### 3- Herpetiform ulcers

are considered a distinct clinical entity that manifests as recurrent crops of small ulcers throughout the oral mucosa.



## Diagnosis of RAS

RAS is essentially diagnosed by exclusion of other diseases.

1. A detailed history
2. Examination.
3. Laboratory investigation should be used when ulcers worsen or begin past the age of 25 years.
4. Biopsies are only indicated when it is necessary to exclude other diseases



## Treatment of RAU

Medication prescribed should relate to the severity of the disease.

### In mild cases

with two or three small lesions, use of a

**protective emollient such as Orabase** is all that is necessary.

Pain relief of minor lesions can be obtained with use of

**Topical Anesthetic Agent**

**Or Topical Diclofenac**, an NSAID frequently used topically.

**Triamcinolone acetonide in orabase ( Kenalog in orabase) 1X3 daily**

**Antiseptic mouth wash( Chlorhexidine gluconate 0.12%) 1x2 daily**

### In more severe cases,

The use of a high-potency topical steroid preparation, such as

**Fluocinonide,  
Betamethasone  
Clobetasol**

placed directly on the lesion shortens healing time and reduces the size of the ulcers.

## **Other topical preparations that have been shown to decrease the healing time of RAS lesions include**

- ❖ **Amlexanox Paste(aphthasol) 5%**
- ❖ **Topical Tetracycline**, which can be used either as a mouth rinse or applied on gauze sponges.
- ❖ **Intralesional Steroids** can be used to treat large major RAS lesions..
- ❖ **Levamisol** can be used to treat RAS lesions.

## **Drugs that have been reported to reduce the number of ulcers in selected cases of ( major aphthae) include**

- ✓ **Colchicine**
- ✓ **Pentoxifylline**
- ✓ **Dapsone**
- ✓ **Short Bursts Of Systemic Steroids**
- ✓ **Thalidomide**

## Behcet's syndrome

It is a chronic relapsing disease characterised by multiple signs & symptoms such as

- .Recurrent orogenital ulcerations
- .Eye involvement
- .Skin manifestations
- .Other system affections

### *Historical Aspect:*

In 1937, **Prof. Hulusi Behçet**, a Turkish dermatologist (1889-1948), described a syndrome characterized by recurrent oral ulcers, genital ulcers, & hypopyon uveitis of unknown cause.



## Behcet's syndrome

BS has an immunogenetic basis because of strong association with certain HLA type.

Four types of BS have been described

- .depending on the major site of involvement
- .Mucocutaneous .
- . Ocular
- . Arthritic .
- . Neurologic

**Oral mucosal involvement is common to all four types also each type may progress to the other types.**

**It affects young people & is more common among males**

### **Oral Lesion**

Recurrent painful ulcer

Single or multiple

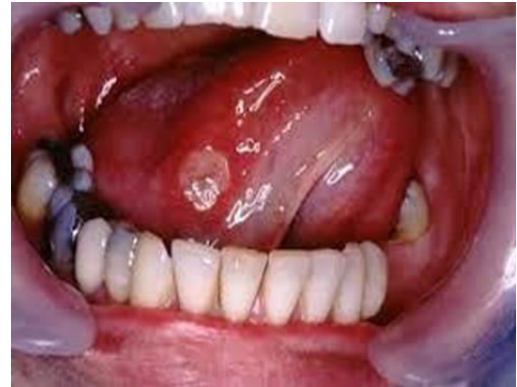Small or large

Round or oval

Yellow floor & red margin

Affecting any part

%90



## Genital lesion

### **Recurrent painful ulcer**

Affect scrotum in male & vulva in female

.%83

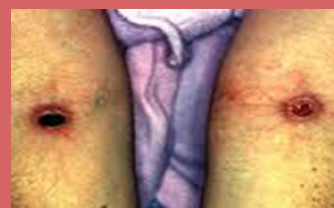## Skin lesion

1. Erythema nodosum.

It appears as red tender lumps or nodule on the legs , ankle, face, neck & arms.

2.Acneform Skin rash.

Pustular lesion.



## Eye lesion

Consist of

Anterior uveitis\_\_\_\_\_characterized by .

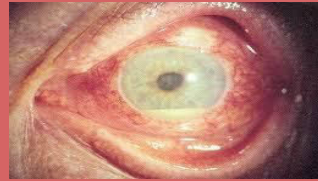Pain

Blurring vision

Light sensitivity

Tearing

Redness



2. Posterior uveitis    Damaging retina .

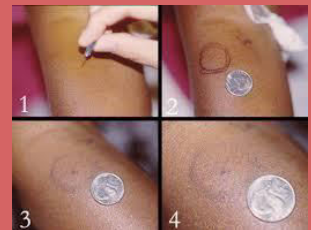## Diagnosis of Behcet's syndrome

### Major criteria

- . Recurrent Oral Ulcer. ➤
- . Recurrent Genital Ulcer. ➤
- . Eye Involvement. ➤
- . Skin Lesions. ➤
- . Ve+ Pathergy Test. Prick Test ➤

## Pathergy test or Prick test

These lesions may be precipitated by trauma, and it is common for patients with Behçet's syndrome to have a cutaneous hyper-reactivity to intracutaneous injection or a needle stick (pathergy)



positive pathergy is defined as an inflammatory reaction forming within 24 hours of needle .puncture, scratch, or saline injection.

## Minor criteria

- 1.GIT lesions .
- 2.CV lesions .
- 3.Vascular lesions .
- 4.Arthritic lesions .
- 5.CNS involvement .
- 6.+ve family history .
- 7-:Laboratory changes such as .
  - .Leukocytosis
  - .Eosinophilia
  - .Increase ESR

## Treatment of BS

### .Oral lesion

.Topical or intra-lesional corticosteroid.

### Ocular +Oral+Skin

Azathioprine ( Imuran) 50 mg tds

Prednisone

### Sever disease

.Cyclosporine +Colchicine +Corticosteroid

### Mucocutaneuos +GIT

Colchicine +Thalidomide

### .Eye lesion

.Pentoxifylline

## The Patient With Chronic Multiple Ulcers

1. Pemphigus Vulgaris
2. Paraneoplastic pemphigus PNPP
3. Pemphigus Vegetans
4. Subepithelial Bullous Dermatoses
5. Bullous Pemphigoid
6. Mucous Membrane Pemphigoid (Cicatrical Pemphigoid)
7. Linear IgA disease(LAD) and Chronic Bullous Disease of Childhood
8. Epidermolysis bullosa acquisita(EBA)



## Pemphigus

is a potentially life-threatening disease that causes blisters and erosions of the skin and mucous membranes.

These epithelial lesions are a result of autoantibodies that react with desmosomal glycoproteins that are present on the cell surface of the keratinocyte .

The immune reaction against these glycoproteins causes a loss of cell-to-cell adhesion, resulting in the formation of intraepithelial bullae.

The highest incidence occurring in the fifth and sixth decades of life, although rare cases have been reported in children and the elderly.

Pemphigus occurs more frequently in the Jewish population in whom studies have shown a strong association with major histocompatibility complex (MHC) class II alleles

**HLA-DR4**

**DQW3.**

**Familial pemphigus has also been reported.**

### The major variants of pemphigus:

- ✓ Pemphigus Vulgaris (PV)
- ✓ Pemphigus Vegetans
- ✓ Pemphigus Foliaceus
- ✓ Pemphigus Erythematosus,
- ✓ Para Neoplastic Pemphigus (PNPP)
- ✓ Drug –Related Pemphigus.

#### **Pemphigus Vegetans**

is a variant of pemphigus vulgaris

#### **Pemphigus Erythematosus**

is a variant of pemphigus Foliaceus.

Each form of this disease has antibodies directed against different target cell surface antigens, resulting in a lesion forming in different layer of the epithelium.

**In Pemphigus Foliaceus**, the blister occurs in the superficial granular cell layer,

**In Pemphigus Vulgaris**, the lesion is deeper, just above the basal cell layer.

Mucosal involvement is not a feature of the Foliaceus and erythematous forms of the disease.

## Pemphigus Vulgaris (PV)

Is the most common form of pemphigus, accounting for over 80% of cases.

The underlying mechanism responsible for causing the intraepithelial lesion of PV is the binding of IgG autoantibodies to Desmoglein 3, a trans membrane glycoprotein adhesion molecule present on desmosomes.

The separation of cells, called Acantholysis, takes place in the lower layers of the stratum spinosum [prickle cell layer] .

The classical lesion of pemphigus is a thin-walled bulla arising on otherwise normal skin or mucosa.

The bulla rapidly breaks but continues to extend peripherally, eventually leaving large areas of denuded skin .

A characteristic sign of the disease may be obtained by application of pressure to an intact bulla.

In patients with PV, the bulla enlarges by extension to an apparently normal surface .

Another characteristic sign of the disease is that pressure to an apparently normal area results in the formation of a new lesion.

This phenomenon, called the Nikolsky's Sign, results from the upper layer of the skin pulling away from the basal layer.

The Nikolsky's sign is most frequently associated with

**Pemphigus Vulgaris.**

**Epidermolysis Bullosa.**

### Oral Manifestations :

Eighty to ninety percent of patients with pemphigus vulgaris develop oral lesions sometime during the course of the disease, and, in 60% of cases, the oral lesions are the first sign.

The oral lesions may begin as the classic bulla on a non-inflamed base; more frequently, the clinician sees shallow irregular ulcers because the bullae rapidly break. Most commonly the lesions start on the buccal mucosa, often in areas of trauma along the occlusal plane. The palate and gingiva are other common sites of involvement.

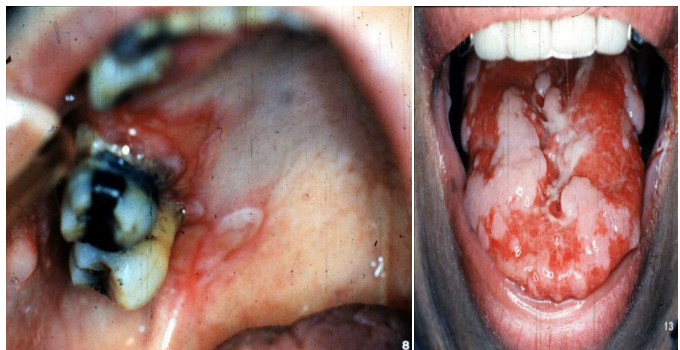In some cases, the lesions may start on the gingiva and called Desquamative gingivitis. It should be remembered that Desquamative gingivitis is not a diagnosis in itself; these lesions must be biopsied to rule out the possibility of

\*Pemphigus vulgaris

\*Bullous pemphigoid

\*Mucous membrane pemphigoid

\*Erosive lichen planus



## Laboratory Tests

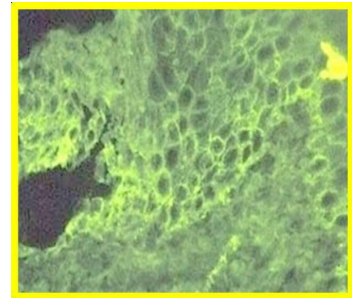
**\*PV is diagnosed by [ Biopsy]**

**\*A second biopsy, to be studied by DIF** In this technique for DIF ,fluorescein- labeled antihuman immunoglobulins are placed over the patient's tissue specimen . In cases of PV, the technique will detect antibodies, usually IgG and complement, bound to the surface of the keratinocytes.

**\*ELISA (enzyme-linked immune sorbent assay) :**

Has been developed that can detect desmoglein 1 and 3 in serum samples of patients with PV.

These laboratory tests should provide a new tool for the accurate diagnosis of PV and may also prove useful in monitoring the progress of the disease.



## **Treatment Of Pemphigus Vulgaris**

### ❖ **Corticosteroids**

The mainstay of treatment **remains high doses of systemic corticosteroids** usually given in dosages of **1 to 2 mg/kg/d**.

❖ **Adjuvant Therapy** When substantial doses of steroids must be used for long periods of time, adjuvant therapy is recommended to reduce the steroid dose and their potential serious complications. The most commonly used adjuvants are

❖ **Immunosuppressive Drugs** such as **Mycophenolate , Azathioprine Or Cyclophosphamide**.

❖ **Other Therapies That Have Been Reported As Beneficial Are**

❖ **Parenteral gold therapy**

❖ **Dapsone**

❖ **Tetracycline**

❖ **Plasmapheresis**, is particularly useful in patients refractory to corticosteroids.

❖ **8-Methoxypsoralen** followed by **exposure of peripheral blood to ultraviolet radiation** .

❖ **Rituximab**(a monoclonal antibody against the CD20 molecule of B lymphocytes) **combined with short-term prednisolone had superior efficacy to prednisolone alone**.

### **Paraneoplastic Pemphigus**

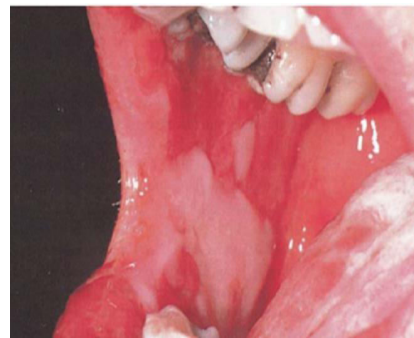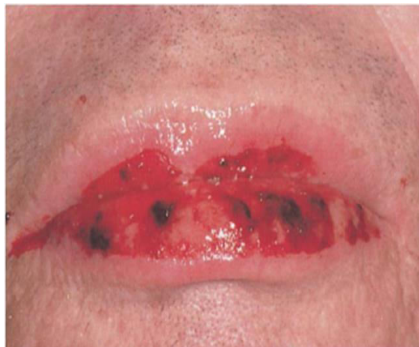is a severe variant of pemphigus that is associated with an underlying neoplasm most frequently

**\*Non-hodgkin's Lymphoma**

**\*Chronic Lymphocytic Leukemia** Patients with this form of pemphigus develop severe blistering and erosions of the mucous membranes and skin .

Treatment of this disease is difficult, **Most Patients Die From**

- **The effects of the underlying tumor,**
- **Respiratory failure due to acantholysis of respiratory epithelium,**



### **Drug-related Pemphigus like reactions**

Drugs implicated in the induction of Pemphigus like reactions are

- **Ampicillin**
- **Procaine Penicillin**
- **Benzyl Penicillin**
- **Pencillamine**
- **Piroxicam**
- **Captopril**
- **Diclofenac**
- **Rifampicin**
- **Gold Salt**
- **Garlic**

## Sub-epithelial Bullous Dermatoses

Sub-epithelial bullous dermatoses are a group of Mucocutaneous autoimmune blistering diseases that are characterized by a lesion in the basement membrane zone.

### The diseases in this group include

- Bullous Pemphigoid (BP)**
- Mucous Membrane (Cicatricial) Pemphigoid (MMP)**
- Linear IgA Disease (LAD)**
- Chronic Bullous Dermatitis Of Childhood (CBDC)**
- Erosive And Bullous Lichen Planus.**

### **Bullous Pemphigoid Etiology and Pathogenesis**

- BP is the most common of the subepithelial blistering diseases,
- Occurs chiefly in adults older than the age of 60 years; it is self-limited and may last from a few months to five years.
- BP may be a cause of death in older debilitated individuals.
- A thorough evaluation for an underlying malignancy is recommended for patients with severe or recalcitrant BP.

BP is an autoimmune disease caused by the binding of autoantibodies to specific antigens found in the lamina lucida region of the basement membrane on the hemidesmosomes of epithelial basal cells. These antigens are glycoproteins referred to as BP antigens, BP 180 and BP 230.

- Binding of antibody to antigen activates both leukocytes and complement, causing localized damage to the basement membrane, resulting in vesicle formation in the subepithelial region

### Clinical Manifestations

- The characteristic skin lesion of BP is a tense blister on an inflamed base accompanied by urticarial plaques in the scalp, abdomen, extremities, axilla, and groin. • Pruritus is a common feature of the skin lesions •

### **Oral Findings**

- ❑ Oral involvement occurs in 10–20% of BP patients.
- ❑ The oral lesions of BP are smaller, more slowly, and less painful than in PV; the often extensive labial involvement seen in PV is not present.
- ❑ Desquamative gingivitis has also been reported as the most common oral manifestation of BP, and the gingival lesions may be the only site of oral involvement.
- ❑ The gingival lesions consist of generalized edema, inflammation, and desquamation with localized areas of vesicle formation.
- ❑ The oral lesions are clinically and histologically indistinguishable from oral lesions of MMP.

### **Laboratory Findings**

Routine histology of a biopsy specimen demonstrates separation of the epithelium from the connective tissue at the basement membrane zone and an inflammatory infiltrate that is usually rich in eosinophils, particularly in skin biopsies

### **Management**

- ❑ Localized oral lesions of BP may be treated with high-potency topical steroids, such as clobetasol or betamethasone, whereas patients with more extensive disease require use of systemic corticosteroids alone or combined with immunosuppressive drugs such as azathioprine, cyclophosphamide, mycophenolate, or rituximab.
- ❑ Patients with moderate levels of disease may minimize the use of systemic steroids by the use of dapsone or tetracycline, doxycycline, or minocycline, which may be combined with niacinamide.

### **Mucous Membrane Pemphigoid (Cicatricial Pemphigoid)**

**MMP is a chronic autoimmune sub-epithelial disease that primarily affects the mucous membranes of patients over the age of 50 years, resulting in mucosal ulceration and subsequent scarring.**

**The primary lesion of MMP occurs when autoantibodies directed against proteins in the basement membrane zone, acting with complement (C3) and neutrophils, cause a sub-epithelial split and subsequent vesicle formation).**



## Clinical Manifestations.

The sub-epithelial lesions of MMP may involve any mucosal surface, but they most frequently involve the

**\*Oral Mucosa.** Similar to PV

**\*The Conjunctiva**

is the second most common site of involvement and can lead to scarring and adhesions developing between the bulbar and palpebral conjunctiva called **symblepharon**. Corneal damage is common, and progressive scarring leads to blindness in close to 15% of patients.

**\*Genital Mucosa,**

causing pain and sexual dysfunction.

**\*Laryngeal Involvement**

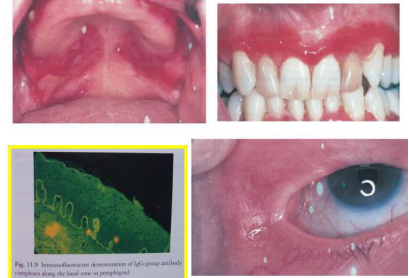
causes pain, hoarseness, and difficulty breathing,

**\* Esophageal Involvement**

may cause dysphagia, which can lead to debilitation and death in severe cases.

**\*Skin Lesions,**

usually of the head and neck region, are present in 20 to 30% of patients.



## Diagnosis.

Patients with MMP must have a

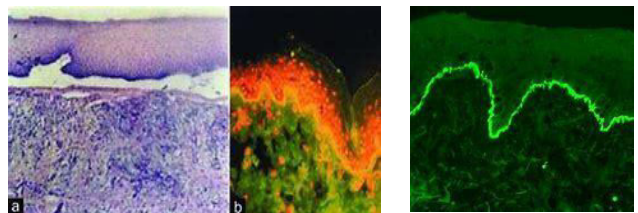
biopsy done for both **Routine And Direct Immunofluorescent Study.**

**Routine histopathology** shows sub-basilar cleavage.

Using the **direct immunofluorescent technique.** Biopsy

specimens taken from MMP patients demonstrate positive fluorescence for immunoglobulin and complement in the basement membrane zone in 50 to 80% of patients. The direct immuno-fluorescent technique is excellent for distinguishing MMP from pemphigus

Only 10% of MMP patients demonstrate positive **indirect immunofluorescence** for circulating anti-basement membrane zone antibodies.



### Management Mucous Membrane (Cicatrical) Pemphigoid (MMP)

Management of MMP depends on the severity of symptoms and sites of involvement.

#### For mild oral disease.

- Optimizing Oral Hygiene
- Topical Corticosteroids
  - Clobetasol paste
  - Or as a mouthwash, such as betamethasone sodium phosphate 0.5 mg in 10 mL of water as a 3-min rinse.
- Intralesional Triamcinolone to localized ulcers

#### For mild to moderate disease.

- Doxycycline----- if ineffective
- Dapsone

#### For more severe oral lesions or where there is multisite involvement

- Low Dose Systemic Steroids
- Immunosuppressive Drug Therapy such as
  - Azathioprine, Mycophenolate Mofetil,
  - Methotrexate, Cyclophosphamide
- Immunoglobuline
- Rituximab Are Reserved For Recalcitrant Disease.

### Epidermolysis bullosa:

The term epidermolysis bullosa [EB] is used for group of mechanobullos diseases characterized by the development of blisters in area of minor trauma .

At least 23 distinct forms of the disease have been recognized .

**Most of these have a hereditary basis** , with onset of blistering lesions at birth or within the first few years of life .

**Epidermolysis bullosa aquista is not hereditary** , however , and appear to be an **autoimmune disorder** , with lesions typically arising during adolescence or adulthood

#### Classification of Epidermolysis Bullosa

- Epidermolysis Bullosa Simplex
- Epidermolysis bullosa Dystrophic, dominant.
- Epidermolysis bullosa Dystrophic ,recessive.
- Junctional Epidermolysis bullosa.
- Epidermolysis bullosa aquista (acquired)

\***Bullae**, usually in areas of friction, which rupture, leaving shallow ulcers, and may result in painful erosion and severe scarring .

\***Enamel hypoplasia** is a common finding in Junctional Forms Of EB .

\***Rampant dental caries** frequently is seen in patients with **junctional EB** and severe **recessive dystrophic EB** .

\***Leukoplakia and squamous-cell carcinoma of the tongue** has been reported in several cases of **Recessive Dystrophic EB** .

\***Skin lesions** are characterized by the formation of bullae, followed by ulcerations and scarring, particularly in areas exposed to low- grade chronic trauma.

\* **Nail involvement, deformities of hands and feet, milia formation, and involvement of the larynx, pharynx, and esophagus** are common in the **Recessive Dystrophic Type** .

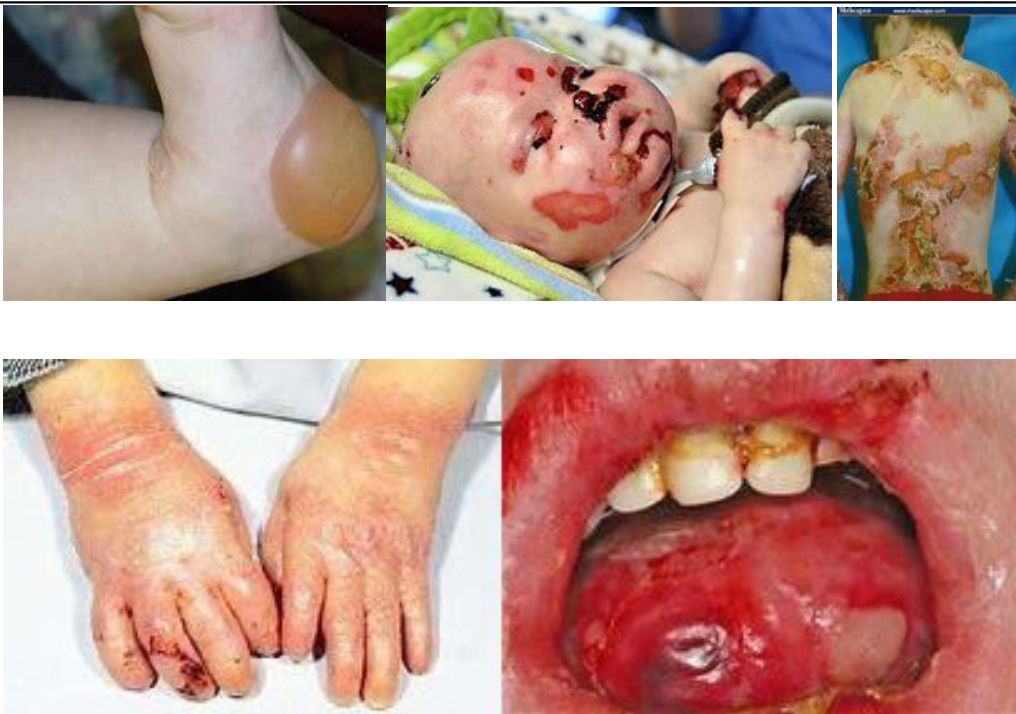**The prognosis for EB** depends on the specific subtype of EB .

EB Lethalis is usually fatal during the first few months of life because of fluid loss and sepsis.

Dystrophic Recessive EB is often fatal before patients reach adulthood.

Milder forms of EB are usually compatible with a normal life span.

**Treatment: Supportive. Systemic steroids in severe cases.**



### Patient with Single Ulcers

1. Traumatic Injuries Causing Solitary Ulcerations
2. Traumatic Ulcerative Granuloma (Eosinophilic Ulcer of Tongue)
3. Infectious Ulcers

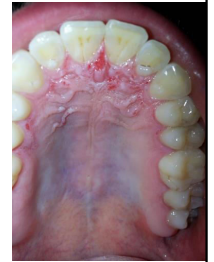
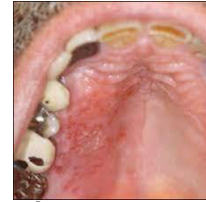
### Traumatic Injuries Causing Solitary Ulcerations

#### Etiology and Pathogenesis

Single mucosal ulcers may be caused by

- Direct Physical/ Mechanical,
- Thermal,
- Chemical Trauma To The Mucosa
- Or Even Vascular Compromise, causing tissue damage and ulceration.



#### Acute bite injuries

an example of **direct physical/ mechanical trauma**, occur often in the oral mucosa .

#### Traumatic injuries

may also result from **malocclusion, ill-fitting dental prostheses, overzealous toothbrushing and flossing, self-injurious habits, and oral piercings.**

#### Thermal injuries including

**Electrical burns** are infrequently seen in children who inadvertently chew on electrical wiring.

More commonly, **thermal burns occur on the palatal mucosa from ingesting hot foods and beverages (such as hot pizza or coffee).**

**An iatrogenic cause of thermal injury is from a heated dental instrument .**

### Chemical trauma

is caused by patients or dentists placing noxious and caustic substances directly on the mucosa or chewing medications such as **Aspirin Or Oral Bisphosphonates** may also lead to severe oral ulcers.

Mouthwashes or other oral care products with high alcoholic content, **Hydrogen Peroxide, Or Phenols** used too frequently or undiluted can cause mucosal ulcerations

- Some over-the-counter medications for treating aphthous ulcers contain high concentrations of **Silver Nitrate, Phenols, Or Sulfuric Acid** and should be used with caution.
- Ulcers have also resulted in the use of **Denture Cleansers As An Oral Rinse.**
- Prolonged contact of **Methacrylate Monomer** on the mucosa may also lead to necrosis of the mucosa.
- Necrosis of the bone and mucosa has been reported from **Chemicals Used In Endodontics** if these are pushed past the apices of teeth.

**Vascular compromise** leads to oral ulcers and two main patterns are identified.

- Necrotizing sialometaplasia** where there is local infarction of the salivary gland tissue leading to overlying ulceration, exfoliation of the necrotic tissue, and healing. Many etiologies have been identified including vasoconstrictors, sustained pressure and bulimia and the most common location for this condition is the hard palatal mucosa although any location that contains salivary glands may be affected.
- Another is systemic vasculitis, where inflammation of vessels leads to thrombosis and infarction. Tongue necrosis is a particularly well-documented aspect of giant cell (temporal) arteritis.**

## Management

1. Smaller lesions heal on their own once the irritant is removed.
  2. Pain can be achieved with topical anesthetics (viscous lidocaine).
  3. Topical steroids or intra-lesional steroid injections may be useful..
  4. Dentists also should be more aware of taking protective measures when using caustic substances and heated instruments.
  5. Electrical burns are generally deep and more extensive, and healing often results in scarring and contracture.
  6. Antibiotics may be necessary to prevent a secondary infection since these burns often take several weeks to heal.
- Necrotizing sialometaplasia heals on its own  
while ulcers of vasculitic origin will generally require treatment with systemic corticosteroids.

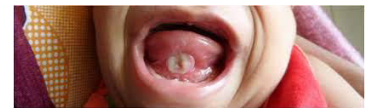## Traumatic Ulcerative Granuloma (Eosinophilic Ulcer of Tongue)

### Etiology and Pathogenesis

- This ulcerative condition of the oral cavity is considered traumatic in nature, although less than 50% of patients recall a history of trauma.
- other acute or chronic ulcerative conditions left untreated may become deep and penetrating.
- Similar lesions are seen on the ventral tongue in infants caused by the tongue rasping against newly erupted primary incisors, a condition known as Riga–Fede disease.

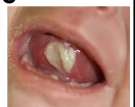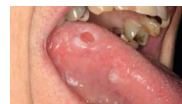### Clinical Manifestations

- First two years of life associated with erupting primary dentition.



### Oral Findings

- In children, the ulcers are always on the anterior ventral or dorsal tongue associated with erupting mandibular or maxillary incisors, respectively.
- The tongue is the site of involvement in approximately 60% of adult cases, usually on the posterior and lateral aspects.



- An ulcer develops that may not be painful in two-thirds of cases and may persist for months.
- A history of trauma is 20–50% of cases.
- The ulcer generally appears cleanly punched out, with surrounding erythema and keratosis if present for weeks or months.
- A single, chronic, painless ulcer with induration raises the suspicion for squamous cell carcinoma (especially if it is on the tongue), salivary gland malignancy or lymphoma.

### **Management**

1. A careful history is important to rule out continued trauma to the site.
2. Intralesional steroid injections performed over a few weeks will often resolve these lesions.
3. Wound debridement also often leads to complete resolution, in 1/3 of cases
4. The use of a nightguard on the lower teeth may help reduce nighttime trauma.

### **Infections Causing Solitary Ulcers**

1. Viral infections such as CMV and EBV of the herpes family may cause single ulcers that last for weeks or months in the immunocompromised patient.
2. The deep mycoses were uncommon causes of oral lesions prior to  
HIV infection,  
myelosuppressive cancer chemotherapy,  
and immunosuppressive drug therapy.

3. The dentist must consider this group of diseases in the differential diagnosis whenever isolated ulcerative oral lesions develop in known or suspected immunosuppressed patients.

If there is **reactive epithelial hyperplasia to the organism**, lesions may appear as **fungating masses resembling squamous cell carcinoma**.

Biopsy of suspected lesions, accompanied by a request for appropriate stains, is necessary for early diagnosis.

Newer molecular-based diagnostic tests are also available.



## Necrotizing Sialometaplasia (NS)

### Description and Etiology

NS is a benign, self-limiting, reactive inflammatory disorder of salivary tissue.

NS can resemble a malignancy and its misdiagnosis has resulted in unnecessary radical surgery.

### The etiology is

- Unknown,
- Although It Likely Represents A Local Ischemic Event
- Infectious Process
- Immune Response To An Unknown Allergen.

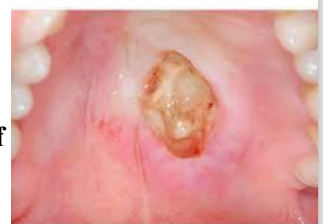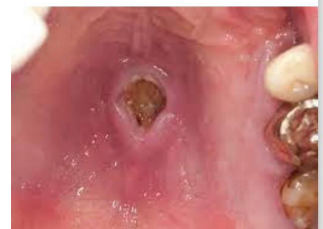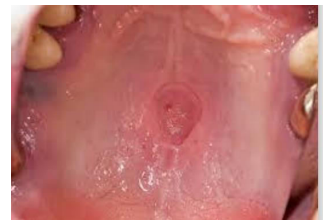### Development of NS has been associated with

- ✓ Smoking
- ✓ Local Injury
- ✓ Blunt Force Trauma
- ✓ Denture Wear
- ✓ Surgical Procedures
- ✓ It has been reported in pregnant patients
- ✓ Diabetes Mellitus
- ✓ Sickle Cell Disease
- ✓ Cocaine Abuse
- ✓ Bulimia
- ✓ Chronic Vomiting

The incidence of NS appears to be higher in **male patients** and especially in those **older than 40 years**.

### Clinical Presentation

- NS has a spectrum of clinical presentations.
- Most commonly it presents as a **painful**, rapidly progressing **swelling of the hard palate** with **central ulceration** and **peripheral erythema**.
- The associated **pain** is often described as **sharp** in character and may precede mucosal changes.
- **Numbness or anesthesia** in the associated area may be an early finding.
- The lesions are of rapid onset and range in **size from 1 to 3 cm**.
- Lesions occur predominantly **on the palate**; however, lesions can occur anywhere salivary gland tissue resides, including the **lips, retromolar, buccal mucosa, tongue, nasal cavity, and maxillary sinus**.
- Although the lesions are usually **unilateral**, **bilateral** cases have been reported.
- Lesion affecting the hard palate **clinically resemble salivary gland malignancies particularly mucoepidermoid carcinoma and adenoid cystic carcinoma**.
- **Rapid onset** of NS may be a distinguishing feature.
- Lesions often **occur shortly after an inciting event** to the area such as **oral surgical procedures, restorative dentistry, or administration of local anesthesia**, but lesions also reported to develop **weeks after a dental procedure or trauma**.
- It is also not uncommon for lesions to develop in an individual with no history of trauma or oral habit



## Diagnosis

- ❖ Histopathologic Diagnosis
- ❖ Complete Clinical History
- ❖ Medical History
- ❖ Clinical Photos Should Be Submitted With The Specimen.

## Treatment

- ❑ NS is considered a self-limiting condition typically resolving within 3-12 weeks.
- ❑ During this time, supportive and symptomatic treatment is usually adequate.
- ❑ Appropriate analgesics combined with use of an antiseptic mouthwash such as 0.12% chlorhexidine gluconate have been recommended.
- ❑ Surgical intervention is typically not required in cases of NS
- ❑ However, there are reports of resolution following debridement for particularly large lesions and those secondarily infected with bacterial species and Candida.

## Cheilitis Glandularis (CG)

### Description and Etiology

CG is a chronic inflammatory disorder affecting the minor salivary glands and their ducts in which thick saliva is secreted from dilated ductal openings.

(CG) is characterized by **Superficial Ulceration, Painless Crusting, Swelling, and Induration Of The Lip; a Mucinous Exudate is apparent at the ductal openings.**

### The etiology of (CG) is

still Undetermined,

it has been suggested that it is an Autosomal Dominant Hereditary Disease.

External Factors (Mainly UV rays)

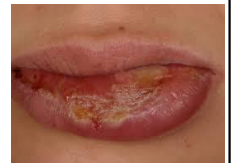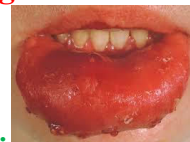Additional proposed predisposing factors include

- Poor Oral Hygiene,
- Chronic Exposure To Sunlight And Wind,
- Smoking,
- Immunocompromised State.

Occur in middle-aged and elderly men with only a few cases reported in women and children.

it is associated with a relatively high incidence of squamous cell carcinoma of the lip.

Although there may be a genetic susceptibility, no definitive cause has been established..

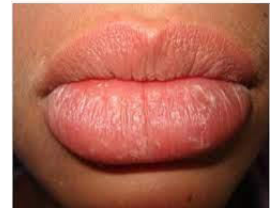

### ❖ Clinical Presentation

- ❖ CG presents with a secretion of thick saliva secreted from dilated ostia of swollen labial minor salivary glands.
- ❖ This saliva often adheres to the vermillion causing discomfort to the patient.
- ❖ Edema and focal ulceration may also be present.
- ❖ CG primarily affects the lower lip, but there are reports of upper lip and even palatal involvement.

### Differential diagnosis (DD) of CG includes :-

- Multiple Mucocele.
- Chronic Sialadenitis Of The Minor Salivary Glands.
- Factitious Cheilitis.
- Orofacial Granulomatosis.
- And Actinic Cheilitis.



### Treatment

- ❑ Elimination Of Potential Predisposing Factors
- ❑ The Use Of Lip Balms, Emollients, And Sunscreens for those with excessive exposure to the sun and wind are advised.
- ❑ Conservative Treatment of CG may involve using topical, intralesional or systemic steroids, systemic anticholinergics, systemic antihistamines, and/or antibiotics.
- ❑ Refractory Cases Require Surgical Intervention such as cryosurgery, vermillionectomy, and/or labial mucosal stripping.

Several reports documented the development of squamous cell carcinoma in areas affected by CG, leading some to call CG a premalignant lesion.

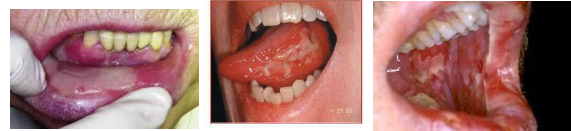## External Beam Radiation-Induced Pathology

### Description and Etiology

- ❑ External beam radiation therapy is standard treatment for head and neck cancers, and the salivary glands are often within the field of radiation.
- ❑ Although therapeutic dosages for cancer are typically in excess of 65 Gy,
- ❑ Permanent salivary gland damage and symptoms of oral dryness can develop after only 24-26 Gy.

The etiopathogenesis of radiation-induced salivary gland destruction is multifactorial, including

- Programmed Cell Death (Apoptosis)
- In Conjunction With Production Of Reactive Oxygen Species And Other Cytotoxic Products.
- Radiation-associated impaired blood flow may also contribute to the destruction of glandular acinar and ductal cells.



### Clinical Presentation

Acute effects on salivary function can be recognized within a week of initiating radiotherapy, with symptoms of

- ❑ Oral Dryness And Thick, Viscous Saliva developing by the end of the 2<sup>nd</sup> week.
- ❑ Oral mucositis is a very common consequence of treatment and can become severe enough to alter the radiation therapy regimen.
- ❑ Mucositis appears as a Sloughing Of The Oral Mucosa with Erythema And Ulceration.
- ❑ The pain associated with mucositis is described as a burning.
- ❑ Mucositis generally persists throughout radiotherapy, peaks at the end of the irradiation, and continues for 1-3 weeks after cessation of treatment.

\*By the end of a typical 6-7 week course of radiotherapy, salivary gland function is nearly absent.

\*Hypofunction remains at a steady rate post-radiation, with only small increases to two years post-radiotherapy (post-RT).

\*This can be permanent if the major salivary glands receive more than 24-26 GY Permanent xerostomia and oral complications of salivary hypofunction impair a patient's quality of life

**Signs and symptoms of radiation-associated xerostomia** include a

- Burning Sensation Of The Tongue
- New And Recurrent Dental Caries
- Difficulty In Wearing Oral Prostheses
- And Increased Thirst.

**Additional sequelae of radiation-induced salivary dysfunction include**

- Candidiasis.
- Microbial Infections.
- Plaque Retention.
- Gingivitis.
- Difficulty In Speaking And Tasting.
- Dysphagia.
- Mucosal Pain.

### **Internal Radiation-Induced Pathology**

#### **Radioactive iodine (RAI)**

is the standard treatment in cases of **Papillary And Follicular Thyroid Carcinomas** following thyroidectomy or in cases of suspected or known metastases.

A significant portion of the RAI taken up by thyroid tissue is concentrated and secreted through the salivary gland tissue resulting in radiation exposure of the salivary parenchyma and possible damage.

Standard doses of RAI often cause obstructive duct symptoms,

While Hyposalivation from Parenchymal damage is usually observed with **larger or repeated doses of RAI.**

**Acute risks associated with RAI include**

- Ageusia.
- Salivary Gland Swelling.
- Pain.

**While Long Term Side Effects Include**

- ✓ Recurrent Sialadenitis With Xerostomia.
- ✓ Stomatitis.
- ✓ Dental Caries.
- ✓ In Some Circumstances, RAI Treatment may lead to Glandular Fibrosis and Permanent Salivary Gland Hypofunction.

### Clinical Presentation

The **glandular effect** of RAI can be **mild to severe**.

Patients may be **asymptomatic**

or may complain of **parotid gland swelling (usually bilaterally), pain,**

**xerostomia,**

**and decreased salivary gland function** almost immediately after treatment.

RAI-induced salivary gland injury is irreversible; however, residual functioning salivary gland tissue is often present and responsive to therapy.

Following administration of  $^{131}\text{I}$ , patients should undergo an **aggressive salivary stimulation routine** that includes **Sugar-free Lozenges, Sour Candies, And Gums** to stimulate salivary flow.

**{{This will aid in clearing the  $^{131}\text{I}$  from the salivary glands and potentially decrease salivary gland damage.}}**

Stimulation of salivary flow by these means, however, should not be initiated within the first 24 hours after  $^{131}\text{I}$  therapy as this has been shown to potentially increase the salivary gland side effects of the RAI.

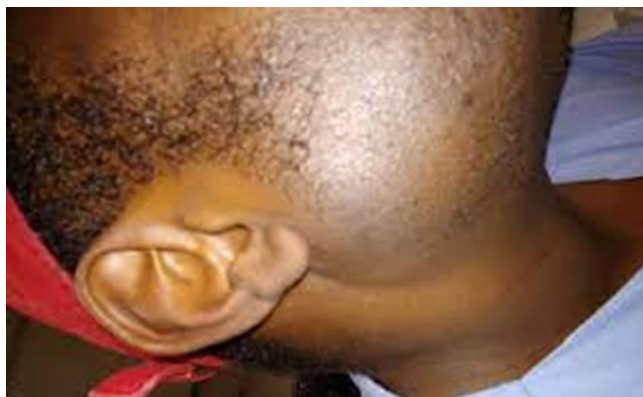**Pilocarpine And Cevimeline** used **before and after RAI treatment** may **decrease transit time through the salivary glands, thereby diminishing exposure.**

### Allergic Sialadenitis

- **Enlargement of the salivary glands has been associated with exposures to various pharmaceutical agents and allergens .**
- **It is unclear whether all of the reported cases are true allergic reaction or whether some represent secondary infections resulting from medication that reduced salivary output.**

### Compounds associated with allergic Sialadenitis

- **Ethambutol.**
- **Heavy metals.**
- **Iodine compounds**
- **Isoproterenol.**
- **Phenobarbital.**
- **Phenothiazine.**
- **Sulfisoxazole**



## Viral Diseases

**Mumps. (Paramyxovirus Or Epidemic Parotitis)** : acute viral infection caused by a ribonucleic acid (RNA) paramyxovirus and is transmitted by direct contact with salivary droplets.

### Clinical Presentation

Mumps typically occurs in children between the ages of 4 and 6 years.

The incubation period is 2-3 weeks.

The symptoms of mumps normally appear 2-3 weeks after the patient has been infected.

However, almost 20 % of people with the virus do not suffer any symptoms at all.

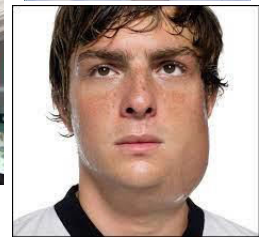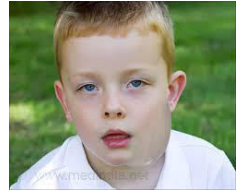Initially, flu-like symptoms will appear, such as:

- Body aches
- Headache
- Loss of appetite and/or nausea
- General fatigue
- Fever (low-grade)

Over the next few days, the classic symptoms of mumps will develop.

The main symptom is

**Painful And Swollen Parotid Glands**, one of three sets of salivary glands; this causes the person's cheeks to puff out. The swelling normally does not occur in one go -it happens in waves.



### Other associated symptoms can include:

- Pain in the sides of the face where it is swollen. Pain experienced when swallowing.
- Trouble swallowing.
- Fever
- Dry Mouth.
- Pain in joints.

Rarely, adults can contract mumps. In these cases, the symptoms are generally the same, but sometimes slightly worse and complications are slightly more likely.

### Treatment for mumps

Drinking plenty of fluids may help to relieve the symptoms of mumps.

Because mumps is viral, antibiotics cannot be used to treat it, and at present, there are no anti-viral medications that can treat mumps.

Current treatment can only help relieve the symptoms until the infection has run its course and the body has built up an immunity, much like a cold.

In most cases, people recover from mumps within 2 weeks.

### **Some steps can be taken to help relieve the symptoms of mumps:**

- Consume plenty of fluids, ideally water - avoid fruit juices as they stimulate the production of saliva, which can be painful.
- Place something cold on the swollen area to alleviate the pain.
- Eat mushy or liquid food as chewing might be painful.
- Get sufficient rest and sleep.
- Gargle warm salt water.
- Take painkillers.

Many painkillers are available to purchase over-the-counter or online, such as **Acetaminophen Or Ibuprofen.**



### Causes of mumps

Mumps is due to an infection by the mumps virus.

It can be transmitted by respiratory secretions (e.g. saliva) from a person already affected with the condition. When contracting mumps, the virus travels from the respiratory tract to the salivary glands and reproduces, causing the glands to swell.

#### Examples of how mumps can be spread include:

- Sneezing Or Coughing.**
- Using the same cutlery and plates as an infected person.**
- Sharing food and drink with someone who is infected.**
- Kissing.**
- An infected person touching their nose or mouth and then passing it onto a surface that someone else may touch.**

### Individuals infected with the mumps virus are contagious

for approximately 15 days (6 days before the symptoms start to show, and up to 9 days after they start).

The mumps virus is part of the paramyxovirus family, a common cause of infection, especially in children.

### Complications of mumps

Complications are more frequent in adults than children, the most common are:

#### Orchitis –

testicles swell and become painful, this happens to 1 in 5 adult males with mumps.

The swelling normally goes down within 1 week; tenderness can last longer than that. This rarely results in infertility.

#### Oophoritis –

ovaries swell and are painful; it occurs in 1 in 20 adult females. The swelling will subside as the immune system fights off the virus. This rarely results in infertility.

#### Viral meningitis –

this is one of the rarest of the common complications. It happens when the virus spreads through the bloodstream and infects the body's central nervous system (brain and spinal cord).

#### Inflamed pancreas (pancreatitis) –

pain will be experienced in the upper abdomen; this occurs in 1 out of 20 cases and is usually mild.

If a pregnant woman contracts mumps in the first 12-16 weeks of her pregnancy, she will have a slightly increased risk of miscarriage.

#### Rarer complications of mumps include:

Encephalitis - the brain swells causing neurological issues. In some cases, this can be fatal. This is a very rare risk factor and affects just 1 in 6,000 cases.

Hearing loss - this is the rarest of all the complications affecting just 1 in 15,000.

As rare as some of these complications are, it is important to seek medical advice or help if an individual suspects they or their child, may be developing them.

### Tests and diagnosis of mumps

Normally, mumps can be diagnosed by its symptoms alone, especially by examining the facial swelling. also:

- Check inside the mouth to see the position of the tonsils - when infected with mumps, a person's tonsils can get pushed to the side.
- Take the patient's temperature.
- Take a sample of blood, urine, or saliva to confirm diagnosis.
- Take a sample of CSF (cerebrospinal fluid) from the spine for testing - this is usually only in severe cases.

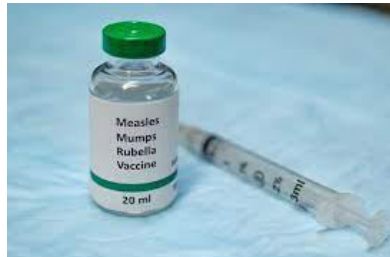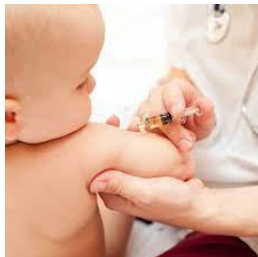### Prevention of mumps

The MMR vaccine will prevent mumps, measles, and rubella.

The mumps vaccine is the best method for preventing mumps; it can come on its own or as part of the MMR vaccine.

The MMR vaccine also defends the body against rubella and measles.

The MMR vaccine is given to an infant when they are just over 1 year old and again, as a booster, just before they start school.



- Mumps usually presents with 1-2 days of malaise, anorexia, and low- grade pyrexia with headache followed by non-purulent gland enlargement.
- Glandular swelling increases over the next few days, lasting about one week.
- 25%of cases may involve unilateral salivary gland swelling, or swelling may develop in the contralateral gland after a time delay, which can complicate diagnosis unless there is a high index of suspicion.
- 95%of symptomatic cases involve the parotid gland only, while about 10% of cases involve the bilateral submandibular and sublingual glands concomitant with the parotid swelling. A minority of cases may involve the submandibular glands alone.
- Salivary gland enlargement is sudden and painful to palpation with edema affecting the overlying skin and the duct orifice.
- If partial duct obstruction occurs, the patient may experience pain while eating.

### Bacterial Sialadenitis

Bacterial infections of the salivary glands are most commonly seen in the patients with reduced salivary gland function.

An acute and sudden onset of a swollen and painful salivary gland is termed an acute bacterial sialadenitis, whereas repeated infections are termed chronic bacterial sialadenitis .

Bacterial sialadenitis occurs more frequently in the parotid glands.

It is theorized that the submandibular glands may be protected by the high level of mucin in the saliva, which has potent antimicrobial activity.

A purulent discharge may be expressed from the duct orifice, and samples of these exudates should be cultured for aerobes and anaerobes type of bacteria.

### Risk factors of sialoadenitis

- Dehydration,
- The use of xerogenic drugs,
- Salivary gland diseases,
- Nerve damage,
- Ductal obstruction,
- Irradiation,
- And chronic diseases such as diabetes mellitus and SS.
- Retrograde bacterial parotitis following surgery under general anesthesia is a well recognized complication. It is due to the markedly decreased salivary flow during anesthesia, often as the result of anticholinergic drugs and relative dehydration.

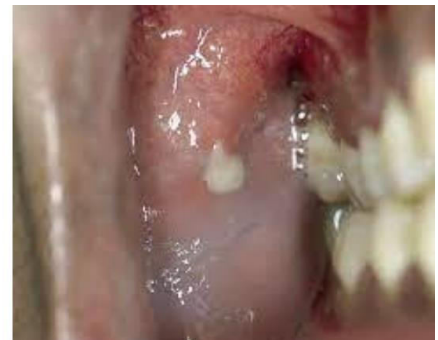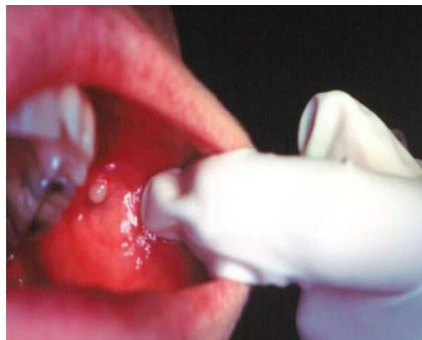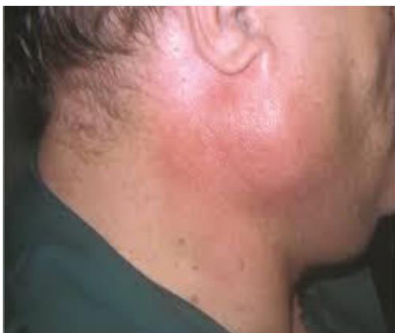Although bacterial sialadenitis occurs most frequently in the parotid glands, it can occur in any of the glands. It is thought that the antimicrobial activity of mucin, found in the saliva of the submandibular and sublingual glands, may competitively inhibit bacterial attachment to the epithelium of the salivary ducts.

The serous parotid gland saliva also contains less lysosomes, IgA antibodies, and sialic acid.

Anatomy may also play a protective role; tongue movements tend to clear the floor of the mouth and protect Wharton's duct. In contrast, the orifice of Stensen's duct is located adjacent to the molars, where heavy bacterial colonization occurs.

### Clinical Presentation

- Patients usually present with a sudden onset of unilateral or bilateral salivary gland enlargement. Approximately 20% of the cases present as bilateral infections.
- Complaints of fevers, chills, malaise, trismus, and dysphagia may accompany these findings.
- Observation of dry oral mucosa may indicate systemic dehydration.
- The involved gland is enlarged, warm, painful, indurated, and tender to palpation.
- If Stensen's duct is involved, it may appear erythematous and edematous.
- Some cases there may also be erythema of the overlying skin.
- In approximately 75% of cases, purulent discharge may be expressed from the orifice.



## Diagnosis

- ❑ Bacterial parotitis is largely a clinical diagnosis.
- ❑ If purulent discharge can be expressed from the duct orifice, samples should be cultured for aerobes, anaerobes, fungi, and mycobacteria.
- ❑ Differentiating between viral and bacterial infectious parotitis can be challenging.
- ❑ In general, viral infections are bilateral, affect younger patients, have prodromal symptoms, do not involve purulent drainage, and patients appear to have less toxicity.
- ❑ Although systemic symptoms follow the development of a symptomatic gland in suppurative parotitis, the order is usually reversed in viral parotitis.
  - Sialendoscopy,
  - US,
  - CT,
  - MRI
  - Sialography,
  - Percutaneous Aspiration

may be helpful to rule out Chronic Salivary Gland

Infections,  
Cysts,  
Obstructions,  
Or Neoplasms.

## Treatment

### Treatment goals of bacterial sialadenitis include

- Resolution of signs and symptoms of infection,
- Elimination of the causative bacteria,
- Rehydration,
- And elimination of obstruction where present.

This may involve the use of

- ❑ Antibiotics,
- ❑ Analgesics,
- ❑ Heat application,
- ❑ Fluids,
- ❑ Glandular massage,
- ❑ Oral hygiene products,
- ❑ Sialogogues.
- ❑ Anti-inflammatory agents including steroids may help to rapidly reduce pain and swelling.
- ❑ Patients should also be instructed to massage the gland several times a day. Where possible.
- ❑ Medications implicated in salivary gland hypofunction should be discontinued.

Significant improvement should be observed within 24 -48 hours. Appropriate antibiotic regimens should include coverage for S. aureus as well as oral polymicrobial aerobic and anaerobic infections.

It is estimated that up to 75% of infections are caused by P-lactamase-producing bacteria, and therefore, treatment with anti-Staphylococcal penicillin, a combination P-lactamase inhibitor, or a first-generation cephalosporin is appropriate.

Macrolides such as azithromycin with metronidazole can be an alternative for those with a penicillin allergy.

Antibiotics should not be started routinely unless bacterial infection is clinically obvious.

Under all circumstances, purulent discharge from the salivary gland should be cultured to confirm the diagnosis and determine antibiotic sensitivity.

Antibiotic therapy may need to be modified later based on culture results.

### Additional potential complications include

- ❑ Facial Nerve Palsy,
- ❑ Sepsis,
- ❑ Mandibular Osteomyelitis,
- ❑ Internal Jugular Vein Thrombophlebitis,
- ❑ Respiratory Obstruction.

## Systemic condition with salivary gland involvement

### 1- Metabolic Conditions Include -

- Diabetes
- Anorexia Nervosa/Bulimia
- Chronic Alcoholism
- Dehydration

### 2- Medication-induced Salivary Dysfunction

There are over 400 medications that are listed as having dry mouth as an adverse event. Some drugs may not actually cause impaired salivary output but may produce alteration in Saliva composition that lead to the perception of oral dryness.

### Common medication categories Associated with salivary hypofunction

- Anticholinergics
- Antihistamines
- Antihypertensive
- Anti-parkinson's disease
- Antiseizure
- Cytotoxic agents ,
- Sedative
- And Tranquilizers,
- Skeletal Muscle Relaxants,
- Tricyclic
- Antidepressants

## 3- Immune Conditions

A- Mikulicz's Disease Previously Known as benign lymphoepithelial lesion, is characterized by symmetrical lacrimal, parotid, and submandibular gland enlargement with associated lymphocytic infiltrations.

### Histopathologically,

Mikulicz's disease is associated with prominent infiltration of IgG4-positive plasmacytes in to involved exocrine glands.

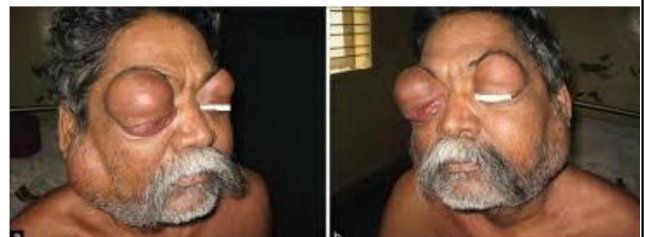### Diagnosis

is based on finding of salivary gland biopsy and the absence of the alterations in peripheral blood and autoimmune serologies seen in Sjogren's syndrome

It can be diagnosed by clinical feature and biopsy.

### Treatment

Surgical removal of the involved gland should be done.



## B- Sjogren's Syndrome (Primary And Secondary)

Sjogren's syndrome is a chronic autoimmune disease characterized by symptoms of oral and ocular dryness, exocrine dysfunction and lymphocytic infiltration, and destruction of the exocrine.

There are two types:

❖ **Primary Sjogren's Syndrome** (it also called **Sicca Syndrome** and consists of dry eyes and dry mouth )

❖ **Secondary Sjogren's Syndrome**:- it consists of

❑ Dry Eyes ,

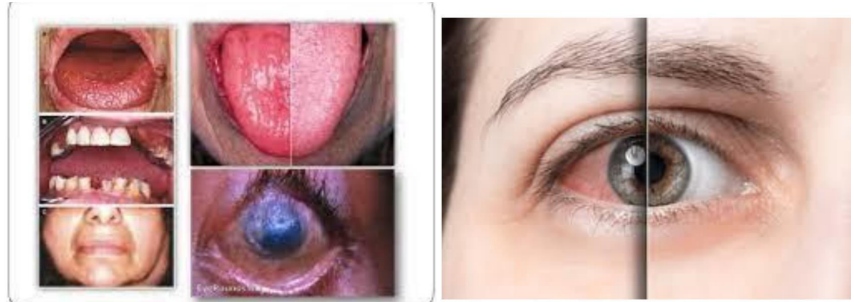
❑ Dry Mouth

❑ Collagen Disorders

➤ **Rheumatoid Arthritis,**

➤ **Systemic Lupus Erythematosus**

➤ **Scleroderma .**



## Oral manifestation of Sjogren's syndrome

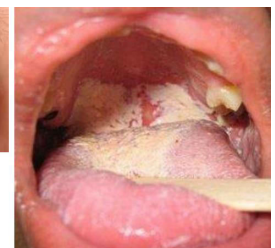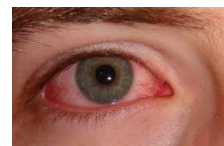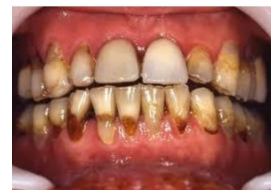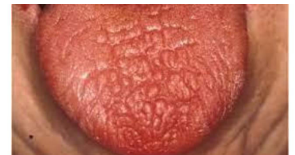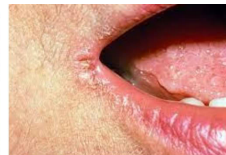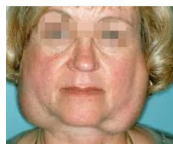- **Xerostomia is A major complaint.**
- **Unpleasant taste**
- **Difficulty in eating .**
- **Pus may be emitted from the duct .**
- **Angular stomatitis and denture stomatitis also occur .**
- **Unilateral or bilateral enlargement of parotid gland.**
- **In advanced cases , the mucosa is glazed , dry and tends to form fine wrinkles .**

• **The tongue typically develops a characteristic**

**Lobulated**

**Red Surface With Partial Or Complete Depapillation .**

- **There is also decrease in number of taste buds , which leads to an impaired sense of taste .**
- **Dental caries is sever and gross accumulation of plaque .**
- **Periodontal disease can also occur .**
- **The Regional lymph node may be enlarged and tender .**







## Management of xerostomia

### 1- Preventing Therapy :

- ❑ The use of Topical Fluorides in a patient with salivary gland hypofunction is absolutely critical to control dental caries.
- ❑ Avoiding cariogenic foods and beverages and brushing immediately after meals.
- ❑ Chronic use of alcohol and caffeine can increase oral dryness and should be minimized.

### 2- Symptomatic Treatment :

- ❑ Patients should be encouraged to sip water throughout the day; this will help moisten the oral cavity, hydrate the mucosa, and clear debris from the mouth.
- ❑ There are a number of oral rinses, mouthwashes, and gels available for dry mouth patients.
- ❑ The frequent use of products containing aloe vera or vitamin e should be encouraged.
- ❑ Saliva replacements ('artificial saliva') can be used.

### 3- Salivary Stimulation :

- ✓ Local or topical stimulation: chewing sugar-free gums or mints.
- ✓ Acupuncture, with application of needles in the perioral and other regions, has been proposed as a therapy for salivary gland hypofunction and xerostomia.
- ✓ Systemic stimulation: pilocarpine. Anticholinergic drugs pilocarpine and cevimeline.

4- Therapy Of Underlying Systemic Disorders:- anti-inflammatory therapies to treat the autoimmune exocrinopathy of Sjogren's syndrome.

## Sialorrhea

Sialorrhea is defined as an excessive secretion of saliva or hypersalivation.

The cause is an increase in saliva production or a decrease in salivary clearance.

### Causes

- ❑ Medications ( Pilocarpine, Cevimeline, Lithium, And Nitrazepam),
- ❑ Hyperhydration ,
- ❑ Infant Teething,
- ❑ The Secretory Phase Of Menstruation,
- ❑ Idiopathic Paroxysmal Hypersalivation,
- ❑ Heavy Metal Poisoning (Iron, Lead, Arsenic, Mercury, Thallium), Organophosphorous ( Acetylcholinesterase ) Poisoning,
- ❑ Nausea,
- ❑ Gastroesophageal Reflux Disease,
- ❑ Obstructive Esophagitis, Neurologic Changes Such As In A Cerebral Vascular Accident (CVA), Neuromuscular Diseases, Neurologic Diseases, And Central Neurologic Infections.

Minor hypersalivation may result from

- Local Irritations, such as Aphthous Ulcers
- or An Ill-fitting Oral Prosthesis.
- Most cases of hypersalivation are a Secretion Clearance Issue.

A blood sample should be obtained and evaluated for heavy metals

There are three types of treatments for hypersalivation according to the exact cause.

\* Physical Therapy \* Medications \* Surgery.



## Salivary gland tumors

The majority of salivary gland tumors (about 80%) arise in the parotid glands.

The submandibular glands account for 10 to 15% of tumors,

The remaining tumors develop in the sublingual or minor salivary glands.

Approximately 80% of parotid gland tumors and approximately half of submandibular gland and minor salivary gland tumors are benign.

In contrast, more than 60% of tumors in the sublingual gland are malignant.

### Benign tumors.

Pleomorphic adenoma (most common.)

The majority of these tumors are found in the parotid glands.

Histologically, the lesion demonstrates both epithelial and mesenchymal elements. The epithelial cells make up a trabecular pattern that is contained within a stroma. The stroma may be chondroid, myxoid, osteoid, or fibroid. The presence of these different elements accounts for the name pleomorphic tumor or mixed tumor. One characteristic of a pleomorphic adenoma is the presence of microscopic projections of tumor outside of the capsule.

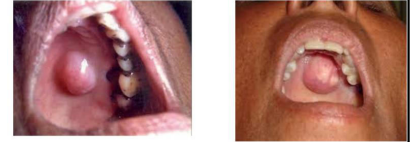About 90% of cases occur in parotid ,

start as small , painless nodule which slowly begins to increase in size .

The tumor tends to be round or oval when it is small , as it grows bigger it becomes lobulated . In some cases , intraoral swelling may be observed . It is firm and rubbery to feel .

Diagnosis:- \*CT will help to know exact extension of location . \* Biopsy

Treatment:- Surgical removal with adequate margins is the principal treatment.



## Monomorphic adenoma .

A monomorphic adenoma is a tumor that is composed predominantly of one cell type.

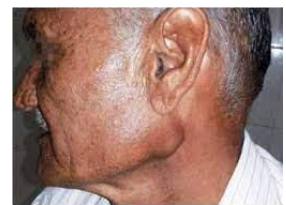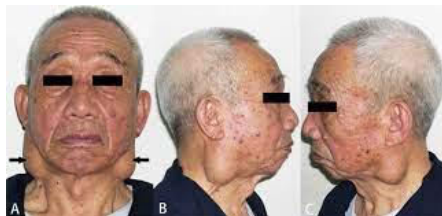Papillary cystadenoma lymphomatosum Known as Warthin's tumor

is the second most common benign tumor of the parotid gland.

It represents 6 to 10% of all parotid tumors and is most commonly located in the inferior pole of the gland, posterior to the angle of the mandible.

Because this tumor contains oncocytes, it will take up technetium and will be visible on tc 99m scintiscans.

Larger tumors that involve a significant amount of the superficial lobe of the parotid gland are best treated by a superficial parotidectomy.



### Oncocytoma

Less common benign tumors that make up less than 1% of all salivary gland neoplasms.

This tumor occurs almost exclusively in the parotid glands, bilateral presentation of this tumor can occur, and it is the second most common salivary gland tumor that occurs bilaterally (after Warthin's tumor), these tumors appear non-cystic and firm.

The treatment for parotid Oncocytomas is superficial parotidectomy with preservation of the facial nerve.

Fig. 1: Clinical photographs of the patient showing

### Basal cell adenoma canalicular

### Adenoma myoepithelioma sebaceous

These lesions are derived from sebaceous glands located within salivary gland tissue. The parotid gland is the most commonly involved gland.

Benign forms contain well differentiated sebaceous cells, whereas malignant forms consist of more poorly differentiated cells.

Intraoral lesions are surgically removed with a border of normal tissue.

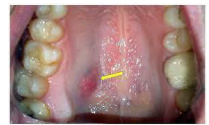### Ductal papilloma

Ductal papilloma form a subset of benign salivary gland tumors that arise from the excretory ducts, predominantly of the minor salivary glands.

## Malignant Tumors

### Mucoepidermoid Carcenoma

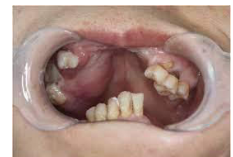It is the most common malignant tumor of the parotid gland and the second most common malignant tumor of the submandibular , after adenoid cystic carcinoma.



### Adenoid Cystic Carcinoma

Account for approximately 6 to 10% of all salivary gland tumors and are the most common malignant tumors of the submandibular and minor salivary glands.

It is characterized by frequent late distant metastases and local recurrences, which account for low long-term survival rates.



### Treatment.

Because of the ability of this lesion to spread along the nerve sheaths,

**Radical Surgical Excision** of the lesion is the appropriate treatment.

Even with aggressive surgical margins, tumor cells can remain, leading to long-term recurrence.

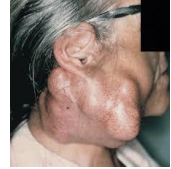### Factors affecting the long term prognosis are

- The Size Of The Primary Lesion,
- Its Anatomic Location,
- The Presence Of Metastases At The Time Of Surgery,
- And Facial Nerve Involvement.

### Acinic cell carcinoma

Represents about 1% of all salivary gland tumors. Between 90 and 95% of these tumors are found in the parotid gland; almost all of the remaining tumors are located in the submandibular gland.

It is the second most common malignant salivary gland tumor in children, second only to mucoepidermoid carcinoma. The superficial lobe and the inferior pole of the parotid gland are common sites of occurrence. Bilateral involvement of the parotid gland has been reported in approximately 3% of cases.



### Treatment

consists of superficial parotidectomy, with facial nerve preservation if possible.

When these tumors are found in the submandibular gland, total gland removal is the treatment of choice

### Carcinoma ex pleomorphic adenoma

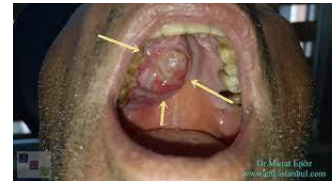Is a malignant tumor that arises within a preexisting pleomorphic adenoma.

The malignant cells in this tumor are epithelial in origin.

This tumor represents 2 to 5% of all salivary gland tumors.

Surgical removal with postoperative radiation therapy is the recommended treatment.

Early removal of benign parotid gland tumors is recommended to avoid the development of this lesion.



### Treatments

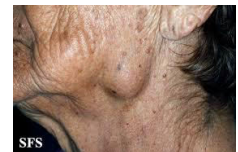For patients of any age involve surgical removal and adjuvant radiotherapy for more advanced cancers.

Efficacy of treatment of malignant tumors is dependent upon stage, location, presence of perineural invasion, treatment modality, histologic type, and presence of regional invasion

### Adenocarcinoma

It is a tumor arising from salivary duct epithelium.

The tumors may be present for weeks, months, or even several years, prior to diagnosis.  
 A mass or lump on the side of the face may be observed, since mostly the parotid Gland is affected.



- Most tumors are locally infiltrative, but some are well-defined.
- Some individuals with basal cell adenocarcinomas may have other unrelated skin Tumors, such as adnexal tumors of skin
- Most tumors are asymptomatic and no significant signs and symptoms are observed.
- Neurological signs and symptoms, such as facial muscle weakness and pain, due To facial nerve involvement may be seen
- Pain while eating/chewing.
- Persistent facial pain at the site of swelling of the tumor; this requires an Immediate checkup by a healthcare provider.
- Tumor infiltration into the bone.
- Involvement of the lymphatic system may be seen in 25% of the cases.

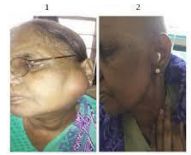## **Lymphoma**

Primary lymphoma of the salivary glands probably arises from lymph tissue within the glands.

However, primary lymphoma of the salivary glands is rare.

The major forms of lymphoma are non- Hodgkin's lymphoma (nhl) and Hodgkin's disease.

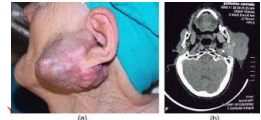
Histologic examination demonstrates b-cell lymphoma tissue that originates from lymphoid tissue associated with malignant mucosa.



## **Myoepithelial carcinoma**

Myoepithelial carcinoma or malignant myoepithelioma is a very rare malignant salivary gland neoplasm with good short-term survival and poor long-term survival. Due to their morphologic heterogeneity, these neoplasms can be confused easily with other tumors.

Early and aggressive surgical removal with close follow- up is required.



## **Frey's syndrome(baillarger's syndrome ,dupuy's syndrome ,auriculotemporal syndrome).**

The best described and more frequent complication following parotidectomy is gustatory sweating or Frey syndrome.

The pathogenesis of Frey syndrome is based on the aberrant regeneration of sectioned parasympathetic secretomotor fibers of the auriculotemporal nerve with inappropriate innervation of the cutaneous facial sweat glands that are normally innervated by sympathetic cholinergic fibers.

As a consequence, Frey syndrome is a disorder characterized by unilateral sweating and Flushing of the facial skin in the area of the parotid gland occurring during meals that becomes evident usually 1-12 months after surgery.



## Multiple sclerosis (MS)

Chronic neurologic disease characterized by Multiple Areas Of Central Nervous System (CNS) White Matter Inflammation, Demyelination, And Gliosis (Scarring).

Myelin is critical for propagation of nerve impulses, and when it is destroyed in MS, slowing and/or complete block of impulse propagation is manifested by abnormal muscular and neurologic signs and symptoms, associated with the myelination of axons within the central nervous system.

The disease occurs more frequently among( women). The average age of onset is during the (4<sup>th</sup> decade of life), but MS may occur at any age.

The disease presents in the form of Recurrent Attacks

### Etiology of MS

1. An Immunologic (Autoimmune Disease) Basis is strongly suggested by the presence of activated T lymphocytes and autoantibodies to glycoproteins detected in MS lesions.
2. Environmental exposure in MS, and two common infectious agents to be implicated in the pathogenesis of this disease are Epstein-Barr virus and Human Herpes Virus 6. Other viruses that have been implicated in the pathogenesis of MS include Measles, Mumps, Rubella, Parainfluenza, And Human T-lymphotropic Virus
3. Increased Antibody Titers Against Measles Virus, Rubella Virus, Mumps Virus, Epstein- Barr Virus, Herpes Simplex Viruses 1 And 2, And Human Herpes Virus 6 (HHV-6) Have Been Found In The Cerebrospinal Fluid And Serum.
4. Genetic Influences Also Appear To Play A Significant Role In The Development Of MS.

### Pathophysiology of multiple sclerosis.

an inflammatory demyelinating disease of the CNS in which activated immune cells invade the central nervous system and cause Inflammation, Neuro Degeneration, And Tissue Damage. The underlying cause is currently unknown. Different cells are involved in the abnormal immune response. Two important types of immune cells are T cells and B cells. T cells become activated in the lymph system and in MS, enter the CNS through blood vessels

### Clinical Manifestations of MS

The dentist have to know the most common symptoms following an acute exacerbation include

- Impairment Of Vision,
- Muscular Incoordination,
- And Bladder Dysfunction

The clinical signs and symptoms of MS depend on the site of the demyelinating lesion of the CNS involved, and frequently affected areas include the Optic Chiasma, Brainstem, Cerebellum, And Spinal Cord.

1. More than 60% of individuals with MS Have Visual Disturbances caused by demyelinating lesions of the second cranial nerve.

The loss of vision usually occurs over a period of several days, with partial recovery within 1month.

1. Other ophthalmic symptoms include —Color Blindness And Diplopia Caused By Involvement Of The Third, Fourth, And Sixth Cranial Nerves.
2. Uhthoff's sign, found in MS, is characterized by Rapid Vision Loss Following A Body Temperature Increase that is associated with strenuous exercise.

4. MS patients frequently complain of **Electric Shock-like Sensations That Are Evoked By Neck Flexion And Radiate Down The Back And Into The Legs.** This is referred to as **Lhermitte's Symptom** and is generally self-limiting but may persist for years

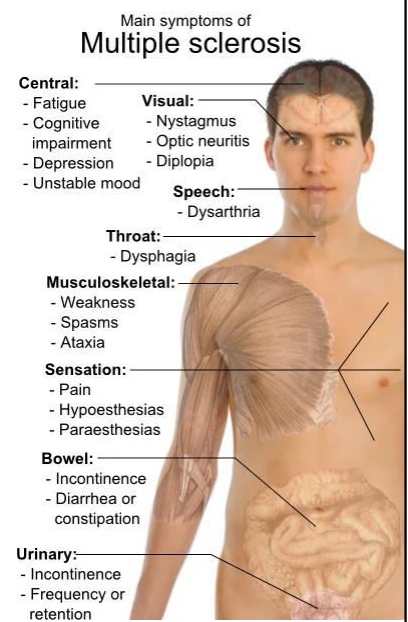
5. **Weakness Or Paresthesia Of The Extremities, With An Increase In The Deep Tendon Reflexes,** is another common early finding in cases of MS.

6. **Bladder Dysfunction, Ataxia, Vertigo, And Generalized Incoordination**

7. The majorities of cases of MS are chronic and are characterized by exacerbations and remissions over a period of many years.

8. During acute episodes, severe neurologic involvement is evident.

This slowly resolves, but some permanent neurologic involvement remains after each episode



## **Diagnosis**

Clinical and is based on the age of the patient, the presence of neurologic signs that cannot be explained by a single lesion, the progressive nature of the disease, and a history of exacerbations and remissions.

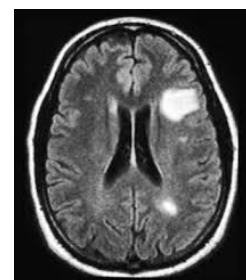
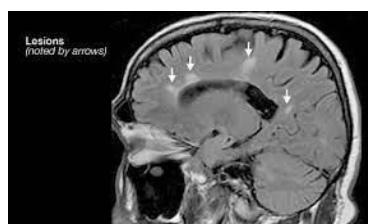
1. There are no definitive laboratory tests for MS, but **Demyelinating Changes can be seen on (MRI) in more than 90% Of Cases.**

MRI demonstrates characteristic abnormalities of MS in >95% of patients.

**MS plaques are visible as hyperintense**

1. **Evoked Potentials Measure CNS Electrical Potentials, And Abnormalities Are Detected In Up To 90% of patients with MS.**

2. **CSF is often analyzed** in patients suspected of having MS, and positive findings include an **Increase In Total Protein And Mononuclear White Blood Cells.**



## Treatment.( the medication should be taken into consideration by the dentist)

### 1. High Doses Of Intravenous Corticosteroids

may arrest the progress of MS;

about 85% of patients with relapsing-remitting MS show objective signs of neurologic improvement during treatment with intravenous corticosteroids.

Glucocorticoids are used to manage both initial attacks and acute exacerbations of MS.

Intravenous Methylprednisolone is typically administered at a dose between 500 and 1000 mg/d for three to five days to reduce the severity and length of an attacks

2. Long-term treatment with Immunosuppressants may reduce the frequency of relapse in patients with MS.

- Azathioprine is probably the safest drug in this category and has reduced relapse to 70% of study patients in 3years.
- Methotrexate appears to be the best therapy for slowing deterioration in patients with chronic progressive MS.

3. Interferon-γ-1b And -1a has shown promise; both have been shown to reduce clinical attacks and lesions

## Oral Health Considerations

Individuals may present with signs and symptoms of MS.

### 1. Trigeminal Neuralgia (TGN),

which is characterized by Electric Shock-like Pain, may be an initial manifestation of MS in up to 3% of cases. MS-related TGN is similar to idiopathic TGN .

Features of MS-related TGN include possible absence of trigger zones and continuous pain with lower intensity.

2. Medications Often Used To Manage TGN In MS are similar to those used for treatment of idiopathic TGN.

3. Patients with MS may also demonstrate Neuropathy Of The Maxillary (V2) And Mandibular Branches (V3) Of The Trigeminal Nerve, Which May Include Burning, Tingling, And/ Or Reduced Sensation.

4. Neuropathy of the Mental Nerve can cause Numbness of the Lower Lip And Chin.

5. Myokymia may be seen in patients with MS and consists of Rapid, Flickering Contractions Of The Facial Musculature Secondary To MS Lesions affecting the facial nerve.

6. Facial Weakness and Paralysis may also be evident in MS patients.

7. Dysarthria that results in a scanning speech pattern is often seen in patients with MS.

8. Temporomandibular Disorder And Headache.

- Evaluate cranial nerve function, if cranial nerve abnormalities are detected, the individual should be referred to a neurologist for further evaluation.
- Dentist should Avoid Elective Dental Treatment in ms patients during acute exacerbations of the disease due to Limited Mobility And Possible Airway Compromise.
- Patients with significant dysfunction may Require Dental Treatment In An Operating Room Under General Anesthesia due to the Inability To Tolerate Treatment in an outpatient setting.
- In addition, Electric Tooth Brushes And Oral Hygiene Products With Larger Handles may be necessary for completing oral hygiene in Patients With Significant Motor Impairment.
- The Dentist should be Aware of possible Interactions of these Medications with those commonly used and prescribed in dentistry, as well as Oral And Systemic Side effects of these agents.

## Alzheimer's disease (ad)

### Dementia

is defined as an Acquired Deterioration in cognitive abilities that impairs the successful performance of activities of daily living.

➤ Memory is the most common cognitive ability lost with dementia;

➤ Other Mental Faculties Affected Include

- Problem- Solving Skills,
- Judgment,
- Visuospatial Ability,
- Language.

The genetic basis of ad has been studied extensively, and specific genetic mutations have been implicated in both the

✓ **Familial**

✓ **Sporadic Forms Of The Disease.**

**Familial AD is an Autosomal Dominant Disorder with onset typically prior to age 65year**

### Clinical manifestations

AD is a slowly progressive disorder represented by a continuum recognizes three stages of AD:

- ❖ Preclinical AD occurs before changes in cognition, and everyday activities are observed and primarily used for research purposes.
- ❖ Cognitive Impairment (CI) due to ad is characterized by mild changes in memory and other cognitive abilities that are noticeable to patients and families but are not sufficient to interfere with day to-day activities.
- ❖ Dementia Due To AD is characterized by changes in two or more aspects of cognition and behavior that interfere with the ability to function in everyday life.

The initial signs of AD involve Retrograde Amnesia from progressive declines in episodic memory. This may initially go unrecognized or be viewed;

however, as the disease progresses, memory loss begins to affect performance of daily activities, including

- **Following Instructions,**
- **Driving,**
- **Normal Decision Making.**

As AD progresses, the individual is often

- Unable To Work,
- Gets Confused
- And Lost Easily,
- And May Require Daily Supervision.
- Language Impairment,
- Loss Of Abstract Reasoning And Skills.

Advanced AD is characterized by

- ✓ Loss Of Cognitive Abilities,
- ✓ Agitation,
- ✓ Delusions,
- ✓ And Psychotic Behavior.
- ✓ Patients may develop muscle rigidity associated with gait disturbances

End-stage AD, patients often become

- ❑ Rigid,
- ❑ Mute,
- ❑ Incontinent,
- ❑ And Bedridden.

Help is needed for basic functions, such as

Eating And Dressing, And Patients May Experience Generalized Seizure Activity.

Death often results from Malnutrition, Heart Disease, Pulmonary Emboli, Or Secondary Infections.

## Diagnosis

- Diagnosis of preclinical AD primarily utilizes biomarker assessment, including markers of
    - ❑ **A $\beta$  Protein Deposition In The Brain,**
    - ❑ **Markers Of Downstream Neuro Degeneration (Elevated CSF Tau Protein And Brain Atrophy On MRI.)**
  - Clinical diagnosis of AD is based on an individual's medical history together with the clinical and neurologic examination findings.
  - Criteria include a history of progressive deterioration in cognitive ability in the absence of other known neurologic or medical problems.
- Possible AD refers to those who meet the criteria for dementia but have another illness that may contribute to the neurologic status, such as:- **Hypothyroidism Or Cerebrovascular Disease, Vitamin Deficiency, Depression, Delirium, Side Effects Of Drugs And Toxicity And Excessive Use Of Alcohol**
- Diagnostic analysis of CSF may show a **slight increase in tau protein and a lower concentration of A $\beta$  peptide** compared with healthy individuals or those with other dementias.
  - **Electroencephalographic (EEG) studies** typically demonstrate generalized slowing without focal features. Neuroimaging is important in evaluating suspected AD to exclude alternative causes of dementia, such as cerebrovascular disease, subdural hematoma, or brain tumor.
  - **MRI and CT** typically reveal dilatation of the lateral ventricles and widening of the cortical sulci, particularly in the temporal regions.
  - **Volumetric MRI** uniformly demonstrates shrinkage in vulnerable brain regions (brain atrophy).

## Treatment

There is no cure for AD, and therapy is aimed at slowing the progression of the disease.

- ❑ **Cholinesterase Inhibitors** are approved to treat **Mild To Moderate Cases Of AD** and are considered the **standard of care.**
- ❑ **Memantine, A Noncompetitive N-methyl-d-aspartate Receptor Antagonist** believed to protect neurons from glutamate-mediated excitotoxicity, is used for treatment of **Moderate To Severe AD.**

Studies have demonstrated greater **Cognitive And Functional Improvement** when **Memantine Is Used In Conjunction With Cholinesterase Inhibitors** compared to monotherapy.

- ❑ **Antidepressants, Such As Selective Serotonin Reuptake Inhibitors,** are commonly used to treat depression, which is often seen in the mild to moderate stages of AD. Antipsychotic agents are used for those patients who display aggressive behavior and psychosis, especially in the later stages of the disease.
- **Other Agents that have been reported to be of clinical value in the treatment of ad include Antioxidants, Such As A-tocopherol (Vitamin E), Cholesterol-lowering Drugs, Anti-Inflammatory, And Herbal**



## **Oral Health Considerations**

Oral and dental health is a major issue in patients with AD because significant deterioration in oral health status is commonly observed with advancing disease.

### **Patients with AD appear to be at higher risk for developing**

- ❑ Coronal And Root Caries,
- ❑ Periodontal Infections,
- ❑ Temporomandibular Joint Abnormalities,
- ❑ Orofacial Pain compared to healthy subjects.

### **Patients with AD should be placed on an**

#### **Aggressive Preventive Dentistry Program, including an**

- Oral Examination,
- Oral Hygiene Education,
- Prosthesis Adjustment,
- Three-month Recall.

Therefore recommended to complete restoration of oral health-care function in the earliest stages of AD because the **patient's ability to cooperate diminishes as cognitive function declines.**

Time-consuming and complex dental treatment should be avoided in persons with severe AD.

- ✓ The dentist should have information about the **adverse effect of the medications** used to treat AD which can cause a variety of **orofacial reactions** and potentially interact with drugs commonly used in dentistry.
- ✓ **Cholinesterase inhibitors** may cause **sialorrhea**, whereas **antidepressants and antipsychotics** are often associated with **xerostomia**.
- ✓ In addition, **dysgeusia and stomatitis** have been reported with use of **antipsychotic agents**.
- ✓ **Antimicrobials**, such as **clarithromycin, erythromycin, and ketoconazole**, may significantly **impair the metabolism of galantamine**(acetylcholinesterase inhibitors), resulting in **central or peripheral cholinergic effects**.
- ✓ **Anticholinesterases** may **increase the possibility of gastrointestinal irritation and bleeding** when used concomitantly with **NSAIDs**.
- ✓ **Local anesthetics with adrenergic vasoconstrictors** should be used with caution in AD patients taking **tricyclic antidepressants** due to potential risk of cardiovascular effects, such as  
hypertensive events  
or dysrhythmias.

## Parkinsonism

A neurodegenerative disorder characterized by:

- 1- Rigidity
- 2- Tremors,
- 3- Brady Kinesis(slowness of movement & speed)
- 4- Impaired Postural Reflexes (Postural Instability).

The most common form of parkinsonism is Parkinson's Disease (Paralysis Agitans), but parkinsonism is seen in a variety of disorders such as

- ❖ Postencephalitic Parkinsonism,
- ❖ And Post-traumatic Parkinsonism Following Closed Head Injury.

Many of the signs of Parkinson's disease are found in the head and neck.

- The Typical —Mask Like Facial Appearance With Infrequent Blinking and Lack of Expression is caused by brady kinesis.
- Muscle Rigidity also causes Difficulty In Swallowing, resulting in Saliva Drooling.
- Speech affected because of the lack of muscle control,
- Mandibular Tremor Results In Masticatory Difficulties, especially in those with removable dental appliances.
- Abnormalities in oral behavior, such as
  - Purposeless Chewing, Grinding, Sucking Movements.



## Treatment

Drug treatment is often not required early in the course of Parkinsonism.

1-Patients with mild symptoms but no disability may be helped by Amantadine.

This drug improves all of the clinical features of Parkinsonism.

2-Anticholinergics are more helpful in alleviating tremor and rigidity than in alleviating bradykinesia, but these drugs have many side effects.

3-levodopa, A Dopamine Precursor that can cross the blood-brain barrier, improves all the major features of Parkinsonism.

## Myasthenia gravis

Disease characterized by progressive muscular weakness on exertion, secondary to a disorder at the neuromuscular junction.

Autoimmune disease ,autoantibodies combine with and may destroy the acetylcholine receptor sites at the neuromuscular junction, preventing the transmission of nerve impulses to the muscle .

The initial signs of this disease commonly occur in areas innervated by the cranial nerves (frequently, the eye muscles).

### Patients present with

1. Ptosis ,Diplopia
2. Difficulty In Chewing Or Swallowing
3. Respiratory Difficulties
4. Limb Weakness
5. Some Combination Of These Problems.

### Oral and facial signs

1. The facial muscles of expression are involved
2. Tongue Edema making eating difficult for patients
3. Difficulty In Chewing; these patients will be unable to finish chewing a bolus of food because of the easy fatigability of the muscles

## Treatment Myasthenia gravis

1. Anticholinesterase drugs such as Neostigmine And Pyridostigmine Bromide
2. Thymectomy
3. Long-term Cortico-steroids and Immunosuppressive drugs are necessary.

### Dental management Myasthenia gravis

1-A respiratory crisis may develop from the disease itself or from over medication.

2- Dental treatment should be performed in a hospital where endotracheal intubation

3-The airway must be kept clear because aspiration may occur in patients whose swallowing muscles are involved.

4- Adequate suction and the use of a rubber dam

5- The dentist should Avoid Prescribing Drugs that may Affect The Neuromuscular Junction, such as:

- ❖ Narcotics,
- ❖ Tranquilizers
- ❖ Barbiturates.
- ❖ Certain antibiotics, including
  - Tetracycline,
  - Streptomycin,
  - Sulfonamides,
  - Clindamycin, may reduce neuromuscular activity and should be avoided.

## **Seizure Disorders & Epilepsy**

A seizure is a paroxysmal event due to abnormal, excessive, hypersynchronous discharges from neuronal aggregates in the CNS.

The term epilepsy describes a group of neurologic disorders characterized by recurrent seizure activity.

1- Focal,

2- Generalized

3- Unknown Seizures

are currently the three major categories of seizure activity used in clinical practice.

### **1. The focal seizure category (Partial Seizures)**

Includes partial seizures; this type of seizure activity originates within networks limited to one hemisphere and clinical manifestations of these seizures depend on the site of origin. Simple partial seizures reflect neuronal discharge from a discrete cortical locus, such as the motor cortex of the frontal lobe, or in subcortical structures, and generally not associated with impaired consciousness.

The dentist have to know that simple partial seizures consist of

**Clonic Activity**, which are rapid jerks that also can be accompanied by somato-sensory phenomena, visual changes/distortions, and auditory, olfactory, and gustatory.

### **2. Generalized Seizures**

arise from both cerebral hemispheres simultaneously and have distinctive clinical features that facilitate diagnosis.

The underlying pathophysiology of generalized seizures is attributed to **abnormal neuronal excitability**.

**a. Absence seizures (petit mal)** are a type of generalized seizure that is characterized by sudden, brief lapses of consciousness without loss of body tone and may be attributed to abnormal oscillatory rhythms generated during sleep by circuits connecting the thalamus and cortex.

**b. Tonic-clonic (grand mal) seizures** are generalized seizures that present with dramatic clinical features, most notably, tonic contracture and uncoordinated clonic muscular movements.

Other types of generalized seizures include atypical absence, atonic, and myoclonic seizures.

### **3- Unknown Seizures.**

Those seizures that cannot be classified as either Focal Or Generalized are termed **Unknown Seizures.**

### Etiology usually varies according to patient's age.

The most common seizures arising in late **Infancy And Early Childhood** are **febrile seizures** without evidence of associated CNS infection; these usually occur between 3 months and 5 years of age and have a peak incidence between 18 and 24 months.

**Isolated, non recurrent, generalized seizures Among Adults** are caused by multiple etiologies, including: **Metabolic Disturbances, Toxins, Drug Effects, Hypotension, Hypoglycemia, Hyponatremia, Uremia, Hepatic Encephalopathy, Drug Overdoses, Drug Withdrawal.**

**Cerebrovascular disease** may account for approximately **50% of new cases of epilepsy in patients older than 65 years.**

### Other etiologies for epilepsy include

- **Degenerative CNS Disease,**
- **Developmental Disabilities,**
- **And Familial/Genetic Factors.**

Epilepsy occurs more frequently in individuals who have neurologic-based disabilities, such as

- **Cerebral Palsy**
- **Autism.**

### Epilepsy

Epilepsy is a condition characterized by **abnormal, recurrent, and excessive neuronal discharges** precipitated by many different disturbances within the central nervous system.

These aberrant discharges may cause episodes of **sensory and motor abnormalities** as well as **loss of consciousness.**

### Common causes of epilepsy:

1. **Infants** are much more likely to suffer from epilepsy after **complications at birth, such as anoxia (lack of oxygen) traumatic brain injury during delivery, intracranial injury, metabolic disorders, abnormal brain development and congenital malformations.**
1. Predominant causes **in children and adolescents** include **head trauma and acute or febrile infections, fever, brain tumors, genetic disorders and brain scarring.**
2. **Young adults** with **alcohol or drug abuse** commonly suffer from generalized seizures after periods of severe abuse.
3. **Epilepsy in older adults** occurs as a complication of any of the previously mentioned causes but is more often associated with **cerebrovascular diseases** such as **stroke, brain scarring, abnormal brain development, head trauma and brain tumors.**

## □ Generalized seizures

The majority of generalized seizures are called either:-

1. -Tonic-clonic seizures (grand mal).(most common type 90% of epileptics experience it alone or in combination with another type of seizure)
2. -Absence (petit mal)seizures

Tonic-clonic seizures (A grand mal seizure) :characteristically begins with an Aura.

The aura may be experienced as

(Epigastric Discomfort, As An Emotion, Or As A Hallucination Of Hearing, Vision, Or Smell).

The aura is followed Seconds To Minutes later by ( Unconsciousness, Or A Cry)

Then Tonic Muscle Spasms; This Rigid Phase Lasts About (30 Seconds).

Because of the spasm of the respiratory muscles,

The patient does Not Breathe And Becomes Cyanotic during this period.

The Tonic Phase Is Followed By A

Clonic Phase Composed Of (Convulsive Jerky Movements, Incontinence, And Tongue Biting).

## □ Absence seizures (petit mal):

Is the second most common type of seizure and it occurs Without An Aura and With Few Or No Clonic Or Tonic Movements.

Absence seizures present almost exclusively in children and frequently disappear during the second decade of life.

## Diagnosis:

1. History & physical examination are critical because the diagnosis may based on clinical findings.
2. A complete neurological examination (testing of cranial nerves)
3. Blood studies: complete blood count, Mg, calcium , glucose to identify metabolic cause
4. Toxins screen: to identify seizure due to drugs,
5. Lumber puncture to exclude any infectious cause
6. Brain imaging: underlying CNS structural abnormalities or pathology MRI and CT
7. EEG (to classify the seizure & to determine the type of anticonvulsant)

## Treatment of Epilepsy .

all of the below medication have adverse effect on the dental treatment

### Antiepileptic drugs (AEDs)

#### > Phenytoin:

Long Half Life, Less Frequently Cause Gingival Over Growth, Hirsutism, Coarsening Of Facial Features

#### > Carbamazepine: Hepatotoxicity, Leukopenia, Aplastic Anemia

#### > Lamotrigine: Skin Rash

#### > Valproic acid: Treatment of General Tonic clonic can cause Bone Marrow Suppression & Hepatotoxicity

#### > Additional Drugs As Topiramate, Gabapentin & Oxcarbazepine



**Discontinuation of pharmacologic therapy is considered when seizure control has been achieved.**

**The following patient characteristics yield the greatest chance of remaining seizure free after discontinuation of drug therapy:**

- (1) Complete medical control of seizures for one to five years;
- (2) Single seizure type;
- (3) normal neurologic examination, including intelligence ;and
- (4) a normal EEG.

Many patients are often withdrawn successfully from medication after an interval of two to four years without seizures who meet the above criteria and who clearly understand the risks and benefits.

**Surgical Procedures:** limited removal of hippocampus & amygdala, temporal lobectomy or hemispherectomy

**Vagus Nerve Stimulation:** placement of an electrode on the left vagal nerve leading to wide spread activation of cortical & sub cortical pathways

**Deep Brain Stimulation (DBS)** and responsive neurostimulation systems are also currently used for treatment of refractory epilepsy.

**Gene Therapy** is currently being investigated as an alternative treatment modality for epilepsy refractory to standard therapies.

### **Oral health consideration**

- Uncontrolled Patients should be referred to a hospital
- Patient with implanted vagus nerve stimulator do not require antibiotic prophylaxis
- Dentist must avoid any triggers of the patient seizures activity
- Placement of fixed prosthesis is recommended rather than removable prosthesis.
- Patient taking the medication mentioned requires laboratory evaluation prior to dental treatment
- Aspirin& NSAD should be avoided in patient taking valproic acid
- Gingival over growth intraoral lesion & lips enlargement
- Xerostomia:

Reduced salivary flow may result from the use of AEDs, may observe increased dental caries and oral candidiasis in patients using these agents.

- Topical fluoride should be considered for patients with seizure disorders who are at increased risk of developing dental caries,
- Antifungal agents should be prescribed if oral candidiasis develops.
- Additional oral findings in patients taking AEDs may include stomatitis ,glossitis and oral ulceration .

## Neuromuscular disorders

**Definition.** Are diseases that affect both nerve and muscle tissue.

Neuromuscular disorders represent a spectrum of nerve-related diseases and conditions that affect the body's voluntary muscles.

Causes weakening of muscles in the body because of interrupted communication between the nervous system and the muscles it controls.

Typically, these diseases can be managed to improve quality and length of life, but are incurable.

### Symptoms of muscle disease may include

**Muscular Weakness, Rigidity, Loss Of Muscular Control, Numbness, Tingling, Twitching, Spasms, Muscle Pain** And Certain Types Of Limb Pain

### Classification of neuromuscular disorders:

- Cerebrovascular Disease
- Multiple Sclerosis
- Alzheimer's Disease
- Seizure Disorders
- Parkinson Disease
- Myasthenia Gravis

### Cerebrovascular disease:-

Cerebrovascular disease includes all disorders that cause damage to the blood vessels supplying the brain, leading to impaired cerebral circulation thereby producing neurologic damage.

Complete Stroke and cerebrovascular accident (CVA) is a sudden impairment in cerebral circulation resulting in death or a focal neurologic deficit lasting more than 24 hours, are terms used to describe an acute neurologic injury resulting from a severe interruption in the flow of blood to the brain.

Complete cessation of the flow may render an irreversible cerebral infarct within a period of 3 or 4 minutes.

### Neurologic events related to CVA include:

**Transient ischemic attack (TIA):-** defined as reversible, acute, short-duration, focal neurologic deficit (mini stroke) resulting from transient (reversible within 24 hours) and localized cerebral ischemia

**Reversible ischemic neurologic defect (RIND):-** defined as reversible, acute, focal neurologic deficit due to transient and localized cerebral ischemia but resulting in neurologic deficits that last more than 24 hours

## Symptoms of cerebrovascular disease

### **Clinical Manifestations**

The clinical manifestations of stroke vary depending on the size and location of the affected brain region.

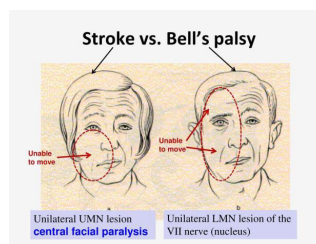
The most common signs and symptoms include

- Sensory And Motor Deficits,
- Changes (Paresis) In Extraocular Muscles And Eye Movements,
- Visual Defects,
- Sudden Headache,
- Altered Mental Status,
- Dizziness,
- Nausea,
- Seizures,
- Impaired Speech Or Hearing,
- And Neurocognitive Deficits Such As **Impaired Memory, Reasoning, And Concentration .**



### General symptoms following stroke:-

- **Variable Motor Paralysis**
- **Sensory Loss**
- **Visual Difficulties**
- **Speech Impairment**



## Types of cerebrovascular diseases according to the causes

Cerebrovascular Accident (CVA) or Stroke either due to:-

- Atherosclerosis**(85%) leading to cerebral ischemia and infarction result from ischemia due to atherosclerotic disease, thrombo embolic events, and occlusion of cerebral blood vessels, with neurologic deficits related to the loss of neural function in tissues distal to the event.
- Cerebral hemorrhage** (15%) result from hemorrhagic events leading to infarction, most often related to hypertension, trauma, substance abuse, or aneurysmal rupture.

**Three major types of ischemic stroke syndromes have been described:**

- 1- Small Vessel (Lacunar),
- 2- Large Vessel (Cerebral Infarction)
- 3- Brain Stem Stroke

**Lacunar strokes:-** result from obstruction of the small (<5 mm diameter) penetrating arterioles.

Age and uncontrolled hypertension are the greatest predisposing factors.

Symptoms usually include unilateral motor or sensory deficit without visual field changes or disturbances of consciousness or language. The prognosis for recovery from lacunar infarction is fair to good, with partial or complete resolution usually occurring over 4-6 weeks.

Thrombotic strokes may be preceded by one or more "mini-strokes," called transient ischemic attacks, or TIAs. ... Although usually mild and transient, the symptoms caused by a TIA are similar to those caused by a stroke. Another type of stroke that occurs in the small blood vessels in the brain is called a lacunar infarct

**Cerebral infarction (large vessel):-** is characterized by extensive downstream ischemia, usually due to a thromboembolic event along the distribution of the internal carotid artery and cerebral arteries. . Emboli often originate from the heart after acute myocardial infarction or in hyperdynamic conditions such as chronic atrial fibrillation. Hypertension is an important risk factor in the development of thrombosis, particularly at the carotid bifurcation, and treatment of severe hypertension is essential for the prevention of stroke. High level brain functions are affected, and the prognosis is poor.

**Brainstem infarction:** - results from occlusion of small or large vessels supplying the brainstem, resulting in variable deficits ranging from motor and sensory deficits to death when respiratory centers are affected.

### **Transient ischemic attack**

A transient ischemic attack (TIA) is a sudden but reversible neurologic deficit that lasts from a few minutes to 24 hours. Approximately 30% of individuals with a history of TIA experience a completed stroke within a 5-year period. An important cause of transient cerebral ischemia is embolization a source is readily apparent in the heart or a major extracranial artery to the head.

### **Clinical manifestations**

The symptoms of TIAs vary markedly among patients. Onset is abrupt and without warning, and recovery usually occurs rapidly, often within a few minutes.

During the attack, a wide variety of neurologic signs and symptoms can develop, depending on which site of the brain is affected by ischemia.

1. Repeated short periods of arm and hand weakness are associated with focal ischemia in the contralateral frontal lobe.
2. If the vertebrobasilar arterial system is involved, short episodes of dizziness, diplopia, dysarthria, facial paresthesia, and headache are common symptoms.

## **Treatment of TIA**

Treatment of TIAs should be initiated as soon as the diagnosis is established and should be directed towards the:-

1. Correction of the immediate pathologic problem (e.g., embolism).
2. Measures to control the primary underlying problem (e.g., hypertension or coagulopathy).
3. Anticoagulant therapy with either heparin or coumadin is often used.
4. Treatment with aspirin, however, significantly reduces the frequency of TIAs and the incidence of stroke in high-risk patients.

## **D.D. of CVA**

- Seizures,
- Hypoglycemia,
- Intracranial Tumors,
- Trauma,
- Infection,
- Encephalitis,
- Multiple Sclerosis (MS),
- And Prolonged Migranous Aura.

## **Diagnosis**

### **In addition to a**

- Thorough neurologic and cardiovascular examination,
- Anatomic and functional brain imaging is central to the diagnosis of stroke.

Time is of the essence for instituting treatment to manage acute stroke. Intracranial hemorrhage must be quickly excluded before life-saving thrombolytic therapy can begin.

- Although brain magnetic resonance imaging (MRI) provides greater anatomic detail and sensitivity for detection of early infarction,
- Non contrast computed tomography (CT) scan is the first line of imaging.
- Laboratory evaluation of the stroke patient includes **Complete Blood Count, Comprehensive Metabolic Panel, Urinalysis, Coagulation Profile, And, When Indicated, Blood Culture, Echocardiography, And Lumbar Puncture.**

However, in the hospital, a series of blood tests to learn the cause of the stroke symptoms:

- Complete Blood Count (CBC)
- Serum Electrolytes.
- Blood Clotting Tests.
- Heart Attack Tests.
- Thyroid Tests. .
- Blood Glucose. .
- Cholesterol Tests. .
- C-reactive Protein Test And Blood Protein Test

### **Treatment in general:-**

The outcome of stroke and related TIAs is significantly affected by the timeliness of treatment. Early intervention is critical to prevention, treatment, and recovery.

TIAs and RIND are treated by reduction in hypertension

**(lifestyle changes such as)**

**Diet,**

**Exercise,**

**Smoking Cessation,**

**And Stress Reduction;**

**Medical Therapy For Hypertension;**

**And Anticoagulant Or Antiplatelet Medications).**

Management of acute stroke includes medical therapy to reduce bleeding or thromboembolic occlusion, medical therapy to reduce brain edema and neurotoxicity/nerve injury, and surgical interventions (revascularization, hemorrhage control).

Once intracranial hemorrhage has been excluded as the source of acute cerebral ischemia, thrombolysis with intravenous tissue plasminogen activator (t-PA) can improve reperfusion, minimize infarction, and reduce disability.

### **After a completed stroke, treatment focuses on:**

- The prevention of further neurological damage, through the reduction of underlying risk factors
- Rehabilitation procedures, including **speech and physical therapy.**
- An intracranial hemorrhage should also be treated as a medical emergency of airway maintenance and requires the transfer of the patient to an **intensive care unit with close monitoring.**
- The surgical treatment of a hemorrhaging aneurysm consists of closing off the blood vessels that supply the area and removing the abnormality.

### **Oral Health Considerations**

- Following stroke, patients may experience several oral problems, including masticatory and facial muscle paralysis, impaired or lost touch and taste sensation, diminished protective gag reflex, and dysphagia. These problems can lead to impairment of food intake, poor nutrition, and weight loss due to diminished taste satisfaction, chewing capacity, and swallowing; choking; and gagging.
- Diminished motor function of masticatory and facial muscles may also reduce food clearance from the mouth and teeth with the presence of diminished dexterity of the arms or hands may adversely affect oral hygiene and increase the risk for caries and periodontal disease.
- The dentist should know that the risk increases of second stroke, during the first 90 days. Therefore optimal medical monitoring for the patients is necessary especially



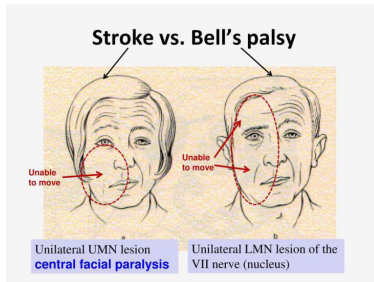
- in invasive dental treatment, with appropriate consideration for stress reduction, medication interactions and adverse effects, neurologic deficit management, also control of underlying cardiovascular/ cerebrovascular risk factors.
- 
- Use of antiplatelet and anticoagulant medications is common in patients with a history of stroke, TIA, and RIND. This includes oral aspirin; oral antiplatelet drugs such as subcutaneous low-molecular- weight heparin, and, less commonly, warfarin. These medications taken in therapeutic dosages, and for warfarin with an international normalized ratio  $\leq 3.5$ , rarely require dose modification before routine dental and minor oral surgical treatment.
- The dentist should know that the concomitant use of non-steroidal anti-inflammatory drugs (NSAIDs) may increase the risk for bleeding, and their long-term use may reduce the protective effect of aspirin.
- Stress reduction and confidence building for the patient during dental visits are important behavioral goals to make the patient comfortable and minimize anxiety- related elevation in blood pressure.
- Pre- or perioperative inhalation- N<sub>2</sub>O-O<sub>2</sub> or oral anxiolytic medication can aid in reducing treatment-related stress and anxiety.
- Use of epinephrine-containing local anesthetics is not contraindicated, but they should be used judiciously and follow guidelines recommended for patients with cardiovascular disease; epinephrine-containing retraction cord should not be used. and blood pressure should be monitored at every visit

### **Important points of Oral Health Considerations:-**

1. The medical management of stroke patients is often depend on anticoagulant therapy, the patient may have a predisposition to excessive bleeding. Therefore obtain current coagulation values (PT, INR ,APTT, bleeding time ) is necessary for the dentist .
2. Xerostomia is a common side effect of the medications used in the management of cerebrovascular disease. Patients can then be susceptible to a higher caries rate.
3. Stroke patients have physical disabilities, which can affect the orofacial area.  
 , weakness in the muscles of the orofacial area may have poor control of oral secretions, a reduced gag reflex, and changes in their ability to masticate, leading to poor nutrition.
4. Patients with apraxia affecting the orofacial region may have impaired voluntary movements, such as protruding the tongue and expectorating during dental treatment
5. Careful history taking, checking of blood pressure prior to treatment, avoidance of lengthy appointments.

Patients taking warfarin or antiplatelet agents face an increased risk of bleeding due to dental procedures. But stopping these medications may put the patient at risk of a thrombotic event (e.g., DVT, stroke). Therefore, the risk of bleeding must be weighed against the risk and consequences of thrombosis

## Bell's palsy



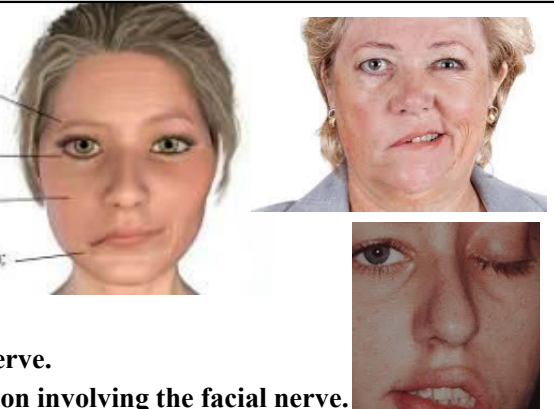
## Bell's Palsy

Inability to wrinkle brow

Drooping eyelid;  
inability to close eye

Inability to puff cheek;  
asymmetrical smile

Drooping corner of mouth;  
dry mouth



Bell's palsy is recognized as a unilateral paresis of the facial nerve.

The dysfunction has been attributed to an inflammatory reaction involving the facial nerve.

A relationship has been demonstrated between Bell's palsy and the isolation of herpes simplex virus 1 from nerve tissues.

Bell's palsy begins with slight pain around one ear, followed by an abrupt paralysis of the muscles on that side of the face.

The eye on the affected side stays open, the corner of the mouth drops, and drooling.

As a result of masseter weakness, food is retained in both the upper and lower buccal and labial folds.

The facial expression changes remarkably, and the creases of the forehead are flattened.

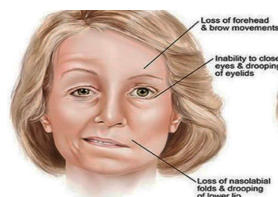
Due to impaired blinking, corneal ulcerations from foreign bodies can occur.

## Causes of Bell's palsy

Although the exact reason Bell's palsy occurs isn't clear, it's often linked to exposure to a viral infection.

Viruses that have been linked to Bell's palsy include the virus that causes:

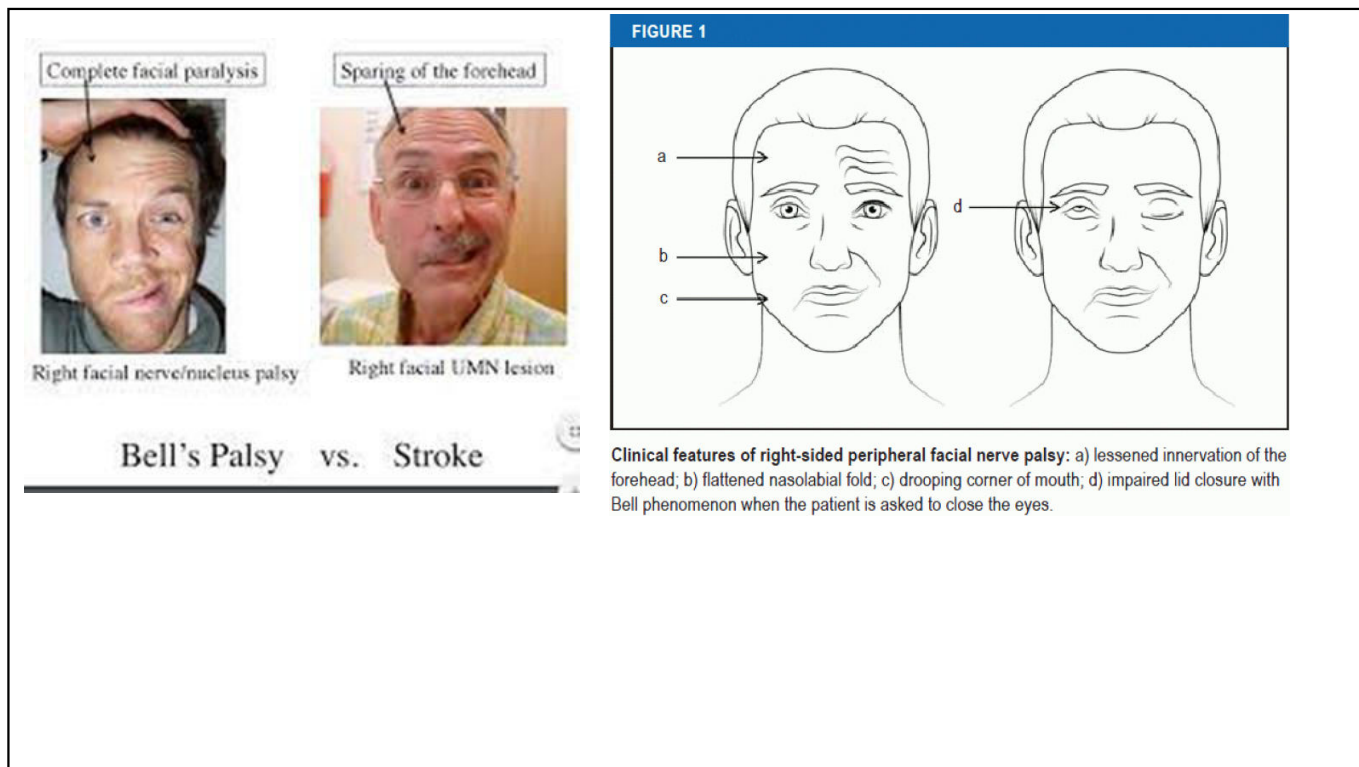
- Cold sores and genital herpes (herpes simplex)
- Chickenpox and shingles (herpes zoster)
- Mononucleosis (Epstein-Barr)
- Cytomegalovirus infections
- Respiratory illnesses (adenovirus)
- German measles (rubella)
- Mumps (mumps virus)
- Flu (influenza B)



## Symptoms of Bell's palsy

Signs and symptoms of Bell's palsy come on suddenly and may include:

1. Rapid onset of mild weakness to total paralysis on one side of face — occurring within hours to days
2. Facial droop and difficulty making facial expressions, such as closing eye or smiling
3. Drooling
4. Pain around the jaw or in or behind ear on the affected side
5. Increased sensitivity to sound on the affected side
6. Headache
7. A decrease in ability to taste
8. Changes in the amount of tears and saliva
9. In rare cases, Bell's palsy can affect the nerves on both sides of face



## Diagnosis .

There's no specific test for Bell's palsy.

Look at face and ask to move facial muscles by closing eyes, lifting brow, showing teeth and frowning, among other movements.

Other conditions — such as a

- Stroke,
- Infections,
- Lyme Disease
- And Tumors

can also cause facial muscle weakness, mimicking Bell's palsy,

may recommend other tests, including

- ❖ **Electromyography (EMG).** This test can confirm the presence of nerve damage and determine its severity. An EMG measures the electrical activity of a muscle in response to stimulation and the nature and speed of the conduction of electrical impulses along a nerve.
- ❖ **Imaging scans.**
  - ❑ **Magnetic Resonance Imaging (MRI)**
  - ❑ **Or Computerized Tomography (CT)** may be needed on occasion to rule out other possible sources of pressure on the facial nerve, such as a tumor or skull fracture

## **Treatment of Bell's palsy**

Commonly used medications to treat Bell's palsy include:

➤ **Corticosteroids**, such as prednisone, are powerful anti-inflammatory agents. If they can reduce the swelling of the facial nerve, it will fit more comfortably within the bony corridor that surrounds it.

Corticosteroids may work best if they're started within several days of when symptoms started.

➤ **Antiviral drugs**. The role of antivirals remains unsettled. Antivirals alone have shown no benefit compared with placebo. Antivirals added to steroids .However, despite this, **valacyclovir (Valtrex)** is sometimes given in combination with prednisone in people with severe facial palsy.

➤ **Physical therapy**

Paralyzed muscles can shrink and shorten, causing permanent contractures. A physical therapy by massage and exercise of facial muscles to help prevent this from occurring.

➤ **Surgery**

In the past, decompression surgery was used to relieve the pressure on the facial nerve by opening the bony passage that the nerve passes through. Today, decompression surgery isn't recommended. Facial nerve injury and permanent hearing loss are possible risks associated with this surgery.

## **Cavernous Sinus Thrombosis**

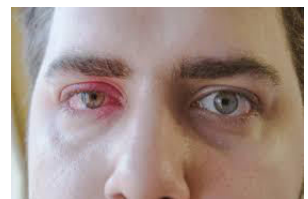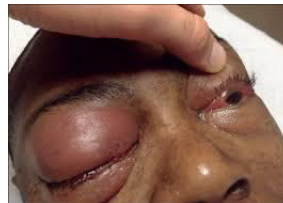**Cavernous Sinus Thrombosis**, Usually secondary to dental, nasal, or ocular infections, is a rare but severe complication because of its possible fatal outcome.

Infections of the maxillary dentition may spread to the cavernous sinus through openings in the cranial bones or through emissary veins connecting the extra- and intra cranial systems.

Venous propagation begins with the facial vein and proceeds through the ophthalmic vein, which is an affluent of the cavernous sinus.

### **Signs and symptoms of cavernous sinus thrombosis**

- Severe headache often accompanied by tearing
- Swelling, redness, or irritation around one or both eyes
- Drooping eyelids and inability to move the eye
- High fever
- Pain or numbness around the face or eyes
- Fatigue
- Vision loss or double vision
- Seizures
- Altered mental status that can range from confusion to coma
- seizures are rare.



In most cases, patients experience rapid swelling of the face and eyelids.

**The classic neurologic signs of acute cavernous sinus thrombosis are:-**

- Exophthalmos,
- Periorbital Edema,
- Retinal Vein Thrombosis,
- Involvement Of The Ophthalmic Division Of The Trigeminal Nerve , Trochlear And Abducent Nerves, leading to Ptosis, Dilated Pupils, And Lack Of Corneal Reflexes.

Cavernous sinus thrombosis is more common in people who take certain medications such as oral contraceptives or who have underlying health conditions such as uncontrolled diabetes or cancer that may increase their risk for blood clots

### **Treatment of cavernous sinus thrombosis:**

Treatment consists of immediate antibiotic therapy and the removal of the source of infection whenever possible. Staphylococcus aureus is the most common pathogen, identified in approximately 70% of cases and is the pathogen implicated in nearly all cases of facial infections and sphenoid sinusitis. Streptococci are cultured less commonly. Anaerobes are found occasionally, especially with sinus, dental, or tonsillar infections. Rarely, fungal infections from Aspergillus fumigatus or mucormycosis have been implicated.

**Therefore, for most etiologies, empiric therapy should include:**

- Vancomycin used until the actual culture results are available, plus
- A third-generation cephalosporin, such as ceftriaxone.
- In patients with documented true allergy to penicillin, a fluoroquinolone should be used instead.
- Intravenous metronidazole should be added if dental or sinus infection is suspected.
- Antifungal therapy has been advocated only in cases of biopsy- confirmed invasive fungal infection.

However, in at-risk patients, antifungal treatment should be considered by the dentist as fungi may cause devastating neurological complications beyond cerebral venous thrombosis.

High doses of intravenous antibiotics are required because thrombus may limit penetration of antibiotics. Bacteria, sequestered within the thrombus, may not be killed until the Dural sinuses have started to recanalize.

Antibiotics also need to be administered over an extended period, for at least 2 weeks beyond the time of clinical resolution. This aims to insure complete sterilization and prevent relapses.

The dentist have to take into consideration that concurrent supportive therapy is necessary alongside antibiotic treatment, and includes resuscitation, oxygen support, and local eye care.

## Allergic manifestation of the oral cavity

### Immunity:

Is the ability of an organism to resist infections.

The immune system is a complex network of Cells And Proteins that defends the body Against Infection.

The immune system keeps a record of every germ (microbe) it has ever defeated so it can recognize and destroy the microbe quickly if it enters the body again.

Abnormalities of the immune system can lead to

- > Allergic diseases.
- > Immuno-deficiencies.
- > Autoimmune disorders.

It is divided into :-

### A- Species (innate) immunity.

The innate immune system includes:

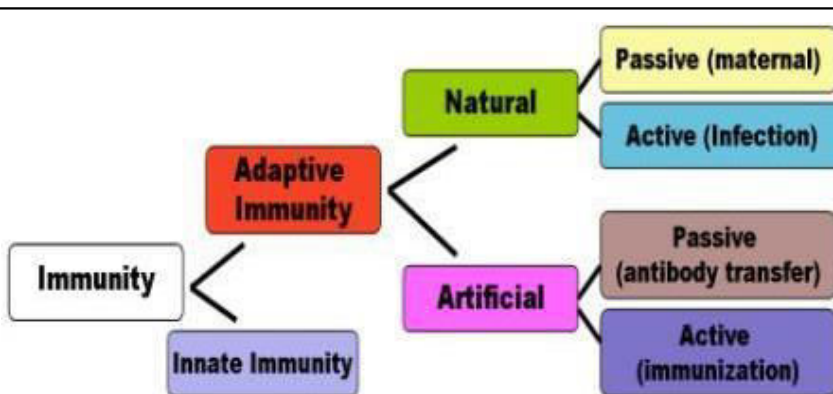
Physical Barriers, such as skin, the gastrointestinal tract, the respiratory tract, the nasopharynx, cilia, eyelashes and other body hair.

Defense Mechanisms, such as secretions, mucous, bile, gastric acid, saliva, tears, and sweat.

General Immune Responses.

### B – Adaptive (acquired) immunity

Antibodies development to destroy Antigen.



Bacteria and virus (Ag) are soluble proteins introduced into the host cell and stimulate reticuloendothelial system (spleen, lymph nodes, bone marrow) to produce Ab

### Antibodies (Ab),

are altered serum globulin molecules when brought in contact with protein or microbes (i.e. Antigen) their production would be excited.

The Ag may be destroyed by : Each antibody has a unique binding site shape which locks onto the specific shape of the antigen. The antibodies destroy the antigen (pathogen) which is then engulfed and digested by macrophages sequence this could be occur by the following

Agglutination, Precipitation, Lyses, Neutralization, Production of phagocytosis.



### **Allergy:**

Immunologic reactions are detrimental to the tissue or physiology of the host.

Antibodies are immunoglobulins produced by plasma cells and of 5 types :

**IgA, IgD, IgE, IgG, IgM**

The Antibodies are located either in :

1- Circulation (in blood stream).

2- Fixed (to cells).

### **Immunoglobulins**

**IgA** can be found in areas containing mucus (e.g. in the saliva, gut, respiratory tract and in the urogenital tract) and prevents the colonization of mucosal areas by pathogens.

**IgD** functions mainly as an antigen receptor on B cells.

**IgE** binds to allergens and triggers histamine release from mast cells (the underlying mechanism of allergy) and also provides protection against helminths (worms).

**IgG** (in its four forms) provides the majority of antibody-based immunity against invading pathogens.

**IgM** is expressed on the surface of B cells and also in a secreted form with very high affinity for eliminating pathogens in the early stages of B cell mediated immunity (i.e. before there is sufficient IgG to do the job).

When the individual exposed to the same Antigen two things happen:

1. Antigen may be neutralized or destroyed in the blood stream, by circulating Antibodies (person is immune).
2. The circulating Antibodies are not enough to destroy Antigen, later reach the tissue cells where it reacts with fixed Antibodies.

### **The reaction leads either to:**

- \* Destroy the cell.
- \* Release of histamine (as Angioedema, Skin rash, Hay fever, Urticaria).
- \* Spasm of smooth muscles (Asthma)

### **Allergens**

Any substances may have come in contact with.

For example, if the patient have a rash on hands, the doctor may ask if latex gloves recently used.

A blood test and skin test can confirm or diagnose allergens

So we could simply have the following facts .

In sensitized person; **Allergic Reaction Of The Oral Tissues** could be due to:

**Systemic Intake (Drug Eruption, Stomatitis Medicamentosa)**

**Direct Contact (Contact Stomatitis, Stomatitis Venenata)**

**Materials used in dental practice that may stimulate allergic reactions are;**

- **Rubber or latex** (Gloves, Rubber Cups, Rubber Dams)
- **Formalin** (in Endodontic Therapy, Tooth Pastes)
- **Fillings** (Isopaste, Light Cure, Free Mercury Of Amalgam)
- **Impression materials** (Rubber Base, Silicon)
- **Lining materials**
- **Dentures** (Acrylics, Chrome-cobalt, Gold Alloys)
- **Other chemicals and materials** (heptane, phenol, procaine, and flavors in mouth washes...etc)

**Substances that stimulate the immune reactions are divided into:-**

- **Soluble proteins** (e.g. those in bacteria and viruses)  
The condition is called bacterial allergy as in tuberculin test.
- **Non bacterial substances** (fresh fruits & vegetables, fish, feather, hair, pollen, milk,
- **Animal products.** These include pet dander, dust mite waste, and cockroaches.
- **Drugs.** Penicillin and sulfa drugs are common triggers.
- **Foods.** Wheat, nuts, milk, shellfish, and egg allergies are common.
- **Insect stings.** These include bees, wasps, and mosquitoes.
- **Mold.** Airborne spores from mold can trigger a reaction.
- **Plants.** Pollens from grass, weeds, and trees, as well as resin from plants such as poison ivy and poison oak, are very common plant allergens.
- **Other allergens.** Latex, often found in latex gloves, and metals like nickel are also common allergens.

➤ **Clinical Findings of the oral tissue reactions to the allergens:**

- **1- Swellings** (e.g. Angioedema)
- **2- Ulcerative Lesions** (e.g. Allergic mucositis, Erythema Multiforme)
- **3-White lesions** (e.g. Lichenoid eruptions)
- **4-Red lesions** (e.g. Plasma cell gingivitis)

**Depending on the speed, allergy may be classified into :**

**1- Immediate (or anaphylactic ) reactions.** Occur in seconds up to 30 minutes.

**2- Accelerated reactions** Occur in 1 hr. to 72 hrs.

**3- Delayed reactions** Occur in days or weeks

**In sensitized person; allergic reaction of the oral tissues could be due to:**

**Systemic intake (Drug Eruption, Stomatitis Medicamentosa)**

**Direct contact (Contact Stomatitis, Stomatitis Venenata)**

**1. Anaphylaxis typically presents many different symptoms over minutes or hours with an average onset of 5 to 30 minutes. The most common areas affected include:**

**Skin Symptoms** typically include generalized **Hives, Itchiness, Flushing, or Swelling.**

**Respiratory symptoms** and signs that may be present include **shortness of breath, wheezes, or stridor.**

The wheezing is typically caused by spasms of the **bronchial** muscles while stridor is related to upper airway obstruction secondary to swelling. **Hoarseness, pain with swallowing, or a cough may also occur.**

**Gastrointestinal,** symptoms may include **crampy abdominal pain, diarrhea, and vomiting.**

There may be confusion, a loss of bladder control or pelvic pain similar to that of **uterine** cramps.

Dilation of blood vessels around the brain may cause **headaches.** A feeling of **anxiety**

**Heart and vasculature Coronary artery spasm** may occur with **Subsequent myocardial infarction, dysrhythmia,** or **cardiac arrest.** Those with underlying coronary disease are at greater risk of cardiac effects from anaphylaxis. The coronary spasm is related to the presence of histamine-releasing cells in the heart.

While **a fast heart rate** caused by low blood pressure is more common, a **Bezold–Jarisch reflex** has been described in 10% of cases where a **slow heart rate** is associated with **low blood pressure.**

The Bezold–Jarisch reflex–Jarisch reflex involves a variety of cardiovascular and neurological processes which cause **hypopnea** (excessively shallow breathing or an abnormally low **respiratory rate**)

**Hypotension** (abnormally low blood pressure) a drop of blood pressure or **shock** (either **distributive** or **cardiogenic**) may cause the feeling of lightheadedness or **loss of consciousness.** **Rarely** very low blood pressure may be the only sign of anaphylaxis, **Bradycardia** (abnormally low resting **heart rate**).

**Heart and vasculature Coronary artery spasm** may occur with a drop of blood pressure or **shock** (either **distributive** or **cardiogenic**) may cause the feeling of lightheadedness or **loss of consciousness.** **Rarely** very low blood pressure may be the only sign of anaphylaxis

Knowing the principles of dealing with this complication is very important for the dentist

**Epinephrine (1 mg/ml aqueous solution [1:1000 dilution]) is the first line treatment for anaphylaxis and should be administered immediately**

In adults, administer a 0.3 mg intramuscular dose using a premeasured or prefilled syringe, or an autoinjector, in the mid-outer thigh (through clothing if necessary)

**Adjunctive measures include**

- Airway Protection,**
- Antihistamines,**
- Steroids,**
- And Beta Agonists.**

Patients taking beta blockers may require additional measures.

## 2. Angioedema (Angioneurotic Oedema)

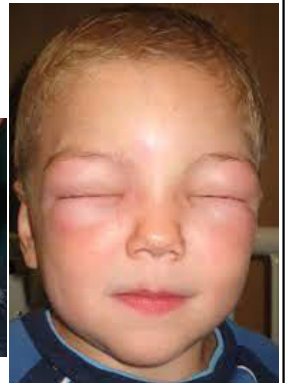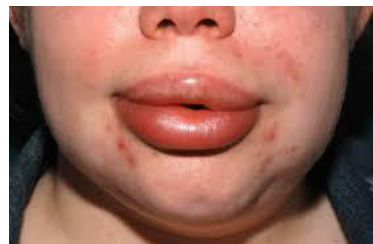- Well demarcated localized bilateral painless swelling (edema) which makes it different from periapical abscess of the anterior teeth.
- It involves the deeper layers of the skin including the subcutaneous tissue.
- The lips are the common site but may occur anywhere on skin or mucous membrane.
- Recurrent episodes of urticaria and/or oedema
- if less than 6 weeks duration are considered acute attacks existed beyond this period are designated chronic.

### Causes of the reaction:

- A significant cases are idiopathic
- Ingestion of food ,drug or contact with allergen
- A recurrent form is inherited as an autosomal dominant trait.

### There are 4 types of angioedema

- Acute Allergic Angioedema.
- None Allergic Drug Induced Angioedema.
- Idiopathic Angioedema.
- Hereditary Angioedema.



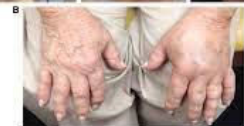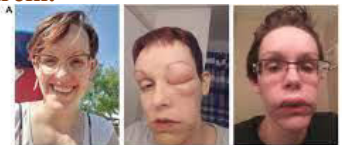
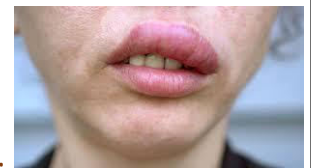### Drug induced angioedema

Is a known complication of the use of Angiotensin converting enzyme inhibitors(ACE) such as Captopril(capoten) and Angiotensin 11 antagonist such as Losartan & Valsartan.

### Hereditary angioedema

is life threatening condition that is not associated with allergens.

- It is a genetic with autosomal dominant pattern of inheritance.
- The underlying defect is a failure to produce adequate levels of C1 esterase inhibitor, which normally acts as inhibitor of the 1<sup>st</sup> component of complement and kallikrein.
- This inhibitor controls the degree of complement activation.
- Activation of kinin- like substances causes a sudden increased in capillary permeability.



### Management

- ❖ Avoidance Of The Allergen (Food, Pollen, Drug)
- ❖ Use Of Antihistamines, Cortisone And Adrenalin In Sever Form.

Hereditary type does not respond to antihistamines, corticosteroids, or epinephrine and in an emergency,

- ✓ The androgen ( Danazol) increases the plasma level of C1 esterase inhibitor.
- ✓ Fresh Frozen Blood Plasma should be given Intravenous.

### **3. Allergic stomatitis**

There are basically two types of hypersensitivity reactions involved in allergic stomatitis,

- Type I immediate hypersensitivity,
- Type IV delayed hypersensitivity.

The allergic stomatitis may present with clinical appearances that mimic classic

**Oral Vesiculobullous and Ulcerative lesions**

**Oral mucosal immuno-inflammatory disorder variably characterized clinically by**

- Erythematous Plaques
- Vesiculation,
- Ulceration,
- Hyperkeratosis
- Pain
- Burning Sensation And Itchiness

### **3.Lichenoid drug eruptions**

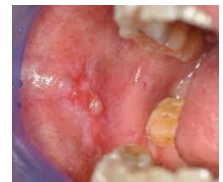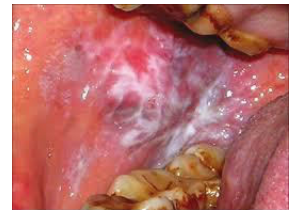Lichenoid drug eruption, also called drug-induced lichen planus, is an uncommon cutaneous adverse effect of several drugs, characterized by a symmetric eruption of flat-topped, erythematous or violaceous papules resembling lichen planus on the trunk and extremities

The incidence of oral lesions without skin eruptions is common.

The etiology is mostly due to drug intake

**Medications commonly reported to trigger a lichenoid drug eruption include:**

- Antihypertensives – ACE inhibitors, beta-blockers, nifedipine, methyldopa
- Diuretics – hydrochlorothiazide, frusemide, spironolactone
- [Non-steroidal anti-inflammatory drugs \(NSAIDs\)](#)
- Phenothiazine derivatives
- Anti-convulsants – carbamazepine, phenytoin
- Medicines to treat tuberculosis
- Antifungal medication – [ketoconazole](#)
- Chemotherapeutic agents – 5-fluorouracil, [imatinib](#)
- [Antimalarial](#) agents such as [hydroxychloroquine](#)
- [Sulfa drugs](#) including sulfonylurea hypoglycaemic agents, [dapson](#)e, mesalazine, [sulfasalazine](#)
- Metals – [gold salts](#)
- Others – allopurinol, iodides and radiocontrast media, interferon- $\alpha$ , omeprazole, penicillamine, [tetracycline](#)



**Other medications that have been reported in association with lichenoid drug eruptions include**

- Tumor necrosis factor antagonists such as [infliximab](#), [etanercept](#) and [adalimumab](#)
- Vaccines (especially those for [herpes zoster](#) and influenza).

**The clinical and the pathogenesis are identical to lichen planus.**

#### 4. Plasma cell gingivitis

It is a rare condition; the cause of which is still not fully understood and is characterized by **massive infiltration of plasma cells into the subepithelial tissue.**

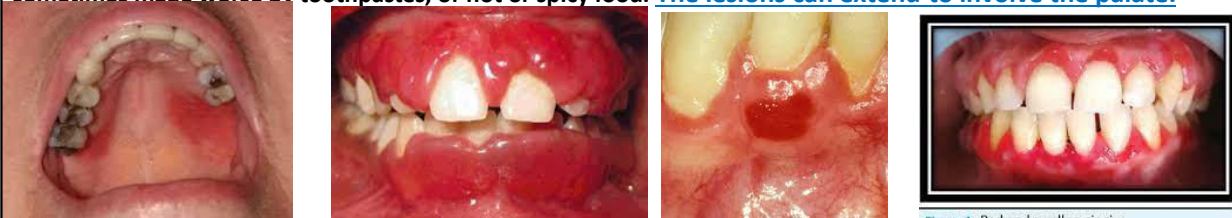**Clinical complication due to contact allergy characterized by Generalized Erythematous, Edematous Attached Gingiva usually accompanied by Inflammation Of The Lip And Tongue.**

**Plasma cell gingivitis** appears as **Mild Gingival Enlargement** and may extend from the Free Marginal Gingiva on to the Attached Gingiva. Sometimes it is blended with a **marginal, plaque induced gingivitis**, or it **does not involve the free marginal gingiva.** It may also be found as **a Solitude Red area within the Attached Gingiva.**

In some cases the healing of a plaque-induced gingivitis or a periodontitis resolves a plasma cell gingivitis situated a few mm from the earlier plaque-infected marginal gingiva. In case of one or few solitary areas of plasma cell gingivitis, no symptoms are reported from the patient. Most often solitary entities are therefore found by the dentist.

**The gums are Red, Friable, or sometimes Granular, and sometimes Bleed easily if traumatized and the Normal Stippling Is Lost.**

There is **not usually any loss of periodontal attachment.** In a few cases a **sore mouth** can develop, and if so pain is sometimes made worse by toothpastes, or hot or spicy food. **The lesions can extend to involve the palate.**



#### 5. Plasma cell cheilitis

appears as **well defined, infiltrated, dark red plaque** with a superficial **lacquer-like glazing.**

Plasma cell cheilitis usually involves the lower lip.

The lips appear dry, **atrophic** and fissured.

**Angular cheilitis** is sometimes present.

Where the condition involves the tongue, there is an **erythematous enlargement with furrows, crenation and loss of the normal dorsal tongue coating.**

#### Diagnosis

Histologically plasma cell gingivitis shows mainly **plasma cells.**  
The **differential diagnosis** is with acute **leukemia** and **multiple myeloma.**

Hence, blood tests are often involved in ruling out other condition

A **biopsy** is usually taken, and allergy testing may also be used.

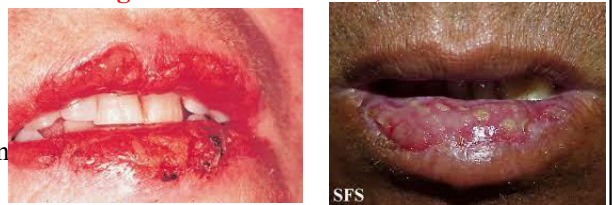The **histopathologic appearance** is characterized by diffuse, sub-epithelial **plasma cell** inflammatory infiltration into the **connective tissue.**

The **epithelium** shows **spongiosis.**

Some consider that **plasmocanthoma** (solitary plasma cell tumor) is part of the same spectrum of disease as plasma cell cheilitis

**Note .Plasma cell neoplasms** are diseases in which abnormal **plasma cells** or **myeloma cells** form **tumors** in the bones or soft tissues of the body. The **plasma cells** also make an antibody protein, called M protein, that is not needed by the body and does not help fight infection.

**NOTE .The disease should be distinguished from neoplastic plasma cell disease such as plasmacytoma, and multiple myeloma.**





## Pigmented Lesions of the Oral Mucosa

### Endogenous Pigmentation

#### ☐☐ Focal Melanocytic Pigmentation

1. Freckle/Ephelis
2. Oral/Labial Melanotic Macule
3. Oral Melanoacanthoma
4. Melanocytic Nevus
5. Malignant Melanoma

#### ☐☐ Multifocal/Diffuse Pigmentation

1. Physiologic Pigmentation
2. Drug-Induced Melanosis
3. Smoker's Melanosis
4. Post-inflammatory (Inflammatory) Hyperpigmentation
5. Melasma (Chloasma)

#### ☐☐ Melanosis Associated with Systemic or Genetic Disease

1. Hypoadrenocorticism (Adrenal Insufficiency or Addison's Disease)
2. Cushing's Syndrome/Cushing's Disease
3. Hyperthyroidism (Graves' Disease)
4. Primary Biliary Cirrhosis
5. Vitamin B12 (Cobalamin) Deficiency
6. Peutz-Jeghers Syndrome
7. Café au Lait Pigmentation
8. HIV/AIDS-Associated Melanosis

#### ☐☐ Idiopathic Pigmentation

1. Leukoplakia, Leukokeratosis

#### ☐☐ Treatment of Mucocutaneous Melanosis

#### ☐☐ Hemoglobin and Iron-Associated Pigmentation

1. Ecchymosis
2. Purpura/Petechiae
3. Hemochromatosis

### Exogenous Pigmentation

1. Amalgam Tattoo
2. Graphite Tattoos
3. Ornamental Tattoos
4. Medicinal Metal-Induced Pigmentation
5. Heavy Metal Pigmentation
6. Drug-Induced Pigmentation
7. Hairy Tongue

## Pigmented Lesions of the Oral Mucosa

- ✓ Although oral and perioral pigmentation may be **physiologic in nature**, particularly in **individuals with dark skin** complexion, in the course of disease, the oral mucosa and perioral tissues can assume a variety of discolorations, including **brown, blue, gray, and black**.
- ✓ **Such color changes are often attributed to the deposition, production, or increased accumulation of various endogenous or exogenous pigmented substances.**

However, although an area may appear pigmented, the discoloration may not be related to actual pigment but rather to the **deposition or accumulation of organic or inorganic substances, including various metals and drug metabolites.**

### **Hemoglobin, hemosiderin, and melanin**

represent the most common endogenous sources of mucosal color change. Sub mucosal collection of hemoglobin or hemosiderin, produced by extravasation and/or lysis of red blood cells, may impart a **red, blue, or brown transient appearance to the oral mucosa.**

- ✓ **Melanin**, which is synthesized by **melanocytes and nevus cells**, may appear **brown, blue**, or black, depending on the amount of melanin and its location within the tissue (superficial vs. deep).
  - ✓ **Exogenous pigmentations** are usually associated **with traumatic or iatrogenic events** that result in the deposition of **foreign material** directly into the mucosal tissues.
  - ✓ In some cases, the substances may be ingested, absorbed, and distributed hematogenously into connective tissues, particularly in areas subject to chronic inflammation, such as the gingiva.
- In other instances, these ingested substances can actually stimulate melanin production, thus precipitating the color change.
- ✓ **Chromogenic bacteria** can also produce oral pigmentation, usually resulting in discoloration of the dorsal tongue.
  - ✓ **Certain foods & drinks** can also result in exogenous pigmentation. However, in most cases, the discoloration can be easily reversed.

**The manifestation of oral pigmentation is quite variable**, ranging from a **solitary macule to large patches**.

The duration, location, number, distribution, size, and shape of the pigmented lesion(s) may also be of diagnostic importance.

**To Obtain An Accurate Diagnosis, Thorough**

- Social
  - Family
  - Medical
  - Dental Histories
- } Are Required
- Various Diagnostic Procedures

Colonoscopy  
Laboratory Tests, Including Biopsy, May Be Necessary.

Thus, an understanding of the various disorders and substances that can contribute to oral and perioral pigmentation is essential for the appropriate **evaluation, diagnosis, and management of the patient**.

**Lesions that are associated with mucosal discoloration but are vascular in origin, including Developmental, Hamartomatous, And Neoplastic Lesions**

**(Hemangioma, Lymphangioma, Angiosarcoma, Kaposi's Sarcoma),**

**it should be noted that these entities are frequently considered in the differential diagnosis of both macular and mass-forming pigmented lesions.**

## Endogenous Pigmentation

Melanin is found universally in nature. Melanin is the pigment derivative of tyrosine and is synthesized by melanocytes, which typically reside in the basal cell layer of the epithelium.

Melanin is synthesized within specialized structures known as melanosomes.

Melanin is actually composed of eumelanin, which is a brown-black pigment, and pheomelanin, which has a red-yellow color

The term Melanosis is frequently used to describe Diffuse Hyperpigmentation.

Overproduction of melanin may be caused by a variety of mechanisms, the most common of which is related to increased sun exposure.

Intraorally, hyperpigmentation is more commonly a consequence of

- **Physiologic**
- **Idiopathic Sources**
- **Neoplasia**
- **Medication**
- **Oral Contraceptive Use**
- **High serum concentrations of pituitary Adrenocorticotrophic Hormone (ACTH)**
- **Post-inflammatory Changes**
- **Genetic**
- **Autoimmune Disease.**

Therefore, **the presence or absence of systemic signs and symptoms**, including cutaneous hyperpigmentation, is of great importance to elucidate the cause of oral pigmentation.

Overproduction of melanin However, if the etiology of the pigmentation cannot be clinically ascertained, a tissue biopsy is warranted for definitive diagnosis.

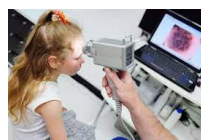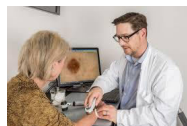
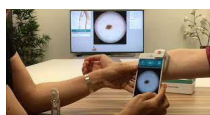
This is critical because malignant melanoma may present with a misleadingly benign clinical appearance.

In addition to Biopsy and Histologic Study, various Laboratory and Clinical Tests, including Diascopy, Radiography, and Blood Tests, may be necessary for definitive diagnosis of oral pigmentation.

Dermascopy, also known as epiluminescence microscopy, is another increasingly employed clinical test that can be useful in the diagnosis of melanocytic lesions.

Although, current instrumentation is designed primarily for the study of cutaneous pigmentation, several studies have described the use of dermascopy in the evaluation of labial and anterior lingual pigmentation.

Briefly, this noninvasive technique is performed through the use of a handheld surface microscope using incident light and oil immersion.



**More advanced method makes use of Binocular Stereo Microscopes** with or without the assistance of digital technology and imaging software.

This diagnostic technique has been shown to be effective in discriminating melanocytic from non melanocytic lesions and benign versus malignant melanocytic processes

## Focal Melanocytic Pigmentation Freckle/Ephelis

The cutaneous freckle, or ephelis, is a commonly occurring, asymptomatic, small (1–3 mm), well-circumscribed, **brown-colored macule** that is often seen on the sun-exposed regions of the **facial and perioral skin**.

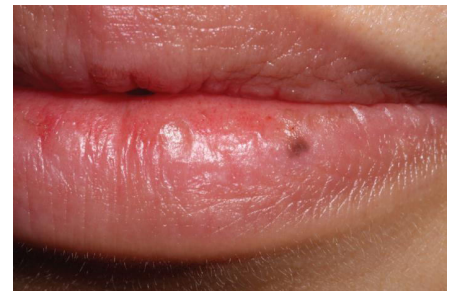**Ephelides** are most commonly observed in **light-skinned individuals**.

Freckles are thought to be **developmental in origin**.

Ephelides are usually more abundant in number and darker in intensity during childhood and adolescence.

Freckles tend to become darker during periods of prolonged sun exposure (spring, summer) and less intense during the autumn and winter months.

In general, no therapeutic intervention is required.



## Oral/Labial Melanotic Macule

The melanotic macule is a unique, **benign, pigmented lesion**.

Melanotic macules are the most common oral lesions of melanocytic origin.

Although the etiology remains elusive, trauma has been postulated to play a role.

Sun exposure is not a precipitating factor.

### Clinical Features

Melanotic macules develop more frequently in females, usually in the lower lip (labial melanotic macule) and gingiva.

However, any mucosal site may be affected.

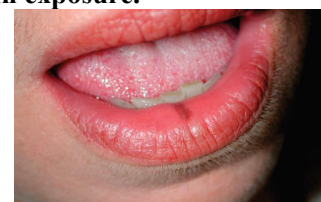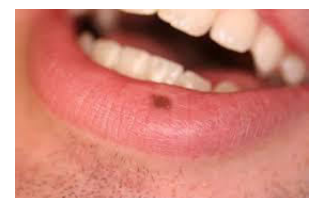Overall, melanotic macules tend to be **small (<1 cm)**, **well circumscribed**, **oval or irregular in outline**, and often **uniformly pigmented**.

Unlike an ephelis, a melanotic macule does not become darker with continued sun exposure.

### The differential diagnosis may include:

- Melanocytic Nevus
- Malignant Melanoma
- Amalgam Tattoo
- Focal Ecchymosis.

If such pigmented lesions are present after a two-week period, ecchymosis can usually be ruled out, and a biopsy specimen should be obtained to secure a definitive diagnosis.

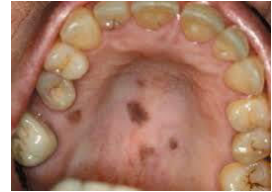
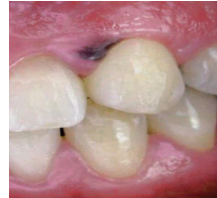
## Oral Melanoacanthoma

Oral melanoacanthoma is another unusual, benign, melanocytic lesion that is unique to the mucosal tissues.

Oral melanoacanthoma may be spontaneously resolve, with or without surgical intervention. Most patients report a rapid onset; and acute trauma or a history of chronic irritation usually precedes the development of the lesion.

The biopsy procedure itself may lead to spontaneous regression of the lesion.



### Clinical Features

Oral melanoacanthoma usually presents as a **rapidly enlarging, ill-defined, darkly pigmented macular or plaque-like lesion**, and mostly develop in black females.

Typically, melanoacanthoma presents as a solitary lesion; however, bilateral and multifocal lesions have been reported. It is generally asymptomatic; however, pain has been reported. Although any mucosal surface may be involved, The size of the lesion is variable, ranging from small and localized to large, diffuse areas of involvement, measuring several centimeters in diameter. The borders are typically irregular in appearance, and the pigmentation may or may not be uniform.

Because oral melanoacanthoma may resemble other melanocytic lesions, such as pigmented nevus, melanotic macule, and melanoma, a biopsy is warranted to obtain a definitive diagnosis

## Melanocytic Nevus

Melanocytic nevi include a diverse group of clinically and/ or microscopically distinct lesions.

Nevi arise as a consequence of melanocytic growth and proliferation.

In the oral cavity, the **intramucosal nevus** is most frequently observed, followed by the **common blue nevus**. **Compound nevi** are less common, and the **junctional nevus** and **combined nevus** (a nevus composed of two different cell types) are infrequently identified.

### Clinical Features

Cutaneous nevi are a common occurrence. The average Caucasian adult patient may have several nevi; some individuals may have dozens. The total number of nevi tends to be higher in males than females. In contrast, oral melanocytic nevi are rare, typically present as solitary lesions, and may be more common in female.

Oral melanocytic nevi have no distinguishing clinical characteristics.

Lesions are usually asymptomatic and often present as a **small (<1 cm), solitary, brown or blue, well-circumscribed nodule or macule** .

Oral nevi may develop at any age; however, most are identified in patients over the age of 30.

The hard palate represents the most common site, followed by the buccal and labial mucosae and gingiva.

### Diagnosis

Biopsy is necessary for diagnostic confirmation of an oral melanocytic nevus

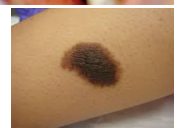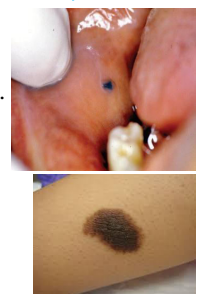
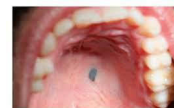### Treatment

Complete but conservative surgical excision is the treatment of choice for oral lesions.

Recurrence has only rarely been reported.

Laser and intense pulse light therapies have been used successfully for the treatment of cutaneous nevi.

However, their value in the treatment of oral nevi is unknown.





## Malignant Melanoma

Melanoma is the malignant neoplasm of melanocyte

Malignant melanoma is the least common but most deadly of all primary skin cancers.

Similar to other malignancies, extrinsic and intrinsic factors play a role in the pathogenesis of melanoma.

A history of multiple episodes of acute sun exposure, especially at a young age; immunosuppression; the presence of multiple cutaneous nevi; and a family history of melanoma are all known risk factors for the development of cutaneous melanoma.

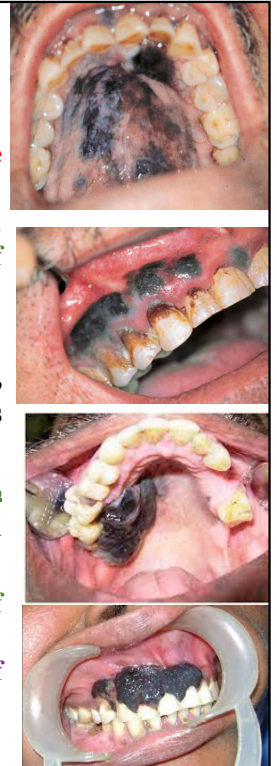### Clinical Features

Cutaneous Melanoma is most common among white populations. However, mortality rates are higher in blacks. Epidemiologic studies suggest that the incidence is increasing in patients, especially males older than 45 years.

Oral melanomas have no distinctive clinical appearance. They may be Macular, Plaque Like Or Mass-forming, Well Circumscribed Or Irregular, And Exhibit Focal Or Diffuse Areas Of Brown, Blue, Or Black Pigmentation.

Up to one-third of oral melanomas may exhibit little or no clinical evidence of pigmentation (amelanosis).

In some cases, oral melanomas may present with what appear to be multifocal areas of pigmentation.



Additional signs and symptoms that may be associated with oral melanoma are nonspecific and similar to those observed with other malignancies.

Ulceration, Pain, Tooth Mobility Or Spontaneous Exfoliation, Root Resorption, Bone Loss, And Paresthesia/Anesthesia May Be Evident.

However, in some patients, the tumors may be completely asymptomatic.

Oral mucosal malignant melanoma is associated with a very poor prognosis.

Studies have demonstrated five-year survival rates of 15%–40%.

The palate shows the worst prognosis compared to other intraoral sites.

Regional lymphatic metastases are frequently identified and contribute to the poor survival rates.

Less than 10% of patients with distant metastases survive after five years.

The 10-year-survival rate is 0%.

### Diagnosis

□ Clinical    Microscopic    Computed Tomography    Magnetic Resonance Imaging

### Management

For primary oral melanomas,

- ❖ Ablative Surgery with wide margins remains the treatment of choice.
- ❖ Adjuvant radiation therapy may also be necessary.
- ❖ A variety of chemotherapeutic and immunotherapeutic strategies are often used if metastases are identified or for palliation.
- ❖ Adjuvant interferon- $\alpha$ -2B therapy has already been approved for the treatment of primary cutaneous melanomas greater than 4 mm in thickness.



## Multifocal/Diffuse Pigmentation

### Physiologic Pigmentation

Physiologic pigmentation is the most common multifocal or diffuse oral mucosal pigmentation. Dark-complexioned individuals, including blacks, Asians, and Latinos, frequently show patchy to generalized hyperpigmentation of the oral mucosal tissues. Although in many patients, the pigment is restricted to the gingiva, melanosis of other mucosal surfaces is not uncommon.

This pigmentation is considered a variation of normal. Nonetheless, the appearance of **brown to black discoloration**, even intraorally, can be esthetically displeasing to some patients.

Treatment:

Surgical intervention may be necessary.

Gingivectomy And Laser therapy have been used to remove pigmented oral mucosa.

Cryosurgery has also been reported to effectively remove oral pigmentation.

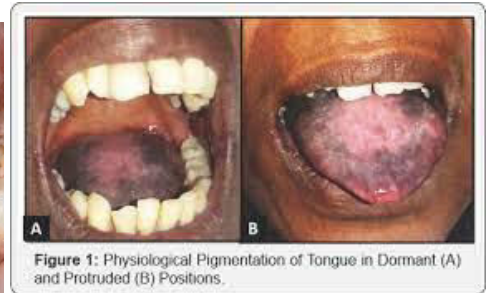
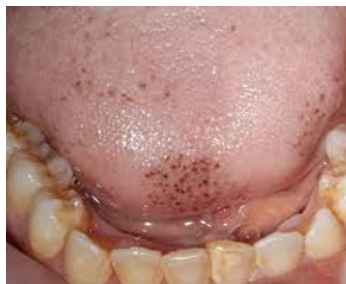
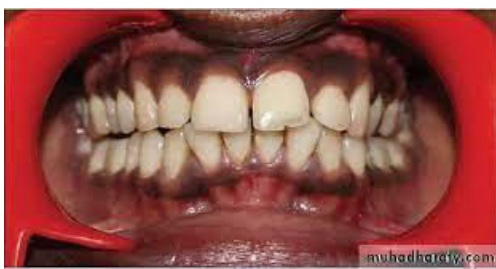
Figure 1: Physiological Pigmentation of Tongue in Dormant (A) and Protruded (B) Positions.

### Drug-Induced Melanosis

Medications may induce a variety of different forms of mucocutaneous pigmentation, including melanosis.

The chief drugs implicated in drug-induced melanosis are

➤ Antimalarials, Including Chloroquine, Hydroxychloroquine, And Quinacrine.

In the Western world, these medications are typically used for the treatment of autoimmune disease.

➤ Phenothiazines, Such As Chlorpromazine,

➤ Oral Contraceptives

➤ Cytotoxic Medications, Such As Cyclophosphamide And Busulfan.

### Clinical Features

Intraorally, the pigment can be diffuse yet localized to one mucosal surface, often the hard palate or it can be multifocal and involve multiple surfaces.

the lesions are flat and without any evidence of nodularity or swelling.

### Diagnosis

In most cases, the discoloration tends to disappear within a few months after the drug is discontinued.

Laboratory tests may be necessary to rule out an underlying endocrinopathy.

## **Smoker's Melanosis**

Diffuse melanosis of the anterior vestibular maxillary and mandibular gingivae, buccal mucosa, lateral tongue, palate, and floor of the mouth is occasionally seen among cigarette smokers.

The pigmented areas are **brown, flat, and irregular.**

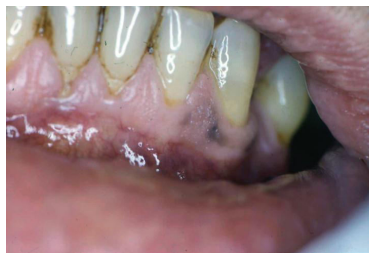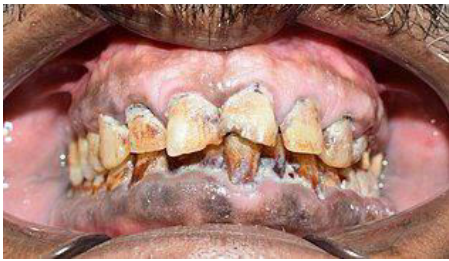Smokeless tobacco (snuff) does not appear to be associated with an increase in oral melanosis.

Thus, it is possible that one or more of the chemical compounds incorporated within cigarettes, rather than the actual tobacco, may be causative. Another possibility is that the heat of the smoke may stimulate the pigmentation.

A reduction in smoking may lead to disappearing of the pigmentation.

Alcohol has also been associated with increased oral pigmentation.

In alcoholics, the posterior regions of the mouth, including the soft palate, tend to be more frequently pigmented than other areas.



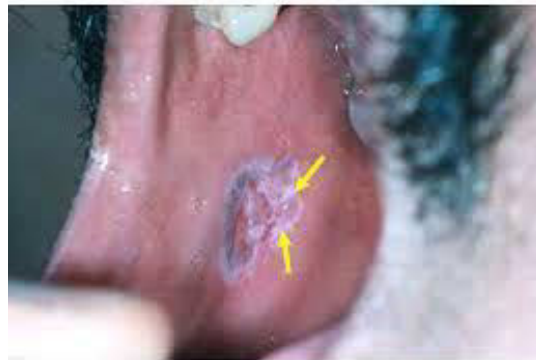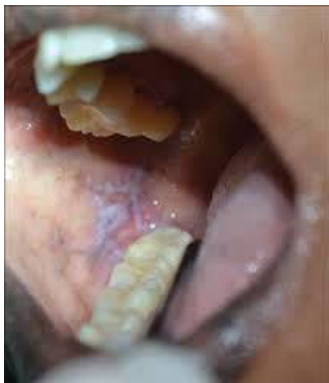## **Post inflammatory Hyperpigmentation**

It is a well-recognized phenomenon that tends to develop more commonly in dark-complexioned individuals.

Most cases present as either focal or diffuse pigmentation in areas that were subjected to previous injury or inflammation.

Oral pigmentation has also been described in patients with lichen planus.

Upon resolution of the lichenoid lesion, in most cases, the pigmentation eventually does subside.



### Melasma (Chloasma)

Melasma is a relatively common, acquired symmetric melanosis that typically develops on sun-exposed areas of the skin and frequently on the face.

The forehead, cheeks, upper lips, and chin are the most commonly affected areas.

There is a distinct female predilection, and most cases arise in darker-skinned individuals.

The term melasma has been used to describe any form of generalized facial hyperpigmentation, including those related to post-inflammatory changes and medication use.

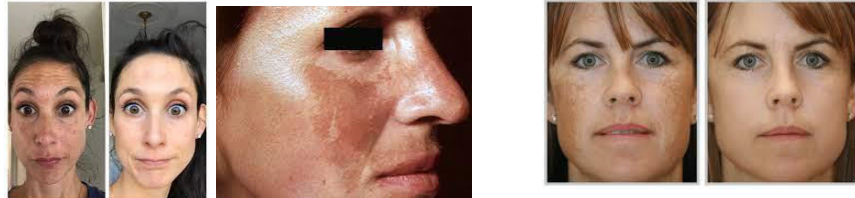However, the term is most appropriately used to describe the pigmentary changes associated with sun exposure and hormonal factors, including pregnancy and contraceptive hormones.

Both pregnancy and use of oral contraceptives have also been associated with oral mucosal melanosis.

Various thyroid abnormalities, including hypothyroidism, may also play a role in the pathogenesis of pregnancy- and nonpregnancy-associated melasma.

Melasma may spontaneously resolve after cessation of the exogenous hormones, or regulation of endogenous sex hormone levels.

A successful therapeutic approach for the treatment of melasma consists in the topical administration of a triple combination product (4% Hydroquinone, 0.05% Tretinoin, And 0.01% Fluocinolone Acetonide) Along With Photoprotection.



### Melanosis Associated With Systemic or Genetic Disease

#### Hypoadrenocorticism (Adrenal Insufficiency or Addison's Disease)

##### Etiology and Pathogenesis

A variety of etiologies may precipitate adrenal insufficiency.

In adults, autoimmune disease represents one of the most common causes.

However, infectious agents, neoplasia, trauma, certain medications, and iatrogenic causes may lead to adrenal destruction or an impairment of endogenous steroid production.

Weakness, poorly defined fatigue, and depression are some of the typical presenting signs of the illness. However, in some patients, the first sign of disease may be mucocutaneous hyperpigmentation. Generalized bronzing of the skin and diffuse but patchy melanosis of the oral mucosa are hallmarks of hypoadrenocorticism. Any oral surface may be affected.

In some patients, oral melanosis may be the first manifestation of their adrenal disease.

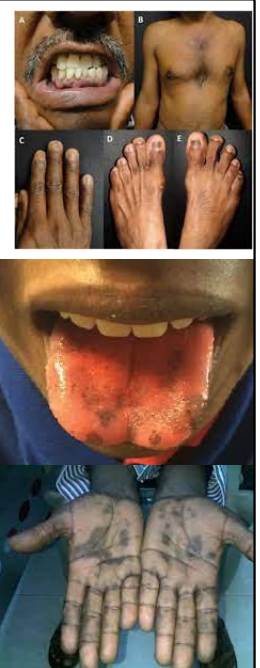
##### Diagnosis

The diagnosis of oral Addisonian pigmentation requires a

- **Clinicopathologic Correlation.**
- **Laboratory tests, including the evaluation of serum cortisol and electrolyte levels, are necessary to make a diagnosis of Addisonian hyperpigmentation.**

Treatment consists of

- Exogenous Steroid Replacement Therapy with glucocorticoids and mineralocorticoids.**
- There is evidence supporting the use of adrenal androgens such as dehydroepiandrosterone to improve the quality of life of patients with Addison's disease.**
- With appropriate therapy, the pigmentation will eventually resolve.**



## **Cushing's Syndrome/Cushing's Disease**

### **Etiology and Pathogenesis**

Cushing's syndrome develops as a consequence of prolonged exposure to relatively high concentrations of endogenous or exogenous corticosteroids.

As steroid levels decrease, there is a compensatory activation of ACTH secretion from the anterior pituitary gland.

- ACTH then acts on the adrenal cortex to stimulate steroid production and ACTH secretion stops.
- If low steroid levels persist, there is a loss of feedback inhibition, resulting in persistent secretion of ACTH into the serum.
- Concurrently, the serum levels of  $\alpha$ -melanocyte-stimulating hormone ( $\alpha$ MSH) also increase.
- At the molecular level, this is explained by the fact that the precursor proopiomelanocortin gene contains the sequences of both the ACTH and  $\alpha$ MSH genes.

### **Clinical Features**

Overall, Cushing's syndrome is more prevalent in female patients.

Apart from the wide array of systemic complications, including weight gain and the characteristic "moon facies," diffuse mucocutaneous pigmentation may be seen in a subset of patients, specifically those whose pathology associated with increased ACTH secretion.

Thus, in most cases, the affected patients have a primary pituitary neoplasm.

The pattern of oral pigmentation is essentially identical to that seen in patients with adrenal insufficiency.

## **Diagnosis**

**Three main tests** are used for the diagnosis of Cushing's syndrome:

- Low-dose dexamethasone suppression test,
- Midnight plasma cortisol,
- And 24-hour urinary free cortisol.

### **Treatment**

The pigmentation often resolves following appropriate

- Surgical,
- Radiation,
- Or Drug Therapy for the specific source of the endocrinopathy.
- Pasireotide (a Somatostatin Analog) has been approved for the treatment of Cushing's syndrome.

### **Hyperthyroidism (Graves' Disease)**

Melanosis is a common consequence of hyperthyroidism (Graves' disease), especially in dark-skinned individuals. At least 40% of black patients with thyrotoxicosis may present with mucocutaneous hyperpigmentation.

The pigmentation tends to resolve following treatment of the thyroid abnormality.

### **Primary Biliary Cirrhosis**

- Diffuse mucocutaneous hyperpigmentation may be one of the earliest manifestations of primary biliary cirrhosis.
  - Up to 47% of patients with this condition develop diffuse melanosis.
  - This uncommon disease is of unknown etiology, although it is thought to be autoimmune in nature as evidenced by the presence of antimicrobial antibodies.
  - It develops mainly in middle-aged women.
  - The disease results from damage to small intrahepatic bile ducts.
  - Primary biliary cirrhosis may also be a source of generalized nonmelanocytic mucocutaneous discoloration.
- Jaundice is usually an end-stage complication of primary biliary cirrhosis.
  - However, jaundice may also be associated with a variety of other etiologies, including liver cirrhosis, hepatitis, neoplasia, gallstones, congenital disorders, and infection.
  - Jaundice is caused by excessive levels of serum bilirubin (a breakdown product of hemoglobin).
  - Hyper-bilirubinemia often induces a yellowish discoloration of the skin, eyes, and mucous membranes.
  - Treatment** of the underlying disease will lead to resolution of jaundice.

### **Vitamin B12 (Cobalamin) Deficiency**

Vitamin B12 deficiency may be associated with a variety of systemic manifestations, including

- Megaloblastic Anemia,**
- Various Neurologic Signs And Symptoms,**
- Various cutaneous manifestations, and oral manifestations, including a generalized burning sensation, erythema, and atrophy of the mucosal tissue.**

**Diffuse mucocutaneous hyperpigmentation is a rare, and poorly recognized, complication of vitamin B12 deficiency.**

**This hyperpigmentation is suggestive of Addison's disease.**

**The pigmentation resolves following restoration of vitamin B12 levels.**



## Peutz–Jeghers Syndrome

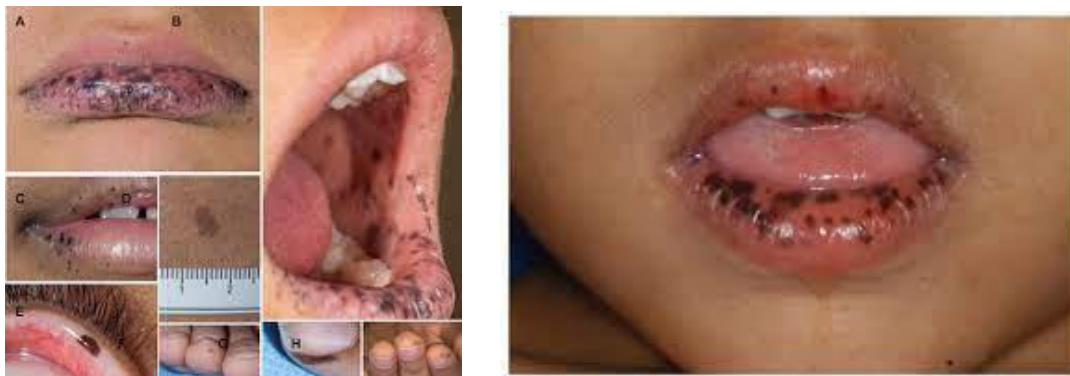Peutz–Jeghers syndrome is an inherited autosomal dominant disease.

Clinical manifestations include

- ❑ Intestinal polyposis,
- ❑ Cancer susceptibility,
- ❑ Multiple, small, dark brown or blue macules of the lips, perioral skin, hands, and feet.

The macules may resemble ephelides, usually measuring <0.5 cm in diameter.

The medical management for Peutz–Jeghers syndrome consists in surveillance and treatment of Hamartomatous polyps.



## Café au Lait Pigmentation

❖ Solitary, idiopathic café au lait (“coffee with milk”) spots are occasionally observed in the general population, but multiple café au lait spots are often indicative of an underlying genetic disorder. Including

Neurofibromatosis Type I.  
McCune Albright Syndrome.  
Noon’s syndrome.

- ❖ It is typically present as **Brown-colored, irregularly shaped macules** of variable size; anywhere on the skin, although unusual, examples of similar-appearing oral macular pigmentation have been described in some patients.
- ❖ In addition, the size, number, and age at onset of the cutaneous café au lait spots are of diagnostic importance for this disease.

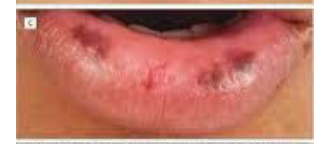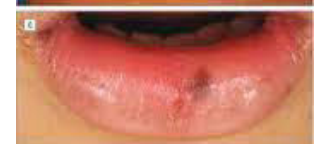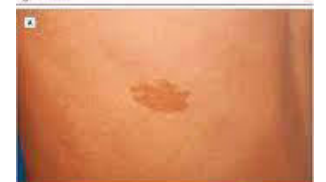## Albright Syndrome

A Type of **fibrous dysplasia** involving all the bones in the skeleton.

- Solitary, idiopathic café au lait
- Endocrine disturbances of varying types.



Figure 1 Case 1

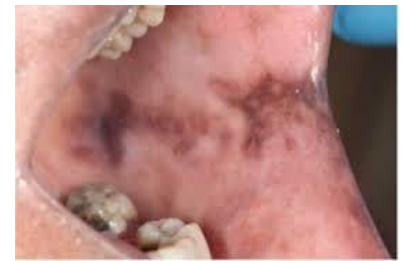

A. Café au lait spot on the forehead. B. Café au lait spot on the chest. C. Café au lait spots on the lips. D. Café au lait spots on the lips.



### HIV/AIDS-Associated Melanosis

- **Diffuse or multifocal mucocutaneous pigmentation** has been frequently described in HIV-seropositive including
  - Antifungal And Antiretroviral Drugs,
  - or as a result of adrenocortical destruction by virulent infectious organisms.
  - Recent studies suggest that melanosis may be an actual potentially late-stage, clinical manifestation of HIV/AIDS.
  - A significant correlation between mucocutaneous pigment and CD4 counts cells/ $\mu$ L $\times$ 200.
  - Studies have also shown that the immune dysregulation associated with HIV/AIDS leads to increased secretion of  $\alpha$ -MSH from the anterior pituitary gland, which may also stimulate increased melanin synthesis
- ⌚ HIV/AIDS patients may present with a history of progressive **hyperpigmentation of the skin, nails, and mucous membranes.**
- ⌚ The pigmentation resembles most of the other forms of diffuse melanosis.
  - The buccal mucosa is the most frequently affected site, but
  - the gingiva,
  - palate,
  - and tongue may also be involved.



### Depigmentation( Vitiligo)

#### Etiology and Pathogenesis

**Vitiligo is a relatively common, acquired, autoimmune disease that is associated with hypomelanosis.**

- Vitiligo affects 0.5–2 % of the world population with no gender or racial preference.
- Although the precise etiology
  - Remains Unknown,
  - Autoimmunity,
  - Cytotoxicity,
  - Genetics,
  - And Alterations From Metabolic Or Oxidative Stress have been implicated in this condition where the end result is a destruction of the melanocytes.

**The pathogenesis of vitiligo is multifactorial, with both**

❖ **Genetic And Environmental Factors** playing a role in the development of this disease.

❖ A recent study has identified a single-nucleotide polymorphism in a vitiligo susceptibility gene that is also associated with susceptibility to other autoimmune diseases, including

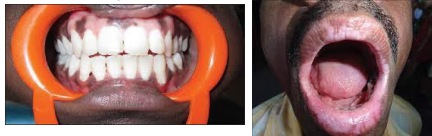- Diabetes Type 1,
- Systemic Lupus Erythematosus,
- Rheumatoid Arthritis

### Clinical Features

- The classification for vitiligo has been recently revised, and now this condition is segregated into **Nonsegmental Vitiligo, Segmental Vitiligo, And Unclassified/Undetermined Vitiligo.**
- Multiple achromic patches with remitting-relapsing course are seen in nonsegmental vitiligo.
- Segmental vitiligo shows a characteristic dermatomeric distribution of the achromic patches with a rapid onset that is usually not progressive.
- The onset of vitiligo may occur at any age, but more frequently during the second and third decade of life.
- The depigmentation is more apparent in patients who have a darker skin tone.

Yet the disease actually occurs in all races.

- Vitiligo may also arise in patients undergoing immunotherapy for the treatment of malignant melanoma.
- Studies suggest that this phenomenon may be associated with a better prognosis for this group of patients.
- Vitiligo rarely affects the intraoral mucosal tissues. However, hypomelanosis of the inner and outer surfaces of the lips and perioral skin may be seen in up to 20% of patients



Segmental Vitiligo

Nonsegmental Vitiligo

### Pathology

Microscopically, there is a destruction of melanocytes by antigen-specific T cells and complete loss of melanin pigmentation in the basal cell layer.

The use of histochemical stains such as Fontana-Masson will confirm the absence of melanin.

### Management Of Vitiligo

In most cases, the objective of therapeutic intervention is to stimulate repigmentation.

- Topical Corticosteroids,
- Topical Calcineurin Inhibitors,
- Ultraviolet B Narrow Band,
- Psoralen And Ultraviolet A exposure have proven to be effective nonsurgical therapies.

In rare cases, small foci of normal pigmented skin may be contained within otherwise diffuse areas of hypomelanosis. Thus, to create a unified skin color, **Cutaneous Bleaching** may be considered.

□ From the standpoint of therapy, labial vitiligo is more resistant to the typical treatments used for cutaneous vitiligo. Due to a lack of hair follicles, the lips do not have a reservoir of melanocytes that can be stimulated to produce pigment.

□ Thus, **Surgical Intervention** may be the only option to achieve an esthetic result.

□ **Autologous Epithelial Grafts** have been used successfully, with patients often reporting a more acceptable cosmetic appearance.

□ **Split-thickness Skin Grafts** have been reported as having the highest repigmentation success rate.

□ **Punch Grafting And Micropigmentation** (whereby an exogenous brown pigment is injected into the lip, much like a tattoo) have also been reported.

□ In rare instances, **Surgical Intervention** may stimulate spontaneous repigmentation of vitiliginous lesions elsewhere on the body

### Treatment of Mucocutaneous Melanosis

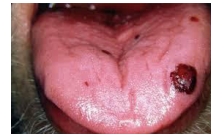- In general, focally pigmented lesions warrant removal, for both diagnostic and therapeutic purposes.
  - However, apart from those cases associated with neoplasia, surgical intervention is less of an option for the treatment of multifocal or diffuse pigmentation.
  - Drug-induced melanosis and other examples of exogenously stimulated generalized pigmentation may spontaneously subside after withdrawal of the offending substance. In other cases, the discoloration may be persistent, if not permanent. In such cases, the cosmetic disfigurement may result in significant social, psychological, and emotional stress.
  - **Different thickness flap, gingivectomy, cryotherapy, electrosurgery, bur abrasion, and scraping with a scalpel** have been successfully used to treat **gingival pigmentation**.
  - **Laser therapy** has also proven to be an effective modality for use in the treatment of oral pigmentation. However, the beneficial effects may only be temporary, with recurrence of at least partial pigmentation in upward of 20% of treated patients.
  - However, first-line therapy remains the **application of topical medications that is, bleaching creams**.
  - Although single agents such as **Azelaic Acid Or Hydroquinone** have been used, more commonly, dual- or triple-combination therapy is recommended.
- A combination of 4% Hydroquinone (0.05%) Retinoic Acid (0.01%) Fluocinolone Acetonide has proven to be effective in greater than 90% of patients.

### □ Hemoglobin and Iron associated Pigmentation

Ecchymosis Purpura/Petechiae Hemochromatosis or Bronze Diabetes

#### □ Ecchymosis

- **Traumatic ecchymosis** is common on the **lips and face** yet uncommon in the oral mucosa, except in cases related to **Blunt-force Trauma And Oral Intubation**.
- Immediately following the traumatic event, erythrocyte extravasation into the connective tissue will appear as **A Bright Red Macule** or as a **swelling if a hematoma forms**. The lesion will assume a **Brown Discoloration** within a few days, after the hemoglobin is degraded to hemosiderin.
- Patients taking anticoagulants may present with oral ecchymosis, particularly on the buccal mucosa or tongue, either of which can be traumatized while chewing.
- Ecchymoses of the oral mucosa may also be encountered in patients with **Liver Cirrhosis, In Patients With Leukemia, And Additionally, In Patients With End-stage Renal Disease Who Are Undergoing Dialysis Treatment**.



#### Laboratory tests, including

- Bleeding Time,
  - Prothrombin Time,
  - Partial Thromboplastin Time, And International Normalization Ratio,
- should be obtained in instances of spontaneous ecchymoses to explore defects in the coagulation pathways.

## Purpura/Petechiae

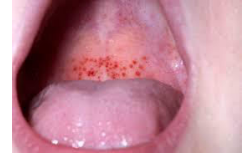Capillary hemorrhages will appear **Red** initially and turn **Brown** in a few days once the extravasated red cells have lysed and have been degraded to hemosiderin.

The distinction between purpura and petechiae is based solely on the **size of the focal hemorrhages**.

**Petechiae are typically characterized as being Pinpoint Or Slightly Larger Than Pinpoint Purpura As Multiple, Small 2–4 Mm Collections Of Extravasated Blood**

Oral purpura/petechiae may develop as a consequence of

- Trauma,
- Viral,
- Systemic Disease



**Petechiae secondary to platelet deficiencies** are usually not limited to the oral mucosa but may occur concomitantly on the skin.

**Viral disease is more commonly associated with oral** rather than cutaneous petechiae.

In most cases, the petechiae are identified on the soft palate, although any mucosal site may be affected.

Within two weeks, the lesions should resolve. Failure to do so should arouse suspicion of a

- Hemorrhagic Diathesis,
- Persistent Infectious Disease,
- Other Systemic Disease, (appropriate laboratory investigations must be undertaken.)

## Hemochromatosis or Bronze Diabetes

Hemochromatosis is a **Chronic, Progressive Disease** that is characterized by **Excessive Iron Deposition** (usually in the form of **hemosiderin**) in the **Liver And Other Organs And Tissues**.

- Idiopathic,
- neonatal,
- blood transfusion,
- and heritable forms of this disease are recognized.

Complications of hemochromatosis may include

- Liver Cirrhosis
- Diabetes
- Anemia
- Heart Failure
- Hypertension
- Bronzing Of The Skin



Figure 1. Pigmentation of the skin in a 68-year-old man with genetic haemochromatosis (Dr P. Marazzi/Science Photo Library)

The cutaneous pigmentation is seen in over 90% of affected patients.

The primary oral manifestation of hemochromatosis is a **Blue-gray To Brown Pigmentation** affecting mainly the **Palate And Gingiva**.

## Exogenous Pigmentation (Amalgam Tattoo)

### Etiology and Pathogenesis

The most common pigmented lesion in the oral mucosa is amalgam tattoo.

By definition, these are iatrogenic in origin and typically a consequence of the accidental deposition of amalgam restorative material into the submucosal tissue.

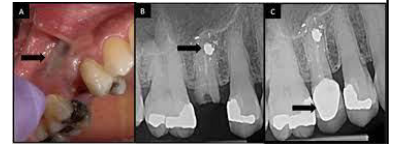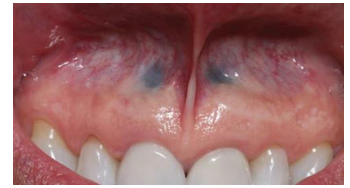### Clinical Features

The lesions are typically

**small, asymptomatic, macular, and Bluish Gray or even black in appearance.**

They may be found on any mucosal surface; however, the **Gingiva, Alveolar Mucosa, Buccal Mucosa, And Floor Of The Mouth** represent the most common sites.

The lesions are often found in the **vicinity of teeth with large amalgam restorations** or crowned teeth that probably had amalgams, **around the apical region of endodontically treated teeth with retrograde restorations or obturated with silver points**, and in areas in and around healed extraction sites

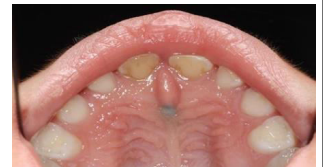

### Graphite Tattoos

Graphite tattoos are an unusual source of focal exogenous pigmentation.

They are most commonly seen on the **Palate And Gingiva** and **represent traumatic implantation of graphite particles from a pencil.**

The lesions may be indistinguishable from amalgam tattoos, often presenting as **a solitary Gray Or Black Macule**. Since the traumatic event often occurs in **childhood**,

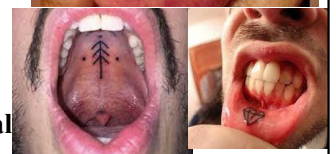


## Ornamental Tattoos

□ Mucosal tattoos in the form of **Lettering Or Complicated Artwork** are becoming increasingly common phenomena.

□ **Amateur Tattoo Inks** are permanent and consist of simple, **Carbon Particles** originating from a variety of sources, including **burnt wood, plastic, or paper**, and from a variety of inks, such as **India ink, pen ink, and plant derived matter**.

□ **Q-switched Laser Therapy** has been used successfully to remove tattoos of the oral mucosa



## Medicinal Metal-Induced Pigmentation

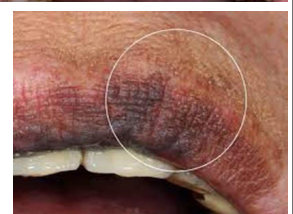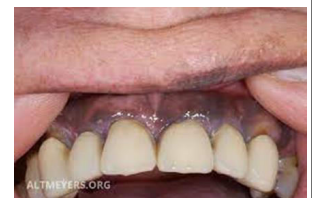□ Historically, a variety of metallic compounds have been used medicinally for the treatment of various systemic diseases.

□ Fortunately, with the advent of methotrexate for the treatment of rheumatoid arthritis, **gold therapy** is in less demand.

□ **Colloidal silver** is another metal-based substance that has been historically used for its beneficial health effects.

□ Although its medical use has been significantly reduced, it has become widely available among patients using “complementary and alternative medicine therapies.”

□ **Gold and colloidal silver** have both been associated with diffuse cutaneous pigmentation.





- **Silver may cause a generalized blue-gray discoloration (Argyria),** whereas **Gold-induced pigment may appear blue-gray or purple (Chrysiasis).** In both cases, the pigmentation may be persistent, if not permanent, even following discontinuation of the substance.
- However, **Oral Lichenoid Eruptions** have been associated with **Systemic Gold Therapy.**
- **Silver Nitrate And Zinc Oxide;** Silver nitrate cautery has been used to treat recurrent aphthous stomatitis, and zinc oxide is a common component of sunblock creams. **Both substances have been associated with Focal Mucocutaneous Pigmentation.**
- Using of zinc oxide containing sunblock in severely chaffed lips may result in the development of hyperpigmentation.
- Medicinal silver-associated pigment appears as **Brown or Black** particulate matter dispersed throughout the connective tissue.
- **Generalized Black Pigmentation** of the tongue has been attributed to the chewing of **Bismuth Subsalicylate Tablets, a commonly used Antacid.**
- This phenomenon is unlike black hairy tongue, which is associated with elongation of the filiform papillae, hyperkeratosis, and superficial colonization of the tongue by bacteria.
- Black tongue induced by bismuth subsalicylate is caused by deposition of actual pigment (bismuth sulfide), without any other lingual changes.
- Discontinuation of the antacid and cleansing of the tongue are curative.
- It should be noted that typical black hairy tongue may also be attributed to the use of bismuth subsalicylate

### **Heavy Metal Pigmentation**

- Diffuse oral pigmentation may be associated with ingestion of heavy metals. Nowadays, this phenomenon is unusually encountered.
- Yet it remains an occupational and health hazard for some individuals who work in certain industrial plants and for those who live in the environment in and around these types of facilities.
- Other relatively common environmental sources include paints, old plumbing, and seafood

### **Drug-Induced Pigmentation**

- **Minocycline,** which is a tetracycline derivative and frequently used in the treatment of acne, is a relatively common cause of drug-induced non-melanin-associated oral pigmentation.
- Similar to tetracycline, minocycline can cause pigmentation of developing teeth. However, most patients are prescribed minocycline in early adulthood.
- When taken chronically, minocycline metabolites may become incorporated into the normal bone.
- Thus, although the teeth may be normal in appearance, the surrounding bone may appear green, blue, or even black.
- As a result, the palatal and alveolar mucosae may appear similarly and diffusely discolored.
- In addition, roots show a green color, whereas developing roots tend to be black.



- Minocycline can also induce actual pigmentation of the oral soft tissues, as well as the skin and nails.
- Minocycline-induced soft tissue pigmentation may appear gray, brown, or black. Often the pigmentation is patchy or diffuse in its presentation. Although, a biopsy may reveal basilar melanosis, more commonly, aggregates of fine brown or golden particles are identified within the submucosal tissue.
- **The particles are often intracellular and contained within macrophages.**
- **It is likely that the particulate substance represents an actual precipitated drug metabolite rather than true melanin.**
- **The mucosal discoloration produced by minocycline often subsides within months after discontinuation of the medication.**
- **Nowadays, acceptable esthetic outcomes are obtained even in severe cases of cutaneous pigmentation associated with minocycline intake when Alexandrite755- nm laser therapy is used.**
- **However, the bone pigment may persist for longer periods of time, if not indefinitely.**
- **Methacycline, another tetracycline derivative that is no longer widely used in clinical practice, can also produce a similar form of pigmentation.**
- **Imatinib (a tyrosine kinase inhibitor used for the treatment of chronic myeloid leukemia) has the potential to induce mucosal pigmentation.**

### Hairy Tongue

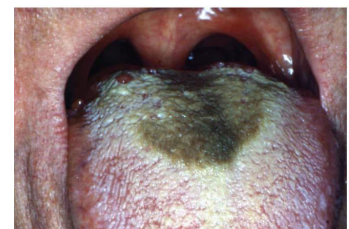- Hairy tongue is a relatively common condition of unknown etiology.
- **The change in oral flora associated with chronic antibiotic therapy may be causative in some patients.**
- The discoloration involves the dorsal tongue, particularly the middle and posterior one-third.
- Rarely children are affected.
- **The filiform papillae are elongated, sometimes markedly so, and have the appearance of fine hairs.**
- **The hyperplastic papillae then become pigmented by the colonization of chromogenic bacteria, which can impart a variety of colors, including white, green, brown, or black.**
- Various foods, drinks, and confectionaries can contribute to the diffuse discoloration.
- **Smoking of tobacco or crack cocaine has been associated with black hairy tongue.**
- Rare examples have been linked to the use of psychotropic medications.
- **It has been associated with other pharmacos such as tetracycline, linezolid, olanzapine, bismuth and erlotinib.**

**Microscopically**, the filiform papillae can be seen as extremely elongated and hyperplastic with hyperkeratosis. Superficial microbial colonization of the papillae is a prominent feature. There are no additional pathologic findings in the remaining epithelium or in the connective tissue.

### Treatments

consist of having the patient brush the tongue, or use a tongue scraper, and limit the ingestion of color-forming foods and drinks until the discoloration resolves.

Since the cause is often undetermined, the condition may recur.



## ***PREMALIGNANT LESIONS AND CONDITIONS***

*Premalignant lesions* are those lesions in which carcinoma may develop.

*Premalignant conditions* are associated with a risk of carcinoma at some site within the mouth, not necessarily marked by a pre-existing lesion.

## ***Leukoplakia***

is currently defined as “a white patch or plaque that cannot be characterized clinically or pathologically as any other disease” WHO,

## *Clinical Features*

Leukoplakia is associated with a middle-aged and older adults, with the vast majority of cases occurring in persons over the age of 40 years.

## *Sites of Leukoplakia*

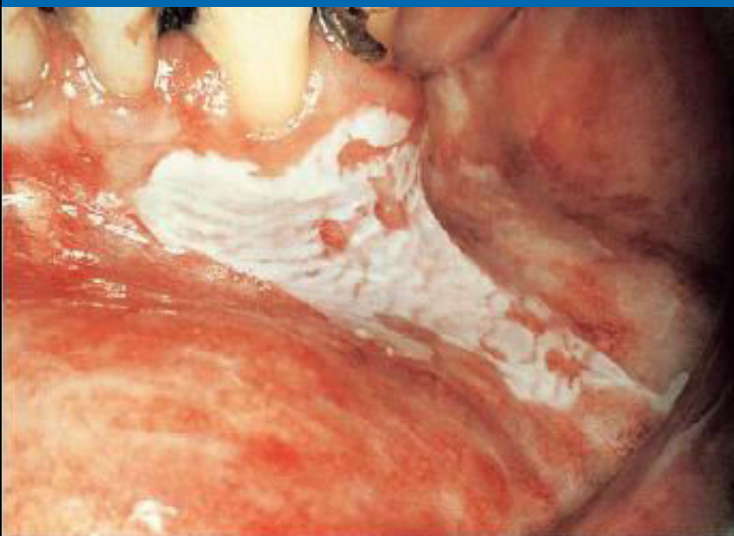- \* The tongue ,buccal mucosa, account for almost half of leukoplakias today.
- \* The palate,maxillary ridge,and lower lip less frequently involved,
- \* The floor of the mouth and retromolar sites are involved infrequently, however, any site can be involved on occasion.

# *Subtypes*

*Many varieties of leukoplakia have been identified.*

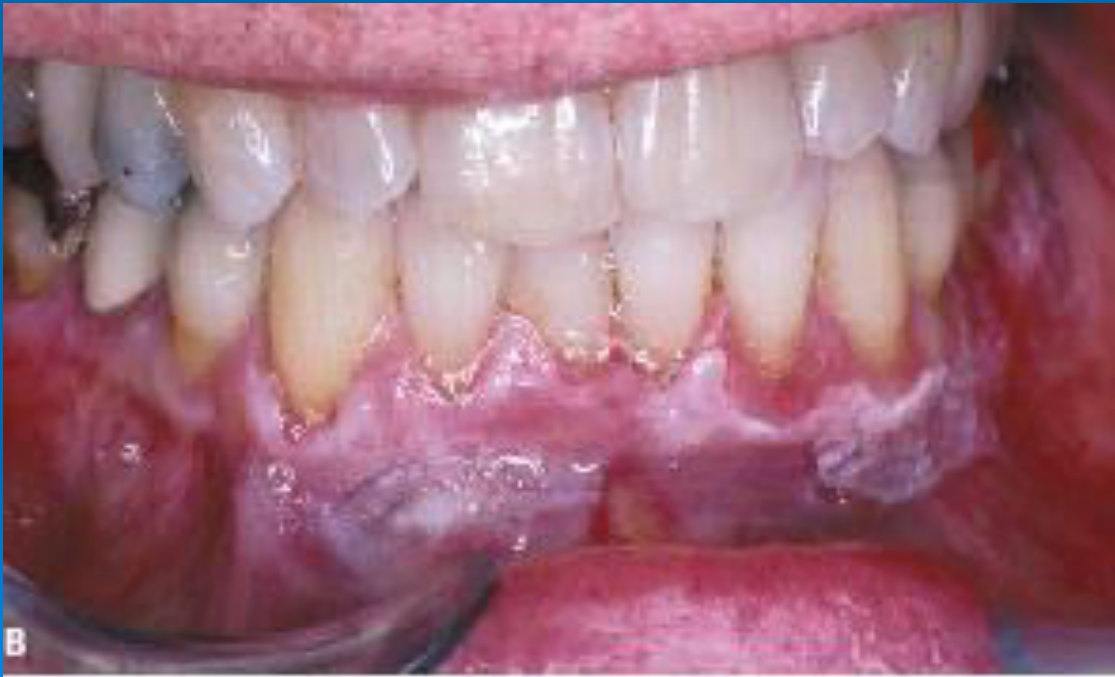- “Homogeneous leukoplakia” or “thick leukoplakia”
- Nodular (speckled) leukoplakia
- “Verrucous leukoplakia” or “verruciform leukoplakia”
- Proliferative verrucous leukoplakia (PVL)

## *Homogeneous leukoplakia” or “thick leukoplakia*

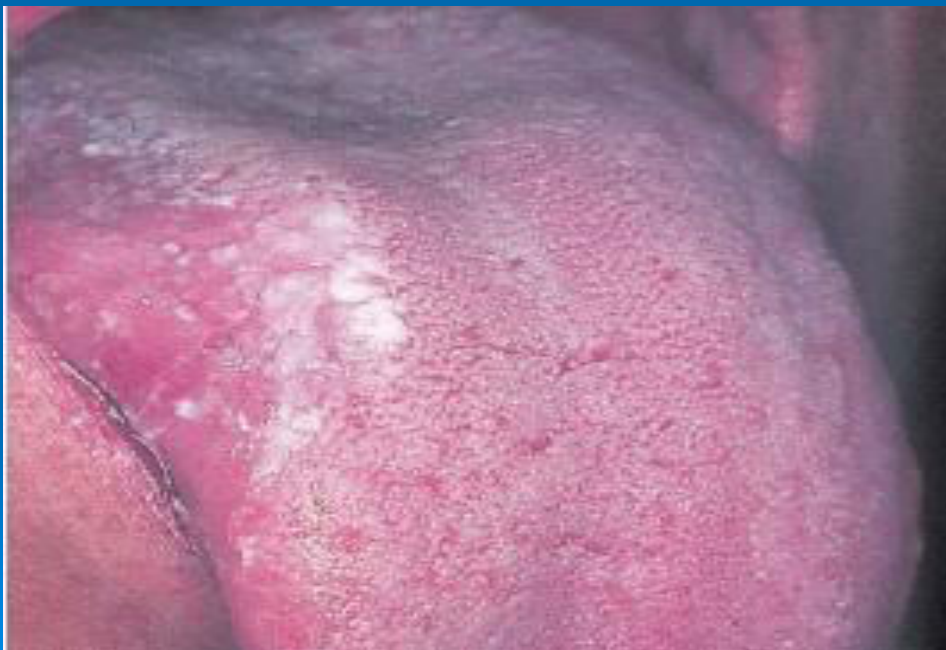

Refers to a usually well-defined white patch, localized or extensive that is slightly elevated and that has a fissured, wrinkled, or corrugated surface

*Homogeneous leukoplakia*  
*“thick leukoplakia”*

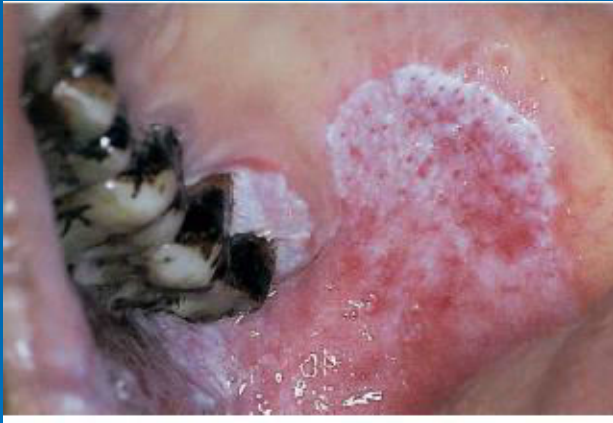

*Homogeneous leukoplakia*  
*“thick leukoplakia”*





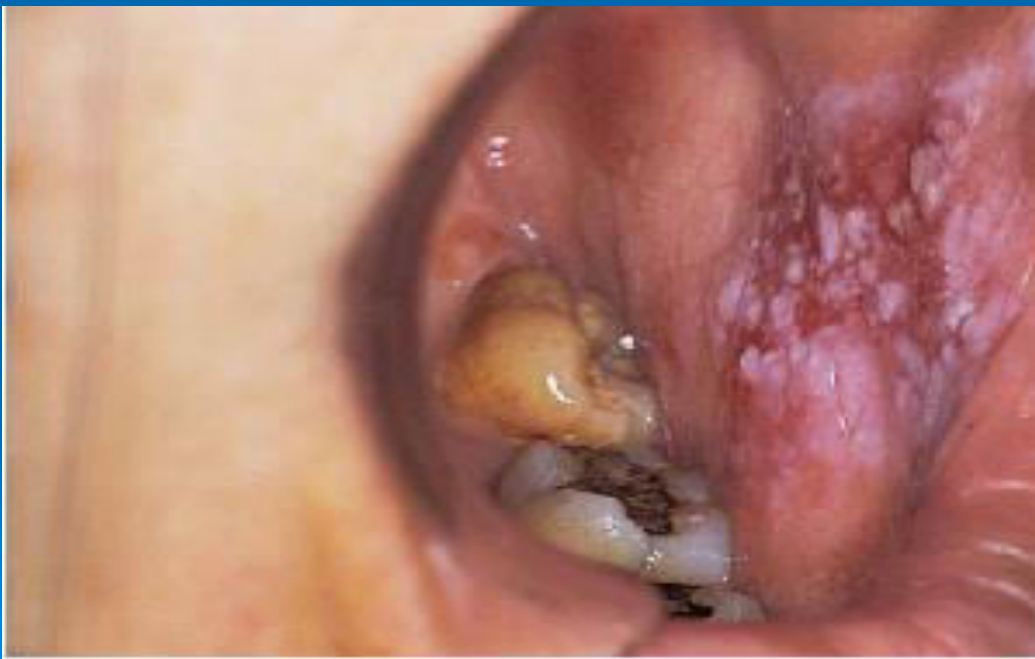## ***Nodular (speckled) leukoplakia is granular or nonhomo-geneous***



*The name refers to a mixed red-and- white lesion in which keratotic white nodules or patches are distributed over an atrophic erythematous background.*

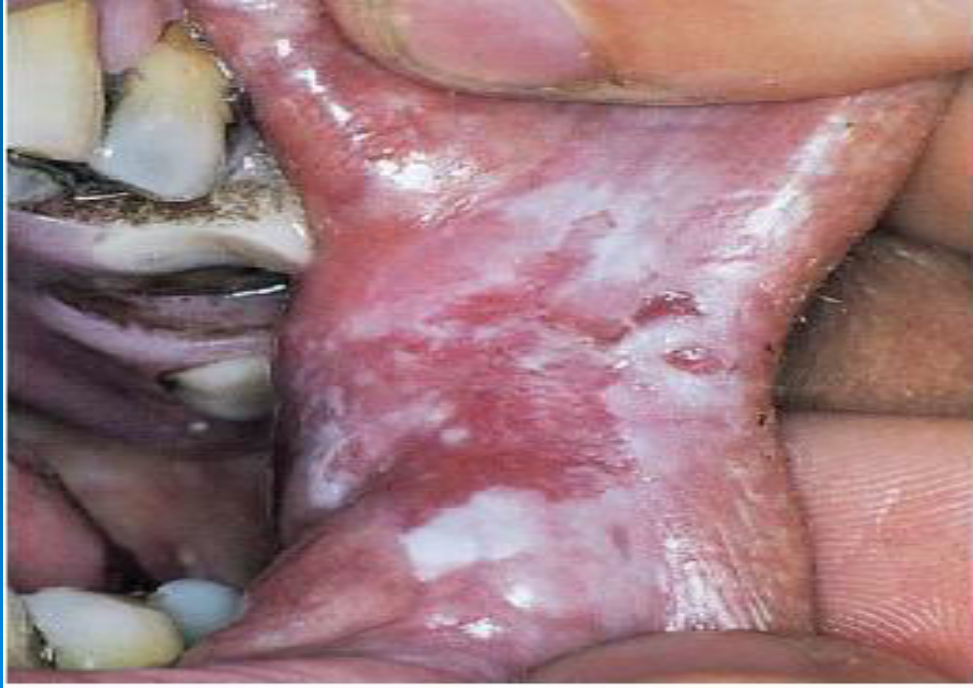
*This type of leukoplakia is associated with a higher malignant transformation rate, with up to two - thirds of the cases in some series showing epithelial dysplasia or carcinoma.*

### ***Nodular (speckled) leukoplakia***

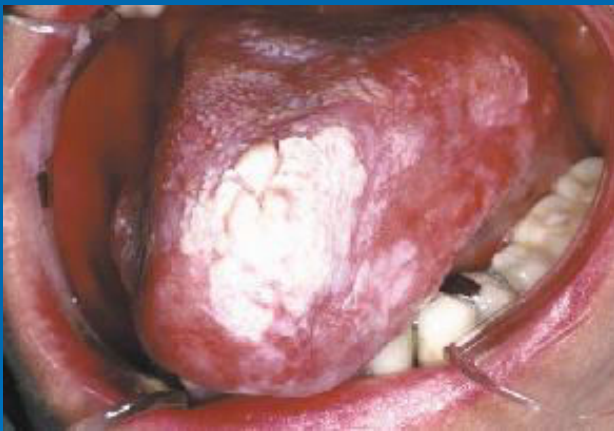



## ***Nodular (speckled) leukoplakia***



## ***“Verrucous leukoplakia or “verruciform leukoplakia***

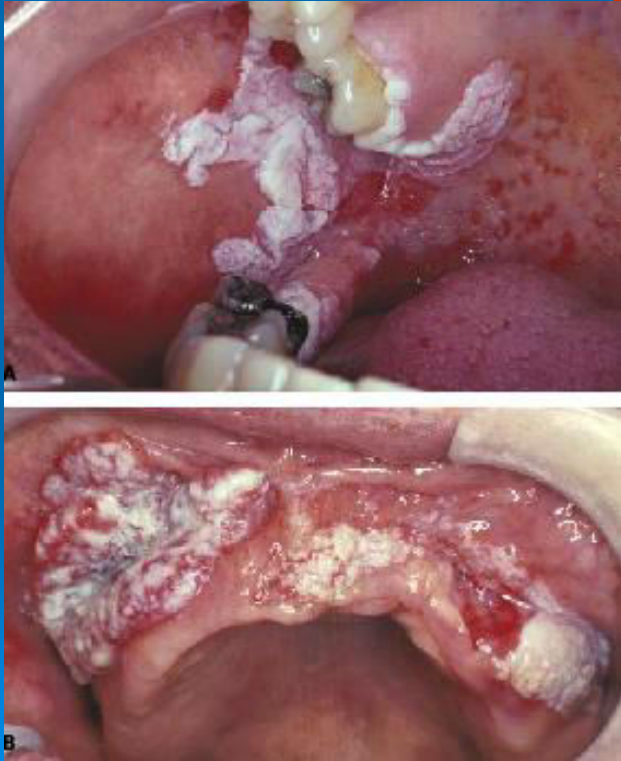


*is a term used to describe the presence of thick white lesions with papillary surfaces in the oral cavity.*

*These lesions are usually heavily keratinized and are most often seen in older adults in the sixth to eighth decades of life.*

*Some of these lesions may exhibit an exophytic growth pattern.*

## **Proliferative verrucous leukoplakia**



The lesions of this special type of leukoplakia have been described as extensive papillary or verrucoid white plaques that tend to slowly involve multiple mucosal sites in the oral cavity and transform into squamous cell carcinomas over a period of many years.

PVL has a very high risk for transformation to dysplasia, squamous cell carcinoma or verrucous carcinoma.

## **Erythroplakia ('Erythroplasia')**

Has been defined as a "bright red velvety plaque or patch which can not be characterized clinically or pathologically as being due to any other condition."

It is uncommon in the mouth but carries the highest risk of malignant transformation and lesions are often already malignant on first biopsy.

*Erythroplakia occurs predominantly in older men, in the sixth and seventh decades of life.*

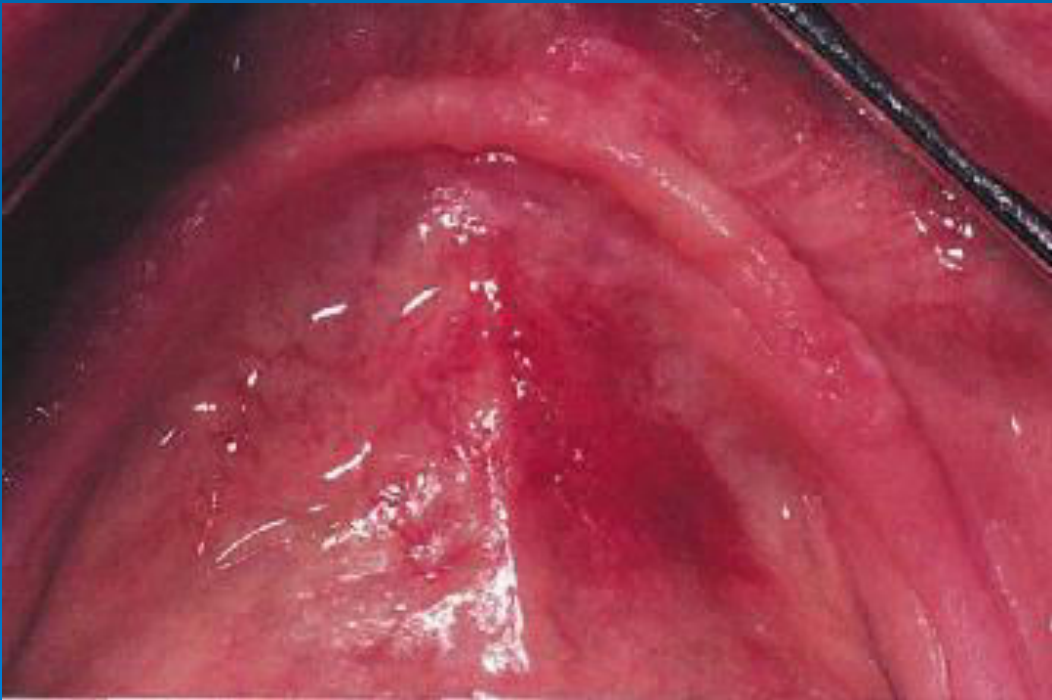*Erythroplakias are more commonly seen on the floor of the mouth  
the ventral tongue  
the soft palate, and  
the tonsillar fauces,*

## ***Clinical Features***

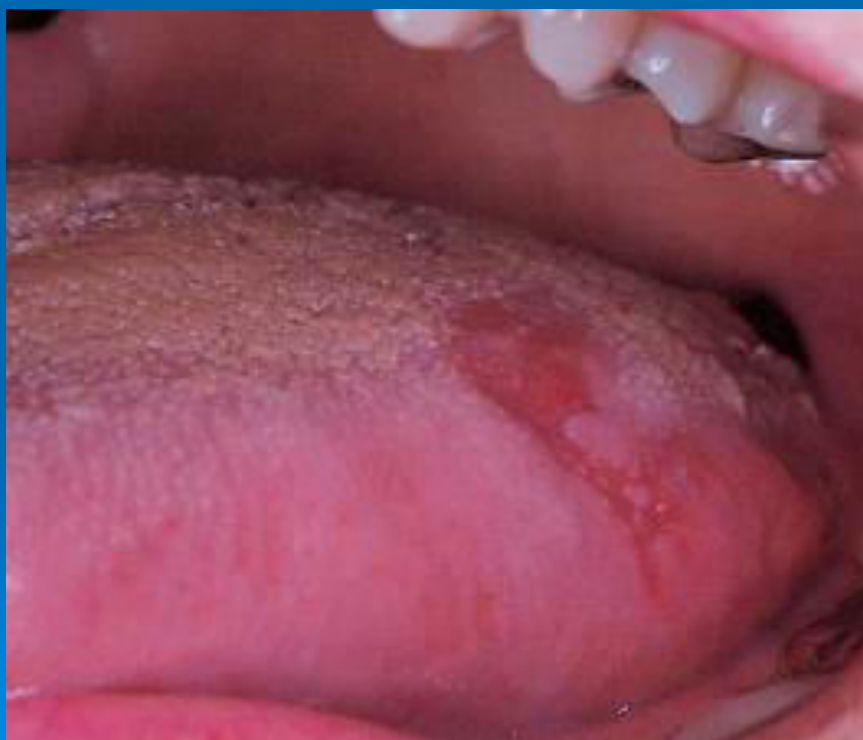*Several clinical variants of erythroplakia have been described,  
but there is no generally accepted classification.*

- 1 Homogeneous erythroplakia*
- 2 Erythroplakia interspersed with patches of leukoplakia •*
- 3 Granular or speckled erythroplakia*

***Erythroplakia ('Erythroplasia')***

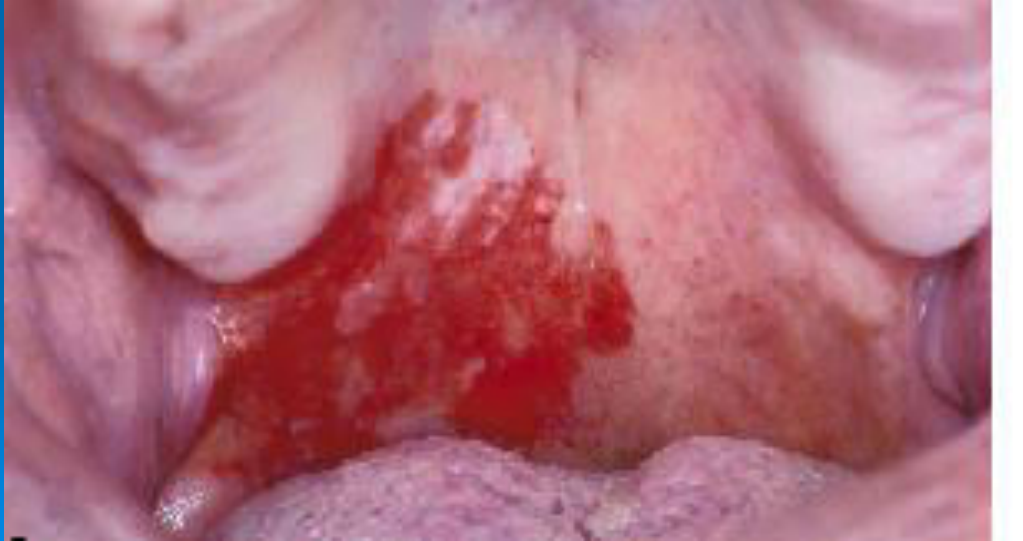

***Erythroplakia ('Erythroplasia')***





## ***Erythroplakia ('Erythroplasia')***



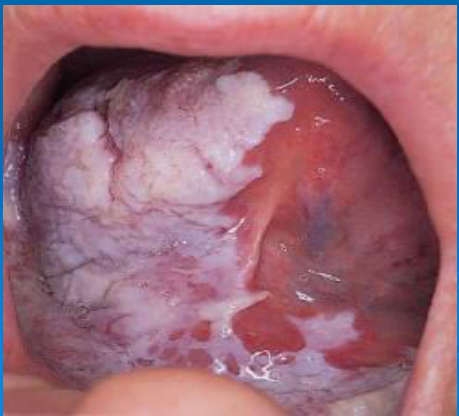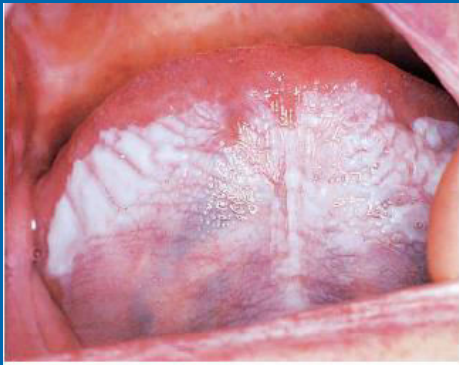## ***Sublingual keratosis***

The term sublingual keratosis is applied to white lesions on the floor of mouth and ventral tongue.

Malignant change was reported in an unusually high proportion of cases (30%) in one series but this has not been widely confirmed.

Probably the risk of malignant transformation is less than 10% and possibly much lower.

## ***Clinical features***



Sublingual keratosis is a ➤ white, soft plaque, usually with a finely wrinkled surface, an irregular but well-defined outline and sometimes bilateral with a butterfly shape. The plaque typically extends from the anterior floor of the mouth to the undersurface of the tongue. There is usually no associated inflammation.

## ***SMOKELESS TOBACCO-RELATED KERATOSES***

Hyperkeratotic mucosal lesions can result from smoking or use of smokeless tobacco.

topical tobacco

snuff-dipping

and tobacco chewing

Tobacco chewing and snuff-dipping (holding flavoured tobacco powder in an oral sulcus) are popular habits in the USA & some part of Europe.



# SMOKELESS TOBACCO-RELATED KERATOSES



## *Tobacco chewing*



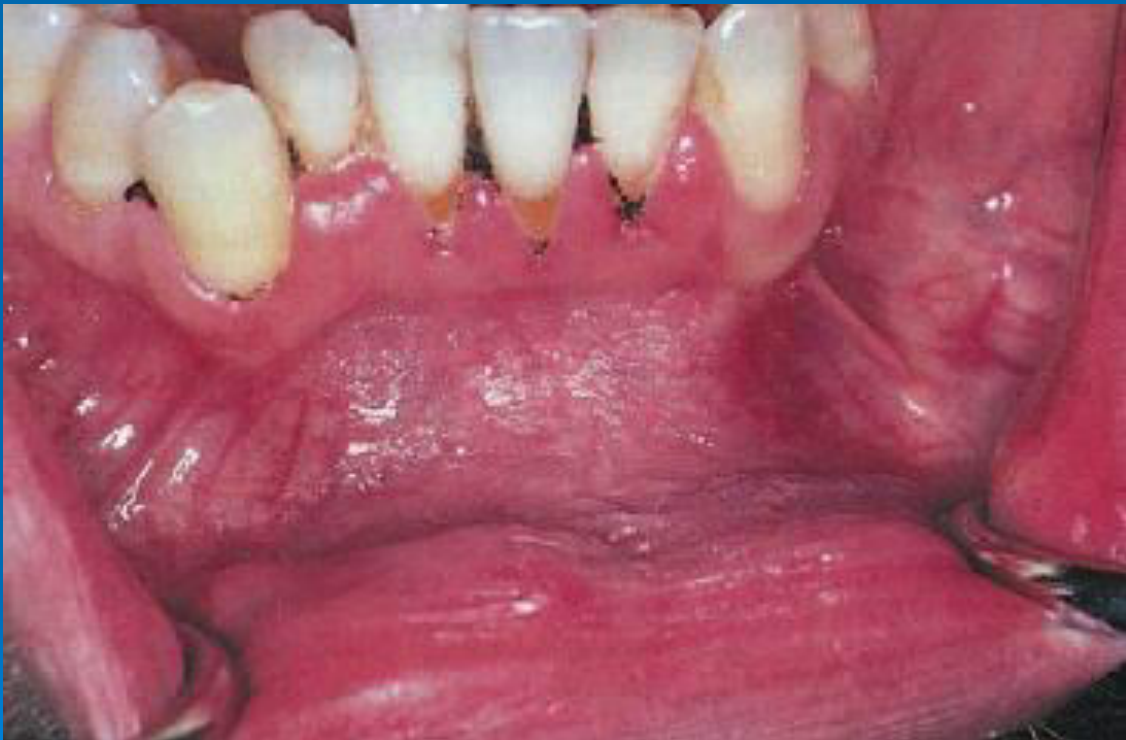## *Clinical features*

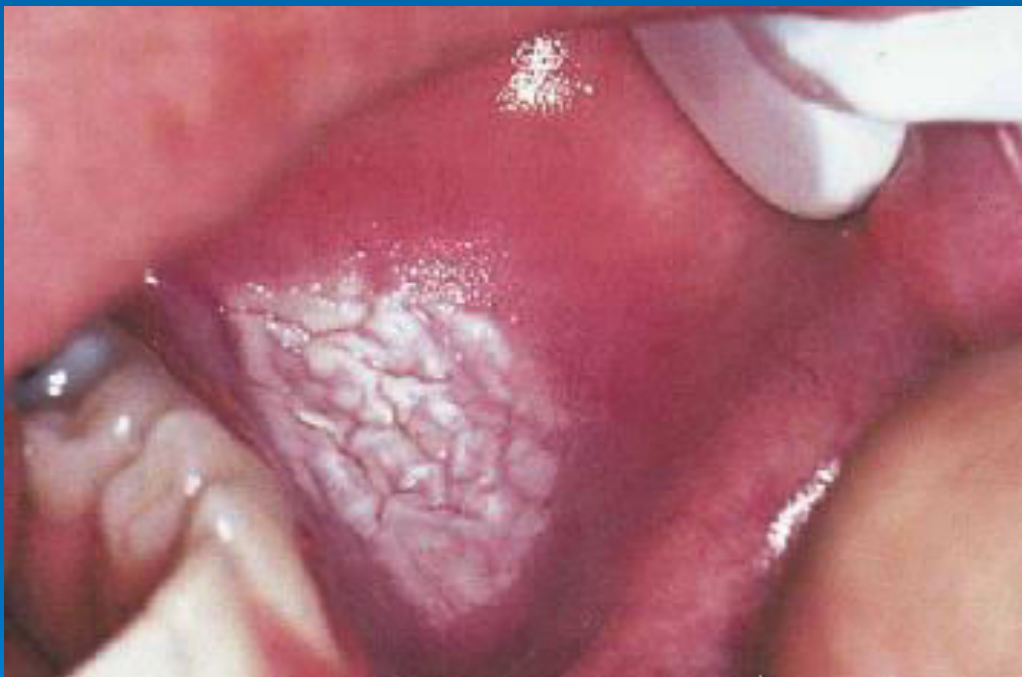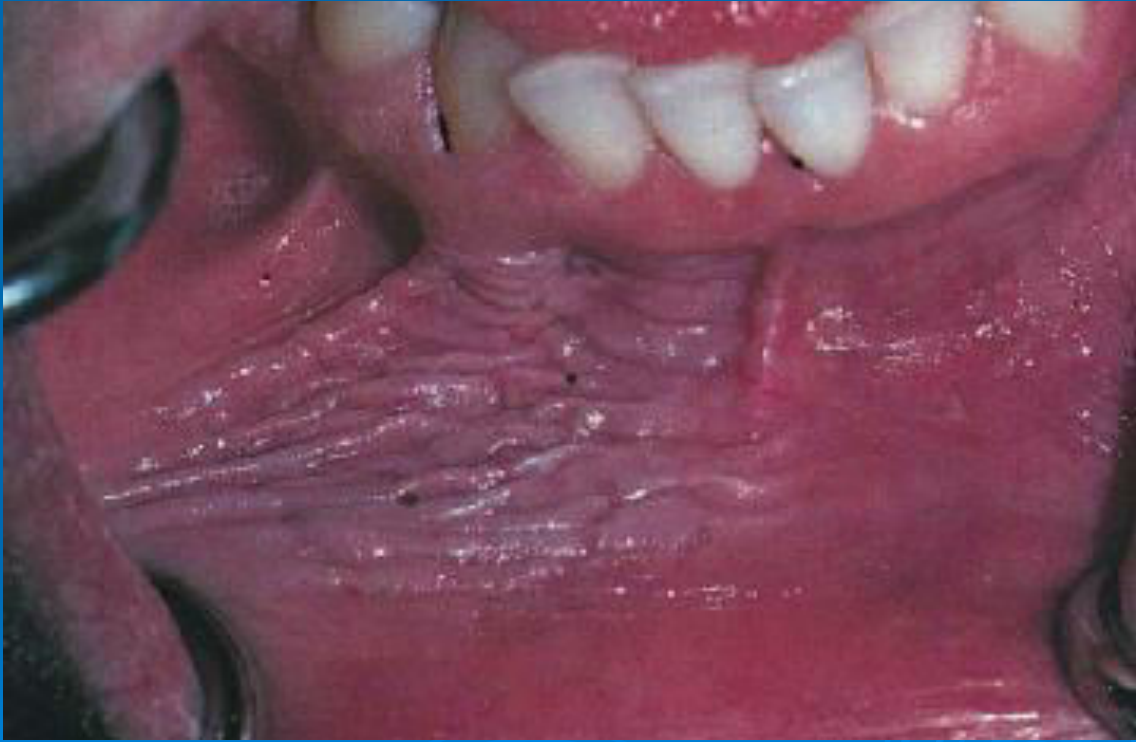*The habit of snuff-dipping or tobacco-chewing may be maintained for decades and gives rise to keratoses in the buccal or labial sulcus, where the tobacco is held.*

*Early changes are erythema and mild, whitish thickening.*

*Long-term use gives rise to extensive white thickening and wrinkling of the buccal mucosa.*

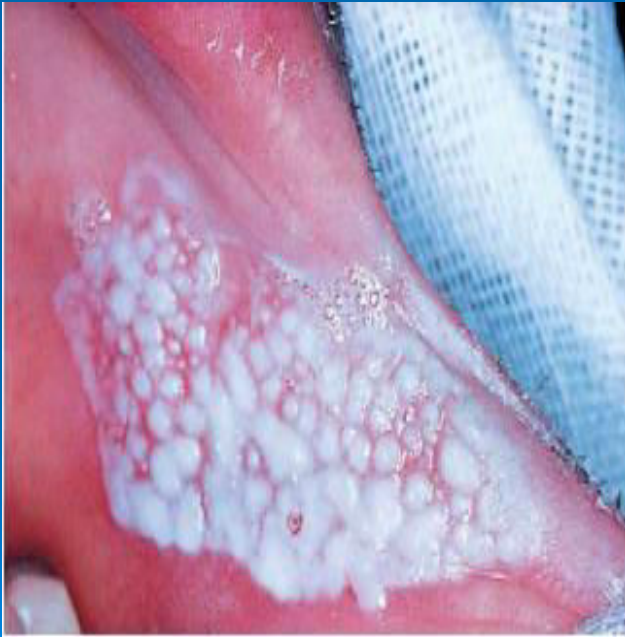*Malignant change can follow, but only after several decades of use. A high proportion of carcinomas in snuff users are verrucous in type but if they remain untreated invasive squamous carcinoma may develop.*







## **CHRONIC HYPERPLASTIC CANDIDOSIS (CANDIDAL LEUKOPLAKIA)**



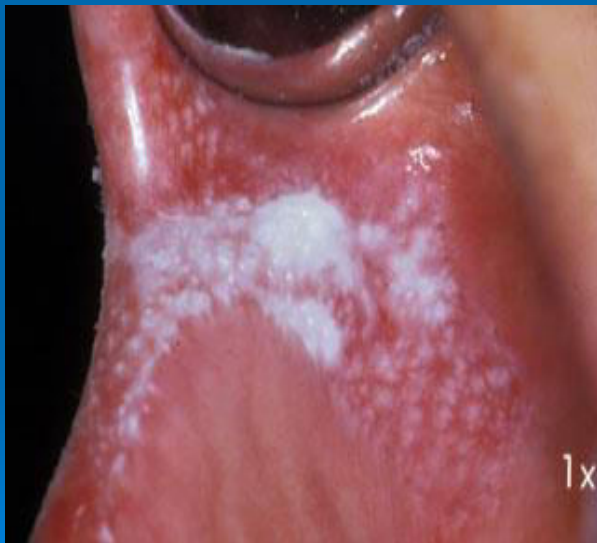*Chronic oral candidosis produces a tough adherent plaque, distinguishable only by biopsy from other leukoplakias.*

*Adults, typically males of middle age or over, are affected.*

*The usual sites are the dorsum of the tongue and the post-commissural buccal mucosa.*

*The plaque is variable in thickness and often rough or irregular in texture, or nodular with an erythematous background (speckled).*

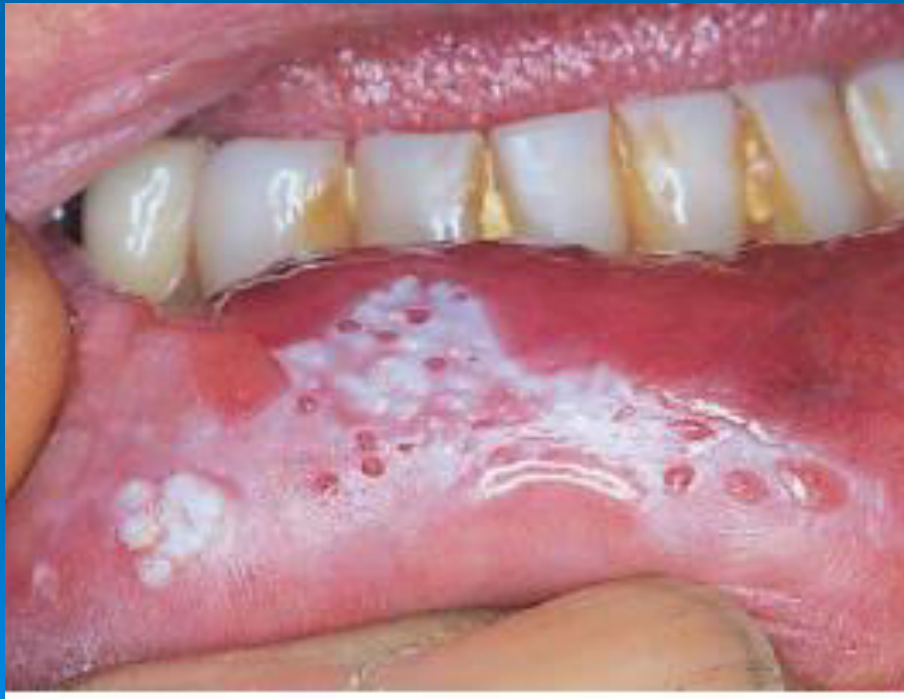## **CANDIDAL LEUKOPLAKIA**



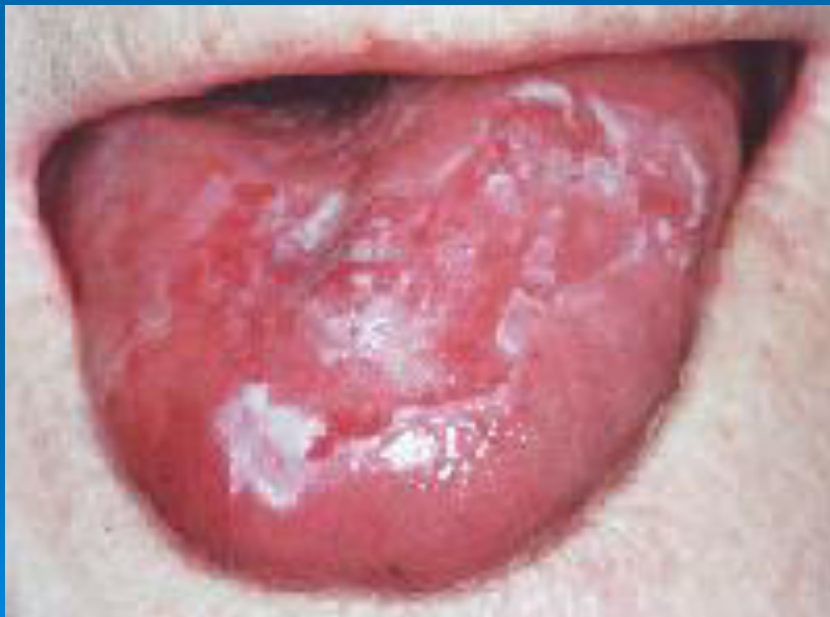*Angular stomatitis ➤ may be associated with this lesion*

*& sometimes ➤ continuous with intra-oral plaques which suggests the candidal nature of the lesion.*

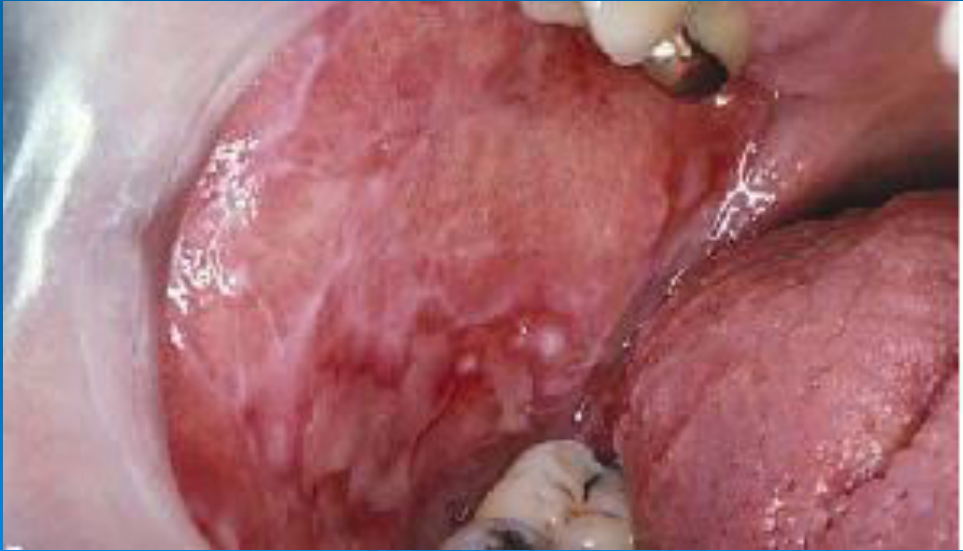**CHRONIC HYPERPLASTIC CANDIDOSIS  
(CANDIDAL LEUKOPLAKIA)**



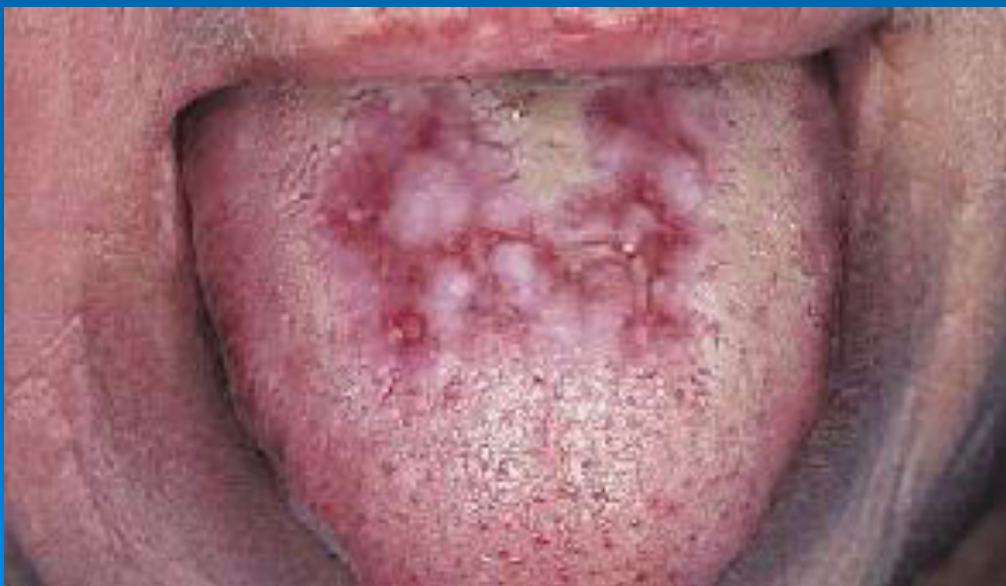**SYPHILITIC LEUKOPLAKIA**



***EROSIVE LICHEN PLANUS***

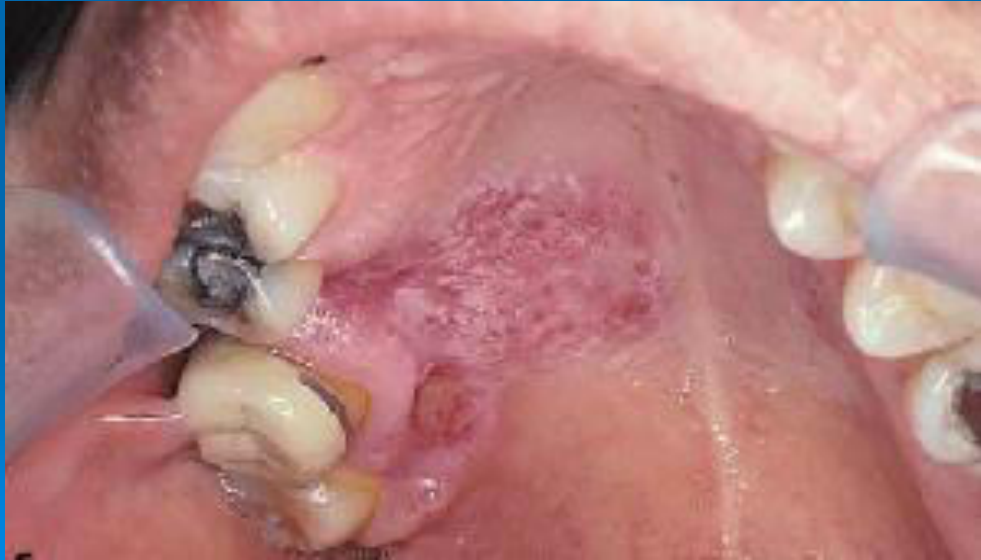

***EROSIVE LICHEN PLANUS***

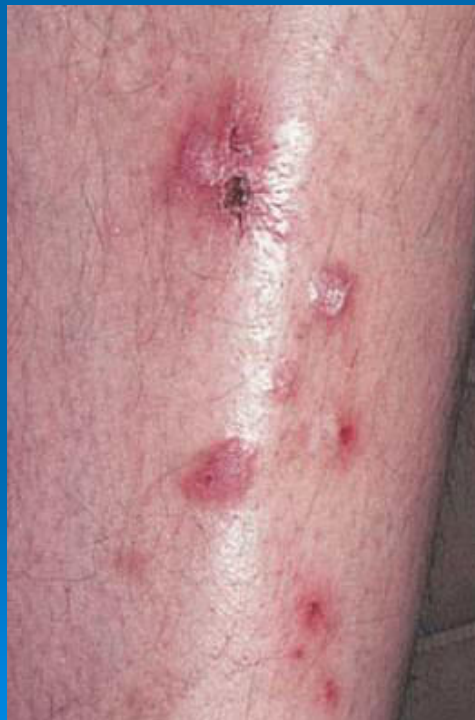



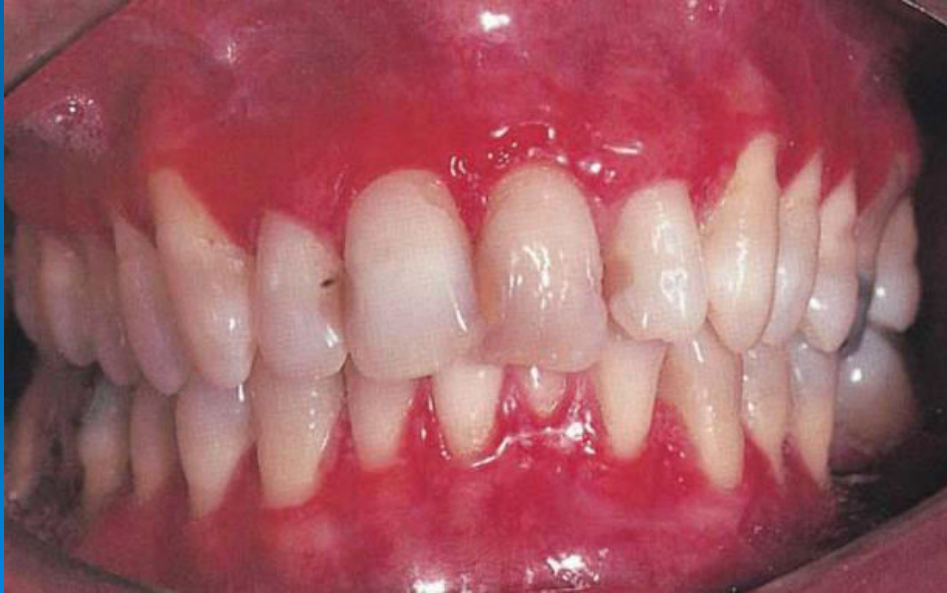## ***EROSIVE LICHEN PLANUS***



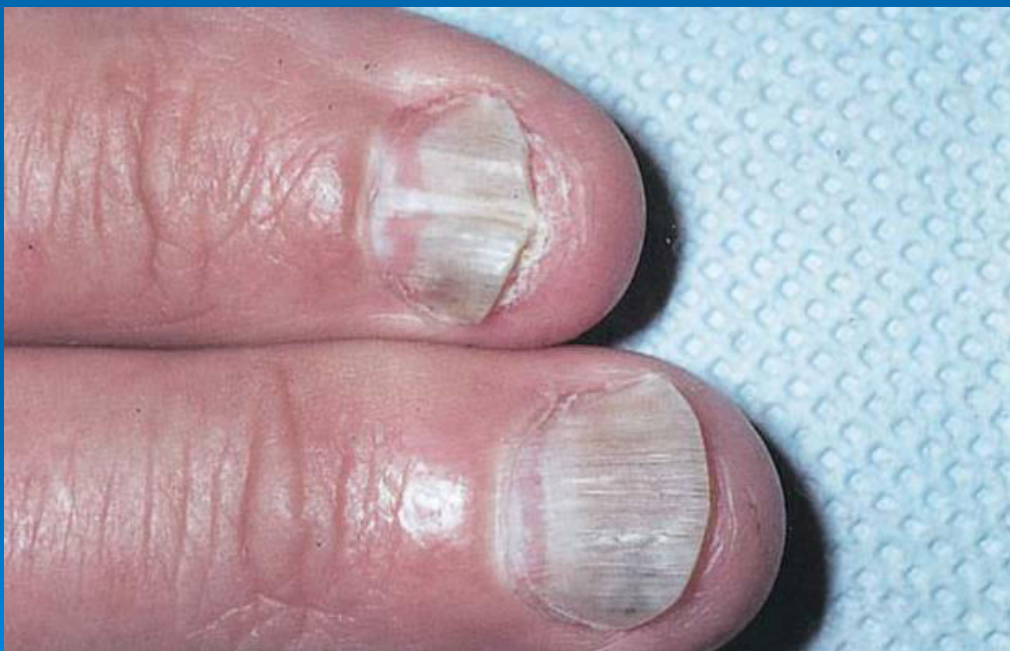## ***Hypertrophic lesions on the skin***



*Red erosive gingival lesions  
( Desquamative lesion )*



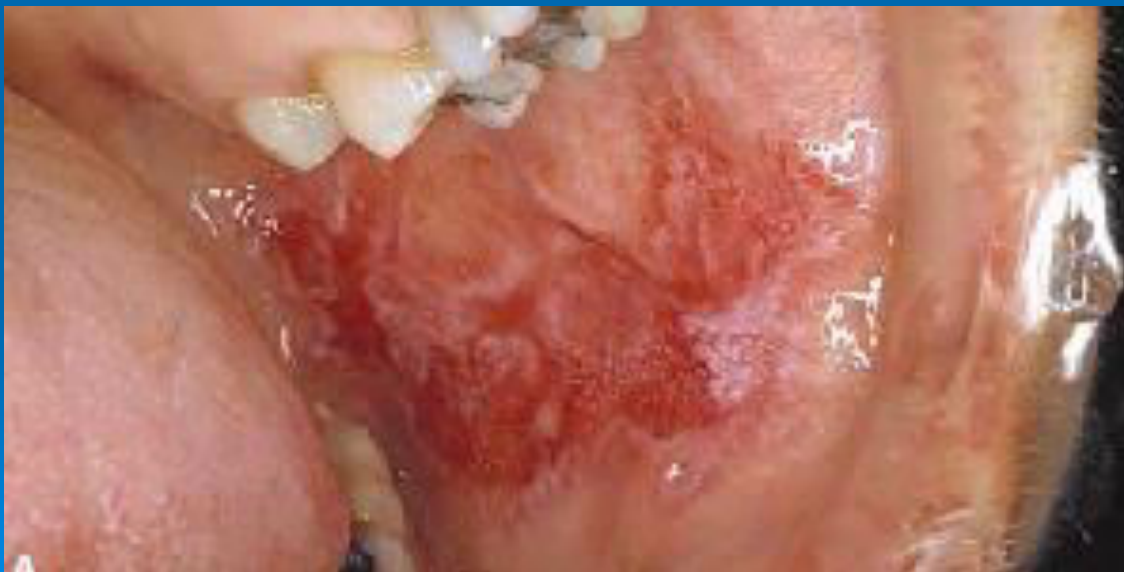*Nail involvement*



## Discoid lupus erythematosus (DLE)

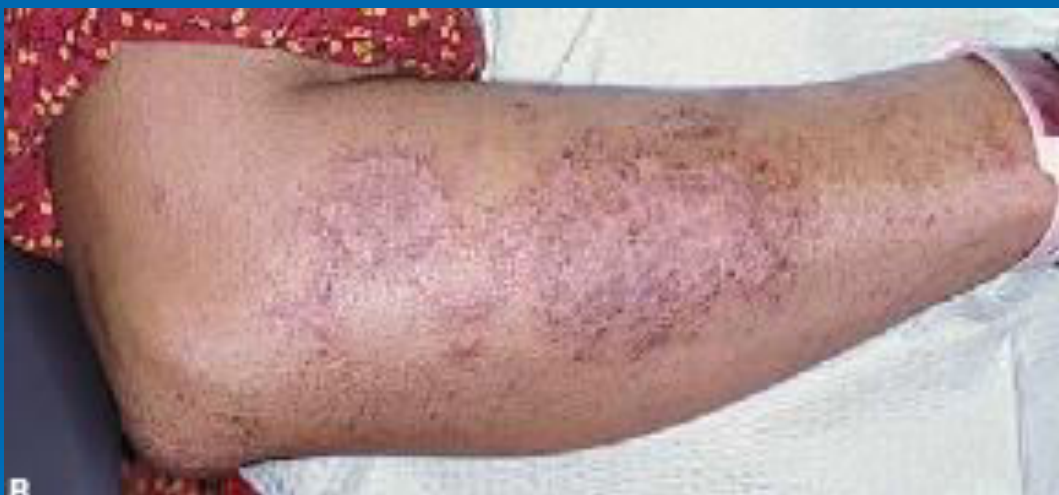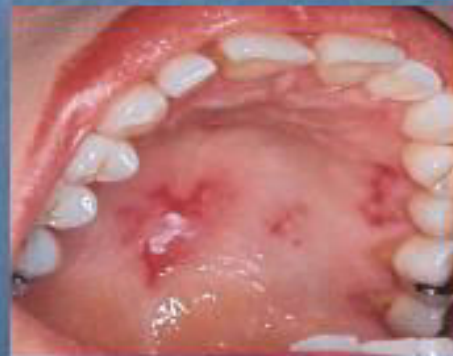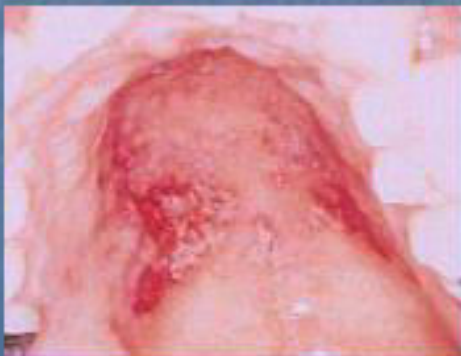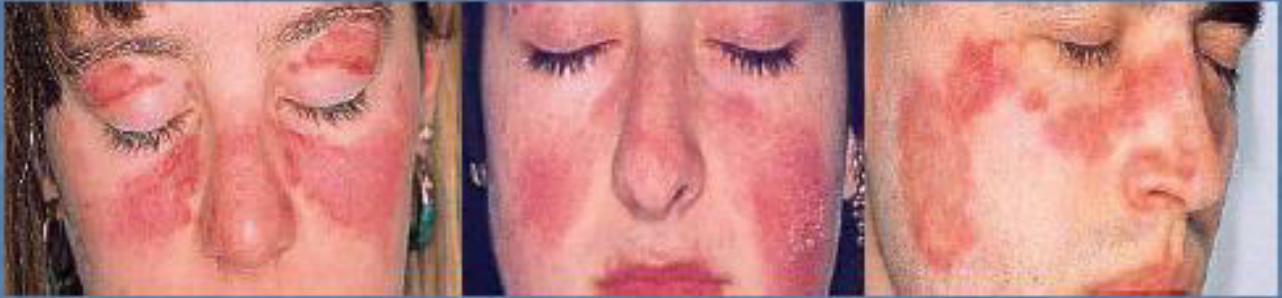is a relatively common disease and occurs predominantly in females in the third or fourth decade of life.

### *LUPUS ERYTHEMATOSUS*





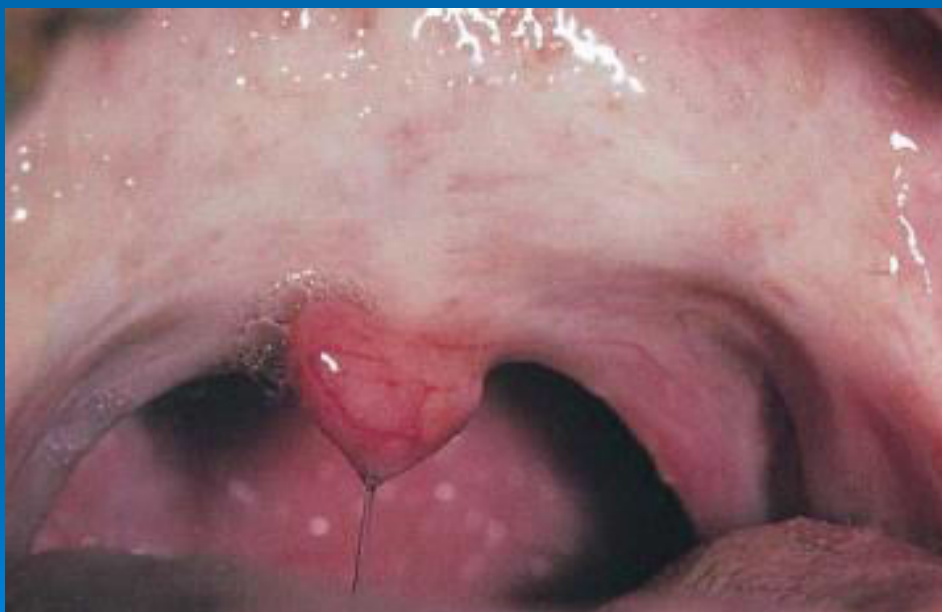
# Systemic Lupus Erythematosus



## *Oral submucous fibrosis (OSF)*

is a slowly progressive chronic fibrotic disease of the oral cavity and oropharynx, characterized by fibroelastic change and inflammation of the mucosa, leading to a progressive inability to open the mouth, swallow, or speak.

## ***ORAL SUBMUCOUS FIBROSIS***



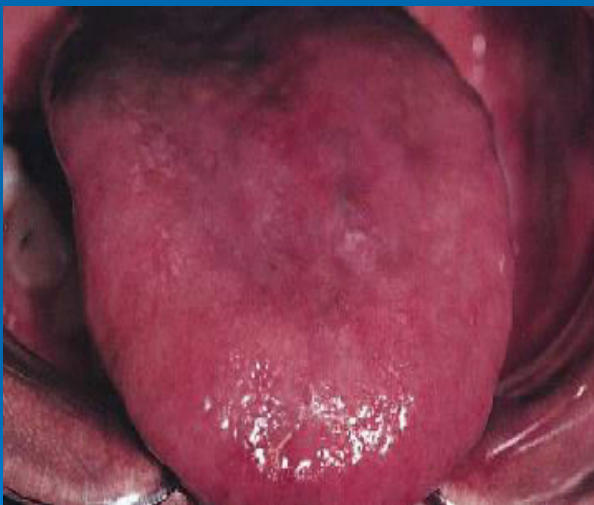# Sideropenic Dysphagia

( Paterson-Kelly or Plummer- Vinson syndrome )

A disorder caused by iron deficiency anemia, and associated with a web-like growth of membranes in the throat that makes swallowing difficult.

Having sideropenic dysphagia may increase the risk of developing esophageal & oral cancer.

# Sideropenic Dysphagia



## ***Clinical Features:-***

Iron deficiency anemia

Stomatitis

Glossitis

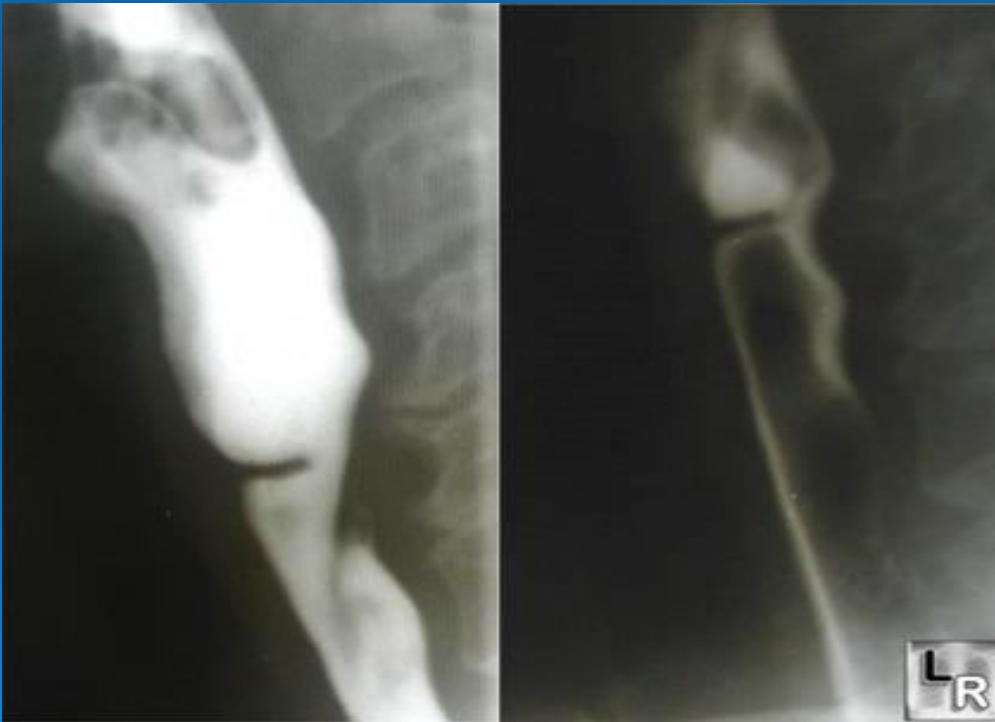Dysphagia

Spoon-shaped nails

Esophageal webs



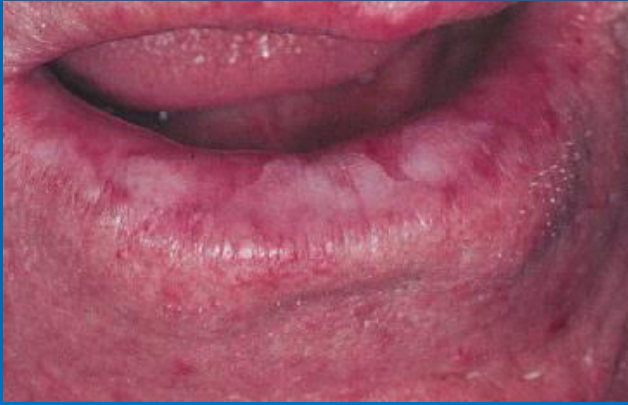## Esophageal webs



## *Actinic cheilosis*

is a clinical lesion of the lower lip caused by excessive solar radiation damage.

## Actinic cheilosis



In early stages, the lower lip is mildly keratotic

## Actinic cheilosis



With increased exposure to the sun, focal white zones that have distinct or diffuse borders become apparent.

## Actinic cheilosis

The lip slowly becomes

Firm

Scaly

Slightly swollen

Fissured

Everted

Ulcerated with encrustation is typical of the chronic condition.

The ulcers may be an early sign of carcinomatous transformation.

## Dyskeratosis congenita

A rare heritable recessive or dominant trait.

The main features are:-

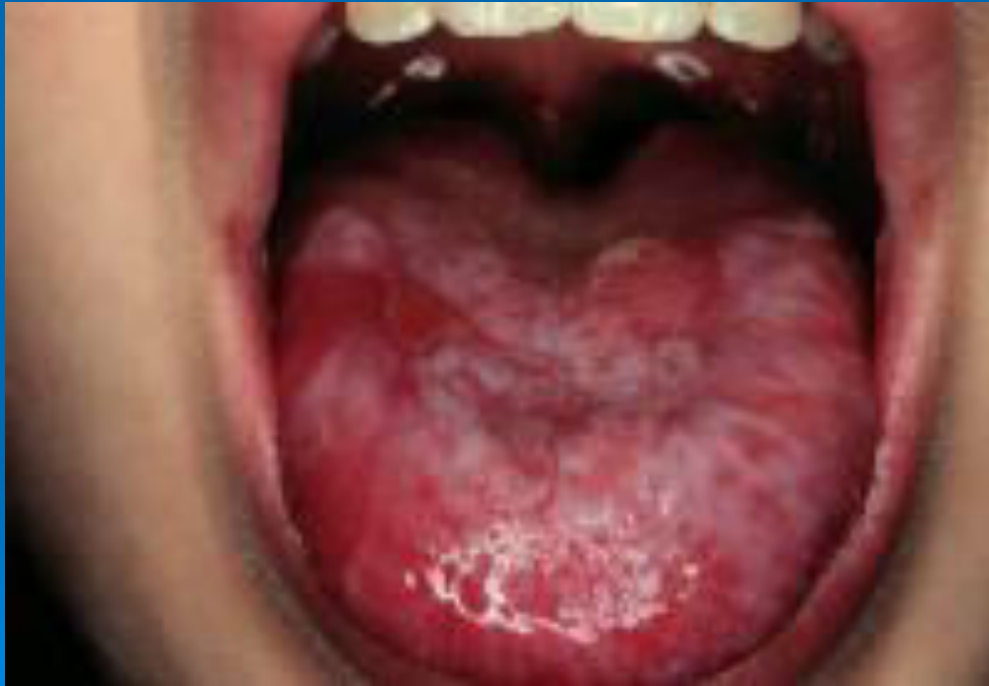Dysplastic white or red lesions of the oral mucosa.

Cutaneous pigmentation.

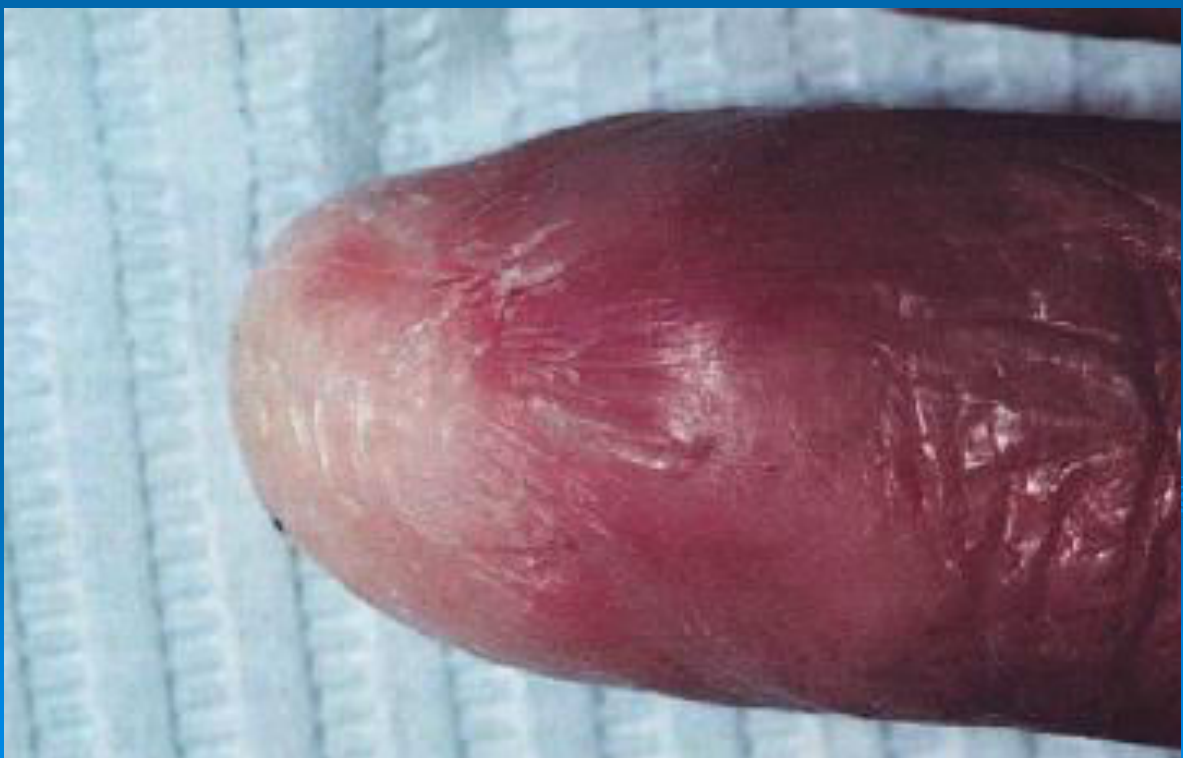Dystrophies of the nails.

Haematological abnormalities.

**DYSKERATOSIS CONGENITA**



**DYSKERATOSIS CONGENITA**



# Xeroderma pigmentosum

A rare autosomal recessive inherited disorder.

It's precancerous nature is strongly marked by basal or squamous cell carcinoma.

Lips & oral cavity also may be involved in the carcinomas changes.

# Dystrophic epidermolysis bullosa

It is a mechanobullos disease characterized by bullae formation which rapidly break down to form erosion or ulceration.

Healing ulcer associated with oral carcinomas.

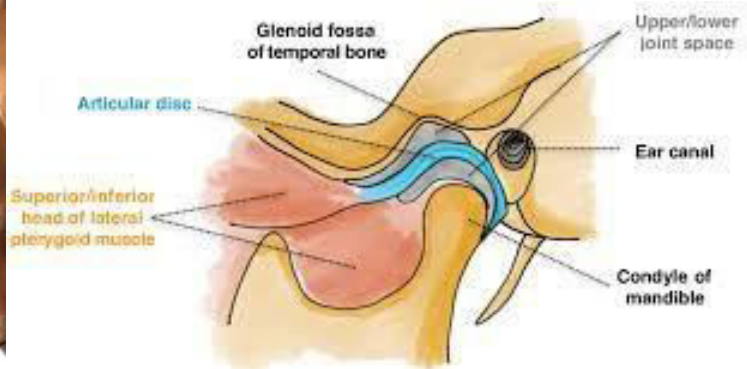
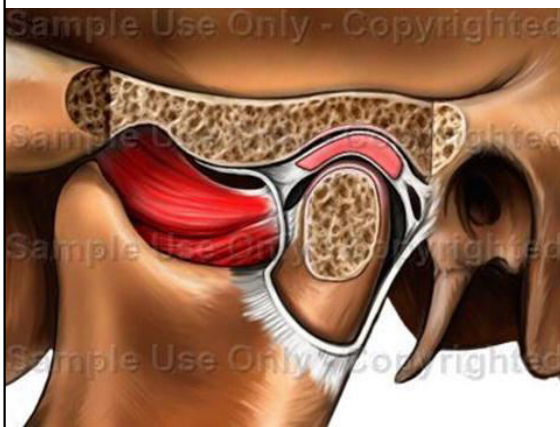
# Suspicious clinical features of a malignant conditions

- 1- persistent ulceration
- 2- indurations
- 3- proliferative growth of tissue
- 4- changes in surface in texture & colour
- 5- fixation to the underlying structures
- 6- lymph node involvement
- 7- sudden loosening of teeth
- 8- pain - a late feature



# Disorders of TMJ

The TMJ is diarthroidal articulation between the condyle of the mandible & the squamous portion of the temporal bone .



## Anatomic features

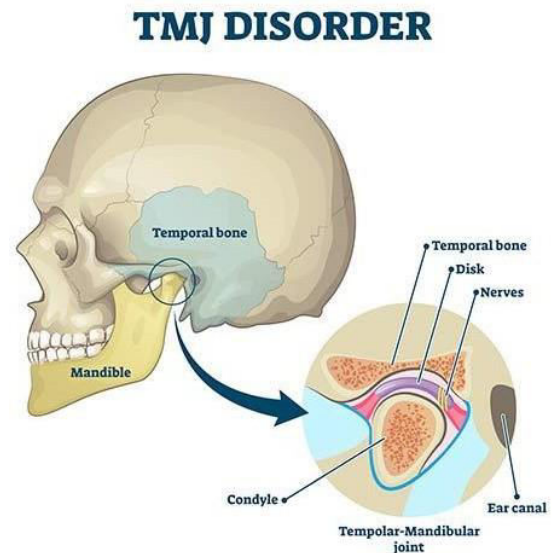
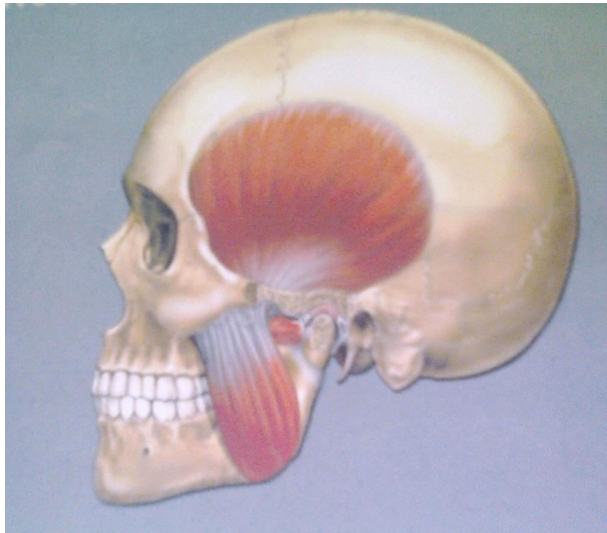
1. The articulating surface is covered by avascular fibrous tissue, with small number of chondrocytes so it is designated as fibro-Cartilaginous.

2. The articulating surface of bone are complex which carry teeth where their shape and position determine the movement of mandible, whereas other joints connected with muscles and ligament only.

3. It has bilateral articulation with the cranium so there are right and left joints acting as one unit.

4. The joint is considered as complex because each joint has an articulating disk between the glenoid fossa and condyle that divides the joint into two compartments, upper and lower.

## Lateral aspect of the TMJ :



## Lateral aspect of the TMJ :

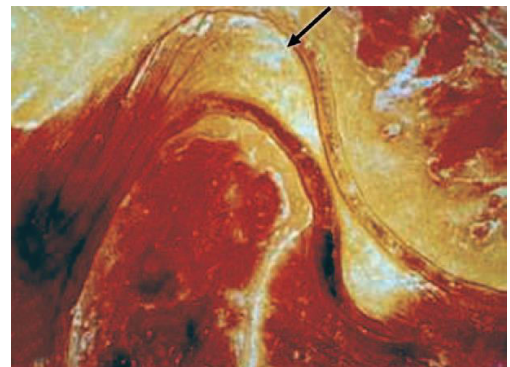### Glenoid Fossa:

The mandibular condyle articulates at the base of the cranium with the squamous portion of the temporal bone. This is called as the glenoid fossa.

### Articular Disc :

It is composed of dense fibrous connective tissue devoid of any blood vessels or nerve fibers.

In the sagittal plane, it can be divided into three regions according to thickness. The central area is the thinnest and is called as intermediate zone. Both anterior and posterior to the intermediate zone, the disc becomes considerably thicker. The posterior border is generally slightly thicker than the anterior border

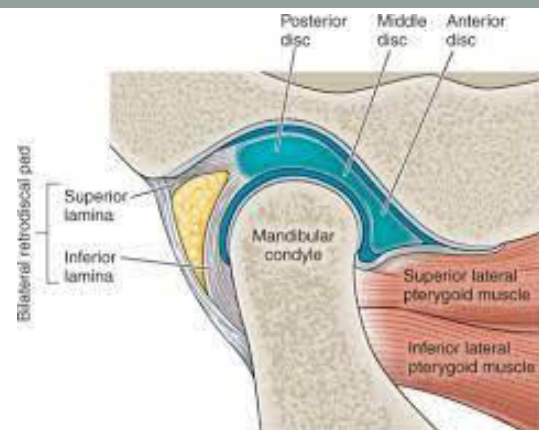
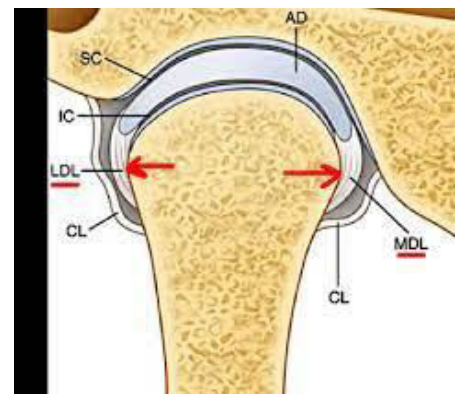
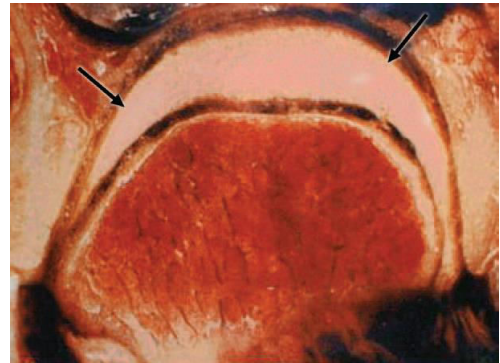


## Anterior view:

From the anterior view, the disc is generally thicker medially than laterally. The precise shape of the disc is determined by the morphology of the condyle and mandibular fossa .

The articular disc is attached to the condyle by TMJ ligament.

This divides the joint into two distinct cavities ; the upper or superior cavity which is bordered by the glenoid fossa and superior surface of the disc and the lower or inferior cavity, which is bordered by the mandibular condyle and inferior surface of the disc.

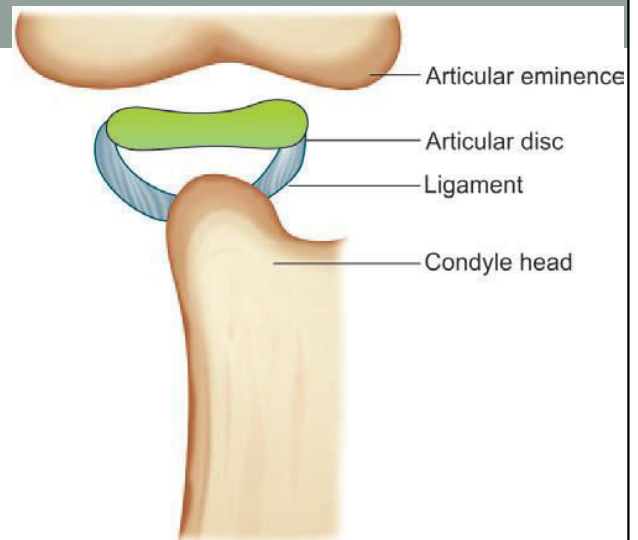
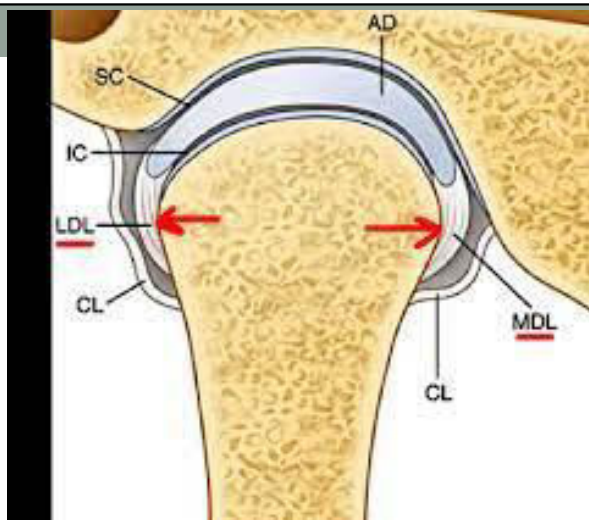


Source: Pamela K. Levinge, Cynthia C. Norkin, Michael D. Lewak. Joint Structure & Function: A Comprehensive Analysis, 6th Ed. Copyright © F. A. Davis Company. All right reserved.

## Retro-discal tissue and lamina:

**Loose connective tissue** occupies the space behind the disc and condyle. It is often referred to as the **posterior attachment or retro-discal tissue**. The posterior attachment is a loosely organized system of **collagen fibers, branching elastic fibers, fat, blood and lymph vessels, and nerves**. Synovium covers the superior and inferior surfaces. The attachment has been described as being arranged in two lamina of dense connective tissue. Both superior and inferior lamina arise from the posterior band of the disc. The superior lamina attaches to the squamo-tympanic fissure and tympanic part of the temporal bone and consists primarily of elastin. The inferior lamina inserts into the inferior margin of the posterior articular slope of the condyle and is composed mostly of collagen fibers.

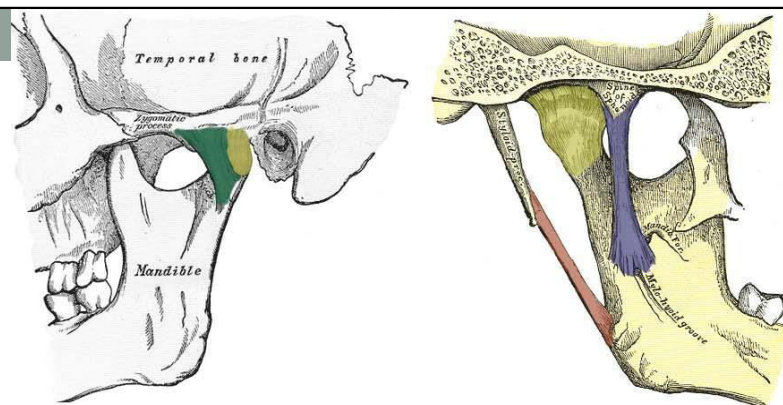




## Ligamentous Structures:

### Collateral ligaments

The collateral ligaments attach the medial and lateral borders of the articular disc to the poles of the condyle. It is commonly called as discal ligament and are two in number. The medial one attaches the medial edge of the disc to the medial pole of the condyle and the lateral one, attaches to the lateral edge of the disc to the lateral pole of the condyle. Their function is to restrict the movement of the disc away from the condyle, as it glides anteriorly and posteriorly.



- Joint Capsule
- Lateral ligament
- Sphenomandibular ligament
- Stylomandibular ligament

© teachmeanatomy  
The #1 Applied Human Anatomy Site on the Web.

## Ligamentous Structures:

### Capsular ligament :

The entire TMJ is surrounded and encompassed by the capsular ligament. The fibres of the capsular ligament are attached superiorly to the temporal bone, along the border of the articular surface of the mandibular fossa and articular eminence. Inferiorly, the fibres are attached to the neck of the condyle. The internal surface of the cavity is surrounded by specialized endothelial cells that form the synovial lining. This lining along with a specialized synovial lining located at the anterior border of the retro-discal tissue produce the synovial fluid, which fills both the joint cavities. Thus, TMJ is referred to as a synovial joint.

It acts to resist any medial, lateral or inferior forces that tend to separate or dislocate the articular surface. Another function is to encompass the joint, thus retaining the synovial fluid.

- ❑ **Temporomandibular ligament** :It is also called as lateral ligament as it is located laterally to the joint. It is composed of two parts, an **outer oblique portion and an inner horizontal portion**. **The outer portion** extends from the outer surface of the articular tubercle and zygomatic process, poster inferiorly to the outer surface of the condylar neck. **The inner horizontal portion** extends from the outer surface of the articular tubercle and zygomatic process posteriorly and horizontally to the lateral pole of the condyle and posterior part of the articular disc. The oblique portion of the ligament resists excessive dropping of the condyle and therefore, acts to limit the extent of mouth opening.
- ❑ **Sphenomandibular ligament**: It is attached to the spine of the sphenoid bone and extends downwards and laterally to the small bony prominence on the medial surface of the ramus of the mandible, called the lingula. It does not have any significant effect on mandibular movement.
- ❑ **Stylomandibular ligament**: It arises from the styloid process and extends downward and forward to the angle and posterior border of the ramus of the mandible. It becomes taut when mandible is protruded but is most relaxed when the mandible is opened. Its function is to limit the excessive protrusive movements of mandible .
- ❑ **Mandibular malleolar ligament**: Actually, the mandibular malleolar ligament consists of fibro elastic tissue with some ligamentous qualities. It originates from the neck and anterior process of malleus and is inserted on the medioposterior and superior part of the capsule , interarticular disc and Sphenomandibular ligament.

## **Vascular supply:**

At the level of the mandibular condylar neck, the **external carotid** bifurcates into the

**Superficial Temporal Artery**

**Internal Maxillary Artery.**

These two arteries supply the **muscles of mastication and the TMJ**.

Arteries within the temporal bone and mandible also send branches to the **capsule**.

## **Nerve supply:**

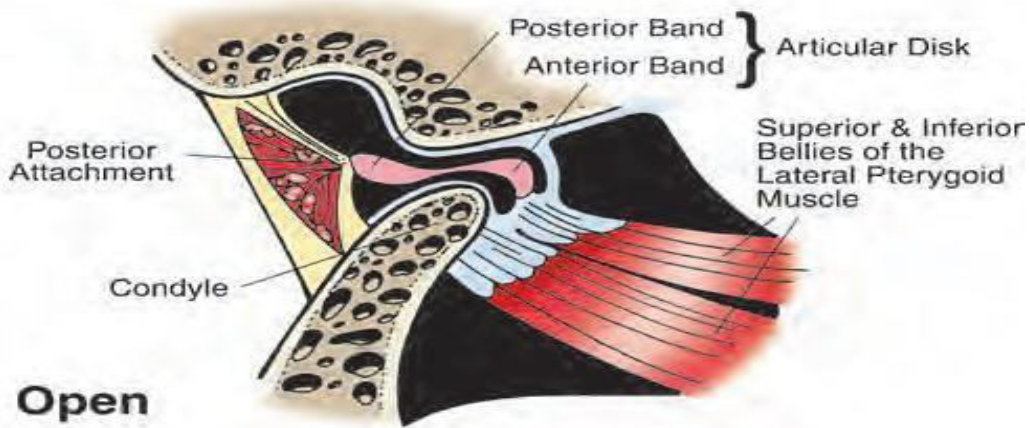
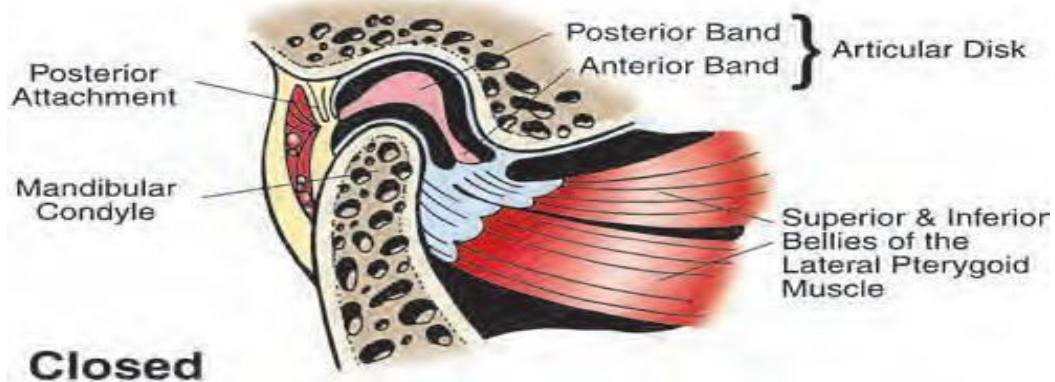
It is innervated by the branches of

**Auriculotemporal Nerve,**

**Masseteric Nerve**

**Posterior Deep Temporal Nerve,**

which are branches of the **mandibular portion of the trigeminal nerve**.



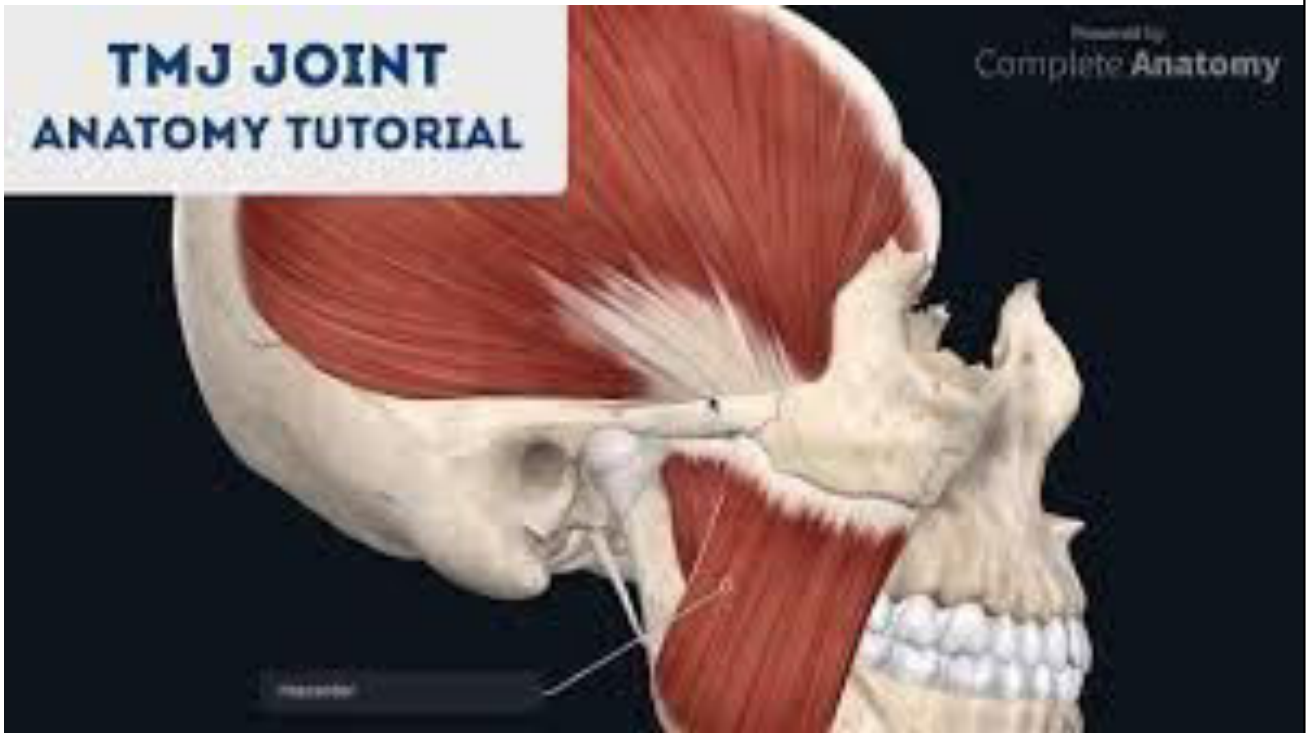## Muscles of mastication

Muscle	Origin	Insertion	Function
Temporalis	Temporal lines	Coronoid process	Closing, retrusion
Masseter	Inferior border of zygomatic arch	Angle of mandible laterally	Closing, strongest muscle in body
M. Pterygoid	Medial surface of lateral pterygoid plate	Angle of mandible medially	Closing
L. Pterygoid	lateral surface of lateral pterygoid plate	Condylar neck and disc	Opening, lateral movement



## TMJ JOINT ANATOMY TUTORIAL

Presented by  
Complete Anatomy



### Functional Movement of TMJ

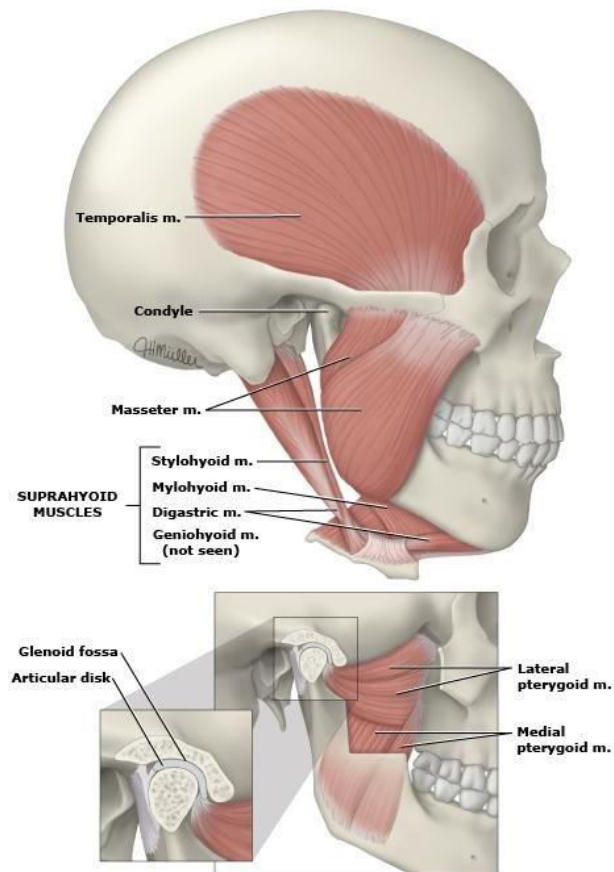
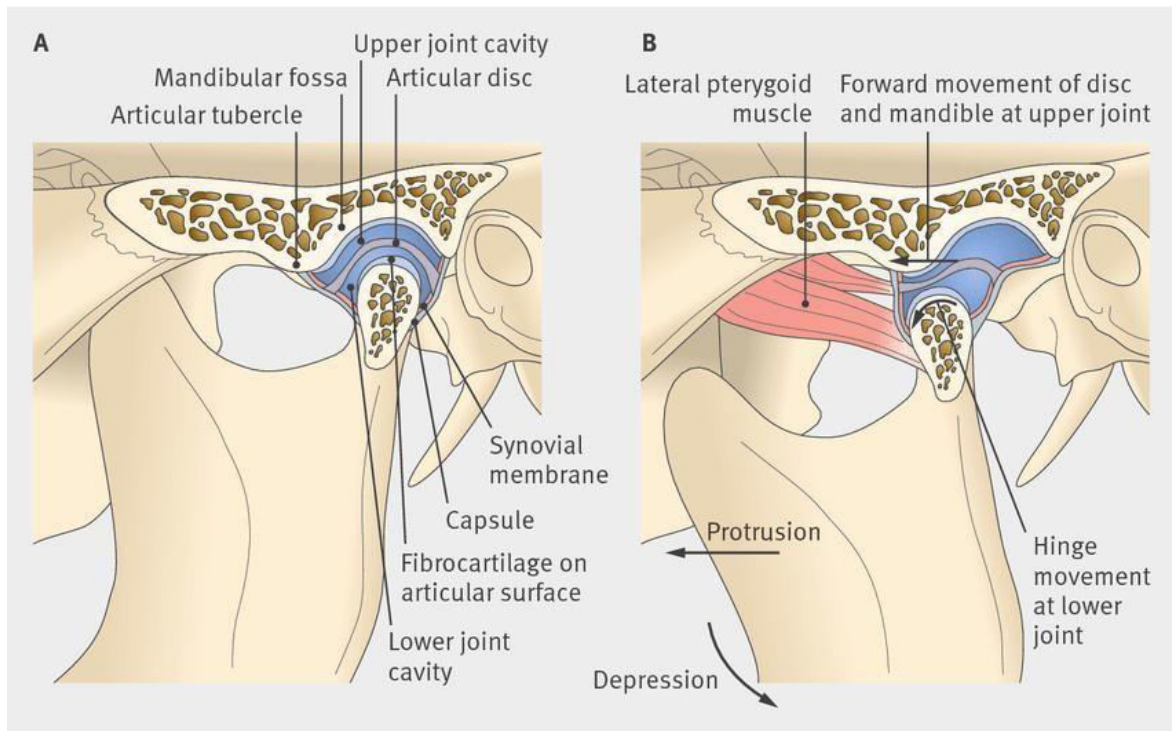
**Elevation (jaw closing):** The mandibular elevators include the coordinated functions of masseter, temporal and medial pterygoid muscle of both the sides. Temporalis maintains the physiological rest position of the mandible. The posterior fibers of temporalis retract the head of mandible while closing the mouth.

**Depression:** The depression of mandible includes the activity of the lateral pterygoid and the suprahyoid muscles. The inferior head of the lateral pterygoid is the main muscle used for depressing the mandible. The superior head of the lateral pterygoid pulls the articular disc forward, creating the glenoid joint activity. The suprahyoid group of muscles also acts in mandibular movement; by initiating and assisting opening of the jaw. The lateral pterygoid muscle has a major role, particularly when the mouth is opened wide or against resistance by the digastric, geniohyoid and mylohyoid muscle. The infrahyoid group of muscles participates in the activity by fixing the hyoid group to exert a downward pull on the mandible.

**Protrusion:** It is performed by the medial and lateral pterygoid muscle of both the sides

**Retrusion :** It is performed by the posterior fibers of temporalis .

**Lateral excursive movements:** In this type of movement ,the medial pterygoid and lateral pterygoid of each side, act alternately. If the mandible is moved to the right side the medial pterygoid of right side and the lateral pterygoid of left side act simultaneously



## Capsular ligament

### Discal ligament

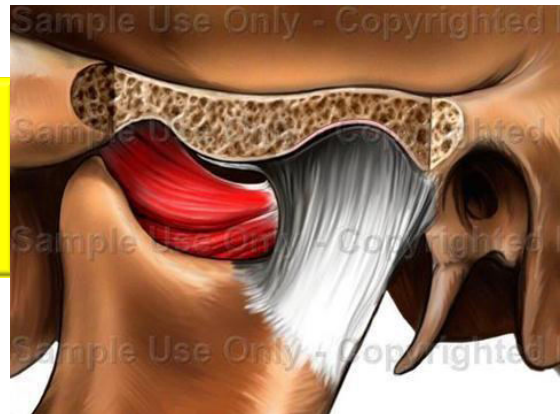
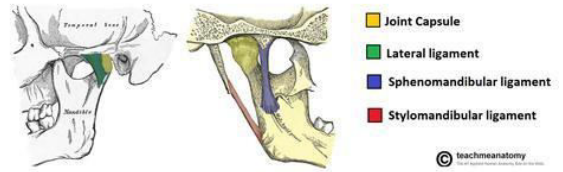
**Medial**  
**Lateral**

### Temporomandibular ligament

**Outer ----oblique**  
**Inner----- horizontal**

### Accessory ligament

**A- Spheno-mandibular ligament**  
**B- Stylo-mandibular ligament**  
**C- Mandibular malleolar ligament.**



## **Diseases of TMJ:**

**A- Intracapsular disorders**

**B-Extracapsular disorders**

## A- Intracapsular disorders

### 1. Developmental:

**Agensis**

**Hyperplasia**

**Hypoplasia**

#### Sign and symptoms

**A. Limitation of opening and pain as ....in hyperplasia.**

**B. Freedom of eccentric movement (excursion) as ....in hypoplasia.**

**C. Anterior open bite and inability to close to ...In agensis of the condyle.**

**D.Asymmetry of the face & deviation during opening.**

**Dx:**

**is confirmed by x-ray**

**Rx:**

**Surgical**

### 2. Infectious diseases:

**As in bacterial infection, these diseases are not common**

#### **Sign and symptoms**

**A.Signs inflammation (hotness, redness, swelling, pain , loss of function)**

**B.Deviation of mandible during opening due to swelling and to overcome pain**

**C. Clicking of joints**

**Dx:**

**History,**

**Clinical examination,**

**Culture and sensitivity**

**Rx:**

**antibiotics**

### 3. Traumatic disorders

**Subluxation**

**Luxation,**

**Ankylosis,**

**Injury to articulating disc**

**Fracture of the condyle**

#### Subluxation

is anterior positioning of head of condyle to articular eminence and patient can retrude the mandible to its physiological position

)

### 3. Traumatic disorders

#### **b. Dislocation:**

Anterior positioning of the head of condyle to the articular eminence, but the patient cannot return the mandible to its physiological position

**Unilaterally Or Bilaterally.**

#### Sign and symptoms:

False class III, Pretragus notch, Drooling of saliva, Improper speech, Hard lock, Malocclusion, Pain.

#### Rx:

1. Muscle relaxant and analgesics

2. Repositioning of the condyle (reduction)

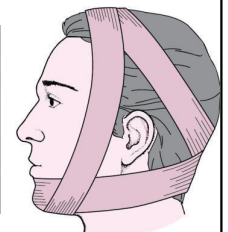

Bandage is applied around the head

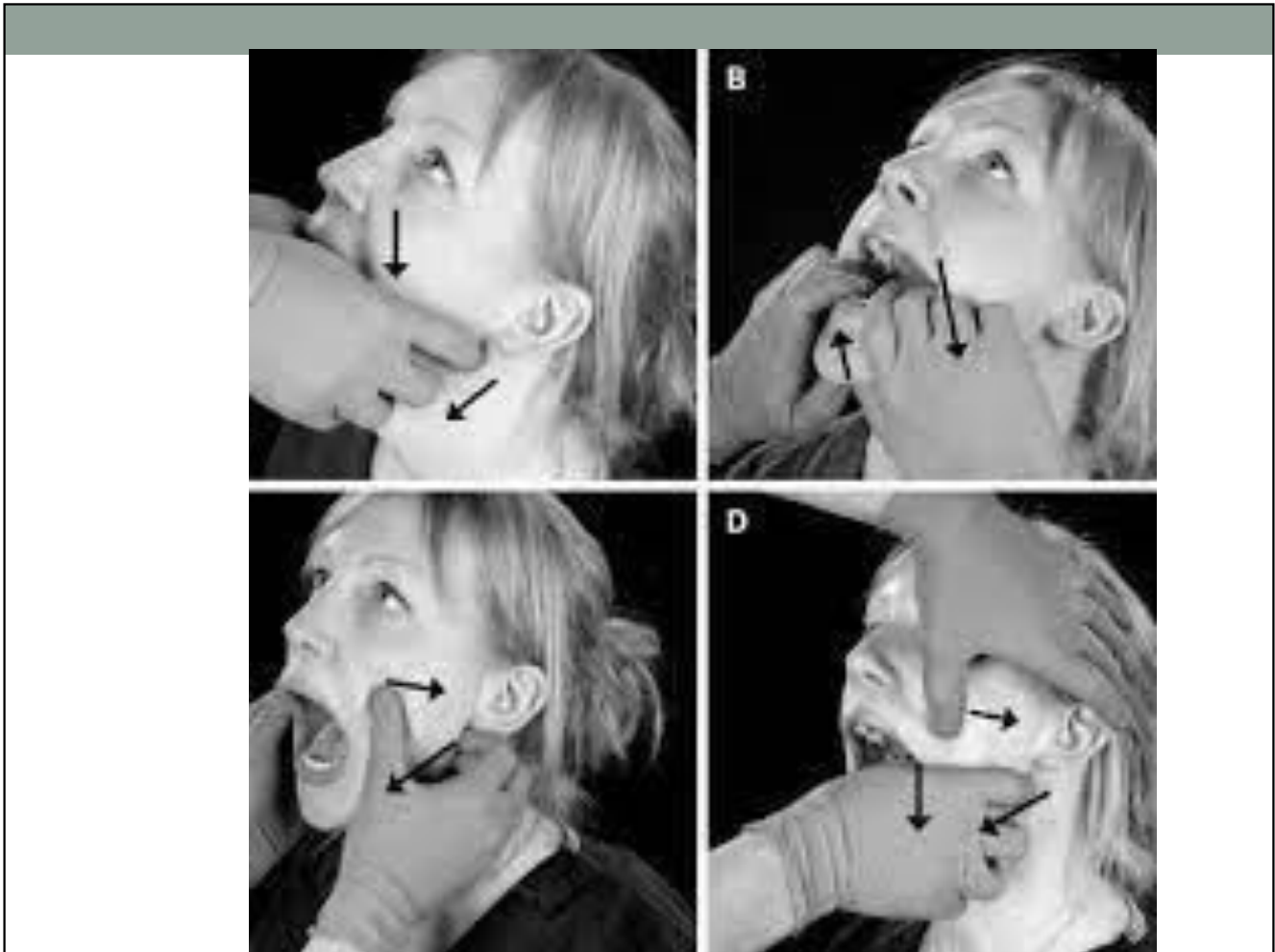
3. **If the dislocation is of chronic type,**

Injection of intracapsular sclerosing agent

(**tetradecyl sulfate, sodium salicylate, normal saline, blood**)

4. If all above procedures are not effective , surgery is done ..... **Eminectomy**





### c. Ankylosis

it is a complication that affects the function of the joint, it may result from trauma. **It is**

**Unilateral Or Bilateral, Fibrous Or Bony Ankylosis**

fibrous Ankylosis is easier to treat

### D. Injury to TMJ

occurs to **capsular ligaments, soft tissue, disk or synovial membrane. Some traumas may cause perforation to the disc.**

Destruction occur to disc during opening, yawing, trauma, overusing of TMJ for long time (as in surgery and dental restoration)

Dx of perforation by **arthrography**: injection of iodine at the superior joint compartment and asking the patient to open and close to see perforation radiographically.

### E. Fracture of head of condyle:

occur if TMJ was subjected to heavy trauma

**Sign and symptoms:**

Pain, asymmetry in face, swelling, limitation during opening and closing, deviation of the mandible to the affected side.

### Perforation of the disc :

it may result from excessive pressure resulting in pain and joint noises .

**Diagnosed by arthrography.**



## 4. Inflammatory disorders

### Rheumatic arthritis (RA):

Is a chronic disease that affect middle age group, the origin of which is unknown, but it may result from immunological reaction

#### Clinical features:

Affect middle age ➤

Female more than male ➤

Affect both joints (bilaterally) ➤

There is limitation and difficulty in opening and chewing. ➤

Morning stiffness that may last for 1 hour and then subside, ➤

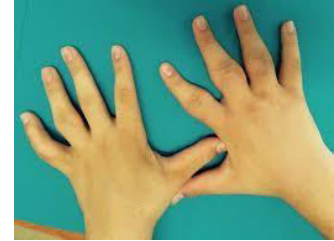Pain could even be experienced during rest and chewing. ➤

Anterior open bite is also present due to capping loss (destruction of articular surface of the condylar head) .This occurs in late stages due to increased joint space. ➤

There is a finding of a spindle-shaped swelling of the involved joints. ➤

The proximal interphalangeal joints are most commonly involved. ➤

The joints that are affected with rheumatoid arthritis become red, swollen, and warm to the touch. ➤



#### Dx:

X-ray,

#### in early stages

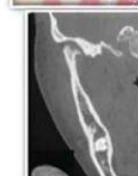
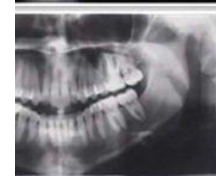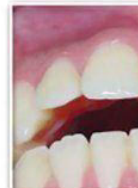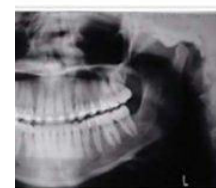nothing appears because no destruction occur to the bone and the defect is only in soft tissue where there is thickening of the synovial membrane and fluid accumulation that leads to pain without radiographic changes , this is called *pannus reaction*.

#### In late stages

there is a change that can appear radiographically due to destruction of cortical surface of condyle and there is increase in joint space that leads to open bite and this is called *capping loss*.

#### Rx

1. NSAIDs to decrease pain.
2. Intraarticular injection of steroid.
3. Using gold salt.
4. Cytotoxic drugs.
5. Surgery by replacement of the joint.



## 2-Psoriatic Arthritis:

It is a chronic disease of unknown aetiology characterized by skin lesions and sometimes joint involvement. Skin lesions are found on the trunk, arms, face and scalp.

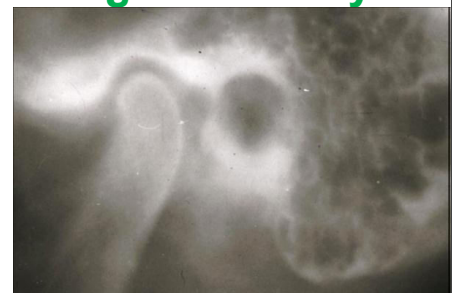
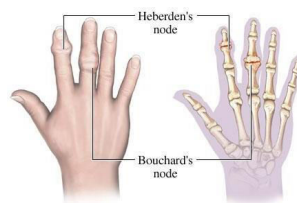
When there are TMJ involvement the main symptom is pain, which is usually unilateral . There is difficulty in opening the mouth . TMJ is tender. Crepitus, deviation towards the affected side and in small proportion of cases, deformities are seen .

## Osteoarthritis

It is a degenerative disease of the bone associated with excessive pressure and aging that leads to osseous remodeling (osteophyte formation), so destruction and formation of new bone occurs leading to changes in condylar shape.

### Sign and symptoms

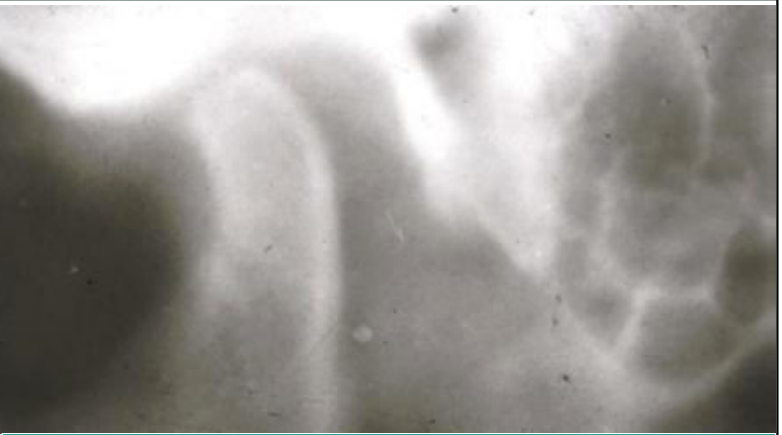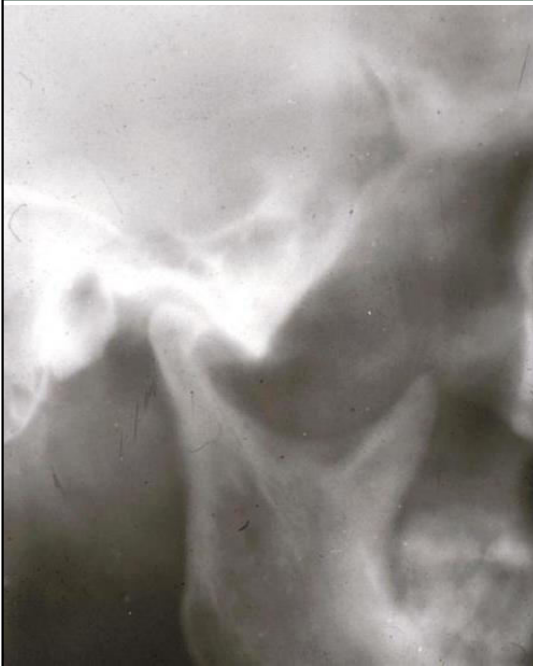1. Almost always unilateral
2. Affect old age patient
3. Pain worsen during the day
4. Pain causes limitation of the joint
5. Crepitation
6. Deviation of mandible
7. Heberden's nodes: nodular protrusion at the distal interphalangeal joints



Tomogram of TMJ showing a normal condyle and fossa.

### Radiograph:

shows decrease in joint space and flattening of condylar surface.



Tomogram of TMJ demonstrating early degenerative changes with erosion of the cortical plate. The fossa is intact.

Tomogram of TMJ identifying moderately advanced degenerative changes. The condyle is significantly flattened, and the eminence of the fossa is also sclerotic and flattened.

## Osteoarthritis

### Treatment:

1. Analgesics
2. Intraarticular injection of steroids
3. Bed rest, soft diet, gradual addition of muscles exercise to promote normal function of mandible
4. Splint to cause anterior repositioning of condyle
5. Surgery (very rare)

### 5. Neoplastic disorders

It is a rare disease

primary (very rare) and secondary (metastatic)

**Diagnosis:**

clinical features

X-ray, biopsy

## **Internal Derangement or Disc Displacement**

The disc is abnormally located in relation to other components of the joint. It is usually displaced anteromedially.

In some rare cases, disc may be displaced posteriorly.

Most of the cases of disc displacement occur due to microtrauma from bruxism or clenching.

It can be defined as a mal-relationship of the meniscus to the condylar head and articular eminence.

**Symptoms are localized joint pain and popping on jaw movement.**

**Diagnosis is based on history and physical examination.**

**If the disk remains anterior, the derangement is said to be without reduction.**

**Restricted jaw opening (locked jaw) and pain in the ear and around the temporomandibular joint may result. If at some point in the joint's excursion the disk returns to the head of the condyle, the derangement is said to be with reduction.**

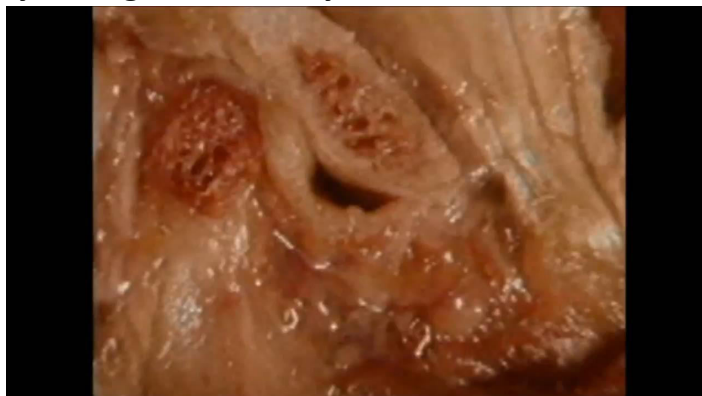- Disc displacement with reduction**
- Disc displacement with reduction with intermittent locking**
- Disc displacement without reduction with limited opening**
- Disc displacement without reduction without limited opening**
- Posterior disc displacement**

### **Disc displacement with reduction**

In disc displacement with reduction, the articular disc has displaced anterior to the condylar head. It may also be displaced medially or laterally.

The disc remains in this position as long as the mouth is closed. When the mouth is opened, the disc is re-situated on the condylar head. The movement of the disc onto and off the condylar head may result in a clicking, snapping, and/or popping sound. This sound does not occur with every mandibular movement.

Because the disc reduces during condylar translation, range of motion is not limited. However, movements may not be as smooth as a normal TMJ because of the momentary sliding of the condyle on and off of the disc



### **Disc displacement with reduction with intermittent locking**

This condition is identical to disc displacement with reduction, with the additional feature of intermittent limited mandibular opening on the occasions that the disc does not reduce.

### **Disc displacement without reduction with limited opening**

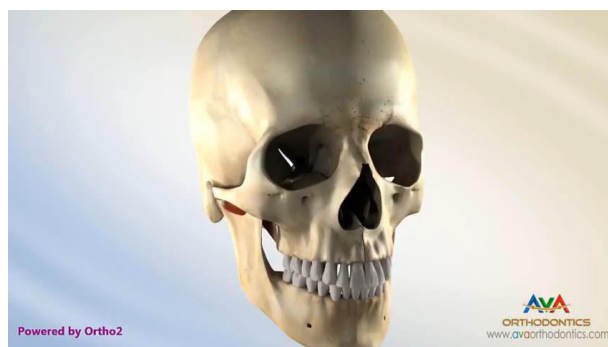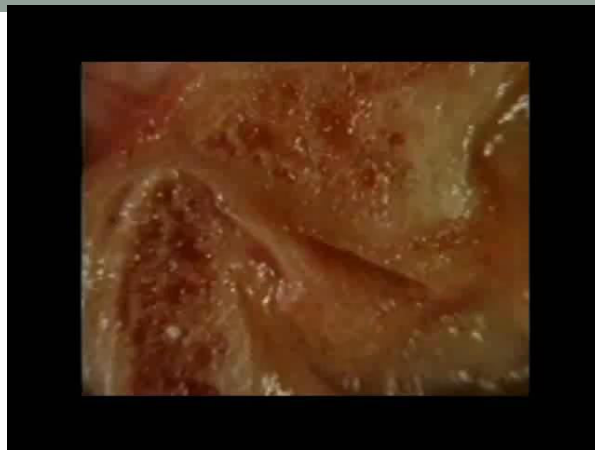
This diagnosis is given when the articular disc consistently does not reduce, resulting in limiting opening. Limited opening is defined as <40 mm between maxillary and mandibular incisor incisal edges with opening assisted by the dentist.

### **Disc displacement without reduction without limited opening**

This condition is identical to the previous condition with the exception that mandibular movement is not limited. However, such limitation must have occurred in the past to the extent that eating was hindered. This condition typically follows the previous condition.

### **Posterior disc displacement**

Because this condition occurs so rarely (very rare of patients with internal derangement). Pain is present more often when the disc is perforated. Joint sounds occur more often in the thin disc type, with a click in approximately half of the cases. Open lock and TMJ luxation each occur roughly in TMJ.



## G-Diseases Associated with Crystal Deposits in Joints

**Gout** is a type of arthritis that occurs when extra uric acid in the body forms crystals in the joint( hyperuricemia). The disease primarily affects men. Acute pain in a single joint is the characteristic clinical presentation.

The TMJ is rarely involved.

Examination of aspirated synovial fluid from the involved joint by polarized light and detection of monosodium urate crystals confirms the diagnosis.

Treatment colchicine, NSAIDs, intra-articular steroid injection.

### **Synovial Chondromatosis**

is an uncommon benign disorder characterized by the presence of multiple cartilaginous nodules of the synovial membrane that break off resulting in clusters of free-floating loose calcified bodies in the joint. Some cases appear to be triggered by trauma, whereas others are of unknown etiology.

Slow progressive swelling in the preauricular region, pain, and limitation of mandibular movement are the most common presenting features.

TMJ clicking, locking, crepitus, and occlusal changes may also be present.

Treatment should be conservative and consist of removal of the mass of loose bodies. This may be done arthroscopically.



## **B -Extracapsular disorders of TMJ**

### **Myofascial Pain Dysfunction Or TMJ Dysfunction Syndrome TMDS**

The Prevalence Of This Disorder Is Wide And Very Common.

Affecting Young Age People

Female More Than Male In A Ratio Of 2:1

The Age Is About 14-25 Years.

Civilized People More Than Rural Ones

## **B -Extracapsular disorders of TMJ**

### **Symptoms:**

1. Pain .
2. Joint sound
3. Restricted mouth opening
4. Less frequent signs and symptoms

#### **A. Ear Problem**

Pain ❖ Tinnitus

❖ Buzzing



Hearing Loss ❖

#### **B. Metallic taste**

1. Muscles and TMJ pain

## 1. Pain

during mastication and speech.

Patient feels discomfort and pain.

Also pain during mandibular movement

### Type of pain is

Acute

Chronic

Sharp

Dull

Unilateral

Bilateral

Localized

Diffused According To Patient.

## 2. Joint sound:

There are two types of joint sound:

### A. Clicking:

which is single joint sound

### B. Crepitation:

which is gravel like sound or multiple

### Etiology of clicking

is still not fully understood, but it may be due to:

1. Uncoordinated contraction of the two heads of the lateral pterygoid muscle
2. Anterior positioning of the disc
3. Organic changes as in RA and OA

### 3. Restricted mouth opening:

#### In Opening Or Closing Also For Lateral Movement Of Mandible

- Normal opening is more than 50 mm
- Normal lateral movement is 5mm
- Limitation in opening <30mm
- Lock (patient can't open at all) <20mm
- To check muscles and TMJ tenderness

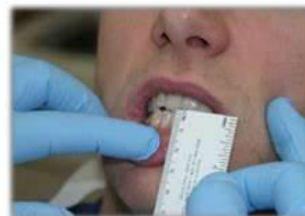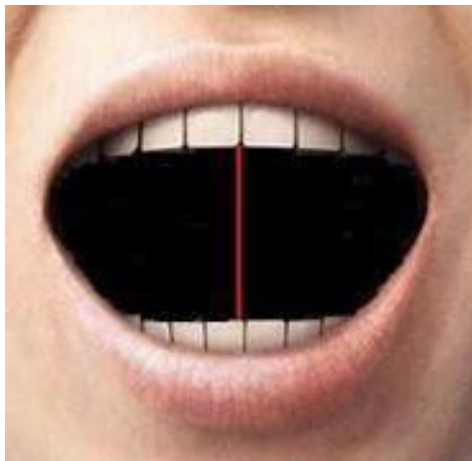**Use Single Firm Touch And The Pressure About 1 Pound For One Second, This Touch Has More Benefits Than Repeated Touches Because Repeated Touches Will Have An Additive Effect Causing Pain Even If Patient Has No Problem**

- Also check muscles of neck, sternocleidomastoid and digastric

### 4. Less frequent signs and symptoms:

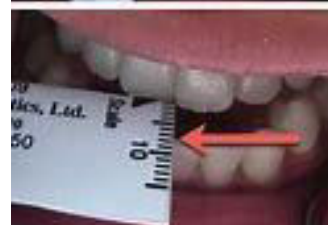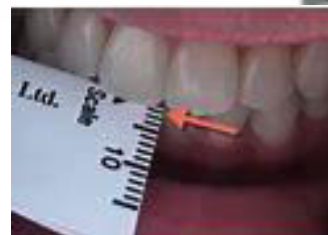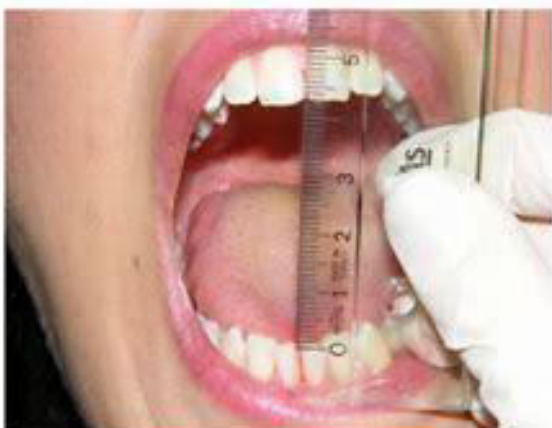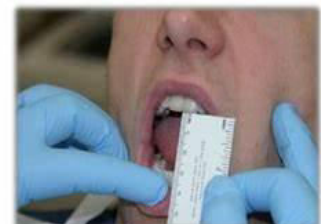- A. Ear problem: pain, tinnitus, buzzing or hearing loss
- B. Metallic taste

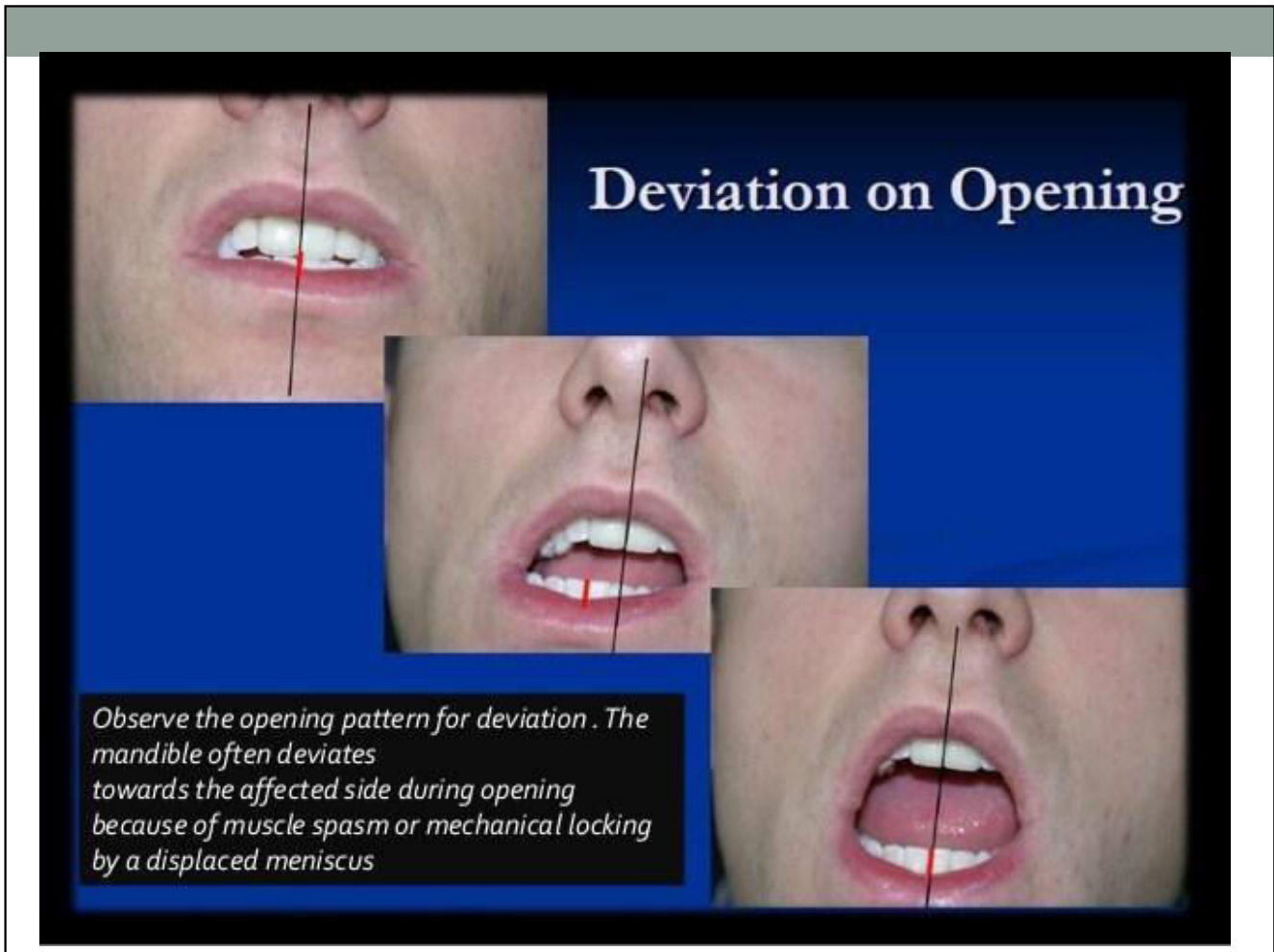
### 5. Muscles and TMJ pain



- The maximum opening distance between the incisal edges of upper and lower incisor is measured using scale, Boley gauge or ruler
- Normal opening – 40 to 55 mm

- Normal opening can also be estimated by patient's own finger
- Normal : three finger end on end
- Two finger opening reveals reduction in opening but not necessarily reduction in function
- One finger opening indicates reduced function





### **Etiology of TMDs**

There are 4 **theories** that described the cause of TMDs:

**A. Malocclusion theory:** this theory states that malocclusion occur due to posterior or anterior displacement of the condyle leading to a pressure in the retro Discal area (highly innervated) leading to pain.

This theory is pure mechanical and is the last one to be accepted

**B. Neuromuscular theory:** disharmony between TMJ and dental occlusion is the cause of TMDs where the presence occlusal interference leads to parafunctional movement like grinding, clenching or over activity of the muscles. Stress increases them.

**C. Muscular theory:** introduced by Kruse in 1969, this theory suggests that the primary cause of TMDs is muscles. Lack of muscles exercise and overstimulation results in muscle fatigue.

**D. Psychological theory:** it is the most accepted theory, indicates that the primary cause of TMDs is the CNS. According to it, muscles fatigue and spasm result is muscle hyperactivity which is initiated centrally.

## **Etiology of TMDs in Iraq**

### **A. Habits:**

- Check Bite**
- Nail Bite**
- Object Bite**
- Lip Bite**
- Clenching**
- Grinding**

### **B. Loss of posterior teeth:**

leads to pseudo class III, condyle is displaced anteriorly.

### **C. Trauma to TMJ**

### **D. Malocclusion**

### **E. Osteoarthritis**

## **Diagnosis of TMDs**

### **1. History:**

### **2. Clinical examination:**

### **3. Investigations**

- a. Radiographs:**
- b. Arthrography:**
- c. C.T scan:**
- d. CBCT**
- e. MRI:**
- f. Electromyography (EMG)**
- g. Casts:**
- h. Arthroscopy**

## Diagnosis of TMDs

### 1. History:

chief complaint,  
HPI (onset, frequency, relieving factors, aggravating factors),  
PDH,  
PMH,  
SH

### 2. Clinical examination:

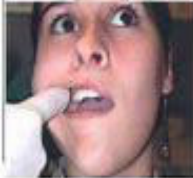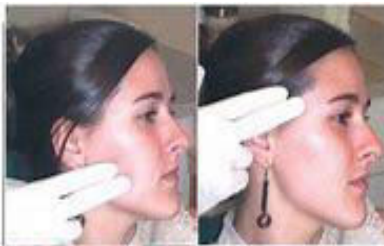#### a. Inspection:

extraoral visualization to see facial asymmetry,  
color of sclera,  
swelling,  
sinus, fistula,  
intraorally to see facet of tooth wear, malocclusion, and to see oral mucosa

#### b. Palpation:

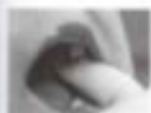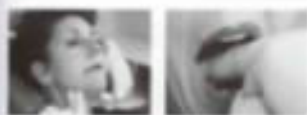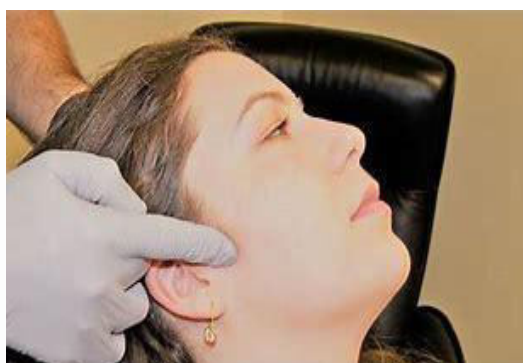
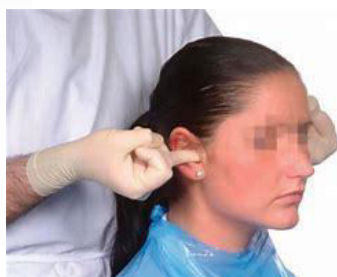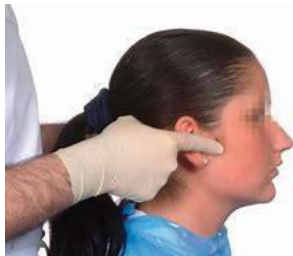for TMJ (intragagus and pretragus),  
for muscles of mastications

(lateral pterygoid intraorally)



Systematic evaluation of muscle mastication.

A. Palpation of masseter muscle  
B. Palpation of temporalis muscle  
C. Palpation of temporalis muscle attachment on coronoid process and ascending ramus.



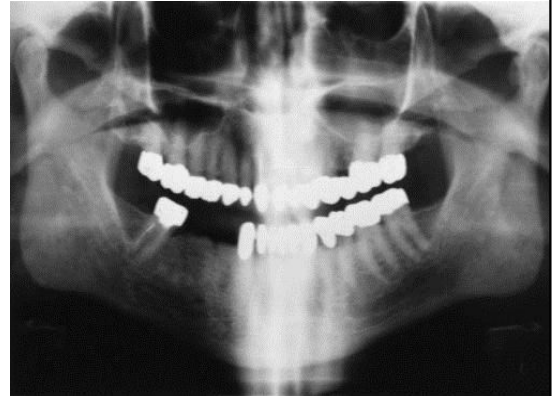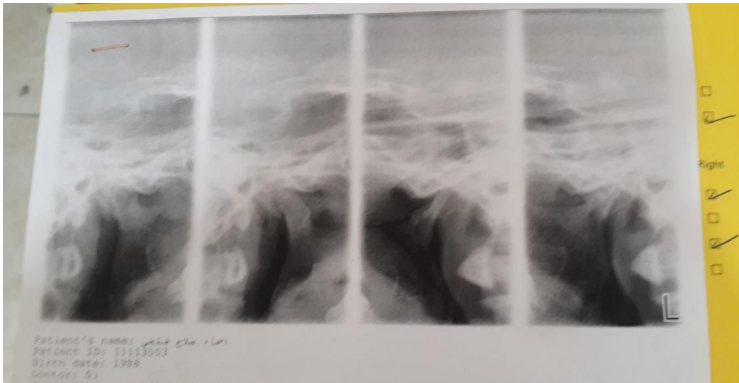


### 3. Investigations

#### a. Radiographs:

O.P.G,  
Trans Pharyngeal,  
Transcranial

which is the most effective view for examining TMJ, it shows right and left condyles, each condyle is imaged during opening and closing.

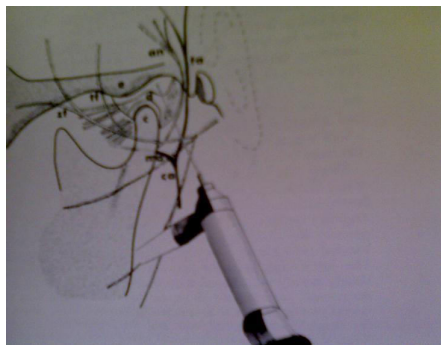


Radiographs are not always needed -as in case of myogenous TMJ problem- because there is no radiographic change to be seen.

However; it is important for patient with RA in late stage, OA or fracture.

#### b. Arthrography:

done by injecting contrast medium (iodine)



Indicated to:

- i. See perforation
- ii. See morphology and position of disc
- iii. Diagnose adhesion (no superior compartment)
- iv. Diagnose the presence of foreign body

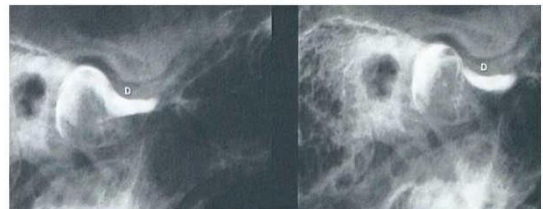
**Disadvantages:**

- i. Invasive procedure (complication of injection, infection)
- ii. Exposure to radiation
- iii. Hypersensitivity to iodine

#### TMJ Imaging

##### Arthrography

- Position, shape and integrity of disk
- Therapeutic dilation
- Accurate in demonstrating displacement
- Extinct?



muhadharaty.com

### C. C.T Scan:

Dose equals to 100 chest x-ray, less expensive than MRI, for bone.

D. MRI: No radiation, expensive.

### E. Electromyography (EMG):

During muscle activity, there is a period called "silent period", this period is prolonged with muscle spasm, the biting force also decreases.

### F. Casts: Analysing occlusion

.

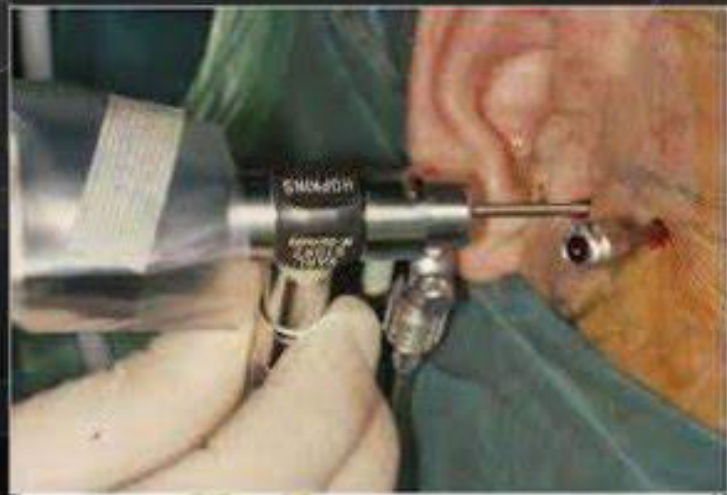### G. Arthroscopy:

**For diagnosis and treatment, to visualize TMJ directly.**

It is an invasive technique and it has complications.

Drugs such as steroids and hyaluronic acid can be injected, synovial fluid can be aspirated,

Treatment can be made using laser attached to the device.



### Differential diagnosis

1. Neural like trigeminal neuralgia, multiple sclerosis
2. Vascular disease: cluster headache, migraine, giant cell arteritis, angina
3. Musculoskeletal syndrome: Eagle syndrome: elongation of styloid process so the patient feels pain upon swallowing, Dx by radiograph
4. Oral problem: Acute or chronic, Periodontitis, Pericoronitis
5. Salivary gland disease: Inflammation, Obstruction or Tumor
6. ENT problem
7. Psychologic problem: like Atypical facial pain (Buzzer pain), Trotter syndrome

### Treatment of TMDs:

Goals of treatment are to

Relief pain

Restore function

Treatment should be chosen

according to case with no specific priority or sequence, options are:

1. **Pharmacological therapy:**

2. **Physical therapy:**

3. **Splint therapy:**

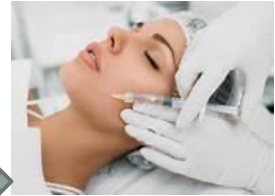Types of occlusal splints

4. **Exercise:**

## Pharmacological Therapy

### **Muscle relaxant**

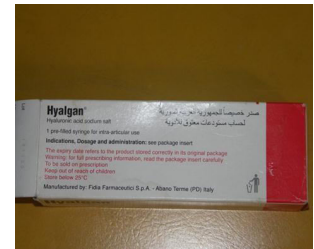- \* Myogenic Or Norgesic Or Kanagesic(Orphenadrine citrate 35mg +paracetamol 450mg)
- \*Relaxone (Chlorzoxazone 250mg +paracetamol 300mg)
- \*Cyclobenzaprine tablet (5mg 7.5mg 10 mg)
- \*Diazepam tablet (Valium 2mg 5mg 10mg)
- \*Baclofen tablet 10mg
- \*Metaxalone (Skelaxin) 800mg
- \*Botulinum toxin A “BOTOX”



injection ampule ( neurotoxin protein that come from Clostridium botulinum bacteria. It relaxes the muscle by stopping the acetylcholine neurotransmitter from releasing).

### **NSAID**

- Ibuprofen Brufen 200mg 400mg
- Naproxen 500mg coated tablet
- Meloxicam (mobic) tablet 7.5mg 15mg



### **Steroid**

### **Sodium hyaluronat**

### **Tricyclic antidepressants—**

most commonly [amitriptyline](#), [desipramine](#), [doxepin](#), and [nortriptyline](#)—are used for the management of chronic TMD pain.

### **Benzodiazepines**

are also used, but are generally limited to two to four weeks in the initial phase of treatment ,[diazepam \[Valium\]](#), [clonazepam](#), [gabapentin \[Neurontin\]](#) may provide more benefit than shorter acting agents.

### **Opioids**

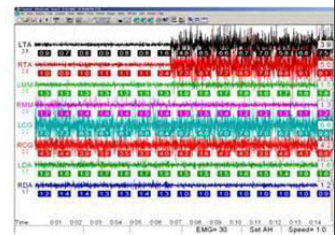
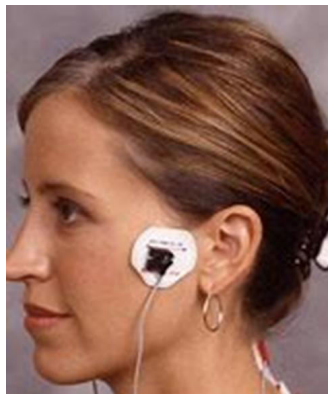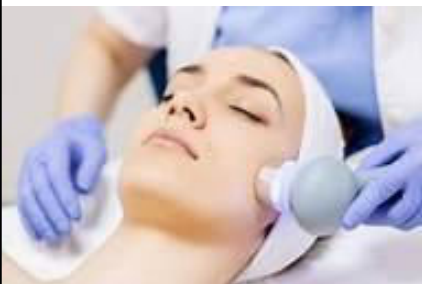are not recommended and, if prescribed, should be used for a short period in the setting of severe pain



## Physical Therapy

which is represent a group of supportive action for managing pain

- \*Thermotherapy
- \*Coolant Therapy
- \*Massage Therapy
- \*Electrical Stimulation Therapy TENS
- \*Ultrasound Therapy
- \*EMG Biofeedback



## \* Exercise therapy :

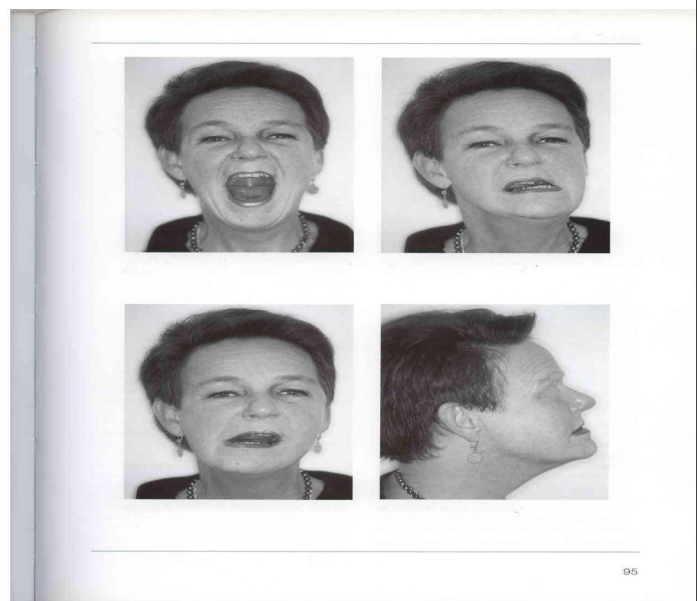
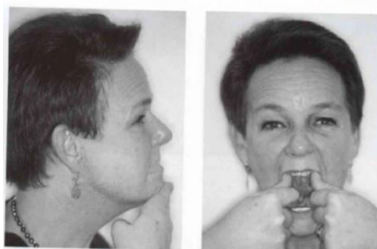**The objective of muscle exercise is to causes reflex relaxation of antagonistic muscle**

Types of muscle exercise

1- Passive Exercise

2- Active Exercise

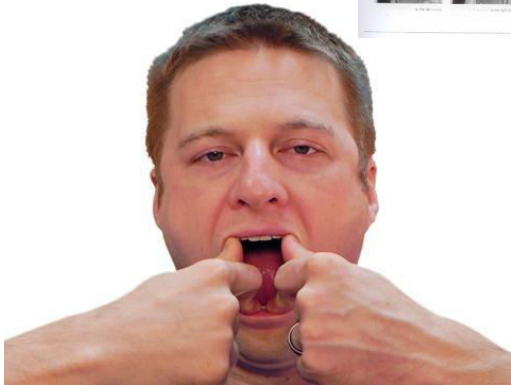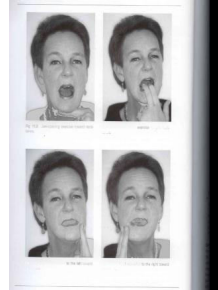- Assisted Stretching
- Resisted Exercise
- Clenching Exercise



## Types of muscle exercise

### 2- Active Exercise

- Assisted Stretching
- Resisted Exercise
- Clenching Exercise



**\*laser therapy**

### The effect of the therapeutic laser include

- \*Reduction Of The Nerve Conduction Velocity**
- \*Selective inhibition of A & C fibres .**

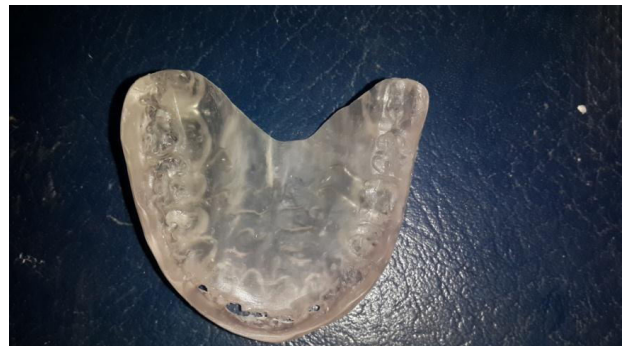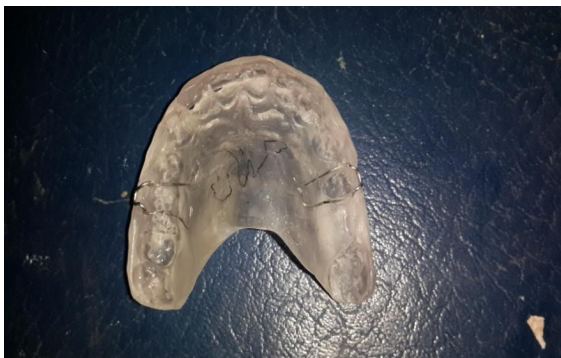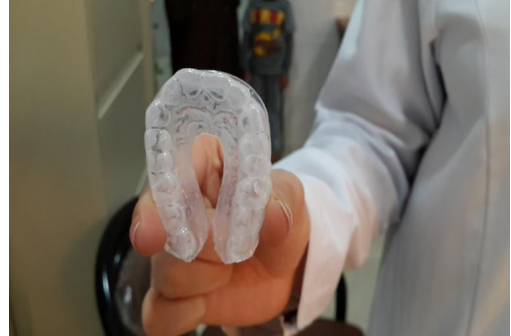**\* occlusal splint therapy**

**It is a removable appliance that fits over the occlusal & incisal surface of the teeth in one arch creating precise occlusal contact with the teeth of the opposing arch.**



## Types of bite plate

1. Centric Relation Splint.
2. Anterior Repositioning Splint.
3. Resilient Splint.
4. Anterior bite plate
5. Posterior bite plate.
6. Pivoting bite plate.



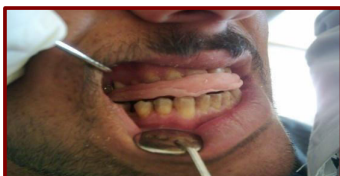
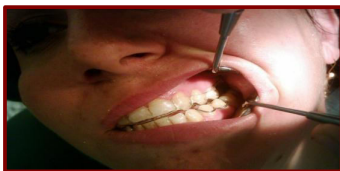Is one of the reversible modality in treatment of temporomandibular joint disorders.

There are five general features common to all splints that may be responsible for decreasing muscle activity and symptoms:

- 1- Alteration of the occlusal condition.
- 2- Alteration of the condylar position.
- 3- Increase in the vertical dimension.
- 4 Cognitive awareness.
- 5 Placebo effect.

## Bite Plate

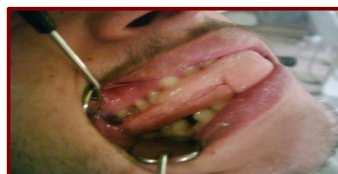
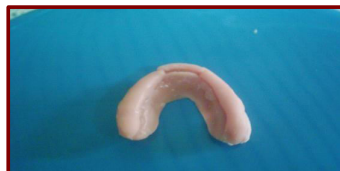### Centric Relation Splint



#### Indications

- 1 For bruxism.
- 2 Muscle hyperactivity.

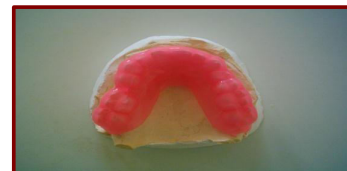### Anterior Repositioning Splint



#### Indications

- 1 TMJ Clicking.
- 2 TMJ Lock.
- 3 Symptomatic treatment of inflammatory disorders.

### Resilient Splint

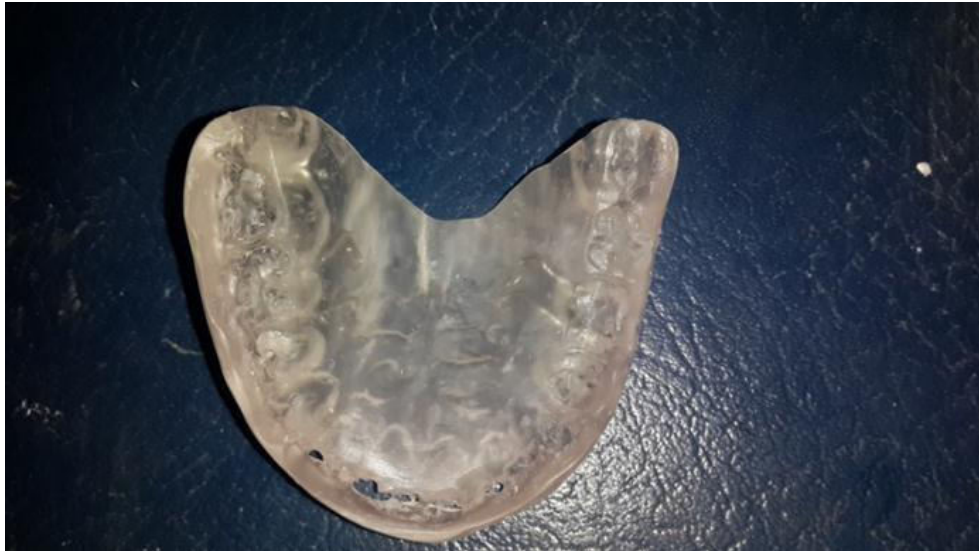

#### Indications

- 1 Chronic sinusitis.
- 2 Teeth protection in athletics.
- 3- Mixed dentition.
- 4- bruxism.

## Centric relation splint :

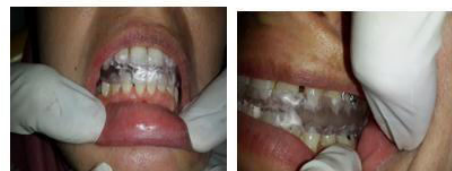it is an interocclusal appliance when it is in place , the condyles are in the most musculoskeletal stable position at the same time the teeth are contact evenly  
indication : it is used to treat muscle hyperactivity



## \* Resilient splint



## Anterior Repositioning Splint



## Surgical care:

### **\*Arthrocentesis , \*Arthroscopic surgery**

TMJ arthrocentesis and arthroscopy are minimally invasive surgical techniques used in the management of TMJD.

**Arthrocentesis** is an office-based procedure that involves the placement of two needles into the superior joint space for the purpose of hydraulic distension then joint lavage.

In the acute “closed lock” or in the painful self-reducing disc displacement disorder arthrocentesis will help mobilize an entrapped disc and will remove nociceptive inflammatory mediators.

**Arthroscopic surgery** is considered a minimally invasive diagnostic and therapeutic procedure however it is usually done in the hospital out-patient setting. Most arthroscopic procedures are used for diagnosis, lysis of adhesions and lavage of inflammatory mediators within the superior joint space.

**\*open surgical treatment** **CONDYLOTOMY , ARTHROPLASTY**

**Acupuncture,**

**Prosthodontic Therapy,**

**Orthodontic Therapy**

## **There are certain recommendation for treatment of patient with TMJ problem :**

1. Treatment should directed toward relaxation of the muscle.
2. Treatment must include several modalities since the problem of multifactorial aetiology .
3. Treatment must include only reversible modalities.
4. Surgery involve the TMJ should not be done unless specific intra-capsular organic problem can be identified .