

Fun and Unusual Cases in Parasitology

Blaine A. Mathison, BS M(ASCP)

Institute for Clinical and Experimental Pathology

ARUP Laboratories

Salt Lake City, UT

blaine.mathison@aruplab.com

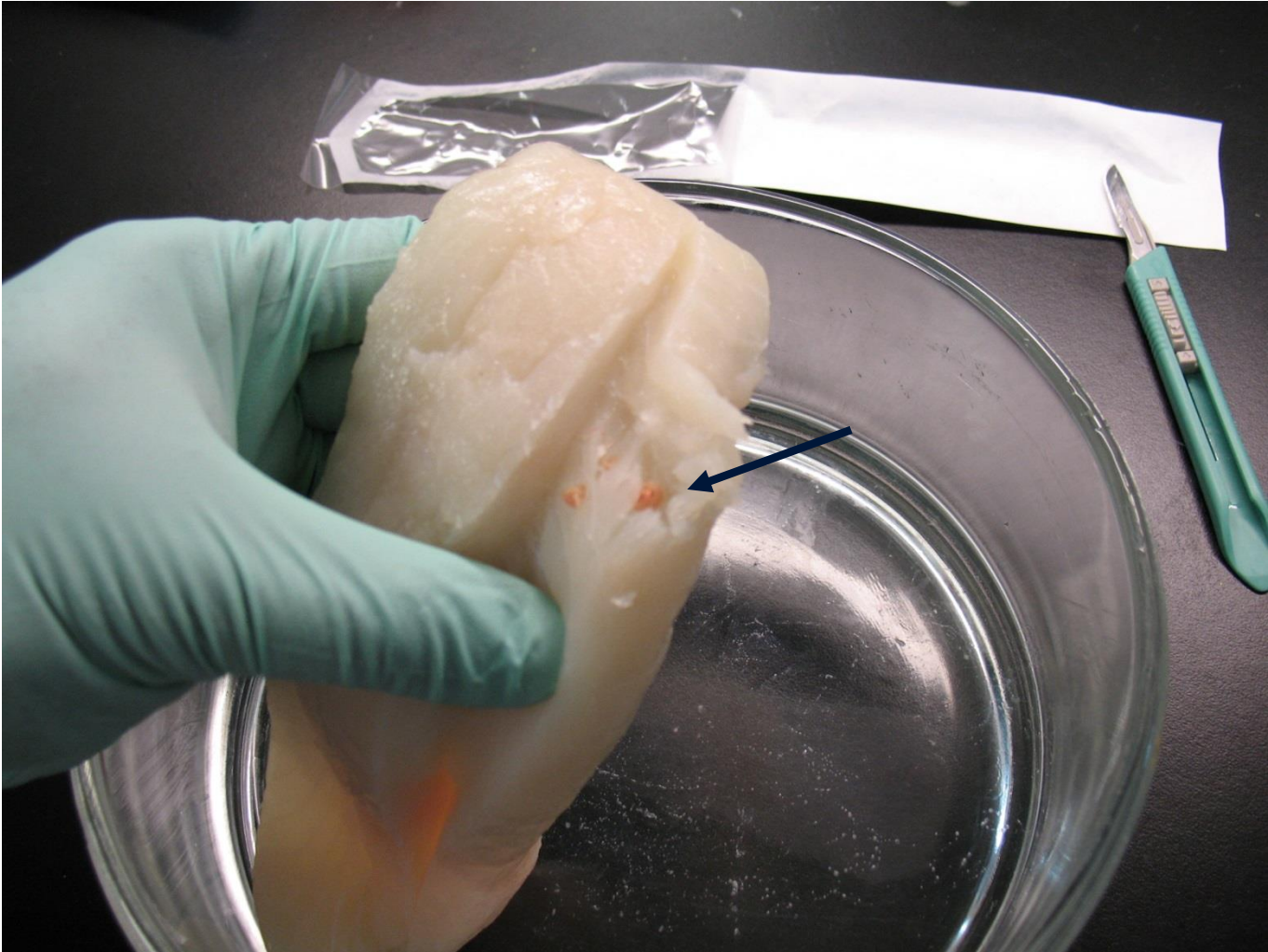
Fairview Health Services

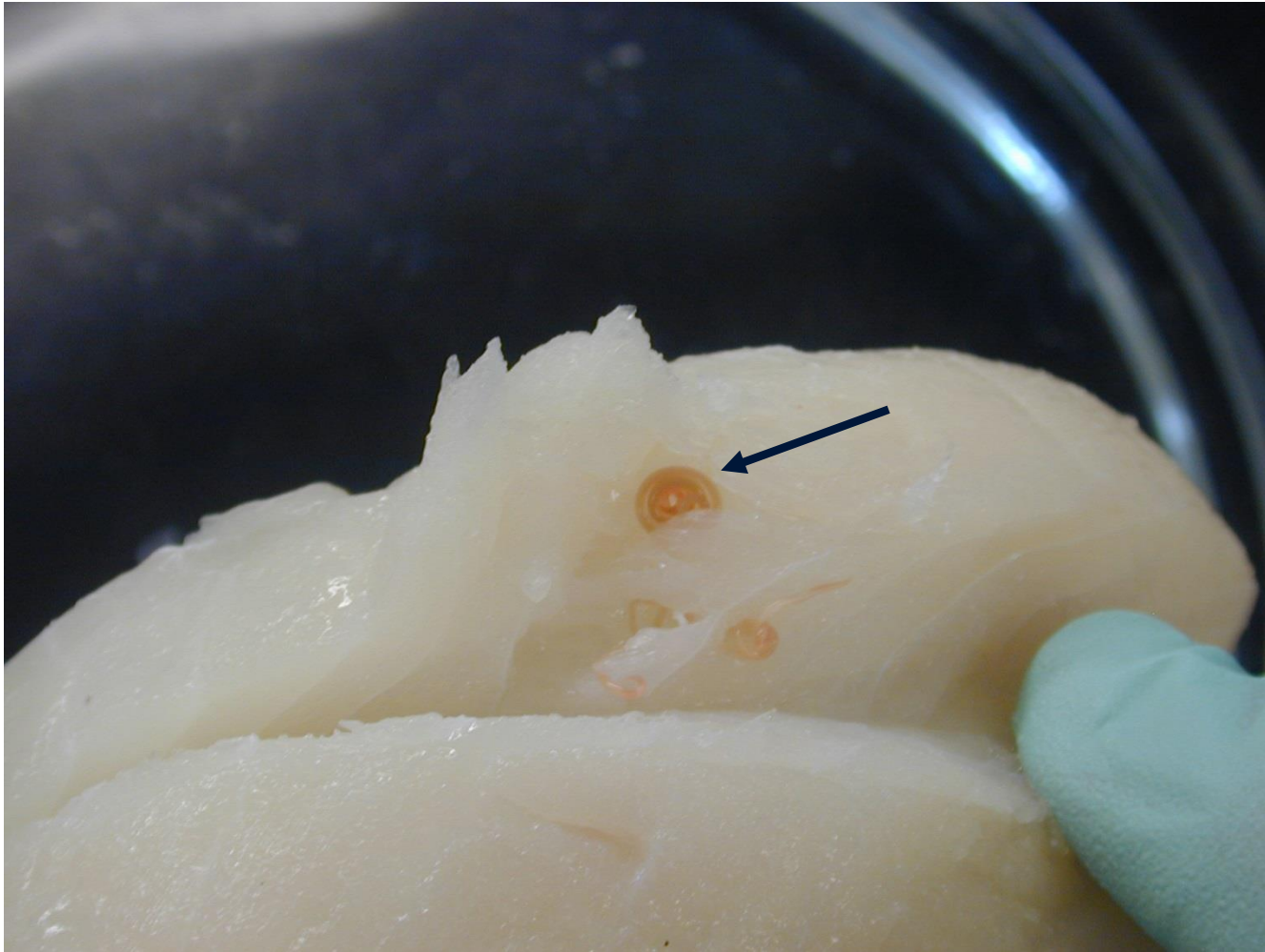
Live virtual from Salt Lake City, UT

March 1, 2021

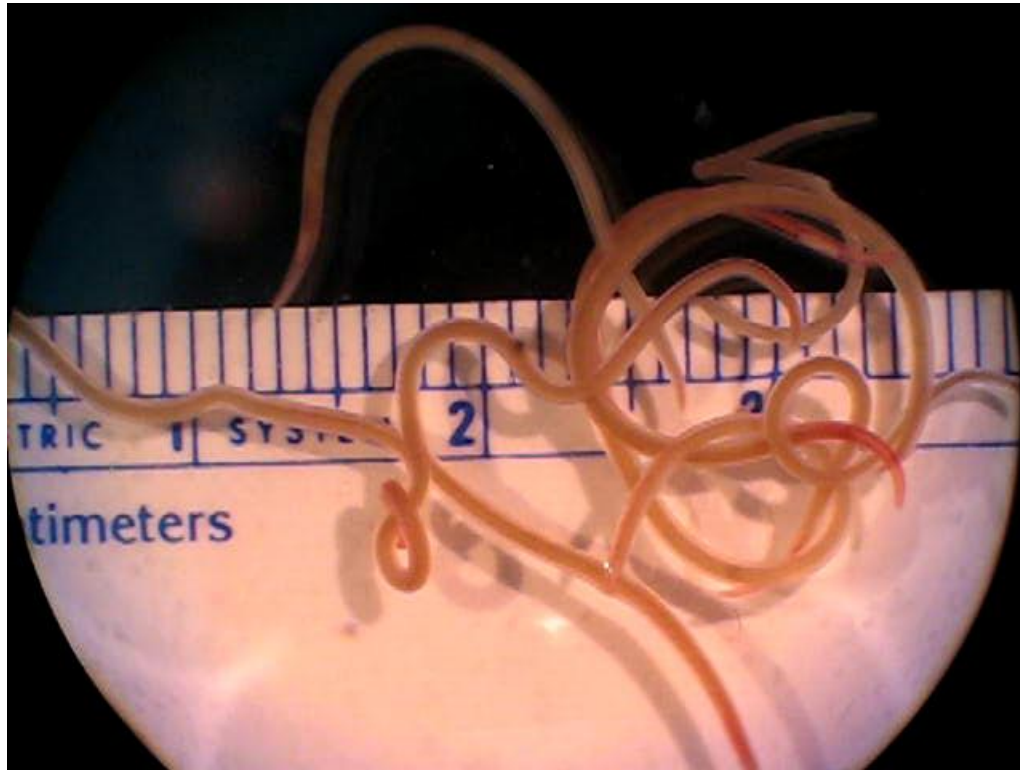
Chapter 1: Something Fishy is Going on in Atlanta!



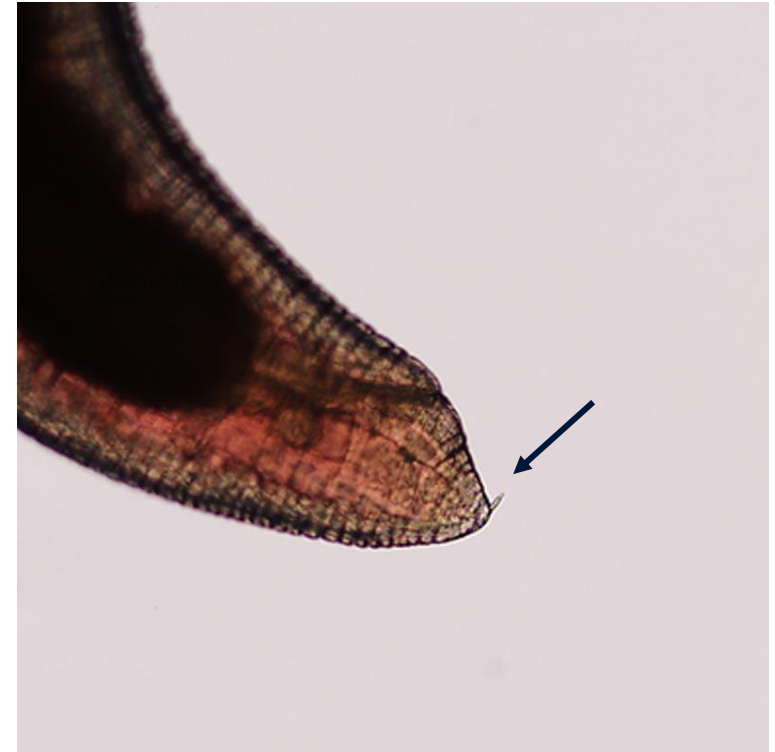
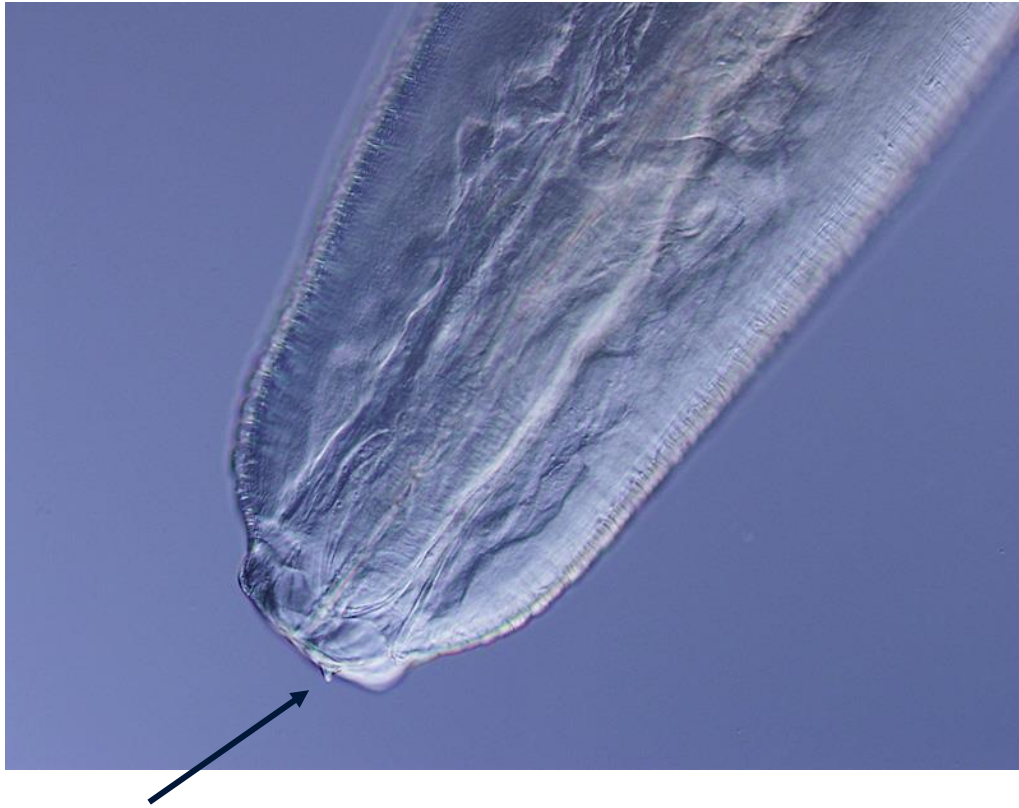




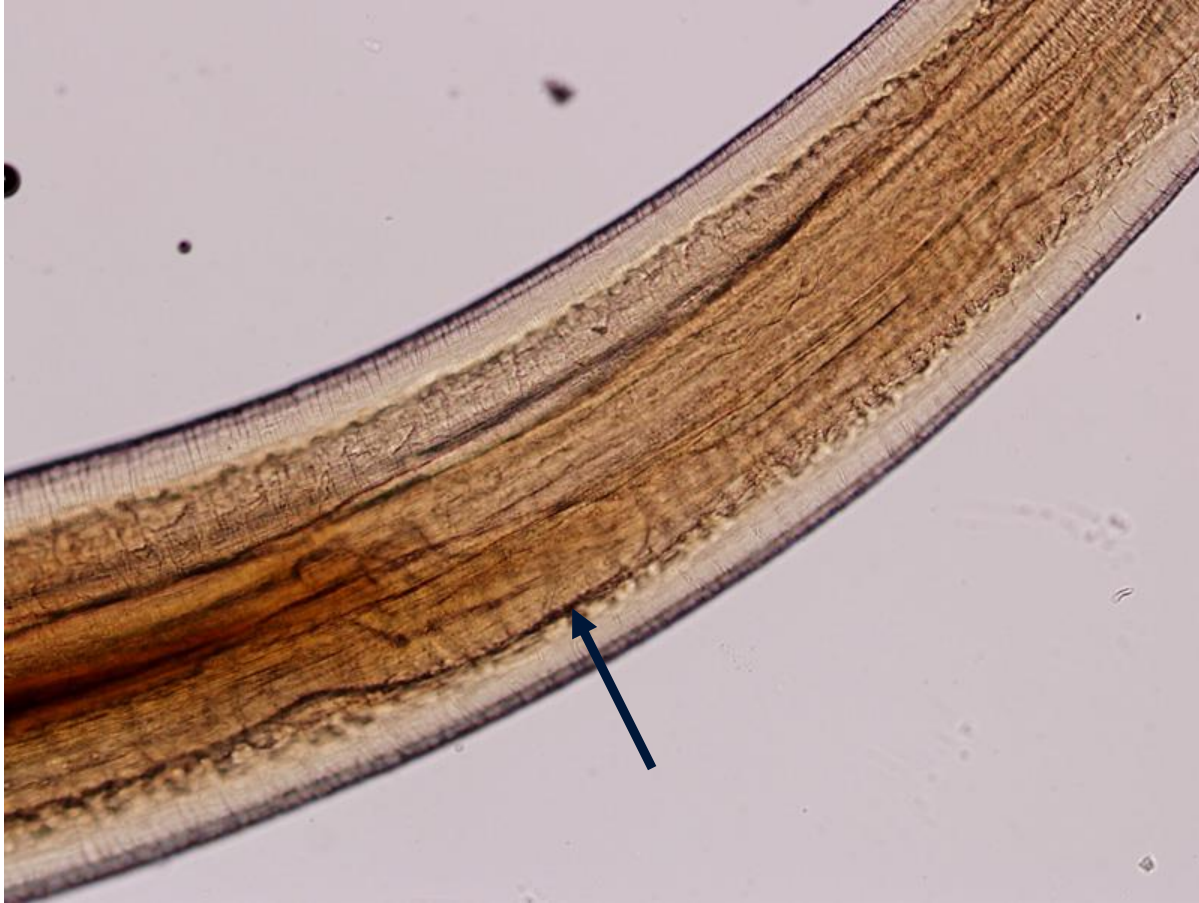[video]



Anterior and Posterior ends of one of the Worms



[after clearing worm in lactophenol]

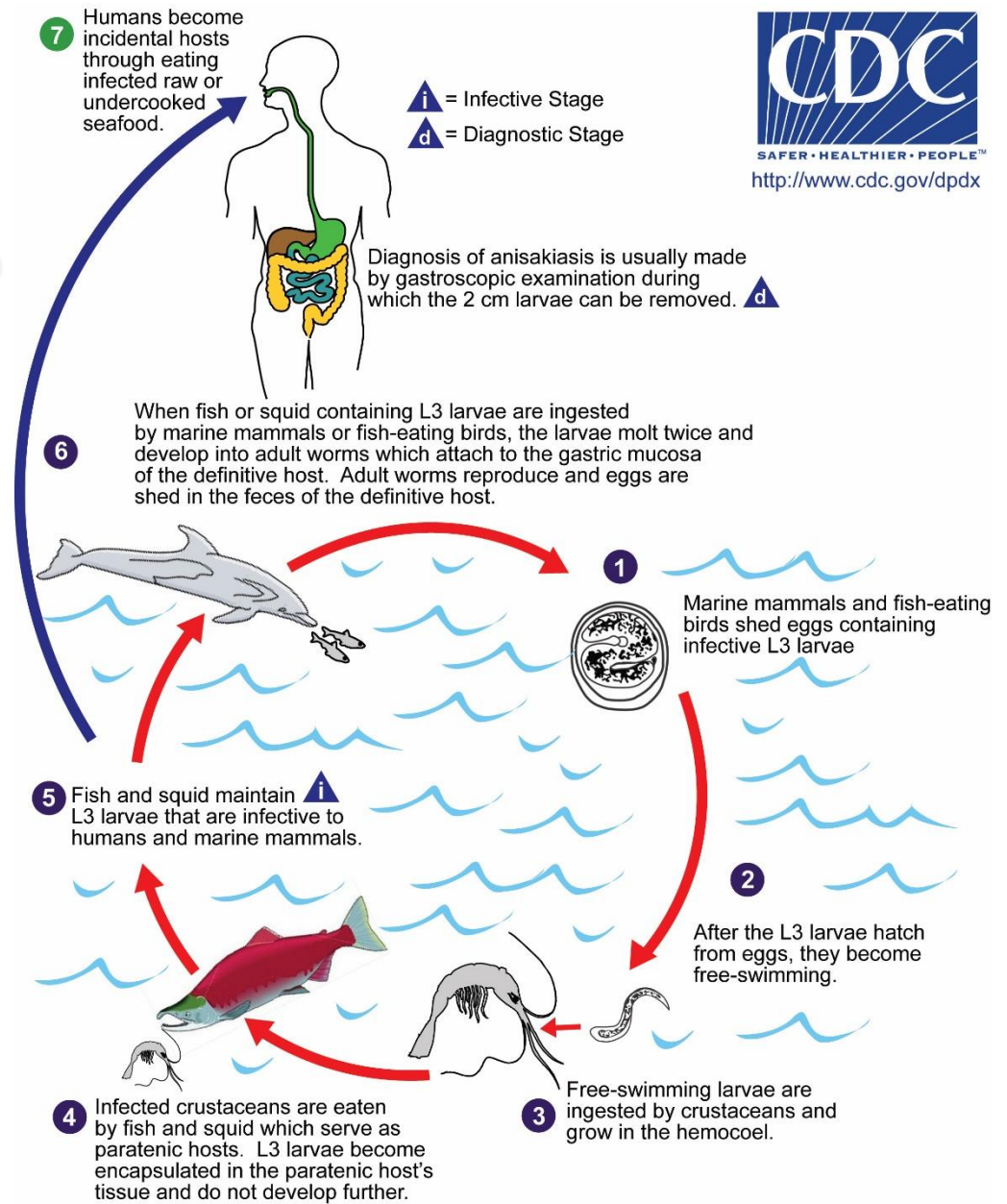


End

Identification: *Pseudoterranova* species.

- Anisakiasis is caused by nematodes in the genera *Anisakis*, *Pseudoterranova*, and *Contracaecum*.
- Marine mammals are normal definitive hosts; humans become infected after eating undercooked fish and mollusks (e.g., squid) infected with infective (L3) larvae.
- Usually occur in the stomach or intestinal wall of the human host; may be coughed up or excreted in feces, or migrate to ectopic sites.
- Diagnosis is typically made by the finding of whole worms expelled, or in biopsy specimens. Some serologic testing available. Molecular methods (sequencing analysis) can be done for genus-level confirmation or species-level ID (not needed for patient management).

Life cycle of Anisakid Nematodes



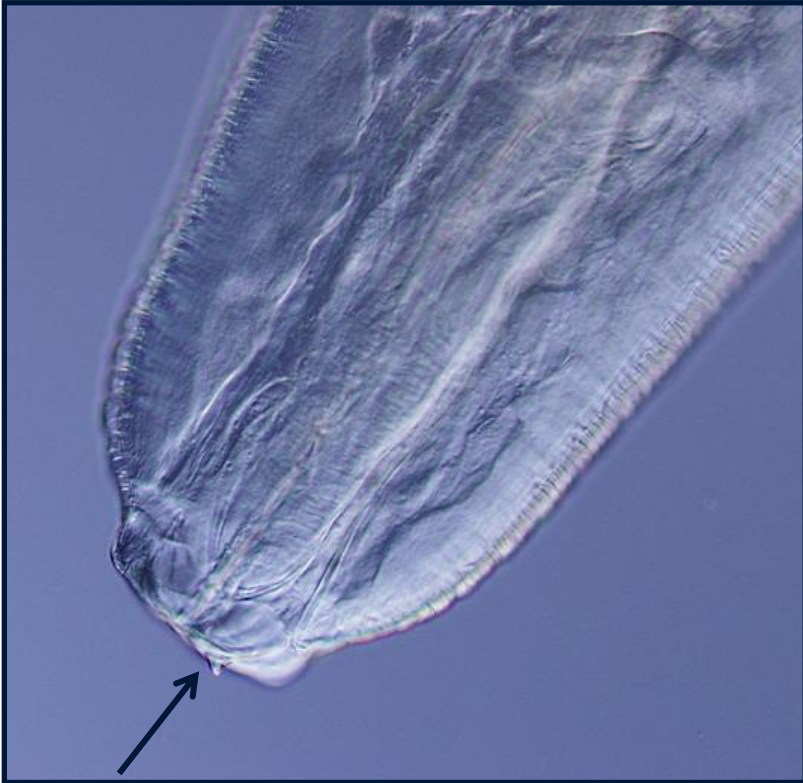Clinical Manifestations

- Four main clinical manifestations of anisakiasis: 1) gastric, 2) intestinal, 3) extraintestinal/ectopic, and 4) acute allergic response.
- Gastric and intestinal anisakiasis may present with nausea, vomiting, abdominal and epigastric pain, and fever. Leukocytosis and eosinophilia may develop within the first couple weeks of infection.
- Ectopic anisakiasis, worms may colonize the umbilicus, peritoneum, spleen, mesocolic lymph nodes, lungs, and perimetrium. Worms usually die at these sites and are often found in biopsy specimens collected for other presumed diagnoses.
- Allergic reactions range from urticarial and angioedema to anaphylactic shock (could this be caused by the fish, or the worms?!). May or may not accompany GI symptoms and the worm need not be viable. Food preparers and fish handlers at risk for conjunctivitis and contact dermatitis from handling infected fish.

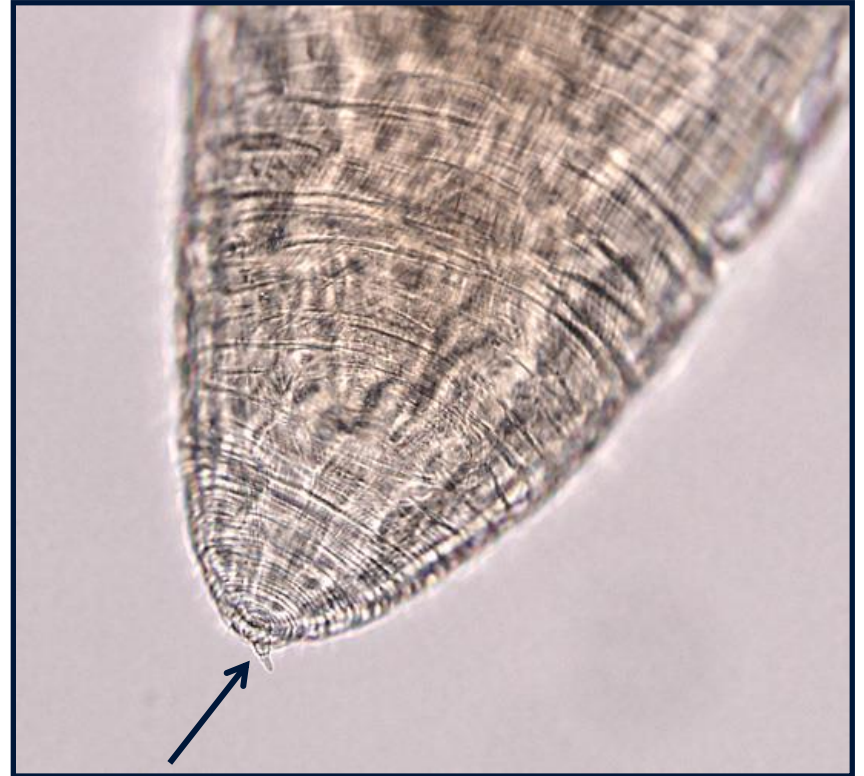Anisakiasis – Diagnosis

- Morphology. The morphologic recognition and identification of worms removed from clinical specimens. An identification to the genus or species level not needed for patient management, but may be accomplished by morphology.
- Serology. A positive skin-prick test, with having compatible clinical manifestations following consumption of fish, and confirmed by specific IgE antibodies against *A. simplex* using additional assays (e.g. radioimmunoassay), as well as a lack of reaction to proteins from the host fish
- Molecular. Useful for epidemiologic studies, but are not typically used for primary clinical diagnosis and patient management. Usually available at research labs.

Anisakid Worms - Morphology

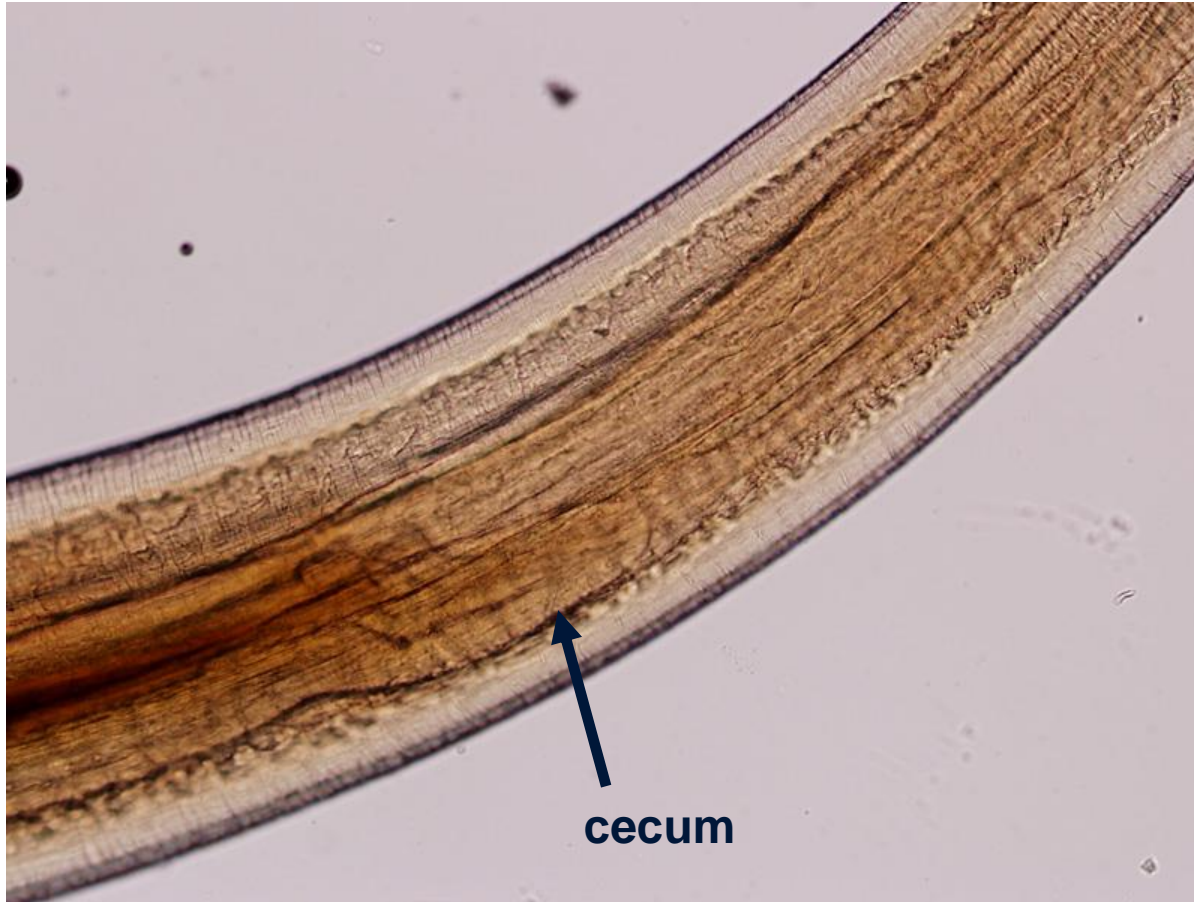


boring tooth



mucron

Anisakid Worms - Morphology



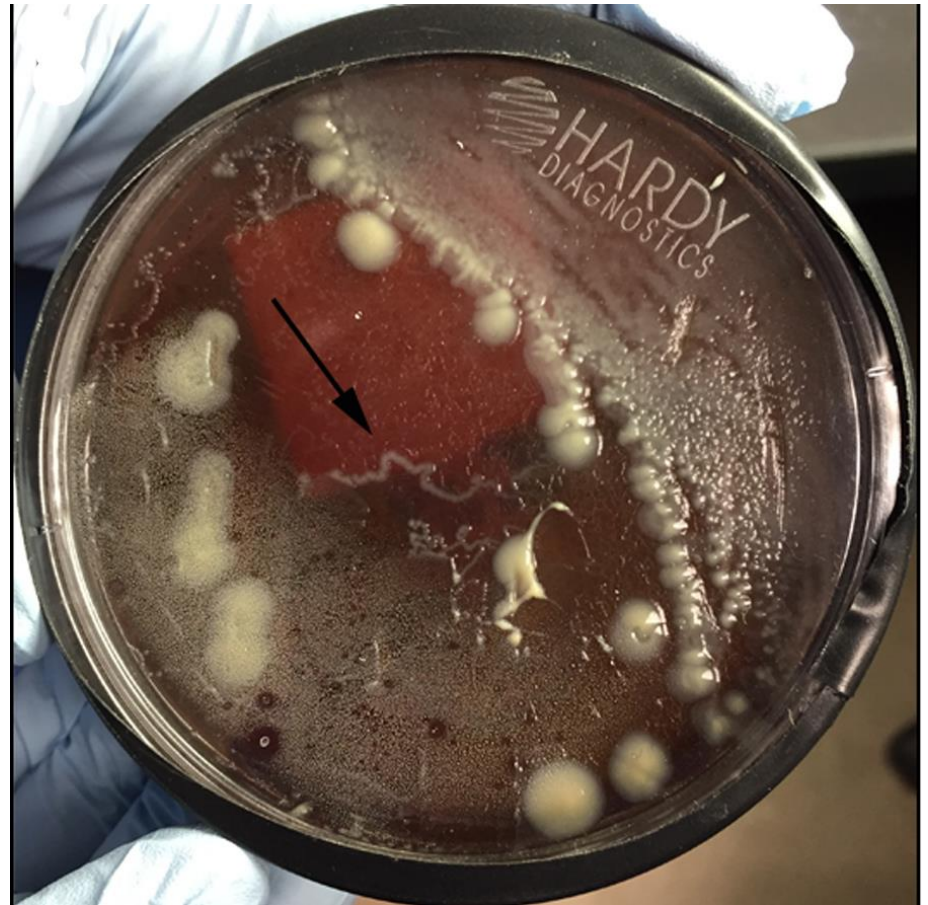Chapter 2: Tracking Worms in the Bacteriology Lab

Case Presentation

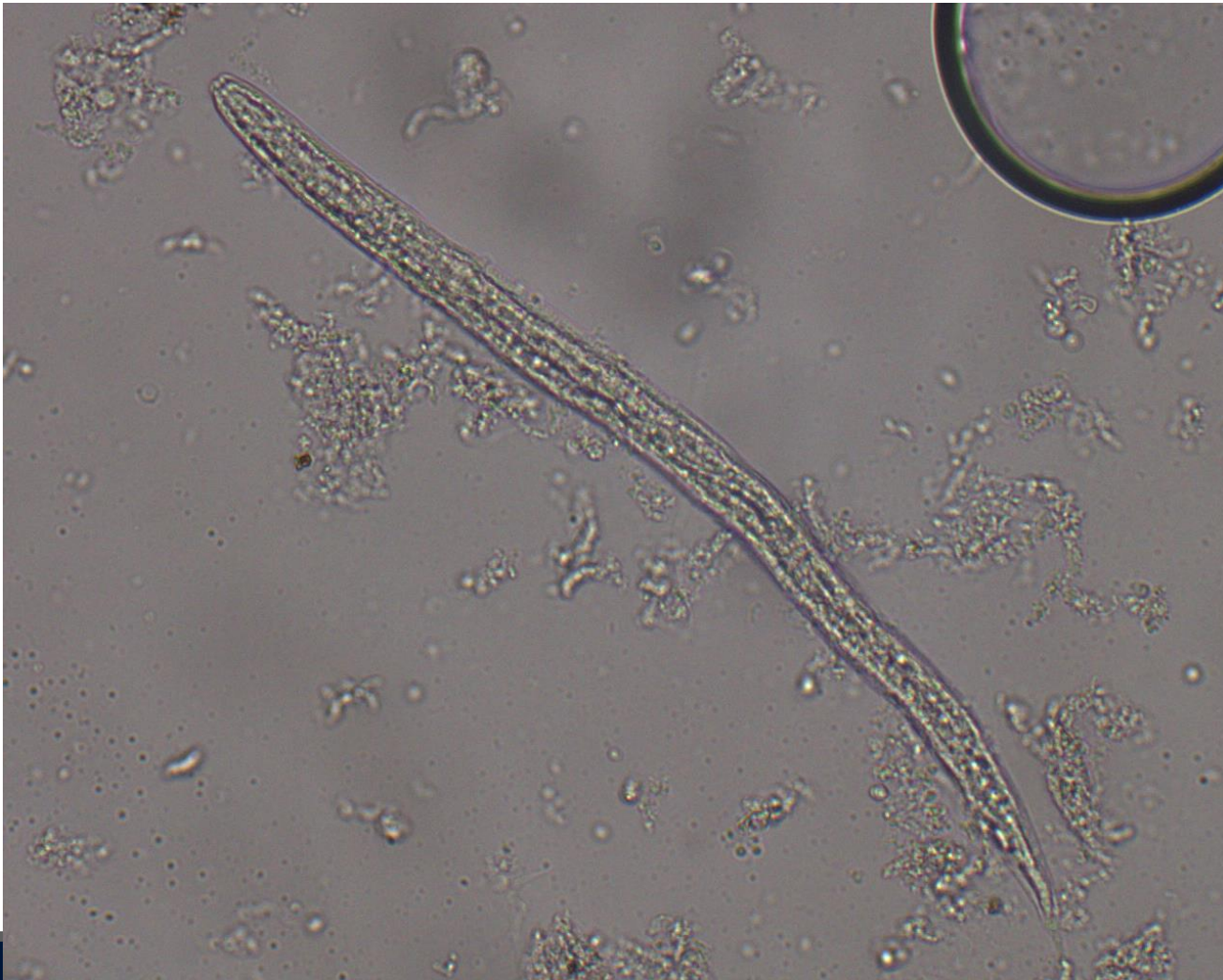- A homeless man in his 50's presented with four days of abdominal pain, vomiting, and constipation. He had recently been a victim of physical trauma after a physical assault..
- He had immigrated from Africa 25 years prior.
- Presumptive diagnosis of cholangitis and pancreatitis.
- Non-contrast CT scan revealed gall bladder distension, interhepatic and extrahepatic biliary ductal dilation, and dilation of the common bile duct without visible obstruction. Pancreatic duct was not dilated.
- ERCP revealed normal upper GI tract.
- Contrast-enhanced pancreatic dual phase CT revealed near total thrombotic occlusion of the portal venous system; extrahepatic portal was patent; confirmed gall bladder distention; cholecystitis was diagnosed and a percutaneous biliary tube was placed. Portal vein thrombus was deemed secondary to cholecystitis and patient was anticoagulated.
- Blood cultures negative, but biliary fluid culture grew *Enterobacter gergoyiae*, *E. cloacae*, and *Candida glabrata*.

Case 6 – Figure 1

- Incidentally, bacterial growth patterns on the BAP plate suggested a motile, possibly parasitic entity.
- O&P exams of the biliary fluid was performed and...



Case 6 – Figure 2



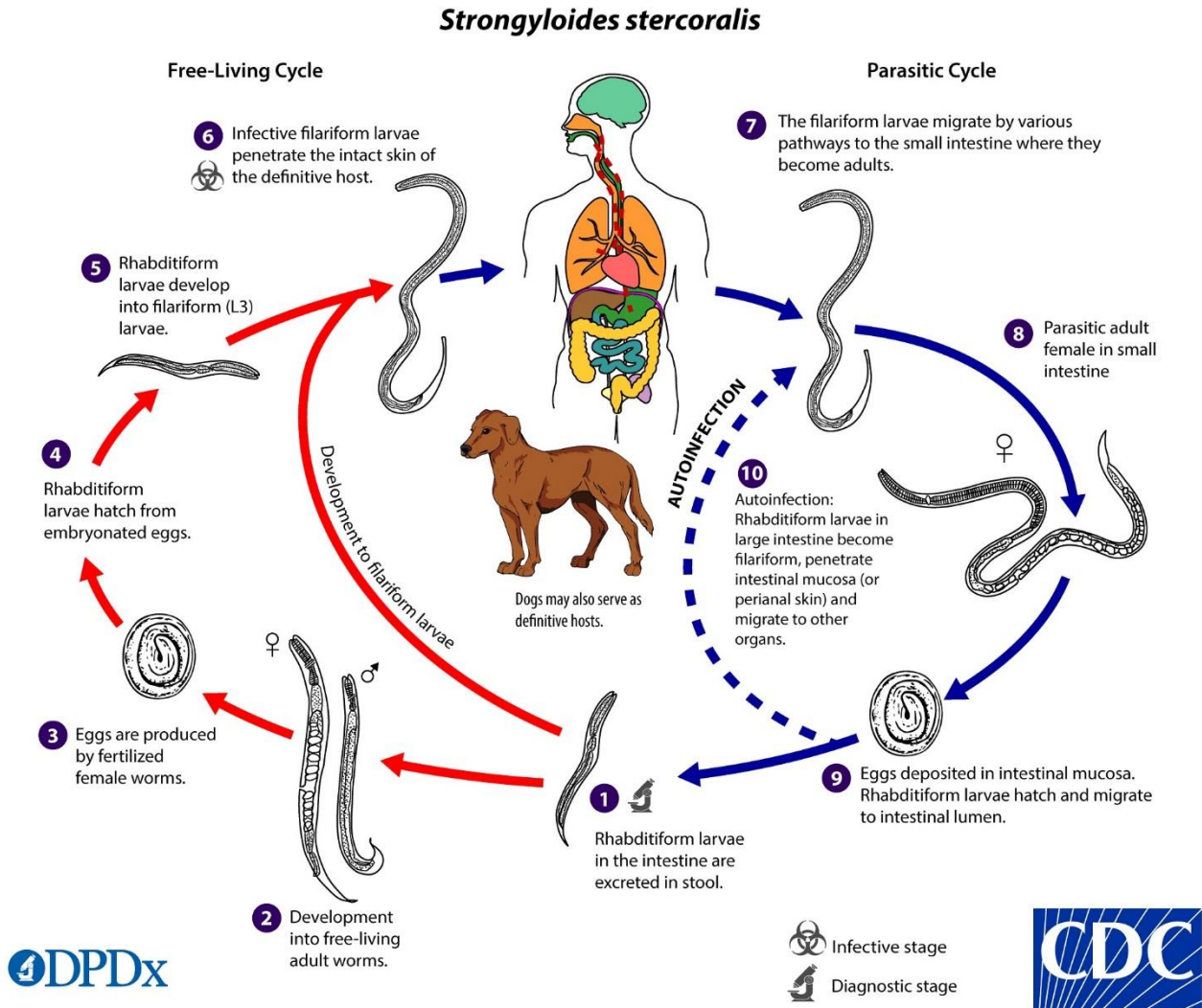
End

Diagnosis: cholecystitis and portal vein thrombosis with non-disseminated strongyloidiasis

- Identification of rhabditiform (L1) larvae of *Strongyloides stercoralis*. Three interesting points:
 - 1) patient had not been in an ‘endemic’ region for 25 years
 - 2) was immunocompetent and was not on steroid therapy
 - 3) serology was negative for strongyloidiasis
- Stool O&P examinations were not ordered (physician did not think it was relevant for clinical diagnosis).
- Patient was administered 15 mg ivermectin daily for 2 weeks without complication.

Filkins LM, *et al.* OFID 2017

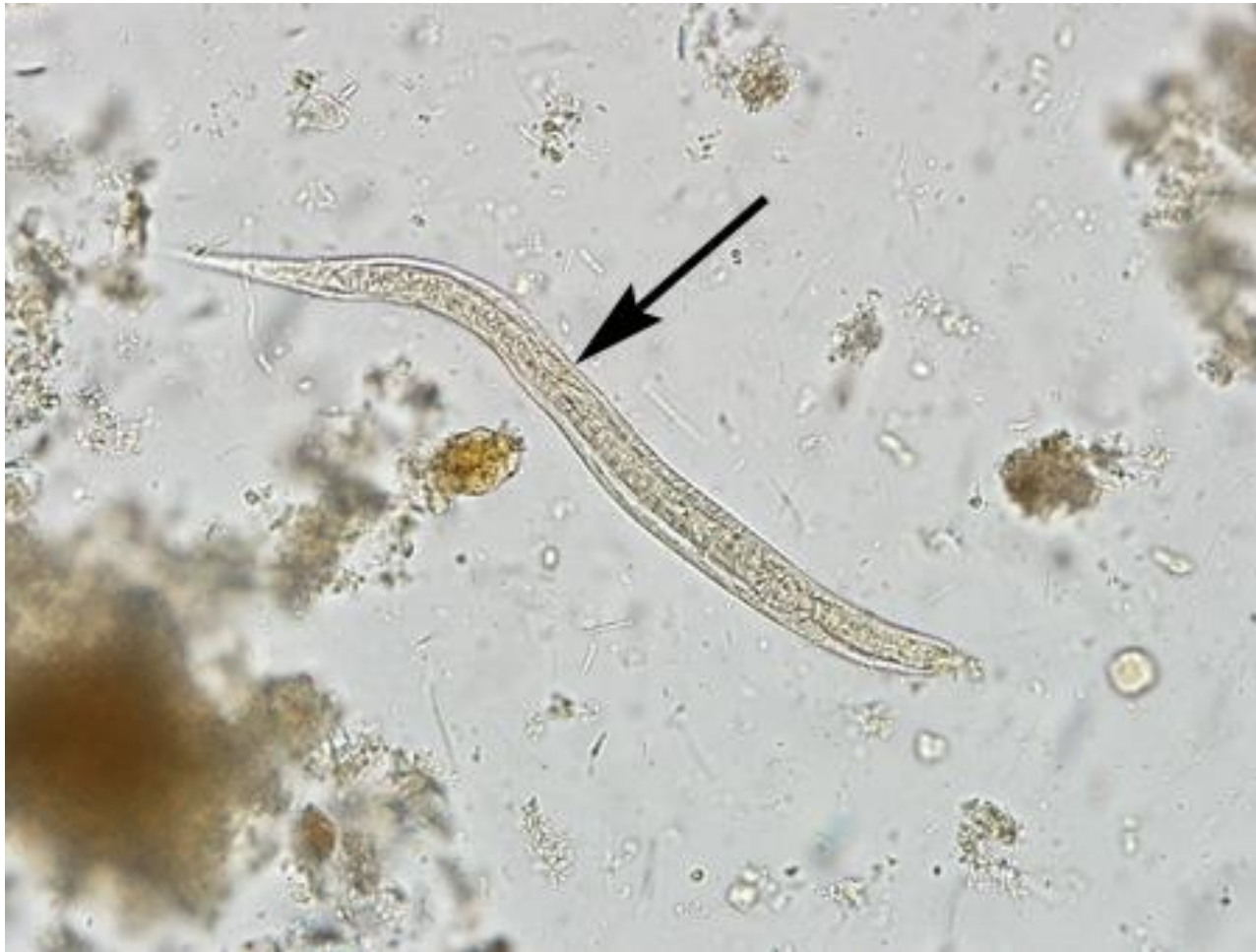Life Cycle of *Strongyloides stercoralis*



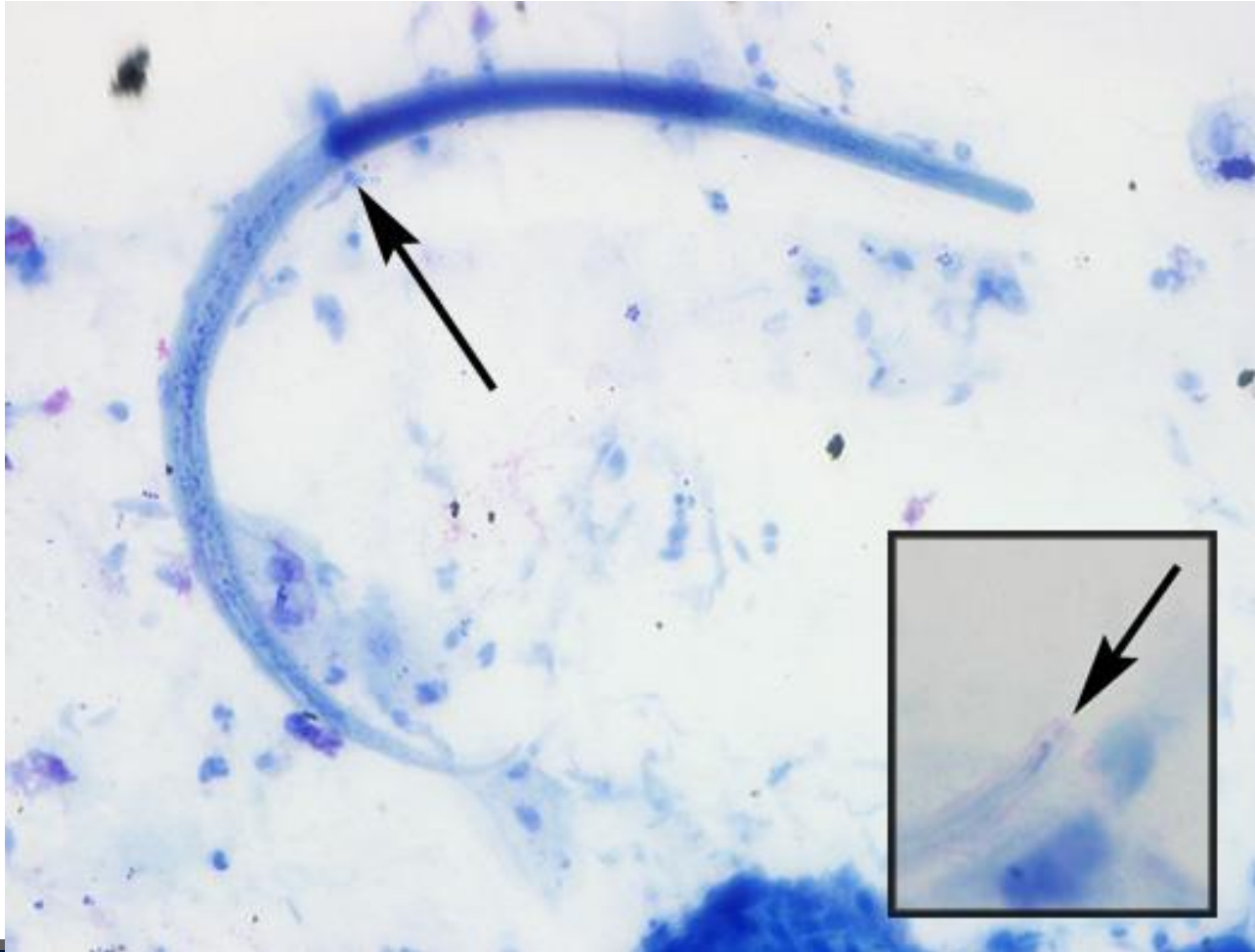
Plausible explanations for gall bladder involvement without true dissemination?

- What is the role of *S. stercoralis* leading to cholecystitis?
 - 1) alone or in conjunction with *Enterobacter*?
- How did the *S. stercoralis* colonize the gall bladder without true dissemination?
 - 1) reflux of duodenal contents through a dysfunctional sphincter of Oddi [patient was on Tramadol for a month before case presentation, and is documented to cause relaxation of the sphincter of Oddi]
 - 2) introduction upon ERCP and biliary stent placement
 - 3) natural, low level migration of the biliary system due to colonization of the upper small intestine/duodenum

Strongyloides stercoralis: L1 larvae in stool



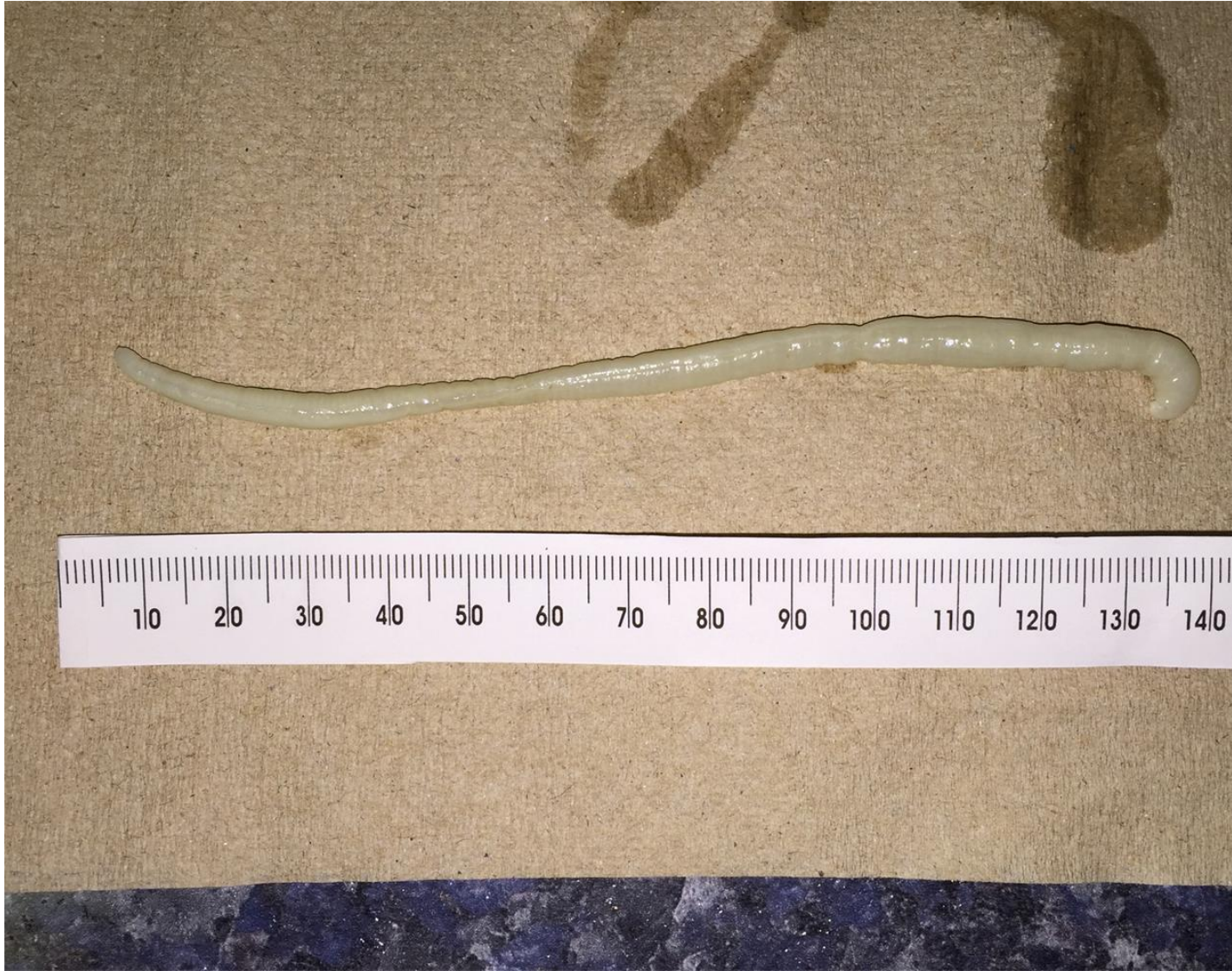Strongyloides stercoralis: L3 larvae in sputum

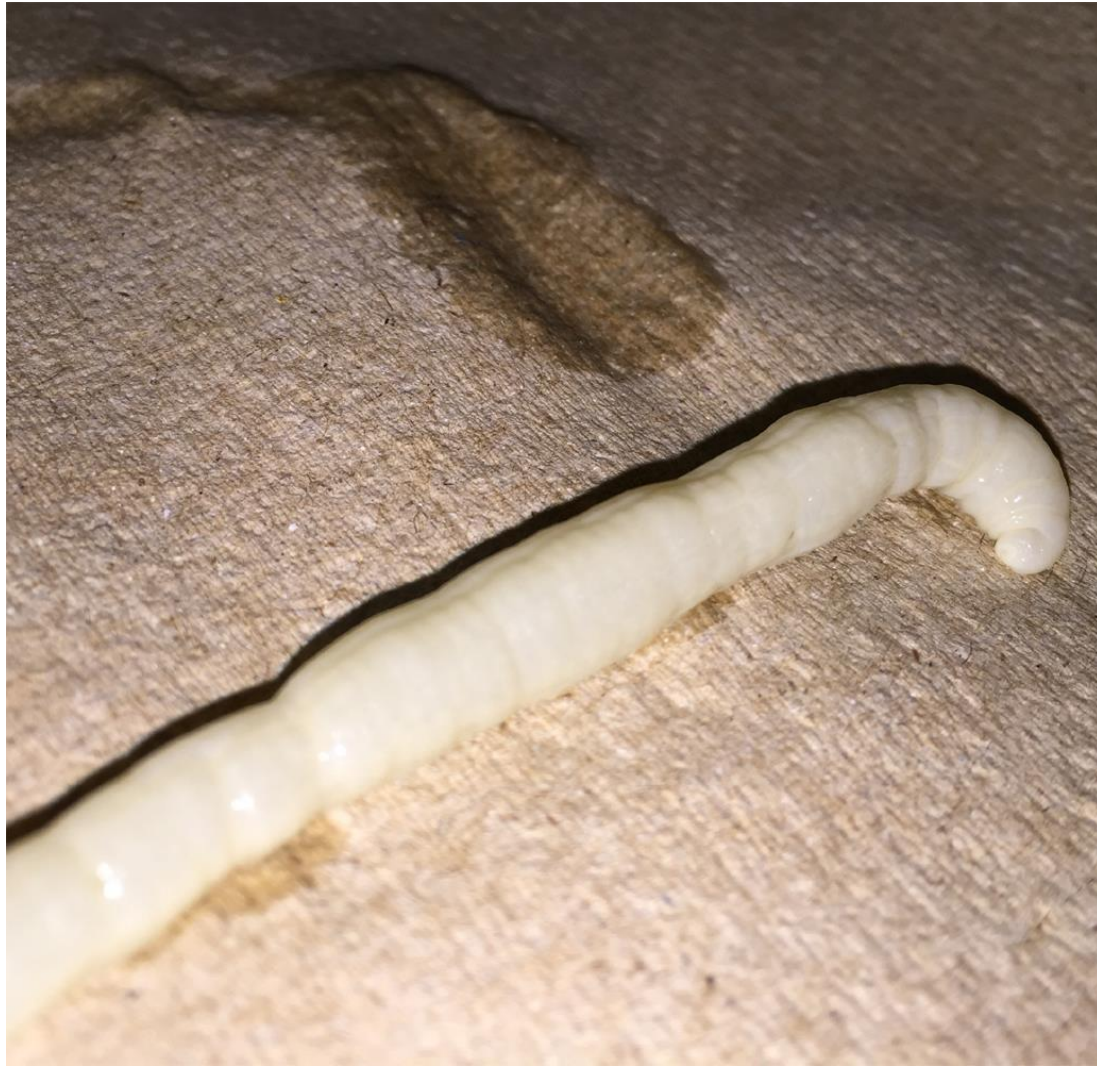

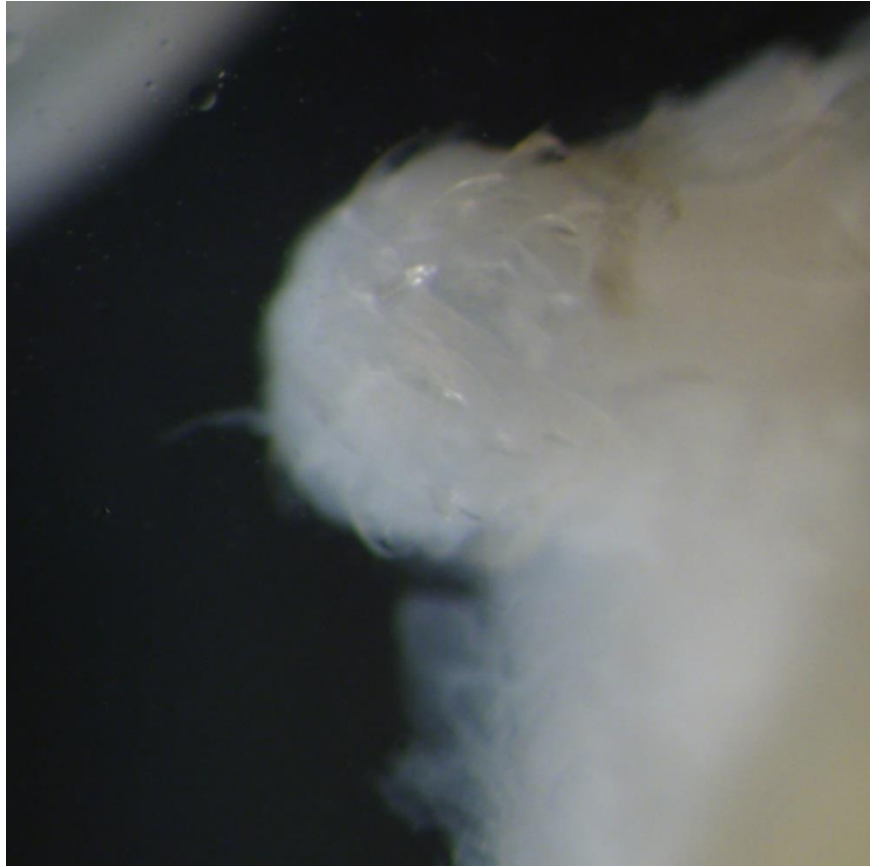
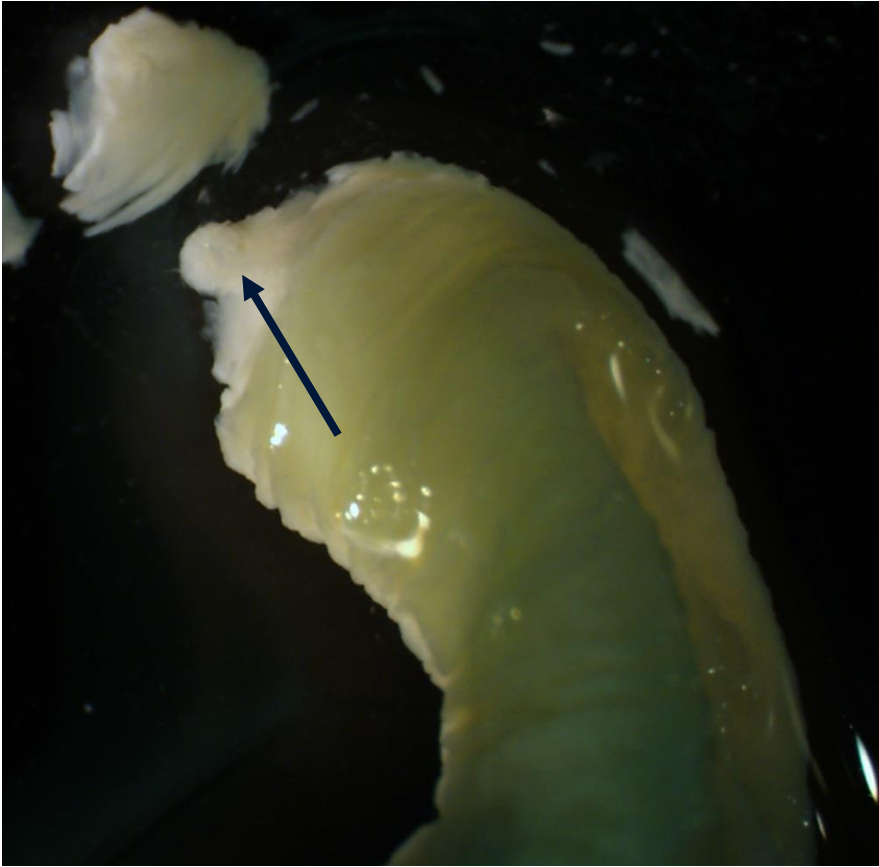
Chapter 3: Worms You Can Get from Your Garden!

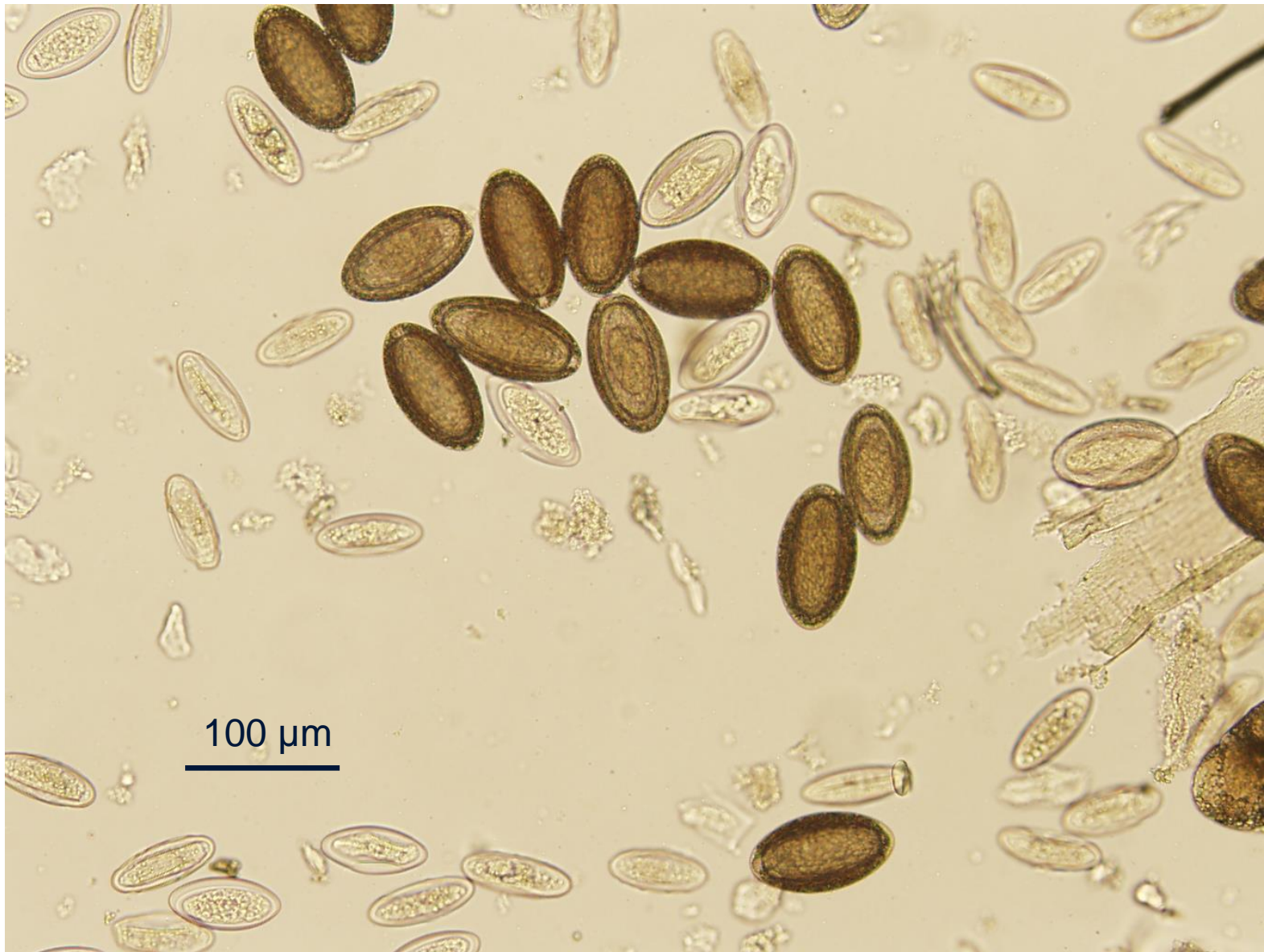Case Presentation

- An 18 m.o. female presented to her pediatrician after a pinkish-white worm-like object, two to three inches in length, that was seen in the diaper upon changing.
- Stool was sent for ova-and-parasite (O&P) exams, which were negative x 3.
- Three months later, another white worm was seen, although this one was larger. This was followed two days later by a slightly larger worm again seen in the stool.
- Repeat O&P exams continued to be negative.
- The girl's pediatrician sent one of these worms to a local hospital microbiology laboratory and another to a commercial reference laboratory for analysis. Both were reported as "segmented worm, not consistent with human parasite."
- No international travel. Diet included organic fruits and vegetables. No pets, no known animal contacts, but the mother reported millipedes in the garden.







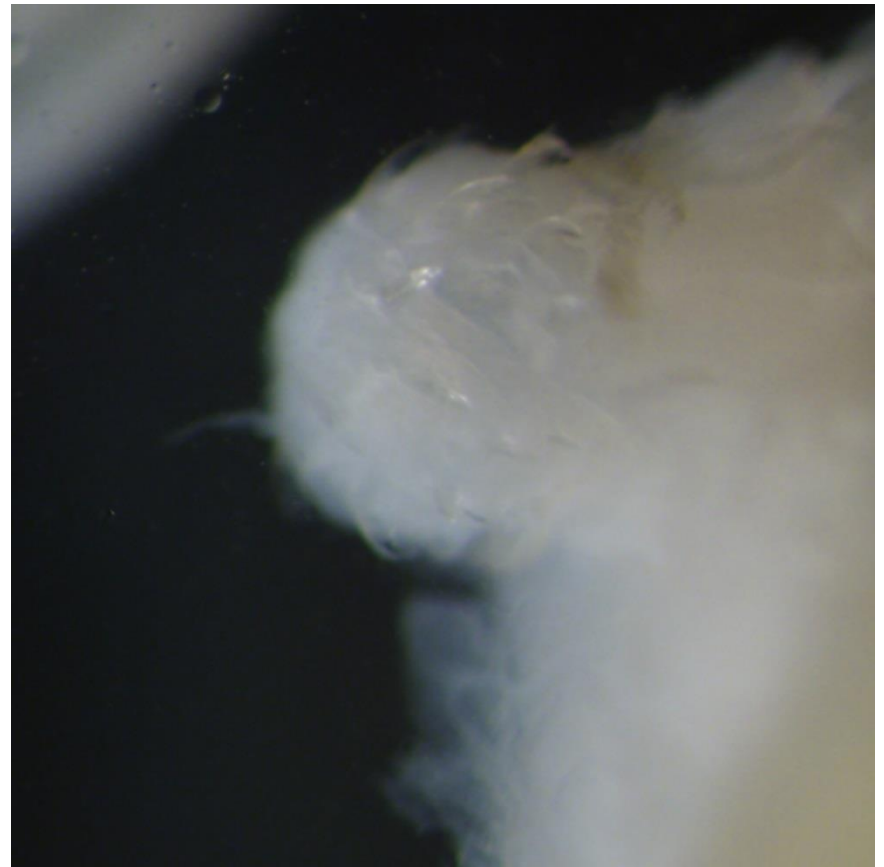

End

Diagnosis: Acanthacephaliasis caused by *Macracanthorynchus ingens*.

- A large, pseudo-segmented worm-like organism.
- Armed rostellum
- Absence of eggs in stool.
- Millipedes (seen in the garden) are natural intermediate host.

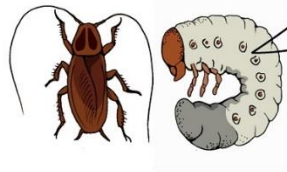
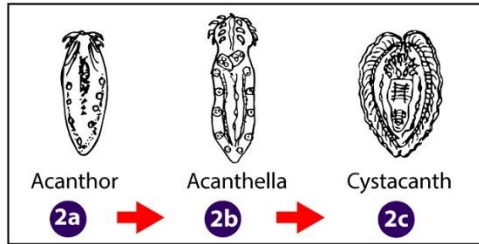
Mathison BA, et al. *Clin Infect Dis*. 2016; 63: 1357-1359.




Life Cycle of Acanthocephalans

1DPDX

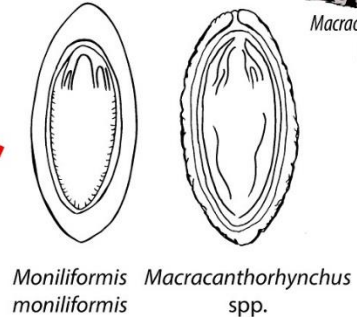
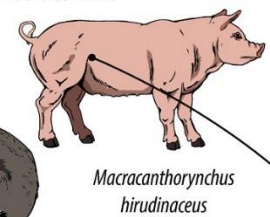

Acanthocephala



2 Eggs ingested by arthropod intermediate host

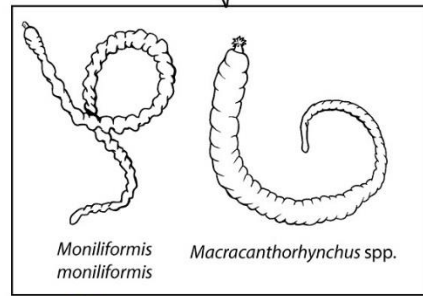
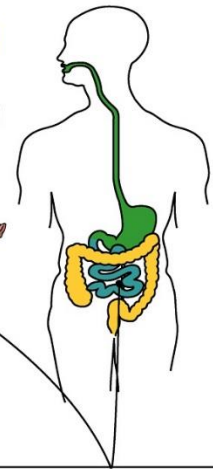


3 Definitive host becomes infected by ingestion of infected intermediate host



1 Eggs shed in feces

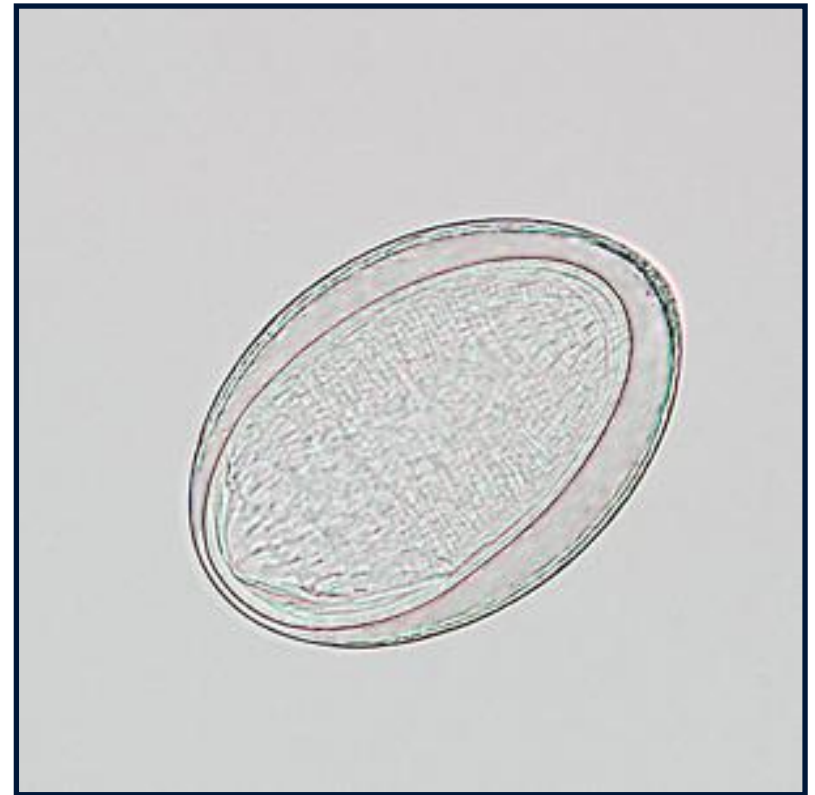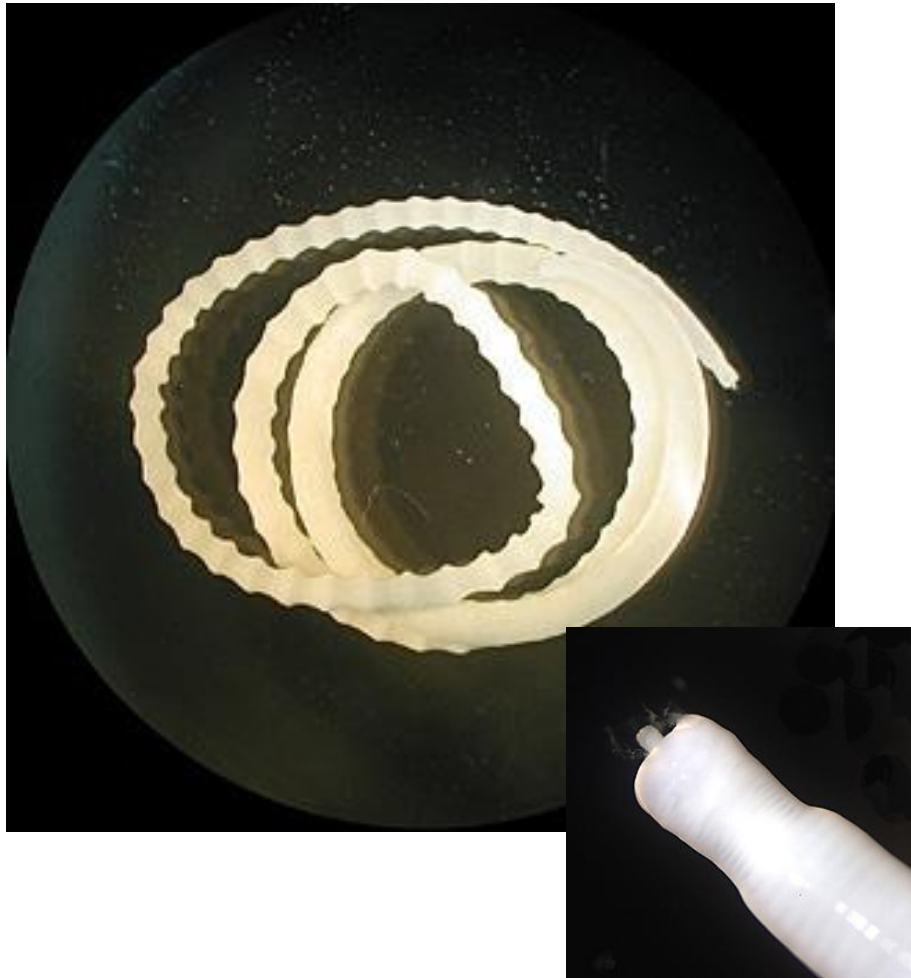5 Aberrant Human Infection



4 Adults in small intestine

Infective stage
 Diagnostic stage

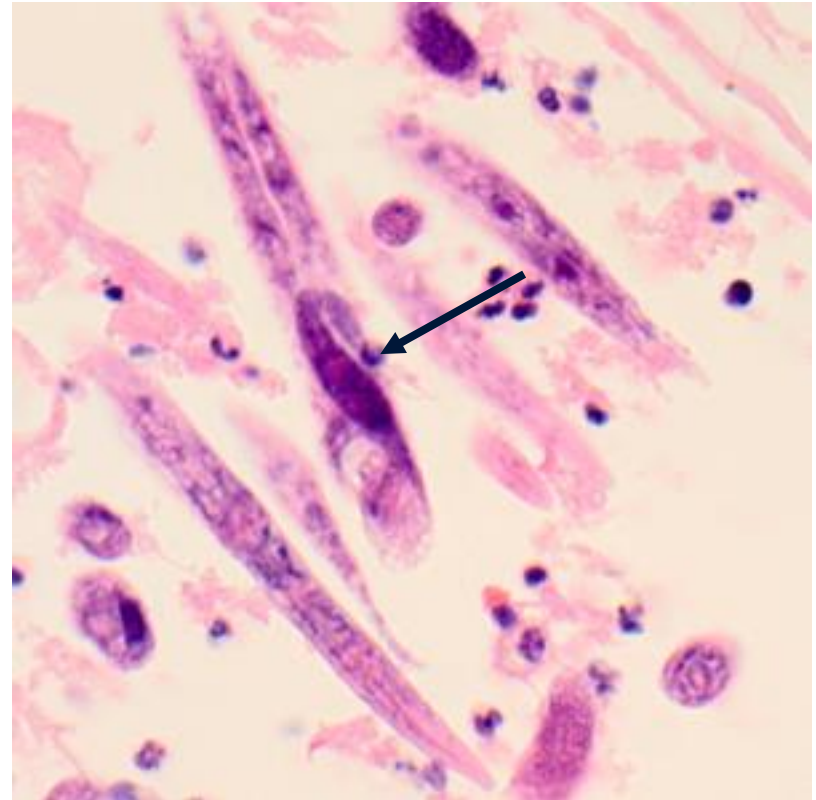
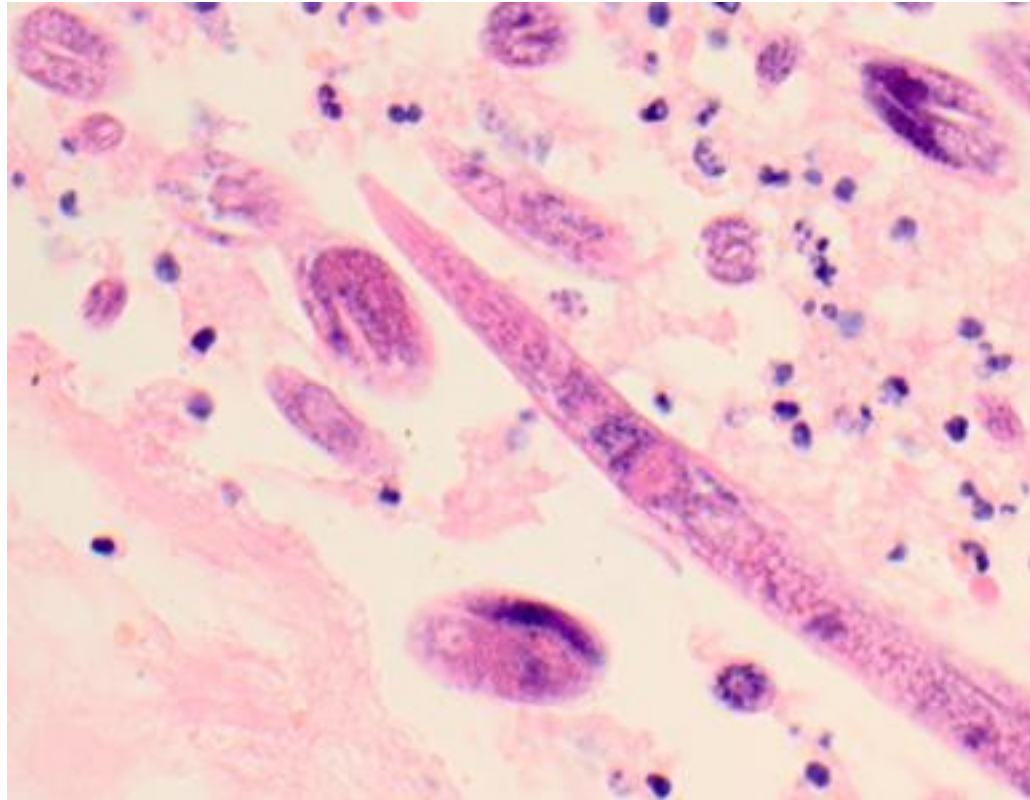
Moniliformis moniliformis

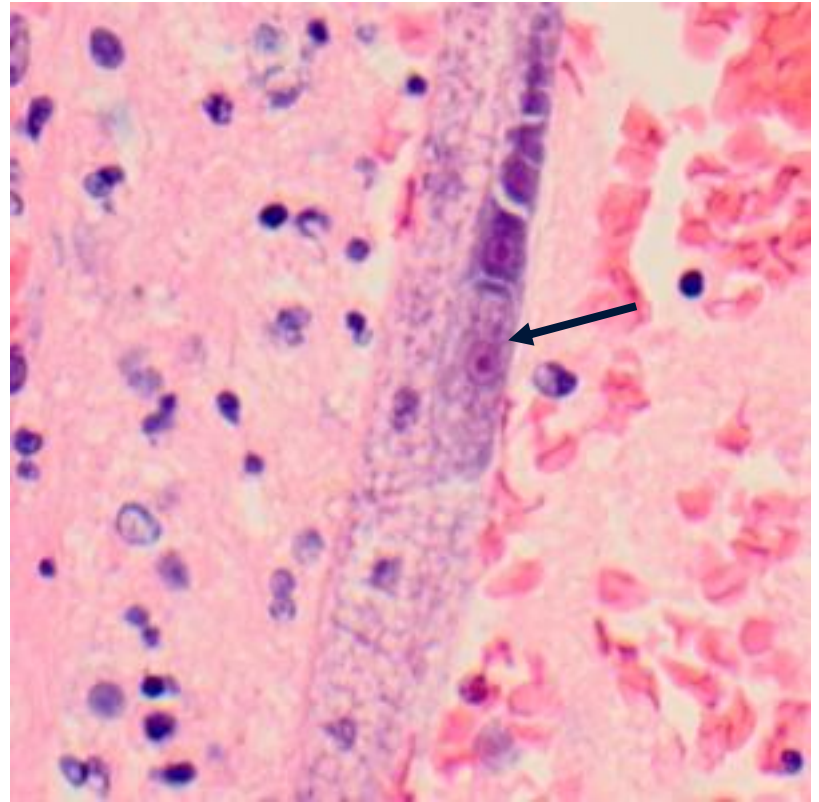
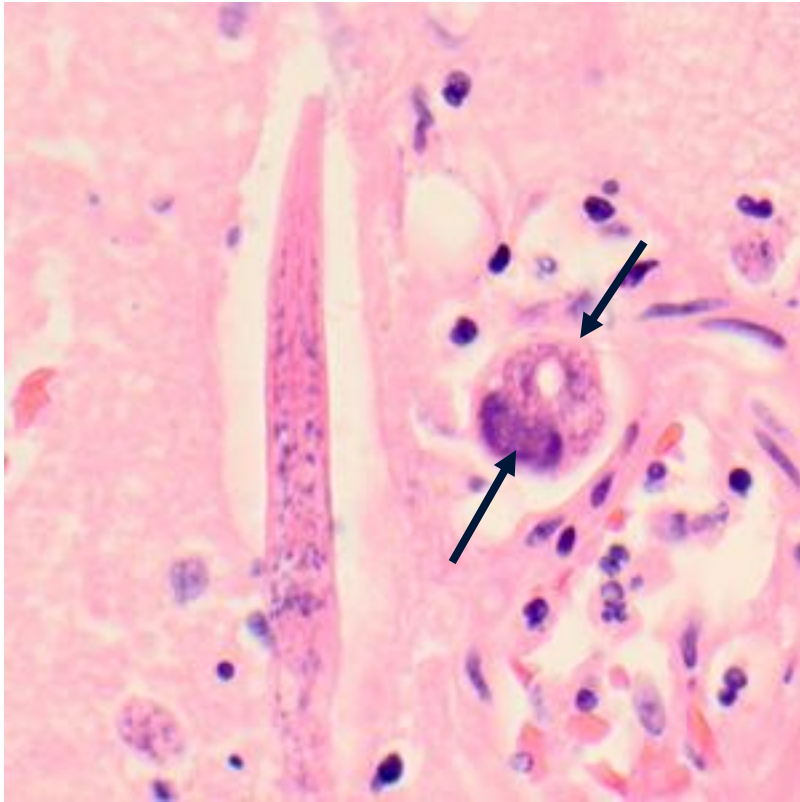


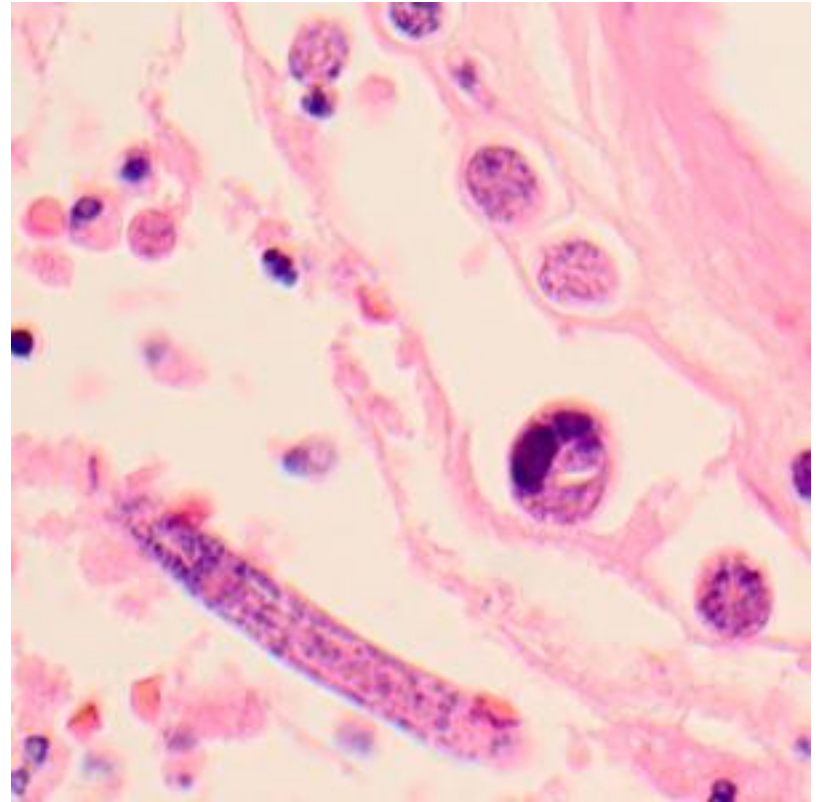
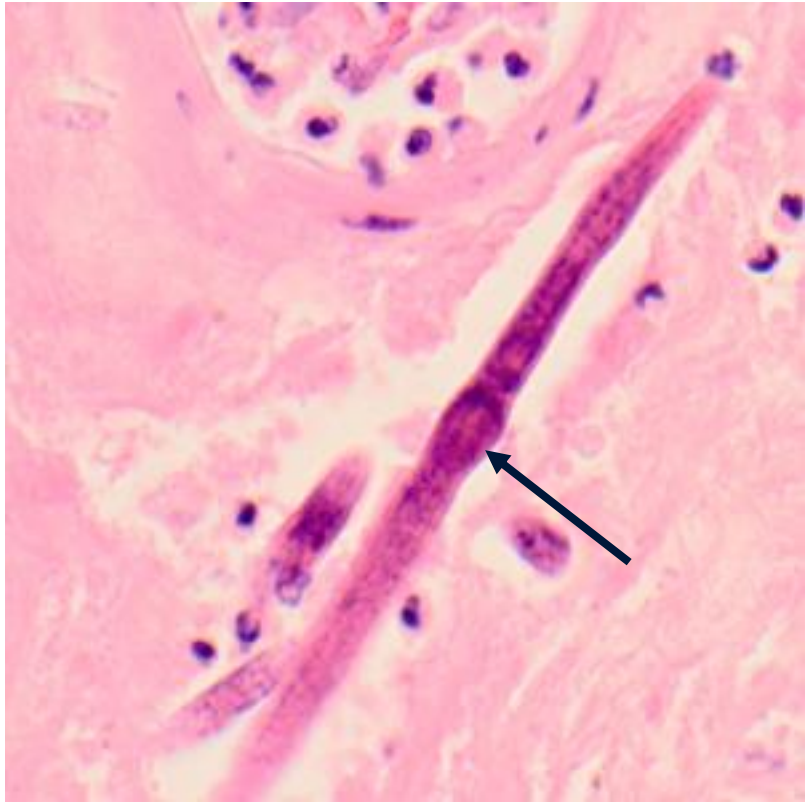
Chapter 4: Hoarders, Horses, and Headaches

Case Presentation

- A 65-year-old female was admitted to the hospital with fever, nausea, and vomiting after recently being treated as an outpatient for a urinary tract infection caused by *Klebsiella*.
- Her past medical history included being diagnosed with chronic back pain, bipolar disorder, hypertension, osteoarthritis, and compression fractures. She was described as a 'hoarder'.
- She was a smoker but denied alcohol use.
- Her only known animal contacts were her pet dogs.
- During hospitalization, she had blurring of vision in her left eye and tenderness in the left temporal area. Her mental health continued to decline and she was pronounced brain-dead after one month's stay at the hospital.
- CT and MRI scans of her brain prior to death did not show any focal lesions. An autopsy was performed and cultures of brain tissue were negative for bacterial and viral agents.
- Sections of brain tissue were processed by Pathology and stained with hematoxylin and eosin (H&E).



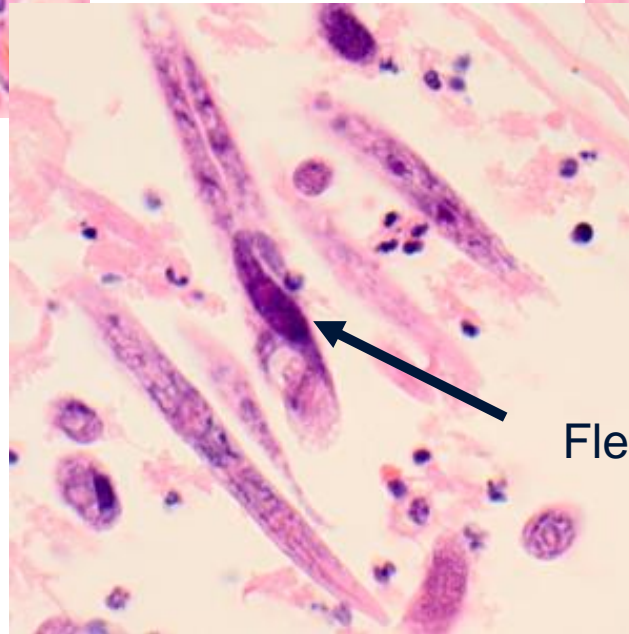
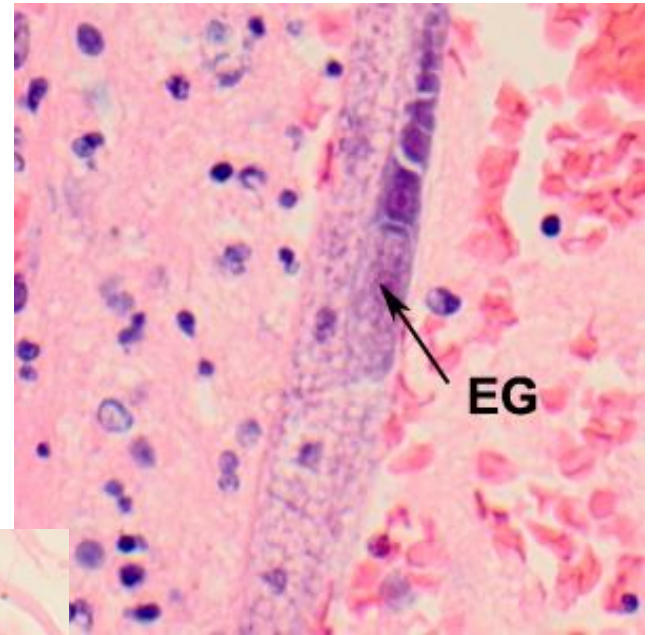
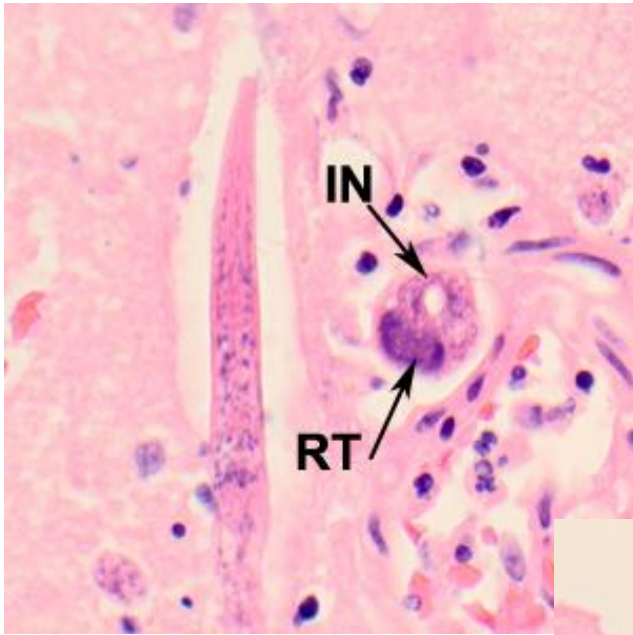




End Case

Diagnosis: meningioencephalitis caused by *Halicephalobus* (prob. *H. gingivalis*)

- *Halicephalobus* spp. Are free-living nematodes associated with damp soil environments.
- *Halicephalobus mephisto* is found at 2.2 miles beneath the surface of the earth in South Africa (only multicellular animal found below 1.2 miles below the surface of the earth).
- Individual males and females occur in the environment where sexual reproduction takes place, but in mammal host only parasitic females are known that reproduce parthenogenetically.
- Route of infection unknown; most cases involve the CNS and are diagnosed on autopsy. One case of transplant-associated infection (kidneys).
- Veterinary importance in horses, causing systemic infections.



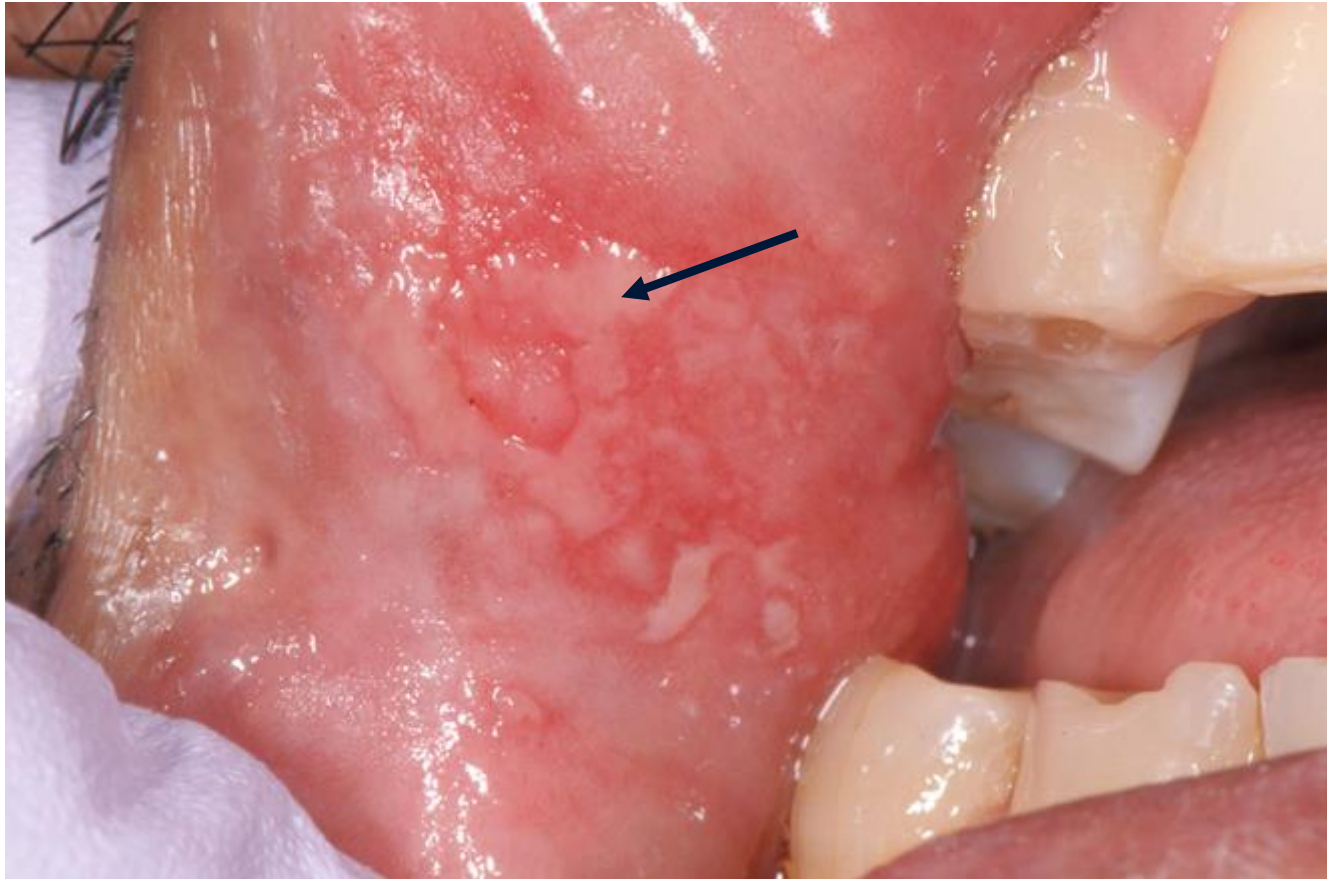Flexed ovary

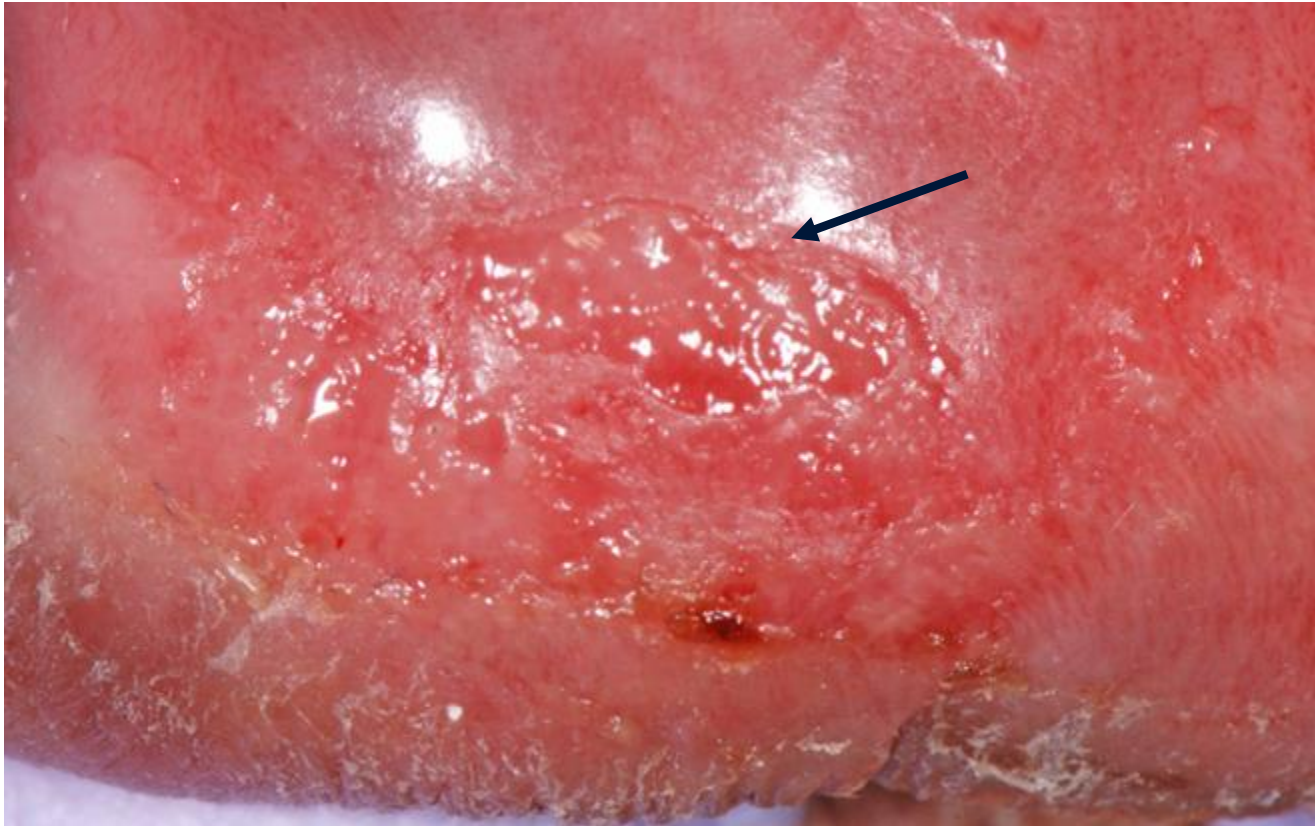
Papadi B, et al. *Am J Trop Med Hyg.* 2013; 88: 1062-1064

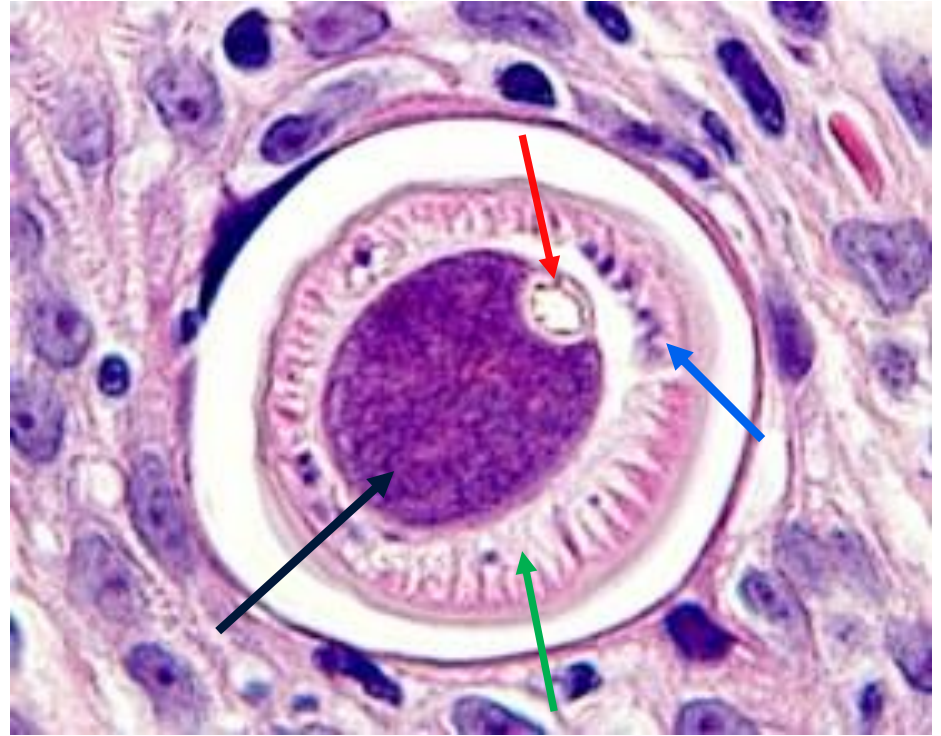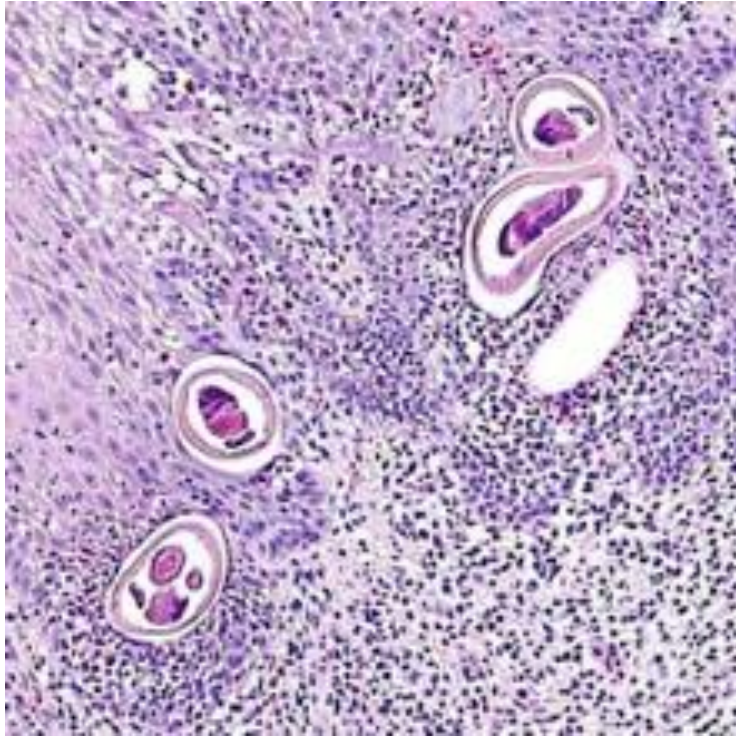
Chapter 5:
HELMINTHOLOGY: What a
Mouthful!

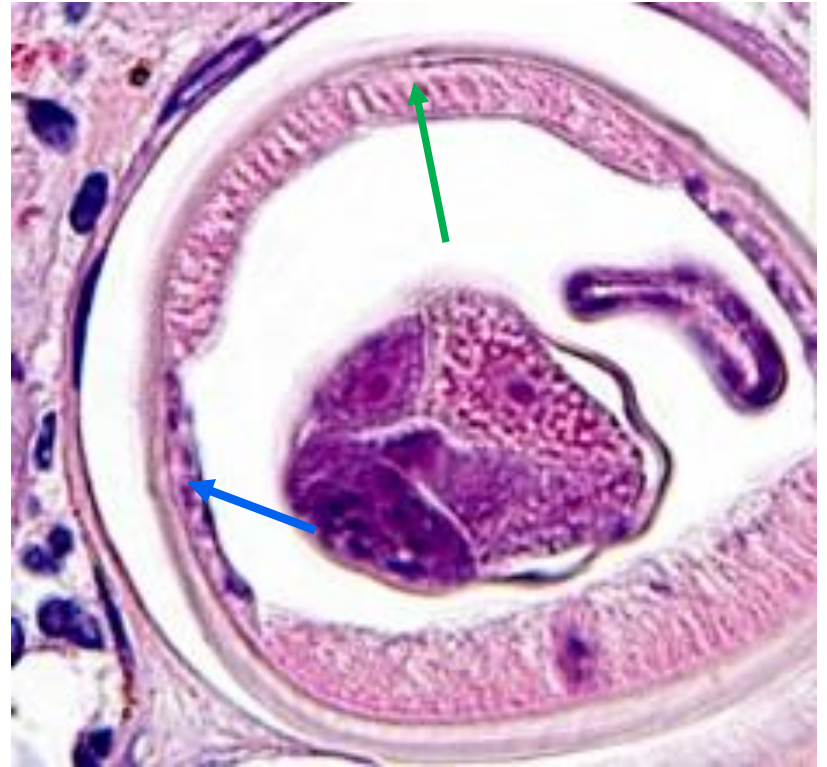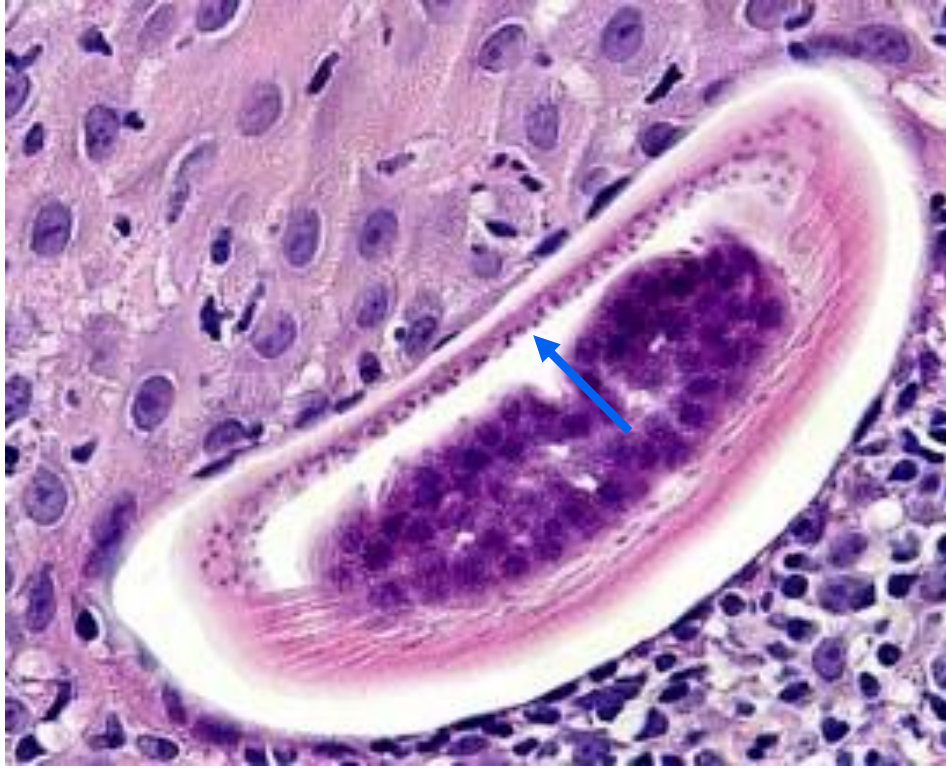Case Presentation

- A 44-year-old Hispanic male presented for a lump in his throat in 2010.
- Originally from Mexico, but spent the last 20 years in Illinois, with recent trips back to Mexico in 2008 and 2009. Currently works as a landscaper, formerly in a foundry and on a pig farm.
- PMH includes hypertension; no known environmental allergies.
- At clinical presentation, patient has multiple oral and lip ulcers and two indurated submucosal nodules.
- Biopsies of the nodules were sent to Pathology for routine histopathology work-up, including H&E staining.









End Case

Diagnosis: *Anatrichosoma* species.

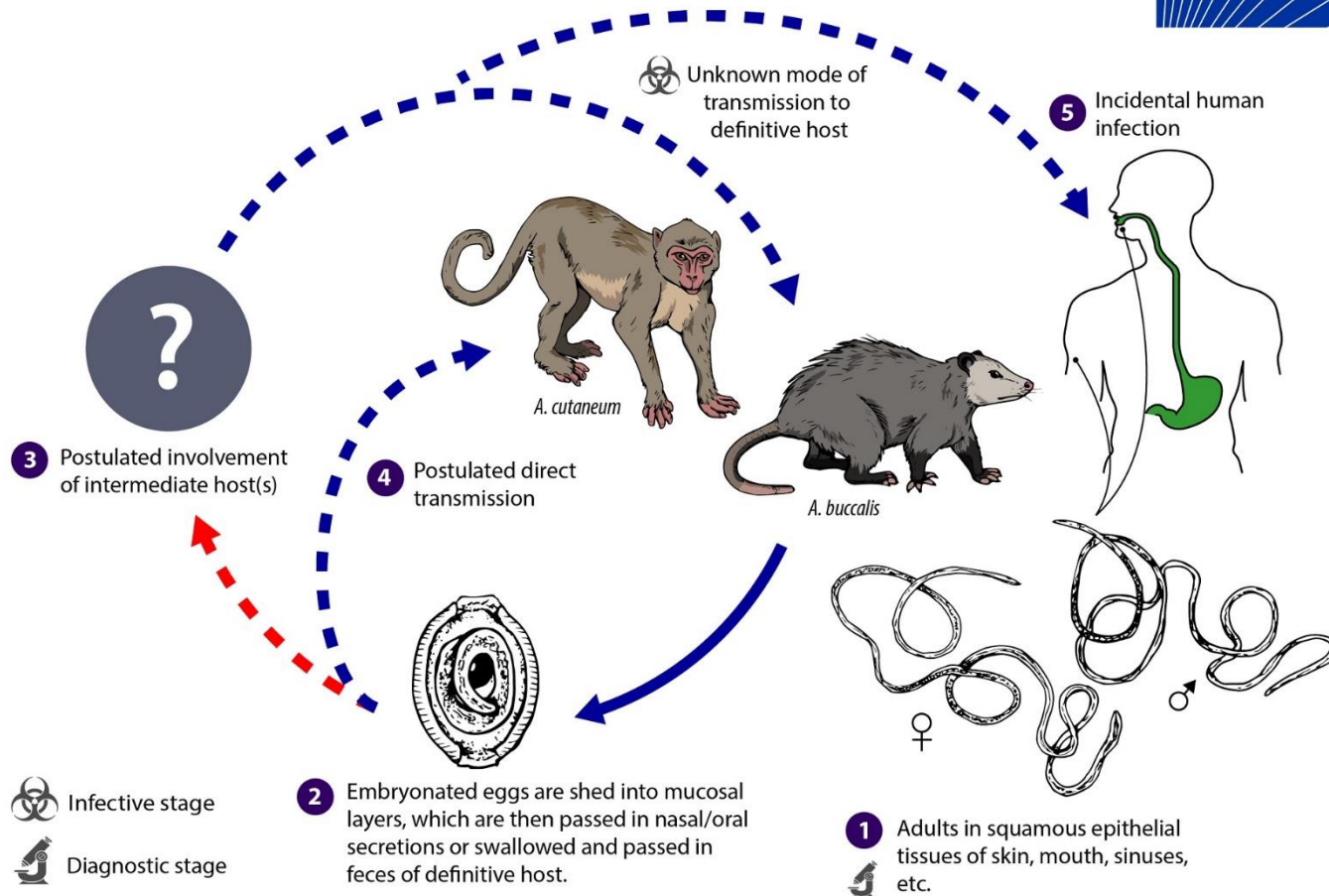
- *Anatrichosoma* spp. are trichurid nematodes related to *Trichuris*, *Trichinella*, and *Capillaria*.
- Life cycle not completely understood.
- Definitive hosts in nature include for *A. buccalis* (opossums, North America), *A. cynamolgi* (rhesus monkeys, SE Asia), *A. ocularis* (tree shrews, Malaysia).
- Human cases are rare, being documented from Japan, Vietnam, and Malaysia (skin lesions) and one from Italy (breast biopsy, co-infection with *Dirofilaria*).
- This was the first documented oral case, suggesting *A. buccalis*.
- In 2014 a second report of oral anatrachosomiasis was published where worms were found in a mother and daughter with travel to Mexico that participated in 'snail facials'.

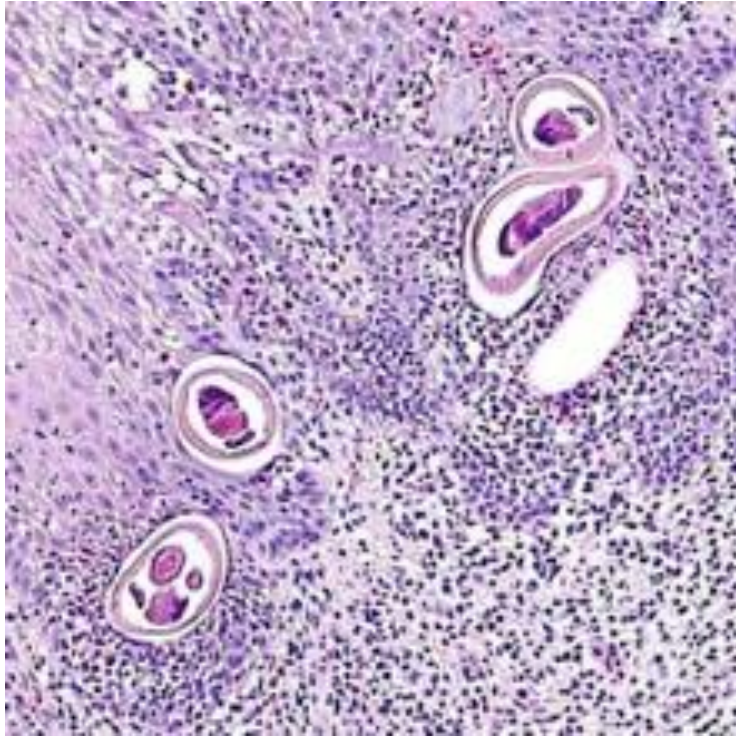
Eberhard ML, et al. *Am J Trop Med Hyg.* 2010; 83: 342-344.

Proposed Life Cycle of *Anatrichosoma* spp.



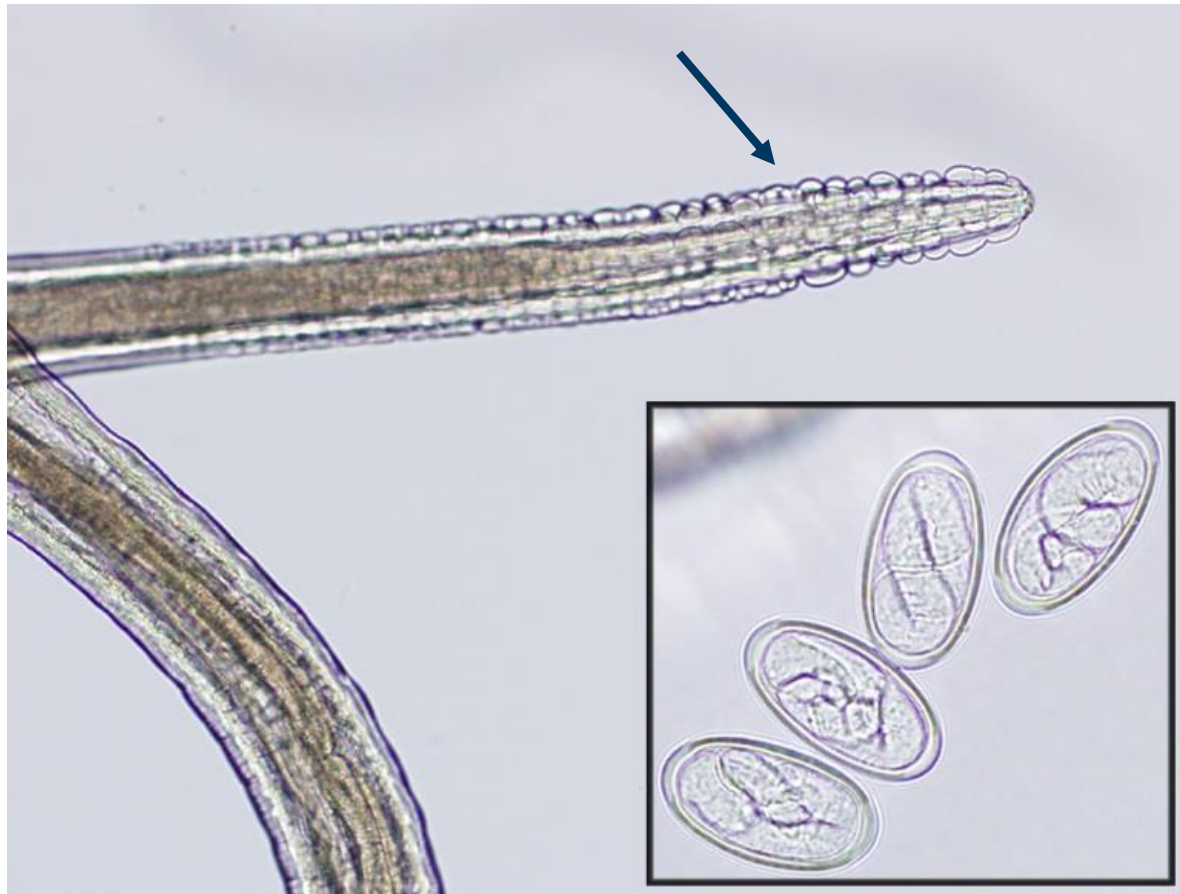Anatrichosoma spp.





- Red arrow: esophagus
- Green arrow: musculature
- Black arrow: stichocyte
- Blue arrow: bacillary bands

Another oral nematode: *Gongylonema pulchrum*



D. Jane Hata, Ph.D.

Chapter 6:

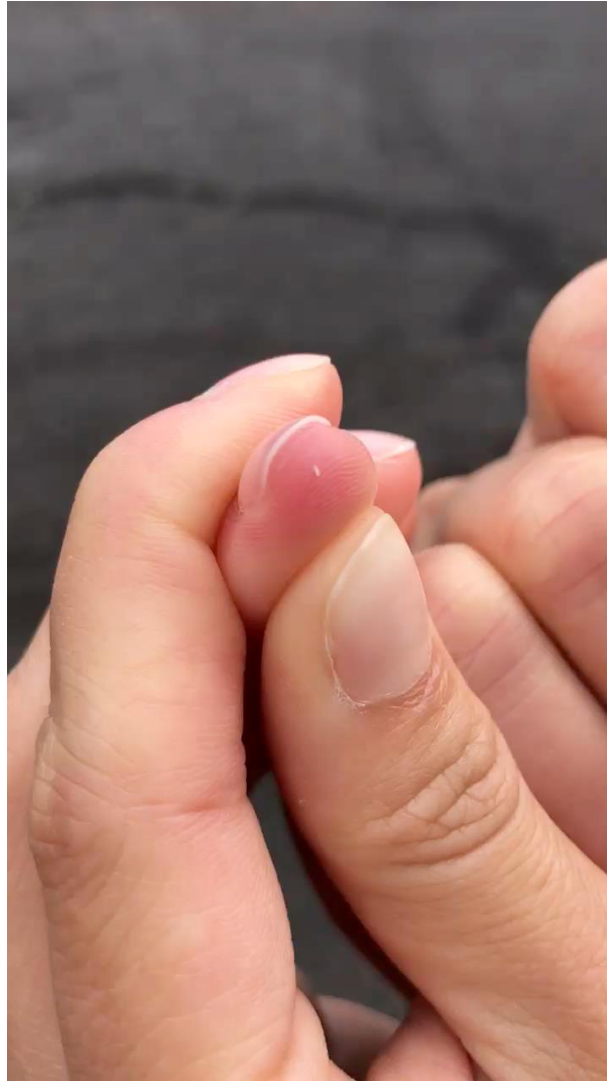Waiter, There's a Fly in my Eye!

Case Presentation

- A 41-year-old male was on vacation in Kona with wife
- While getting out of his car, an insect went into his eye
- Immediately, had tearing, eye was very irritated
- Bought saline at Target, flushed his eye, wife thought she saw something moving
- Went to ER, slit lamp exam neg for corneal abrasion, no labs/imaging done, discharged
- Eye still very irritated, red
- Past Medical History:
 - Allergic rhinitis
 - LASIK surgery several years ago
 - Non-smoker; rare drinker

Case Presentation (cont'd)

- Wife notices 3 moving objects in his eye, and pulls them out
- Specimens were collected in a ChapStik tube and brought back to their PCP at the University of Utah...
- Went back to ER, where slit lamp exam reveals 2 more...



Case 6: Microscopic examination



Images courtesy of Dr. Richard Davis, Univ. of Utah

Case 6: Diagnosis: *Oestrus ovis*

- Nearly worldwide in sheep-raising regions.
- Typically resides in the nose and respiratory tract of sheep, goats, other ruminants.
- Females deposit larvae directly on the host.
- Usually manifests as ophthalmomyiasis in humans.


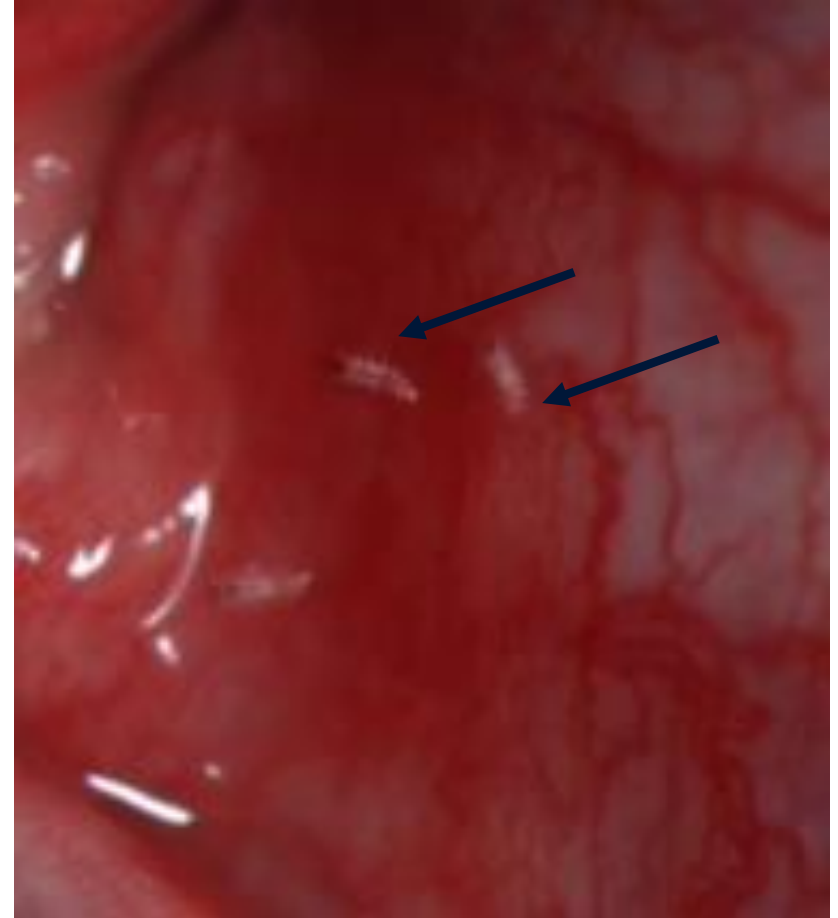
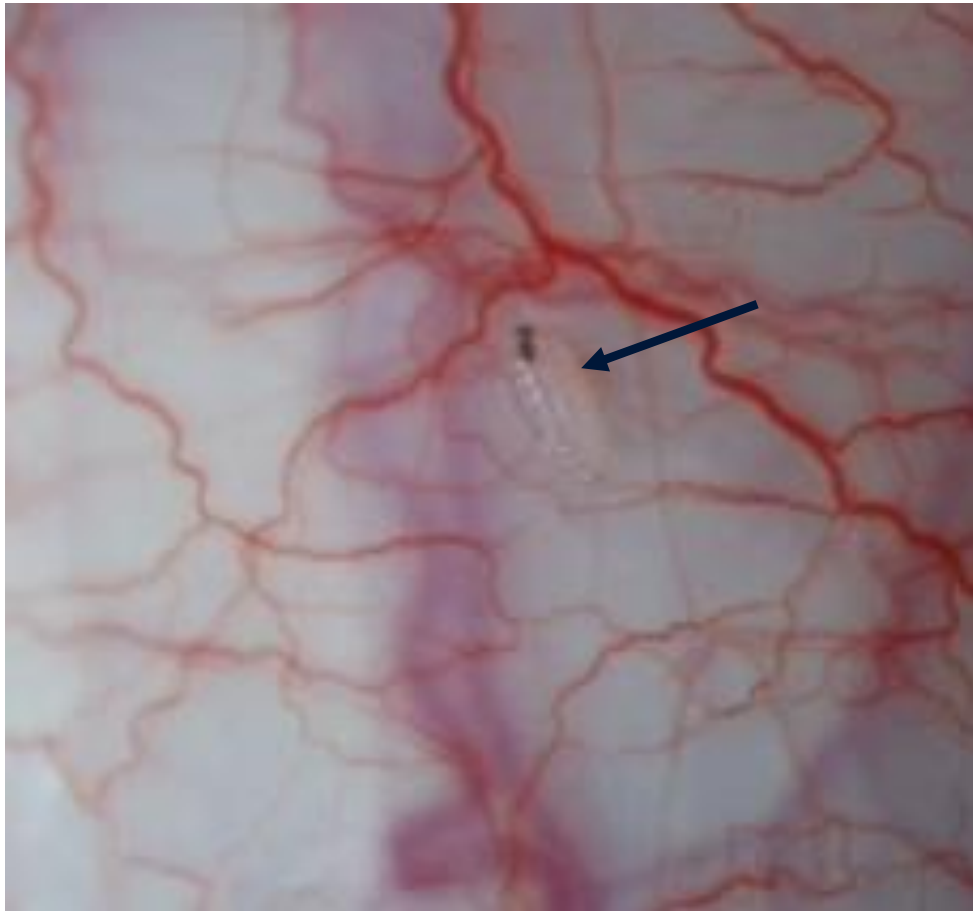


Image courtesy of the CDC-DPDx

Case 6: *Oestrus ovis*, New York ex: Israel

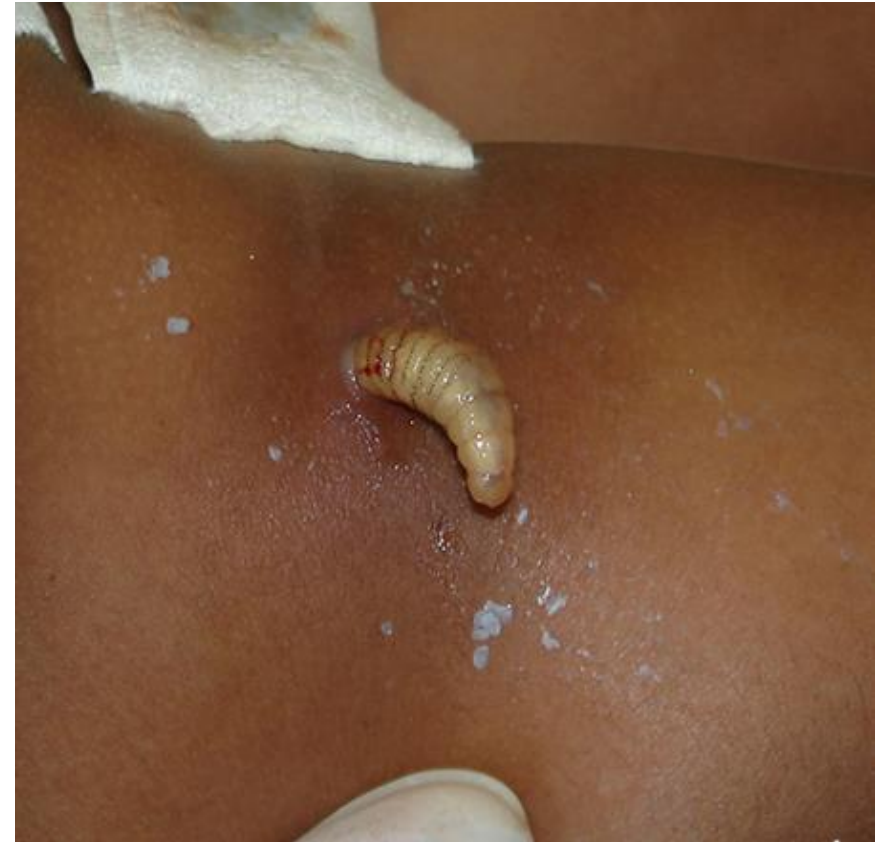
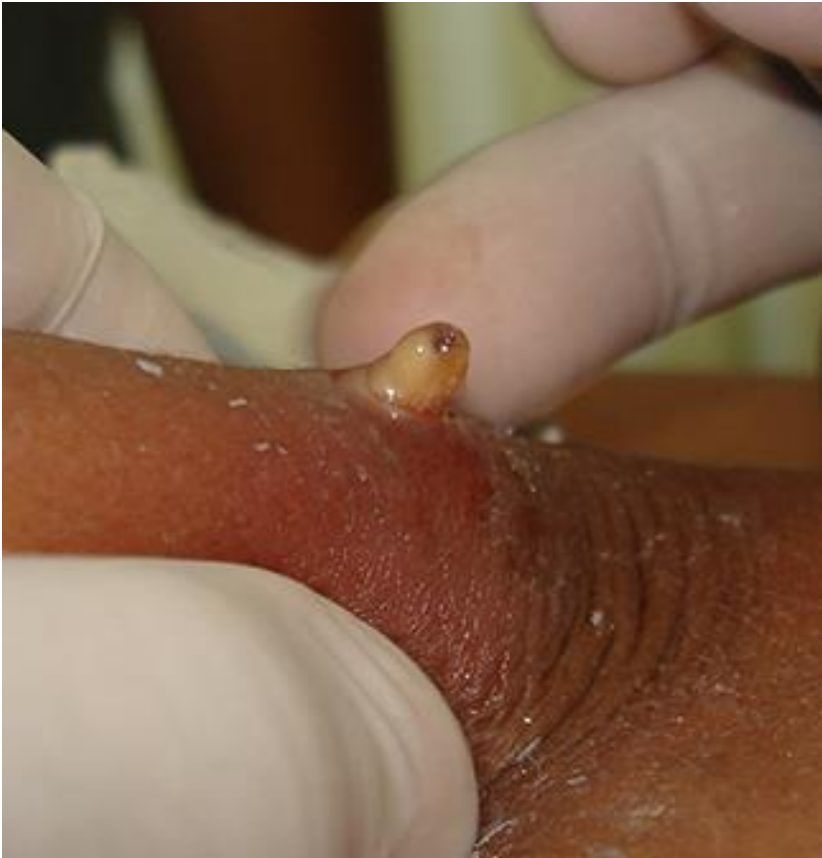
Images courtesy of Carmine Harula, Mt. Sinai Hospital

Myiasis

- **Myiasis** – Infestation with fly larvae (maggots!)
 - **Obligatory Myiasis:** The developing larvae are dependent on host tissue for development and are capable of consuming, and often require, healthy host tissue.
 - **Facultative Myiasis:** The larvae colonize pre-existing wounds and diseased tissue and feed on dead or decaying tissue (some species that initially cause facultative myiasis may go on to attack healthy tissue as well).
 - **Incidental Myiasis:** The human body becomes colonized with normally free-living or saprophagous species.
- Removal is Curative!

Dermatobia hominis; Venezuela



Images courtesy of Dr. Carlos Chaccour, www.parasitewonders.com

Dermatobia hominis

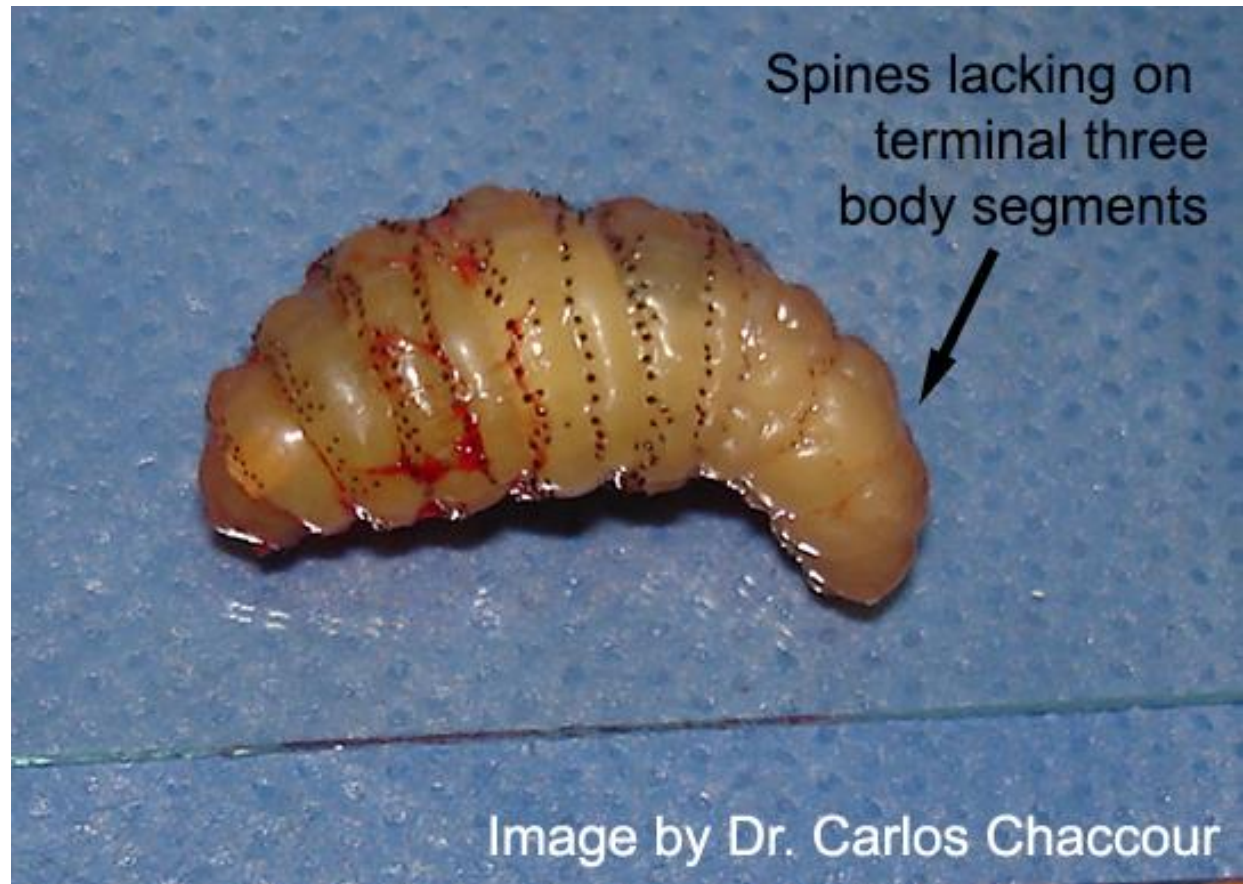
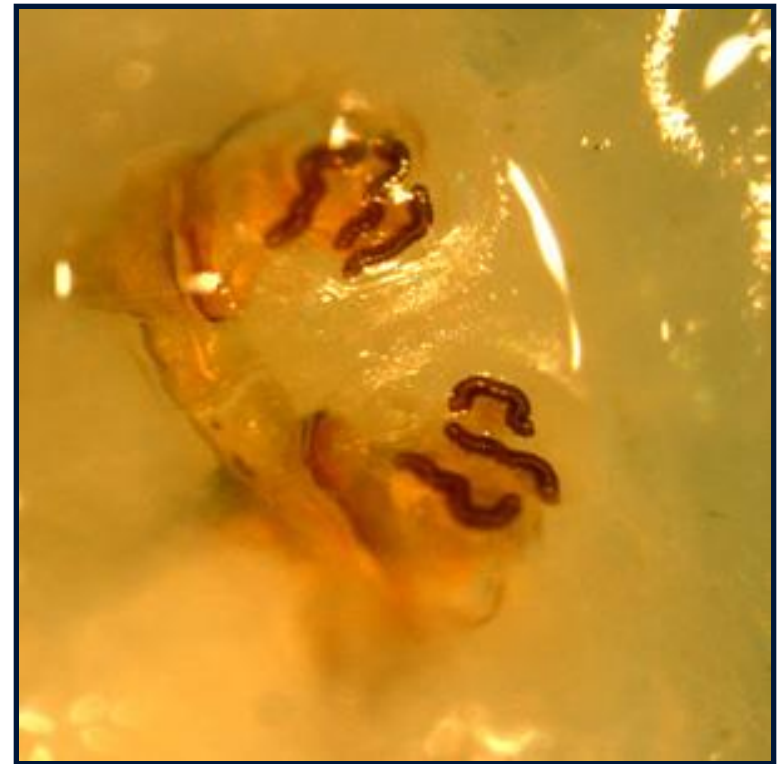


Image courtesy of Dr. Carlos Chaccour, www.parasitewonders.com

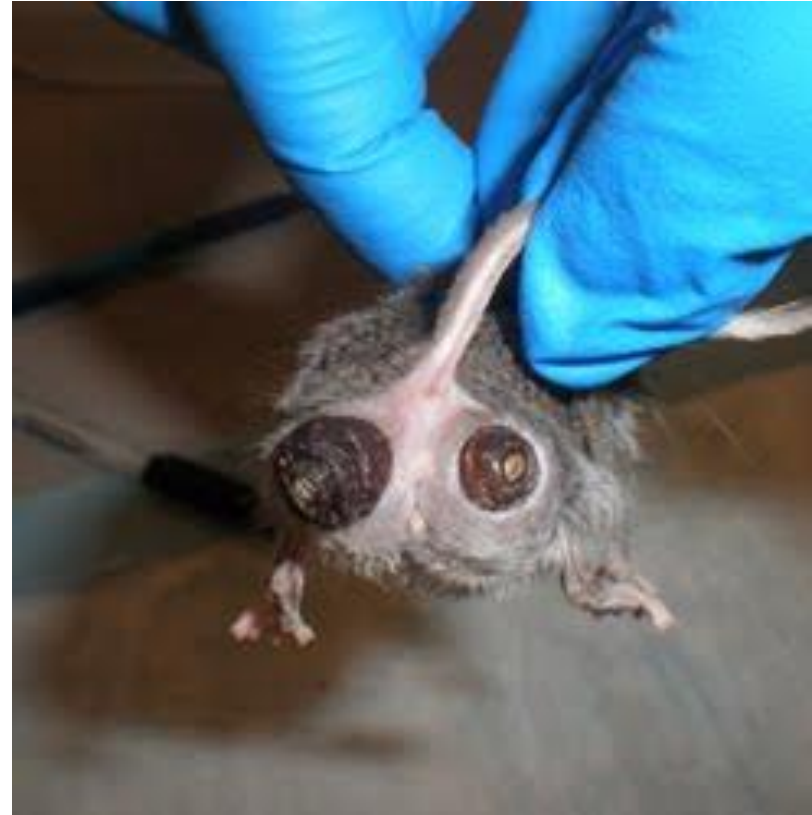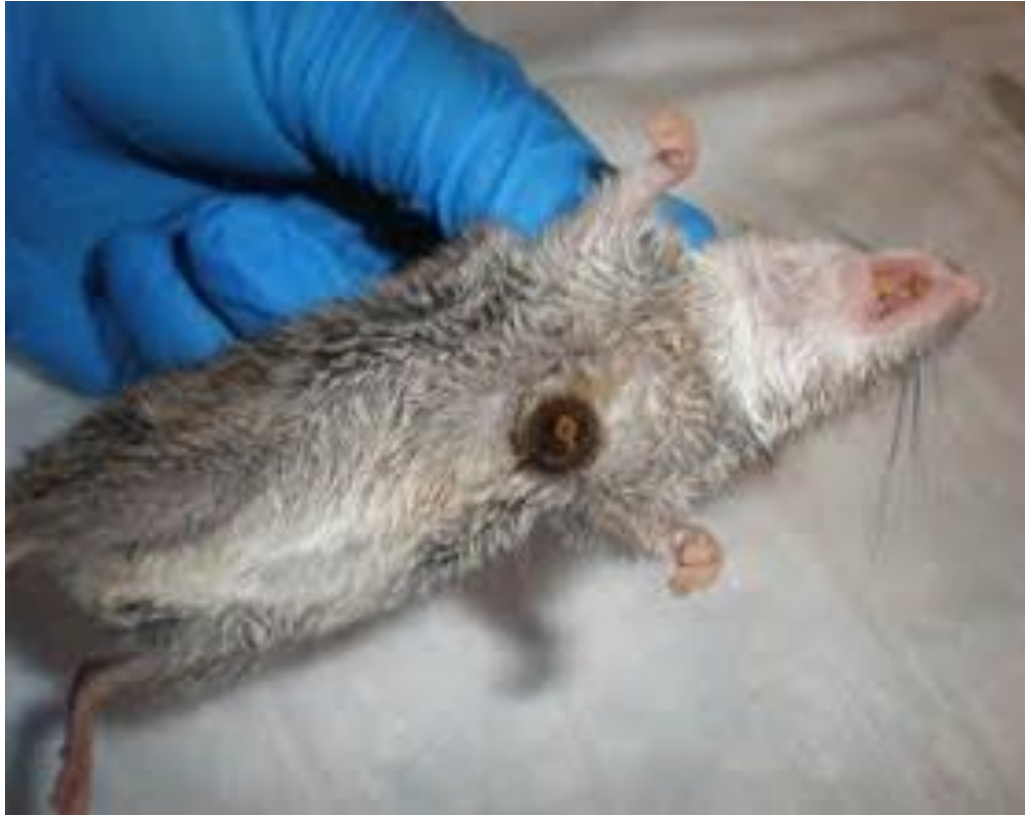Cuterebra sp., rabbit and rodent bots



Cordylobia anthropophaga



Cuterebra species in natural hosts



Images courtesy of Dr. Bobbi S. Pritt.

Lucilia sp.

- Cosmopolitan flies in the family Calliphoridae
- Saprophagous species; cause facultative myiasis.
- Do not attack healthy tissue
- Utilized in maggot therapy



Image courtesy of Tom Murray

Lucilia species; foot wound

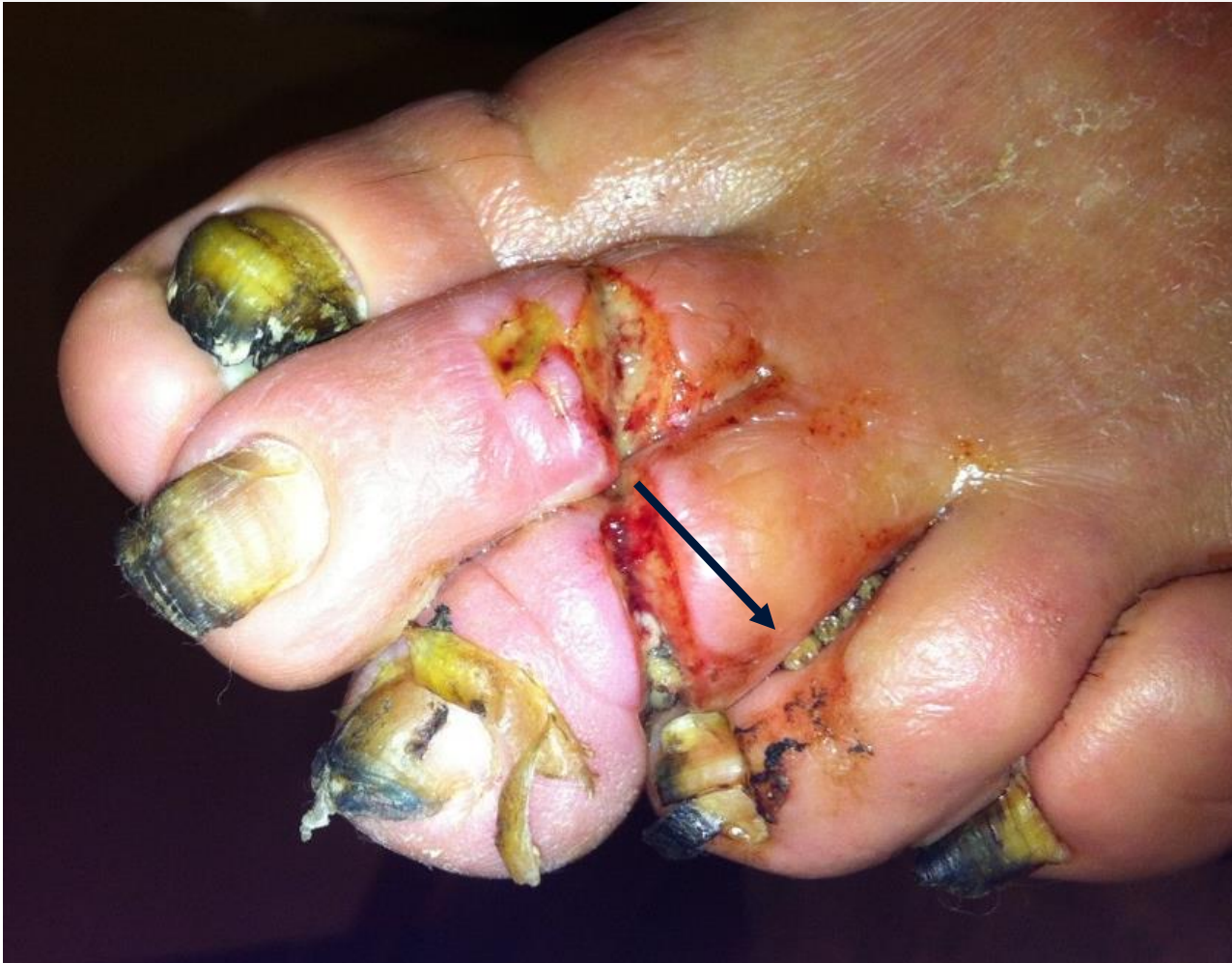

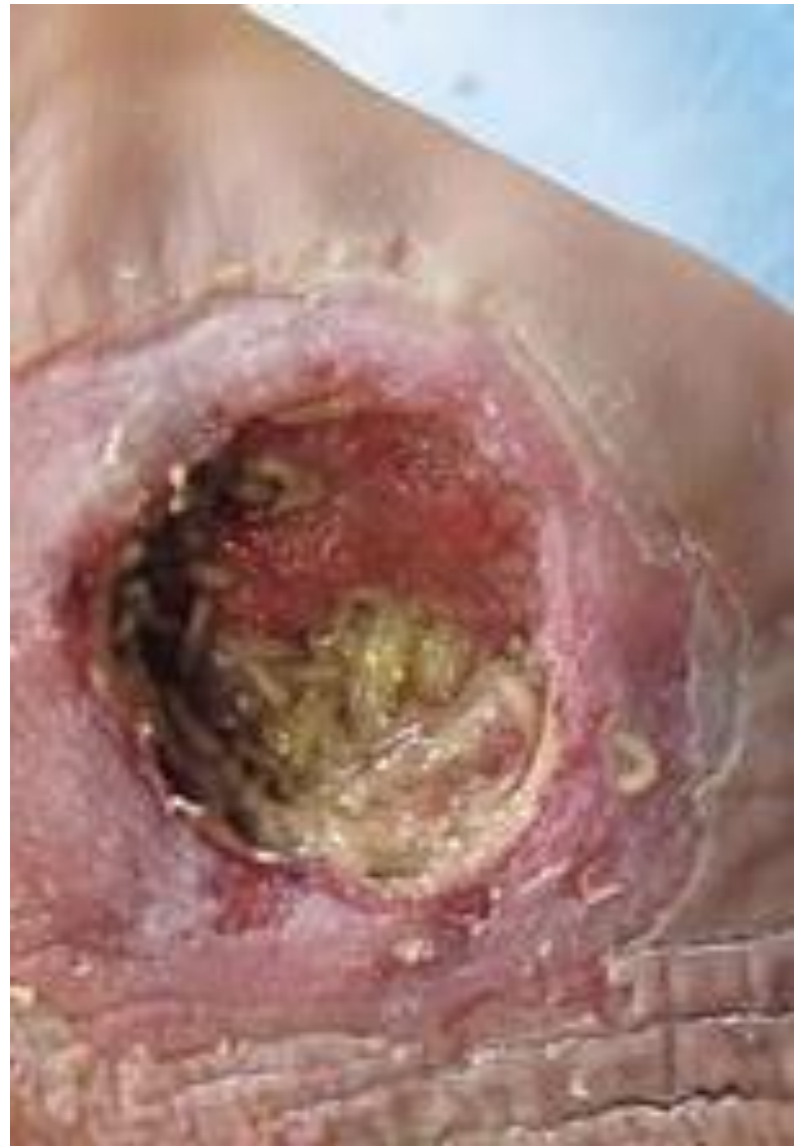Image courtesy of
James W. Snyder

Lucilia species



Maggot Therapy

- FDA approval (2004) for:
 - Non-healing necrotic skin and soft tissue wounds
 - Pressure ulcers
 - Neuropathic foot ulcers
 - Non-healing traumatic or post-surgical wounds
- Examples: diabetic and severe burn patients

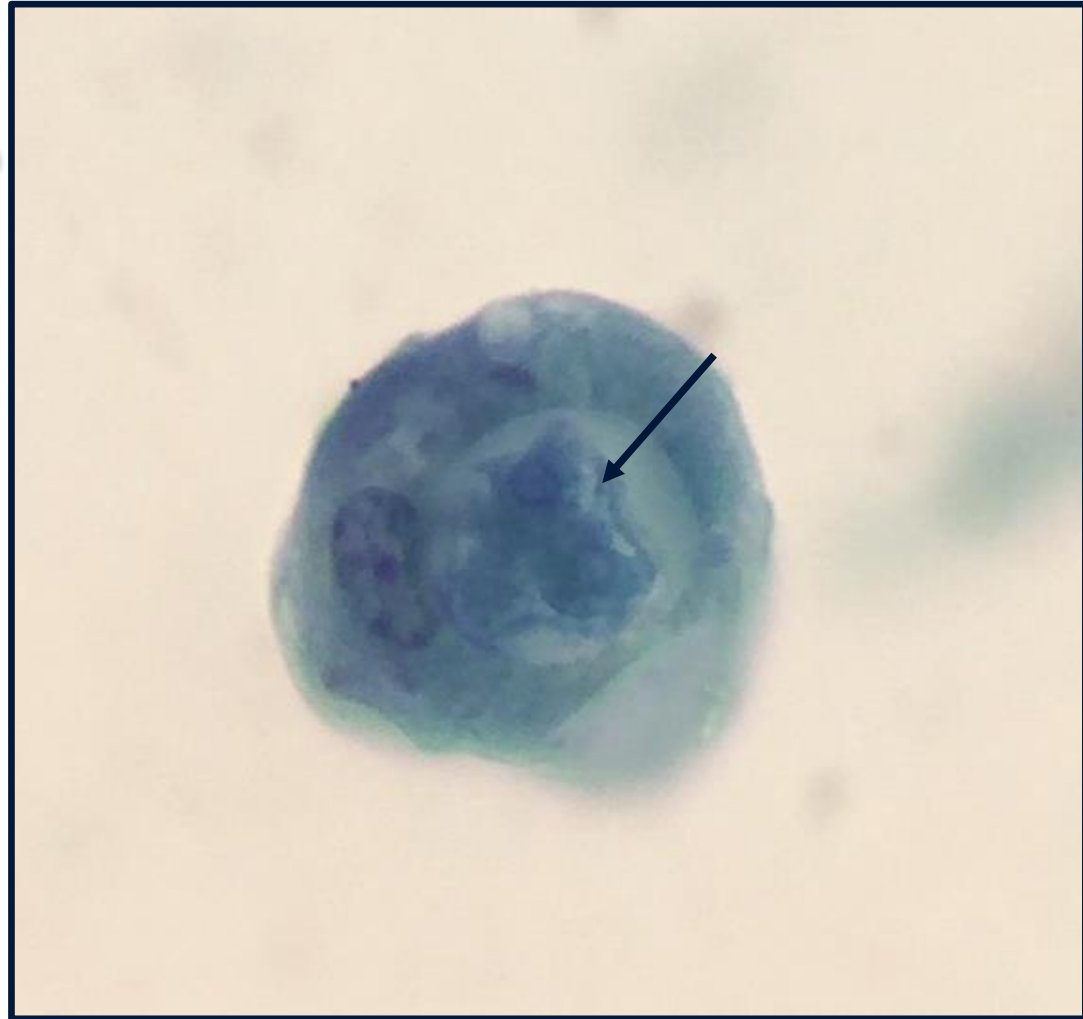


https://en.wikipedia.org/wiki/Maggot_therapy

Epilogue:
Sometimes it's a Dog-eat-Dog World

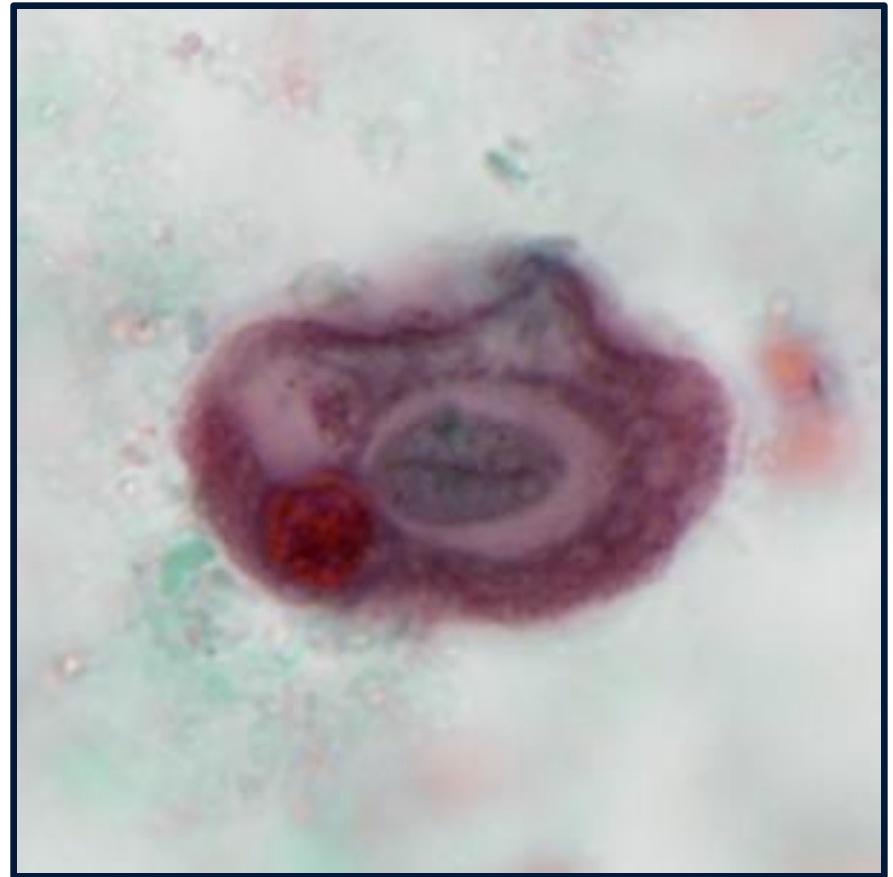
Epilogue

- A simple case: the following was observed on a trichrome-stained slide of stool.
- No known travel history.

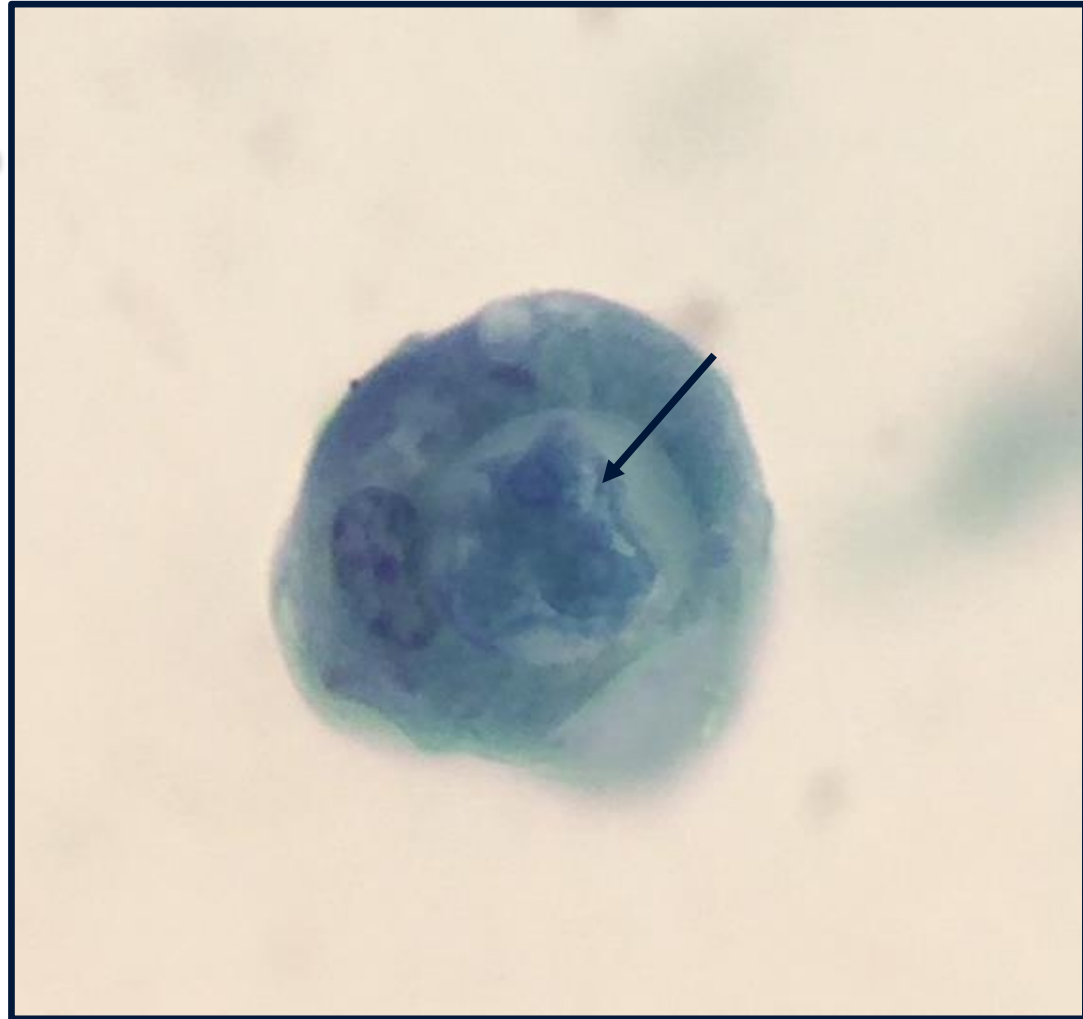


Epilogue: Diagnosis

- Trophozoite of *Entamoeba coli* that had ingested a cyst of *Entamoeba histolytica/dispar*!
- Hungry, Hungry Hippos of the protozoan realm!



Entamoeba coli



Acknowledgements

- Henry Bishop (anisakiasis)
- Laura M. Filkins, David C. Gaston, Marc R. Couturier, Clair Ciarkowski, Ryan Murphy, Kimberly Hanson, Paloma Cariello (strongyloidiasis).
- Henry Bishop, Richard Bradbury, Samaly dos Santos, Chad Sanborn (acanthocephaliasis)
- Henry Bishop, Mark Eberhard, Bhavesh Papadi, Carole Boudreaux, J. Allen Tucker (halicephalobiasis)
- Mark Eberhard, Henry Bishop, Nidhi Handoo, John Hellstein (anatrivosomiasis)
- Jane Hata (*Gongylonema*)
- Daniel Leung, Richard Davis, Bobbi S. Pritt, Carlos Chaccour (myiasis)
- Ryan Jensen (*Entamoeba coli*)
- The CDC's DPDx Team (additional images and life cycles)



© 2014 ARUP Laboratories