

Uveoscleral Outflow

Current understanding and methods of measurement.

BY CAROL B. TORIS, PhD

The term *uveoscleral outflow* refers to the drainage of ocular aqueous humor from the anterior chamber into the anterior chamber angle other than through the trabecular meshwork (Figure). Unlike the trabecular outflow route, the uveoscleral outflow route is not a distinctive pathway with tubes and channels. Rather, it is a route whereby aqueous humor seeps through, around, and between tissues, including the supraciliary space, ciliary muscle, suprachoroidal space, choroidal vessels, emissarial canals, sclera, and lymphatic vessels. The lack of a well-defined structural pathway has given this route the label *unconventional outflow pathway*.

Uveoscleral outflow was found to be a legitimate drainage pathway by Anders Bill^{1,2} in the 1960s. By the perfusion of radioactive tracers in the anterior chamber of monkeys, he was able to follow the flow of aqueous humor through the uvea and out of the eye. Scientific interest in this drainage pathway was piqued when it was discovered that prostaglandin analogues now used to treat glaucoma lowered IOP by increasing this flow.³

CURRENT UNDERSTANDING

Uveoscleral outflow is thought to be driven or changed by pressure gradients through the uvea, by movements of the ciliary muscle, and by cytoskeletal alterations or changes in the extracellular matrix within the drainage tissues.

Uveoscleral outflow changes throughout life and in various syndromes associated with elevated IOP. It is reduced with aging⁴ and in exfoliation syndrome⁵ and ocular hypertension,⁶ but it increases in iridocyclitis⁷ and glaucomatocyclitic crisis.⁸ Uveoscleral outflow also slows

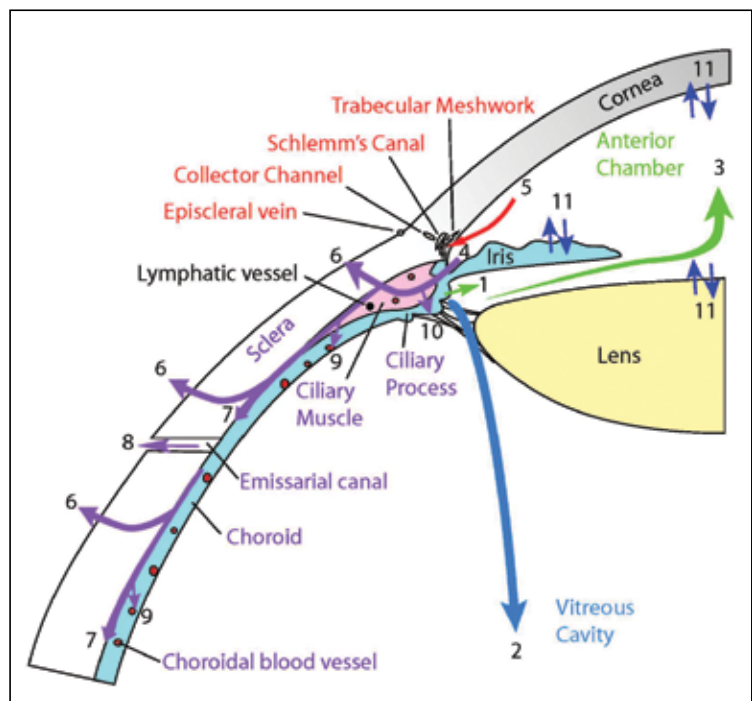


Figure. Aqueous humor dynamics. Most ocular aqueous humor circulates through the anterior chamber and exits the eye at the anterior chamber angle. The uveoscleral outflow route is drawn in purple. After the fluid reaches the ciliary muscle, it flows in several directions, including across the sclera (6), within the supraciliary and suprachoroidal spaces (7), through emissarial canals (8), into uveal vessels (9) and vortex veins (not drawn), and possibly into ciliary processes (10), where it could be secreted again. Lymphatic vessels, recently identified in the uvea, may also contribute to uveoscleral outflow.

every night, as reported in patients with ocular hypertension⁹ and in healthy adults of the same age.¹⁰ One reason for this slowing is that aqueous production decreases at night, leaving less fluid to drain through the uveoscleral tissues. Other factors may be involved in this nocturnal slowing.

TECHNIQUES FOR MEASURING UVEOSCLERAL OUTFLOW

Of all the parameters of aqueous humor dynamics, uveoscleral outflow is the most difficult to assess. Several methods have been tried over the decades, but new ones are slow to appear.

Mathematical Calculation

Uveoscleral outflow (F_u) is often calculated by utilizing the modified Goldmann equation, $F_u = F - C(IOP - P_v)$. Outflow facility (C) is determined by numerous methods, including tonography. IOP is measured by tonometry, aqueous flow (F) by fluorophotometry, and episcleral venous pressure (P_v) by venomanometry. This is a non-invasive assessment of uveoscleral outflow that has been used in numerous studies of human volunteers or animal studies in which sacrifice is to be avoided. This method yields large standard deviations by requiring the measurement of four other parameters, each with inherent variability. Twenty to 30 humans must be enrolled in a study to achieve sufficient power to detect clinically relevant differences between experimental and control conditions. Episcleral venous pressure needed for the calculation often is not measured but assumed. If one were to assume erroneously that episcleral venous pressure is unchanged during the course of a study, wrong conclusions could be reached concerning the cause of an IOP effect. The calculation method may not be able to detect the absolute value of uveoscleral outflow, but relative differences between groups or experimental manipulations can be found.

Invasive Methods

The intracameral infusion of a tracer to measure uveoscleral outflow is more direct than the mathematical calculation method. The former involves infusing a tracer into the anterior chamber at a set pressure for a specific time. The tracer is collected from the tissues of the outflow pathway and measured. The main limitation of this method is that some of the tracer may be lost during the collection process, thus underestimating uveoscleral outflow. Often, collection of the tracer requires sacrifice of the animal, precluding its use in clinical studies.

New Ideas

Functional magnetic resonance imaging has been attempted to measure aqueous flow and to monitor outflow in live rhesus monkeys.¹¹ Anesthetized animals are placed in a functional magnetic resonance imaging unit for baseline images of the eye. The anterior chamber is injected with nanoparticles that are detected by the magnet, and digital sections of the eye are made

every 15 minutes for an hour. Optical densities are calculated for the anterior chamber and the ciliary muscle. Uveoscleral outflow is the product of the slope of the ciliary muscle tracer clearance curve and the volume of the ciliary muscle. Because this method requires the animal to remain perfectly still for a lengthy period of time, anesthesia is required. Much more work needs to be done before this method is acceptable for the quantitative assessment of flow. Nevertheless, the future may show uveoscleral outflow measured by magnetic resonance imaging in humans.

With the recent advances in anterior segment imaging systems, someday in the not-too-distant future, it may become possible to use ultrasound biomicroscopy to calculate the ciliary body volume and to determine the route and rate of flow of a tracer from the anterior chamber through the uvea. If successful, this method could be used in a clinical setting.

CONCLUSION

Uveoscleral outflow remains an important component of aqueous humor dynamics that contributes to the maintenance of IOP. Better methods for measuring uveoscleral outflow are still needed, but new ideas are germinating. The near future may bring new methods not only to collect research data but also to facilitate the diagnosis and treatment of elevated IOP. ■

Carol B. Toris, PhD, is the director of glaucoma research for the Department of Ophthalmology at the University of Nebraska Medical Center in Omaha, Nebraska. Dr. Toris may be reached at (402) 559-7492; ctoris@unmc.edu.



1. Bill A. The aqueous humor drainage mechanism in the cynomolgus monkey (*macaca irus*) with evidence for unconventional routes. *Invest Ophthalmol.* 1965;4(5):911-919.
2. Bill A, Hellsing K. Production and drainage of aqueous humor in the cynomolgus monkey (*macaca irus*). *Invest Ophthalmol.* 1965;4(5):920-926.
3. Weinreb RN, Toris CB, Gabelt BT, et al. Effects of prostaglandins on the aqueous humor outflow pathways. *Surv Ophthalmol.* 2002;47:553-564.
4. Toris CB, Yablonski ME, Wang Y, Camras CB. Aqueous humor dynamics in the aging human eye. *Am J Ophthalmol.* 1999;127(4):407-412.
5. Johnson TV, Fan S, Camras CB, Toris CB. Aqueous humor dynamics in exfoliation syndrome. *Arch Ophthalmol.* 2008;126(7):914-920.
6. Toris CB, Koepsell SA, Yablonski ME, Camras CB. Aqueous humor dynamics in ocular hypertensive patients. *J Glaucoma.* 2002;11(3):253-258.
7. Toris CB, Pederson JE. Aqueous humor dynamics in experimental iridocyclitis. *Invest Ophthalmol Vis Sci.* 1986;27(3 suppl):289.
8. Camras CB, Chacko DM, Schlossman A, Posner A. Posner-schlossman syndrome. In: Prepose JS, Holland GN, Wilhelmus KR, eds. *Ocular Infection & Immunity*. St. Louis: Mosby-Year Book, Inc; 1996:529-537.
9. Fan S, Hejkal JJ, Gulati V, et al. Aqueous humor dynamics during the day and night in volunteers with ocular hypertension. *Arch Ophthalmol.* 2011;129(9):1162-1166.
10. Liu H, Fan S, Gulati V, et al. Aqueous humor dynamics during the day and night in healthy mature volunteers. *Arch Ophthalmol.* 2011;129(3):269-275.
11. Toris CB, Gong H, Dawson WW. Use of functional magnetic resonance imaging to measure aqueous flow and monitor outflow in living rhesus monkeys. Poster presented at: The International Society for Eye Research; 2008; Beijing, China.