

ENLARGEMENT OF CHOROIDAL OSTEOMA IN A CHILD

A discussion and case report of the diagnosis and management of this rare tumor.

BY MARIA PEFKIANAKI, MD, MSc, PhD; KAREEM SIOUFI, MD; AND CAROL L. SHIELDS, MD



Choroidal osteoma is a rare intraocular bony tumor that typically manifests as a yellow-white, well-demarcated mass with geographic pseudopodal margins.¹⁻³

This benign tumor predominantly occurs in the peripapillary or papillomacular region, most often in young women.^{1,2} Occasionally, choroidal osteoma can simulate an amelanotic choroidal tumor such as melanoma, nevus, or metastasis.^{1,2} This tumor can also simulate choroidal inflammatory disease such as sarcoidosis, tuberculosis, and other causes of solitary idiopathic choroiditis.^{2,4} Due to its calcified nature, choroidal osteoma can be confused with sclerochoroidal calcification, a degenerative condition found in elderly patients, located in an extramacular site and associated with serum calcium metabolic disorders.⁴ Choroidal osteoma can demonstrate growth, particularly into the submacular region, with potential reduction in visual acuity and potential risk for choroidal neovascularization.⁵ In this article we describe a young child with documented enlargement of choroidal osteoma in the macular region.

CASE REPORT

A 14-year-old asymptomatic Caucasian female was referred for evaluation of an amelanotic choroidal mass in the left eye (OS) that demonstrated slight enlargement over 16-months. At presentation, visual acuity was 20/20 in right eye (OD) and 20/25 OS. Anterior segment examination was normal in both eyes. Fundus examination OD was unremarkable. Fundus examination OS revealed a 5.0 x 3.0 x 1.2 mm amelanotic choroidal lesion in the temporal macular region, extending under the foveola. The mass had slight geographic configuration with crisp margins, no subretinal fluid or hemorrhage and trace overlying retinal pigment epithelial (RPE) clumping. In comparison to photographic documentation from 16 months earlier (Figure 1A) the mass was approximately 500 μ m to 800 μ m larger, particularly the inferior margin (Figure 1B).

On ultrasonography, the lesion demonstrated a hyper-echoic signal with posterior shadowing suggestive of calcification. On spectral domain enhanced depth imaging optical coherence tomography (EDI-OCT), the mass extended under the foveola and there was no evidence of choroidal neovascular membrane (CNVM) or subretinal fluid (Figure 2).

These features were suggestive of choroidal osteoma with documentation of slow, slight enlargement. Given the preserved visual acuity and subfoveal location of the osteoma, we elected to observe the lesion. Calcium supplementation was suggested to maintain calcification of the mass, as decalcification is a known factor predictive of poor visual outcome.⁶

DISCUSSION

Choroidal osteoma is a benign calcified tumor that can focally replace normal vascular tissue with mature bone. The cause of this condition is unknown.^{1,2} Unlike other types of intraocular calcification, choroidal osteoma generally occurs



AT A GLANCE

- Choroidal osteoma is a rare intraocular bony tumor that can focally replace normal vascular tissue with mature bone.
- The differential diagnosis of choroidal osteoma includes amelanotic choroidal tumors such as amelanotic melanoma, hemangioma, and metastasis, as well as sclerochoroidal calcification.
- OCT plays an important role in the diagnosis and management of choroidal osteoma; management of tumor growth depends on the specific location of the osteoma.
- Choroidal osteoma can demonstrate growth in 51% of cases, decalcification in 46% of cases, and development of CNVM in 31% of cases.

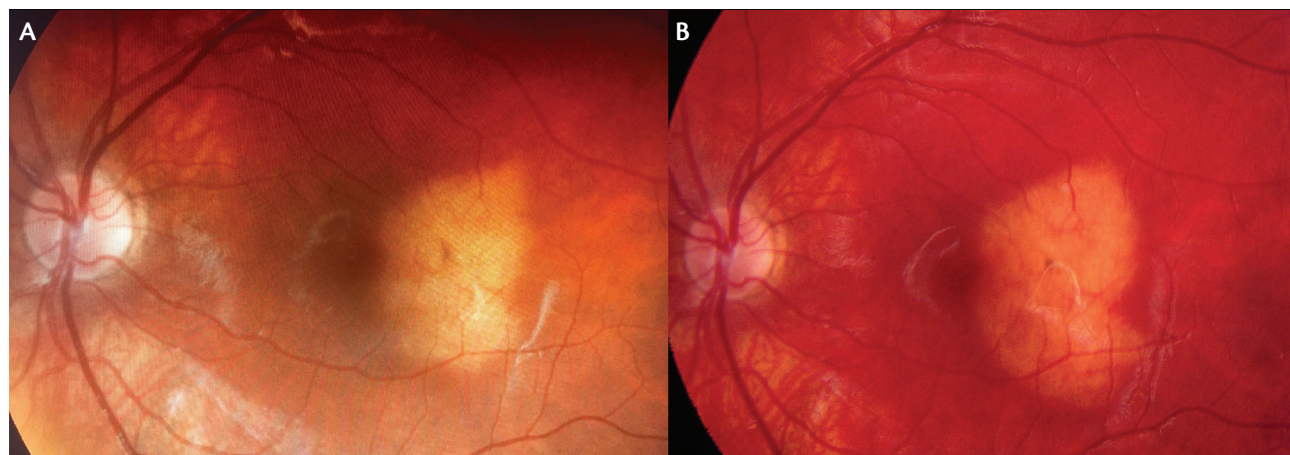


Figure 1. A 14-year-old Caucasian female was found to have choroidal osteoma (A) that had demonstrated mild tumor enlargement (B) over a period of 16 months, especially on the inferior margin.

in healthy eyes that have not had previous trauma or inflammation.² Choroidal osteoma usually presents as a unilateral amelanotic mass and is typically discovered during the second or third decade of life.¹ The diagnosis is established based on clinical and imaging features, particularly crisp margins, calcification on ultrasonography, and lamellar bone with Haversian canals on EDI-OCT.⁷⁻⁹

Differential Diagnosis

The differential diagnosis of choroidal osteoma includes several tumors, such as choroidal amelanotic melanoma, hemangioma, and metastasis, as well as sclerochoroidal calcification.¹⁻⁴ Osteoma has fairly sharp margins and can demonstrate some degree of pseudopodal growth, whereas amelanotic choroidal melanoma is generally more elevated with less well-defined margins.^{2,10} However, the differentiation is best made with ultrasonography, as osteoma is echodense with shadowing, and melanoma is echolucent.^{2,10}

Choroidal hemangioma typically appears as an orange-colored lesion with classic dome configuration and round, smooth margins delineated by compressed normal uveal pigment.¹¹ Differentiation is made by funduscopy, as hemangioma is round without pseudopods. Ultrasonography shows both hemangioma and osteoma as dense lesions, but osteoma is hyperreflective and casts a shadow.¹¹ EDI-OCT can be useful in the differentiation of the two, as hemangioma shows expansion of normal choroidal vessels with a smooth dome-shaped configuration and osteoma shows irregular surface contour and linear bone lamellae.^{7,11-14}

Choroidal metastasis is generally yellow in color, like osteoma, but shows a characteristic EDI-OCT feature of “lumpy bumpy” tumor contour.¹⁵

Sclerochoroidal calcification resembles osteoma with its yellow color, but the two occur in opposite age groups: the

elderly and the young, respectively.^{2,4} Additionally, sclerochoroidal calcification is usually found in an extramacular, extrapapillary region, unlike osteoma.⁴ EDI-OCT differentiates the two, as sclerochoroidal calcification demonstrates an abruptly elevated, pointed configuration.^{7,14,16}

EDI-OCT plays an important role in the diagnosis and management of choroidal osteoma. Pellegrini et al¹⁴ and Shields et al⁷ described the features of choroidal osteoma using EDI-OCT. Both studies showed that choroidal osteoma demonstrates a fairly smooth surface topography, occasionally with undulation or excavation. Shields et al⁷ found unique EDI-OCT features of horizontal lamellar lines (100%), horizontal tubules (60%), vertical tubules (13%), and speckled regions (40%), giving the tumor a sponge-like appearance. Cases with tumor deossification, whether partial or complete, showed overlying photoreceptor degeneration that correlated with decreased visual acuity.⁷

Clinical Course

The clinical course of choroidal osteoma varies. In one analysis of 74 eyes with choroidal osteoma, the 10-year outcomes revealed evidence of growth (51%), tumor decalcification (46%), and development of CNVM (31%).⁵

Management of CNVM associated with osteoma involves intravitreal injection of anti-VEGF agents.^{17,18} Khan et al¹⁸ studied eight eyes with choroidal osteoma and CNVM that were treated with anti-VEGF agents and found that the medication alone or in combination with photodynamic therapy (PDT) resulted in anatomic improvement, with resolution of subretinal fluid on OCT in seven of eight eyes (87%) and modest visual gain of 1 ± 4 lines (range, loss of 3 to gain of 7 lines) at a mean 32 months of follow-up.

Management of tumor growth depends on the specific location of the osteoma. For those that are extrafoveal,

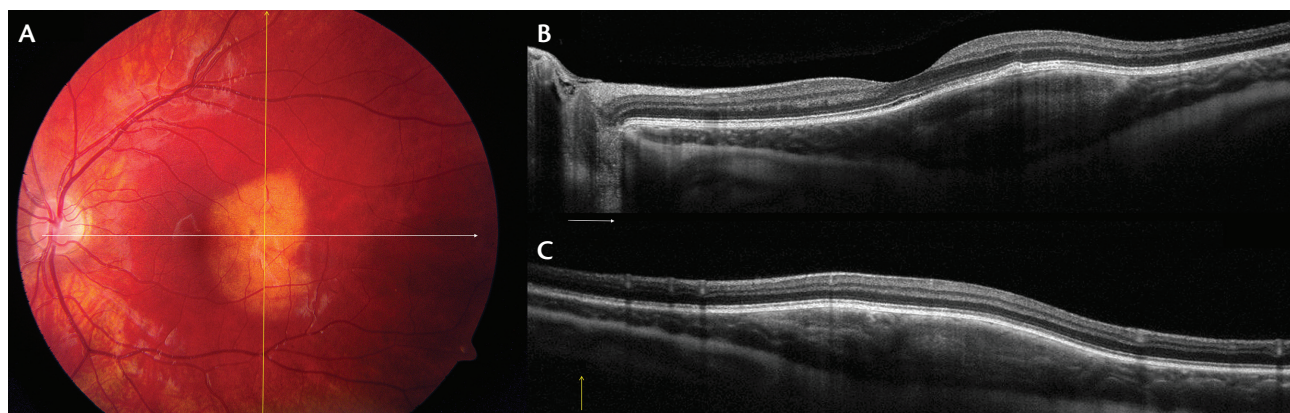


Figure 2. Choroidal osteoma (A) with EDI-OCT showing horizontal cut through the foveola (B) and vertical cut through the lesion (C) demonstrating a smooth-surfaced, elevated choroidal mass extending under the foveola and with obliteration of normal choroidal vascular structures. There are fine lamellar lines within the mass that could represent bone lamella. A flattened pigment epithelial detachment was noted (B).

treatment with PDT can induce decalcification and prevent further growth under the foveola.¹⁹ If the tumor is subfoveal, no therapy is recommended, and the goal is to maintain a calcified mass with calcium supplementation so that the overlying neurosensory retina remains intact.⁶ It has been shown that decalcification of osteoma is associated with choriocapillaris atrophy, RPE atrophy, photoreceptor loss, and visual acuity loss.^{5,6} In our case, the patient was followed conservatively, as OCT demonstrated a calcified subfoveal tumor, and calcium supplementation was suggested.

CONCLUSION

Choroidal osteoma is a rare choroidal lesion of bone density with propensity for growth, decalcification, and development of CNVM. In the case presented here, tumor growth over a 16-month period in a teenager was noted, and visual acuity remained stable. Long-term monitoring of the tumor will be important. ■

- Shields JA, Shields CL. Choroidal Osteoma. In: Shields JA, Shields CL, eds. *Atlas of Intraocular Tumors*, 3rd ed. Philadelphia: Lippincott, Wolters Kluwer; 2016:285-289.
- Shields CL, Shields JA, Augsburger JJ. Choroidal osteoma. *Surv Ophthalmol*. 1988;33(1):17-27.
- Aylward GW, Chang TS, Pautler SE, Gass JD. A long-term follow-up of choroidal osteoma. *Arch Ophthalmol*. 1998;116(10):1337-1341.
- Shields CL, Hasanreisoglu M, Saktanasate J, et al. Sclerochoroidal calcification: clinical features, outcomes, and relationship with hypercalcemia and parathyroid adenoma in 179 eyes. *Retina*. 2015;35(3):547-554.
- Shields CL, Sun H, Demirci H, Shields JA. Factors predictive of tumor growth, tumor decalcification, choroidal neovascularization, and visual outcome in 74 eyes with choroidal osteoma. *Arch Ophthalmol*. 2005;123(12):1658-1666.
- Shields CL, Perez B, Materin MA, et al. Optical coherence tomography of choroidal osteoma in 22 cases: evidence for photoreceptor atrophy over the decalcified portion of the tumor. *Ophthalmology*. 2007;114(12):e53-58.
- Shields CL, Arepalli S, Atalay HT, et al. Choroidal osteoma shows bone lamella and vascular channels on enhanced depth imaging optical coherence tomography in 15 eyes. *Retina*. 2015;35(4):750-757.
- Sisk RA, Riemann CD, Petersen MR, et al. Fundus autofluorescence findings of choroidal osteoma. *Retina*. 2013;33(1):97-104.
- Shields CL, Manalac J, Das C, et al. Review of spectral domain-enhanced depth imaging optical coherence tomography of tumors of the retina and retinal pigment epithelium in children and adults. *Ind J Ophthalmol*. 2015;63(2):128-132.
- Alameddine RM, Mansour AM, Kahtani E. Review of choroidal osteomas. *Middle East Afr J Ophthalmol*. 2014;21(3):244-250.
- Shields CL, Honavar SG, Shields JA, et al. Circumscribed choroidal hemangioma: clinical manifestations and factors predictive of visual outcome in 200 consecutive cases. *Ophthalmology*. 2001;108(12):2237-2248.
- Rojanaporn D, Kaliki S, Ferenczy SR, Shields CL. Enhanced depth imaging optical coherence tomography of circumscribed choroidal hemangioma in 10 consecutive cases. *Middle East Afr J Ophthalmol*. 2015;22(2):192-197.
- Shields CL, Manalac J, Das C, et al. Review of spectral domain enhanced depth imaging optical coherence tomography (EDI-OCT) of tumors of the choroid. *Ind J Ophthalmol*. 2015;63(2):117-121.

- Pellegrini M, Invernizzi A, Giani A, Staurenghi G. Enhanced depth imaging optical coherence tomography features of choroidal osteoma. *Retina*. 2014;34(5):958-963.
- Al-Dahmash SA, Shields CL, Kaliki S, et al. Enhanced depth imaging optical coherence tomography of choroidal metastasis in 14 eyes. *Retina*. 2014;34(8):1588-1593.
- Hasanreisoglu M, Saktanasate J, Shields PW, Shields CL. Classification of sclerochoroidal calcification based on enhanced depth imaging optical coherence tomography 'mountain like' features. *Retina*. 2015;35(7):1407-1414.
- Shields CL, Salazar PF, Demirci H, et al. Intravitreal bevacizumab (Avastin) and ranibizumab (Lucentis) for choroidal neovascularization overlying choroidal osteoma. *Retina Cases Brief Rep*. 2008;2(1):18-20.
- Khan MA, DeCrosos FC, Storey PP, et al. Outcomes of anti-vascular endothelial growth factor therapy in the management of choroidal neovascularization associated with choroidal osteoma. *Retina*. 2014;34(9):1750-1756.
- Shields CL, Materin MA, Mehta S, et al. Regression of extrafoveal choroidal osteoma following photodynamic therapy. *Arch Ophthalmol*. 2008;126(1):135-137.

Maria Pefkianaki, MD, MSc, PhD

- ocular oncology fellow, Wills Eye Hospital, Philadelphia, Pa.
- mpefkianaki@willseye.org

Carol L. Shields, MD

- co-director of the Ocular Oncology Service, Wills Eye Hospital, Thomas Jefferson University in Philadelphia, Pa.
- member of the *Retina Today* editorial advisory board
- carolshields@gmail.com

Kareem Sioufi, MD

- research intern of the Ocular Oncology Service, Wills Eye Hospital, Thomas Jefferson University in Philadelphia, Pa.
- kareem.sioufi@gmail.com

No conflicting relationship exists for any author.

Support provided by Eye Tumor Research Foundation, Philadelphia, Pa. (CLS). The funders had no role in the design and conduct of the study, in the collection, analysis and interpretation of the data, and in the preparation, review or approval of the manuscript. Carol L. Shields, MD, has had full access to all the data in the study and takes responsibility for the integrity of the data and the accuracy of the data analysis.