

Imaging the Urinary Tract

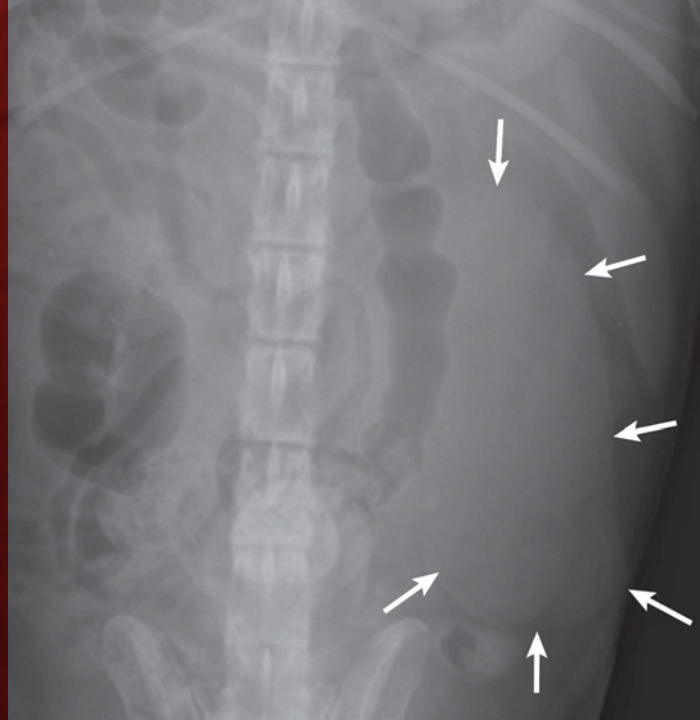
Laura Armbrust, DVM, DACVR
Gregory F. Grauer, DVM, MS, DACVIM
Kansas State University

Radiographic and ultrasound imaging—in addition to history, physical examination, and clinicopathologic testing—are often used to provide diagnostic information in dogs and cats with known or suspected urinary tract disorders. Although ultrasound has largely become the first-choice imaging modality for small animal urinary tract disease, radiographic imaging is complementary to ultrasonography; both should be employed to evaluate cases whenever possible.

Kidneys

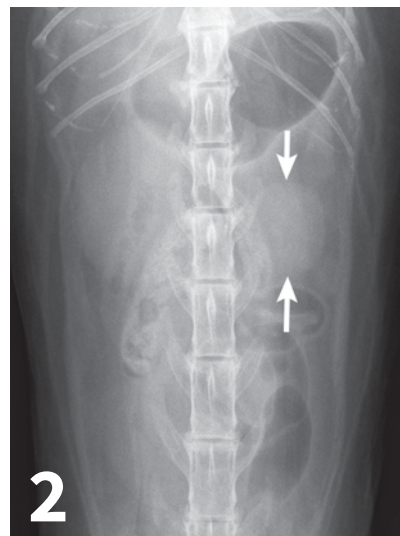
Survey abdominal radiographs (*Figures 1 and 2*) offer important information on kidney number, size, shape, symmetry, and location, as well as the presence of any mineralized opacities (eg, calcified tissue, nephroliths). The utility of abdominal radiographs is decreased in patients with abdominal fluid or lack of abdominal fat (eg, young or emaciated patients) because of lack of contrast. Excretory urography (IV pyelography), although more invasive, can augment survey radiographs and provide information about renal parenchymal architecture (eg, filling defects associated with cysts or infiltrative disease), the renal pelvis, and ureters as well as a qualitative assessment of global and individual renal excretory function (*Figure 3*, next page).

Similar to survey radiography, ultrasonography can document the number, size, shape, and location



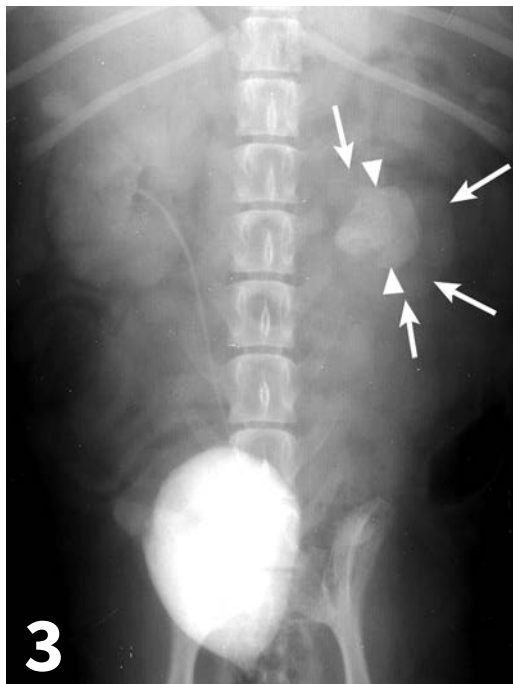
1

▲ An enlarged left kidney with an irregular shape (**arrows**) is noted on the VD view of a dog with renal adenocarcinoma. The left kidney measured 4.5 times the length of L2; normal kidney length in the dog is 2.5 to 3.5 times the length of L2.



2

▲ The left kidney (**arrows**) is decreased in size compared to the right kidney on the VD view of a cat. The left kidney measured 1.5 times the length of L2; normal kidney length in the cat is 2 to 3 times the length of L2. Both kidneys are normal in shape and opacity.



◀ VD radiograph from a dog in which excretory urography had been performed. The radiograph was taken 10 minutes after contrast injection. The right kidney, right ureter, and urinary bladder are contrast-enhanced. The left kidney contains a mineral opacity in the location and shape of the renal pelvis that was visible on noncontrast radiographs and was consistent with a large nephrolith (**arrowheads**). Overall kidney size is decreased, and the margins are irregular (**arrows**). There is no contrast uptake seen in the left kidney or ureter, which is consistent with poor kidney function.

Normal ureters cannot be visualized with survey radiography or ultrasonography, but normal and abnormal ureters are readily visualized with excretory urography.

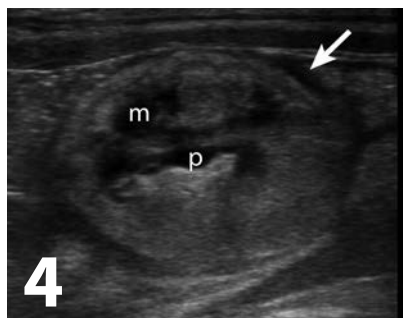
of the kidneys as well as the presence of mineralized tissue and nephroliths. In contrast to radiography, abdominal fluid or lack of abdominal fat does not limit the utility of ultrasound. The major advantage of ultrasound for evaluating kidney disease is its ability to assess the internal renal architecture and perirenal tissues. Both focal and diffuse lesions are recognized. Focal lesions may be solid, either homogenous or heterogenous, or fluid in nature. Diffuse lesions (*Figures 4-8*, next page) may uniformly affect the parenchyma or be heterogenous. The renal cortex, medulla, or both regions may be affected depending on the disease process.

Renal pelvic dilation (pyelectasia) and proximal ureteral dilation are readily observed with ultrasound and renomegaly may be seen on radiographs if dilation is severe (*Figures 9 and 10*, page 88). Ultrasound can also be used to guide fine-needle aspiration and tissue biopsies of the kidney and fluid aspiration from a dilated renal pelvis. The major limitation of

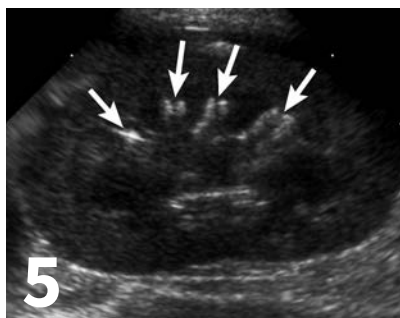
ultrasonographic evaluation of the kidneys is operator experience and expertise.

Ureters

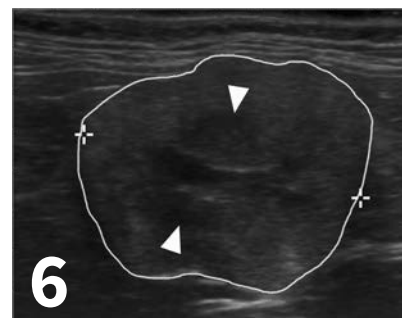
Normal ureters cannot be visualized with survey radiography or ultrasonography, but normal and abnormal ureters are readily visualized with excretory urography. The location of a ureteral obstruction or rupture as well as the presence of an ectopic ureter (especially when combined with pneumocystography) can be documented with excretory urography (*Figure 11*, page 88). A dilated ureter (hydroureter) can be observed with ultrasonography (*Figure 12*, page 89). Pyelocentesis (for cytology and culture) and antegrade pyelography (nephropyelography) (*Figure 13*, page 89) to document obstruction or leakage can be conducted via ultrasound guidance with heavy sedation or anesthesia. Ultrasonography can also be used to visualize retroperitoneal fluid



▲ Ultrasound of the kidney, in the sagittal scan plane, from a cat with renal lymphoma and with a heterogenous cortex. The medulla (**m**) remains hypoechoic. There is mild dilation of the renal pelvis (**p**). Perinephric hypoechoic tissue or fluid is present (**arrow**).



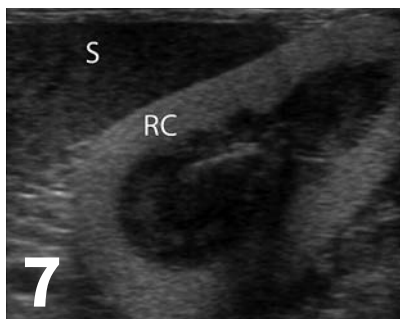
▲ Ultrasound of the kidney, in the sagittal scan plane, from a dog. The hyperechoic, linear, parallel lines present are associated with renal diverticuli in this dog with nephrocalcinosis.



▲ Ultrasound of the kidney, in the sagittal scan plane, from a cat with chronic renal disease. The kidney is decreased in size (3.2 cm in length) with irregular margins (**outlined in white**) and decreased cortico-medullary definition (**arrowheads**).

accumulation, which may occur with a ureteral rupture, hemorrhage, or infectious or neoplastic disease. Whereas ureteroliths without hydronephrosis may be missed on ultrasonography, radiopaque ureteroliths can be observed on survey radiography (**Figure 14**, page 89). Survey radiographic visualization of radiopaque ureteroliths may be facilitated by enemas to empty the colon of fecal material and/or use of a radiolucent paddle to apply regional compression over the ureter to separate adjacent organs (eg, loops of bowel) (**Figure 15**, page 89). Aged cats with chronic kidney disease (CKD) frequently have calcium oxalate nephroliths; in some cases, these nephroliths will migrate into the ureters. Survey radiographs should be employed to rule out ureterolithiasis, especially in cats with acute decompensation of their CKD (**Figure 16**, page 90).

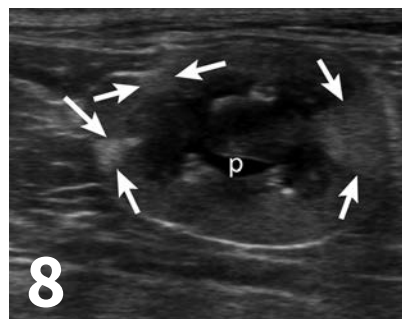
CKD = chronic kidney disease



▲ The renal cortex (**RC**) is hyperechoic compared to the spleen (**S**) in this dog with ethylene glycol toxicity. Cortico-medullary definition is enhanced by the increased echogenicity of the renal cortex. Ultrasound comparison of echogenicity between organs is useful for determining abnormalities.

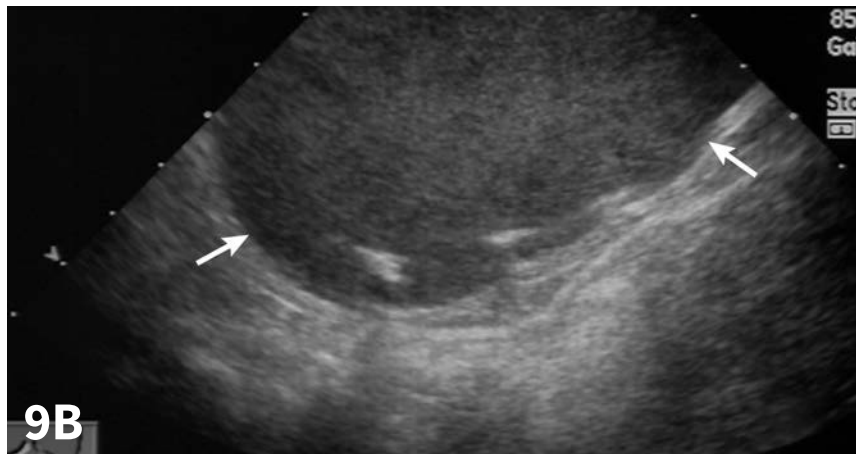
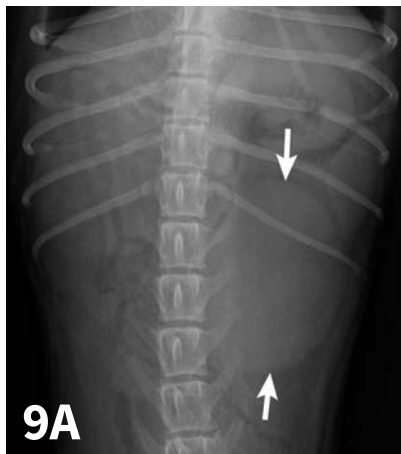
Urinary Bladder

Survey radiographs of the urinary bladder are helpful for evaluation of size and location and for detection of radiopaque calculi. Urinary bladder distention is readily

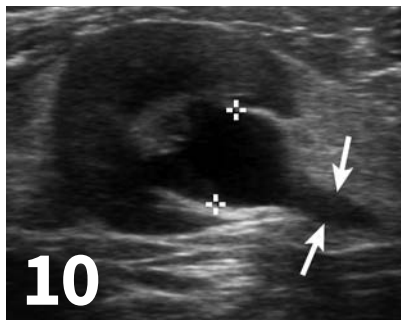

▲ The kidney contains multiple hyperechoic, wedge-shaped areas (**arrows**), consistent with chronic renal infarcts, in the renal cortex. In some of these areas, the margin of the kidney is concave. There is mild dilation of the renal pelvis (**p**).

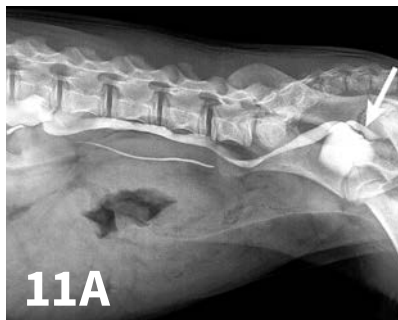detected (**Figure 17**, page 90). Radiographs are of limited value in evaluating mural disease because the bladder wall cannot be differentiated from the fluid contained within the bladder. Bladder wall



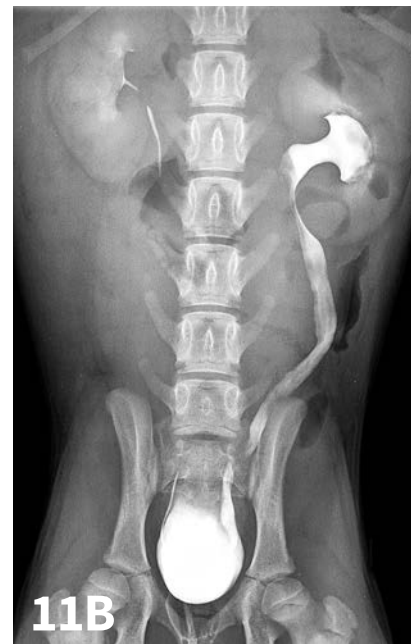▲ Severe enlargement of the left kidney (**arrows**) was noted on the VD radiograph (**A**). The kidney measures 4 times the length of L2. Although this enlargement has multiple differentials, the ultrasound (**B**) showed severe hydronephrosis with echogenic fluid and minimal renal tissue remaining (**arrows**). An ultrasound-guided aspiration with cytology and culture was performed, and renal abscess was diagnosed.



▲ An ultrasound, in the transverse scan plane, of the kidney in a cat with pyelonephritis shows dilation of the renal pelvis (between caliper markers, **+**) and dilation of the proximal ureter (**arrows**). The tissue surrounding the proximal ureter is hyperechoic.



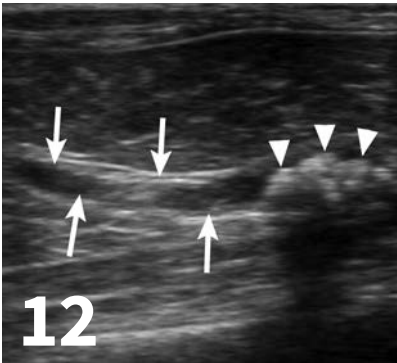
▲ Lateral oblique (**A**) and VD (**B**) radiographic views from a young dog with a left ectopic ureter that was diagnosed with excretory urography. The left ureter and renal pelvis are dilated. The left ureter extends beyond the trigone region of the urinary bladder on the lateral oblique view (**arrow**).



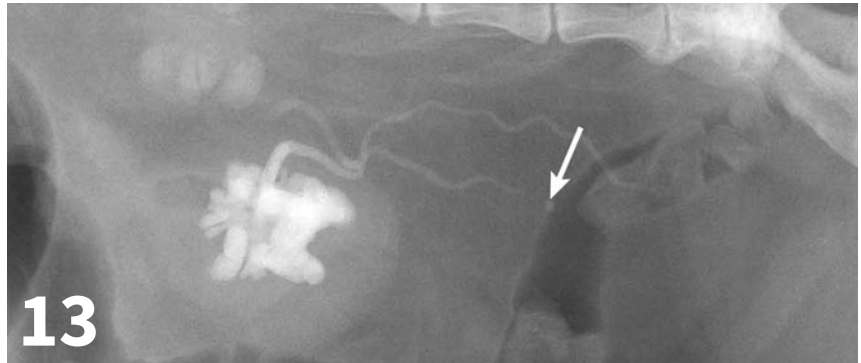
thickening (eg, bacterial inflammation, polypoid cystitis, neoplasia) is best evaluated by ultrasonography or double-contrast cystography (**Figure 18**, page 90). It should be noted that the degree of bladder

filling can affect bladder wall thickness. For example, a small, mildly distended bladder may appear to have a thickened bladder wall on ultrasound compared with a moderately or severely distended

bladder (**Figure 19**, page 90). This potential disadvantage can often be overcome by reevaluating the bladder several hours after preventing voiding.



▲ In this ultrasound image, the ureter (between **arrows**) was distended and could be followed to an accumulation of hyperechoic structures (**arrowheads**) with distal acoustic shadowing, consistent with multiple ureteroliths.

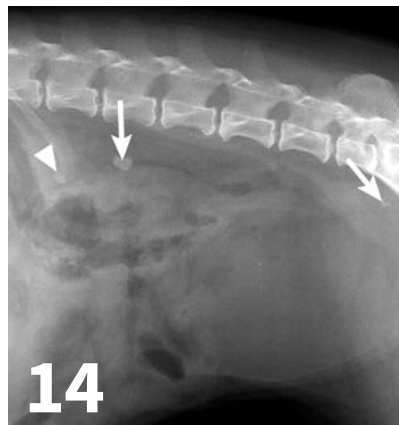


▲ Bilateral antegrade pyelography was performed in a cat with bilateral pyelectasia, in which a cause was not identified on ultrasound. Both renal pelves and ureters are dilated. There is a radiopaque ureterolith (**arrow**) that was not seen on survey radiographs (most likely because of colonic superimposition); ureteral contrast did not extend beyond the ureterolith. Ideally, the colon would be evacuated before the study.

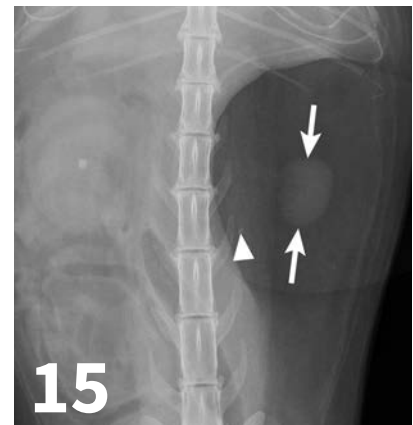
Double-contrast cystography can be an excellent tool to evaluate bladder wall thickness and any irregularities of the bladder mucosal surface and to rule out the presence of radiolucent cystouroliths (*Figure 20*, next page). Although double-contrast cystography is more invasive because of the need for urethral catheterization, artifactual bladder wall thickening is usually not an issue because the degree of bladder distention can be controlled.

Positive-contrast cystography is useful when evaluation of urinary bladder location or integrity is questioned (*Figures 21* and *22*, page 91).

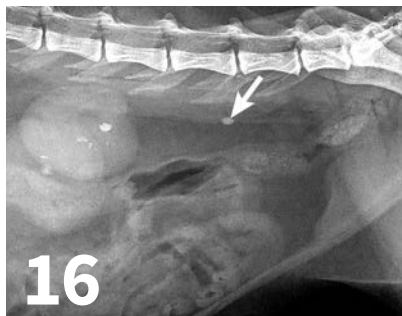
The major advantage to survey radiography of the urinary bladder is the detection of radiopaque cystouroliths. In many cases, the radiodensity, size, and shape of the uroliths aid in determining urolith type, which is not possible with ultrasonography



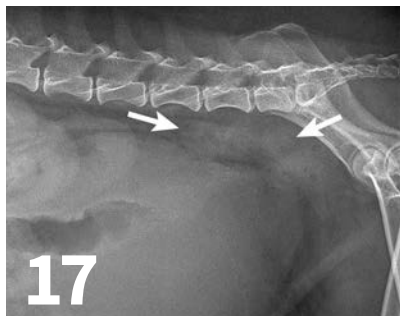
▲ Multiple mineral opaque ureteroliths (**arrows**) and a nephrolith (**arrowhead**) are seen in this lateral abdominal radiograph of a dog.



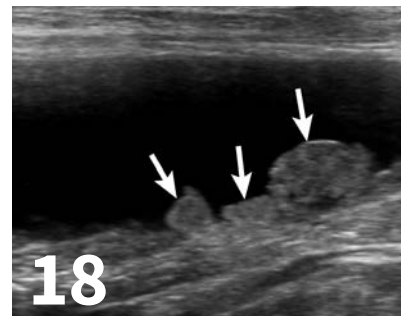
▲ Compression radiography helped isolate the small left kidney (**arrows**) and localize the left ureterolith (**arrowhead**) in the ventrodorsal image of a cat. There is also a nephrolith present in the right kidney.



▲ This lateral abdominal radiograph in a cat with CKD demonstrates the irregular kidneys with multifocal regions of mineralization. There is an ovoid, mineral opaque ureterolith (**arrow**) in the caudal retroperitoneum.

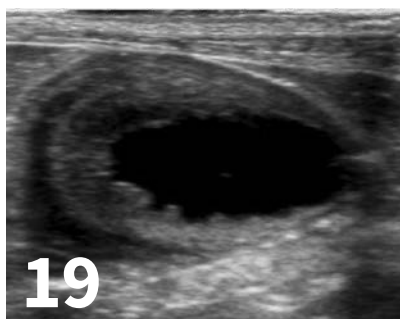


▲ This dog had a severely distended urinary bladder on evaluation of lateral abdominal radiographs. Ill-defined, soft tissue opacity was present in the region of the medial iliac lymph nodes (**arrows**). The dog had urethral neoplasia, which was the cause of the urinary outflow obstruction and lymph node enlargement.

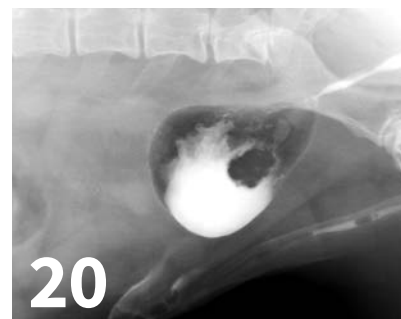

▲ This dog had nodular thickening (**arrows**) of the dorsal bladder wall noted on ultrasound of the bladder in the sagittal scan plane, with the patient in dorsal recumbency. The diagnosis was transitional cell carcinoma.

(*Figures 23 and 24, next page*), but type of urolith cannot be definitively determined with radiography. Ultrasonography has the advantage of detecting radiolucent cystouroliths (*Figure 25, next page*). Emphysematous cystitis can be observed on both survey radiography and ultrasonography (*Figure 26, page 92*). Standing the patient may be useful when trying to determine if a bladder abnormality is within or adhered to the wall or free within the lumen (hematoma or calculi) (*Figure 27, page 92*). Ultrasonography has the advantage of allowing evaluation of sublumbar lymph nodes and other perivesicular structures as well as enabling cystocentesis when the bladder is small and minimally distended. Extension of neoplasia to the spine, as with transitional cell carcinoma of the bladder, is more easily identified with radiography.

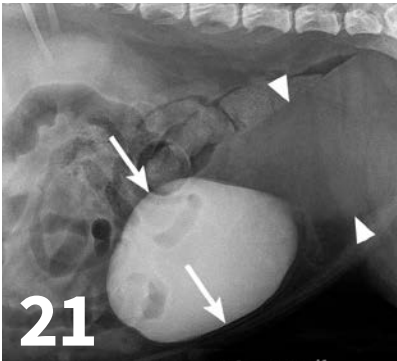


▲ Ultrasound of this nondistended urinary bladder can be difficult to interpret. The bladder wall thickening and irregular mucosal margin may be because of lack of distention or pathology (cystitis or neoplasia). Repeat ultrasound should be performed with the urinary bladder distended.



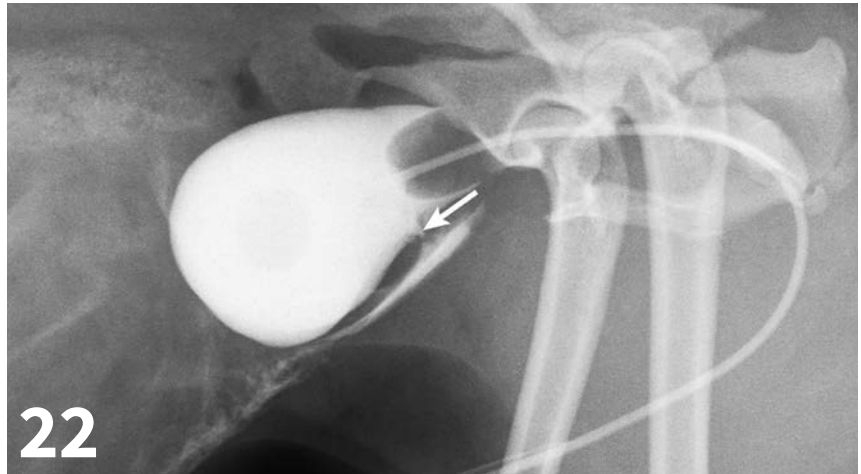
▲ Double-contrast cystography was performed in a dog with transitional cell carcinoma. The margins of the contrast are extremely irregular, and there is an irregular filling defect in the caudal aspect of the contrast material.

CKD = chronic kidney disease



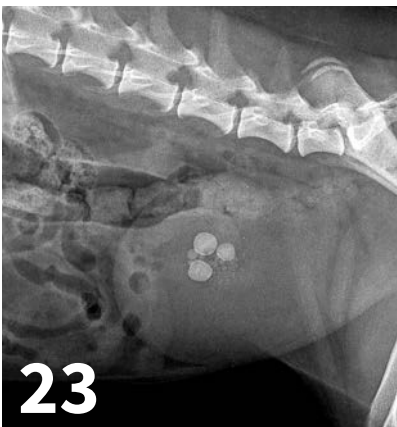
21

▲ Two large soft-tissue opaque masses were noted on survey radiographs in a dog. After positive-contrast cystography, the more cranial structure (**arrows**) was identified as the urinary bladder. The caudal soft tissue mass (**arrowheads**) was diagnosed as a uterine leiomyoma.



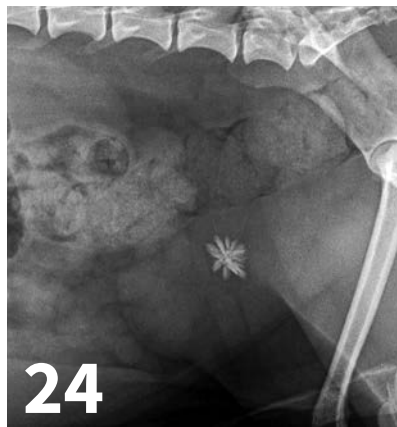22

▲ A positive-contrast cystogram was performed in this dog that was hit by a car and had reduced serosal detail and pelvic fractures. There is a triangular region (**arrow**) of contrast extravasation from the ventral bladder wall and contrast within the peritoneal cavity consistent with a bladder wall tear and uroabdomen.



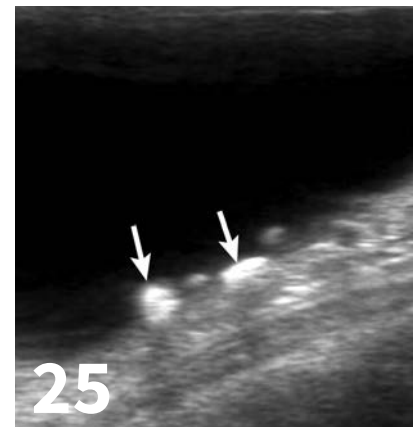23

▲ Multiple round, smooth, mineral opaque calculi are present in the central urinary bladder in this dog with struvite uroliths.



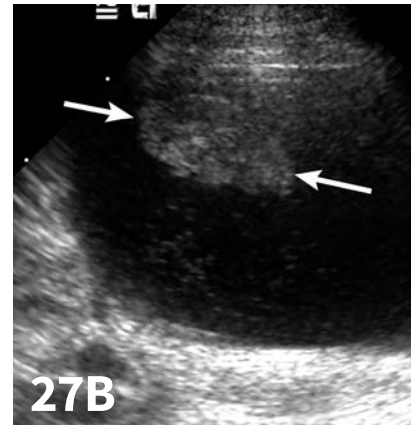
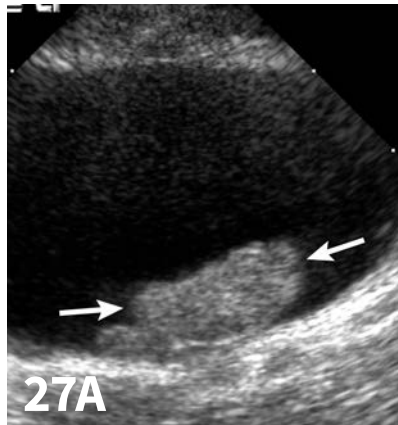
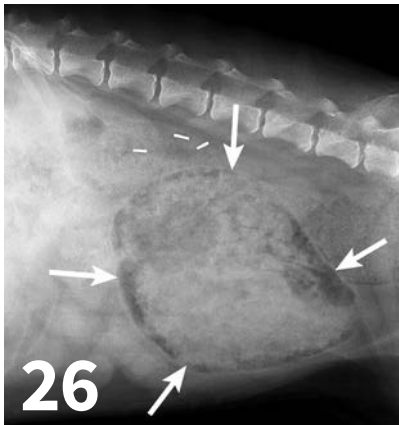
24

▲ A solitary urolith with a stellate appearance is centrally located in the urinary bladder of this dog. Calcium oxalate urolith was diagnosed on stone analysis.



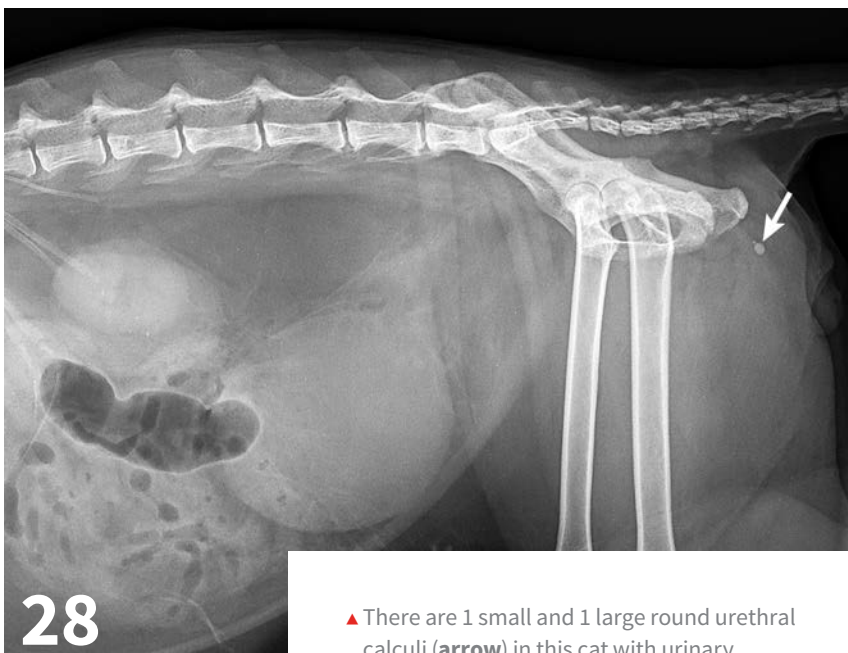
25

▲ Small cystoliths, which were not seen with radiography, were identified on ultrasound. On the ultrasound image, the calculi are gravity-dependent and the 2 larger calculi (**arrows**) demonstrate distal acoustic shadowing.



▲ In this diabetic dog, the bladder wall contained gas, giving the bladder (arrows) a mottled appearance on radiographs. Bladder wall gas is consistent with emphysematous cystitis.

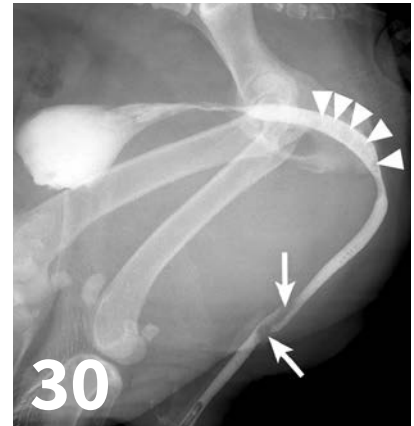
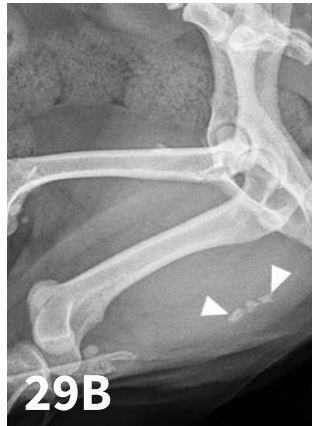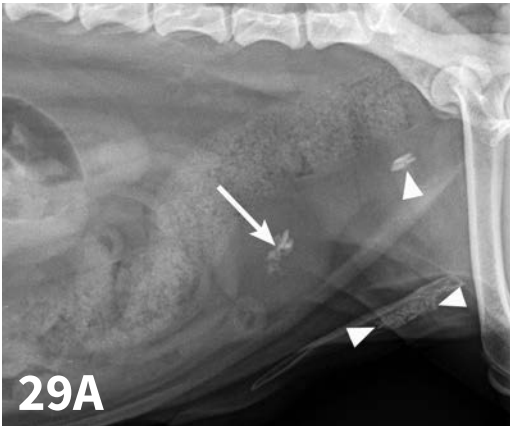
▲ In the ultrasound image (A), an ovoid, heterogenous structure is present at the gravity-dependent dorsal bladder wall, with the patient in dorsal recumbency. When this patient stood and ultrasound was repeated, this structure moved to the gravity-dependent ventral wall (B). The mobility of the structure helped rule out neoplasia, and a diagnosis of hematoma was made.



▲ There are 1 small and 1 large round urethral calculi (arrow) in this cat with urinary obstruction. The bladder is severely distended, and there is decreased detail caudal to the bladder. This demonstrates the importance of including the entire urethra on radiographs when urinary bladder obstruction is present or suspected.

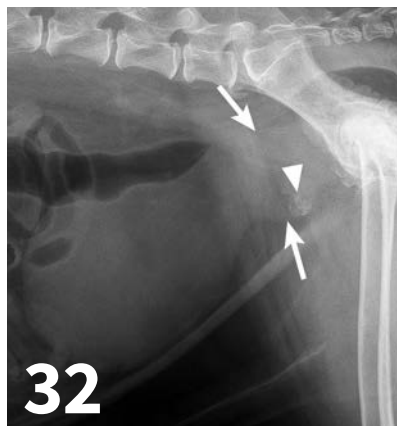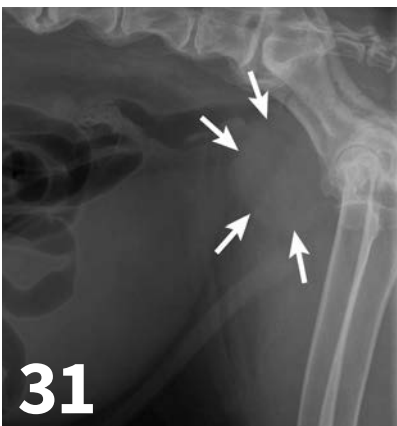Urethra

The normal urethra of dogs and cats is difficult to visualize on survey radiography and ultrasonography. Radiopaque urethroliths can be observed on survey radiographs, and therefore the entire urethra should always be included in the field of view (Figure 28). In male dogs, it is useful to pull the hindlimbs forward to assess the urethra between the pelvis and os penis (Figure 29, next page). The prostate gland and proximal urethra, before entering the pelvic canal, can be visualized with ultrasonography, especially if there is urethral distention. In male dogs, the urethra at the proximal os penis can be evaluated with ultrasonography to assess for urethroliths, which commonly lodge in this location. Positive-contrast retrograde urethrography is the best tool for diagnosis of intraluminal, intramural,



▲ A standard abdominal view (A) in a dog with cystouroliths. There is mineral within the bladder (arrow) and multiple urethroliths (arrowheads). On the perineal view (B), additional urethroliths are present (arrowheads). Additional urethroliths are seen because the hindlimbs were pulled forward; otherwise, they might have been blocked from view by the femurs.

▲ A urethrogram in this male dog defines a mural lesion that appears as a filling defect within the contrast (arrows). This area repeatedly did not fill with contrast and was diagnosed as transitional cell carcinoma. Proximal to this lesion, there are multiple small circular filling defects that are consistent with gas bubbles (arrowheads).



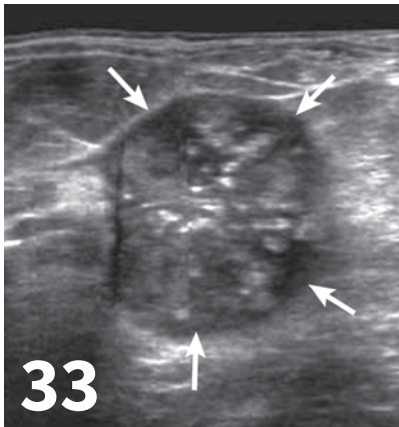
▲ The prostate gland (arrows) in this intact male dog is enlarged but normal in shape with smooth margins and soft tissue opacity. Although this is consistent with benign prostatic hypertrophy, ultrasound would be useful to further define tissue architecture.

▲ The prostatic enlargement (arrows) in this castrated male dog would be most consistent with prostatic neoplasia; the prostate gland should not be visible in a castrated dog. Additionally, there is mineralization (arrowhead) in the ventral prostate; this is commonly associated with neoplasia.

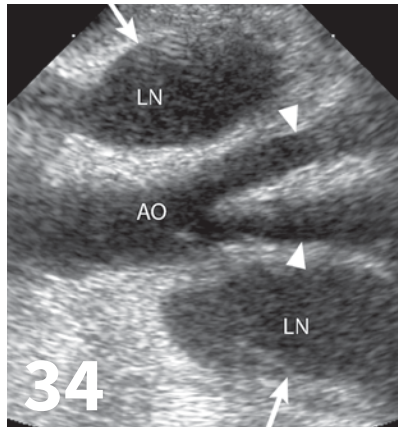
and extramural compressive urethral disorders as well urethral rupture (Figure 30).

Prostate Gland

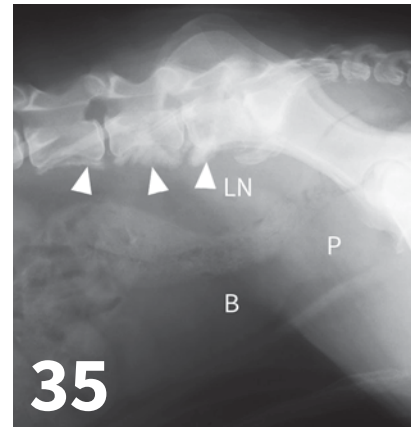
Survey radiography can be used to evaluate the size, shape, and opacity of the prostate gland (Figures 31 and 32). Ultrasonography has the advantage of providing tissue-architecture information. Prostatic abscesses, internal cysts, and paraprostatic cysts are readily visualized on ultrasonography. Ultrasonography can also aid in diagnosing benign hyperplasia (homogenous echotexture with intact capsule) and prostatic neoplasia (heterogenous with coarse echotexture and irregular margins) (Figure 33, next page) and with identifying any potential source of excess androgen production (eg, adrenal



▲ The ultrasound changes of the prostate in this castrated male dog are consistent with neoplasia. The prostate (**arrows**) is heterogeneous, including multiple pinpoint-to-linear hyperechoic areas, some of which shadow (typical for mineral).



▲ Enlarged medial iliac lymph nodes (**arrows, LN**) were identified in a dog with prostatic neoplasia. The lymph nodes are hypoechoic and thickened. These lymph nodes are visible at the level of the terminal aorta (**AO**), where the aorta branches into the external iliac arteries (**arrowheads**).



▲ Although spinal changes can sometimes be detected with ultrasound, this radiograph better depicts the irregular periosteal reaction (**arrowheads**) associated with L5-7 that can be seen with metastatic extension of prostatic neoplasia. The medial iliac lymph nodes (**LN**) are enlarged; this causes ventral displacement of the colon. The prostate (**P**) is easily seen in this castrated male dog. Bladder is labeled (**B**).

glands, retained testes) in cases of suspected squamous metaplasia of the prostate gland. Mineralization of the prostate in a neutered dog is suggestive of neoplasia and can be detected by both survey radiography and ultrasonography. Sublumbar lymph nodes can also be evaluated by ultrasonography, whereas radiography is best for evaluating the adjacent lumbar spine (**Figures 34 and 35**).

Conclusion

Radiography and ultrasonography have distinct advantages and weaknesses in the evaluation of urinary tract disorders in dogs and cats. Combining these 2 imaging modalities will almost always provide improved diagnostic information compared with the use of 1 modality alone. ■

Suggested Reading

1. Feeney DA, Anderson KL. Radiographic imaging in urinary tract disease. In: Bartges J, Polzin DJ, eds. *Nephrology and Urology of Small Animals*. Ames, IA: Wiley-Blackwell; 2011:97-127.
2. Hecht S, Henry GA. Ultrasonography of the urinary tract. In: Bartges J, Polzin DJ, eds. *Nephrology and Urology of Small Animals*. Ames, IA: Wiley-Blackwell; 2011:128-145.
3. Dennis R, McConnell F. Diagnostic imaging of the urinary tract. In: Elliott J, Grauer GF, eds. *BSAVA Manual of Canine and Feline Nephrology and Urology*, 2nd ed. Gloucester, UK: British Small Animal Veterinary Association; 2007:126-158.