



## **Cyst Wall Ultrastructure of Two Sarcocystis spp. from European Mouflon (*Ovis ammon musimon*) in Germany Compared with Domestic Sheep**

Authors: Odening, K., Stolte, M., Walter, G., and Bockhardt, I.

Source: Journal of Wildlife Diseases, 31(4) : 550-554

Published By: Wildlife Disease Association

URL: <https://doi.org/10.7589/0090-3558-31.4.550>

---

BioOne Complete ([complete.BioOne.org](https://complete.BioOne.org)) is a full-text database of 200 subscribed and open-access titles in the biological, ecological, and environmental sciences published by nonprofit societies, associations, museums, institutions, and presses.

Your use of this PDF, the BioOne Complete website, and all posted and associated content indicates your acceptance of BioOne's Terms of Use, available at [www.bioone.org/terms-of-use](https://www.bioone.org/terms-of-use).

Usage of BioOne Complete content is strictly limited to personal, educational, and non - commercial use. Commercial inquiries or rights and permissions requests should be directed to the individual publisher as copyright holder.

---

BioOne sees sustainable scholarly publishing as an inherently collaborative enterprise connecting authors, nonprofit publishers, academic institutions, research libraries, and research funders in the common goal of maximizing access to critical research.

## Cyst Wall Ultrastructure of Two *Sarcocystis* spp. from European Mouflon (*Ovis ammon musimon*) in Germany Compared with Domestic Sheep

K. Odening, M. Stolte, G. Walter, and I. Bockhardt, Institut für Zoo- und Wildtierforschung, Postfach 1103, 10252 Berlin, Germany

**ABSTRACT:** Muscle samples from six wild and two captive European mouflons (*Ovis ammon musimon*) in Germany as well as one domestic sheep from a German zoo were infected with sarcocysts (*Sarcocystis*: Sarcocystidae, Apicomplexa). *Sarcocystis tenella* and *S. arieticanis* were identified by light and electron microscopy. Both species are determined for the first time from wild sheep, and this is the first description of *S. arieticanis* from wild sheep.

**Key words:** *Sarcocystis tenella*, *S. arieticanis*, *Ovis ammon musimon*, domestic sheep, zoo, free range, Germany.

Sarcocysts of at least four *Sarcocystis* species occur in domestic sheep (*Ovis ammon* L., hemerotype) (Dubey et al., 1989): *Sarcocystis tenella* (Railliet, 1886), *S. gigantea* (Railliet, 1886), *S. arieticanis* Heydorn, 1985, and *S. medusififormis* Collins et al., 1979. The first three species occur globally; *S. medusififormis* has been reported only from Australia and New Zealand (Dubey et al., 1989).

Sarcocysts occasionally were found in free-ranging mouflon (*Ovis ammon* L., agriotype), conspecific with domestic sheep. Most of these reports did not include detailed descriptions. Nigro et al. (1991) first described a *Sarcocystis* species in detail from wild sheep (*O. ammon musimon*) in Italy; the parasite probably was *S. tenella*, based on the fine structure of the cyst wall. In our study, we extend the host range of two *Sarcocystis* species to free-ranging mouflon, and compare them with same species of sarcocysts from a domestic sheep, occurring in the same area.

Muscle samples from eight European mouflons (*Ovis ammon musimon*) were evaluated for the occurrence of sarcocysts in 1993 and 1994. Six of these mouflons originated from a population near Niederfinow, Land Brandenburg, Germany

(52°51'N, 13°40'E), founded in 1981 (Briedermann, 1990). The other two mouflons came from two zoos (Tierpark Berlin-Friedrichsfelde and Tierpark Eberswalde, Land Brandenburg, Germany). Sarcocysts from a 7-yr-old domestic sheep that died in June 1993 were used for comparison; this sheep as well as its parents were born in the zoo Tierpark Berlin-Friedrichsfelde. Fresh samples of muscle tissue from head, neck, larynx, heart and loin (*Musculus psoas major*) were tested. Individual sarcocysts found in the musculature were extracted from the muscle fibers under a dissecting microscope for fresh-state examination or prepared for transmission electron microscopical (TEM) investigations. The size of the bradyzoites (cystozoites) was determined in fresh preparations. Their length was taken by measuring the more or less bent median line from pole to pole. Their width was measured at the widest diameter. For TEM investigation the sarcocysts were fixed according to Pospischil and von Bomhard (1979). After repeated washing with 0.1 mol phosphate buffer, they were post-fixed in 2% osmium tetroxide (Serva Feinbiochemica Heidelberg, Germany) solution, dehydrated in ethanol and embedded in Epon® 812 (Serva Feinbiochemica Heidelberg, Germany), and exposed to polymerization for 3 days. The TEM investigations were carried out using an EM 902 A microscope (Zeiss, Oberkochen, Germany).

We found *Sarcocystis tenella* (Railliet, 1886) (synonyms: *S. ovicanis* Heydorn et al., 1975; *Sarcocystis* sp. Nigro et al., 1991) in all eight mouflons and the domestic sheep. The sarcocysts were up to 2.4 mm long and 186 µm wide. The cyst walls were 1.08 to 3.85 µm thick ( $n = 130$ ) and had

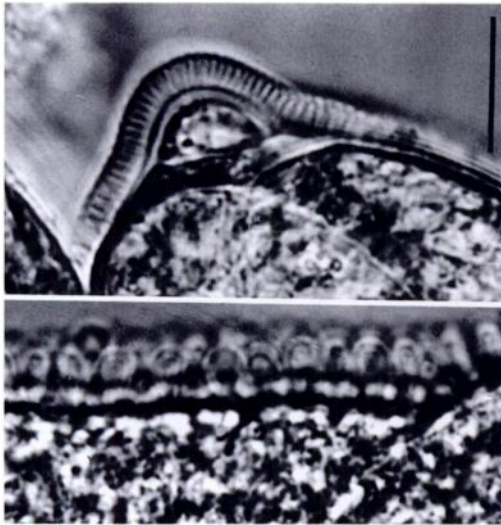


FIGURE 1. *Sarcocystis tenella* from a mouflon, views of the fresh state. Bar = 10  $\mu\text{m}$ . Above: top of a 1.9 mm long sarcocyst from larynx in which the fingerlike protrusions are most prominent. Below: part of the cyst wall from the middle of the sarcocyst.

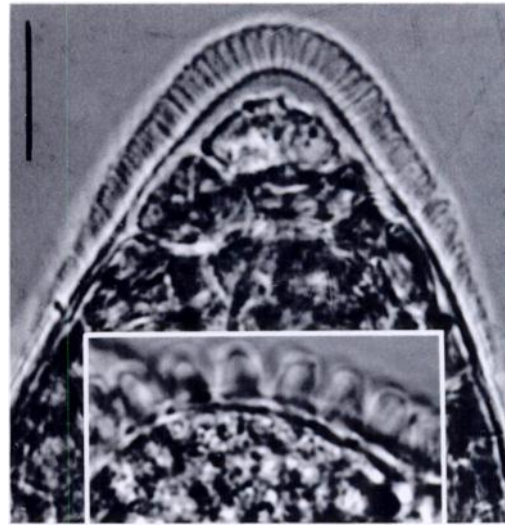


FIGURE 2. *Sarcocystis tenella* from a domestic sheep, fresh state views. Bar = 10  $\mu\text{m}$ . Above: top of a 1.4 mm long mature sarcocyst from Musculus psoas major in which the fingerlike protrusions are most prominent. Below: a part of the cyst wall from the middle of the sarcocyst.

a palisade-like texture, with finger-shaped villar protrusions that were positioned closely side by side (Figs. 1 and 2). The protrusions were 2.10 to 3.85  $\mu\text{m}$  long and 0.42 to 2.14  $\mu\text{m}$  wide ( $n = 105$ ). The distance between the protrusions was 0.2 to 0.5  $\mu\text{m}$  at their base; in mouflons the mean  $\pm$  SD value was  $0.32 \pm 0.10 \mu\text{m}$  ( $n = 15$ ) and in the domestic sheep the mean  $\pm$  SD value  $0.43 \pm 0.11$  ( $n = 10$ ). The protrusions had a truncated tip with plaquelike condensations (Fig. 4). Numerous fine and a few large granules lay in the core (Figs. 3 and 4). The diameters of the compartments in the region of the cyst wall ranged from 6.2 to 31.0  $\mu\text{m}$  in the mouflon ( $\bar{x} \pm \text{SD} = 14.8 \pm 6.6 \mu\text{m}$ ,  $n = 50$ ), and 11.0 to 49.5  $\mu\text{m}$  in the domestic sheep ( $\bar{x} \pm \text{SD} = 28.6 \pm 14.6 \mu\text{m}$ ,  $n = 6$ ). The diameters of the compartments in direction of the center were 6.2 to 28.5  $\mu\text{m}$  in the mouflon ( $\bar{x} \pm \text{SD} = 13.2 \pm 5.9 \mu\text{m}$ ,  $n = 20$ ) and 16.5 to 30.2  $\mu\text{m}$  ( $\bar{x} \pm \text{SD} = 24.3 \pm 6.4 \mu\text{m}$ ,  $n = 6$ ) in the domestic sheep.

All eight mouflons and the domestic sheep also had *Sarcocystis arieticanis* Hey-

dorn, 1985 (synonym: *Sarcocystis* sp. Boch et al., 1979). The sarcocysts were up to 1.8 mm long and 286  $\mu\text{m}$  wide. The cyst walls were thin (0.21 to 0.62  $\mu\text{m}$ ,  $n = 35$ ). They had unstable hairlike, 5.7 to 11.8  $\mu\text{m}$  ( $n = 100$ ) long villar protrusions (Figs. 5 and 6), which contained numerous fine granules in the core (Figs. 7 and 8). The diameters of the compartments in the region of the cyst wall ranged from 20.0 to 59.9  $\mu\text{m}$  ( $\bar{x} \pm \text{SD} = 35.7 \pm 7.9 \mu\text{m}$ ,  $n = 50$ ). The diameters of the compartments in direction of the center ranged from 46.6 to 73.3  $\mu\text{m}$  ( $\bar{x} \pm \text{SD} = 57.9 \pm 10.3 \mu\text{m}$ ,  $n = 10$ ).

The four *Sarcocystis* species known from domestic sheep are unequivocally defined morphologically and easily well distinguished from each other (Dubey et al., 1988, 1989). They can be distinguished clearly from *S. ferovis* Dubey, 1983 (with flattened mushroom-like protrusions) described from the bighorn sheep (*Ovis canadensis*), as well as from *Sarcocystis* sp. Foreyt, 1989 from the American mountain goat (*Oreamnos americanus*) in North America (Dubey et al., 1989), and *Sarco-*

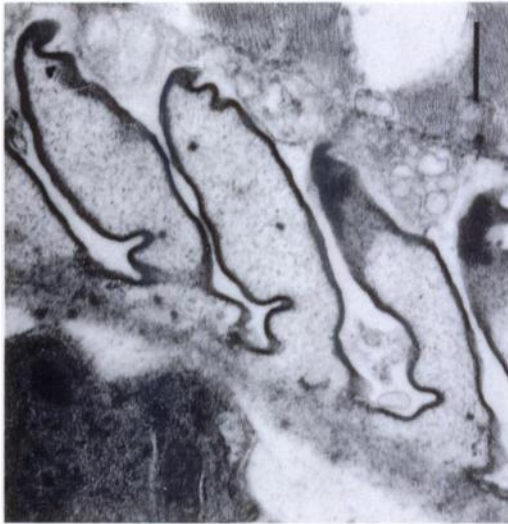

FIGURE 3. *Sarcocystis tenella* from a mouflon; transmission electron micrograph of a longitudinal section of three villar protrusions from a 0.6 mm long sarcocyst from the diaphragm. Note the two large granules in the core of two protrusions. Bar = 0.4  $\mu$ m.

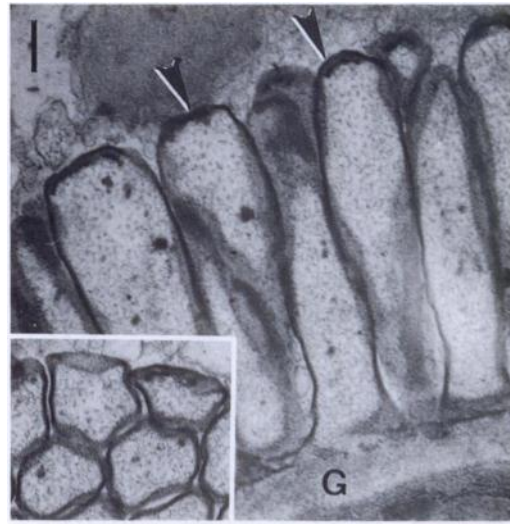


FIGURE 4. *Sarcocystis tenella* from a domestic sheep; transmission electron micrographs of the cyst wall of a 0.6 mm long mature sarcocyst from the Musculus psoas major. Longitudinal section of the villar protrusions; note the electron-dense plaques on the top (arrowhead). Inset: cross-section of the protrusions. G = Ground substance. Bar = 0.4  $\mu$ m.

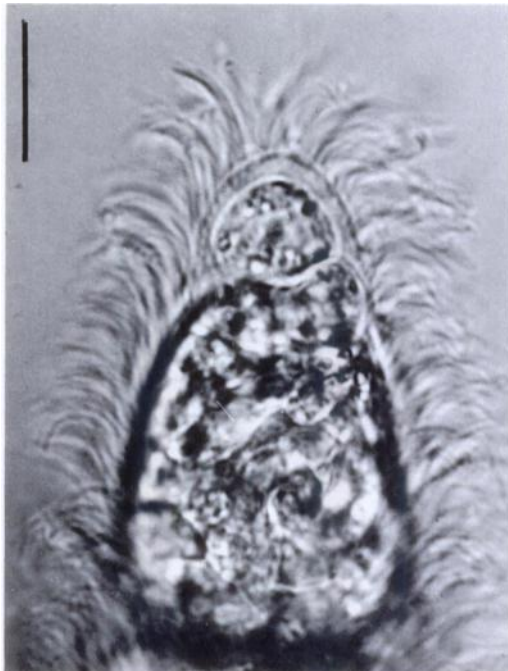

FIGURE 5. *Sarcocystis arieticanis* from a mouflon; fresh state view of a 1.2 mm long mature sarcocyst from neck, with hairlike villar protrusions. Bar = 10  $\mu$ m.

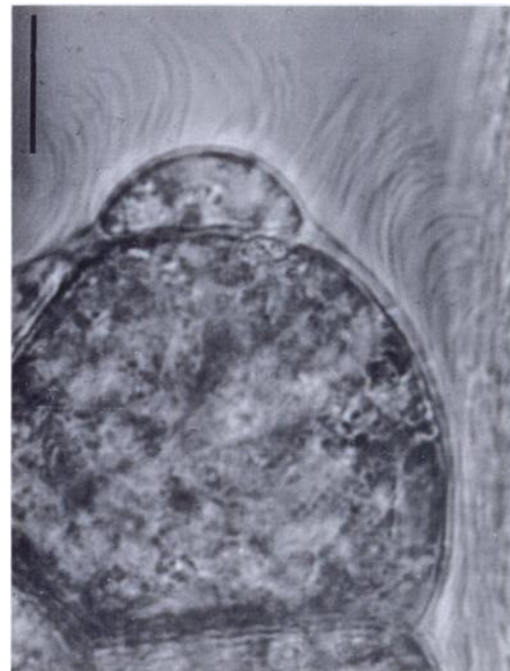


FIGURE 6. *Sarcocystis arieticanis* from a domestic sheep; fresh state view of a 1.1 mm long mature sarcocyst from Musculus psoas major, showing the hairlike villar protrusions on the top. Bar = 10  $\mu$ m.

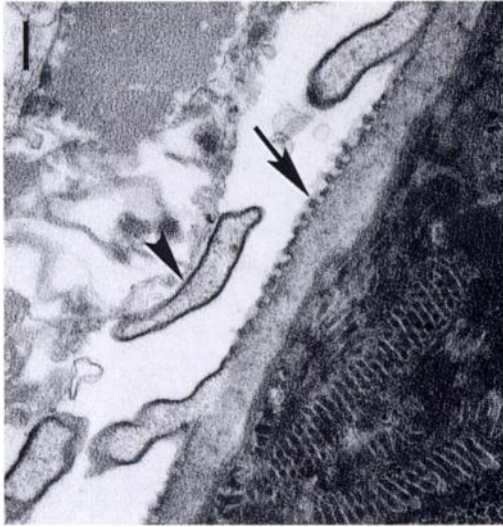

FIGURE 7. *Sarcocystis arieticanis* from a mouflon; transmission electron micrograph of a 0.4 mm long mature sarcocyst from heart, showing the invaginations (arrows) of the cyst wall and sections of hairlike villar protrusions (arrowheads). Bar = 0.4  $\mu$ m.

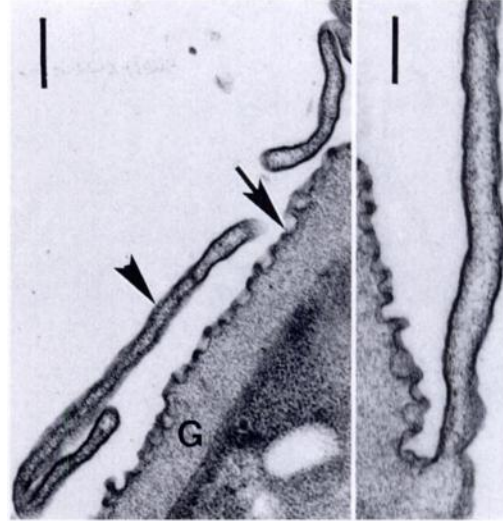


FIGURE 8. *Sarcocystis arieticanis* from a domestic sheep; transmission electron micrographs of the cyst wall of a 1.6 mm long mature sarcocyst from *Musculus psoas major* with invaginations (arrows) and longitudinal cuts of hair-like protrusions (arrowheads). G = Ground substance. Left bar = 0.6  $\mu$ m, right bar = 0.25  $\mu$ m.

*cystis* sp. (2) Cornaglia et al., 1980 from the chamois (*Rupicapra rupicapra*) in Europe. Both sarcocyst forms from the Rupicaprinae, *Rupicapra* sp. and *Oreamnos* sp., appear similar if one compares fig. 10 by Cornaglia et al. (1980) with fig. 3 by Foreyt (1989); the protrusions are club-shaped, with two longitudinal grooves and a bundle of microtubules reaching into the ground substance. *Sarcocystis tenella* and *S. arieticanis* in sheep and the morphologically very similar species *S. capracanis* Fischer, 1979 and *S. hircicanis* Heydorn and Unterholzner, 1983 in goats are different species separated by intermediate host specificity, as shown by unsuccessful transmitting experiments with *S. tenella* and *S. arieticanis* to goats (Heydorn, 1985; Dubey et al., 1989) and with *S. capracanis* and *S. hircicanis* to sheep (Balbo et al., 1988; Dubey et al., 1989). On the other hand, cross transmission experiments by Balbo et al. (1988) provide evidence for a less marked intermediate host specificity. Most *Sarcocystis* spp. described from Caprinae and Rupicaprinae can be distin-

guished according to the ultrastructure of the cyst wall and the species of the intermediate host.

The species composition of *Sarcocystis* spp. in domestic sheep is well established (Dubey et al., 1988, 1989), especially for *S. tenella* and *S. arieticanis* which use canids as definitive hosts. The mature sarcocysts of *S. tenella* and *S. arieticanis* can be distinguished microscopically in the fresh state (Boch et al., 1979; Figs. 1 and 2 compared with Figs. 5 and 6) or also in standard histological preparations (Savini et al., 1993). The fine structure of the cyst wall of *S. tenella* was identical in our domestic sheep and the mouflon (Figs. 3 and 4) and was similar to that described previously for this parasite from domestic sheep (Bergmann and Kinder, 1975; Vlemmas et al., 1989) and from the mouflon (Nigro et al., 1991). Also in *S. arieticanis*, the fine structure of the cyst wall was identical in both our domestic sheep and the mouflon (Figs. 7 and 8). The TEM pictures from domestic sheep in the literature (Heydorn and Mehlhorn, 1987)

correspond well with ours. *Sarcocystis arieticanis* seems to occur less frequently than *S. tenella* (Schmidtová, 1992), but may be more frequent in western Australia (Savini et al., 1993). The present description is the first report from wild sheep.

There are different data on the size of the sarcocysts of both *Sarcocystis* species described here. *Sarcocystis arieticanis* reaches a length of 1.0 mm according to Boch et al. (1979), of 0.9 mm after Dubey et al. (1989), of 2.92 mm according to Schmidtová (1992), of 1.3 mm after Savini et al. (1993), and 1.8 mm in our material. *Sarcocystis tenella* is up to 0.58 mm long after Boch et al. (1979), seldom over 1.0 mm at 105 days post-infection after Heydorn (1985), up to 0.7 mm according to Dubey et al. (1989), up to 1.3 mm according to Savini et al. (1993), and 2.4 mm in our samples.

#### LITERATURE CITED

- BALBO, T., L. ROSSI, P. LANFRANCHI, P. G. MENEGUZ, D. DE MENEGHI, AND M. G. CANESE. 1988. Experimental transmission of a sarcosporidian from alpine ibex to domestic sheep and goats. *Parassitologia* 30: 241–247.
- BERGMANN, V., AND E. KINDER. 1975. Unterschiede in der Struktur der Zystenwand bei Sarcocysten des Schafes. *Monatshefte für Veterinärmedizin* 30: 772–774.
- BOCH, J., A. BIRSCHENCK, M. ERBER, AND G. WEILAND. 1979. *Sarcocystis*- und *Toxoplasma*-Infektionen bei Schlachtschafen in Bayern. *Berliner und Münchener Tierärztliche Wochenschrift* 92: 137–141.
- BRIEDERMANN, L. 1990. Erfahrungen beim Aufbau einer freilebenden Versuchstierpopulation von Mufflons mittels Prägung und Habituation. *Zeitschrift für Jagdwissenschaft* 36: 83–94.
- CORNAGLIA, E., F. GUARDA, F. GUARDA, AND M. E. MISCIATTELLI. 1980. Ricerca, frequenza, diagnosi, morfologia istopatologica ed ultrastrutturale della sarcosporidiosi cardiaca nei camosci e stambecchi. *Annali della Facoltà di Medicina Veterinaria di Torino* 27: 279–296.
- DUBEY, J. P., D. S. LINDSAY, C. A. SPEER, R. FAYER, AND C. W. LIVINGSTON, JR. 1988. *Sarcocystis arieticanis* and other *Sarcocystis* species in sheep in the United States. *The Journal of Parasitology* 74: 1033–1038.
- , C. A. SPEER, AND R. FAYER. 1989. Sarcocystosis of animals and man. CRC Press, Inc., Boca Raton, Florida, 215 pp.
- FOREYT, W. J. 1989. *Sarcocystis* sp. in mountain goats (*Oreamnos americanus*) in Washington: Prevalence and search for the definitive host. *Journal of Wildlife Diseases* 25: 619–622.
- HEYDORN, A. O. 1985. Zur Entwicklung von *Sarcocystis arieticanis* n. sp. *Berliner und Münchener Tierärztliche Wochenschrift* 98: 231–241.
- , AND H. MEHLHORN. 1987. Fine structure of *Sarcocystis arieticanis* Heydorn, 1985 in its intermediate and final hosts (sheep and dog). *Zentralblatt für Bakteriologie, Mikrobiologie und Hygiene A* 264: 353–362.
- NIGRO, M., F. MANCIANTI, P. ROSSETTI, AND A. POLI. 1991. Ultrastructure of the cyst and life cycle of *Sarcocystis* sp. from wild sheep (*Ovis montanus*). *Journal of Wildlife Diseases* 27: 217–224.
- POSPISCHIL, A., AND D. VON BOMHARD. 1979. Der Einsatz des Elektronenmikroskops in der Diagnostik des Veterinärpathologen. *Zentralblatt für Veterinärmedizin A* 26: 643–651.
- SAVINI, G., J. D. DUNSMORE, I. D. ROBERTSON, AND P. SENEVIRATNA. 1993. *Sarcocystis* spp in western Australian sheep. *Australian Veterinary Journal* 70: 152–154.
- SCHMIDTOVÁ, D. 1992. Some characteristics of *Sarcocystis* spp. found in the muscles of sheep. *Folia Parasitologica* 39: 83–84.
- VLEMMAS, I., G. KANAKOUDIS, TH. TSANGARIS, I. THEODORIDES, AND E. KALDRYMIDOU. 1989. Ultrastructure of *Sarcocystis tenella* (*Sarcocystis ovicantis*). *Veterinary Parasitology* 33: 207–217.

Received for publication 7 June 1994.