

Biomaterials and Epithesis, Our Experience in Maxillo Facial Surgery

G. Fini, L.M. Moricca, A. Leonardi,
S. Buonaccorsi and V. Pellacchia
*La Sapienza/ Roma
Italy*

1. Introduction

Maxillofacial prosthetics is considered in literature as "... the art and science of anatomic, functional and cosmetic reconstruction, by the use of non-living substitutes, of those regions in the maxillae, mandible and face that are missing or defective..." 1. In the maxillofacial surgery where malformative, oncologic traumatologic pathology and the plastic surgery are treated, the maxillofacial prostheses, in selected cases, can reach a satisfactory therapeutic result from functional, aesthetic, psychologic, and social point of views. In a delicate district, such as the face, where a heavy deficit can determine huge psychologic and social problems, the conventional reconstructive surgery intervenes with reconstructive techniques and with the biomaterials insertion, often insufficient to guarantee the restoration of the harmony of the face. When these conditions are verified, the solution resides in the osteointegration concept and in the application of the epithesis. There are certainly some limits of application of these prostheses, first, the ethics limits: the epithesis constitute in fact an alternative only when the conventional reconstructive surgery cannot be applied, but inside these limits, it is really possible to find an excellent therapeutic resource in patients who cannot undergo surgical interventions. In literature, it is possible to find different kinds of reconstruction of missing body parts by the application of prothesis². The osteointegration concept was introduced at first time by Professor Branemark in 1960 to describe the "direct structural and functional connection between living bone and the surface of a plant exposed to load, understood as a not static but dynamic process³. According to his school of thought, the technique of positioning of the implant is fundamental, to take place in the most complete precision and to allow the initial stability of one's self. Other elements conditioning the success of the osteointegration are the material of the implant, the form, the areas of the application, and the patient's clinical conditions. The first titanium osteointegration implant was positioned in 1965 in the jaw without dental elements 4; in 1977, implants were positioned in mastoid areas for the application of an acoustic translator. In 1979, implants for the fixation of epithesis of ears, noses, and eyes were positioned. At present, the indication to the position of epithesis as the first choice of treatment is when the conventional reconstructive interventions turn out to be inapplicable or ineffective. The epithesis is a good resolution for the patient because it is not traumatic and has short-time result, removing every psychologic physique obstacle for the inclusion in a normal social life.

2. Our experience

From May 2002 to December 2010, 415 facial prosthesis (1117 implants) have been positioned in our Ephitesy Center. Defects were congenital (N = 142), consequent to trauma (N = 95) and to demolitive surgery for malignant tumors (N = 95), and infection (N = 83). In 40 patients, implants were placed in previously irradiated areas. A total of 1117 titanium implants were placed to support 187 auricular prostheses (bilateral in 29 cases), 126 orbital prostheses, 89 nasal prostheses, and 13 complex midfacial prostheses.

Clinical Case 1 U.G., 57-year-old patient, came to our observation with ethmoidal-sphenoidal-orbital-hemimaxillary resection and reconstruction with pectoral flap complicated in the same year by cerebral abscess of *Eikenella*. The patient was presenting the absence of the skeleton structures and the soft tissues of the third middle of the right emi-face with involvement of the nose and of the hard palate. The pectoral flap was causing deficit in the movements of extent and left rotation of the head. As a consequence of a cerebral ictus and for the detachment of septic carotid plaque embolus, the patient presented with hemiplegy. Heavy deficits were furthermore present to deglutition and masticatory function. The patient was arriving to our observation in order to restore the symmetry of the face and the integrity of the hard palate and to recover the motility of the cervical stroke. A surgical intervention of positioning of epithesis to rebuild the third middle and superior of the face and of the revision of the pectoral flap was therefore planned. Four fixtures with related abutments were placed to support anchoration for the midfacial prosthesis (Figs 3 and 4). In addition, a dental implant was placed in the right tuber maxillae to support a palatal obturator (Fig 5). Finally, a surgical revision of the pectoral flap was performed. Ten months after surgery, a palatal obturator was placed so that it was possible to remove percutaneous endoscopicgastrostomy (PEG).

Clinical Case 2, R.A., a 40-year-old man affected by the Goldenhar syndrome, underwent different reconstructive surgical treatments to restore the normal symmetry of the face soft tissues. The patient came to our center presenting a facial asymmetry characterized by atrophy of the right hemifacial soft tissues, associated to auricular agenesis and to esterior uditive conduct and "anteroposizione" of the left auricular (Figs 6 and 7). Clinical and radiologic examinations with computer tomography dental scan and Telecranium x-ray in 2 projections with cefalometric study were performed to evaluate the bone and the soft tissues. After 1 month, a surgery has been performed to remove the residual cartilage planted in the site corresponding to porous polyethylene prosthesis, positioned during the previous surgical treatment. In addition, 2 fixtures with abutment have been positioned in the right mastoid bone. Then the left auricular was positioned to reestablish the normal structures of the face. In the same surgical time, 2 porous polyethylene prostheses were implanted in the malar region to restore the sagittal diameter of the middle third of the face; then 2 porous polyethylene prostheses were implanted in the mandibular angle, and 1 prosthesis was implanted on the mandibulae, to restore the transversal and sagittal diameter of the third inferior of the face. After 3 months, an auricular prosthesis associated to polyacrylamide implant was positioned in bilateral preauricular area (Figs 8 and 9). Clinical and radiologic follow-up demonstrated a good integration of implants and the biomaterial

Clinical Case 3 A.S., a 51-year-old man affected with posttraumatic anophthalmia, sequelae of left orbit exenteration and reconstruction of the eye socket with a titanium mesh covered by dermo-adipose flap, came to our observation with anophthalmia O.S. and fibrotic scars. Clinical and radiologic examinations with three-dimensional computed tomography were

performed to evaluate the bone and the soft tissues (Figs 10 and 11). After the clinical and radiologic evaluation and the patient's agreement, 4 fixtures with corresponding abutments were placed to support the anchor of the orbital epithesis. Nasal and orbital scars were corrected by little flaps (Figs 12 and 13).

Clinical Case 4 F.M., a 61-year-old man, was referred with a nose extirpation for a squamocellular cancer on the nasal tip, involving all nasal structure, 7 years before (Fig 14). The patient and his family declined any kind of reconstructive operative interventions, so the patient underwent nasal movable prosthesis resting. Based on this situation, we had proposed to him nasal removable prosthesis fixed with bone paranasal implants. For this reason, the patient had undergone computed tomography scan of the head and neck to study bone density and then 2 implants (4 mm) were placed. Follow-up at 3, 6, and 12 months with clinical visits and computed tomography scan revealed correct implant bone integration (Fig 15).

Clinical Case 5 P.D., a 25-year-old woman, underwent surgical exenteration orbitae because of retinoblastoma. The orbital cavity was restored by temporal muscle flap and dermal-free flap. The patient underwent many reconstructive surgical treatments through the use of fillers of biomaterials in frontal-temporal-cheek side, to reconstitute the anatomic structure. She arrived in our observation with a moving orbital prosthesis (Fig 16). Clinical and radiologic examinations with three-dimensional computed tomography were performed to evaluate the bone and the soft tissues. In accordance with the patient's desire, 3 titanium fixtures with abutments were implanted to position the orbital prosthesis (Fig 17).

Clinical Case 6 M.N., a 56-year-old woman, was referred with a partial auricular extirpation for a basocellular cancer on the auricular left elice. The 2/3 superiors of the auricular pavilion have been removed, with a partial deficit of the pavilion itself, which has caused psychologic problems to the patient. In agreement with the patient, a second surgical treatment was performed, modeling porous polyethylene peace with Nagata technique and covered by temporoparietal fascia and dermo-epidermic flap to fill the auricular fault. The biomaterial is not osteointegrated, so it has been removed. For such reason, in agreement with the patient justified strongly to an immediate and no invasive aesthetic rehabilitation, 2 fixtures with abutments have been positioned that support auricular epithesis (Figs 18Y20). The clinical and radiologic follow-up has shown a correct osteointegration of the implants reaching psychologic stability of the patient.

Clinical Case 7 G.B., a 68-year-old woman, with epatotrasplanting and hepatitis C virus has arrived in our observation with a necrotic lesion of the nasal tip resulting to immunosuppressive therapy. She was referring to have noticed the appearance of the necrosy and his progressive growth soon after the end of the therapy. The patient was presenting exposure of the cartilaginous septum with erosion and cutaneous necrosy to the nasal base (Fig 21). Because of the clinical conditions of the patient, a fixture's implant has been made for the positioning of an epithesis in order to obtain an effective reconstruction. Three fixtures with abutments have been applied. A fixture was removed approximately 2 months after the installing because it is not integrated. The other 2 implants seemed to be well supplemented to allow the positioning of the bar that supports the epithesis, but after 2 months, 1 fixture has been removed because of missed osteointegration. Therefore, it was decided to position some magnets to anchorage the epithesis (Fig 22).

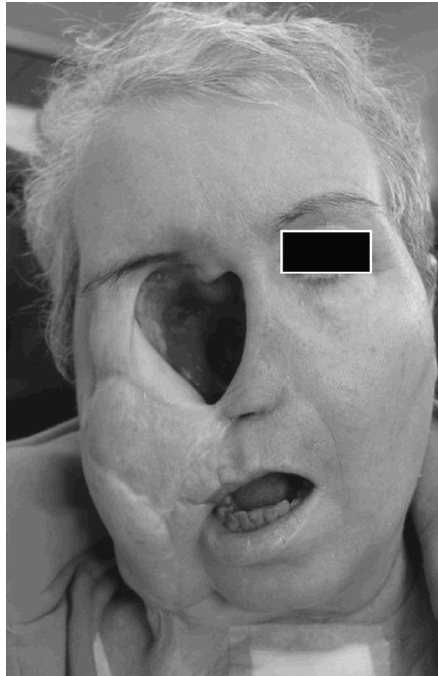

Fig. 1. Preoperative frontal view of the patient.

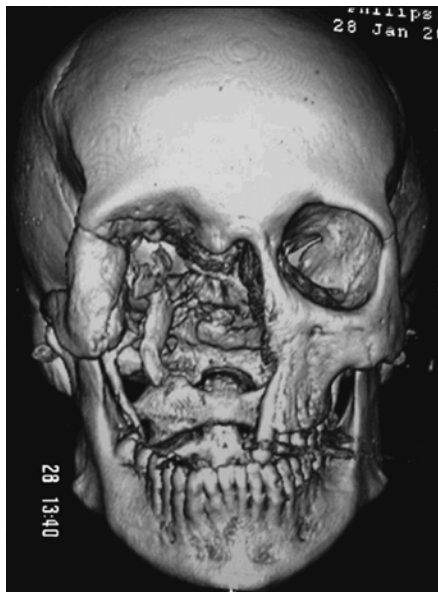


Fig. 2. Preoperative three-dimensional computed. TomographyVfrontal view of the patient.

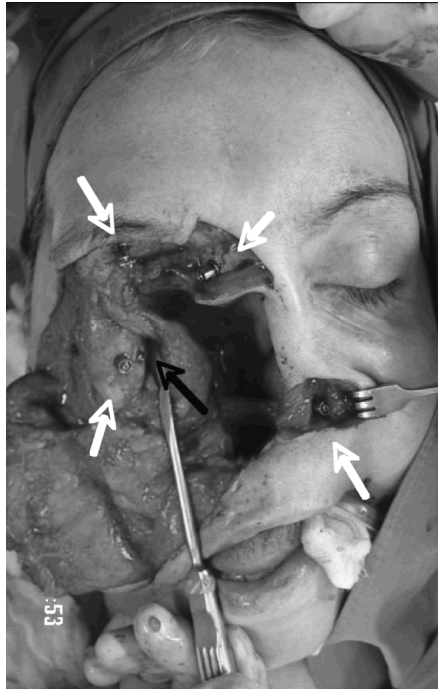


Fig. 3. Intraoperative point of view.

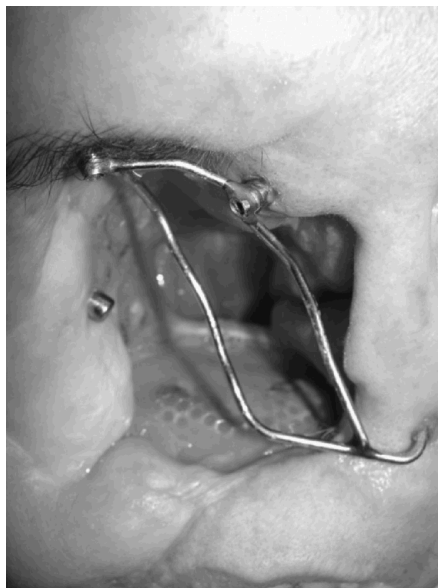

Fig. 4. Anchorage for the midfacial prosthesis.

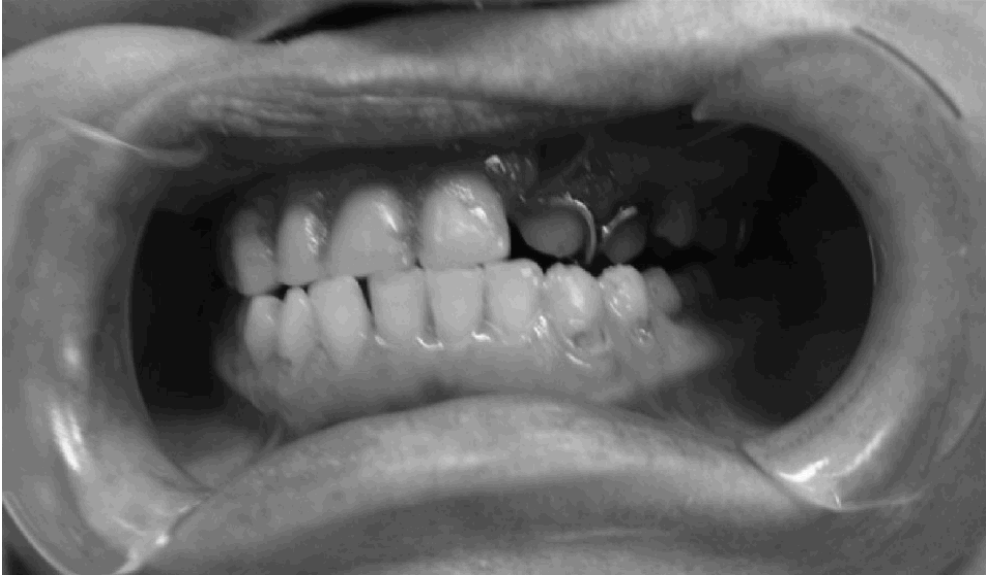

Fig. 5. The palatal obturator.

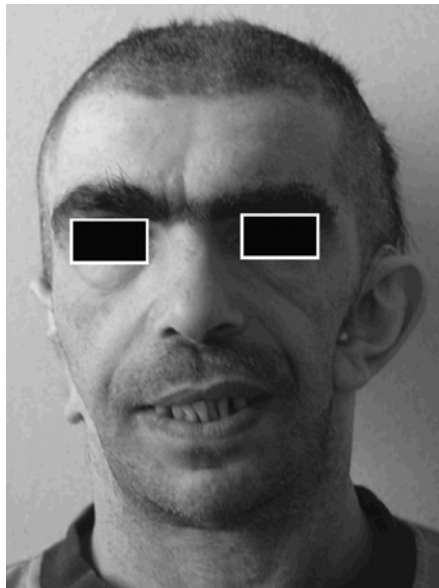

Fig. 6. Preoperative frontal view of the patient.

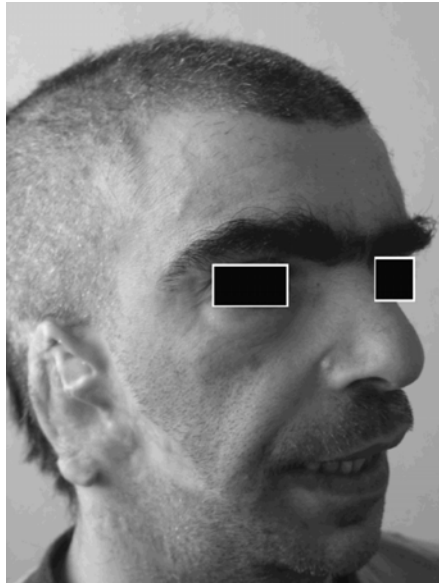


Fig. 7. Preoperative lateral view of the patient.

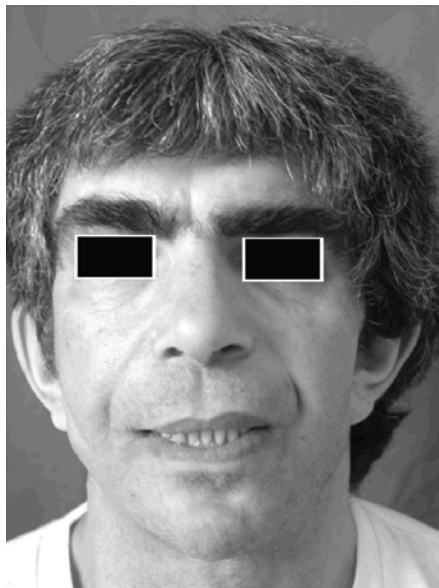


Fig. 8. Postoperative frontal view of the patient.

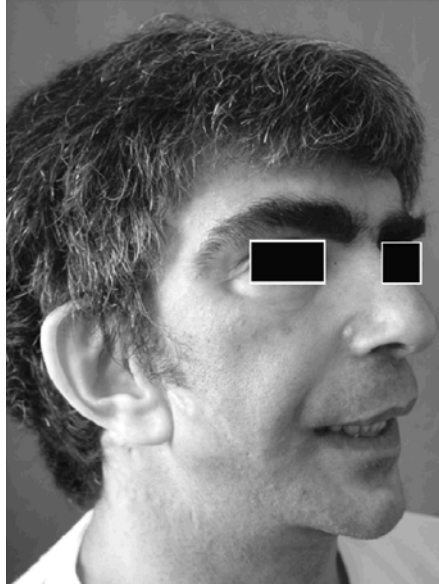

Fig. 9. Postoperative lateral view of the patient.

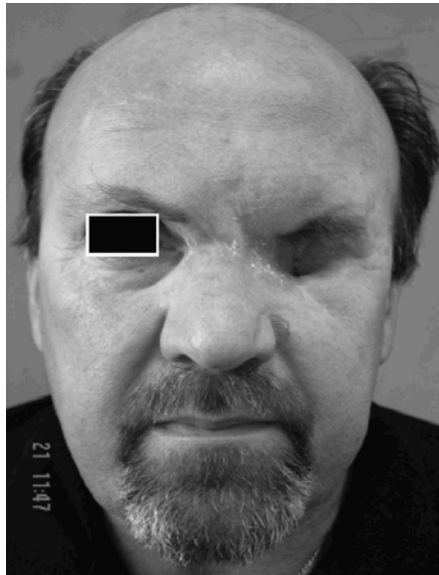


Fig. 10. Preoperative frontal view of the patient.

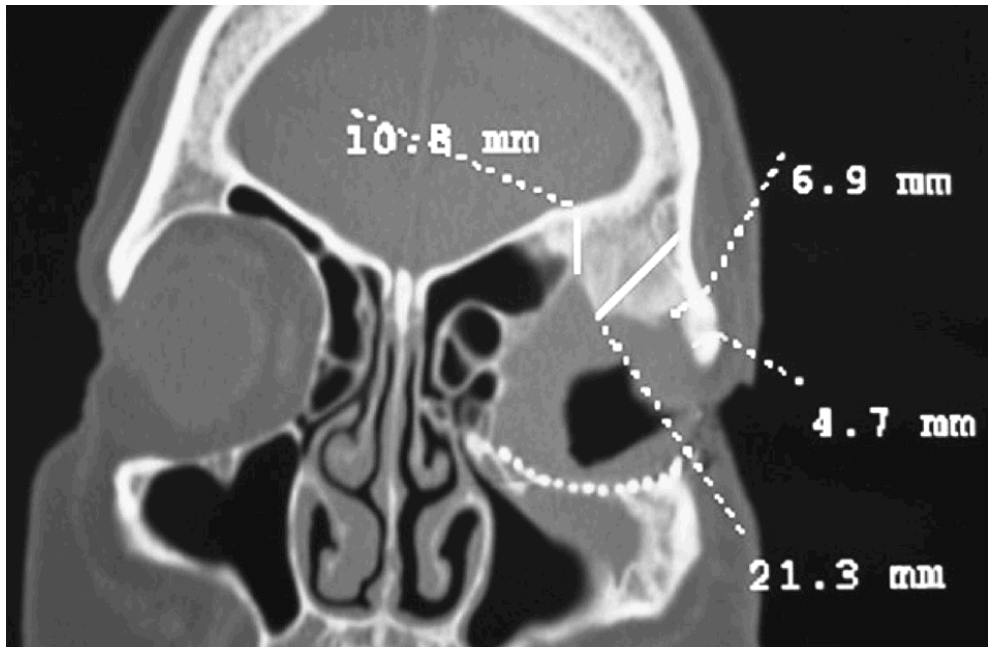


Fig. 11. Preoperative computer tomography Vfrontal view.

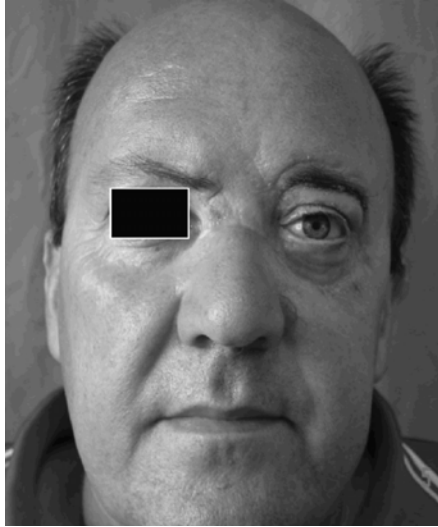

Fig. 12. Postoperative frontal view of the patient.

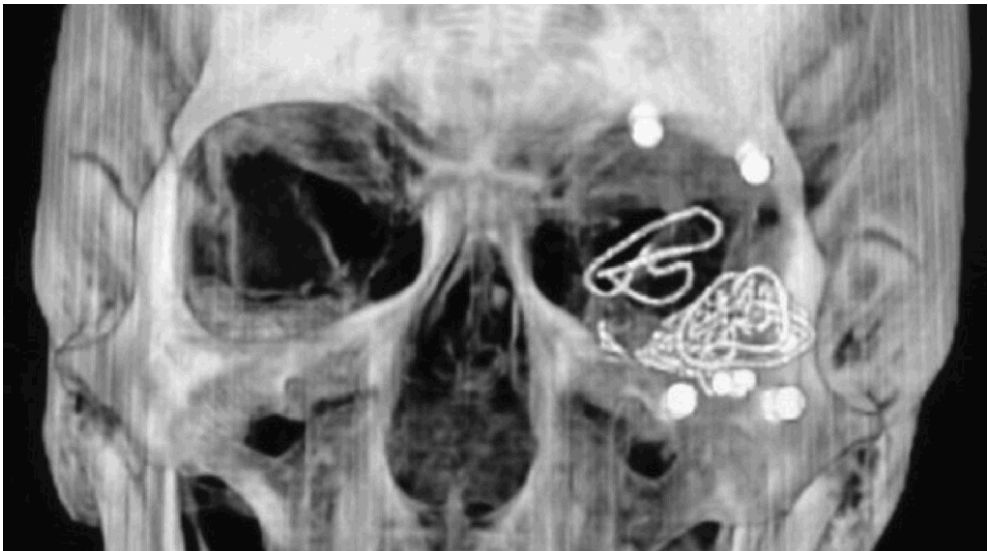


Fig. 13. Postoperative computer tomography frontal view.

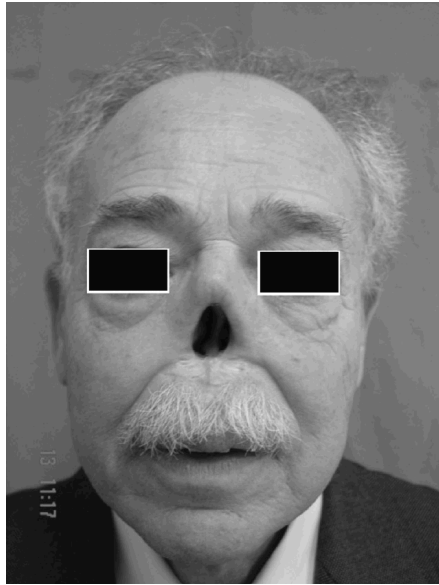


Fig. 14. Preoperative frontal view of the patient.

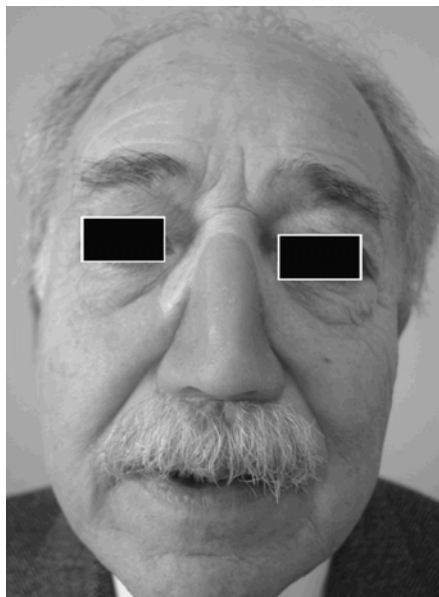


Fig. 15. Postoperative frontal view of the patient.

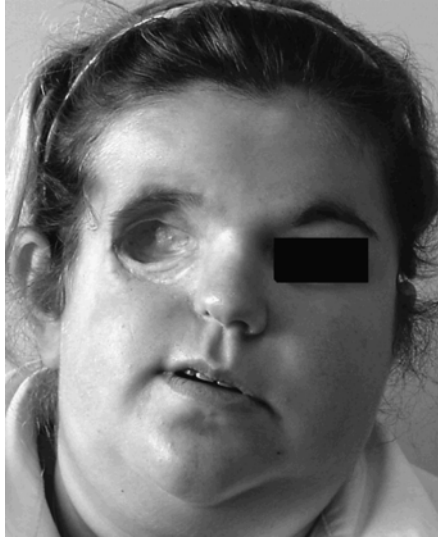

Fig. 16. Preoperative frontal view of the patient.

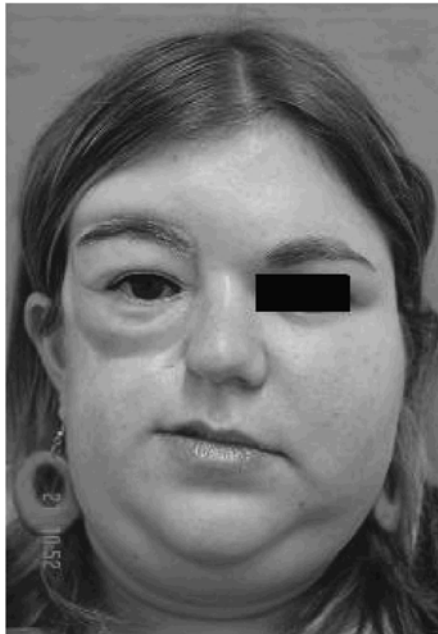

Fig. 17. Postoperative frontal view of the patient.

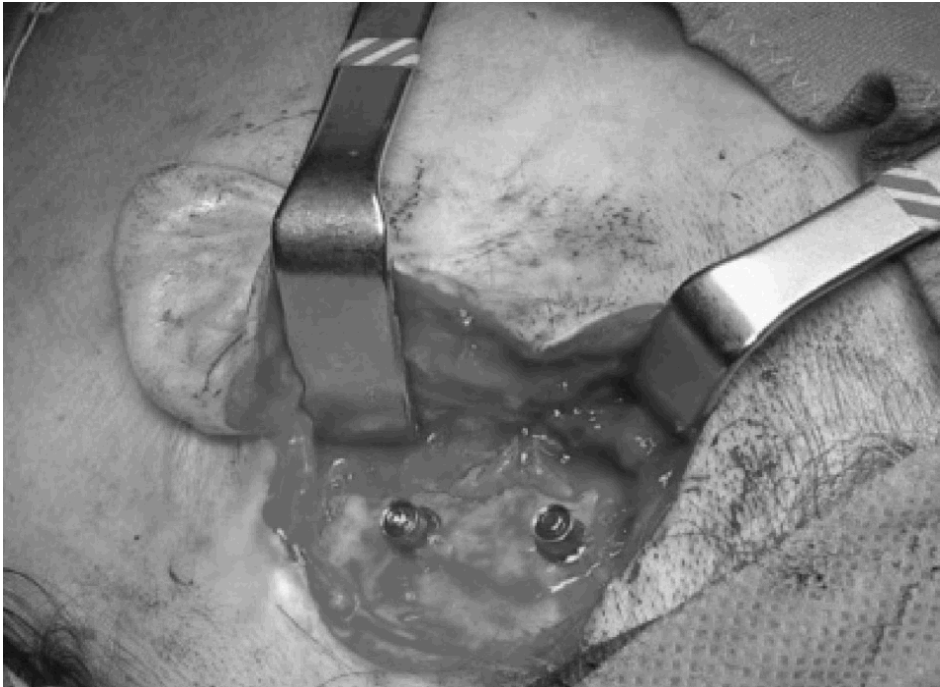

Fig. 18. Fixtures positioning.

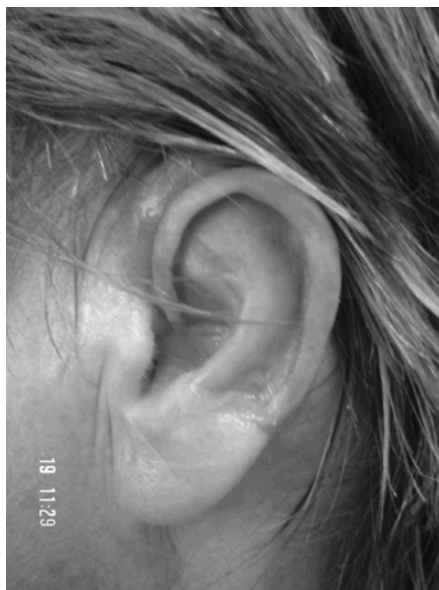


Fig. 19. Patient with auricular epithesis.

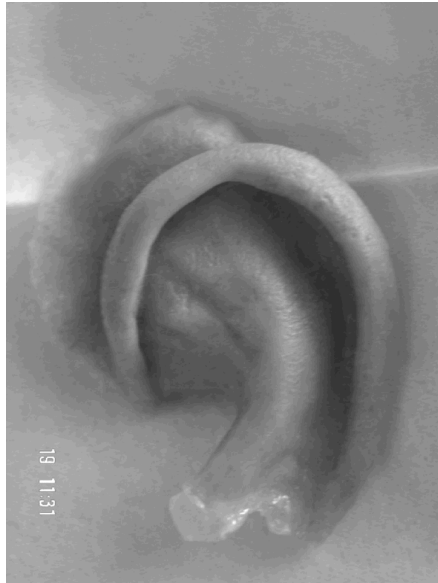

Fig. 20. Auricular epithesis.

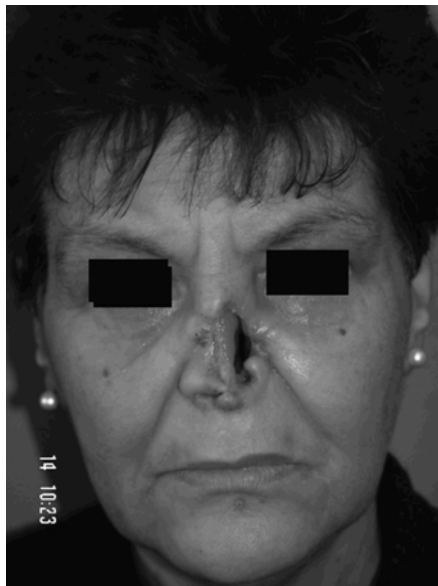

Fig. 21. Preoperative frontal view of the patient.

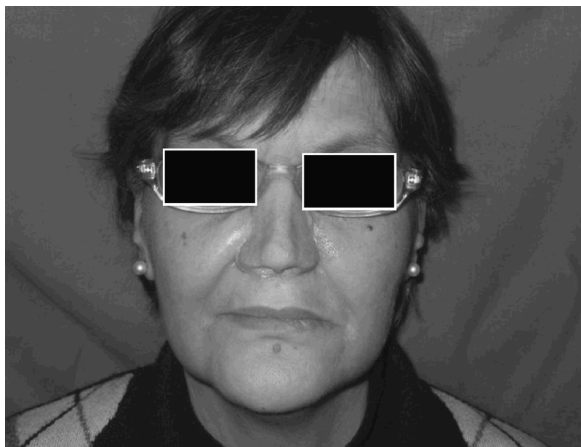

Fig. 22. Postoperative frontal view of the patient.

3. Conclusion

The facial prosthetic rehabilitation is a valid alternative when the conventional reconstructive surgical techniques cannot be applied either because of the psychophysical conditions of the patient or because of an excessive substance loss. The surgical technique with prosthesis has several applications: malformative, infective, traumatic pathology, results of oncologic surgery and radiant therapy, and particular clinical conditions such as diabetes, leukemia, and others. The position of epithesis, as described in the literature^{5,6} and confirmed by the experience of our epithesis Center, is suitable in selected cases:

- reconstruction with patient's own tissue, which is uneventful or impossible;
- "Reversible" intervention to operate clinically;
- Surveillance in oncologic patients;
- Advanced age or poor health; and poor tissues quality patient's choice

The described technique presents absolute limits such as osteolytic process, leukemia-lymphoma, and terminal cirrhosis and relative limits such as ending life, hygienic deficiency, and psychological refuse. Another important limit is the radiotherapy treatment; the skeletal structure of persons who undergone radiotherapy react to the osteointegration process with a lower success percent. It goes, in fact, to consider that if the combined application of the chemotherapy and radiotherapy treatments with demolitive surgery increases the life on average, the survival of the subject with surgical cancer⁷ ablation increases, compromising the quality of life.⁷ The results of the osteointegration in patients who have underwent chemotherapy are very variable, approximately 60% and 100%.⁸ In accordance with the literature, we can affirm that the radiotherapy compromises the human tissues, hindering the osteointegration process, when the irradiation is around 5000 Gy. Besides the site and the radiation dose, the time existing between the radiant treatment and the positioning of the implant is another determinant factor for the success of osteointegration process. In particular, 6 months should exist between the term of the radiant treatment and the positioning of the implant period in which the tissue alteration produced by the radiations are in regression. According to the oncologic guideline, it would

be more opportune to wait 1 year to avoid the recidivism risk.⁸ Furthermore, the treatment in the hyperbaric room is effective in the bone life, with higher success percents.^{8,9} Another fundamental aspect is the epithesis stability, which depends from many circumstances such as hygienic condition, material quality, and the correct method of the epithesis production; when these conditions are respected, the epithesis can resist for 2 years. The application of an epithesis happens with no invasive and immediate results, both from the aesthetic and psychologic point of views, allowing to get around with the heavy social insertion problems derived from his facial deformation. The therapeutic iter in the reconstructive treatment with epithesis foresees a dynamic study with few fundamental stages:

- clinical, radiologic, and psychologic evaluation;
- surgical planning;
- positioning of the fixtures;
- templating;
- preparation of the epithesis;
- fixtures; and epithesis exposure.


Beyond the application of bone implants, several retention methods are possible: anatomic, exploiting the premade cavity getting to the deficit (ocular epithesis), and mechanical, exploiting outside anchorage strengths (sight glasses) and adhesive, by glue.¹⁰ Thanks to the use of the bone implants, it has been able to get around the problems caused by the use of adhesives like decoloration, the precocious deterioration of the epithesis, and inflammatory phenomena of the skin in contact with epithesis' materials. Under the point of view of the aesthetic result, the margins of an epithesis can be easily hidden, and the prosthesis is more stable, is easy to wear, and keeps under a hygienic point of view. Furthermore, the psychologic appearance should not be neglected because, unlike traditional prosthesis, the epithesis fixed with implants are not considered as an extraneous object, with the consequent improvement of a good quality of life. At present, our experience teaches us that the indication to the position of epithesis as the first choice of treatment is when the conventional reconstructive interventions turn out to be inapplicable or ineffective

4. References

- Bulbulian AH. Maxillofacial prosthetics: evolution and practical application in patient rehabilitation. *J Prosthet Dent* 1965; 15:554Y569
- Fini Hatzikiriakos G. Uno sguardo al passato, curiosita` sulle protesi nasali. *Il Valsala* 1985;61:61Y64
- Tjellstrom A. Osteointegrated implants for replacement of absent or defective ears. *Clin Plast Surg* 1990;17:355Y366
- Tjellstrom A, Granstrom G. One stage procedure to establish osteointegration: a zero to five years follow-up report. *J Laryngol Otol* 1995;109:593Y598
- Schaaf NG. Maxillofacial prosthetics and the head and neck cancer patients. *Cancer* 1984;54:2682Y2690
- Labbe´ D, Be´nateau H, Compe`re JF, et al. Implants extra-oraux: indications et contre-indications. *Rev Stomatol Chir Maxillofac* 2001;102:239Y242

- Be´nateau H, Crasson F, Labbe´ D, et al. Implants extra-oraux et irradiation: tendances actuelles. *Rev Stomatol Chir Maxillofac* 2001;102:266Y269
- Granstrom G, Jacobsson M, Tjellstrom A. Titanium implants in irradiated tissue: benefits from hyperbaric oxygenation. *Int J Oral Maxillofac Implants* 1992;7:15Y25
- Markt JC, Lemon JC. Extraoral maxillofacial prosthetic rehabilitation at the M.D. Anderson Cancer Center: a survey of patient attitudes and opinions. *J Prosthet Dent* 2001;85:608Y613
- Tjellstrom A, Granstrom G. One-stage procedure to establish osteointegration: a zero to five years follow-up report. *J Laryngol Otol* 1995;109:593Y598
- Ramires PA, Miccoli MA, Panzarini E, Dini L, Protopapa C. In vitro and in vivo biocompatibility of a Polyalkyamide Hydrogel for soft tissue augmentation. *J.Biomed.Mater.Res.Part.2004*; 72: 230-238. 2004.
- Christensen LC, Breiting VB, Aasted A, Jorgensen A, Kebuladze I. Long-Term effects of polyacrylamide hydrogel in human breast tissue. *Plast.Reconstr.Surg.*2003; 11:1883-1890
- Rees TD, Ashlet FL, Delgado JP. Silicone fluid injectons for facial atrophy: a 10 years study. *Plast.Reconstr.Surgery.* 1985;52: 118-125.
- Greenwald AS, Boden SD, goldberg VM et al. Bone graft substitutes: Facts, fictions and applications. *J. Bone Joint Surg Am* 2001; 83-A:S98-S103
- Bauer TW, Muschler GF. Bone Graft Materials. An overview of The basic science. *Clin Orthop.* 2000; 371:10-27.
- Oka Y, Ikeda M. Treatment of severe osteochondritis dissecans of the elbow using osteochondral grafts from a rib. *J Bone Joint Surg Am.* 2001 83-b: 738-739
- Stevenson S. Biology of bone grafts. *Orthoped Clin North Am.* 1999; 30:543-552.
- Skowronski PP, An Yh. Bone graft materials in orthopaedics. *MUSC Orthopaed J.* 2003;6:58-66
- Betz RR. Limitation of autograft and allograft: new synthetic solutions. *Orthopedics* 2002;25(Suppl):S561-S560
- Hollinger JO, Mark DE, Goco P, et al. A comparison of four particulate bone derivatives. *Clin*
- Pietrzak WS, MillervSD, Kucharzyk DW, et al. Demineralized bone graftvformulations: Design, development, and a novel exemple. *Proceedings of the Pittsburg BonevSymposium, Pittsburg, PA, August 19-23,*"003,557-575.
- Davy DT. Biomechanical issues in bone transplantation. *Orthop Clin North Am.*1999;30:553-56 science and technology for the Craniomaxillofacial Surgeon. *J Craniofac. Surg.* 005(16);6:981-988.15
- Mauriello JA, McShane R, Voglino J. Use Vicryl(Polyglactina 910) mesh implant for correcting enophthalmos A study of 16 patients. *Ophthal Plast Reconstr Surg* 1990; 6:247-251.
- S. Ozturk, M Sengezer, S Isik et all. Long Term Outcomes of Ultra Thin Porous Polyethylene Implants used for Reconstruction of Orbital Floor Defects. *J Craniofac Surg.* 2005 (16) 6:973-977.
- S. Buelow, D Heimburg, N. Pallua. Efficacy ad Safety of Polycrylamide Hydrogel for Facial Soft-Tissue Augmentation. *Plast Reconstr Surg* 2005 (15);1137-1146.
- KW Broder, SR Cohen. An Overview of Permanent and Semipermanent Fillers. *Plast Reconstr Surg* 2006 118(3 suppl.) S7_S14

Biomaterial Implantation in Facial Esthetic Diseases: Ultrasonography Monitor Follow-Up
Elena Indrizzi, MDS, Luca Maria Moricca, MD, Valentina Pellacchia, MD,
Alessandra Leonardi, MD, Sara Buonaccorsi, MD, Giuseppina Fini, MDS, PhD. The
Journal of Craniofacial Surgery -Vol.19, N. 4 -July 2008



Biomaterials - Physics and Chemistry

Edited by Prof. Rosario Pignatello

ISBN 978-953-307-418-4

Hard cover, 490 pages

Publisher InTech

Published online 14, November, 2011

Published in print edition November, 2011

These contribution books collect reviews and original articles from eminent experts working in the interdisciplinary arena of biomaterial development and use. From their direct and recent experience, the readers can achieve a wide vision on the new and ongoing potentialities of different synthetic and engineered biomaterials. Contributions were selected not based on a direct market or clinical interest, but based on results coming from very fundamental studies. This too will allow to gain a more general view of what and how the various biomaterials can do and work for, along with the methodologies necessary to design, develop and characterize them, without the restrictions necessarily imposed by industrial or profit concerns. The chapters have been arranged to give readers an organized view of this research area. In particular, this book contains 25 chapters related to recent researches on new and known materials, with a particular attention to their physical, mechanical and chemical characterization, along with biocompatibility and histopathological studies. Readers will be guided inside the range of disciplines and design methodologies used to develop biomaterials possessing the physical and biological properties needed for specific medical and clinical applications.

How to reference

In order to correctly reference this scholarly work, feel free to copy and paste the following:

G. Fini, L.M. Moricca, A. Leonardi, S. Buonaccorsi and V. Pellacchia (2011). Biomaterials and Epithesis, Our Experience in Maxillo Facial Surgery, Biomaterials - Physics and Chemistry, Prof. Rosario Pignatello (Ed.), ISBN: 978-953-307-418-4, InTech, Available from: <http://www.intechopen.com/books/biomaterials-physics-and-chemistry/biomaterials-and-epithesis-our-experience-in-maxillo-facial-surgery>

INTECH
open science | open minds

InTech Europe

University Campus STeP Ri
Slavka Krautzeka 83/A
51000 Rijeka, Croatia
Phone: +385 (51) 770 447
Fax: +385 (51) 686 166
www.intechopen.com

InTech China

Unit 405, Office Block, Hotel Equatorial Shanghai
No.65, Yan An Road (West), Shanghai, 200040, China
中国上海市延安西路65号上海国际贵都大饭店办公楼405单元
Phone: +86-21-62489820
Fax: +86-21-62489821

© 2011 The Author(s). Licensee IntechOpen. This is an open access article distributed under the terms of the [Creative Commons Attribution 3.0 License](#), which permits unrestricted use, distribution, and reproduction in any medium, provided the original work is properly cited.