

## Chapter

# A Comprehensive Overview of Broca's Aphasia after Ischemic Stroke

*Dragoș Cătălin Jianu, Tihomir V. Ilic, Silviana Nina Jianu, Any Docu Axelerad, Claudiu Dumitru Bîrdac, Traian Flavius Dan, Anca Elena Gogu and Georgiana Munteanu*

## Abstract

Aphasia denotes an acquired central disorder of language, which alters patient's ability of understanding and/or producing spoken and written language. The main cause of aphasia is represented by ischemic stroke. The language disturbances are frequently combined into aphasic syndromes, contained in different vascular syndromes, which may suffer evolution/involution in the acute stage of ischemic stroke. The main determining factor of the vascular aphasia's form is the infarct location. Broca's aphasia is a non-fluent aphasia, comprising a wide range of symptoms (articulatory disturbances, paraphasias, agrammatism, anomia, and discrete comprehension disorders of spoken and written language) and is considered the third most common form of acute vascular aphasia, after global and Wernicke's aphasia. It is caused by a lesion situated in the dominant cerebral hemisphere (the left one in right-handed persons), in those cortical regions vascularized by the superior division of the left middle cerebral artery (Broca's area, the rolandic operculum, the insular cortex, subjacent white matter, centrum semiovale, the caudate nucleus head, the putamen, and the periventricular areas). The role of this chapter is to present the most important acquirements in the field of language and neurologic examination, diagnosis, and therapy of the patient with Broca's aphasia secondary to ischemic stroke.

**Keywords:** language, aphasia, Broca's aphasia, ischemic stroke, vascular aphasia

## 1. Introduction

Aphasia that acquired central disorder of language, which alters the patient's capacity of understanding and/or producing spoken and written language, occurs in about one-third of the patients with acute stroke (ischemic or hemorrhagic). The language disturbances are frequently combined into aphasic syndromes, contained in different vascular syndromes. Still, aphasia subtype is changeable and may undergo variations over time: in the acute stage of the recovery, the most common type of aphasia is the global one; during the first year after stroke, anomia seems to be the most common aphasia subtype. In fact, anomia

denotes the most important aphasia manifestation and long-term vascular aphasia consequence [1].

Broca's aphasia (after Goodglass-Kaplan classification), known also as “motor cortical aphasia” (Lichtheim), “efferent or kinetic motor aphasia” (Luria), “expressive aphasia” (Déjerine, Albert, Pick, Weissenburg, McBride), “phonematic aphasia” (Hécaen), “Broca aphasia—the common form” (Lecours & Lhermitte), “verbal aphasia” (Head), “syntactic aphasia” (Wepman & Jones) is a non-fluent aphasia, comprising the widest range of symptoms: articulatory disturbances, paraphasias, agrammatism, evocation disorders, and discrete comprehension disorders of spoken and written language. It is a type of aphasia whose primary, trademark feature is considered to be the disability of spelling words (word evocation disorder), leading thus to impaired fluency and agrammatism (deficit in formulating and processing syntax) [2, 3]. Several studies concluded that in acute first-ever stroke, the frequency of Broca's aphasia is from 10 to 15%, being the third most frequent type of aphasia after global aphasia (almost 30%) and Wernicke's aphasia (almost 16%) [2, 4–6].

## **2. Clinical aspects**

The different levels of the language (phonetic, phonemic, morphemic, morpho-syntactic, semantic, and pragmatic) can be differentially affected in the various types of language disturbances. For instance, Broca's aphasia is significantly associated with grammatical defects (so-called agrammatism in Broca's aphasia), whereas the semantics of nouns is impaired in posterior fluent aphasias [3].

The different aphasia subtypes are characterized by specific language disturbances. In the evaluation of each patient who presents with aphasic language disorders, the following aspects must be followed: the assessment of oral output/spontaneous speech, the assessment of repetition, the assessment of comprehension, and last but not least, the assessment of reading (lexia) and writing (graphia).

### **2.1 Language assessment**

#### *2.1.1 Assessment of oral production (spontaneous speech)*

##### *2.1.1.1 Fluency*

In the absence of aphasic mutism or when mutism has regressed, the patient presents a non-fluent, unwieldy verbal output, characterized by difficulties to initiate spontaneous speech, effortful, with hesitations and slow output (10–15 words/min), and interrupted by frequent word-finding pauses. Sometimes, he presents dysprosody, remarking a monotonously oral expression, with the absence of melodic modulation [2, 5–11].

##### *2.1.1.2 Presence of deviations at various levels*

a. Sound/arthritis level (incorrect articulation of a sound)—dysarthria.

- Patients with Broca's aphasia are having difficulties in precisely making articulatory movements, resulting in a lot of phonetic abnormalities (incorrect production of phonemes), occasionally ensuing the so-called “foreign accent” or “pseudo accent” [2, 3].

b. Phonemic level (omission, addition, substitution, inversion of a phoneme)—phonemic paraphasias.

- Phonological paraphasias are the result of the apraxia of speech [3];
- even though it could be argued that apraxia of speech is not exactly a language defect [3].

c. Verbal level (naming):

- Semantic (verbal) paraphasias;
- Word-finding difficulty (anomia), especially in spontaneous speech;
- Deficits in action naming being more severe than deficits in object naming.

d. Syntactic level:

- Agrammatism (frequently more obvious afterward the acute phase): oversight of functional/grammatical words (conjunctions, articles, prepositions, auxiliary verbs/e.g., “the,” “an,” and inflections), while conceptual words (verbs, adverbs, and nouns) are used more frequently, resulting in the so-called “telegraphic speech.” From time to time, the oral output can be limited to a few stereotypical terms (e.g., “tan tan”) [2, 8, 11–13].

### *2.1.2 Assessment of repetition*

In patients with Broca's aphasia, the humble repetition is characteristic. The repetition of operational words and flexional endings is difficult, resulting in phonemic and verbal paraphasias (e.g., “My mother reads a book”/“mother-read-book”). Repetition and naming are impaired, although this is less marked than spontaneous speech.

Automatic speech consisting of numbering from 1 to 10, enumerating the days of the week, the months of the year, repeating a poem, can spectacularly ameliorate the verbal fluence [11, 14, 15].

### *2.1.3 Assessment of oral comprehension*

Comprehension is preserved in most Broca aphasic patients. Good oral comprehension (the patient easily manages to perform the examiner's tasks/commands) allows the complete evaluation of language components. In some cases, syntactic comprehension can be more difficult, especially when the examiner requests for understanding more complex sentences or to perform multiple commands [6]:

- a. Distinguishing between different operational words (“in,” “on,” “under,” “over”) is almost impossible.
- b. Comprehension of passive reversible sentences can be affected [12, 16].

Examples:

(Q): “The girl was kissed by the boy. Who kissed whom?”

(A): Girl kiss boy.”

(Q): “The chicken was eaten by the dog. Who ate whom?”

(A): Chicken eat dog.”

#### 2.1.4 Assessment of reading and writing

Reading and writing are furthermore compromised [14]. Receptive lexia is more affected than oral comprehension. Frontal alexia—literal alexia, was first described by Benson [8] and represents the incapacity in recognizing and naming individual letters, though full words are well recognized. In some cases, a deep central alexia is noticed, with incapacity of reading nonexistent words [17]. Lexia of abstract words or operational words is more difficult than that of concrete or conceptual words [17].

Regarding the graphia, it is also impaired in patients with Broca's aphasia. It is not only the result of right hemiplegia, as long as it is also present in patients without motor deficit. Graphia shows changes similar to those of the oral expression, but with different intensity. There are troubles of writing spontaneous or dictated texts, while the copied graphia is relatively well conserved. Agraphia has central (linguistic) and peripheral elements [11]. Discaligraphy, literal and/or grapheme paragraphs are observed; there is a tendency toward agrammatism of variable intensity (thus operational words and inflectional endings are omitted) [18]. After a while, dissociation between a reduced oral language, with agrammatism, and jargon-agraphia phenomena occurs, causing a succession of incomprehensible paragraphs [19].

In conclusion, there are three determinant characteristics representing the essence of Broca's aphasia: preserved comprehension, agrammatism, and dysarthria [2, 5–8].

## 2.2 Associated signs and symptoms

### 2.2.1 Contralateral hemiparesis (*right hemiparesis/hemiplegia*)

Lesions that cause Broca's aphasia also interrupt adjacent cortical motor fibers and deep fiber tracts, this type of aphasia being usually associated with a motor defect in the right hemi body. The hemiparesis [20]:

- affects especially the hand and the face, the leg being less affected;
- moreover, it is more distal than proximal (affecting the hand muscles more than the shoulder ones);
- being caused by a lesion situated at the level of the upper motor neuron, in most cases, the hemiparesis is characterized by an increased muscle tone (spastic hemiparesis);
- its severity is variable, depending on the extension of the cerebral lesion;
- may have impact over the articulatory organs (lips, tongue, cheeks), usually leading to a spastic dysarthria (upper motor neuron injury). This type of dysarthria is characterized by imprecise consonants, monotonous tone, reduced stress, rough voice, mono loudness, and a sluggish speech rate.

### 2.2.2 Apraxia of speech

Apraxia of speech represents a deficiency in planning and programming the sequences of movements necessary in speech production. Along with agrammatism, it is considered as another essential clinical element in the diagnosis of Broca's aphasia.

It is characterized by abnormalities in phoneme production (phonetic deviations), omissions, and substitutions of speech sounds, leading to decreased speech rate (non-fluent speech, evoked with difficulty). Automatic language (counting from 1 to 10, counting the days of the week, the months of the year) is preserved; instead, repetition is clumsy [20]:

It can be associated with bucco-facial apraxia (difficulties in planning and performing facial and mouth movements on request: to open the mouth, to blow air, to move the tongue) and/or dysarthria.

The patient is aware of his problem, unsuccessfully trying to correct his disturbance by effort. Instead, he presents difficulty in initiating statements, awkwardness articulatory movements. The patient is presenting articulatory variation, repeating attempts of the same expression.

### *2.2.3 Frontal acalculia*

Patients with prefrontal injuries frequently develop calculation difficulties that are not easily detected. Patients with damage in the prefrontal areas of the brain may display serious difficulties in mental operations, successive operations (particularly backward operations; e.g., 100–7), and solving multistep numerical problems. Written arithmetic operations are notoriously easier than mental operations. Difficulties in calculation tasks in these patients correspond to different types [20]:

- Attention difficulties
  - i. are reflected in the patient's difficulty in maintaining concentration on the issue;
  - ii. result in defects in maintaining the conditions of the tasks and impulsiveness in answers;
- Perseveration
  - i. is observed in the tendency to continue presenting the very same response to different conditions;
  - ii. can be found in extrasylvian (transcortical) motor (dysexecutive) aphasia;
- Deficiency of complex mathematical concepts.

### *2.2.4 Depression*

The patient with Broca's aphasia is aware of his oral expression disorder, developing feelings of helplessness and frustration, with a slightly irascible frame of mind, eventually leading to anxiety and depression [5–7], adding much more struggle in the recovery process of language.

## **3. Anatomico-clinical correlations**

Broca's aphasias are generally the consequence of infarcts (usually embolic) in the anterior superficial sylvian territory of the dominant hemisphere for language. Other causes are cranio-cerebral trauma, cerebral hemorrhage, and less frequently, multiple brain metastases or infiltrative multiform glioblastomas. In the last two conditions, the spontaneous evolution is toward global aphasia.

Lesions or dysfunctions usually involve the left side of the brain in right-handed individuals [21], precisely the following structures:

a. Broca's area:

- the posterior part of the third frontal gyrus (F3)—Brodmann areas 44 and 45.
- lesions in this area determine transitory apraxia of speech.
- larger lesions, involving besides Broca's area the subjacent white matter, produce transient mutism, quickly followed by an improving syndrome with noticeable arthric distortions and difficulties in action naming rather than in object naming.

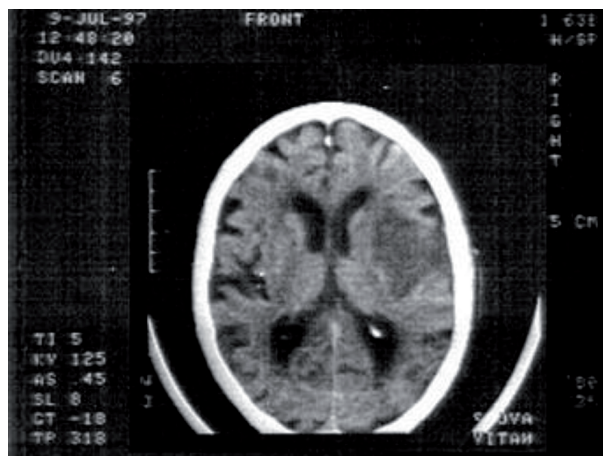
b. Rolandic operculum:

- inferior part of the motor area: Fa.

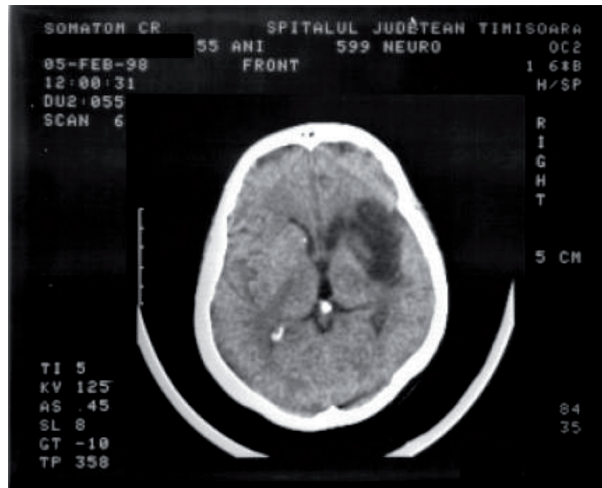c. Lesions can extend or individually affect:

- the insular cortex and subjacent white matter;
- centrum semiovale;
- capsulostriatum (head of caudate nucleus and putamen);
- periventricular areas.

Ischemic lesions comprising together these structures and Broca's area can produce the complete syndrome of Broca's aphasia. Broca's aphasia is produced by infarcts/severe hypoperfusion of the superior division of the left middle cerebral artery (MCA) (**Figures 1 and 2**) [2, 5, 6, 22–24].



**Figure 1.** Example of native brain CT scan of a Broca aphasic patient, showing a hypodense area of 3.5/3 cm arranged in the left frontal region, affecting the frontal operculum (*operculum frontale*), the frontoparietal one (*operculum fronto-parietale*), the island, a portion of the underlying white matter and the putamen [2].



**Figure 2.**  
*Example of native brain CT scan of a Broca's aphasic patient, revealing a hypodense area of 5/4 cm with left frontal location [2].*

During the last two decades, there were conducted different studies that were meant to study the hypothesis that during the acute period of the stroke, the lesion's location is the main conclusive factor in establishing the type of aphasia. Kreisler et al. pointed out in their study that imaging supported the classical anatomic localization (for example: lesions situated in the left inferior frontal gyrus might lead to Broca's aphasia and lesion situated in the left superior temporal gyrus might lead to Wernicke's aphasia). Furthermore, their study concluded that non-fluent aphasia was correlated with lesions of postero-inferior frontal gyrus, the putamen, centrum semiovale, and the inferior parietal lobule; repetition disorders were associated with injuries of external capsule and posterior internal capsule, and difficulty in finding words was related with injuries of anterior and posterior language areas or with the subcortical structures [25]. There are other studies conducted by Godefroy et al. and Z.-H. Yang et al., which also pointed out that the most significant factor in establishing the aphasia type was the lesion's site [26, 27].

On the other hand, there are some studies that found out that a great number of aphasia types were not concordant with the classical neuroanatomical site of expression and comprehension [28, 29].

Concluding, there are two hypotheses [30]:

- One that sustains that the language center is the liable core for language (though, the brain mechanism of language functions is not restricted to that limited area of the cerebral cortex);
- Another one that sustains that wide-ranging areas related to language are the connection of the language functions and that coordination and close interconnection between these two components have made it possible for people to carry out complex and various language activities, so necessary for human communication.

Language system of the brain is a wide, complex network, and this topic requires further investigation.

Different imaging techniques have been used to precisely specify the site of the brain lesion responsible for aphasic syndromes: diffusion MRI (diffusion

tensorimaging—DTI: tractography—used in detecting the course of a specific nerve fiber bundles), MRI diffusion-weighted imaging (especially helpful in detecting the areas of acute infarction, soon after the clinical stroke onset—within 15–20 min), functional MRI (fMRI—quantifies hemodynamic changes associated with active metabolism during ongoing neuronal activity; as the linguistic areas are activated, more oxygen is consumed in those areas, resulting in release of greater amounts of deoxyhemoglobin), positron emission CT (PET—detects radioisotopes injected into the bloodstream and reaching to specific areas of the brain). However, there are still needed complex studies to establish this multifaceted language process [31].

#### **4. Evolution of Broca's aphasia**

Primarily, the patient is unable to release any sound (mutism), with a tremendously impaired comprehension (global aphasia) or, in opposition, almost normal. In evolution, stereotypes can sometimes be installed, which consist of the involuntary repetition of a syllable, a word, or even a phrase, in the absence of any other expression [6, 8, 18, 19, 32–34].

In rare situations, the regression of language disturbances stops at the level of monotonous permanent stereotypes (without prosody) and without semantic significance. In some old Broca aphasias, stereotypes with semantic significance, with hyperprosody and, possibly, with rich gestures can be observed. In most cases, however, the evolution is favorable, the patient developing the typical clinical picture of Broca aphasia [18, 32]. Subsequently, there is a partial restoration of verbal fluency (hereinafter, slow fluency), with decreased articulation disorders and those of evocation of conceptual words (lexical enrichment) [2]. Voluntary-automatic dissociation occurs and the language begins to convert into propositional [2]. Sometimes, the evolution is toward agrammatism, other times toward motor transcortical aphasia or motor amnesic aphasia [19].

Studies have reported better recovery in Broca's and conduction aphasia, lower rates of recovery in global and anomic aphasia [4, 35, 36]. A study completed by Mazzoni et al. supported the idea that comprehension has a better recovery than expression [37], whereas Basso et al. reported that transcortical sensory aphasia had a worse prognosis than Broca's or transcortical motor aphasia [38]. El Hachioui et al. related that different levels of the language improve at different times, as phonology recovers earlier than semantic or syntactic language, and comprehensive language recovers earlier than expressive language [39].

#### **5. Therapeutical approach in Broca's aphasia**

##### **5.1 Pharmacological therapy**

At the moment, in acute ischemic stroke, the rapid reestablishment of cortical perfusion (i.v. thrombolysis/endovascular therapy—thrombectomy) during the first 4.5 h (thrombolysis), and 6–12 h (thrombectomy) from the clinical onset, represents the most efficient acute treatment approach. Several large randomized clinical trials have shown significant value in outcome with intravenous thrombolysis [40] or endovascular therapy [41]. Although all these studies were not designed to specifically assess the language's evolution, a secondary investigation of a large randomized clinical trial of endovascular therapy (Multicenter Randomized Clinical Trial of Endovascular Treatment for Acute Ischemic Stroke in the Netherlands; MR CLEAN) [42] has proven that the language score on NIHSS



Scale gained points (0–2 points) in the intervention group, compared with the control group. Hillis et al. conducted a small randomized clinical trial, which demonstrated that temporary rise of blood flow early after left hemisphere stroke due to large vessel occlusion or severe stenosis was related to language improvement [43].

In chronic post-stroke Broca's aphasia, no other pharmaceutical intervention has proven its efficacy, since no randomized study has been able to demonstrate their efficiency [44]. Nevertheless, there are some trials that showed that there are some medications that have improved the results of speech therapy. The main idea of these studies is that recovery of language depends on neuroplasticity, which might be stimulated by administering medications that modulate neurotransmitters [45]. Studies have proven that behavioral interventions can lead to neural reorganization. Even more, this process is facilitated by some neurotransmitters such as: acetylcholine, dopamine, norepinephrine, and serotonin [46, 47]. In conclusion, medications that increase the availability of these neurotransmitters may strengthen the process of neuroplasticity. The main studied medications are donepezil (cholinesterase inhibitors), memantine (noncompetitive antagonist of the Nmethyl-D-aspartate receptor), and piracetam. Preliminary positive results were found using piracetam in nonfluent aphasia (Broca's aphasia), but it has not been proven to be effective in long-term use [48].

Consequently, a series of drugs targeting improving language deficits have been studied during the last years. Until now, the conclusion is that some agents may be mainly suitable for treating speech output deficits and picture naming with poor influence over comprehension, particularly in severe cases [49]. There are some theories that support the idea that selective serotonin reuptake inhibitors (SSRIs) might be useful for persons with non-fluent aphasia (e.g., Broca's aphasia), which are also associating depression and frustration, but probably they are less suitable for persons with fluent aphasia (coursing with excitement and reduced awareness) [44].

Another promising therapeutic strategy is represented by using biotechnologically prepared peptides that stimulate neurotrophic regulation in the central nervous system (with neurotrophic and neuroprotective activities). Between 2005 and 2009, a large Romanian study has been conducted in four departments of neurology, analyzing 2212 consecutive Broca's aphasics following a first acute ischemic stroke. The purpose of this study was to evaluate the efficacy of Cerebrolysin administration (30 ml Cerebrolysin mixed with 70 ml of normal saline/day/iv infusion, for 21 days) in Broca's aphasics with acute ischemic stroke (n = 156: 52 in cerebrolysin and 104 in placebo) [50]. The conclusion of this study was that spontaneous (voluntary and automatically) speech, repetition, and naming in acute Broca's aphasia have been positive influenced [44, 50]. Our study clearly demonstrated that intravenous adjuvant treatment with cerebrolysin results in statistically significant and clinically important improvements of language function in patients with Broca's aphasia with a first acute ischemic stroke [50]. Further larger studies are crucial for sustaining this pertinent hypothesis.

## **5.2 Speech therapy**

While pharmacological approach produces unreliable results, with small/moderate language improvements, speech therapy is nowadays considered the gold standard in recovery of aphasias. Brady et al. analyzed 57 randomized controlled trials, comparing patient group with speech therapy and other without it and demonstrated that speech therapy led to clinically significance improvements in patients' ability of communicating. The intensity and duration of speech therapy are very important, the longer the duration of therapy, the more effective the recovery [51]. In patients with chronic aphasia secondary to stroke, intensive speech and language

therapy has proven superiority over delayed or even the absence of treatment [52]. Breitenstein et al. concluded that 3 weeks of intensive speech and language therapy of 10 or more hours per week can be considered an evidence-based intervention for patients with chronic aphasia after stroke (aged 70 years or younger) [52].

### **5.3 Transcranial magnetic stimulation (TMS)**

Transcranial magnetic stimulation (TMS) is a noninvasive method of brain stimulation that relies on electromagnetic induction using an insulated coil placed over the scalp, focused on the specific, desired area of the cortex, which offers a promising alternative approach in amplifying neuroplasticity processes involved in language recovery after stroke. Repetitive transcranial magnetic stimulation (rTMS) modulates neural activity using two mechanisms: by decreasing the cortical excitability with low-frequency rTMS ( $\leq 1$  Hz) applied on nondominant hemisphere or by releasing the inhibition of the dominant hemisphere with high-frequency rTMS ( $\geq 5$  Hz).

Most trials of low-frequency or high-frequency rTMS in subacute stroke have reported significantly greater language improvement in the rTMS than in the sham group or condition [53].

Regarding rTMS in rehabilitation of Broca's aphasic patients, few studies have been conducted targeted on recovering one single type of aphasia. The meta-analysis conducted by J. Zhang and his collaborators indicated that rTMS groups had a superior language recovery than sham rTMS groups and conventional rehabilitation groups. Low-frequency rTMS brought greater improvement in language recovery (excepting comprehension) than the sham rTMS. Conversely, high-frequency rTMS did not improve the evolution of rTMS groups compared with sham rTMS and conventional rehabilitation groups (speech therapy) [54].

The entire neuroscience community is still studying different methods of stimulating the reestablishment of network connections that could finally improve language disturbances, using transcranial magnetic stimulation.

## **6. Conclusions**

Broca's aphasia is the third most common form of aphasia due to acute stroke. Given the severe disability suffered by aphasic patients and the complexity of language recovery (taking into consideration all forms of aphasia), studies are still insufficient to elucidate clear treatment strategies for aphasias at this time. Regarding the current clinical and imaging diagnosis, the anatomical correlations with different forms of aphasia still remain poorly understood. Several studies have demonstrated that it is possible to draw a neuroanatomical map of aphasic syndromes, which are superimposable on a significant percentage of cases reported in the literature. This concludes to the idea that the main determining factor of aphasic disorders is the neuroanatomical location of the lesion. This does not mean that the injury of one restricted area with certain language or speech functions is going to determine the same aphasic syndrome in different individuals. Examining language disturbances should focus more on aphasic symptoms rather than on aphasic syndromes.

## Author details

Dragoş Cătălin Jianu<sup>1,2,3\*</sup>, Tihomir V. Ilic<sup>4</sup>, Silviana Nina Jianu<sup>5</sup>,  
Any Docu Axelerad<sup>6</sup>, Claudiu Dumitru Bîrdac<sup>2,3</sup>, Traian Flavius Dan<sup>1,2,3</sup>,  
Anca Elena Gogu<sup>1,2,3</sup> and Georgiana Munteanu<sup>1,2,3</sup>

1 Department of Neurosciences-Division of Neurology, Victor Babeş,  
University of Medicine and Pharmacy, Timisoara, Romania

2 Centre for Cognitive Research in Neuropsychiatric Pathology (NeuroPsy-Cog),  
Department of Neurosciences, Victor Babeş, University of Medicine and Pharmacy,  
Timisoara, Romania

3 First Department of Neurology, Pius Brânzeu Emergency County Hospital,  
Timisoara, Romania

4 Department of Neurology, Medical Faculty of Military Medical Academy,  
University of Defence, Belgrade, Serbia


5 Department of Ophthalmology, “Dr. Victor Popescu” Military Emergency  
Hospital, Timisoara, Romania

6 Department of Neurology, General Medicine Faculty, “Ovidius” University,  
Constanta, Romania

\*Address all correspondence to: [dcjianu@yahoo.com](mailto:dcjianu@yahoo.com)

## IntechOpen

---

© 2021 The Author(s). Licensee IntechOpen. This chapter is distributed under the terms of the Creative Commons Attribution License (<http://creativecommons.org/licenses/by/3.0>), which permits unrestricted use, distribution, and reproduction in any medium, provided the original work is properly cited. 

## References

- [1] Ardila A. Chapter 2. Aphasia etiologies. In: *Aphasia Handbook 2*. Miami, Florida, USA: Florida International University; 2014. pp. 29-45
- [2] Jianu DC. *Elemente de afaziologie (Romanian)*. Mirton: Timisoara, Romania; 2001
- [3] Ardila A. Chapter 4. Major aphasic syndromes: Wernicke's aphasia and Broca's aphasia. In: *Aphasia Handbook 2*. Miami, Florida, USA: Florida International University; 2014. pp. 60-75
- [4] Pedersen PM, Vinter K, Olsen TS. Aphasia after stroke: Type, severity and prognosis. The Copenhagen aphasia study. *Cerebrovascular Diseases*. 2004;**17**(1):35-43. Epub 2003 Oct 3. DOI: 10.1159/000073896
- [5] Abou Zeki D, Hillis A. Chapter 12. Acquired disorders of language and speech. In: Masud H, Schott JM, editors. *Oxford Textbook of Cognitive Neurology and Dementia*. UK: Oxford University Press; 2016. pp. 123-133
- [6] Croquelois A, Godefroy O. Chapter 7. Vascular aphasias. In: Godefroy O, editor. *The Behavioral and Cognitive Neurology of Stroke*. 2nd ed. UK: Cambridge University Press; 2013. pp. 65-75
- [7] Alajouanine T. *L'aphasie et le langage pathologique*. Paris: J.B. Baillière et fils éditeurs; 1968. p. 19
- [8] Benson FD, Geschwind N. Aphasia and related cortical disturbances. In: Baker AB, Baker LH, editor. *Clinical Neurology*. Philadelphia: Harper and Row; 1971
- [9] Kearns KP. Chapter 8. Broca's aphasia. In: La Pointe LL, editor. *Aphasia and Related Neurogenic Language Disorders*. 3rd ed. New York, Stuttgart: Thieme; 2005. pp. 117-141.
- [10] Alexander MP, Naeser MA. Broca's area aphasics. *Brain and Language*. 1992;**43**(3):215-227
- [11] Haartmann HJ, Kolk HHJ. The production of grammatical morphology in Broca's and Wernicke's aphasics. *Cortex*. 1992;**28**:97-112
- [12] Jianu DC, Bednar M, Zolog A. Diagnosticul diferențial între tulburările fonetice și fonologice la afazici (Romanian). *Revista Societății de Neurologie și Psihiatrie pentru Copii și adolescenți din România*. 1999;**2**:55-58
- [13] Jianu DC. Managementul afazicilor romani consecutiv infarctelor cerebrale (Romanian). Mirton: Timisoara, Romania; 2011
- [14] Damasio AR. Aphasia. *New England Journal of Medicine*. 1992;**326**:531-539
- [15] Kertesz A. Clinical forms of aphasia. *Acta Neurochirurgica. Supplementum (Wien)*. 1993;**56**:52-58
- [16] Kory Calomfirescu S, Kory MM. Afazia în accidentele vasculare cerebrale (Romanian). Casa Cărții de Știință: Cluj-Napoca, Romania; 1996
- [17] Rapp B, Goldrick M. Interactivity? The relationship between semantics and phonology in speech production. *Brain and Language*. 1997;**50**:1-194; 50-53
- [18] Verstichel P, Cambier J. Capitolul XXVI—Afaziile. In: Botez MI, editor. *Neuropsihologie clinică și Neurologia comportamentului*. Ediția a II-a ed. Masson, Editura Medicală, București: Les Presses de L'Université de Montréal; 1996. pp. 457-491
- [19] Zolog A. Afaziile, semiologie, neurolingvistică, sindromologie. Timișoara: Editura Eurobit; 1997

- [20] Ardila A. Chapter 8. Associated disorders. In: *Aphasia Handbook 2*. Miami, Florida, USA: Florida International University; 2014. pp. 140-154
- [21] Jianu DC, Jianu SN, Petrica L, Dan TF, Munteanu G. Chapter 3: Vascular aphasia. In: *Ischemic Stroke*. London, United Kingdom: IntechOpen; 2020. pp. 37-60. DOI: 10.5772/intechopen.92691
- [22] Thompson CK. Chapter 2. Functional neuroimaging. In: La Pointe LL, editor. *Aphasia and Related Neurogenic Language Disorders*. 3rd ed. New York-Stuttgart: Thieme; 2005. pp. 19-38.
- [23] Hanna D. Chapter I. Neuroimaging contributions to the understanding of aphasia. In: Boller F, editor. *Handbook of Neuropsychology*. Vol. 2. Amsterdam, Netherlands: Elsevier Science Publishers, B.V; 1989
- [24] Poeck K, de Bleser R, von Keyserlink DG. Computed tomography localization of standard aphasic syndromes. In: Rose FC, editor. *Advances in Neurology*. Vol. 42. Progress in Aphasiology. New York: Raven Press; 1984. pp. 71-89
- [25] Kreisler A, Goderfroy O, Delmaire C. The anatomy of aphasia revisited. *Neurology*. 2000;**54**:1117-1123
- [26] Godefroy O, Dubois C, Debachy B, et al. Vascular aphasia main characteristics of patients hospitalized in acute stroke units. *Stroke*. 2002;**33**: 702-706
- [27] Yang Z-H, Zhao X-Q, Wang C-X, Chenand H-Y, Zhang Y-M. Neuroanatomic correlation of the post-stroke aphasia studied with imaging. *Neurological Research*. 2008;**30**:356-360. DOI: 10.1179/174313208X300332
- [28] Basso A, Lecours AR, Moraschini S, et al. Anatomoclinical correlations of the aphasias as defined through computerized tomography: Exceptions. *Brain and Language*. 1985;**26**:201-229
- [29] Willmes K, Poeck K. To what extent can aphasic syndromes be localized? *Brain*. 1993;**116**:1527-1540
- [30] Nina F, Dronkers A. The pursuit of brain–language relationships. *Brain and Language*. 2000;**71**:59-61
- [31] Hallowell B. *Aphasia and Other Acquired Neurogenic Language Disorders: A Guide Forclinical Excellence*. San Diego, CA: Plural Publishing; 2017. Chapter 8. pp. 122-124. ISBN 9781597564779
- [32] Ropper AH, Brown RH. Chapter 23: Disorders of speech and language. In: Adams and Victor's *Principles of Neurology*. 8th edition. New York: Mc Graw-Hill; 2005. pp. 413-430
- [33] Damasio AR. The neural basis of language. *Annual Review of Neuroscience* (Palo Alto, CA). 1984;**7**:127-147
- [34] Caplan LR et al. Caudate infarcts. *Archives of Neurology*. 1990;**47**:133-143
- [35] Demeurisse G, Demol O, Beuckelaer RDE. Quantitative study of the rate of recovery from aphasia due to ischemic stroke. *Stroke*. 1979;**11**(5): 455-458
- [36] Kertesz A, McCabe P. Recovery patterns and prognosis in aphasia. *Brain*. 1977;**100**:1-18
- [37] Mazzoni M, Vista M, Pardossi L, Avila L, et al. Spontaneous evolution of aphasia after ischaemic stroke. *Aphasiology*. 1992;**6**(4):37-41
- [38] Basso A, Capitani E, Vignolo LA. Influence of rehabilitation on language skills in aphasic patients. A controlled study. *Archives of Neurology*. 1979; **36**(4):190-196

- [39] El Hachoui H, Lingsma HF, van de Sandt-Koenderman ME, Dippel DWJ, Koudstaal PJ, Visch-Brink EG. Recovery of aphasia after stroke: A 1-year follow-up study. *Journal of Neurology*. 2013;**260**(1):166-171
- [40] NINDS TPA (The National Institute of Neurological Disorders and Stroke RT-PA Stroke Study Group). Tissue plasminogen activator for acute ischemic stroke. *The New England Journal of Medicine*. 1995;**333**:1581-1587
- [41] Campbell BCV, Mitchell PJ, Kleinig TJ, et al. Endovascular therapy for ischemic stroke with perfusion-imaging selection. *The New England Journal of Medicine*. 2015;**372**:1009-1018
- [42] Crijnen YS, Nouwens F, de Lau LML, et al. Early effect of intra-arterial treatment in ischemic stroke on aphasia recovery in MR CLEAN. *Neurology*. 2016;**86**:2049-2055
- [43] Hillis AE, Ulatowski JA, Barker PB, et al. A pilot randomized trial of induced blood pressure elevation: Effects on function and focal perfusion in acute and subacute stroke. *Cerebrovascular Diseases*. 2003;**16**:236-246
- [44] Berthier ML. Ten key reasons for continuing research on pharmacotherapy for post-stroke aphasia. *Aphasiology*. 2021;**35**(6):824-858
- [45] Crosson B, Rodriguez AD, Copland D, et al. Neuroplasticity and aphasia treatments: New approaches for an old problem. *Journal of Neurology, Neurosurgery, and Psychiatry*. 2019;**90**:1147-1155
- [46] Brzosko Z, Mierau SB, Paulsen O. Neuromodulation of spike-timing-dependent plasticity: Past, present, and future. *Neuron*. 2019;**103**:563-581
- [47] Llano DA, Small SL. Pharmacotherapy for Aphasia. In: Small S, Hickok G, editors. *Neurobiology of Language*. Amsterdam: Elsevier; 2015. pp. 1067-1083
- [48] Güngör L, Terzi M, Onar MK. Does long term use of piracetam improve speech disturbances due to ischemic cerebrovascular diseases? *Brain and Language*. 2011;**117**:23-27
- [49] Woodhead ZV, Crinion J, Teki S, Penny W, Price CJ, Leff AP. Auditory training changes temporal lobe connectivity in 'Wernicke's aphasia': A randomised trial. *Journal of Neurology, Neurosurgery, and Psychiatry*. 2017;**88**(7):586-594. DOI: 10.1136/jnnp-2016-314621
- [50] Jianu DC, Muresanu DF, Bajenaru O, Popescu BO, Deme SM, Moessler H, et al. Cerebrolysin adjuvant treatment in Broca's aphasics following first acute ischemic stroke of the left middle cerebral artery. *Journal of Medicine and Life*. 2010;**3**(3):297-307
- [51] Brady MC, Kelly H, Godwin J, Enderby P, Campbell P. Speech and language therapy for aphasia following stroke. *Cochrane Database of Systematic Reviews*. 2016;**6**:CD000425
- [52] Breitenstein C, Grewe T, Flöel A, Ziegler W, Springer L, Martus P, et al. Intensive speech and language therapy in patients with chronic aphasia after stroke: A randomised, open-label, blinded-endpoint, controlled trial in a health-care setting. *Lancet*. 2017;**389**(10078):1528-1538. Epub 2017 Mar 1. Erratum in: *Lancet*. 2017;**389**(10078):1518
- [53] Tsai P-Y, Wang C-P, Ko JS, Chung Y-M, Chang Y-W, Wang J-X. The persistent and broadly modulating effect of inhibitory rTMS in nonfluent aphasic patients: A sham-controlled, double-blind study. *Neurorehabilitation and Neural Repair*. 2014;**28**:779-787

[54] Zhang J, Zhong D, Xiao X, Yuan L, Li Y, Zheng Y, et al. Effects of repetitive transcranial magnetic stimulation (rTMS) on aphasia in stroke patients: A systematic review and meta-analysis. *Clinical Rehabilitation*. 2021;**35**(8):1103-11116. DOI: 10.1177/0269215521999554