

Fatal Sporotrichosis

Christopher B. Yelverton, MD, MBA; Cloyce L. Stetson, MD; Ran H. Bang, MD; Justin W. Clark, MD; David F. Butler, MD

Disseminated sporotrichosis is a serious fungal infection caused by the soil inhabitant Sporothrix schenckii. It is seen in immunocompromised patients, with a substantial number of recent cases involving patients with acquired immunodeficiency syndrome (AIDS). However, individuals with other conditions that affect the immune system also are at increased risk. We report a case of fatal disseminated sporotrichosis in a patient with liver disease and a diagnosis of a granulomatous condition presumed to be sarcoidosis; the patient was receiving systemic corticosteroid therapy. The various presentations of S schenckii infection, the risk of disseminated disease in immunocompromised hosts, and the importance of making accurate histologic diagnoses are reviewed.

Cutis. 2006;78:253-256.

Case Report

A 55-year-old man with a 9-month history of "sarcoidosis" treated with systemic corticosteroids presented with a 2-week history of tender cutaneous lesions on all 4 extremities. His past medical history was significant for hepatitis C with cirrhosis and rheumatoid arthritis. The cutaneous lesions had been unresponsive to systemic steroid therapy, oral erythromycin, and intravenous ceftriaxone.

Results of a physical examination showed an ill-appearing, afebrile, white man with multiple large, tender, ulcerated, necrotic plaques on his arms and legs. The lesions had indurated, erythematous borders, adherent eschars, and surrounding ecchymoses (Figures 1 and 2). Results of an examination of his joints were unremarkable.

Results of laboratory investigations revealed a complete blood count within reference range,

with a white blood cell count of 6400/ μ L (reference range, 4500–11,000/ μ L), an elevated creatinine phosphokinase level of 784 U/L (reference range, 25–200 U/L), and an elevated γ -glutamyltransferase level of 238 U/L (reference range, 8–78 U/L). Test results for human immunodeficiency virus (HIV) were negative. Results of cultures of cerebrospinal fluid and blood were negative for bacteria, acid-fast bacilli, and fungi. Results of chest x-rays revealed linear streaking consistent with atelectasis.

Results from a punch biopsy specimen showed numerous organisms in macrophages on hematoxylin and eosin staining (Figure 3). Periodic acid-Schiff stain revealed hundreds of yeast forms and cigar-shaped bodies (Figure 4). The tissue fungal culture grew *Sporothrix schenckii*. The patient was treated with intravenous amphotericin B. He developed renal failure and died 3 days later.

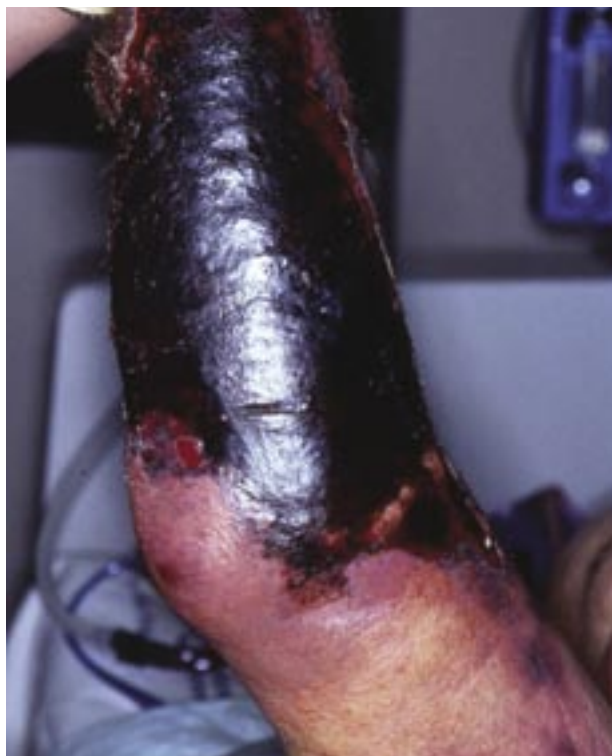

Figure 1. Necrotic plaque on the patient's arm.

Accepted for publication September 9, 2005.

Dr. Yelverton is from Wake Forest University, Winston-Salem, North Carolina. Drs. Stetson and Clark are from Texas Tech University Health Sciences Center, Lubbock. Dr. Bang is from the University of New Mexico, Albuquerque. Dr. Butler is from the Division of Dermatology, Scott and White Clinic, Temple, Texas.

The authors report no conflict of interest.

Reprints not available from the authors.

Comment

Sporotrichosis is caused by the saprophytic fungus *S schenckii*, a common inhabitant of plant matter worldwide. Sporotrichosis is endemic in Mexico, Central and South America, and South Africa. In more temperate climates, such as North America, sporotrichosis most often is seen in gardeners. *S schenckii* is a dimorphic fungus that exists as mold in soil and as yeast in tissue. Human infection typically occurs via inoculation of the skin from a puncture wound involving plant material. Individuals most commonly affected include gardeners, agricultural workers, and miners. Rose thorns, sphagnum moss, hay, and conifer needles commonly are associated with sporotrichosis infections. Less commonly, sporotrichosis may be acquired from animal bites or scratches, or from medical instrumentation.^{1,2}

Sporotrichosis may manifest cutaneously or extracutaneously. In immunocompetent hosts, the most common form of infection is lymphocutaneous sporotrichosis, which begins with the development of an ulcerated nodule at the site of inoculation that occurs within the first few weeks after the initial trauma.

Following this lesion, similar nodules appear proximally along the ascending lymphatic chain. A fixed cutaneous form also has been described where the initial lesion develops at the site of inoculation, but the lymphatics are not involved. This manifestation appears to be more prominent among children.³

Extracutaneous (systemic) forms of *S schenckii* are rare and may be asymptomatic, unifocal, or multifocal. Virtually any organ system can be affected. Unifocal extracutaneous sporotrichosis most often affects the skeletal, pulmonary, or genitourinary systems. Joint involvement is the most frequent extracutaneous finding.⁴ Multifocal disease may occur via direct spread from a cutaneous source or hematogenous seeding, or from a primary pulmonary source. Interestingly, pulmonary involvement in multifocal disease appears as linear and nodular infiltrates on chest film, while cavitary nodules more commonly are found in primary pulmonary sporotrichosis. Most

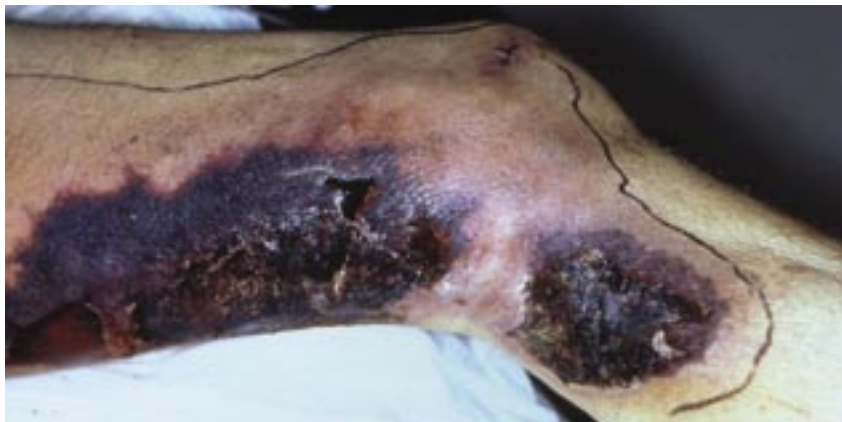

Figure 2. Necrotic plaque with surrounding erythema on the patient's leg.

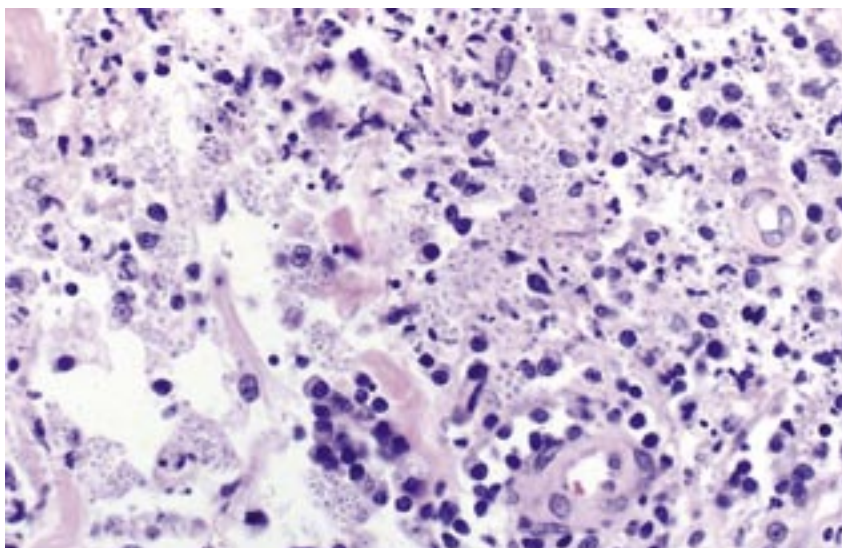


Figure 3. Suppurative granulomas with organisms (H&E, original magnification $\times 200$).

patients with multifocal disease have significant generalized cutaneous involvement.⁵

The primary risk factor for the development of disseminated sporotrichosis appears to be a state of immune compromise.⁴ Most cases since 1989 have involved patients with acquired immunodeficiency syndrome (AIDS)/HIV.⁶⁻⁹ Disseminated sporotrichosis even may be a presenting infection in patients with AIDS.¹⁰ However, other immunocompromised states, such as alcoholism, diabetes mellitus, organ transplantation, and systemic corticosteroid therapy, also place individuals at increased risk for infection.^{11,12} Our patient was immunocompromised by his preexisting hepatitis C infection with cirrhosis as well as his rheumatoid arthritis. In addition, his therapy with systemic corticosteroids likely contributed to the development of disseminated disease.

The differential diagnosis of disseminated *S schenckii* infection is broad and includes other

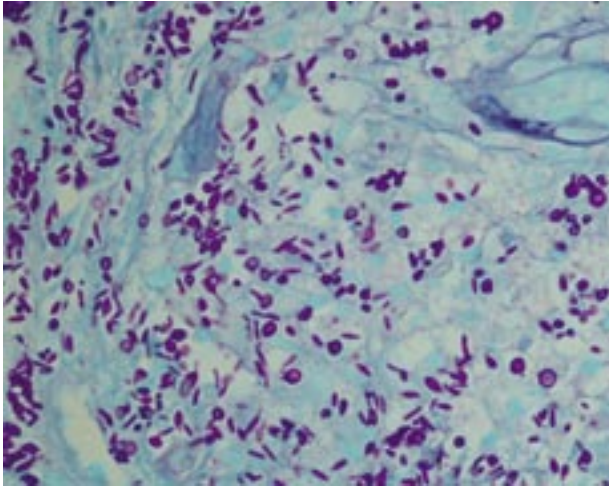


Figure 4. Numerous cigar-shaped yeast forms and budding yeasts (periodic acid-Schiff, original magnification $\times 200$).

infections such as disseminated aspergillosis, disseminated mucormycosis, and *Neisseria meningitidis* septicemia. Additionally, conditions such as collagen vascular disease, large vessel vasculitis, warfarin necrosis, protein C/protein S deficiency, and pyoderma gangrenosum clinically may resemble disseminated sporotrichosis.

Accurate diagnosis of sporotrichosis depends on biopsy and fungal culture results. Histologically, sporotrichosis may appear as necrotic granulomas with sparse organisms and occasional asteroid bodies. There may be pseudoepitheliomatous hyperplasia with intraepidermal microabscess formation. The absence of organisms on special stains does not exclude the possibility of sporotrichosis. *S schenckii* is described as a cigar-shaped budding yeast and is sometimes seen on periodic acid-Schiff stain specimens from immunocompromised hosts. Results of the biopsy performed on our patient showed an unusually large number of organisms. Typically, results of fungal cultures taken from affected skin, or synovial fluid in patients with articular involvement, are required for diagnosis. Results of blood and cerebrospinal fluid cultures rarely are positive. Fungal cultures may take up to a month for definitive diagnosis. Therefore, awaiting culture results in cases of suspected disseminated disease might unnecessarily delay treatment.

Treatment of sporotrichosis depends on the extent of spread. A supersaturated solution of potassium iodide has been used in cutaneous disease, with favorable results.¹³ Itraconazole has been used for cutaneous forms of sporotrichosis because of the agent's high concentration in the skin. Itraconazole also has been successfully used in many cases of disseminated disease.

Additionally, itraconazole can be used for long-term suppressive therapy in chronically immunocompromised patients.¹⁰ Severe disseminated disease requires amphotericin B.⁴ Intravenous amphotericin B is used most commonly, though this agent is limited because of renal toxicity. Lipid complex formulations of amphotericin B may permit higher dosing with fewer side effects.⁷ However, 30% to 40% of cases with joint involvement do not respond to intravenous amphotericin B. In such cases, intra-articular amphotericin B may be beneficial.^{4,5} Surgical debridement of articular sporotrichosis also may be attempted in conjunction with antifungal treatment.

With prompt treatment, death from disseminated sporotrichosis is relatively uncommon. Our literature review found only 26 cases published in the past century in which active disseminated sporotrichosis likely contributed to the patient's death.^{4-6,9,10,14-22} Several cases involve patients who presented with sporotrichosis during the early part of the 20th century and were primarily treated with a supersaturated solution of potassium iodide.⁵ Many of the cases reported in the 1980s and 1990s involved patients with AIDS, many with multiple opportunistic infection at the time of death.^{6,10,20,22}

Several unresolved issues exist with our case. One issue is the diagnosis of sarcoidosis in our patient. There have been case reports of patients who were initially thought to have sarcoidosis on the basis of pulmonary findings and histologic granulomas but developed disseminated sporotrichosis following initiation of corticosteroid therapy.^{21,23} The fact that our patient did not receive an autopsy prevented us from knowing the full extent of his disease. Another issue is that disseminated sporotrichosis was not suspected in our patient until biopsy results were available, at which point the patient was already obtunded.

Conclusion

Disseminated sporotrichosis is a rare yet important fungal disease that primarily affects immunocompromised individuals. A high index of suspicion and accurate histologic diagnosis are critical to timely initiation of appropriate therapy in this potentially fatal condition. Systemic amphotericin B is the mainstay of treatment for disseminated disease.

REFERENCES

1. Dunstan RW, Langham RF, Reimann KA, et al. Feline sporotrichosis: a report of five cases with transmission to humans. *J Am Acad Dermatol.* 1986;15:37-45.
2. Kim S, Rusk MH, James WD. Erysipeloid sporotrichosis in a woman with Cushing's disease. *J Am Acad Dermatol.* 1999;40:272-274.

- Burch JM, Morelli JG, Weston WL. Unsuspected sporotrichosis in childhood. *Pediatr Infect Dis J*. 2001;20:442-445.
- Lynch PJ, Voorhees JJ, Harrell ER. Systemic sporotrichosis. *Ann Intern Med*. 1970;73:23-30.
- Wilson DE, Mann JJ, Bennett JE, et al. Clinical features of extracutaneous sporotrichosis. *Medicine (Baltimore)*. 1967;46:265-279.
- Shaw JC, Levinson W, Montanaro A. Sporotrichosis in the acquired immunodeficiency syndrome. *J Am Acad Dermatol*. 1989;21:1145-1147.
- Ware AJ, Cockerell CJ, Skiest DJ, et al. Disseminated sporotrichosis with extensive cutaneous involvement in a patient with AIDS. *J Am Acad Dermatol*. 1999;40:350-355.
- Ticoras CJ, Schroeter AL, Hornbeck KL. Disseminated ulcerated papules and nodules. *Arch Dermatol*. 1996;132:963-964, 966-967.
- Dong JA, Chren MM, Elewski BE. Bonsai tree: risk factor for disseminated sporotrichosis. *J Am Acad Dermatol*. 1995;33:839-840.
- Al-Tawfiq JA, Wools KK. Disseminated sporotrichosis and *Sporothrix schenckii* fungemia as the initial presentation of human immunodeficiency virus infection. *Clin Infect Dis*. 1998;26:1403-1406.
- Gullberg RM, Quintanilla A, Levin ML, et al. Sporotrichosis: recurrent cutaneous, articular, and central nervous system infection in a renal transplant recipient. *Rev Infect Dis*. 1987;9:369-375.
- Manhart JW, Wilson JA, Korbitz BC. Articular and cutaneous sporotrichosis. *J Am Med Assoc*. 1970;214:365-367.
- Sterling JB, Heymann WR. Potassium iodide in dermatology: a 19th century drug for the 21st century—uses, pharmacology, adverse effects, and contraindications. *J Am Acad Dermatol*. 2000;43:691-697.
- Addy JH. Disseminated cutaneous sporotrichosis associated with anergic immuno-suppression due to military tuberculosis. *West Afr J Med*. 1992;11:216-220.
- Vasen W, Terg R, Robles AM, et al. Disseminated sporotrichosis in a patient with chronic hepatopathy and hepatocarcinoma: report of a case [in Spanish]. *Enferm Infecc Microbiol Clin*. 1996;14:514-515.
- Castrejon OV, Robles M, Zubieta Arroyo OE. Fatal fungemia due to *Sporothrix schenckii*. *Mycoses*. 1995;38:373-376.
- Kluge RM, Hornick RB. Sporotrichosis: an unusual disseminated cutaneous case and a fatal pulmonary case. *South Med J*. 1976;69:855-857.
- Padhye AA, Kaufman L, Durry E, et al. Fatal pulmonary sporotrichosis caused by *Sporothrix schenckii* var. *luriei* in India. *J Clin Microbiol*. 1992;30:2492-2494.
- Ewing GE, Bosl GJ, Peterson PK. *Sporothrix schenckii* meningitis in a farmer with Hodgkin's disease. *Am J Med*. 1980;68:455-457.
- Heller HM, Fuhrer J. Disseminated sporotrichosis in patients with AIDS: case report and review of the literature. *AIDS*. 1991;5:1243-1246.
- Lynch PJ, Voorhees JJ, Harrell ER. Sporotrichosis and sarcoidosis. *Arch Dermatol*. 1971;103:298-303.
- Hardman S, Stephenson I, Jenkins DR, et al. Disseminated *Sporothrix schenckii* in a patient with AIDS. *J Infect*. 2005;51:e73-e77.
- Boehm D, Lynch JM, Hodges GR, et al. Disseminated sporotrichosis presenting as sarcoidosis: electron microscopic and immunologic studies. *Am J Med Sci*. 1982;283:71-78.