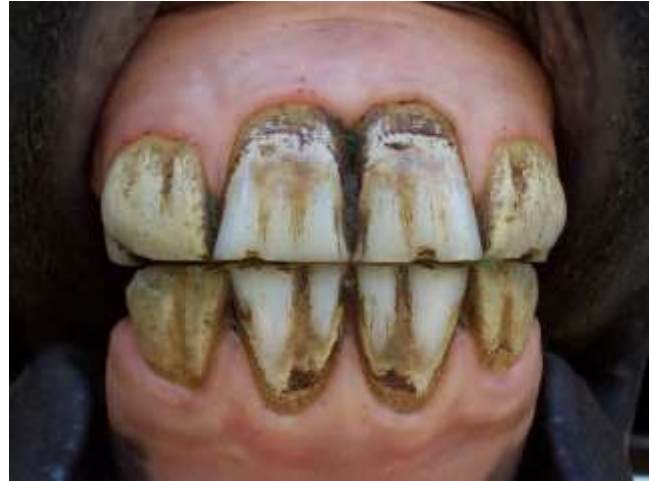

## Equine Dentistry: A Functional Basis

By Bruce Whittle, DVM

The horse's mouth is actually an exquisitely designed machine. It has three major functions: nipping off grass, grinding grass and other feedstuffs and transporting the ground feed material into the esophagus so it can then be moved down into the stomach for digestion. Fortunately for the horse, the parts that accomplish these missions do not have to be in perfect alignment, but they do have to work within certain tolerances.

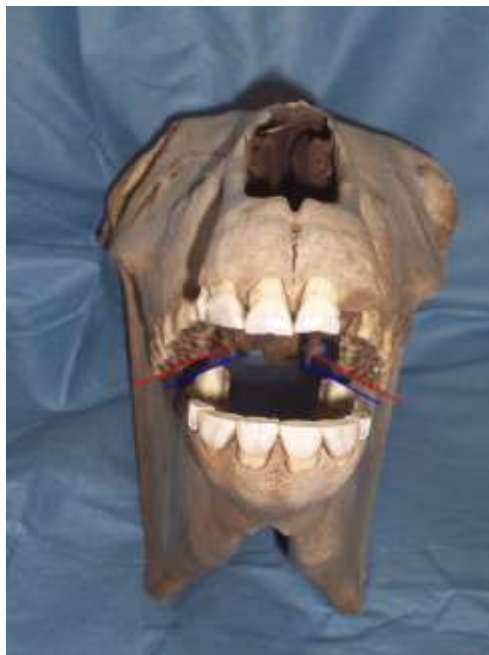
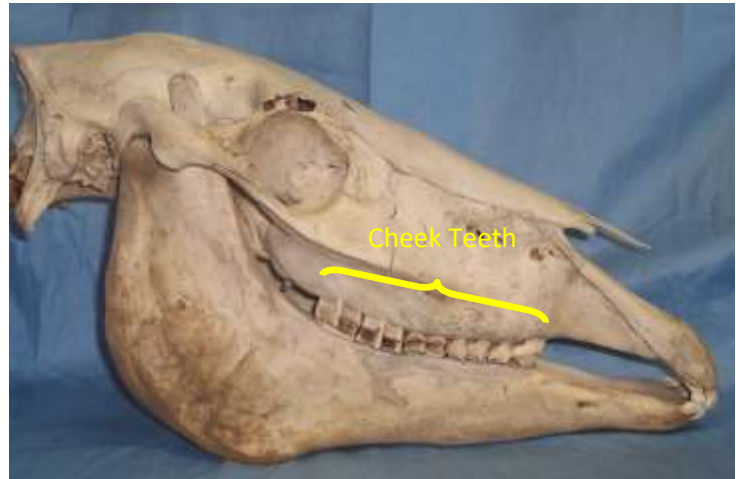
The incisors are the nipping teeth. Their function is to shear off the grass. They work best when they have a relatively level bite and there are no gaps between the teeth. When the horse nips the grass, the incisors typically work in the centric or neutral position in which the central incisors line up with their opposing teeth.



The incisors are hypsodont teeth which means they erupt throughout the horse's life. Therefore as the tooth is worn down by abrasive feed material, the tooth erupts to provide a continually renewed grinding surface. As can be seen in the incisor tooth example on the left, the tooth is relatively long. It will wear at a rate of about 2-3 mm per year and will hopefully erupt at about the same rate so that an even bite is maintained. Abnormal eruption or wear of the incisors can result in problems with the function of these teeth. Since the horse erupts then loses 24 baby teeth and up to 44 permanent teeth in the first 5 years of life, twice annual oral examinations by your veterinarian during this time will help ensure that any problems are detected at an early stage so that the horse can regain a normal bite.

The second function of the horse's mouth is to grind the feed material. This is the role of the cheek teeth of which a horse has 12 deciduous or baby cheek teeth, all premolars, and 24 permanent teeth comprised of a mix of premolars and molars. In the adult horse, the 24 teeth are divided into 4 cheek teeth rows, one upper and lower on each side of the mouth. The teeth of each cheek teeth row



should be packed closely together with no gaps and should be relatively level in relationship with each other in a front to back dimension. The cheek teeth rows actually have an angled chewing surface from the cheek side to the tongue side of approximately 10 to 15 degrees. This can be seen in the picture to the left with the occlusal table angles represented by the red and blue lines. Some horses will have occlusal table angles outside of this range but it is VERY RARE that we would intentionally change this angle. Doing so would probably render the horse unable to chew at all.

Like the incisor teeth, the cheek teeth are hypsodont teeth which continually erupt throughout a horse's life. The upper premolar on the right is from a young horse and measures about 4 inches in length. This tooth would usually wear at a rate of 2-3 mm per year.

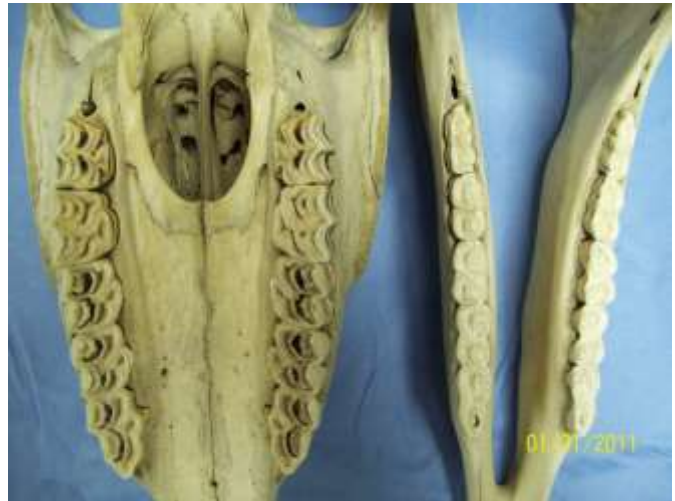

Another unique aspect of equine dental anatomy is anisognathism. This is a fancy word which means a difference in jaw widths. In the horse, the maxillary or upper jaw is wider than the mandibular or lower jaw. This can be seen in the photo to the right.

Due to anisognathism, a horse must move its lower jaw to each side to bring the upper and lower cheek teeth into contact for grinding.

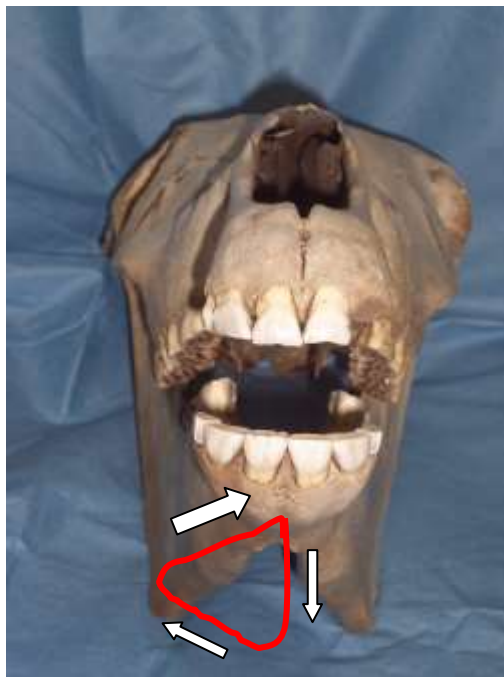
This is important because it allows a less than perfect mouth to still function properly. If this were not

the case, a horse's teeth would have to be perfectly aligned for them to accomplish the necessary functions. Fortunately for the horse, it does not have to be perfect to survive.



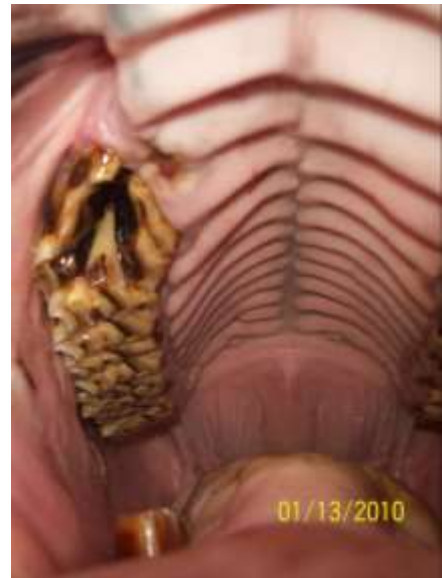When the horse chews its feed, the mandible or lower jaw drops down and

then moves laterally (to one side) and slightly upward until the upper and lower cheek teeth on that side come into contact. It then moves up and back toward the center in a powerful grinding stroke. This is demonstrated diagrammatically in the picture to the left. The red line represents a tracing of the center of the mandible during a chewing cycle on one side of the mouth. The white arrows represent the direction of travel of the mandible during that cycle. Because of the angulation of the chewing surfaces, the horse can only chew on one side at a time. Although horses do tend to chew alternately on both sides, most horses



predominate on one side of the mouth or the other. Watch your horse carefully to see if he is a left or ride-sided chewer.

The final function of a horse's mouth is to transport the ground feed material back to the throat area where it can enter the esophagus and then travel on to the stomach. These functions are performed by the tongue and the palate. The palatal folds can be seen in the photo on the right. The folds do not generally cross the centerline of the mouth and tend to be offset from one side to the other. When the tongue pushes up against these irregular folds, an auger-like effect is achieved which effectively spirals the ground feed material back into the throat.



As you can see, a horse's mouth is indeed a busy place. A horse's mouth does not have to be perfect to perform its needed functions. A horse can survive with pretty significant dental abnormalities. However, we would prefer to give the horse a better life than just survival. The role of a veterinarian in equine dental care is to examine the entire oral cavity and associated structures and to decide whether or not the horse needs any dental treatments. The goal of any dental treatment is to minimize pain and ensure that a given horse's mouth can perform its functions as efficiently as possible. Some horses may be examined and not need any dental treatment at all. Other horses may have significant malocclusions which can interfere with its ability to properly process and transport its feed material. We cannot and sometimes should not correct all problems. That is why a thorough oral examination by a veterinarian is important in arriving at a proper diagnosis and implementing an appropriate treatment plan.

The horse's mouth is indeed a well designed machine that, like any machine, requires periodic maintenance to keep it running efficiently. With timely oral examinations and treatments based upon these findings, we can help our horses to live happier, healthier lives.

*All photos copyrighted by Bruce Whittle, DVM. Permission to reprint necessary for reproduction.*