



Efficacy of Early Laparoscopic Surgery in Acute Abdomen Secondary to Perforated Jejunal Diverticulitis

Ramiro Gálvez-Valdovinos*, Ernesto Marin Y Santillan and Gustavo López-Ambriz

Laparoscopy and Robotic Service, Hospital Angeles León, Mexico

*Corresponding author: Ramiro Gálvez-Valdovinos, Laparoscopy and Robotic Service, Hospital Angeles León, Guanajuato, Mexico, E-mail: vgalvez@angelesleon.com

Abstract

A 39-year-old man with abdominal pain, fever and general poor state. Physical examination showed fever, Tachycardia, Left basal hypoventilation and acute surgical abdomen. A Abdominal X-Ray showed accumulation of calcifications in mesogastric. The laboratory test showed leukocytosis and the abdominal CT-Scan showed the cause of the acute surgical abdomen. The laparoscopic surgery was recommended and performed. A 12-inch angle of Treitz was found perforated diverticulum which was covered with omentum. Forty inches of jejunum including the perforated diverticulum were resected. The patient was discharged from the hospital on the sixth postoperative day. The pathological evaluation revealed a perforated jejunal diverticulum and diverticulosis yeyunal.

Keywords

Diverticulitis, Jejunum, Acute surgical abdomen, Laparoscopy, Midgut

examination showed a left basal hypoventilation. Upon inspection of the abdomen, without the presence of previous surgical scars, distended abdomen slightly. Auscultation of abdomen presented diminished of bowel sounds. Percussion was not carried out by pain.

Introduction

Usually jejunal diverticula disease are asymptomatic. When presented symptoms are nonspecific. The preoperative diagnosis of diverticulitis jejunal in cases of acute abdomen is difficult, given the uncharacteristic clinical symptoms and the low prevalence of this process [1]. The most common acute complications are perforation, bleeding and intestinal obstruction, these complications when they occur jeopardize the patient's life and need a rapid and precise to diagnosis not to delay the laparoscopic surgery. The prevalence of diverticula increases with age and reaches its peak in the 6th and 7th decade of life, and in this communication is important to underline that the particularity of this case is that it refers to a patient of 39 years age.

Case Report

A 39-year-old man was admitted to the emergency room with abdominal pain located in mesogastric and irradiated to upper quadrant and left flank, fever of 102.2 F, state generates attack since three days. The digestive past medical history was not significant. Physical examination disclosed; the temperature was 101 F, pulse rate was 111, and blood pressure was 110/70 and respiratory rate 18 breaths/min. The patient tended to lie still with their knees flexed as doing so provides some alleviation of their pain. The chest

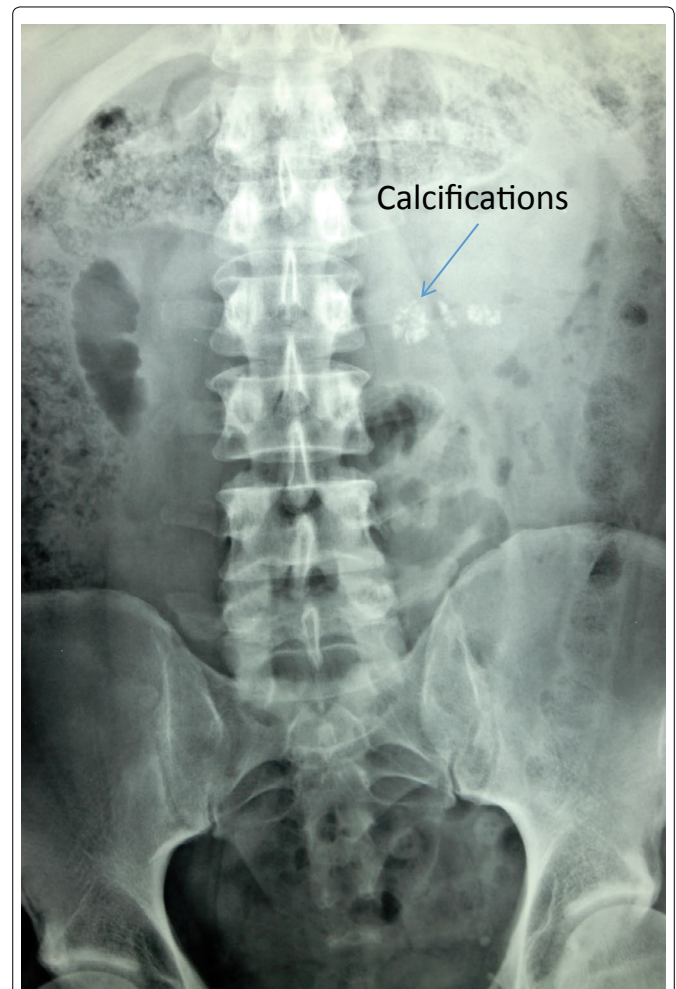


Figure 1: Abdominal X Ray accumulation of calcifications in mesogastric level and displayed multiple dilated loops of small bowel.

Abdominal palpation revealed a generalized abdominal tenderness and rebound tenderness. A complete blood count revealed a leukocytosis (19,000) and a left shift. Abdominal X-ray showed accumulation of calcifications in mesogastric level and displayed multiple dilated loops of small bowel (Figure 1). The CT-scan of abdomen showed the cause of the acute surgical abdomen (Figure 2). Multiple small bowel diverticula were identified with surrounding pockets of free air and fluid adjacent to the jejunal diverticula. The laparoscopic surgery was recommended and performed. The Pneumoperitoneum was performed with direct technique followed by the placement of the first trocar 5 mm at the level of the umbilicus. Laparoscopic exploration showed the peritoneal cavity contained a moderate amount of diffuse serous exudate. Three ports are needed in order to “run” the small bowel adequately. Usually a central trocar with two additional ports is used to allow optimal triangulation. A 12-inch angle of Treitz was found perforated diverticulum which was covered with omentum. It was plastered together by recent fibrinous adhesions. On laparoscopic examination appreciate 40 inches proximal jejunum affected by diverticula (Figure 3). Forty inches of jejunum including the perforated diverticulum were resected. A big number of the non-inflamed adjacent diverticula were removed in the resected segment. An side-to-side anastomosis with cutting linear stapler was then performed. The surgery was completed by closing the mesenteric, aspirated, peritoneal lavage irrigated and placing a Jackson-Pratt drain. Pathological analysis of the resected specimen revealed a perforated diverticulum (Figure 4) and 40 inches of proximal jejunum affected by diverticulosis. The patient was discharged from the hospital on the sixth postoperative day and her remaind well since then.

Discussion

Diverticula are mainly localized in the large intestine, but

can be found in all parts of the digestive tract. The most famous is Meckel’s diverticulum, the most common congenital anomaly of the gastrointestinal system [1]. In the small intestine diverticulum are very rare, with an incidence ranges from 0.06% to 1.3% [2]. The most common part of the small bowel to be affected by diverticula is the proximal jejunum (75%), followed by the distal jejunum (20%) and the ileum (5%) [3]. They are usually multiple and can vary in size from a few millimeters until reaching large dimensions. They remain asymptomatic in 60-70% of cases and cause symptoms or surgical complications in the 10-19% [4]. Diverticulitis jejunal or ileal, with or without perforation, occurring in 2.3-6.4% of cases, and is usually secondary to an acute inflammatory reaction necrotizing. Yeyunal

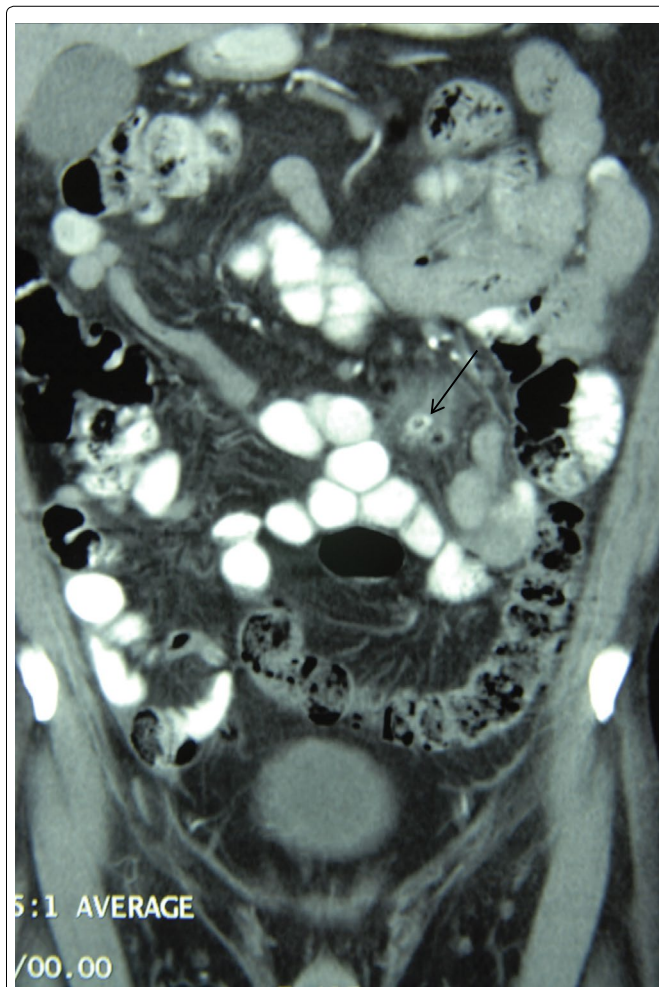


Figure 2: Coronal CT shows multiple small bowel diverticula were identified with surrounding pockets of free air and fluid adjacent to the jejunal diverticula with black arrow.

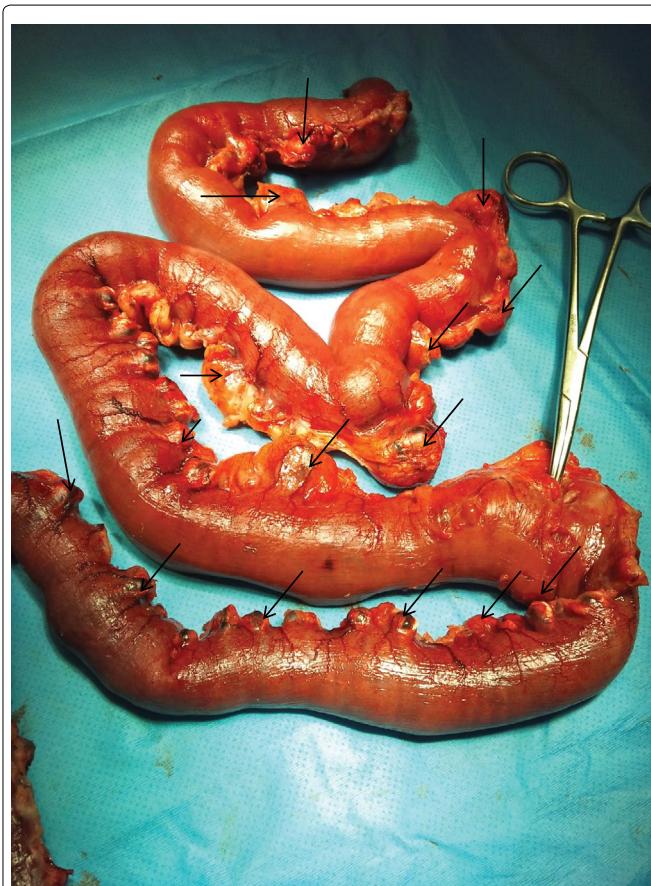

Figure 3: Small bowel resection, clip marks the perforated diverticulum. Arrows mark the multiple diverticula.

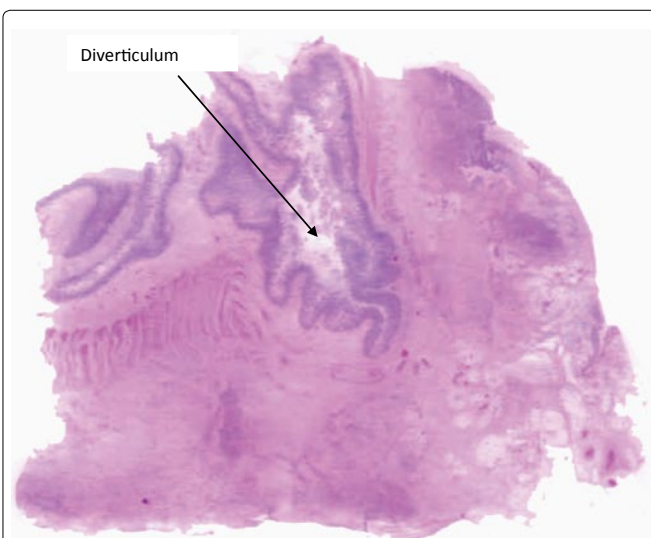


Figure 4: Histological section of the wall of the small intestine in the presence of a ruptured diverticulum, with mucoid material in abundant light and diffuse acute inflammatory infiltrate in the serosa muscular propriay addition to fibrosis. Hematoxylin and eosin stained section, magnification X8.

diverticula is false diverticula, that is to say, they lack the muscle layer, which appear through a mechanism of compulsion in the mesenteric border of the bowel wall [5,6]. The clinical symptoms of diverticulitis jejunal perforated mimic other pictures of acute abdomen, and often the initial clinical examination does not suggest the need for emergent surgical intervention [7]. This delay in the indication of laparotomy correlates with mortality [8]. Usually cause a peritonitis localized, since the diverticulum is isolated by the mesentery adjacent to it, the leaves mesenteric contribute to contain the peritoneal contamination, which usually lead to a delayed diagnosis in the elderly or debilitated may lead to sepsis, multiorgan failure, and death [9]. Diagnosis is often difficult and the diagnosis is performed mainly by imaging studies. The overall mortality of the history of the diverticulitis jejunal perforated is 24%, this has reduced to 14% when performed bowel resection with primary anastomosis [10]. These figures had been maintained in the last decades, in connection with the advanced age of the patients and delay diagnosis and therapeutic, although in the recent publications reported a mortality of 0%, attributable to the improvement in the perioperative care [11]. The X-ray of the abdomen can give information about the air-fluid levels, the existence of open and dilated bowel loops in the abdomen [12], in our case the X-ray showed accumulation of calcifications in mesogastric level and displayed multiple dilated loops of small bowel. In the meta analysis by Spasojevic, et al. [11] found that CT-scan showed a correct diagnosis was made in 77.1%. Tomographic findings described in the literature are as follows; free fluid in the abdominal cavity, a diverticula containing contrast air-liquid contents in the jejunal wall, mass lesion containing extraluminal air bubbles, a dilated small bowel loop with hyperenhancing and thickened wall, the involvement of the surrounding tissue and hyperdense appearance of the mesentery [12,13]. If perforation occurs, the free intraperitoneal air and fluid, if inflammation develops, loculated collection with high density. In our case the report read as follows; Multiple small bowel diverticula were identified with surrounding pockets of free air and fluid adjacent to the jejunal diverticula. Laparoscopy has a high sensitivity for identifying data from direct and indirect perforated diverticulum [14]. Upon entering the peritoneal cavity is visualized the free fluid the peritoneal aspect sero-purulent, and with fibrin, the swelling that is formed with the greater omentum and the site of the perforation is easily identified. If it gets difficult to find the perforation it is recommended to scan carefully all the loops of small intestine, then you must start the exploration of the ileocecal valve following in ascending order until you reach the ligament of Treitz and in this way it can detect the presence of other small bowel diverticula [15]. There is a discrepancy regarding the treatment of other diverticula yeyunales not inflamed coexisting [16]. The resection of the entire segment of bowel affected, is based on the potential risk of future complications due to diverticula remaining, but it would not be justified in elderly patients and debilitated. Recently, it has been suggested the possibility of conservative treatment of diverticulitis jejunal perforated, by means of intravenous antibiotic therapy, percutaneous drainage and control with the CT-scan of the intra abdominal collections, which offers the advantage of performing elective surgery afterwards, reducing the morbidity of a bowel resection extensive in the context of an intra-abdominal sepsis [17]. This conservative attitude requires a clinical diagnosis accurate, which is often difficult preoperatively, and a study using CT-scans to check that the inflammatory process is localized. However, the conservative treatment is expensive for the hospital stay, not free of complications and that the patient requires an urgent

surgery. There is a general agreement that the treatment of choice for diverticulitis jejunal perforated is resection of the affected segment with primary anastomosis, either via laparotómica or laparoscopic [18]. Once the diagnosis should prepare the patient for surgery, without delay early surgery. In patients whose medical conditions do not ensure emergency surgery must admit for improving critical conditions and the surgeon will assess when and how to perform safe surgery.

References

1. Kamal E, Bani-Hani, Nawaf J (2004) Meckel's diverticulum Shatnawi: Comparison of incidental and symptomatic cases. *World J Surg* 28: 917-920.
2. Staszewicz W, Christodoulou M, S Proietti, Dermartines N (2015) Acute ulcerative jejunal diverticulitis: Case report of an uncommon entity. *World J Gastroenterol* 200: 6265-6267.
3. Makris K, Tsiotos GG, Stafyla V, Sakorafas GH (2007) Small intestinal nonmeckelian diverticulosis: Clinical review. *J Clin Gastroenterol* 43: 201-207.
4. Woods K, Williams E, Melvin W, Sharp K (2008) Acquired jejunoileal diverticulosis and its complications: a review of the literature. *Am Surg* 74: 849-850.
5. Kassir R, Boueil-Bourlier A, Baccot S, Abboud K, Dubois J, et al. (2015) Jejuno-ileal diverticulitis: Etiopathogenicity, diagnosis and management. *Int J Surg Case Rep* 10: 151-153.
6. Tsiotos GG, Farnell MB, Ilstrup DM (1994) Nonmeckelianjejunal or ileal diverticulosis: an analysis of 112 cases. *Surgery* 116: 726-731.
7. Ahkrass R, Yaffe MB, Fischer C, Ponsky J, Shuck JM (1997) Small bowel diverticulosis: perceptions and reality. *J Am Coll Surg* 184: 383-388.
8. Khan HS, Ayyaz M (2015) Jejunal diverticulosis presenting as an acute emergency. *J Coll Physicians Surg Pak* 25: S20-1.
9. Johnson KN, Fankhauser GT, Chapital AB, Merritt MV, Johnson DJ (2014) Emergency management of complicated jejunal diverticulosis. *Am Surg* 80: 600-603.
10. Kassahun WT, Fangmann J, Harms J, Bartels M, Hauss J (2007) Complicated small-bowel diverticulosis: a case report and review of the literature. *World J Gastroenterol* 13: 2240-2242.
11. Spasojevic M, Naesgaard JM, Ignjatovic D (2012) Perforated midgut diverticulitis: revisited. *World J Gastroenterol* 18: 4714-4720.
12. Fidan N, Mermi EU, Acay MB, Murat M, Zobaci E (2015) Jejunal Diverticulosis Presented with Acute Abdomen and Diverticulitis Complication: A Case Report. *Pol J Radiol* 80: 532-535.
13. Patel VA, Jefferis H, Spiegelberg B, Iqbal Q, Prabhudesai A, Harris S (2008) Jejunal diverticulosis is not always a silent spectator: a report of 4 cases and review of the literature. *World J Gastroenterol* 14: 5916-5919.
14. Cross MJ, Snyder SK (1993) Laparoscopic-directed small bowel resection for jejunal diverticulitis with perforation. *J Laparoendoscopic Surg* 3: 47-49.
15. Garg N, Khullar R, Sharma A, Soni V, Bajjal M, et al. (2009) Total laparoscopic management of large complicated jejunal diverticulum. *J Minim Access Surg* 5: 115-117.
16. Hugh Shunsuke Colvin, Chin Kuenfoo, Taufiek Konrad Rajab, Thomas Sayadatas (2009) Non-surgical management of recurrent perforation of a jejunal diverticulum following previous segmental bowel resection: a case report. *J Med Case Reports* 3: 7318.
17. Melissa M Levack, Maria Lucia Madariaga, Haytham MA Kaafarani (2014) Non-operative successful management of a perforated small bowel diverticulum. *World J Gastroenterol* 20: 18477-18479.
18. Téoule P, Birgin E, Zaltenbach B, Kähler G, Wilhelm TJ, et al. (2015) A Retrospective, Unicentric Evaluation of Complicated Diverticulosis Jejuni: Symptoms, Treatment, and Postoperative Course. *Front Surg* 2: 57.