

1903

Modern Surgery - Chapter 27. Diseases and Injuries of the Abdomen - Surgery of the Stomach and Intestine

Let us know how access to this document benefits you

Follow this and additional works at: http://jdc.jefferson.edu/dacosta_modernsurgery



Part of the [History of Science, Technology, and Medicine Commons](#)

Recommended Citation

"Modern Surgery - Chapter 27. Diseases and Injuries of the Abdomen - Surgery of the Stomach and Intestine" (1903). *Modern Surgery, 4th edition, by John Chalmers Da Costa*. Paper 19.

http://jdc.jefferson.edu/dacosta_modernsurgery/19

This Article is brought to you for free and open access by the Jefferson Digital Commons. The Jefferson Digital Commons is a service of Thomas Jefferson University's [Center for Teaching and Learning \(CTL\)](#). The Commons is a showcase for Jefferson books and journals, peer-reviewed scholarly publications, unique historical collections from the University archives, and teaching tools. The Jefferson Digital Commons allows researchers and interested readers anywhere in the world to learn about and keep up to date with Jefferson scholarship. This article has been accepted for inclusion in *Modern Surgery, 4th edition, by John Chalmers Da Costa* by an authorized administrator of the Jefferson Digital Commons. For more information, please contact: JeffersonDigitalCommons@jefferson.edu.

"Jour. Amer. Med. Assoc.," Oct. 5, 1901). In 124 cases (including all chronic cases and those acute cases in which the inflammation had not extended beyond the peritoneal coat) there was 1 death. The usual causes of death are intestinal obstruction, septic peritonitis, septic endocarditis, pylophlebitis, hepatic suppuration, metastatic abscesses, endocarditis and gangrene of the bowel.

Enterorrhaphy, or Suture of the Intestine.—Surgical opinion has



Fig. 372.—Eye of the calyx-eyed needle.

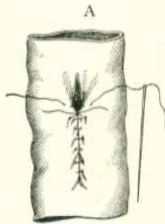
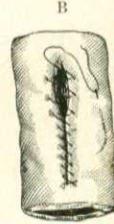

Fig. 373.—Enterorrhaphy: A, Lembert's suture; B, Dupuytren's suture.



greatly altered in regard to this operation since the day when John Bell wrote his famous attack on Benjamin Bell. John Bell said: "If in all surgery there is a work of supererogation, it is this operation of sewing up a wounded gut." To-day we know that if in all surgery there is a proceeding of imperative necessity, it is the sewing up of a wound in the intestine. To perform this operation, take fine sterile silk and thread a thin, round, straight calyx-eyed

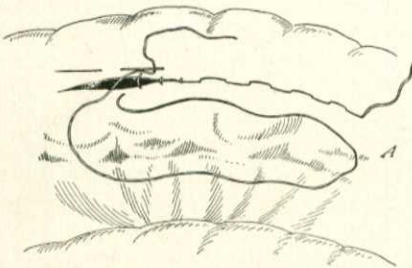


Fig. 374.—Cushing's right-angled suture (Senn).

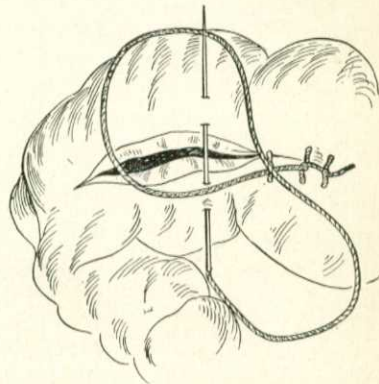


Fig. 375.—Ford's stitch, showing a Lembert insertion and the needle passed so as to tie a single knot by drawing it on through.

needle with it (Fig. 372). This needle is very useful, as it can be threaded rapidly by pushing the calyx eye down upon the silk thread while the latter is kept taut. *Lembert's suture* (Figs. 373, A, 379, and 380) was introduced in 1823. Lembert used it on animals, but never on man. It is inserted at right angles to the wound. It goes down to, but not through, the mucous membrane. It is formed by picking up a fold of the intestine (one-twelfth to one-

eighth of an inch wide) one-eighth of an inch from the edge on one side of the wound, passing the needle through, picking up a fold on the opposite side of the wound, and passing the needle through. On tying the threads the serous membrane is inverted and peritoneum is brought into contact with peritoneum. For many years it was taught that this suture should include only the serous coat, but Halsted, in 1887, showed that it must include the tough submucous coat. The submucous coat is strong, and will hold a suture. The other coats

are thin, tear easily, and will not hold a suture. So thin are the coats that a surgeon could not suture the serous coat alone were he to try. Sutures which include only the muscular and serous coats tear out easily. *Dupuytren's suture* (Fig. 373, B) is simply a continuous Lembert suture running obliquely across the wound. *Cushing's right-angled suture* (Fig. 374) is a continuous suture catching up the submucous coat and serving to invert the serous layer. Ford, of San Francisco, employs a continuous inversion suture, which is tied in a single knot each time it is drawn through (Fig. 375). Downes, of Philadelphia, uses a similar stitch. Halsted's mattress or quilt suture is shown in Fig. 376. Each

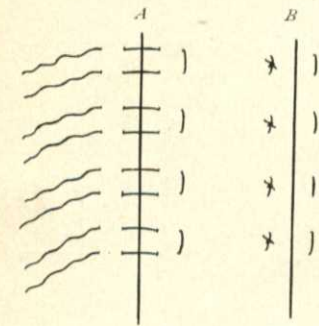


Fig. 376.—A, Halsted sutures untied; B, Halsted sutures tied and serous surface inverted.

stitch picks up the submucous coat. Mattress sutures do not tear out easily, they appose evenly considerable surfaces, and do not constrict the tissue as much as Lembert stitches. The *Czerny-Lembert suture* is a suture passed through the serous membrane on one side of the wound, made to perforate the mucous membrane, and to emerge at a corresponding point of the serous membrane. A Lembert suture is added (Fig. 377). As at present used, the Czerny suture is carried to, but not through, the mucous membrane.

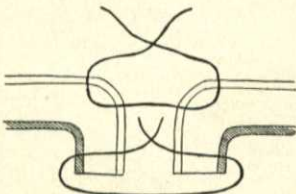


Fig. 377.—Czerny-Lembert suture.

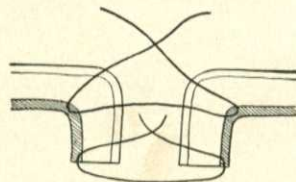


Fig. 378.—Czerny-Lembert suture as at present used.

Gussenbauer's suture is similar to the Czerny-Lembert suture, except that it applies the Czerny and the Lembert with one suture, and this suture does not pass through the mucous membrane (Fig. 382). In *Connell's suture* the knots are placed within the lumen of the bowel (Plate 9). *Wölfler's suture* unites broad layers of the serous coat, the knots being tied internally (Fig. 381). Senn says that after suturing a large wound of the stomach or of the intestine a strip of omentum ought to be laid over the wound and fastened by catgut sutures (omental graft). These grafts adhere and are a

EXPLANATION OF PLATE 9.

Intestinal suture, all knots inside (Connell).

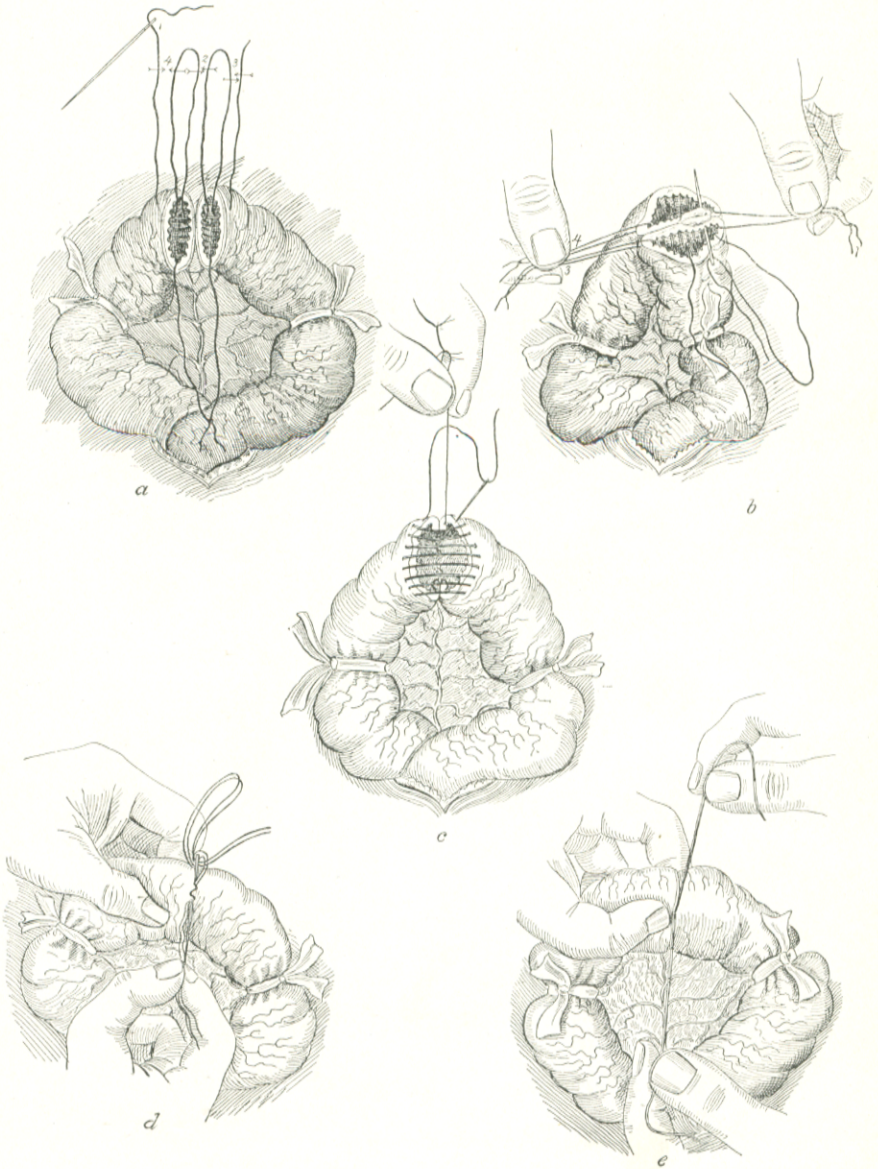
a, Suspending loops 2, 3, and 4 are made with one thread inserted at a point two thirds of the distance from mesenteric to convex border. The needle with suture is passed through the four walls of the cut ends, and that portion of suture within each lumen is drawn up to a sufficient length, then cut, and the contiguous threads tied at the points indicated by the arrows; thus having as a result four suspending loops dividing the circumference of each cut end into thirds. Instead of employing four suspending loops which divide the circumference of the bowel into thirds, we may use but two loops, and thus divide the circumference into halves; or, if available, the "holder" devised by Dr. E. H. Lee can be recommended highly, and will be found a most efficient aid in maintaining the cut edges in apposition. (The description of the instrument will be found in the "Annals of Surgery," January, 1901.)

b, Loop 2 has been cut away, and loop 1 takes its place in one hand of the assistant, with loops 3 and 4 held in the other hand, thereby bringing into apposition that portion of the walls to be included in the second third of the suture. The operator continues the suture to the points of insertion of loops 3 and 4, where again a back stitch is taken, to fix the suture and prevent a purse-string contraction of the same. The white elevation in the center of illustration, representing mesentery, shows that that portion of the intestinal wall not covered by peritoneum, at the mesenteric border, has been secured in the suture.

c, The needle, after having entered the lumen, is passed out again on the same side $\frac{1}{8}$ inch distant; then over to the opposite cut end, where it is inserted from without in, and again emerges from within out, on the same side. This step—the taking of a bite—is repeated alternately on opposing margins until the necessary number of stitches have been inserted. It will be observed that when the needle enters the lumen the last time, it makes what might be termed a half-stitch, as it does not return again *through* the wall; but having reached the point where the suture was commenced, the free end and the needle end will complete the last stitch, when tied, on the mucosa. The needle at this point is then brought out of the lumen at the angle of wound alongside of the free end of the suture. The cross-over stitches are next carefully drawn up, thus bringing into contact the opposing serous surfaces at every point except where the suture ends still protrude.

d, The eye-end of threaded needle is made to emerge alongside of the suture ends, and is then withdrawn a little, which causes its thread to form a loop, through which the assistant passes the ends of the suture. The operator next withdraws the threaded needle, at the same time bringing with it the suture ends, and they present externally at the point of withdrawal of the needle. The serous coats throughout the entire circumference are now in apposition, and the suture ends can be tied.

e, By slight traction on the suture ends the opposing mucous surfaces are brought in close contact; the suture ends are then tied firmly, and deep between the serous coats, thus tying the knot upon the mucous coat, and the ends then cut off short.



safeguard against leakage. For other methods of enterorrhaphy, see Intestinal Resection and Anastomosis.

Operations upon the Stomach.—A patient must be carefully prepared for an operation upon the stomach. The Johns Hopkins method, founded on the researches of Harvey Cushing regarding sterilization of the stomach, is to be used. During the two or three days immediately preceding operation clean the mouth and teeth several times during the day with a car-

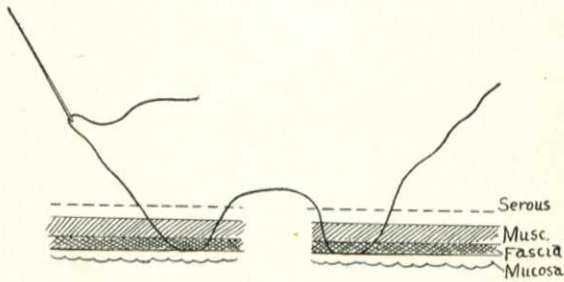


Fig. 379.—Lembert's suture.

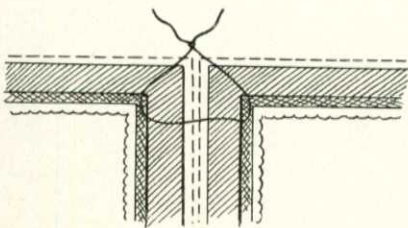


Fig. 380.—Lembert's suture closed.

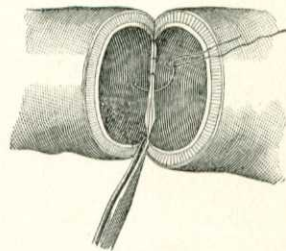


Fig. 381.—Wölfler's suture.

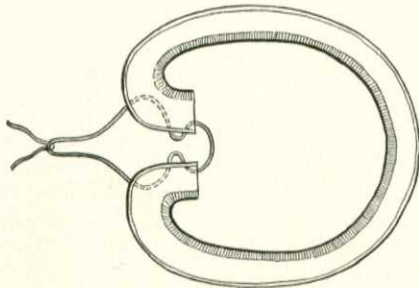


Fig. 382.—Gussenbauer's suture.

bolic solution. Give only sterile water and sterile liquid food by the mouth, and for twelve hours before operation give no food whatever. During the two or three days before operation wash the stomach with boiled water night and morning. I do not wash immediately before operation, as it sometimes leads to annoying vomiting and thus may interfere with anesthetization. After operation give no food whatever for thirty-six or forty-eight hours. A little hot water is given early. During the first twenty-four hours give an

enema of hot salt solution and coffee every five hours and then alternate nutritive enemata with salt enemata. After thirty-six or forty-eight hours usually begin to give food; at first small doses of albumin-water, and, if this is tolerated, broth and milk (Finney, in "Johns Hopkins Hosp. Bull.," July, 1902). Solid food should not be given for three weeks.

Digital Dilatation of Pylorus for Cicatricial Stenosis (Lor-eta's Operation).—Place the patient recumbent and administer ether. Make a vertical incision in the linea alba or through the right rectus muscle. The median incision begins one inch below the ensiform cartilage. The cut in either case should be five inches in length. When the peritoneum has been opened the stomach is drawn out of the wound, any adherent omentum is separated, and the pylorus is carefully examined. The stomach, after being surrounded with gauze pads, is opened near the center of its anterior surface, "but rather nearer to its pyloric end" (Jacobson).

Insert the index-finger through the stomach wound and into the pylorus, and follow that with the middle finger. The pylorus can be well dilated by separating the fingers. If the stenosis is so tight as to prevent the entry of a

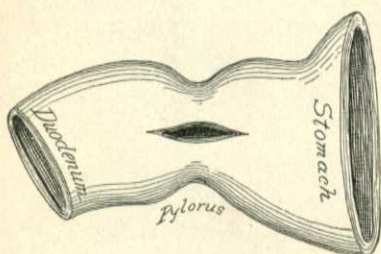


Fig. 383.—Heineke-Mikulicz's pyloroplasty: the incision.

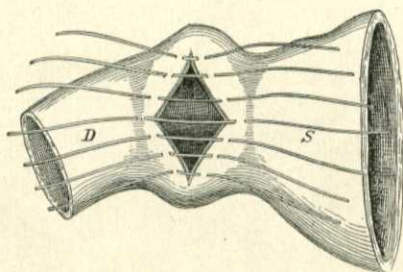


Fig. 384.—Heineke-Mikulicz's pyloroplasty. The axis of the incision is changed by traction from horizontal to vertical; sutures in position; only one of the two rows of sutures is shown.

finger, first introduce a pair of hemostatic forceps and open the blades a little when they are within the lumen of the constricted area. The wound in the stomach is closed by a continuous silk suture of the mucous membrane and two layers of Halsted sutures, to invert and approximate the peritoneal surfaces. After closure of the stomach wound the abdominal wound is sutured.

Divulsion by the fingers or by an instrument is no longer practised, because experience has shown that the constriction is sure to return.

Pyloroplasty (Heineke-Mikulicz Operation).—The first operation was performed by Heineke in 1886. Early in 1887, Mikulicz, not knowing of Heineke's antecedent operation, did the same thing. Open the abdomen in the middle line, or, better, through the right rectus muscle. Draw up the pylorus as well as possible and pack warm moist gauze pads around it; make an incision through the stricture and in a direction corresponding to the long axis of the stomach and bowel (Fig. 383). Catch an aneurysm-needle under the upper margin of the incision and draw it up, and an aneurysm-needle under the lower margin and draw it down. The effect of traction is to convert the transverse wound into a vertical one. The sutures are applied so as to main-

tain the wound in a vertical line. The mucous membrane is sutured with a continuous suture of silk, and interrupted Lembert or Halsted sutures of silk close the peritoneal and muscular coats (Figs. 384, 385). Drain for twenty-four hours, because there is danger of leakage. A. W. Mayo Robson inserts a bone bobbin and then applies the sutures. The operation of pyloroplasty shows a mortality about the same as or slightly less than gastro-enterostomy. It is often a very satisfactory procedure, but there are objections to it. The outlet is not at the most dependent part of the stomach, hence the stomach may not empty itself. Further, as Finney points out, it cannot be performed if there are firm adhesions, or active ulceration, and the scar may contract and give rise to stenosis. Again, it is difficult to suture so as to certainly provide against leakage. Finney has devised an operation to correct these objections.

Finney's Method of Pyloroplasty.—This operation is described in the "Johns Hopkins Hospital Bulletin," July, 1902. It is performed as follows: Thoroughly free the first portion of the duodenum and the pyloric end of the stomach. Insert three retractor sutures (Fig. 386) and draw upon them.

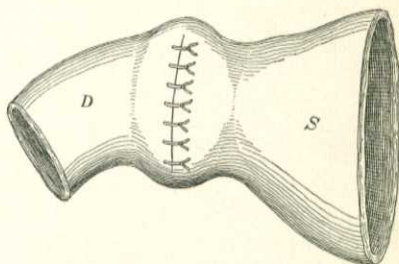


Fig. 385.—Heineke-Mikulicz's pyloroplasty: after tying the sutures.

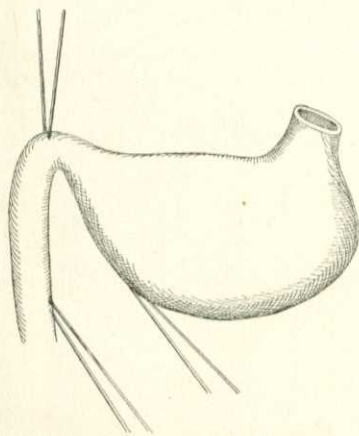


Fig. 386.—Finney's pyloroplasty. The retractor sutures.

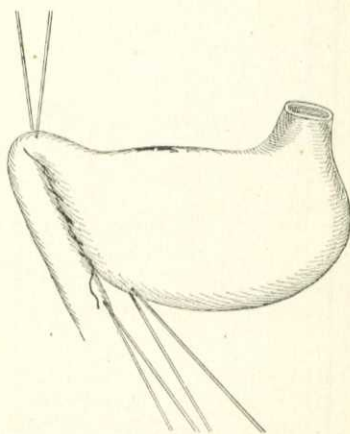


Fig. 387.—Finney's pyloroplasty. Suture of greater curvature of stomach to duodenum.

Suture together, as far posterior as possible, the peritoneal surface of the duodenum and the peritoneal surface of the stomach, along its greater curvature (Fig. 387). Insert an anterior row of mattress sutures, but do not tie them as yet (Fig. 388). Make a horseshoe-shaped incision (Fig. 389); arrest bleeding; excise as much scar-tissue as possible on either side of the incision, and trim off the redundant mucous membrane. Insert a continuous catgut

suture on the posterior side of the incision and carry it through all the coats (Fig. 390). Straighten out the anterior sutures and tie them (Fig. 391).

Pylorotomy (Excision of the Pylorus).—The removal of a portion of the stomach is a partial gastrectomy, and pylorotomy is a partial gastrectomy in which the pylorus and also a portion of duodenum are removed.

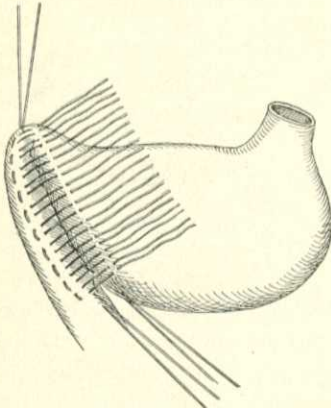


Fig. 388.—Finney's pyloroplasty. Shows the three retractor sutures, the posterior line of sutures tied and the anterior line of sutures untied.

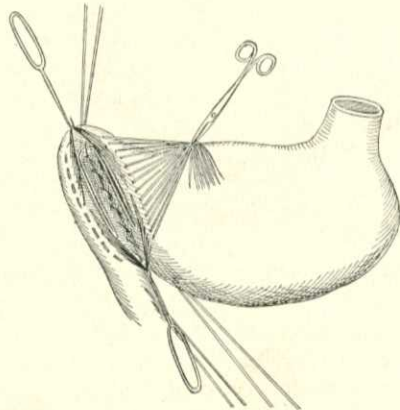


Fig. 389.—Finney's pyloroplasty. The anterior sutures gathered and lifted.

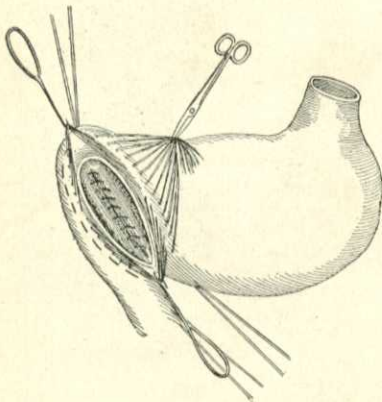


Fig. 390.—Finney's pyloroplasty. The continuous posterior catgut suture.

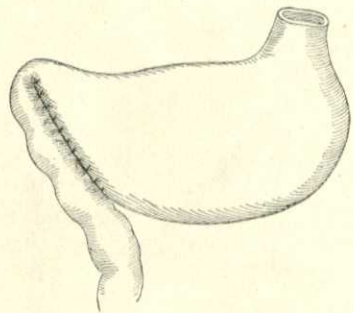


Fig. 391.—Finney's pyloroplasty completed by tying the anterior sutures.

This operation was first performed by Péan in 1879. It was next performed by Rydygier in 1880. Billroth did the first successful pylorotomy in 1881. Practically its only use is in cases of cancer of the pylorus. In most cases of pyloric cancer the abdomen is opened after a palpable tumor is detected, and when a palpable tumor is detectable it is usually too late to perform pylorotomy.*

*Keen's "Cartwright Lectures" for 1898.

Keen agrees with Hemmeter that stenotic symptoms, even when no tumor is palpable, call for exploratory laparotomy; if the stomach is dilated, if there is cachexia, if there is no free hydrochloric acid in the gastric juice, if there is

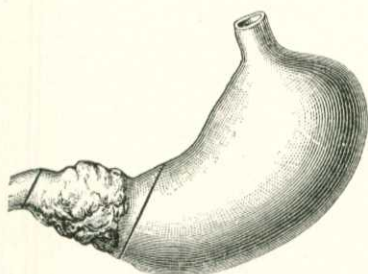


Fig. 392.—Billroth's method of pylorectomy.

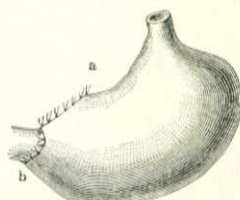


Fig. 393.—Pylorectomy.

an excess of lactic acid in the gastric juice, if the patient is at or beyond forty years of age, when there is vomiting of blood, when the Oppler bacillus is present, when blood examination shows a diminution in red corpuscles and hemoglobin, and also shows that there is no increase in white corpuscles after a full meal. After the abdomen has been opened the stomach is examined, and if a tumor exists the surgeon must decide between the performance of pylorectomy and gastro-enterostomy. If the tumor is not very extensive, if there is no glandular involvement or only involvement which can be removed, and if adhesions are not extensive, pylorectomy is chosen; otherwise gastro-enterostomy is selected.

Until very lately the mortality from pylorectomy was estimated to be 25 per cent., even in favorable cases. In 9 complete pylorectomies, with closure of both the stomach and duodenal ends, communication being re-established by the performance of gastro-jejuno-stomy, Mayo reports 1 death, and in 14 pylorectomies and partial gastrectomies he reports 2 deaths, or 14 per cent. (Wm. J. Mayo, in "Annals of Surgery," Aug., 1902). Prepare the patient for pylorectomy as for any stomach operation. The best incision

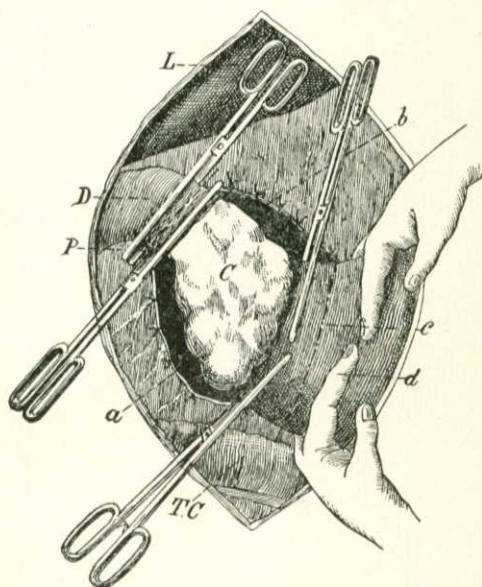


Fig. 394.—Kocher's method of pylorectomy: *L*, Liver; *D*, duodenum; *P*, pylorus; *C*, carcinoma; *T.C.*, transverse colon; *a*, separation-place of the ligature gastrocolic; *b*, separation-place of the lesser omentum; *c*, separation-line of the stomach; *d*, place where the stomach is kept closed by the middle and index fingers.

through the abdominal wall is transverse over the middle of the tumor. A small incision is made first to permit of exploration, and if the growth is found to be removable the incision is enlarged. The center of the incision is over the most prominent part of the tumor, and the direction of the incision corresponds with the long axis of the pylorus. Draw the tumor into the wound, and tuck pads about the stomach and the pylorus to catch extravasated fluids. Free the pylorus; incise between forceps the great omentum near the greater curvature of the stomach, and ligate each end in segments; treat the lesser omentum in the same manner. Each omentum is divided only to an extent sufficient to permit removal of the growth. Repack the gauze pads and tie a rubber tube around the duodenum below the growth. In making the excision

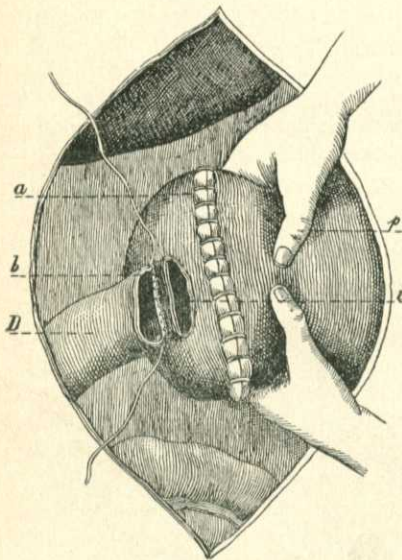


Fig. 395.—Kocher's method of pylorotomy: *D*, Duodenum at the posterior wall; *a*, continuous suture of the peritoneum; *b*, posterior line of peritoneal continuous suture of the ring; *p*, assistant's thumb pressing the stomach against the duodenum so as to close its lumen; *i*, incision in the posterior gastric wall.

remember that the stomach-wound will be much larger than the duodenal wound, and a special method of suturing will be required to approximate the two wounds in size. The lines of incision are shown in Fig. 393. The stomach is cut with scissors until two-thirds of its depth is divided, and the organ is washed out. After stopping hemorrhage this cut is closed by a continuous suture for the mucous membrane and by Halsted sutures for the other coats. The remaining portion of the stomach is cut through. The duodenum is cut through its upper half below the growth, and is fastened to the stomach by Halsted sutures at the upper border and Wölfler's sutures at the posterior borders. Wölfler's sutures are applied from inside, they pierce all coats, and bring broad layers of the serous coat into apposition. The remainder of the duodenum is cut through, and its anterior and inferior parts are united to the stomach by a

double row of Halsted sutures, as set forth above (Fig. 393). Stitch the edges of the cut omenta to the stomach, cleanse the parts, replace the stomach, insert gauze for drainage, close the abdominal incision, and dress the wound. Drainage is necessary after any extensive operation upon the stomach because there is great danger of extravasation, this danger being due, as Richardson shows, to the difficulty of making a tight approximation and to the action of the gastric juice.* Another method of performing pylorotomy is to excise the growth as directed above, suture the opening in the stomach, and implant the duodenum in the anterior or posterior wall of the stomach, making an incision through the stomach-wall to permit of it. Kocher

* M. H. Richardson, in Boston Med. and Surg. Jour., Aug. 4, 1898.

advocates implantation of the duodenum in the posterior wall of the stomach. Kocher's method of pylorotomy with gastro-enterostomy is shown in Figs. 394, 395. The junction between the duodenum and the posterior wall of the stomach may be effected by a large Murphy button. Give nothing by the mouth for thirty-six or forty-eight hours after the performance of pylorotomy. Thirst can be relieved by enemata of water or by the hypodermatic injection of boiled water. After thirty-six or forty-eight hours begin with stomach feeding, starting with small doses of albumin water, and if this is tolerated giving dessertspoonful doses of peptonized milk every hour.

Total Gastrectomy.—The entire stomach was first removed by Conner, of Cincinnati. The first successful operation was performed by Schlatter, of Zürich, in 1898. Total gastrectomy will rarely be required, but in certain unusual cases it will be proper to perform it. In some cases the duodenal end can be sutured to the divided esophagus; in others it will be necessary to close the end of the divided first portion of the duodenum, and anastomose the esophagus to the third portion of the duodenum.

The cases suitable for total gastrectomy are those in which the entire viscus, or almost the entire viscus, is cancerous, the stomach being still freely movable, and the glands not so much implicated as to forbid attempts at removal. It is a remarkable fact, first demonstrated in Schlatter's case, that an individual can digest food very well without a stomach.

Gastrostomy.—This term is used to designate the operation of opening the stomach for the accomplishment of some purpose, and immediately closing the incision in the gastric wall when that purpose is accomplished. Gastrostomy may be performed to permit of the removal of foreign bodies, of exploration of the stomach and its extremities, of divulsion of the pyloric orifice, of the treatment of bleeding, of an esophageal stricture, or a stricture of the cardiac orifice of the stomach, or of the removal of a foreign body lodged in the esophagus.

The patient is prepared as for pylorotomy. The incision may be vertical in the middle line or identical with the incision for pylorotomy. If a large foreign body can be felt, the incision is made directly over it. When the peritoneal cavity is opened, the surgeon decides as to the point where the stomach is to be incised, and draws this portion out through the wound, packing gauze pads under and around it. The stomach is opened by means of scissors, the cut being at a right angle to the long axis of the viscus (Jacobson). Bleeding vessels are ligated with catgut. The purpose for which the stomach was opened is now to be carried out, the interior of the stomach and the surface of the extruded portion are irrigated with hot salt solution, the mucous membrane is sutured with a continuous suture of silk, and two rows of Halsted sutures are inserted. The abdominal wound is closed, drainage being employed for twenty-four hours.

Gastrostomy is the making of a permanent gastric fistula, through which opening the patient can be fed. Gastrostomy was first proposed by Egebert in 1837 (Keen), and was first performed by Sédillot in 1849. In 1875 Sydney Jones operated upon the twenty-ninth case and obtained the first recovery (Keen). Up to 1884 the estimated mortality was 80 per cent. At present the mortality in malignant cases is from 20 to 25 per cent., and in non-malignant cases from 8 to 10 per cent. Gastrostomy is employed in cases of esophageal obstruction or obstruction of the cardiac end of the

stomach. In many cases of malignant disease the operation is performed too late, and if performed when the patient is greatly emaciated and exhausted the operation has, of course, a high mortality. An early operation is far safer and confers the maximum of relief. The operation should be performed, as Mikulicz advises, when the patient is steadily losing weight and there is beginning to be difficulty in swallowing semi-solids or liquids. The surgeon must endeavor to perform an operation which will not permit of leakage. Prepare the patient as for any stomach operation.

Witzel's Method.—This operation was first practised in 1891. An incision is made four inches long, running to the left from the middle line, just below the border of the ribs. After opening the peritoneal cavity seize the stomach,




Fig. 396.—Witzel's method of gastrostomy, showing application of sutures in wall of stomach, embedding tube obliquely therein.

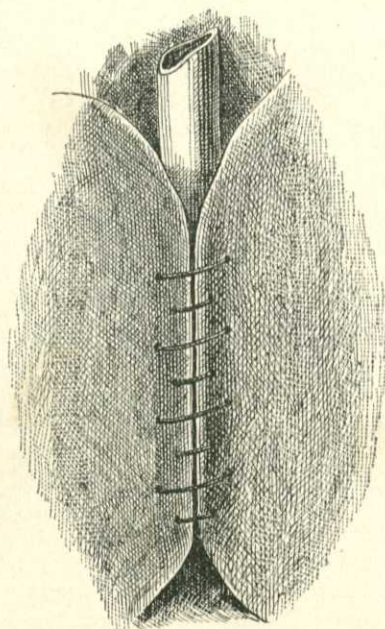


Fig. 397.—Sutures tied, completely embedding tube obliquely therein.

bring it out of the wound, and pack gauze around it. Introduce a rubber tube into the stomach and enfold it by a double row of Lembert sutures (Figs. 396, 397): This tube should be five inches long and of the same diameter as a No. 25 French bougie. The opening is made in the stomach toward the cardiac extremity, the tube is placed parallel with the belly-wound, and the outer end of the tube emerges in the median line. The tube is retained in place by a catgut stitch carried through the tube and the stomach-wall. The stomach is returned and is stitched by three sutures to the abdominal wall. The abdominal incision is sutured and a clamp is placed on the tube. When the patient is fed, a funnel is slipped into the tube, the clamp is removed, and liquid food is poured into the funnel.

After the wound heals it is not necessary to permanently retain the tube. It is passed when the patient desires food.

Kader's Method.—This operation was devised in 1896. It is a modifica-

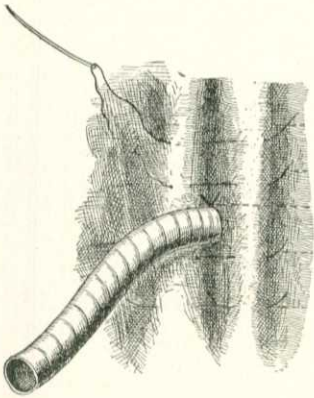


Fig. 398.—Kader's method of gastrostomy. Tube in place and first row of sutures inserted.

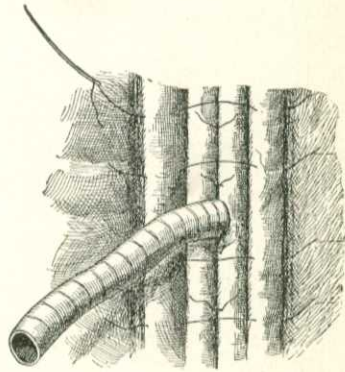


Fig. 399.—Kader's method of gastrostomy. First row of sutures tied and second row inserted.

tion of Witzel's method. A small incision is made in the stomach and a tube is introduced and fastened to the stomach by one catgut stitch. Four Lembert sutures are passed so as to form a fold on each side of the tube and turn the stomach-wall inward around the tube (Fig. 398). Lembert sutures are inserted in the furrow on each side of the tube. Two more folds are formed over the first two (Figs. 399 and 400). The stomach-wall is stitched to the parietal peritoneum and sheath of the rectus muscle (Willy Meyer).

The Ssabanejew-Frank Method.—This operation is preferred by many surgeons. I usually employ it if the stomach is not so shrunken as to render the pulling out of a sufficient cone impossible. It was first performed by Ssabanejew in 1890 and was performed independently by Frank in 1893. Fenger's incision is made (a curved incision at the margin of the costal cartilages of the left side). A cone of the stomach is pulled out of the wound and is passed under a bridge of skin which has been prepared for it. The stomach is fixed above the margin of the ribs and opened (Figs. 401, 402). Von Hacker makes the gastric fistula through the left rectus muscle, and Hahn between two of the rib cartilages (Willy Meyer).

The Younger Senn's Method.—Emanuel Senn devised the following

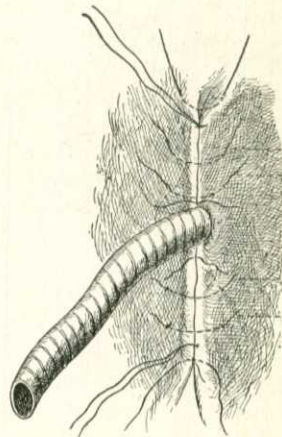


Fig. 400.—Kader's method of gastrostomy. Second row of sutures tied.

method: A cone of the stomach is pulled out of the abdominal wound, and this cone is puckered by the insertion of two drawing-string sutures of chromic catgut through the serous and muscular coats. A cuff of gastrocolic omentum is sutured by silk around the neck of the puckered cone. The stomach is sutured to the belly-wall with silk, the sutures including the omental cuff, the serous and muscular coats of the stomach, and the structures of the belly-wall, except the skin. The skin is partly sutured. The stomach may be opened at any time.

Gastro-enterostomy or **gastro-jejunostomy** is the establishment of a permanent fistula between the stomach and the small intestine, in order to side-track the pylorus. The operation is performed for cancer of the pylorus, for non-cancerous stenosis of the pylorus, and in some cases of ulcer of the stomach. Anterior gastro-enterostomy was proposed by Nicolaoni in 1881 and was first performed by Wölfler the same year. Posterior

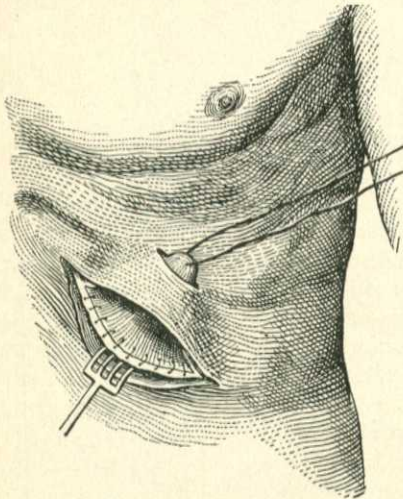


Fig. 401.

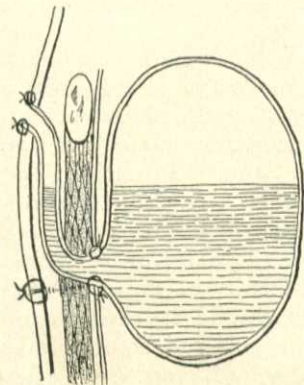


Fig. 402.

Figs. 401, 402.—The Ssabanejew-Frank method of gastrostomy in carcinoma of the esophagus.

gastro-enterostomy was first proposed by Courvoisier in 1883. His plan necessitated a transverse division of the mesocolon, but it was found that this impaired the blood-supply of a part of the colon and might lead to gangrene. Von Hacker, in 1885, devised the method we now practise. As a matter of fact, the transverse mesocolon has a marginal artery, unlike other parts of the colon, and the danger of gangrene from a transverse incision is probably not very great. In non-malignant conditions the mortality is very low (under 6 per cent.), the hyperacidity of the gastric juice disappears, and the functions of the stomach are restored. In malignant cases the mortality is about 20 per cent., but even in such cases, if operation is done early, life may be prolonged and made comfortable for months. Wm. J. Mayo reports 107 gastro-enterostomies with 10 deaths, an average mortality of 9 per cent. ("Annals of Surgery," Aug., 1902). The mortality in the malignant cases was 20 per cent.; in non-malignant cases, under 6 per cent.

The causes of death, according to Mayo, are: exhaustion, exhaustion with vomiting, pneumonia, and detachment of the anastomosed intestine.

Complications Following Gastro-enterostomy.—Among them are lung complications. These are not due to the anesthetic, for they tend to occur even when a local anesthetic was used. They are not due to the epigastric incision interfering with cough and expectoration, for they are not nearly so common after operations upon the gall-bladder (Wm. J. Mayo). Mayo says that the latest theory is that some of the venous blood returning from the stomach does not pass through the liver, and infected emboli are deposited in the lungs. The suture line may leak after gastro-enterostomy, because of imperfect suturing, or the anastomosed intestine may become detached. Twenty per cent. of the deaths among Mayo's cases resulted from this cause. Contraction of the anastomosis opening may gradually take place. This has been held by some to be particularly common in cases of dilated stomach, shrinking of the stomach being the efficient cause; but evidence upon this point is not conclusive. In cases in which the pylorus is not obstructed shrinking often occurs, but it rarely takes place when the pylorus is obstructed. In some cases, after operation a spur forms in the jejunum because of angulation; in other cases adhesions produce obstruction; and in rare instances ulceration takes place in the duodenum or jejunum. The most common complication after gastro-enterostomy is persistent vomiting, which may or may not be expressive of the formation of a vicious circle.

The Vicious Circle and Regurgitation.—Vomiting may occur after the performance of gastro-enterostomy. It may soon cease, may be productive of disastrous consequences, and may be expressive of an existing complication of great gravity. In some cases of gastro-enterostomy vomiting arises because the anastomosis has been made high up on the anterior wall and the stomach is not drained. In other cases ether induces vomiting, and the mechanical efforts force the contents of the duodenum and even of the jejunum into the stomach. The true "vicious circle" is a condition in which the contents of the stomach pass through the anastomosis opening into the duodenal side of the loop of intestine, mix with the duodenal secretions, and return to the stomach (Fowler, in "Annals of Surgery," Nov., 1902). The following conditions are often classified under the same head, but each is called by Fowler a regurgitation or reflux: (1) When the duodenal secretions pass back into the stomach through a permeable pylorus (as in cases of gastropnoia, non-cancerous pyloric stenosis, and gastric dilatation); (2) when the duodenal secretions enter the stomach through the anastomosis opening; (3) when the contents of the jejunum pass into the stomach, because of efforts at vomiting or as a result of reversed peristalsis. In some cases the contents of the jejunum may pass into the afferent loop of intestine and distend it.

Persistent vomiting is in some cases due to kinking or twisting of the distal loop; in others, to failure of peristalsis in the proximal loop; in still others, to contraction of the opening in the stomach-wall (Chlumsky on Gastro-enterostomy in the Breslau Clinic; article by Charles L. Gibson, in "Annals of Surgery," Aug., 1898). In order to lessen the danger of vomiting after gastro-enterostomy, use a local anesthetic whenever possible (Fowler).

After Billroth's operation (Fig. 405), and in all the earlier methods, the contents of the duodenum certainly pass into the stomach, mix with the

stomach-contents, and usually, but not always, pass into the efferent loop. In all these operations there is great danger of the development of a vicious circle.

Lücke devised an operation with the idea of preventing such a complication. In the Lücke operation the direction of peristalsis in the efferent loop is the same as in the stomach (Fig. 403). McGraw points out that

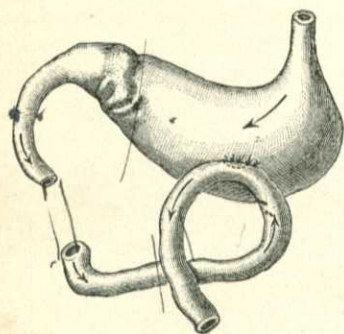


Fig. 403.—Gastro-enterostomy (after Lücke).

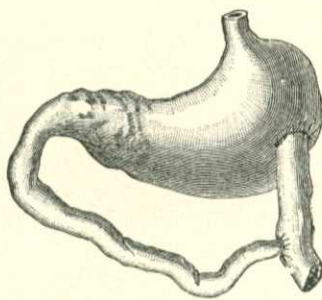


Fig. 404.—Implantation of duodenum into jejunum and jejunum into stomach (after Wölfler).

the crossing of the loop which is effected is dangerous. The Wölfler-Lücke operation is shown in Fig. 410. Wölfler devised the operation pictured in Fig. 405. Von Hacker's posterior operation is thought by some to be less apt than the anterior method to be followed by the vicious circle (Fig. 411). Kocher devised an operation in which a valve is formed, but, as Fowler points out, this valve does not prevent filling of the duodenum and imbibition of the material by the stomach; and further, that the valve does not work when the parts become cicatricial.

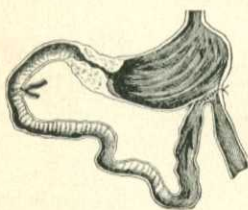


Fig. 405.—Billroth's method of gastro-enterostomy.

The combination of gastro-enterostomy with entero-anastomosis does tend to prevent the vicious circle. This operation is shown in Figs. 408 and 409. The defect in such an operation is that there is still a communication between the stomach and the afferent loop. Fowler's operation (Fig. 411) corrects this defect. McGraw's operation tends to prevent the formation of a vicious circle.

Treatment of Persistent Vomiting after Gastro-enterostomy.—If vomiting persists in spite of gastric lavage and rectal feeding after the operation of gastro-enterostomy without entero-anastomosis, open the abdomen again and perform anastomosis between the afferent and efferent loops of intestine.

Anterior Gastro-enterostomy.—*Senn's Method.*—A median incision is made through the abdominal wall, from below the xiphoid cartilage to the umbilicus. An opening is made in the lower part of the anterior wall of the stomach in the direction of the long axis of the viscus and its edges are stitched with a continuous catgut suture. The contents of the jejunum are forced along to below the point where an incision is to be made. The duodenal loop of jejunum should be from 12 to 14 inches in length. A rubber tube is fastened

around the bowel above this point, and another below it; an incision is made in the long axis of the bowel, and the margins of the wound are sutured in the same manner as the stomach-wound. Bone plates are introduced into the stomach and intestine, and the ligatures are tied as in intestinal anastomosis. Catgut rings or rubber rings may be used. Fig. 404 shows Wölfler's original method of gastro-enterostomy.

Mayo's Method (Fig. 406).—Open the abdomen, and pick up the small intestine and find a point of jejunum about 14 inches from the point at which it emerges from under the mesocolon. Effect the union to the inferior border of the stomach close to the greater curvature and at the lowest portion of the stomach pouch. When the anastomosis is completed, the stomach pouch is funnel-shaped. The usual custom has been to place the opening higher on the anterior wall. It sometimes led to the formation of a pouch on the anterior wall, did not drain the stomach, and caused vomiting. After the performance of gastro-enterostomy the edges of the omentum are caught upon each side of the anastomosis and are sutured to each other and to the stomach-wall one inch above the opening. The edges are then united to each other in a downward direction for about three inches so as to form an apron over the anastomosis, yet not connected with it. Catgut is used for suturing. If leakage occurs, the omentum is adjacent and "available." If leakage does not occur, the omentum soon returns to its normal position (Wm. J. Mayo, in "Annals of Surgery," Aug., 1902).

Kocher's Method (Fig. 407).—After opening the abdomen, lift up the omentum, pull up a loop of intestine, and find the point where the jejunum appears from under the mesocolon. Select a loop sixteen inches from the origin of the jejunum and prepare to attach it to the stomach. Wölfler showed that the intestine should be applied to the stomach in such a manner that the direction of peristalsis in the bowel must correspond to the direction of the stomach-tide. This can be accomplished by having the proximal portion of gut to the left, and the distal portion to the right. The operation is to be so performed that after its completion the stomach-contents pass

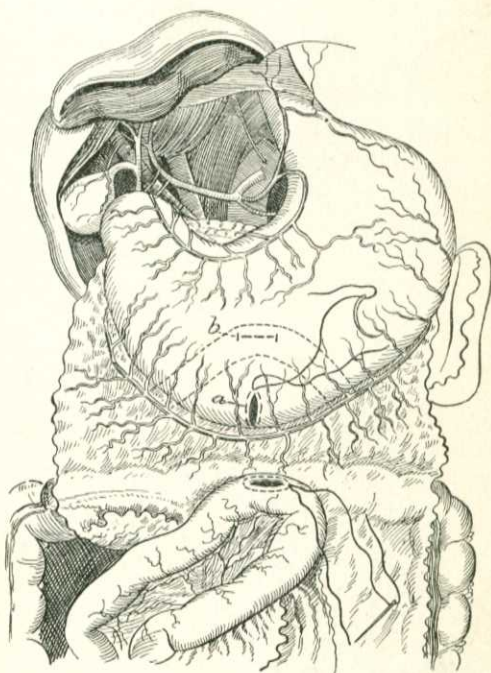


Fig. 406.—Mayo's method of gastro-enterostomy, showing proper and improper locations of opening: *a*, Proper position, leaving no pouch; *b*, usual position, forming intragastric pouch ("Annals of Surgery").

into the distal portion of the gut, and the intestinal contents do not tend to enter the stomach. In order to accomplish this Kocher hangs the intestine to the stomach-wall in such a manner that the proximal portion of the loop is posterior and ascending, and the distal portion is anterior and descending.

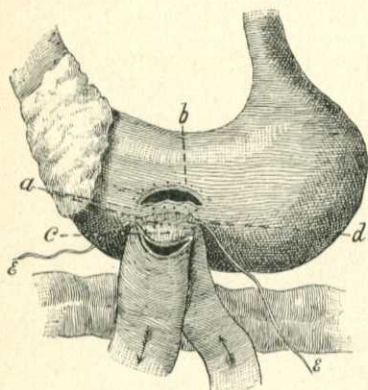


Fig. 407.—Kocher's method of gastro-enterostomy: *a*, Places of posterior annular suture through entire wall of stomach and intestine; *b*, places of anterior annular suture through the entire wall; *c*, valve at the jejunum by arch-formed incision; *d*, posterior annular suture of the serosa; *e*, thread ends for continuing anterior suture of the serosa.

Thus the danger of infection is greatly lessened, for when the anastomosis opening is formed it is completely encompassed by firm adhesions. Further, the danger of the formation of a vicious circle is greatly lessened because there is no communication between the stomach and bowel for between forty-eight and seventy-two hours, the period in which vomiting of the type previously described is most apt to occur.

The bowel is hung to the stomach by a continuous serous suture of silk, the ends of which are left long. The intestine is opened by a curved incision, the convexity of which is downward. The stomach is opened so that the convexity of the cut is upward. The valve-like portion of the bowel-wall is sutured to the stomach below the incision in that viscus. The two openings are well approximated by sutures.

Operation by McGraw's Elastic Ligature.—The intestine and stomach are sutured together by Lembert sutures. The elastic cord is passed through the stomach and then the bowel, in the long axis of each, and is tightly tied, and the knot is fastened with a silk thread. Another row of Lembert sutures buries the silk cord from sight. The cord cuts through in from forty-eight to seventy-two hours and makes the anastomosis.

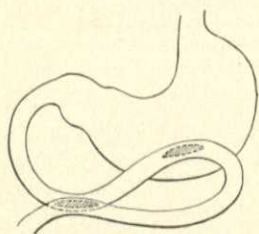


Fig. 408.—Jaboulay's method of gastro-enterostomy.

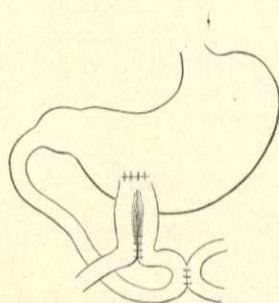


Fig. 409.—Braun's method of gastro-enterostomy.

Gastro-duodenostomy.—This operation was devised by Jaboulay in 1892. It aims to obviate some of the objections to pyloroplasty and at the same time to retain the advantages this operation possesses over gastro-jejunosomy. It has never become popular with surgeons, and Finney's method of pyloroplasty is much more satisfactory.

Posterior Gastro-enterostomy.—In a thin subject with a long mesocolon posterior gastro-enterostomy is to be chosen, but if the mesentery is short or contains much fat, or if the vascular loop coming from the superior mesenteric artery, and which supplies the transverse colon with blood, is small, so that on opening the posterior layer of the gastro-colic omentum would be close to the artery, the anterior operation is employed (Wm. J. Mayo, in "Annals of Surgery," Aug., 1902). If a Murphy button is used, the posterior operation is selected. The operation is performed as follows: After the abdomen has been opened the stomach and omentum are raised; a portion of the upper jejunum is seized, emptied, and tied with tubes as previously described. The portion selected should be at least ten inches below the emergence of the jejunum from under the mesocolon. A spot is selected on the transverse mesocolon where there are no vessels and an opening is made through the mesocolon with a dry dissector. The posterior wall of the stomach is pulled into the opening and sutured to its edges. This prevents downward displacement of the stomach and obstruction of the loop of gut. The sutures are so inserted that a flap is formed of the mesenteric margin to protect the line of

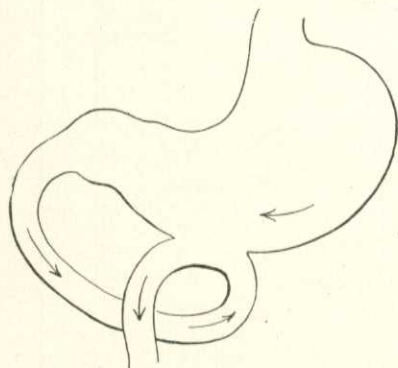


Fig. 410.—Wölfler-Lücke method of gastro-enterostomy.

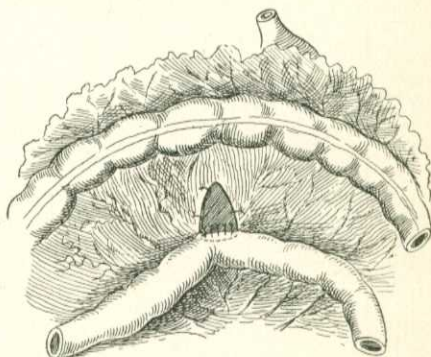


Fig. 411.—Von Hacker's posterior gastro-enterostomy.

junction of the anastomotic opening (Willy Meyer). An anastomosis is then performed. Regurgitation is less common after posterior than after anterior gastro-enterostomy. In 250 posterior operations in Czerny's clinic there was not one case of regurgitant vomiting. One hundred and seventy cases were button operations and 45 were by sutures alone (Peterson). Von Hacker had one instance of regurgitation in 60 posterior operations.

Operation by the Murphy Button.—Gastro-enterostomy may be quickly performed by the use of a large-sized Murphy button. Murphy says that in some reported cases the button has slipped back into the stomach, but this accident can be prevented by the use of an oblong button and by making the anastomosis on the posterior stomach-wall. The same surgeon advises us to scarify the peritoneum to hasten union, and says supporting sutures about the button are not required, except when considerable tension exists. There is no question that an anastomosis on the anterior wall, accomplished by a Murphy button, can be speedily performed. Anastomosis on the posterior wall cannot be so performed speedily, and it sacrifices to some extent the great advantage

of the button operation—that is, speed. In spite of the reported cases, we can positively assert that the danger of the button producing grave trouble is slight. In some cases it drops into the stomach and remains there, but seems to do no harm. In other cases it takes a long time to pass. In one of the author's cases it did not pass until the eighty-sixth day. If it does not pass in two or

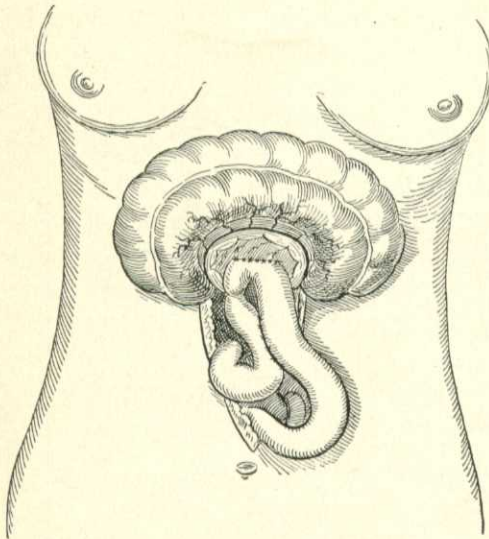


Fig. 412.—Fowler's method of gastro-enterostomy.

three weeks, the rectum should be explored with the finger from time to time to see if it is lodged there. The *x*-rays may determine whether the button is in transit. If the wall of the stomach is thick, the incision should be made in the stomach-wall before the suture is passed, and this suture should pick up only a small portion of the stomach-wall, otherwise the button may be retained in place for a very long time (Wm. J. Mayo). "In many cases in which the button passes, vomiting with symptoms of obstruction may appear in the second or third week while it is in transit. Gastric lavage and rectal feeding for a day or two cause these symptoms to subside" (Wm. J. Mayo, in "Annals of Surgery," Aug., 1902). Mayo considers the suture operation as good as the button, and thinks the results are about the same. Mikulicz says that in the suture operation entero-anastomosis is necessary, but not in the button operation,

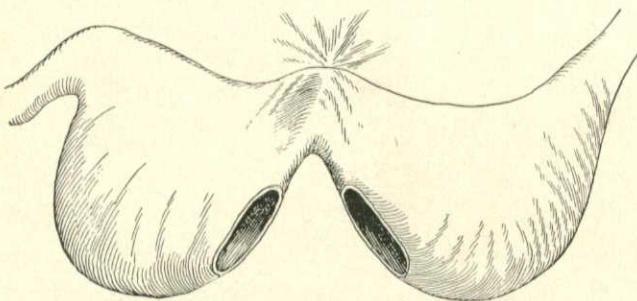


Fig. 413.—Wölfler's method of gastrogastrostomy for hour-glass stomach, showing the anastomotic openings.

because the button while in place prevents angulation. The last-named surgeon uses the button in malignant cases and the suture in benign cases. Czerny is an advocate of the button. Every button should be tested before it is used. Mayo finds nearly 20 per cent. of buttons imperfect and dangerous.

Fowler's Method (Fig. 412).—Anastomose the posterior wall of the stomach to jejunum and do an entero-anastomosis between the afferent and efferent loops of jejunum. Pass a No. 20 silver wire two or three times around the afferent loop of jejunum and draw it sufficiently tight to occlude the lumen without strangulating the wall of the gut. The ends are twisted, cut short, rolled into a flat coil, the cut ends being in the coil. (See Geo. Ryerson Fowler on the "Circulus Vitiosus" following gastro-enterostomy, "Annals of Surgery," Nov., 1902.) This operation positively prevents the entrance of material from the duodenal loop into the stomach and also drains that loop.

Gastrogastrostomy is an operation performed for hour-glass contraction of the stomach, a condition which occasionally ensues on the healing of an ulcer. In this operation an anastomosis is effected between the pyloric and cardiac ends (Fig. 413). Wolfe, Watson, Wölfler, and Eiselberg have performed this operation. Weir and Foote maintain that double gastro-enterostomy, "tapping each sac," is a preferable procedure.* In some cases

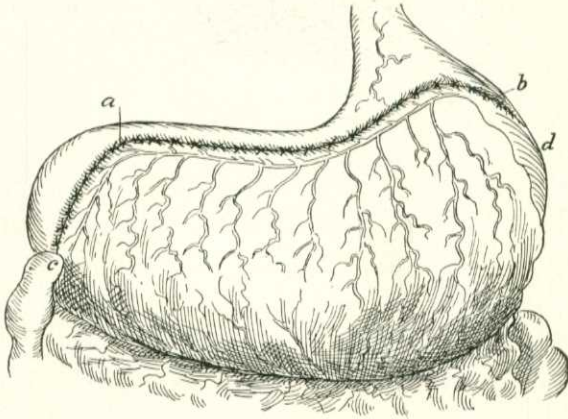


Fig. 414.—Bircher's method of gastroplication.

an operation identical with pyloroplasty can be performed (incision of the constriction in the direction of the long axis of the stomach and suturing vertically—gastroplasty). Watson folds the two stomachs over each other, using the narrow isthmus as a hinge; sutures the pouches together and leaves the ends of the sutures long. He incises the anterior wall of the anterior stomach in order to obtain access to the double septum between the two pouches. He makes an anastomosis opening through the double septum, sutures the edges and closes the wound in the anterior wall of the anterior stomach.

Gastroplication (Brandt's Operation of Stomach-reefing for Dilated Stomach).—Apply sutures in the anterior wall so as to form reefs, then tear through the great omentum and apply sutures in the posterior wall. The sutures pass through the serous and muscular coats. A continuous suture may be used on the anterior wall and another on the posterior wall,

* F. S. Watson, in Boston Med. and Surg. Jour., April 2, 1896; Weir and Foote, Medical News, April 25, 1896.

or numerous interrupted sutures may be inserted. This operation is of questionable value, and must never be used if stenosis of the pylorus exists, and stenosis of the pylorus is the most common cause of gastric dilatation.

Bircher's method of gastroplication is shown in Fig. 414.

Gastropexy (Duret's Operation for Gastroptosis).—It has been shown by Duret that dyspepsia of a peculiarly severe type may be produced by prolapse or downward displacement of the stomach. In this condition he advises the following operation: Perform a median laparotomy, but do not incise the peritoneum in the upper portion of the wound. Expose the stomach and fix it by means of a silk suture to the undivided but exposed peritoneum. The suture should be parallel to the lesser curvature and near the pylorus should be horizontal.* Duret's operation, the operation of Rovsing, and

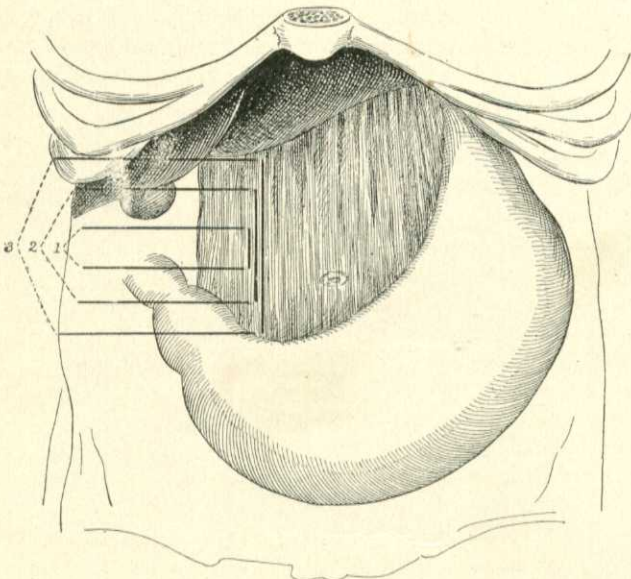


Fig. 415.—Beyea's operation for gastroptosis: 1, Position of one suture of first row; 2, one suture of second row; 3, one suture of third row. Others of each row introduced at intervals to and including the gastrophrenic ligament.

the operation of Hartman, fix and distort the stomach. Beyea has devised an operation which is free from this objection.

Beyea's Operation for Gastroptosis.—Insert three rows of interrupted silk sutures through the gastrohepatic omentum and the gastrophrenic ligament. Each suture is passed from above downward and the row begins at the right and passes to the left (Fig. 415). When the sutures are tied, a fold or plication is formed in the ligaments, the supports of the stomach are shortened, and the viscus is elevated to a normal position without any disturbance of its physiological mobility ("Univ. of Penna. Med. Bull.," Feb., 1903).

Duodenostomy and Jejunostomy.—It has been suggested that one of the above operations should be performed in a case of pyloric obstruction in

* Rev. de Chir., June, 1896.

which pylorotomy is not feasible. Duodenostomy is an easy operation because of the mobility of the pylorus and first part of the duodenum, and, it is not only easier, but is safer than jejunostomy, because it makes the fistula above the opening of the common bile-duct ("Bull. et Mém. de la Soc. de Chir. de Paris," No. 39, 1901). Cackove advocates the operation in some cases of gastric ulcer with repeated hemorrhages and some cases of gastric cancer. In the latter cases he asserts that the mortality is about the same as from gastro-enterostomy and the prolongation of life is greater ("Arch. f. klin. Chir.," Bd. lxx, Heft 2). Hartman's case of duodenostomy lived two months. The operation was performed for extreme cicatricial stenosis of the pylorus due to swallowing hydrochloric acid. Moynihan points out that if the operation is done at all the indication for jejunostomy is cancer involving the entire stomach or leather-bottle stomach. He operated on 2 cases. One lived one month and one seven weeks (B. G. A. Moynihan, "Brit. Med. Jour.," June 28, 1902).

Jacobson disapproves of both procedures, and objects particularly to duodenostomy, because it involves a portion of the intestine which is difficult to deal with, and because important fluids escape constantly from the fistula.*

The same author objects to jejunostomy because of the inevitable leakage of nutritive fluids.

Reported cases of duodenostomy and jejunostomy certainly do not indicate that the operations prolong life to any considerable degree.

Enterectomy, or Resection of the Intestine with Approximation by Circular Enterorrhaphy.—How much of the intestine can be removed without the patient dying from lack of nutrition? The question is not settled. It has been stated that the removal from an adult of more than six and two-thirds feet produces intestinal disturbance, and that a child tolerates the removal of a piece relatively larger better than does an adult. Certain it is that great lengths have been successfully removed, and the patients have not only lived, but have been well nourished. Ruggi removed eleven feet successfully. Hayes removed eight feet four and one-half inches from a boy of ten years of age, and the patient was well eight months later. Dressman reported 26 cases in each of which more than three feet three inches had been removed (Alexander Blaney, in "Brit. Med. Jour.," Nov. 16, 1901). Blaney adds 7 cases from literature, and tells us that in 9 of the 33 cases death occurred soon after operation.

Alexander Blaney, in the previously quoted article, reviews the subject of the resection of great lengths of intestine. He tells us that how much remains after a resection is important but uncertain. It is uncertain because, as Treves has shown, the length of the intestine varies from fifteen feet six inches to thirty-one feet ten inches.

Resection of the jejunum is much more dangerous than resection of an equal length of ileum. If resection is employed, all diseased or injured bowel must be removed irrespective of ultimate bad consequences (Blaney). The operation is performed as follows: After opening the abdomen isolate the loop of intestine we intend to resect. Push a rubber tube through the mesentery close to the bowel, above the seat of operation, and pass a rubber tube through the mesentery below the seat of operation. Empty this segment of bowel by squeezing and stroking, tighten the rubber tubes, and clamp them

* Jacobson's "Operations of Surgery."

to keep the bowel empty (Fig. 416). Instead of tubes, strips of iodoform gauze may be used to encircle the bowel. The diseased intestine is resected, each incision being carried through a healthy segment, and care being taken that the cuts are so arranged that at each end a blood-vessel from the mesentery reaches the edge of the cut bowel. Otherwise repair can scarcely occur. The lumen of each end of the divided gut is irrigated with salt solution. The divided surfaces are approximated by a double row of sutures—a continuous suture for the mucous membrane, and Lembert's, Dupuytren's, or Cushing's suture to effect inversion. Thoroughly satisfactory approximation can be effected by one row of Halsted sutures. If a redundant fold of mesentery is left, it can be stitched at its raw edge (Fig. 417). Many surgeons remove a V-shaped piece of mesentery and tie the divided mesenteric vessels (Fig. 416). The tubes are removed, and the wound is cleansed, closed, and dressed.

Senn effects invagination by means of a bone ring (Fig. 419).

If the two segments of bowel are unequal in size, the narrow part of the bowel should be cut obliquely and the larger part should be cut transversely.

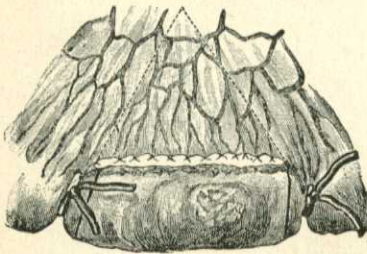


Fig. 416.—Excision of bowel; first step (Esmarch and Kowalzig).

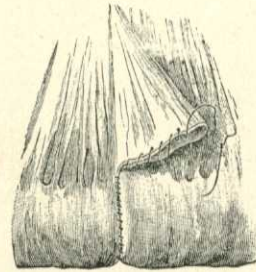

Fig. 417.—Excision of bowel with enterorrhaphy and stitching of the redundant mesentery; second step (Esmarch and Kowalzig).

To meet this complication Billroth devised lateral implantation. Suppose the cecum has been resected; its lower end is closed by Lembert sutures, an opening is made in the long axis of the colon opposite the attachment of the mesocolon, and the end of the ileum is sutured into this incision. This is called end-to-side approximation, or implantation. It is used in the sigmoid, in the cecum, and in any intestinal segment in which the circulation is deficient. Eugene A. Smith ("Amer. Med.," May 10, 1902) sums up the advantages of end-to-side approximation as follows: The strain of peristalsis is less than in end-to-end union; the circulation of each end of the bowel and the parts of bowel adjacent is better; each cut edge of mesentery is free to recover its circulation, and there is no dead space at the mesenteric border to lead to leakage.

Senn advises the insertion of an anastomosis-ring in the ileum, the invagination of the colon as the ring is pulled into place, and firm suturing of the line of junction. By Senn's method the ileum may be implanted into the end of the colon or into a slit in the wall of the large bowel after the end of the colon has been closed. In some cases, where one portion of bowel is larger than the other, lateral anastomosis is the preferable method. For a full week

after an intestinal resection the patient is fed chiefly by nutrient enemata. During the first twenty-four hours nothing is given by the stomach but bits of ice, and for the next six days but a little liquid food is allowed to be swallowed.

The use of Murphy's button permits of rapid approximation after resection (Fig. 418, *b* and *c*). This button closely approximates the portions of the intestine within its bite, rapid adhesion taking place. The diaphragm of tissue

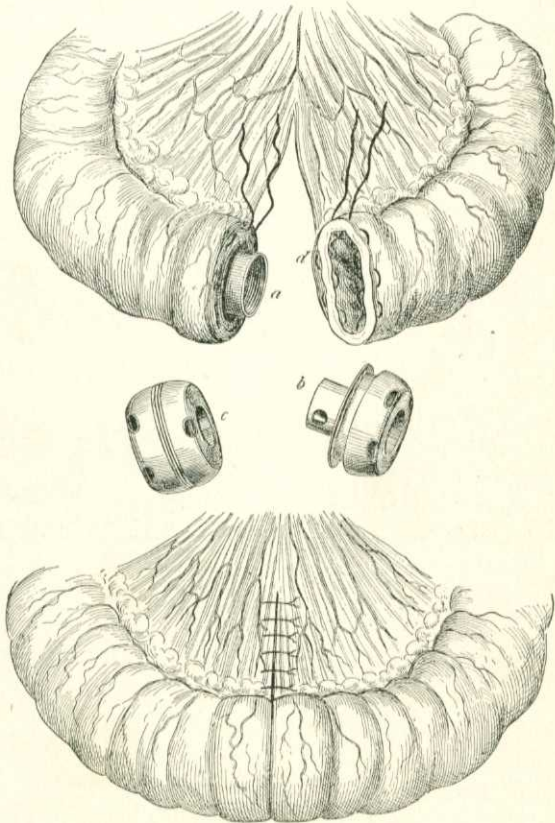


Fig. 418.—Resection of intestine: *a*, *b*, The two halves of the button; *c*, the two portions clamped together; *d*, introduction of the sutures for holding each half of the button in place. The lower figure shows the completed union of the intestine by the Murphy button; the slit in the mesentery has been closed by linear union (after Zuckerkandl).

undergoes pressure-atrophy, and liberates the button, which is passed per anum. It is claimed that the button-opening contracts but slightly. For end-to-end or side-to-side approximation of the small intestine a No. 3 button is used. For similar operations on the large intestine a No. 4 button is employed (Murphy). After the resection one-half of a button is inserted into each segment, and is held in place by a purse-string suture of silk which passes through all the coats (Fig. 418). The redundant mucous membrane is tucked in or clipped off, so that it will not be interposed between the serous surfaces. The

serous surfaces are scratched with a needle and the halves of the button are locked (Fig. 418). It is not necessary to surround the margin of junction with sutures.

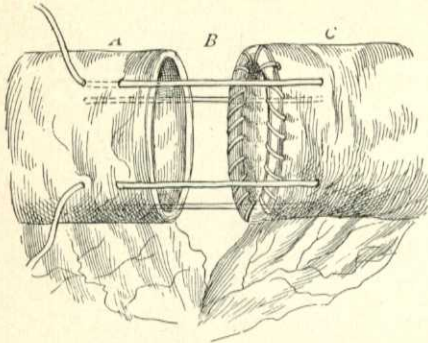


Fig. 419.—Senn's modification of Jobert's invagination method: *A*, Upper end lined with ring; *B*, invagination sutures in place; *C*, lower end.

Murphy says that liquid nourishment should be given as soon as the patient has recovered from the effect of the ether, and that the bowels should be moved at an early period, and frequent evacuations should be maintained. If the button does not pass in four weeks, examine the rectum for it.* The situation of the button can be ascertained by the x-rays. An objection to the button is that it introduces a

foreign body which must pass per rectum to complete the operation successfully. It may not pass, but trouble does not of necessity follow. But in some cases its retention leads to trouble, and obstruction ensues. If the caliber of the button blocks before dislodgment, obstruction follows; hence the rule to give saline purgatives the day after the operation.

Some surgeons have sought to make a button which would come apart and be absorbed after it had accomplished its purpose. The best of these appliances is Frank's coupler, which is made of bone, the compression being furnished by rubber. In this apparatus, however, the amount of pressure obtained is always uncertain and the rubber is apt to wear out. The button gives a lower mortality than the suture operation, and many surgeons now use it who once condemned it. Czerny is a strong advocate of the button.

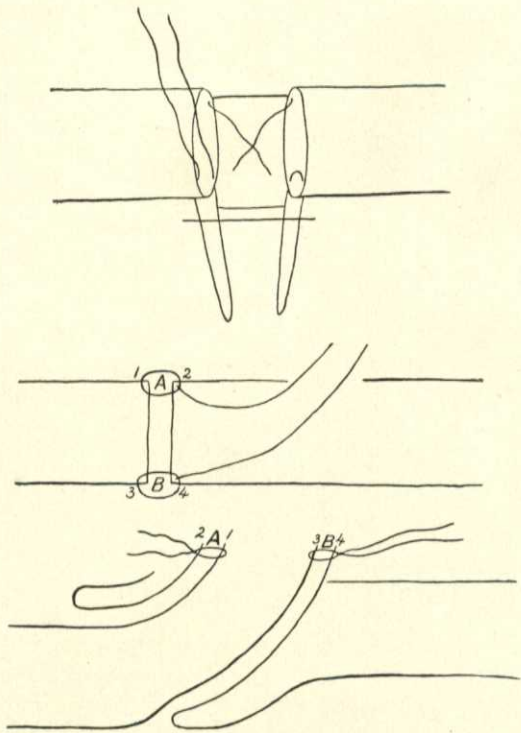


Fig. 420.—Maunsell's method of anastomosis (after Wiggin).

* John B. Murphy, in *Med. News*, Feb. 9, 1895.

After intestinal resection Halsted performs circular enterorrhaphy by means of his mattress sutures.

Maunsell has devised a most ingenious method of circular enterorrhaphy. The two portions of bowel are attached by two fixation sutures which penetrate all the coats (Fig. 420). An incision one and one-half inches in length is made through the wall of the proximal segment of gut, about one inch from its edge.

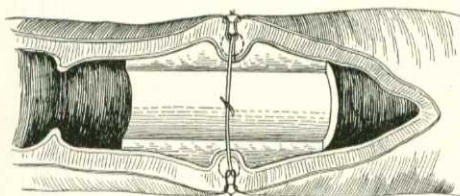


Fig. 421.—Robson's decalcified bone bobbin.

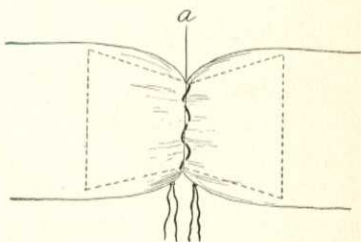


Fig. 422.—Allingham's decalcified bone bobbin.

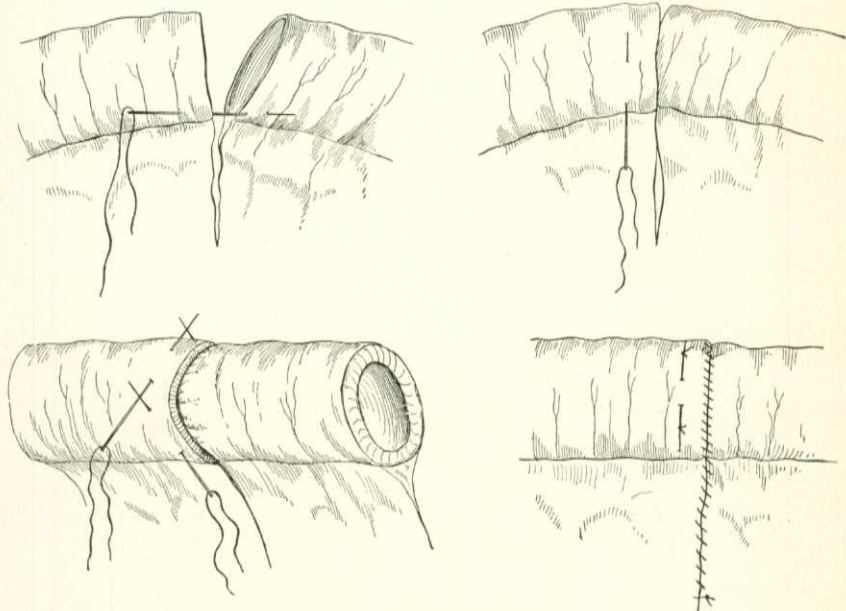


Fig. 423.—Harris's method of circular enterorrhaphy.

The fixation sutures are brought through this opening, traction is made upon them, the distal portion of the bowel is invaginated into the proximal portion, and the ends emerge from the opening, their peritoneal surfaces being in contact (Fig. 420). Sutures of silk are passed through both sides of the area of invagination, the threads are caught up in the center, cut, and tied on each side. The fixation sutures are cut off. The invagination is reduced by traction. The longitudinal cut is closed by Lembert sutures.

A. W. Mayo Robson performs circular enterorrhaphy and brings the ends of the gut together over a bobbin of decalcified bone (Fig. 421). Allingham uses a bone bobbin the shape of two cones joined at their apices. The bobbin is decalcified, except an area at the center (Fig. 422). Kocher performs circular enterorrhaphy as follows: A fixation suture is

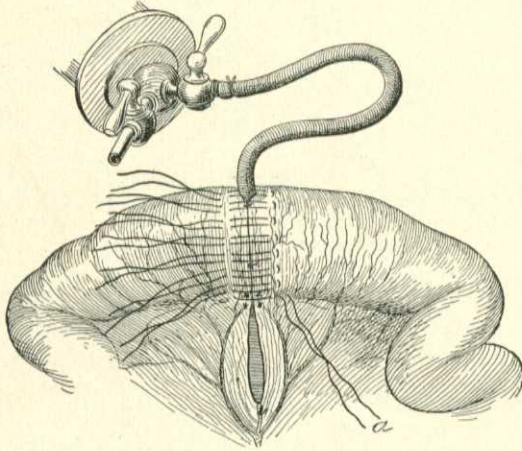


Fig. 424.—Use of Halsted's inflated rubber cylinder in circular enterorrhaphy.

introduced through the bowel at the mesenteric attachment and another is inserted at an opposite point. The intestinal ends are approximated by a continuous silk suture, which passes through all of the coats, but which includes more of the serous than of the mucous coat. The suture-line is overlaid by a continuous Lembert suture which includes the serous and a portion of the muscular coat. Harris removes a portion of mucous membrane from the distal end by means of a curet. Three needles are threaded with fine silk. The first needle is pushed through the bowel-wall to one side of the mesentery. The point of the needle picks up a portion of the distal end transversely. The needle is used as a lever to invaginate the distal end into the proximal end. The same procedure is carried out with the other needles. When invagination is effected the needles are

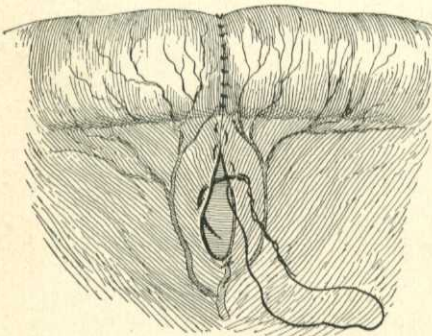


Fig. 425.—Suture of the mesentery after circular enterorrhaphy (Halsted).

pulled through and the threads are tied. The free end of the bowel is now sutured to the invaginated part by interrupted inversion sutures or by a continuous inversion suture broken once (Fig. 423).*

* Chicago Med. Record, Jan., 1897.

Some surgeons employ inflatable rubber cylinders in making an end-to-end anastomosis (Halsted, Downes, and others). The method was devised by Treves, but was subsequently abandoned by him. Halsted maintains that the use of the inflatable rubber cylinder enables the surgeon to finish the operation more quickly and to dispense with clamps; arrests the vermicular motion of the intestine; makes easy the adjustment of two pieces of intestine of unequal size; and renders it possible to apply stitches rapidly, evenly, and securely.* Three presection sutures are inserted; a portion of bowel and a V-shaped piece of mesentery are resected, the mesenteric incision being so made as to leave a vessel uncut at each edge to supply each end of the divided intestine. The mesenteric vessels are ligated and the ends

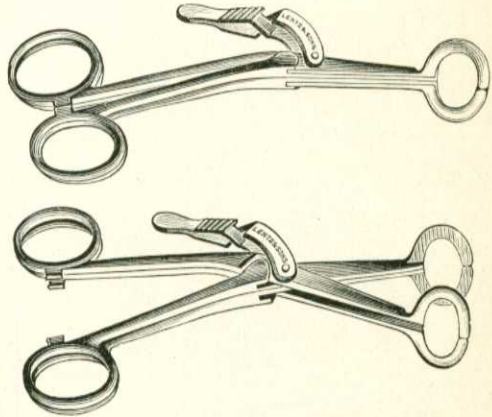


Fig. 426.—Laplace's forceps for intestinal anastomosis.

of the bowel are pulled together by the presection stitches, two of which are tied. The collapsed rubber cylinder is pushed into the bowel by means of forceps and is inflated with a syringe (Fig. 424). Twelve mattress sutures are inserted, the bag is collapsed and withdrawn and the sutures are tied,

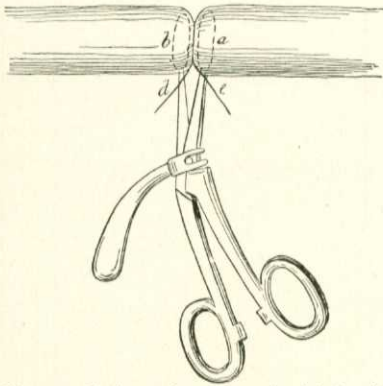


Fig. 427.—End-to-end anastomosis with the aid of Laplace's forceps.

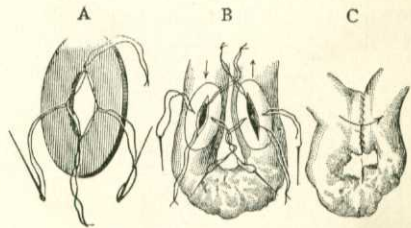


Fig. 428.—Senn's entero-anastomosis: A, Senn's bone plate; B, intestinal anastomosis; C, operation complete.

the stitch *a* being tied first (Fig. 424). The slit in the mesentery is sewed in such a way that the mesenteric vessels which nourish the bowel are not interfered with (Fig. 425).

Connell has devised a method which places the knots in the lumen of the

* Phila. Med. Jour., Jan. 8, 1898.

bowel (F. Gregory Connell, "Medicine," April, 1901). He maintains that the placing of the knots within the lumen of the gut has the following advantages: there is no foreign body; the suture passes away early; adhesions to

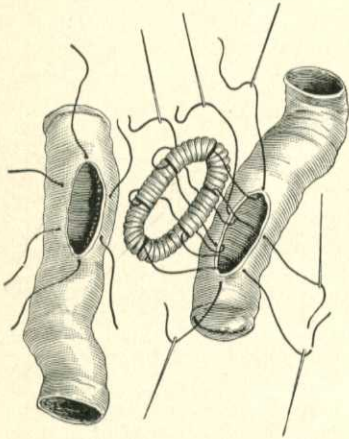


Fig. 429.—Method of passing the silk sutures in inserting the rings of Abbe.

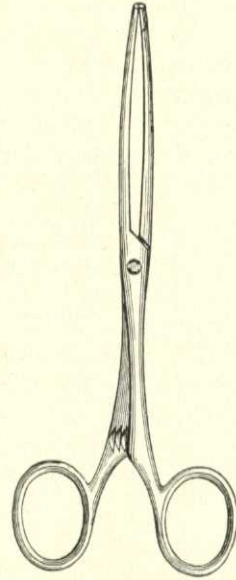


Fig. 430.—O'Hara's anastomosis forceps (about one-third original size).

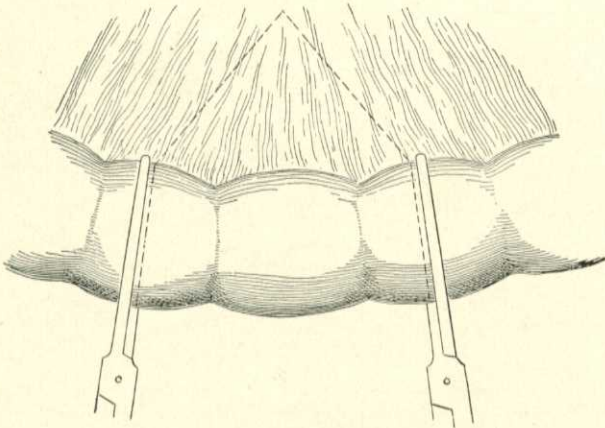


Fig. 431.—Showing the manner of placing forceps in resection of bowel; dotted lines show the incision to be made (O'Hara).

neighboring organs are few; the serous approximation is perfect; the suture line is more secure; the septum is smaller and the danger of necrosis is less. The suture is shown in Plate 9.

Laplace has devised forceps which greatly facilitate suturing, which make

it easy to obtain an even suture-line, and which can be withdrawn after the suturing is finished, the small opening through which the instrument emerged being closed with a stitch (Figs. 426, 427). By aid of Laplace's forceps the operation can be neatly and rapidly performed, but a large diaphragm is formed, a considerable area is exposed to infection, the tissues of the diaphragm are bruised and may slough, the raw ends may grow together and cause obstruction, and it seems probable that considerable contraction will follow. Another objection is that an infected instrument is withdrawn from the bowel

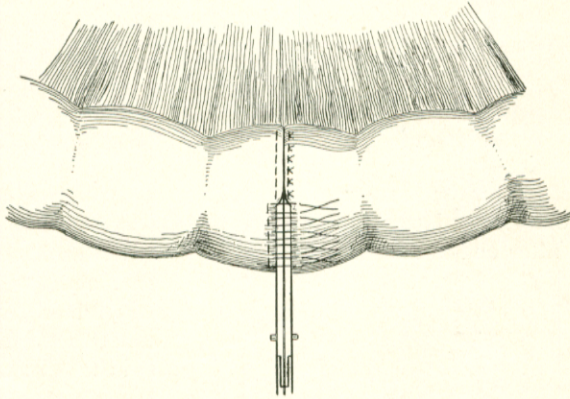


Fig. 432.—End-to-end anastomosis. Forceps brought together and held by serre-fine (not shown); sutures introduced, some of which are tied (O'Hara).

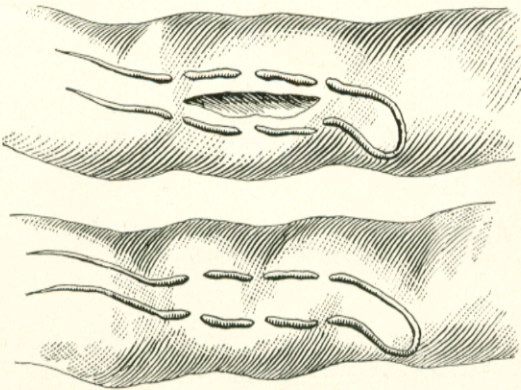


Fig. 433.—Showing relative size of incision and method of introducing sutures in lateral approximation with Murphy's button.

and may contaminate the peritoneum. O'Hara's forceps permit of rapid and accurate suturing, but possess the same disadvantages as the Laplace forceps. In one case within my knowledge absolute obstruction from adhesion of the raw edges of the septum followed its employment. Figs. 431 and 432 show the use of O'Hara's forceps. Of the operations previously set forth, I prefer the simple suture as employed by Halsted (although distention by an inflated cylinder is not a necessary adjunct) or the operation with the Murphy button.

Lateral Intestinal Anastomosis.—Approximation may be effected by other methods than by end-to-end junction or implantation. Lateral anastomosis may be practised after intestinal resection or may be done without pre-

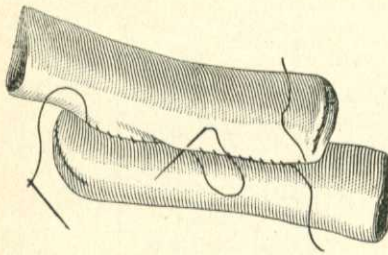


Fig. 434.—Suturing intestines in apposition before incision (Abbe).

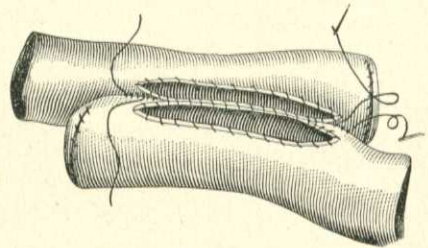


Fig. 435.—Showing the four-inch incision and sewing of the edges (Abbe).

liminary resection for the purpose of short-circuiting the fecal current to avoid an obstruction. After lateral anastomosis the parts obtain a better blood-

supply than after end-to-end suturing, because in the former operation the mesenteric vessels are not interfered with. Further, in lateral anastomosis there is little tendency to cicatricial contraction. It has the disadvantage that the diseased structure is not removed.

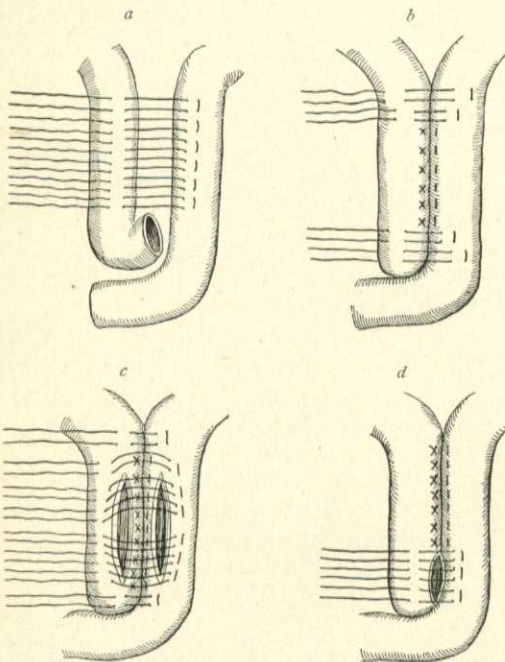


Fig. 436.—Halsted's operation for lateral anastomosis, showing four steps of same (Jessett, from Halsted).

Operation with Rings.

—In this operation a portion of bowel above the obstruction and a loop below the obstruction are brought into the wound. These segments are emptied, and are kept empty by fastening around them rubber tubes or iodoform strips. Two tubes are needed for each loop of bowel. Pack in gauze pads. Make an incision in one loop, in the long axis of the bowel, on the surface away from the mesentery; permit the contents to escape externally; irrigate

this segment with saline solution; and introduce the bone plate of Senn (Fig. 428, A) or Abbe's catgut ring (Fig. 429). Calyx-eyed needles are used to pass the silk, and the threads of the ring are carried through the coats of the bowel and are gathered together in the bite of a pair of forceps. The other loop of

intestine is treated in a similar manner. The two segments of intestine are so brought together that the two wounds are opposite each other, the posterior sutures being tied first, the upper next, then the lower, and finally the anterior threads. The ends of the threads are cut off and the entire anastomosis is surrounded by a layer of Lembert or Halsted sutures or is encircled by Cushing's suture. Fig. 428, B, shows an intestinal anastomosis partly finished, and Fig. 428, c, shows an anastomosis complete. Fig. 429 shows the passing of the sutures when the catgut rings of Abbe are employed. After an intestinal resection, each end can be closed and anastomosis effected as described above. Lateral anastomosis can be accomplished with a Murphy button, the intestine being prepared for the button as is shown in Fig. 433.

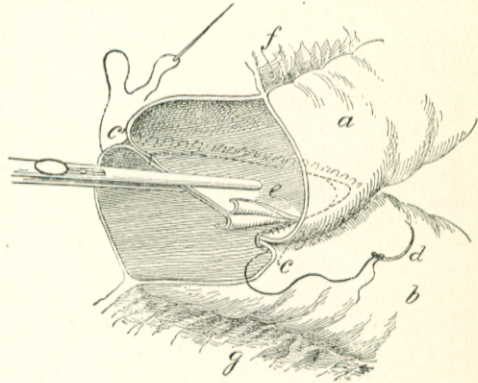


Fig. 437.—Represents the ends of the intestine in position and grasped by the artery forceps. The first row of sutures has been partially applied, the septum partly cut away, and the second row of overhand sutures begun. *a, b*, are the two ends of the intestine; *c, c'*, the first row of sutures (Cushing); *d*, the second row of sutures (overhand); *e*, the septum; *f* and *g*, the mesentery (J. Shelton Horsley).

Abbe's method of anastomosis without mechanical aid is as follows:

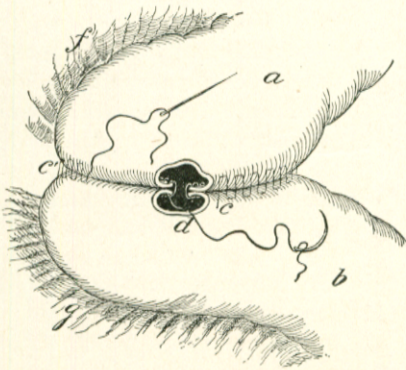


Fig. 438.—Operation nearly completed. The septum has been cut away, and the row of overhand sutures has been brought almost to its point of commencement. The cut also shows the first row of sutures (Cushing) as it should be continued after the overhand sutures are finished (J. Shelton Horsley).

After resecting the bowel and mesentery and closing the ends of the bowel he places the extremities side by side and applies two rows of a Dupuytren suture, one-quarter of an inch apart. These rows of sutures are an inch longer than the slit in the bowel will be (Fig. 434), the thread at the end of each row being left long. An incision is made in the bowel, one-quarter of an inch from the sutures, both rows of threads being on the same side of the cut. This incision is four inches long. The other portion of the bowel is then incised in the same way. The adjacent cut edges are united by a whip-stitch which goes through all the coats, and the free cut edges are stitched in the same

manner (Fig. 435). The surgeon now utilizes the long threads of the first sutures, and brings the serous surfaces of the opposite sides together by means of Dupuytren's suture. Halsted performs anastomosis as follows: He places

the two portions of bowel with their mesenteric borders in contact. Six quilted sutures of silk are introduced, tied, and cut off (Fig. 436, *a*). At each end of this row of sutures two quilted sutures are introduced, tied, and

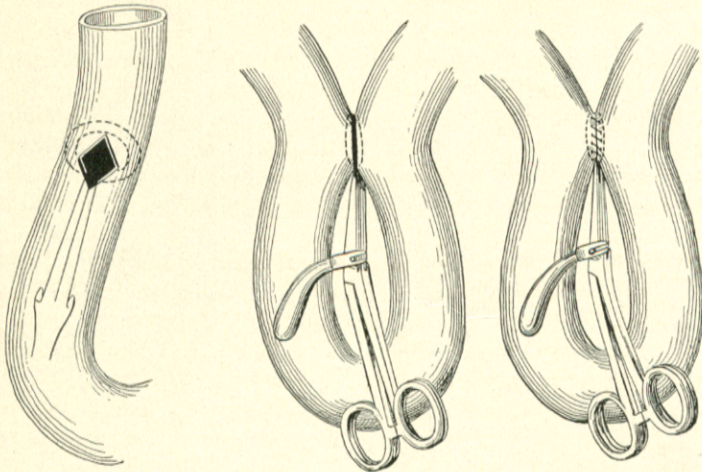


Fig. 439.—Lateral anastomosis with the aid of Laplace's forceps.

cut (Fig. 436, *b*). A number of quilted sutures are introduced, as is shown in Fig. 436, *c*. The intestinal openings are made with scissors, and the sutures last introduced are tied and cut off (Fig. 436, *d*).

J. Shelton Horsley has suggested an ingenious method of intestinal anastomosis which secures for the sutured portion a greater diameter

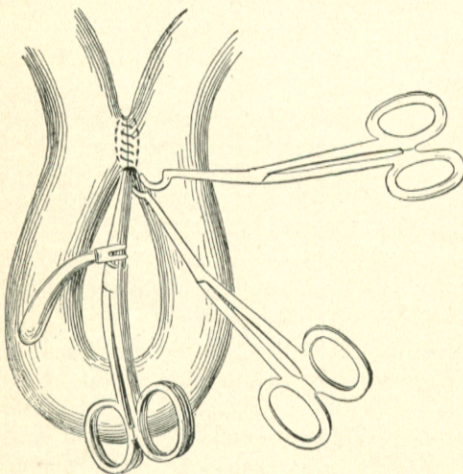


Fig. 440.—Withdrawal of Laplace's forceps.

than that normal to the intestine.* After resection of the intestine and a V-shaped piece of mesentery, the ends of the bowel are placed side by side, the openings being in the same direction, and are clamped in place (Fig. 437). The first stitch approximates the two limbs of the bowel near the mesenteric attachment, is carried obliquely for about two inches to the border opposite the mesenteric attachment, and continued over the other side (Fig. 437). The septum is cut away, a margin being left one-third of an inch wide. The

edge of the shelf made by cutting the septum is sutured. When the suture reaches the end of the shelf it is continued by invaginating the rest of the resected ends (Fig. 438).

* New York Polyclinic.

Bodine's method of intestinal anastomosis is referred to on page 818. Laplace, of Philadelphia, has devised an operation in which temporary approximation is effected by means of forceps, the instrument being withdrawn before the abdomen is closed. Junction of two segments of intestine can be quickly and neatly effected by this method and the suture line is even and secure. The objections are that an infected instrument is withdrawn from the bowel and may contaminate the surface; that the septum is tightly squeezed and this septum may slough, or may become infected, conditions which will be followed by infection of the suture line; and that contraction of the collar may ensue. The operation is more liable to be followed by leakage or by partial or complete obstruction than is the operation without forceps. Figs. 439 and 440 illustrate the use of Laplace's forceps in lateral anastomosis.

Consideration of Methods of Intestinal Approximation.—The best method of uniting a divided intestine is a matter of dispute. The Murphy button can be applied with great rapidity, and rapid operation is of immense importance in intestinal work. The opening left by the Murphy button is small (too small, some surgeons think), but it does not strongly tend in most instances to contract because the tissue-diaphragm is separated by tissue-atrophy and not by inflammatory gangrene. Occasionally the opening made by the button contracts and gives trouble; occasionally the lumen of the button blocks with feces; occasionally the button is retained, this latter complication being especially frequent after anterior gastro-enterostomy. If the button is used, liquid food should be given soon after the effect of the anesthetic has passed off, and movement of the bowels should be obtained at an early period after operation and frequent evacuations should be maintained. The button gives better results in end-to-end approximation than in lateral anastomosis. Laplace's forceps, O'Hara's forceps, the decalcified bone plates of Senn, the catgut rings of Abbe, the catgut strands inside of rubber tubing of Brokaw, Chaput's button, Allingham's bone bobbin, Robson's bone bobbin, Frank's coupler, Clark's bobbin, tubes or plates of potato and carrot, and rings or plates of leather, all have their adherents. Of mechanical appliances the best are Murphy's button, the bone ring, Laplace's forceps, and the inflatable rubber cylinder. Of recent years many surgeons have abandoned all mechanical aids, and have returned to closure by simple sutures. The ideal operation is without mechanical contrivances. But such devices are time-savers, and to lessen the time of operation will often save life. What method to follow must be determined in each particular case by a study of the necessities of the situation. Nevertheless, it may be possible to formulate a few general rules: If the condition of the patient is excellent and the bowel is in a fairly healthy condition well above and well below the seat of trouble, end-to-end approximation should be performed by simple circular enterorrhaphy. If the condition of the patient is such as to make haste necessary, use a Murphy button. If the bowel below the seat of trouble is much contracted, and haste is necessary, do not use a Murphy button, but use Senn's bone plate, or Robson's bobbin. If haste is not imperatively necessary, do simple enterorrhaphy. If the surgeon is obliged to join a very much distended bowel to a very much contracted bowel, perform end-to-side approximation (implantation)

with the bone plate of Senn, by simple suturing, or else effect side-to-side junction by the method of Abbe.*

Local Intestinal Exclusion.—This operation was introduced by Salzer in 1891. It excludes the fecal current from a portion of the intestine. In complete exclusion the intestine is cut through above and below the diseased portion and the ends of the healthy gut are united to each other or the end of one portion of gut is implanted into the side of the other. Both ends of the excluded portion may be fastened to the skin, making a double fistula (Von Eiselberg); the distal end or the proximal alone may be fastened to the skin, the other end being closed by sutures and replaced within the abdomen. Sometimes each end is closed and dropped back, and a fistula is made in the middle of the excluded portion to permit of drainage. Some operators close each end by suture and drop them back, and do not drain the excluded portion; and others aim at the same end by suturing together the two ends of the excluded part. It seems wisest to suture both ends, or at least

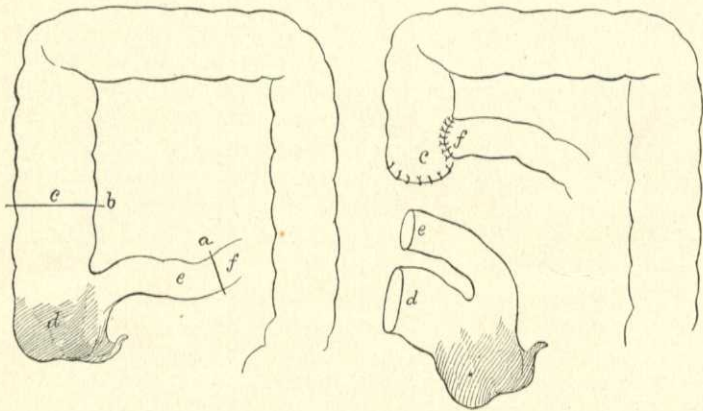


Fig. 441.—Operation of complete exclusion of the cecum: *a* and *b*, Lines of incision; *f* is implanted into *c*; *e* and *d* are sutured to the abdominal wall.

one end to the skin (LeDentu, in "Rev. de Gyn. et de Chir.," Jan. and Feb., 1899). It is true this makes a permanent fistula, but if it is not done the loop may become distended with secretion containing virulent bacteria, a condition which may lead to perforation and death. Exclusion is rarely performed upon the small intestine. It is best suited to the large intestine. If it is done at all, complete exclusion is the best operation (Fig. 441). Partial exclusion is rarely satisfactory. The operation has been done instead of colostomy in cases of intestinal obstruction, but it is best suited to inflammatory areas or tumors, irremovable because of adhesions or some other cause. After the operation the diseased area may improve because of drainage and freedom from irritant fecal matter. In many cases it can be irrigated through the fistula. Sometimes the diseased part improves sufficiently after a time to permit of extirpation.

* See the discussion of this subject by the late J. Greig Smith in his "Abdominal Surgery."

Surgical Treatment of Ascites Resulting from Hepatic Cirrhosis (Epioplexy).—The portal system communicates with the vena cava by means of a number of small vessels. Normally only an insignificant amount of portal blood passes by this route to the general circulation. When cirrhosis obstructs the flow of blood through the liver, the radicles of communication between the portal system and the vena cava enlarge and an increased amount of blood is thus sent direct to the systemic circulation. Adhesions develop between the parietal peritoneum and some of the viscera and the collateral circulation is further increased. Thus, Nature seeks to prevent ascites. If, however, the obstruction to the passage of portal blood becomes so great that “the collateral circulation is no longer able to maintain an equilibrium in the blood-pressure in the portal radicles, the pressure thus rises to a point at which transudation takes place and ascites develops” (M. L. Harris, paper read before Chicago Medical Society, Feb., 1902). The theory above set forth is the “mechanical theory”; but as Harris points out, increased portal tension is not the only factor concerned in the production of ascites, chronic inflammatory changes in the peritoneum being “materially instrumental” in maintaining ascites by lessening the absorbing power of the peritoneum. Influenced by the mechanical theory of causation, Talma, of Utrecht, devised an operation to cure ascites by establishing more free communication between the portal system and the systemic circulation. Drummond and Morison about the same time devised a like procedure independently.* In some cases the abdomen has been opened and the omentum sutured in the abdominal wound; in others, to the anterior abdominal wall (epioplexy). The gall-bladder may be sutured to the abdominal wall as well as the omentum. The liver and spleen, under surface of the diaphragm, and parietal peritoneum about the liver and spleen are usually rubbed harshly with a piece of gauze. Drainage is not to be used. It does not appear to contribute any favorable chances and it exposes the patient to the danger of infection.

The operation ought to be performed early, before the onset of chronic inflammation of the peritoneum. In a great majority of cases the operation proves futile, and not uncommonly death soon follows from complications or because the disease is very far advanced. In exceptional cases the operation proves of distinct benefit.

Harris, in the paper previously quoted, collected 46 cases. Twenty-three of these were instances of alcoholic cirrhosis. Thirty per cent. were dead within fourteen days; 52 per cent. were dead within two months; 56 per cent. were dead within six months. Of the late deaths, ascites had returned in all. At the end of one year or longer 13 per cent. had recovered from the ascites. The remaining 30 per cent. were either unimproved or were said to be improved with some ascites.

Of the group of mixed cases constituting the remainder of those Harris collected, 10 per cent. were dead in four days, 25 per cent. were dead in four months. In 40 per cent. no improvement took place. In 10 per cent. the report was too early to give any information. About 15 per cent. were free of ascites after one year or longer, and 5 per cent. were cured of intestinal hemorrhage, ascites never having been present.

* Brit. Med. Jour., Sept. 19, 1896.

Operation for Intussusception.—Air distention and hydrostatic pressure are uncertain; in an advanced case may rupture the gut; even in a recent case may fail or may reduce the bulk of the intussusception, but not its apex. Russell ("Intercol. Med. Jour. of Australasia," March 20, 1902) alludes to the uncertainty of the method. He used hydrostatic pressure in 5 cases. Two died and two recovered. In one case the method failed and operation was then performed. It is safer and better to operate early; but if the conservative plan is tried and fails, operation should certainly be done at once, because an early operation enables the surgeon to easily effect reduction, and also because early complications are unusual. The incision is made in the mid-line above the umbilicus. The surgeon endeavors by manipulation to reduce the intussusception by pushing it back, not by pulling it out. If the intussusception is gangrenous, perform intestinal resection and circular enterorrhaphy. The same rule maintains when malignant disease of the gut exists (D'Arcy Power). It is inadvisable to make an artificial anus. Maunsell's operation is suited to cases of irreducible intussusception. It is performed as follows: A longitudinal incision is made in the intussusciens. The intussusception is gently pulled upon and is caused to protrude from this opening. Two straight needles threaded with horse-hair are passed so as to transfix the base, and one-fourth of an inch above the needles the intussusception is cut off. The needles are carried completely through, the sutures are hooked up in the middle and cut, and the two ends are tied on each side. These sutures unite the intussusception to the intussusciens. The two surfaces are now carefully approximated by sutures. The sutures are cut. The stump is replaced. The longitudinal incision is closed with Lembert sutures.*

Russell reports 16 cases operated upon: 12 recovered and 4 died. In every one of the 4 fatal cases the diagnosis was not made until the disease had lasted several days. In 2 of the successful cases the diagnosis was made late ("Intercolonial Med. Jour. of Australasia," March 20, 1902).

Senn's Operation for Fecal Fistula.—Suture the opening transversely with Czerny sutures of silk in order to prevent infection. Cleanse the surface thoroughly. Open the abdomen and separate the edges of the bowel from the parietes. Deliver the portion of bowel which contains the fistula and apply Lembert sutures over the Czerny sutures. Another method is to open the abdomen above the fistula, insert the fingers, cut out the skin and tissues around the fistula in an elliptical course, leaving them attached to the bowel, draw the bowel from the abdomen, pack gauze around, remove the tissues adherent to it, and suture the fistula transversely (Hearn).

Enterostomy is the making of an artificial anus. If performed in the large bowel, it is called colostomy. In some cases of intestinal obstruction it is necessary to open the small intestine, and if this is required the artificial anus should be made as near as possible to the cecum. The nearer to the stomach it is made the more apt is the patient to die of lack of nourishment. The anus may be made in the middle line or in the right iliac region. The bowel is fixed and opened as directed under colostomy. In acute intestinal obstruction it may be necessary to open the bowel at once. In such a case Paul's tube is very useful. Paul's tube is made of glass, is bent to a right

* T. Pickering Pick, Quarterly Med. Jour., Jan., 1897.

angle, and has a rim near each end. The large tube is used in the colon, the small tube in the small intestine. A small opening is made in the intestine, the tube is introduced, and is tied in place by a silk suture which surrounds all of the coats of the bowel, a quantity of feces is caught in a basin, a rubber tube is fastened to the glass tube, and fluid feces are collected in a bottle under antiseptic fluid.* In from three or four days to a week the tube becomes loose and can be removed.

Inguinal Colostomy.—Maydl's Operation.—In this operation a vertical or oblique incision four inches long is made over the portion of colon to be incised. In all cases where it is possible, do a left inguinal colostomy. In right inguinal colostomy it is difficult to deliver the bowel as in Maydl's operation because of shortness or absence of mesocolon at this point of the colon. Right inguinal colostomy is occasionally performed for chronic amebic dysentery. It puts the colon at rest and permits of free irrigation. It is kept open until the dysentery is well (Francis W. Murray, "Annals of Surgery," May, 1901). It has also been employed for the treatment of ulceration of the colon. After the incision on the left side the colon usually bulges into the wound, but if it does not it may easily be found by following with the finger the parietal peritoneum outward, backward, and inward, the first obstruction it encounters being the mesocolon. Draw the colon out of the wound until its mesenteric attachment is level with the abdominal incision. Push a glass bar through a slit in the mesocolon near the bowel, and wrap the ends of the bar with iodoform gauze to prevent slipping. Instead of the bar, a piece of gauze can be employed, or a bridge of skin can

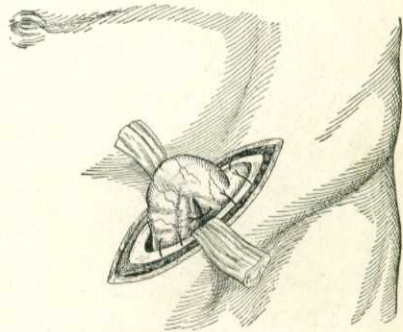


Fig. 442.—Inguinal colostomy (after Zuckerkandl).

be made under the bowel by suturing the two skin edges. The two parts of the flexure are stitched together by sutures which penetrate to and catch the submucous coat (Fig. 442). Stitch the serous coat of the bowel to the parietal peritoneum. Whenever possible, wait from twenty-four to forty-eight hours before opening. The colon is opened by the cautery or by scissors. If the artificial anus is to be permanent, make a transverse incision through the bowel. Cut one-fourth way through the colon when it is first opened, and entirely across at a later period. If the artificial anus is to be temporary, the incision is longitudinal. Maydl's operation has great advantages; it is quick, certain, reasonably safe, satisfactorily prevents fecal accumulation below the opening, and is rarely followed by absolute fecal incontinence. In many cases the bowels move but two or three times a day. The movements, however, come quickly with but little warning. Sometimes there is no warning. If diarrhea develops, there will be fecal incontinence as long as it lasts. An air-pad covered with gauze and held in place by a firm belt is the best form of permanent apparatus to wear.

* Paul, in *Liverpool Med.-Chir. Jour.*, July, 1892.

Bodine's Operation.—Bodine's method of colostomy permits of a future restoration of the fecal current by an easily performed anastomosis. This surgeon maintains that the spur after colostomy should reach to and remain at the level of the skin, a condition impossible of attainment by hanging the bowel over a rod or piece of gauze, because a spur thus formed is not thick and rigid and is inevitably dragged below the skin-level, and when this dragging has taken place some fecal matter will pass into the bowel below the artificial anus. Bodine opens the abdomen, sutures the parietal peritoneum to the skin, seeks for the lesion, and draws it with six inches of healthy bowel out of the incision. He lays the limbs of the loop side by side. He inserts a silk stitch, beginning at the point where exsection is to be made, and for six inches unites the two segments close to their mesenteric borders. The loop

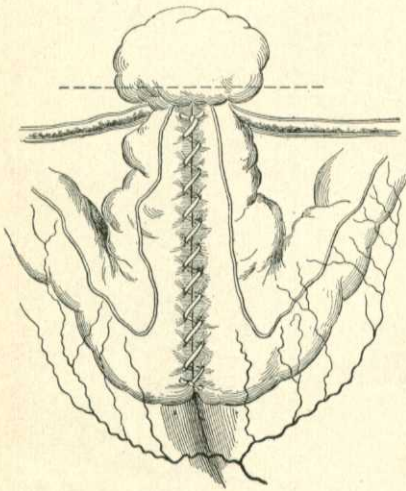


Fig. 443.—Bodine's method of colostomy, showing one side of the loop after it has been sutured, passed back into the cavity and stitched into the abdominal wound. The lesion is left protruding, and the dotted line indicates where the protrusion is to be clipped off.

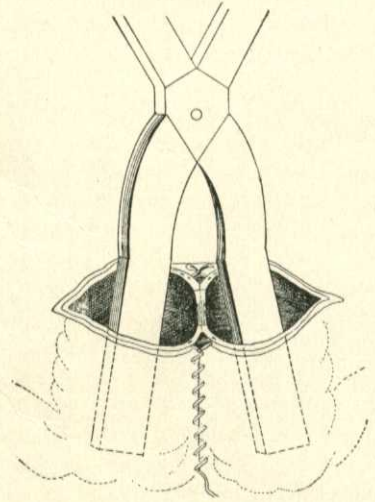


Fig. 444.—Bodine's method of colostomy, showing the septum to be divided in restoring the fecal current; Grant's clamp in position for the division. (In permanent colostomy this septum remains as a rigid and effective spur.)

is dropped into the abdomen until the beginning of the suture is on a level with the skin, and at this point it is fastened to the abdominal wound with a continuous catgut suture. The protruding lesion is cut off along the dotted line (Fig. 443). The artificial anus is thus established. When it is desired to close the artificial anus, divide the septum with scissors or a Grant clamp, and close the abdominal wound (Fig. 444).*

Lumbar Colostomy.—Lumbar colostomy is a most unsatisfactory operation. It does not completely intercept the fecal current, and leaves the patient in a condition of wretched discomfort because fecal incontinence is inevitable. A patient who has had lumbar colostomy performed upon him either gets no benefit because the feces pass into the bowel below the opening which was made to intercept them or else they pour out of the opening un-

* New York Polyclinic, Feb. 15, 1897.

controlled, making the poor unfortunate a living horror to himself and others. It is rarely performed at the present day.

The Incision for Operations upon the Gall-bladder and Bile-ducts.—I have employed several methods, but am most content with Bevan's incision (Fig. 445). The primary portion of the incision is shaped like the italic letter *j*. It is by the side of or through the right rectus muscle, and is shown by the double line in Fig. 445. The primary incision is used for exploration and cholecystotomy. The primary incision is from three to four inches long, and the extended portions, shown by heavy lines in Fig. 445, are added if required (Arthur Dean Bevan, "Annals of Surgery," July, 1899). This incision gives most satisfactory exposure, its edges can be separated without tension, and it injures but few of the nerves of the abdominal walls.

Cholecystotomy is the operation of opening the gall-bladder in order to remove gall-stones or secure drainage. It is performed in cases of acute cholecystitis; in hydrops of the gall-bladder; in gall-stone cases in which jaundice has lasted for four weeks or more, and in colic of the gall-bladder with fever, the colic having recurred a second or third time (Carl Beck). The operation completed in one stage is performed as follows: The patient is placed recumbent with a sand-pillow under the back. Bevan's incision is made (Fig. 445). The peritoneum is opened. If the gall-bladder is distended, it is surrounded with pads and aspirated, and is then opened. Gall-stones are removed by forceps, the scoop, or irrigation. The gall-ducts are examined by the fingers external to them, and are sounded, if possible.

If a stone is wedged in the duct, try to manipulate it back into the gall-bladder. If this fails, introduce an instrument from the gall-bladder and break up the stone; if this fails, open the duct, remove the stone, and close the incision in the duct (A. W. Mayo Robson). The only way to be certain that stones have been entirely removed from the cystic duct is to insert a finger and dilate. Sounds are unreliable. After the removal of all stones and fragments pass a rubber tube which has no side perforations into the gall-bladder, cut it off level with the cutaneous surface, purse up the cut in the gall-bladder around the tube by means of a catgut suture, and suture the gall-bladder to the abdominal aponeurosis. If sutured to the skin, a permanent biliary fistula is apt to follow. It will seldom follow if the gall-bladder is sutured to the aponeurosis. The drainage-tube can usually be dispensed with in from one

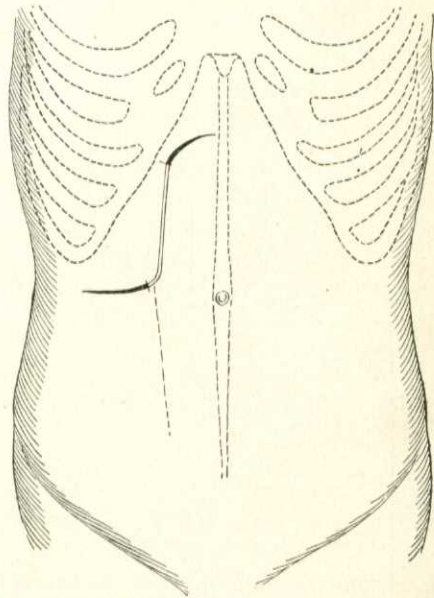


Fig. 445.—Incision for the surgery of the bile-tracts (Bevan).

week to ten days. It should not be dispensed with until the bile becomes sterile.

Some surgeons have advocated immediate suture of the gall-bladder after removing a stone. This is not advisable, because small calculi may be in the ducts, and minute fragments of stone are often left in the bladder, and the drainage will remove them and relieve the diseased condition of the gall-ducts and bladder. Further, the operation with immediate suture is decidedly more dangerous.

It is advised by some that the operation of cholecystotomy be performed in two stages. First, the bladder is exposed and sutured to the parietal peritoneum. When adhesion takes place the gall-bladder can be opened without risk of infecting the general peritoneal surface. Riedel advocates operation in two stages, and so did Christian Fenger in certain cases. The two-stage operation is objectionable because it does not permit of satisfactory exploration of the ducts. The fistula which is left by cholecystotomy usually closes spontaneously, but may not. If it does not close and the secretion is pure mucus, it is evident that the cystic duct is absolutely blocked and cholecystotomy should be performed.

If the secretion from a fistula is bile and the common duct is not obstructed, separate the edges of the gall-bladder opening from the parietal peritoneum, endeavoring to avoid entering the abdominal cavity, and close the fistula with Lembert or Halsted sutures. If the secretion is bile and the common duct is obstructed permanently, perform cholecystenterostomy. In 214 cases of cholecystotomy for stone in the gall-bladder, in the cystic duct, or both, Mayo had 2 deaths (Wm. J. Mayo, "Annals of Surgery," June, 1902).

Cholecystenterostomy consists in making an anastomosis between the gall-bladder and intestine, preferably the duodenum. It is employed in cases of irremovable obstruction of the cystic or common duct. It is done chiefly in cases of malignant obstruction. It is not a suitable operation for gall-stones impacted in the common duct because it does not remove the cause of trouble, infection of the bile-passages is apt to follow, and the fistula is liable to contract. In those rare cases of common duct obstruction from gall-stones, in which the gall-bladder is distended and the patient is desperately ill, it may be done (Robson). In such a case Robson attaches the gall-bladder to the colon because the operation is easier and because he considers it as useful as the attachment to the duodenum. Cholecystenterostomy can be done most rapidly and successfully by means of a small Murphy button. Before the gall-bladder is incised it is aspirated. The operation is shown in Fig. 446, and is similar in performance to intestinal anastomosis.

Cholecystectomy is the extirpation of the gall-bladder. Its performance may be demanded by the existence of phlegmonous inflammation or gangrene, ulceration, "in chronic cholecystitis from gall-stones where the gall-bladder is shrunken, and too small to safely drain, and where the common duct is free from obstruction" (A. W. Mayo Robson), in empyema with greatly damaged walls, in fistula associated with irremediable obstruction of the cystic duct, the common duct being free, and in some wounds.

The peritoneum which covers the gall-bladder must be divided just below the liver, the gall-bladder is dissected from the liver until the cystic duct is

reached, the duct is ligated with silk and divided, the stump is touched with pure carbolic acid and is covered with a layer of peritoneum fastened by sutures of fine silk. Wm. J. Mayo reports 33 cases of cholecystectomy with 1 death ("Annals of Surgery," June, 1902).

Removal of the Mucous Membrane of the Gall-bladder.—Mayo has suggested the removal of all the mucous membrane of the gall-bladder as an occasional substitute for cholecystectomy. A positive objection to the operation is that, as glands pass from the mucous coat to and through the muscular coat, it is impossible to absolutely remove the mucous membrane of the gall-bladder alone (Emil Ries).

Choledochotomy is the operation of incising the common duct for the

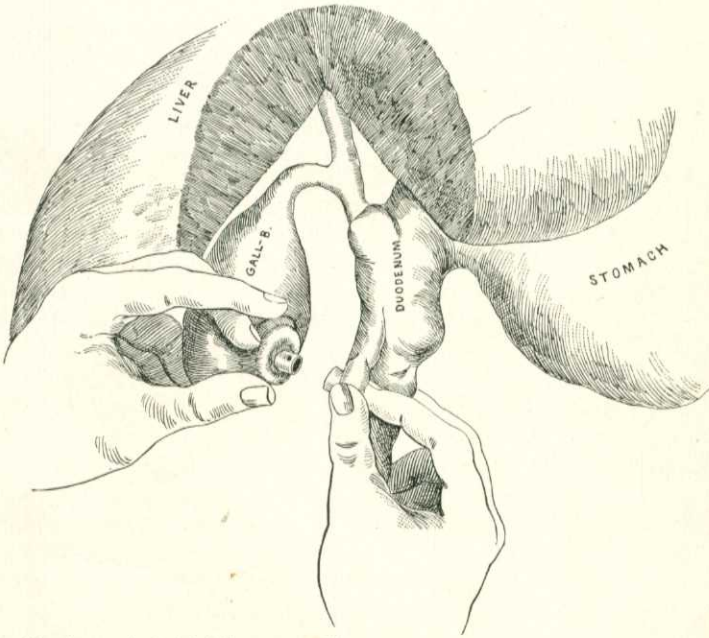


Fig. 446.—Showing method of holding parts while approximating a Murphy button in cholecystenterostomy.

removal of a stone. It is also called choledocholithotomy. It was first performed by Courvoisier in 1890.

Cases upon which this operation is done are often deeply jaundiced and there is grave danger of fatal oozing of blood. In one of my cases this happened. The patient was laboring under stones in the common duct, associated with cancer of the head of the pancreas. If jaundice exists, endeavor to prevent hemorrhage by employing Robson's plan: Give by the mouth from 30 to 60 grains of chlorid of calcium three times a day during the twenty-four or forty-eight hours preceding the operation, and 60 grains by enema three times a day for the forty-eight hours following the operation.

When ready to operate, a sand-bag should be placed under the lower ribs. This will bring the liver at least two inches nearer to the abdominal wound.

The abdominal incision must be longer than that employed for cholecystotomy. The pylorus and stomach are drawn to the left, the colon and omentum are drawn downward, and the liver and ribs are lifted strongly upward.

"The operator should now, after having separated adhesions, have a good view of the common duct within the free border of the lesser omentum, and on inserting his left index-finger into the foramen of Winslow, or on grasping the duct between the index-finger and thumb, he can, without difficulty, bring the duct well within reach, the concretion making a distinct projection."* A longitudinal incision is made, the stone is removed, and a probe is introduced into the duct to determine whether other stones are present.

If possible, suture the incision in the duct. This procedure is rendered easier by the use of Halsted's hammer, which draws the duct toward the surface and keeps it under control (Fig. 447).

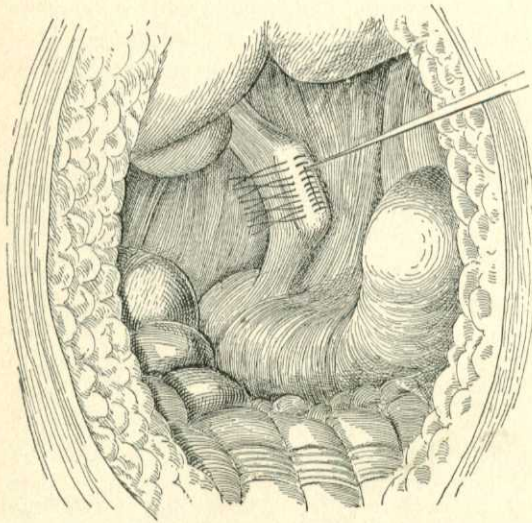


Fig. 447.—Suture of duct over Halsted's hammer.

Interrupted sutures of fine silk are used. The muscular and serous coats may be included in each suture, and over this layer Lembert or Halsted sutures are applied. A drainage-tube is inserted and a piece of iodoform gauze is placed upon the suture line, the other end being brought out of the abdominal wound. This precaution is taken because leakage may occur. If it is found impossible to suture the wound in the duct, carry a glass

tube down to the opening and surround it with iodoform gauze, or make an incision into the right loin after the plan of Rutherford Morison, and carry a tube into the right kidney pouch, which is the most dependent part of the peritoneal cavity when the patient is recumbent.

Robson ("Lancet," April 12, 1902) has performed the operation of choledochotomy sixty times. In 10 cases he manipulated the stone back into the gall-bladder and removed it through an incision in that viscus by means of a scoop. The above manœuvre is impossible unless the cystic duct is dilated. In 30 cases he crushed the stones between his finger and thumb, but this is only possible when the stones are soft, and it has the objection that it may leave fragments. If a stone is lodged in the common duct and cannot be manipulated back into the gall-bladder, choledochotomy should be performed. Robson's mortality in 60 cases of choledochotomy was 16.6 per cent. Since 1900 his mortality has been 7.1 per cent. Before that it was 23.8 per cent.

* A. W. Mayo Robson's "Treatise on Diseases of the Gall-bladder and Bile-ducts."

Duodenocholedochotomy (*McBurney's Operation; the Transduodenal Route*).—In 1891 McBurney proposed this method for the removal of gallstones impacted near the papilla ("Annals of Surgery," Oct., 1898). McBurney's original suggestion was to open the duodenum, dilate or incise the papilla, remove the stone, and suture the duodenum. When the stone is not impacted at the outlet, but is lodged a little higher up, and when dense adhesions render access by the ordinary supraduodenal route difficult or impossible, the anterior wall of the duodenum may be opened longitudinally, the posterior wall of the duodenum and the common duct incised over the stone, the stone removed, the duodenum and common duct sutured together (internal choledochoduodenostomy), and the anterior wall of the duodenum closed. (See Charles Otto Thienhaus, in "Annals of Surgery," Dec., 1902.) This last-mentioned modification of McBurney's operation was first performed by Kocher. Robson opposes the transduodenal route and says he has abandoned it because of the danger of sepsis. Thienhaus ("Annals of Surgery," Dec., 1902) opposes this view of Robson and shows that in 29 operations by the transduodenal route there were but 2 deaths.

Splenectomy.—This operation is performed for wounds and rupture of the spleen, cysts, floating spleen, and non-leukemic splenic hypertrophy. It should not be performed if leukemia exists. In 42 cases of splenectomy for leukemic hypertrophy collected by Février ("Rev. de Chir.," Nov., 1901) there were only 4 recoveries, and in 2 of these cases the nature of the trouble was doubtful. The same author states that during the preceding ten years splenectomy has been performed for malarial spleen eighty-six times, with a mortality of 17.4 per cent. It is to be noted that the operation does not cure the malaria. Février's statistics show 16 splenectomies for idiopathic enlargement of the spleen, with 3 deaths. In 46 splenectomies for rupture of the spleen there were 23 deaths (Février). The incision is from the anterior superior spine of the ilium to the ribs (Bryant). The peritoneum is opened. Adhesions are divided between ligatures. If the spleen is adherent to the pancreas, it may be necessary to remove a fragment of the last-named organ (Esmarch). Ligate the suspensory ligament and cut it. Bring the spleen well out of the wound. Surround it with gauze pads. Transfix the pedicle with stout silk. Tie it firmly, leaving the ends of the ligature long for a time, and cut through the pedicle beyond the ligature. Ligate the vessels separately with catgut. Cut off the long ends of the silk ligature and drop the pedicle back, unless apprehensive of bleeding, when it may be fastened to the surface. The wound is closed without drainage.

About two weeks after the removal of a normal spleen certain definite changes happen in adults but not in children. These changes last for several weeks and are manifested by enlargement of the lymph-glands, tenderness of bones, and blood-changes, loss of weight, weakness, thirst, polyuria, abdominal pain, elevation of temperature, and rapid pulse.* Tizzoni says that these changes are not obvious in children, because in them compensatory organs act at once, whereas in adults compensatory organs act slowly and with painful effort. Such symptoms are noticed when the spleen is removed because of a wound or a rupture, but rarely after removal of a diseased spleen. It is likely that compensating organs become

* Ballance, in Practitioner, April, 1898; H. Martyn Jordan, in Lancet, Jan. 22, 1898.

active when the spleen is diseased, and consequently are in full operation when such a spleen is removed. After partial splenectomy these conditions do not arise (Jordan). Changes can be prevented after splenectomy by the administration of tablets of extract of spleen and red bone-marrow (Ballance).

Abdominal Hernia or Rupture.—This condition is a protrusion of peritoneum containing at times or permanently any viscus or part of a viscus from the abdominal cavity. MacCormac says the term implies that the protruded viscus is covered with integument; hence a protrusion of viscera through a wound does not constitute a hernia. A hernia has three parts—the sac, the sac-contents, and the sac-coverings. The *sac* is formed of peritoneum. A congenital sac is due to developmental defect, and is found only in the inguinal or umbilical region. An acquired sac is due to intra-abdominal pressure bulging the peritoneal covering of an abdominal ring and converting it into a pouch. The sac comprises a body, a neck, and a mouth. A sac once formed is almost certain to persist, because it adheres by its outer surface to surrounding parts, and hence the sac of a hernia is usually irreducible even when the contents are reducible. The neck of the sac is due to the constriction through which the sac passes; it becomes furrowed and folded, and the adhesion of these folds causes thickening and rigidity. Hernia of the bladder or of the cecum may have no sac, or but a partial sac. The *contents of the sac* depend chiefly on the situation, a portion of the ileum being the usual contents. The colon, the stomach, the great omentum, the bladder, and other structures may enter the hernial sac. An *enterocele* contains only intestine; an *epiplocele* contains only omentum; an *entero-epiplocele* contains both omentum and intestine; a *cystocele* contains a portion of the bladder. The *coverings of the sac*, which vary with its situation, will be set forth during the consideration of special forms of hernia. In old herniæ the layers are never distinct, fat and muscle waste, tissues adhere, and the skin stretches and atrophies. The sac of an old hernia occasionally becomes tuberculous, and the disease may remain local in the hernial sac or spread to the general peritoneum. Renault tells us that *tuberculosis of a hernia* is made manifest by increase in size, pain on pressure, and loss of body-weight.

Causes of Hernia.—Hernia is a common trouble. According to Berger, in 1000 people 4.4 per cent. suffer from hernia. It occurs at all periods of life, and hereditary predisposition sometimes seems to exist. The male sex is three times as liable to hernia as the female sex. That increase of intra-abdominal tension is a common cause in children has been amply demonstrated. (See Hernia in Childhood, page 846.) Excessive length of the mesentery has been assigned as a cause. In some instances a mass of fat forms and advances before the hernia, and seems to bear a causative relation to it. Lucas-Championnière explains this as follows: when a person begins to take on fat, it is deposited not only under the skin, but also in the omentum, mesentery, and subperitoneal tissues. This semifluid fat is easily influenced by pressure. The deposit of fat within the abdomen lessens the size of that cavity, intra-abdominal pressure is increased, and fat protrudes at any weak spot in the wall. The protruding mass of fat adheres to and makes traction upon the peritoneum, and this membrane is drawn upon to form a sac, and the sac is surrounded by fat. This method of formation is frequently noticed in umbilical herniæ, and occasionally in inguinal herniæ.