

Heart Transplantation: Donor Operation for Heart and Lung Transplantation

Phillip C. Camp, Jr, MD

Procurement of thoracic organs in anticipation of subsequent heart and lung transplantation is often a second thought to most surgeons, lacking the dramatic environment associated with implantation and the resulting resumption of normalized function. However, transplant surgeons recognize that this first technical intervention begins a critical and time-sensitive cascade that is very much dependent on the precise, timely, and accurate actions of the transient organ preservation and anatomic dissection/resection. Added complexity is the need for a solid understanding of the needs of each transplanting cardiothoracic team by the other (heart, lung) to coordinate the preservation and allocate tissue margins fairly. Poor preservation at the time of procurement can lead to early graft dysfunction, or more critically, graft failure following implantation. Dissection between the organs being procured has several points that have a very small margin for error. A surgeon's lack of understanding of this aspect of the operation can severely and adversely impact the implantation of all thoracic organs and has led to the unplanned discard of thoracic organs following inattention to anatomic landmarks and intrusion into critical organ structures.

When first arriving at a center for planned thoracic organ procurement, there is a critical list of confirmations and verifications that must occur. Before beginning any clinical assessment, the donor must be properly identified using their United Network for Organ Sharing donor-specific ID as well as a second unique identifier, and then the ABO compatibility of the donor and recipient must be documented. Subsequently, the collection of donor-specific documentation must be reviewed to assure that the donor has met the local definition of brain death (if not donation after cardiac death [DCD]) and that appropriate consent for all specific thoracic organs and tissues has been obtained. Furthermore, the surgeon must carefully review the health information and data to assure that no previously unreported health issues (infectious disease, high-risk behavior, other relevant medical findings) are noted in the donor's information packet or were unappreciated by the local Organ Procurement Organization representative.

Immediately after completing the administrative duties of the procurement surgeon, the clinical status of the donor must be assessed, including current interventions and changes since the accepting thoracic team last reviewed the clinical data. Often the unique physiology of the organ donor is not fully appreciated by all members of the care team. Many procurements occur at smaller facilities or locations that do not frequently care for the organ donor. Fluid management and appropriate use and dose of cardiovascular agents must be discussed with the local providers to maintain stability and avoid potential complications. Hemodynamic monitoring should be continued in the OR, including blood pressure, central filling pressures, pulmonary artery monitoring (if available). Vasoactive medications should be titrated to maintain a normal mean arterial pressure, and overhydration should be avoided. Ventilation should provide 10 mL per kilogram with FiO₂ maintained at, or below, 0.50 if possible. Positive end-expiratory pressure (PEEP) should be continued at 5 to 8 mm Hg, and if the patient is taken off the vent, brief recruitment should occur. Coordination with the OR nursing staff about specific instrument needs and unique setup or orientation to your team's specific profusion arrangement should occur shortly after arriving in the OR.

Many abdominal transplant centers have protocols for donors that involve agents that may not be appropriate in the setting of thoracic organ procurement. Discussion of all planned interventions, use of protocols, and/or specific medications should be discussed before initiating the operation. Furthermore, clarification about the status of each of the intended recipients is important before initiating any operative intervention. In this age, many recipients have undergone previous surgery and it should be anticipated that additional time will be required for the implanting surgeon to provide adequate exposure for the intended implant. Most thoracic transplant surgeons prefer to delay induction of anesthesia for their recipients until the procurement surgeon has confirmed the appropriateness of the donor. This lowers the potential risk to the recipient but creates a need for subsequent time that must be understood, communicated, and coordinated by their procurement team. This in turn impacts each of the other procurement teams and their recipients. Good communication between all procurement teams can minimize donor organ ischemic time, lower the risk of a donor becoming unstable if open but "waiting," and is, frankly, polite.

Lung Transplant Program, Harvard Medical School, and Division of Thoracic Surgery, Brigham and Woman's Hospital, Boston, Massachusetts. Address reprint requests to Phillip C. Camp, Jr, MD, Division of Thoracic Surgery, Brigham and Woman's Hospital, 75 Francis Street, Boston, MA 02115. E-mail: pcamp@partners.org

The heart procurement surgeon should personally review the echocardiogram and coronary arteriogram. Although mild valvular disease and ventricular hypertrophy are not clinically significant in most patients, they can have a very important impact in terms of heart transplantation. Hypertrophy in the ventricle makes tissue preservation more difficult and postimplant function can be markedly reduced both from poor tissue preservation as well as from increased diastolic dysfunction due to tissue ischemia during preservation and transportation. Mild coronary artery disease is rarely clinically significant in the average patient. However, the milieu following transplantation promotes early and relatively rapid atherosclerotic coronary artery disease. As such, even "mild" disease may be appreciated in a more cautious manner by a transplant surgeon when considering the intended recipient.

The lung procurement surgeon should personally review all the chest imaging studies, check the most recent blood gas, and perform a flexible bronchoscopy to assure the airway is free of significant airway secretions and is not unduly in-

flamed or edematous and that there is no anatomic variation that could limit surgical implantation. One common mistake in evaluation of lungs for transplantation is confusing consolidation on imaging for infection rather than atelectasis. Bronchoscopy in the hands of an experienced surgeon can differentiate minor airway plugging, mucus from the upper airway, and purulent secretions that might be associated with a true lobar process. Anatomic variations are reportedly uncommon but it is our experience that they seem to be far too common when evaluating a donor. Nonsurgeons do not evaluate airway anatomy in terms of subsequent anastomotic risk; thus, the unique surgical perspective is important.

When the patient is positioned on the OR table, coordination with the anesthesia staff regarding what physiologic changes should be promptly communicated, and what the surgical teams will need to have done with deep central lines and the endotracheal tube, should be clearly stated. The OR table should be moved well down and away from the anesthesia devices to help accommodate the 6 to 10 surgeons, fellows, residents, and others.

Operative Technique

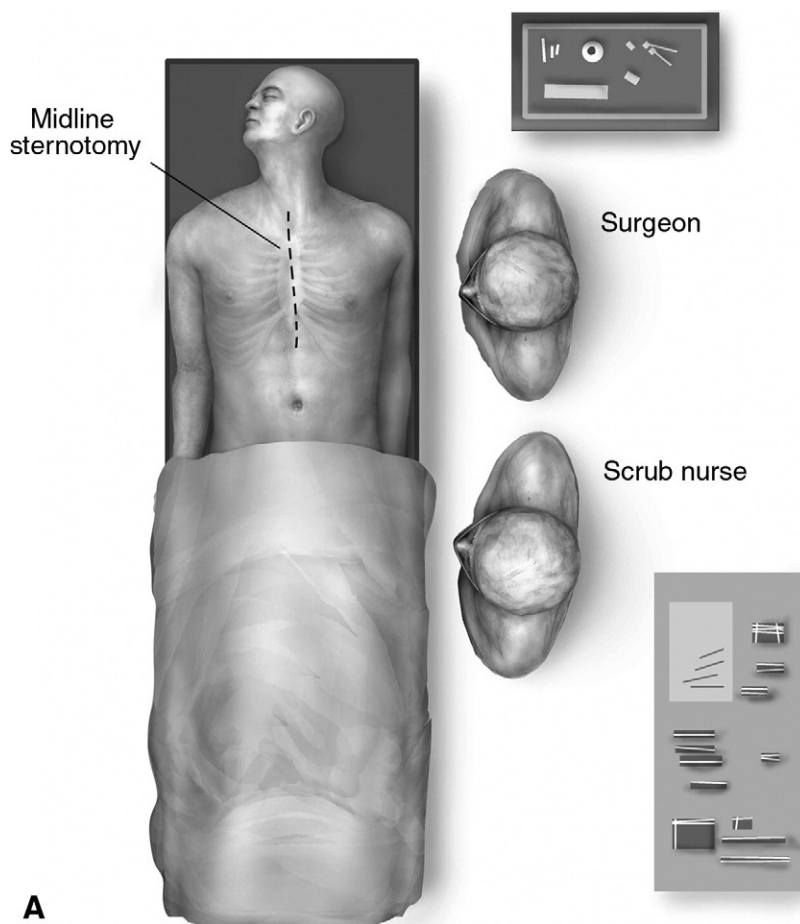
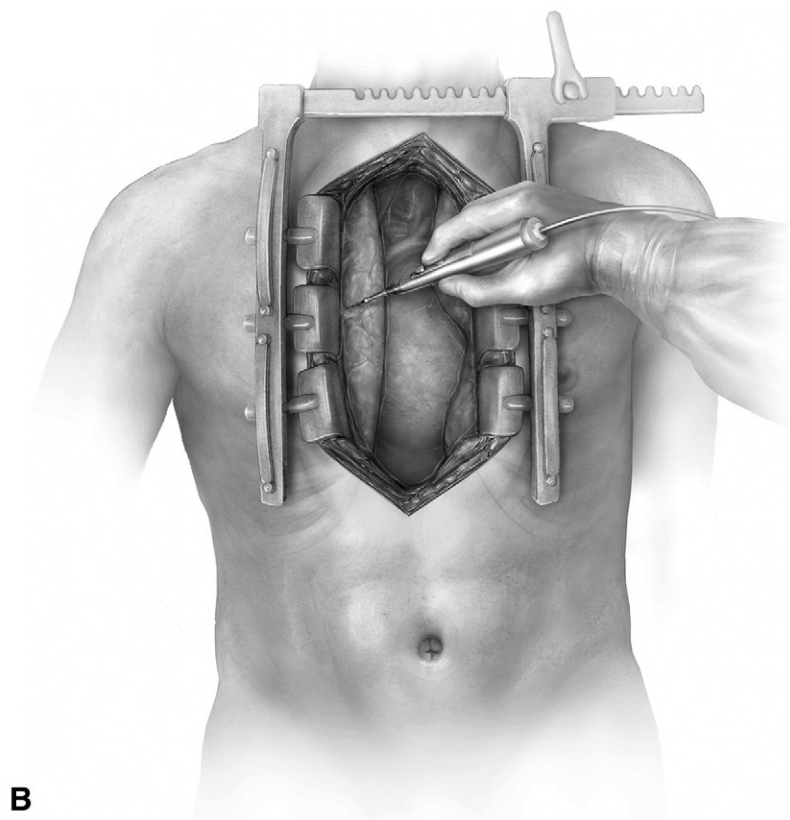


Figure 1 (A) The positioned donor is prepped and draped from chin to pubis with exclusion of all lines, wounds, etc. A generous median sternotomy is created in continuity with the abdominal midline incision created by the abdominal transplant team. Care should be taken at the inferior aspect to protect the liver from unintended injury. Local hemostasis is obtained with bone wax and electrocautery. (B) A sternal retractor with shallow or medium depth blades is placed upside down, however, to keep the crossbar out of the common working area between the chest and abdomen. Sponges or surgical towels along the sternal edge help keep the retractor from sliding as the reverse position otherwise often allows the device to migrate. The pleural reflections are opened along their entire length bilaterally. Both lungs are palpated to assure no unsuspected lesions are identified. The pulmonary ligament is not taken down at this point to avoid cardiopulmonary embarrassment.



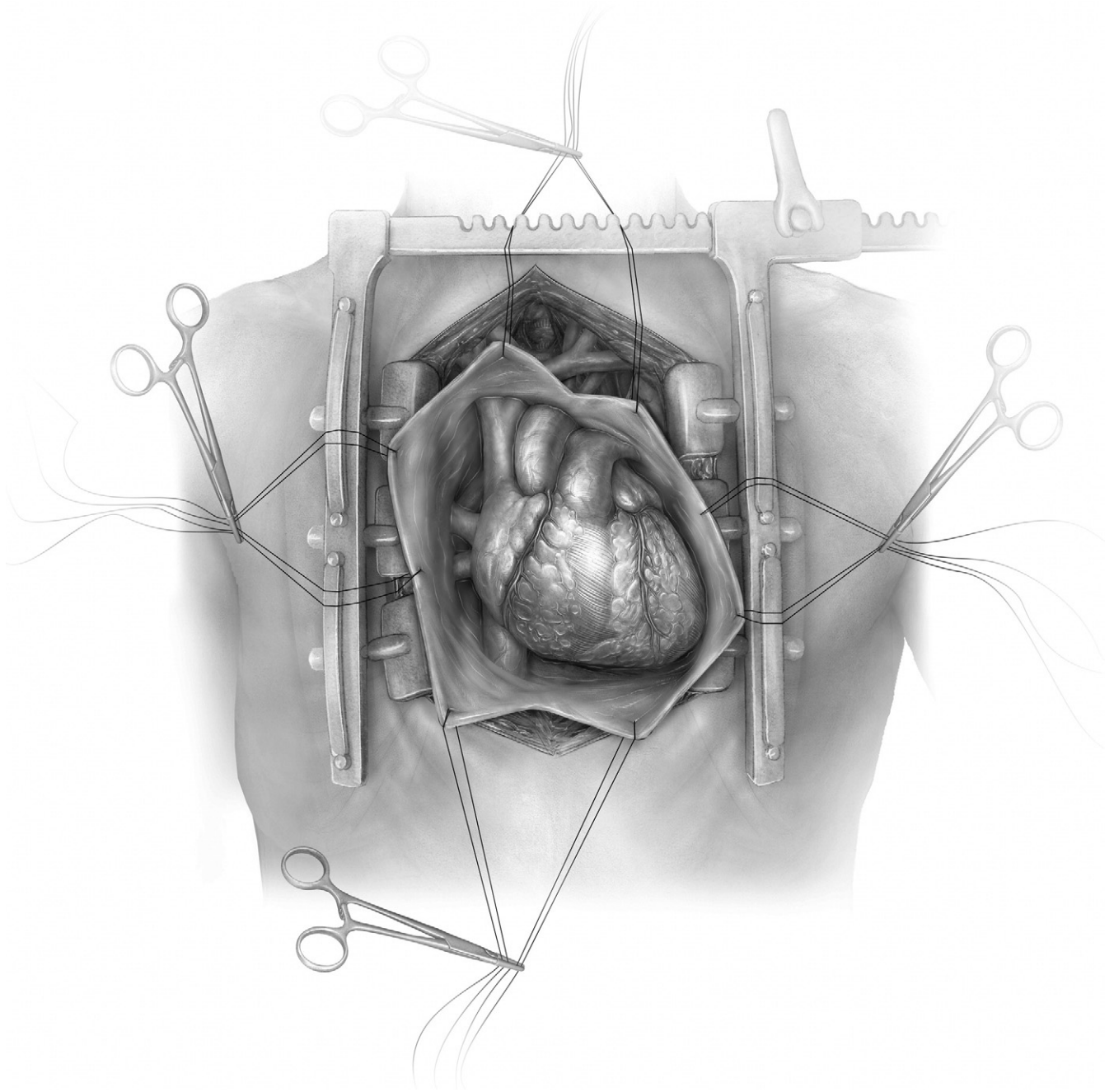


Figure 2 The pericardium is opened vertically from the diaphragm to its inflection at the ascending aorta or arch. Four to 6 silk retention sutures are placed into the pericardium bilaterally to create a pericardial well. When doing concurrent heart and lung procurement, the retention sutures should be left with 1 heavy snap on each side rather than secured to the chest tissue individually to allow easy transition to each of the thoracic working areas. The heart is inspected for function, chamber distension, coronary calcification, myocardial contusions, and other anatomic variations. It is important to communicate any cardiac manipulation with the anesthesia team in advance. Rarely is that individual/team well versed in cardiothoracic anesthesia. Without good communication, transient cardiopulmonary embarrassment can be misinterpreted and intravenous push medication inappropriately administered. (Many others only perform minimal dissection until the point that cardiopulmonary perfusion and preservation has occurred. Often the concern is that anatomic manipulation of the heart and related vascular structures can lead to hemodynamic instability. However, we believe that in the hands of an experienced surgeon this is not clinically a problem. Our practice is to complete the tissue dissection as completely as possible before heparinization and cannulation. The charged vascular structures are easy to define, allowing rather easy identification of important avascular planes. It is also a much more efficient use of time during the typically longer operative dissection required by the abdominal teams.)

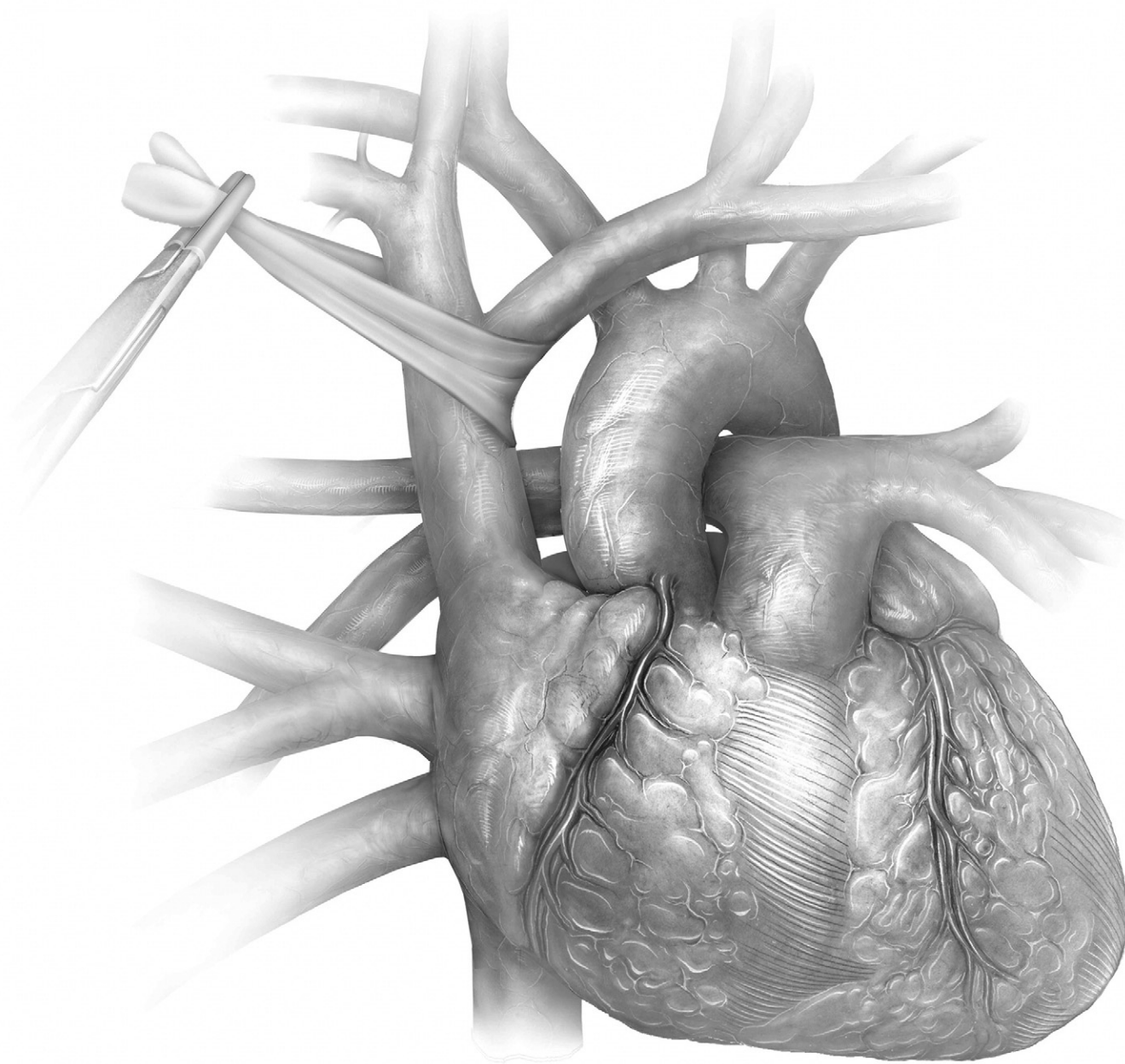


Figure 3 Sharp and electrocautery dissection is used to mobilize the aorta from the main pulmonary artery. The aorta should be proximally dissected such that the right pulmonary artery is completely free and visible from the mobilized ascending aorta. However, care should be taken at this point not to mobilize more proximally into the root to avoid injury to the coronary arteries. Continue mobilizing the ascending aorta so it is completely free of the pulmonary artery. Subsequently expose the anterior aspect of the aorta, arch, and great vessels. The innominate vein is mobilized off the arch carefully, which allows for excellent exposure of the great vessels. Once the arch is dissected, mobilize the pulmonary artery at the point of the bifurcation of the right and left side.

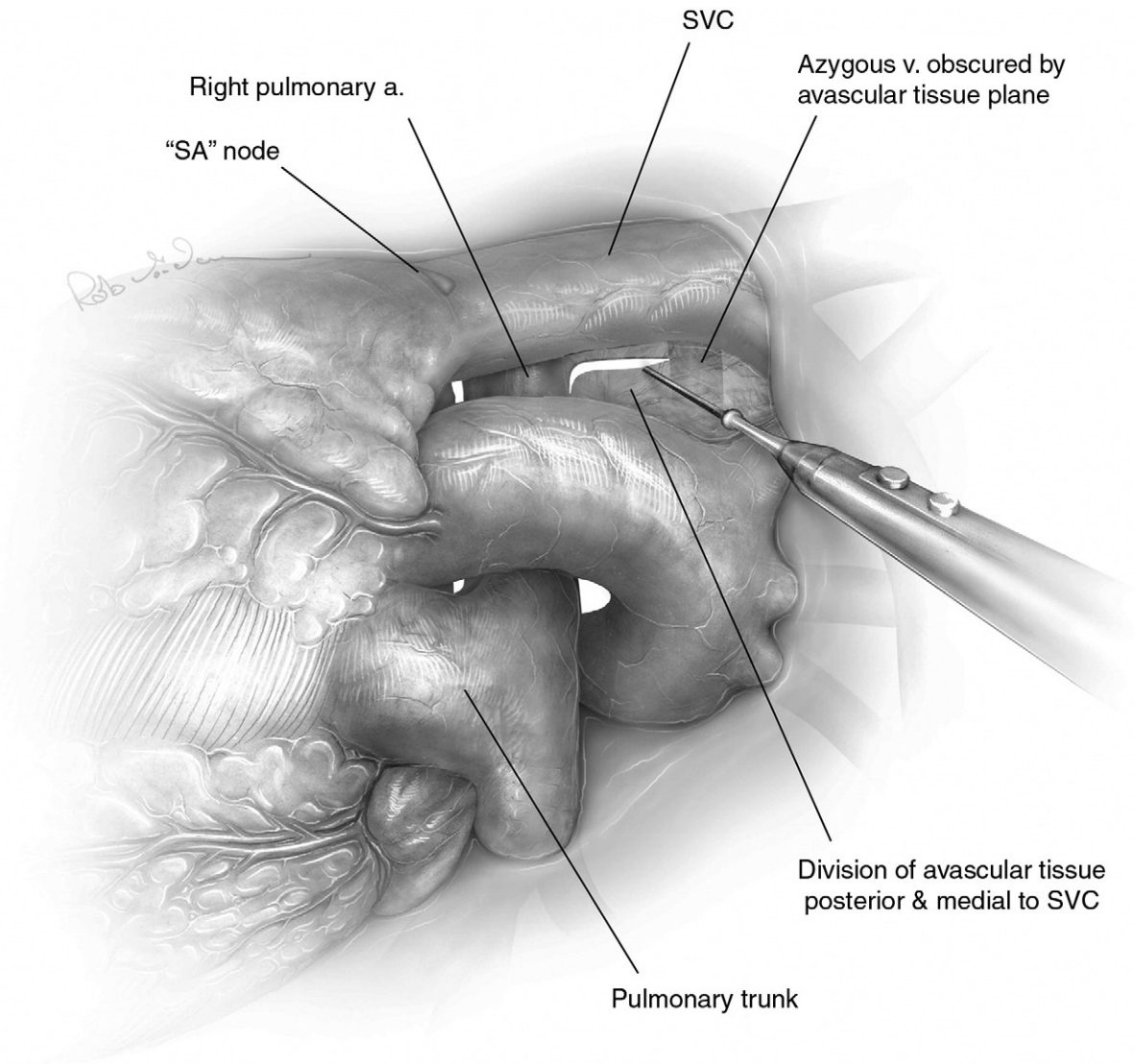


Figure 4 With care not to instrument the periauricular tissue of the right atria, and with it the sino-atrial (SA) node, grasp the superior vena cava (SVC) with forceps and distract laterally. Incise the reflection, starting first at the right pulmonary artery, which should be easier to recognize given your previous dissection. Carry this superiorly up to the junction with the innominate vein. Divide and mobilize the avascular tissue posterior to the SVC with care to identify and not injure the azygous vein. Subsequently distract the SVC medially and complete the dissection of the reflection so that the SVC is completely mobile from the right atria (RA) to the azygous vein or above. a. = artery; v. = vein.

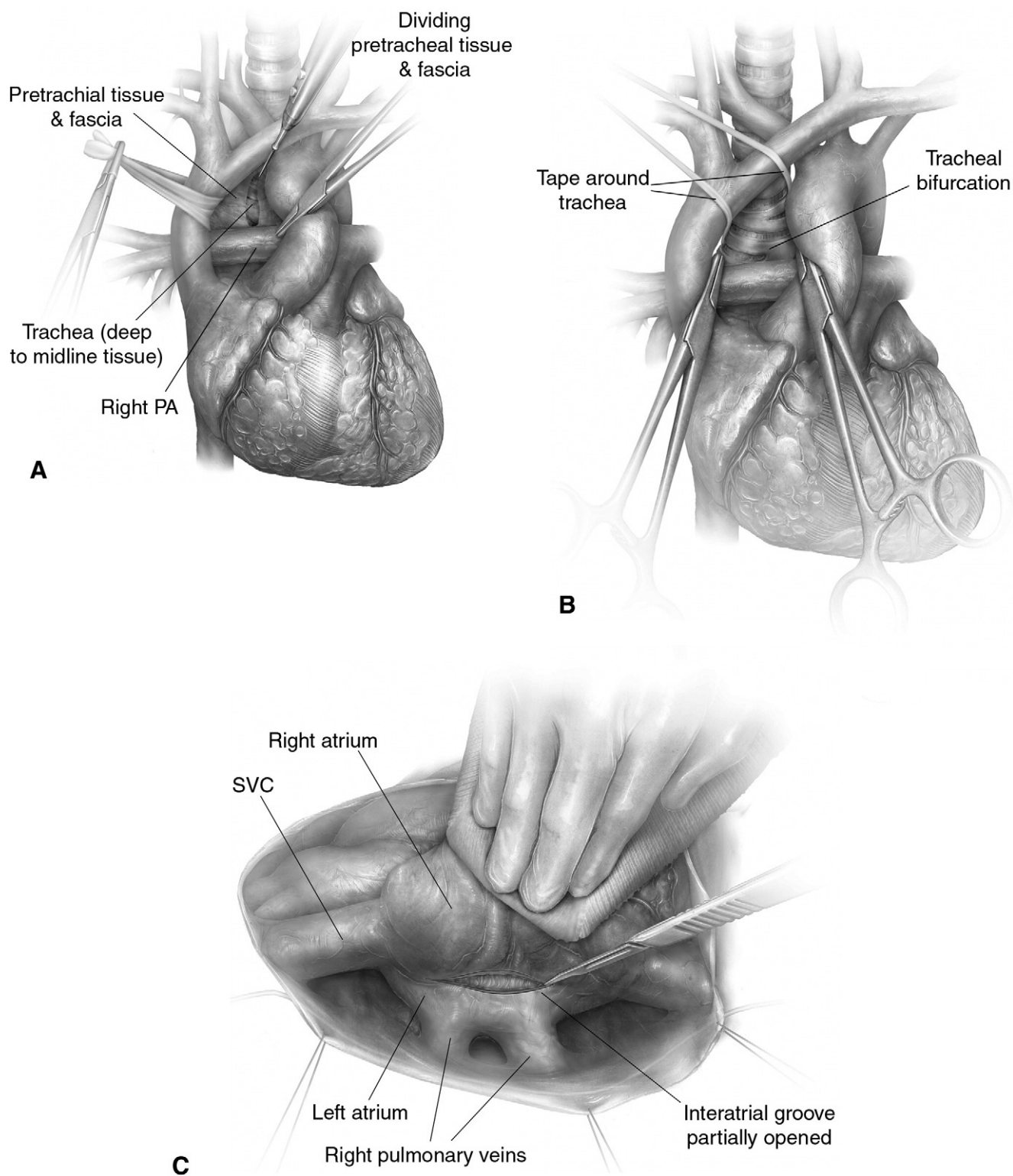


Figure 5 (A) Once these vascular structures are fully mobilized, the aorta is gently distracted to the left. The trachea is palpated through the posterior tissue. There are no other significant structures immediately posterior to the aorta and anterior to the trachea. Open the plane with electrocautery vertically from the right pulmonary artery upwards, stopping frequently to digitally palpate the trachea and assess your progress. Once the pretracheal fascia has been opened longitudinally, gently dissect on both sides of the trachea in the avascular plane until you have defined the point where the firm anterior cartilage transitions to the posterior membranous tissue. (B) It is possible to confuse the left bronchus proximally with the distal trachea, so circumferential mobilization of the airway should be done fairly proximally, often at the level of the innominate vein. Using digital dissection or with a large, very blunt right angle instrument, mobilize behind the upper trachea. Pass an umbilical tape around at this point for later reference.

(C) When taking both heart and lung organs, we further define the most contentious anatomy zone well in advance but after all other anatomic dissection. With a small wet sponge, the heart is gently retracted to the left, exposing the right pulmonary veins. The interface of the left and right atria, better known as Waterston's or Sundergard's groove, is opened sharply along its entire length. The goal of this exposure is to better define the interface of the left atria and right pulmonary veins, at the same time as defining the planned sewing edge of the left atria and the adjoining right atria. PA = pulmonary artery; SVC = superior vena cava.

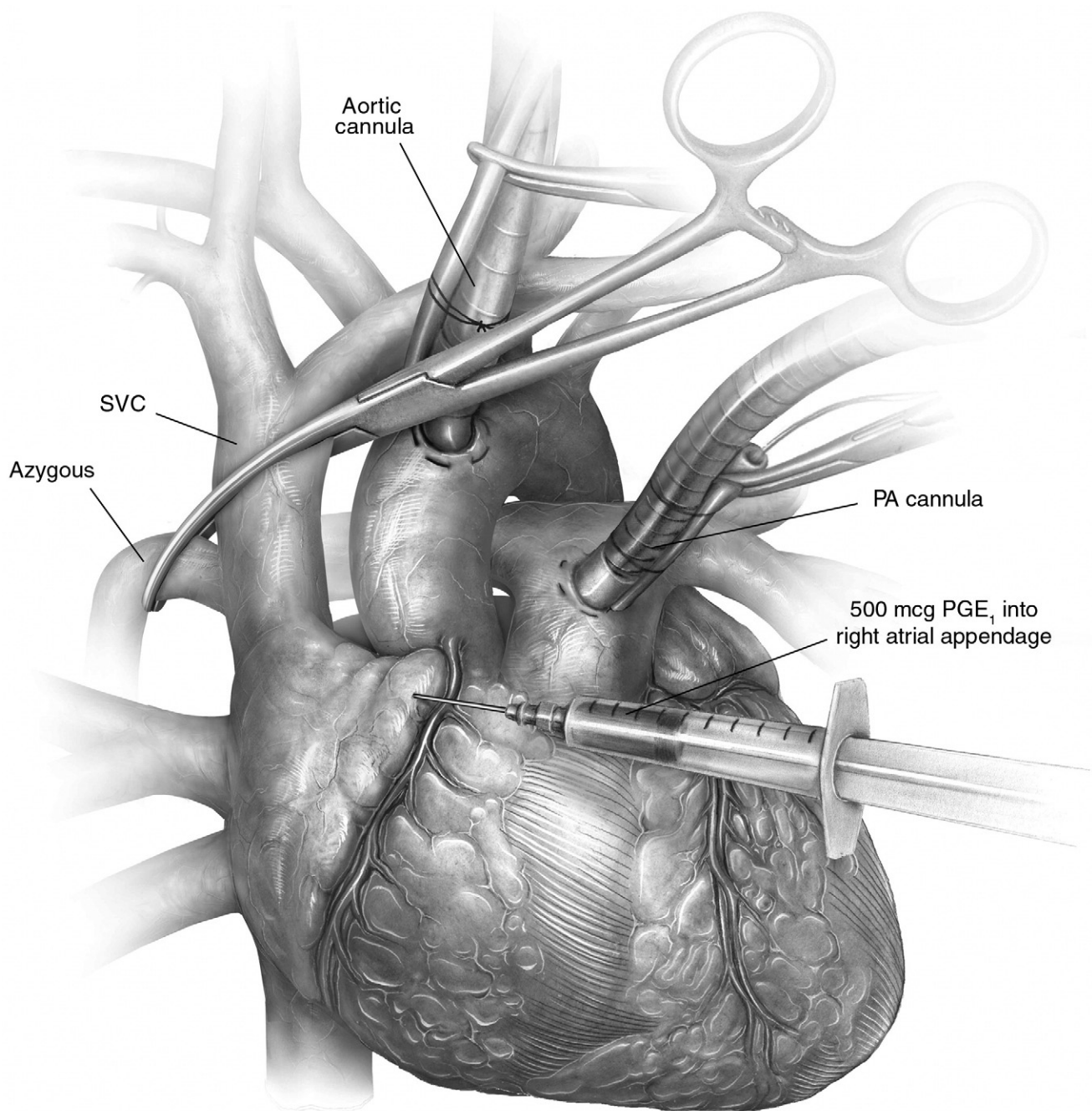


Figure 6 Once all the participating teams have completed their dissection and organ mobilization, AND after confirming with the heart and lung recipient surgical teams that they are prepared for you based on your expected arrival, prepare for cannulation and organ procurement. The previously prepared perfusion materials are passed up the table, secured, and flushed to de-air. A purse-string suture is placed into the anterior ascending aorta, and anteriorly in the later third of the main pulmonary artery. The patient is systemically heparinized and perfusion cannulae are placed into the aorta and pulmonary artery, respectively. It is our practice to secure the aortic cannula as we use it for cardioplegia once we return to our home institution. The cardioplegia is delivered at a consistent pressure of 150 mm Hg by using a pressure bag. The pulmonary catheter is a large bore with a diffusion tip to allow nondirected, large-volume, low-pressure flushing of the pulmonary vasculature. It is held in place with a Rommel tourniquet. When “ready” to apply vascular clamps, we inject into the right atrial appendage 500 μg prostaglandin E_1 . PA = pulmonary artery; PGE_1 = prostaglandin E_1 ; SVC = superior vena cava.

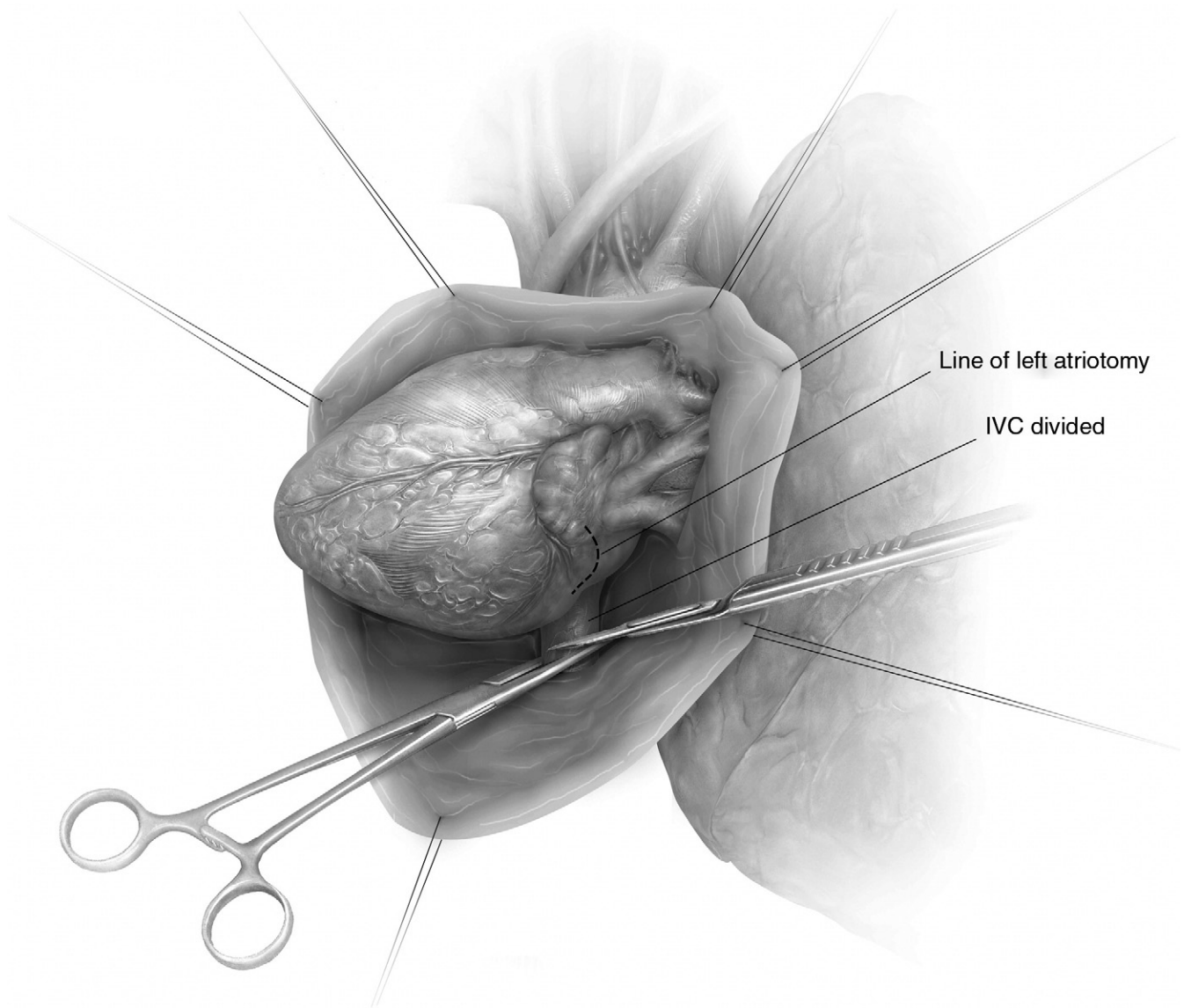


Figure 7 The initial part of the perfusion sequence starts with having anesthesia pull back all deep neck lines so they are above the azygous vein. We place a small straight vascular clamp across the SVC and azygous vein. The heart is lifted up out of the pericardium, exposing the most inferior aspect of the left atrium. Using a no. 11 scalpel, a linear incision at least 2 cm long and toward the posterior aspect of the exposed left atria is created. While still exposed, a pool-tip suction device is passed through the incision into the left atria but assuring there is a large portion of the “holes” that remain in the pericardial well. While the heart is retracted, the exposed inferior vena cava (IVC) is grasped using a long forceps, with the forceps resting along the diaphragm. The same no. 11 blade is then used to divide the IVC, using the instrument as a guide. (This technique assures the liver team the slight cuff they need and preserves a healthy cuff for the IVC well away from the orifice of the coronary sinus. Furthermore, the instrument acts as a guide so that the posterior IVC wall is not shorted, as is commonly seen with the use of scissors.) The heart is released back into the pericardium and the forceps is removed. A second pool-tip suction device is held into the now open IVC. The aorta is now gently lifted upward and is cross-clamped at the level of the distal ascending aorta. Cardioplegia (1-2 L antegrade) and pulmonary perfusate (3 L antegrade) are then opened. Topical cooling with cold saline or slush (NO ICE) complements the perfusion. Aortic root pressure and ventricular distension are continuously monitored to assure good perfusion pressure and avoid elevated ventricular wall pressures. This technique negates the need to lift the heart during perfusion.

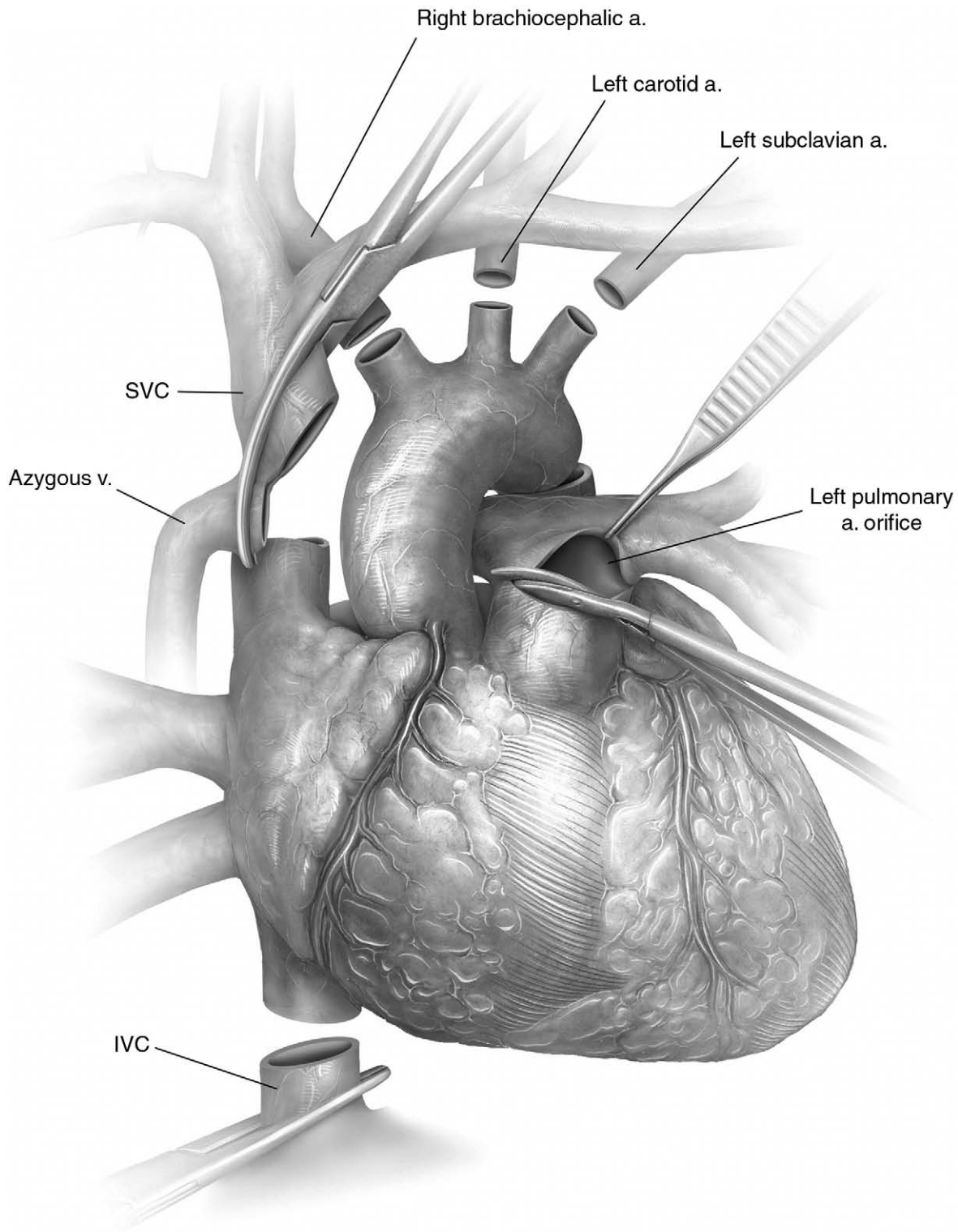
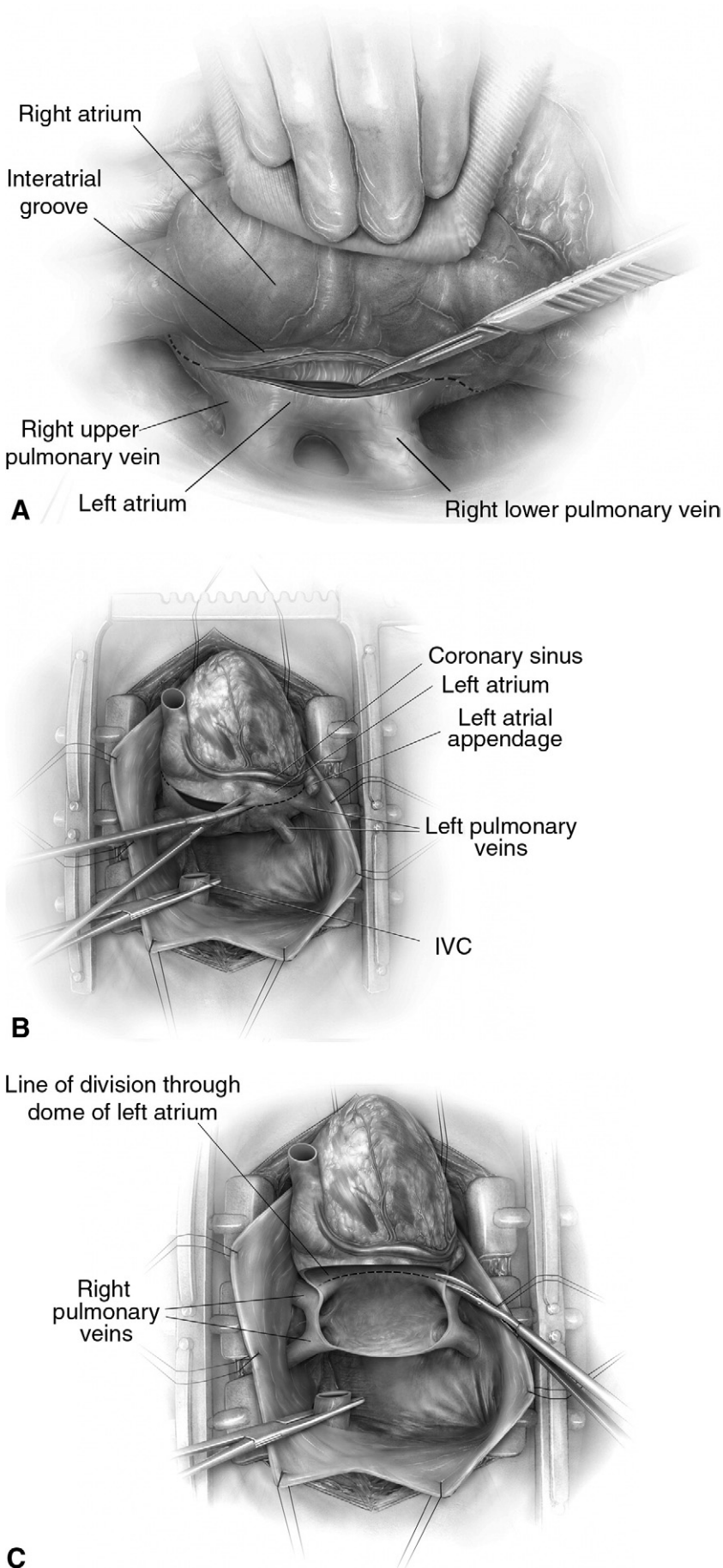


Figure 8 Once the heart and lung perfusion is complete, the donor cardiectomy is completed next. The aortic cannula is detached from the perfusion tubing but left in the aorta. The pulmonary catheter and suture are both removed. We employ a “front-to-back” technique to improve the ease of our mobilization and the visualization of some of the more difficult to see structures. Below the clamp, the SVC is sharply divided, creating a common orifice of the SVC and azygous. If there are any additional points of attachment, the IVC division is completed sharply. The aortic arch, already mostly dissected before this point, is completely mobilized by sharply dividing all the head vessels, and then finally the proximal descending aorta is divided at the level of the ligamentum arteriosum. This in turn exposes the pulmonary artery. The anterior pulmonary artery is opened at the location of the perfusion cannula and carried around so that the orifice of the left and right pulmonary arteries is left intact. a. = artery; v. = vein.

Figure 9 (A) The heart is then gently retracted to the left, exposing the previous dissection in Waterston's groove. Without distorting that tissue plan, a no. 11 blade opens into the left atria at a point equal between the right pulmonary arteries and the still fused margin of the left and right atria. (B) This leaves equal sewing tissue for both organs. The heart is then lifted superiorly out of the pericardial well, exposing the original incision into the left atria. With either a no. 11 blade or a sharp scissors, the incision is extended to the right and the already opened left atrium/pulmonary vein junction, all the while looking inside the atria to assure proper alignment. The incision is then extended to the left to the base of the left atrial appendage. (C) This leaves only the superior dome of the left atria. As both venous cuffs are now well defined, the incision can sweep deeply posteriorly with an hourglass-like curve completing the cardiectomy. Although some prefer to complete this last incision full thickness, we complete this in layers, first defining the planned line with a no. 11 blade, then completing in a pass or 2 more.

The heart is brought to the back table where all the valves are carefully examined. Patent foramen ovale is ruled out or fixed and any additional surgical issues or anatomic findings are noted. The heart is then packed for shipment back to the recipient. IVC = inferior vena cava.



C

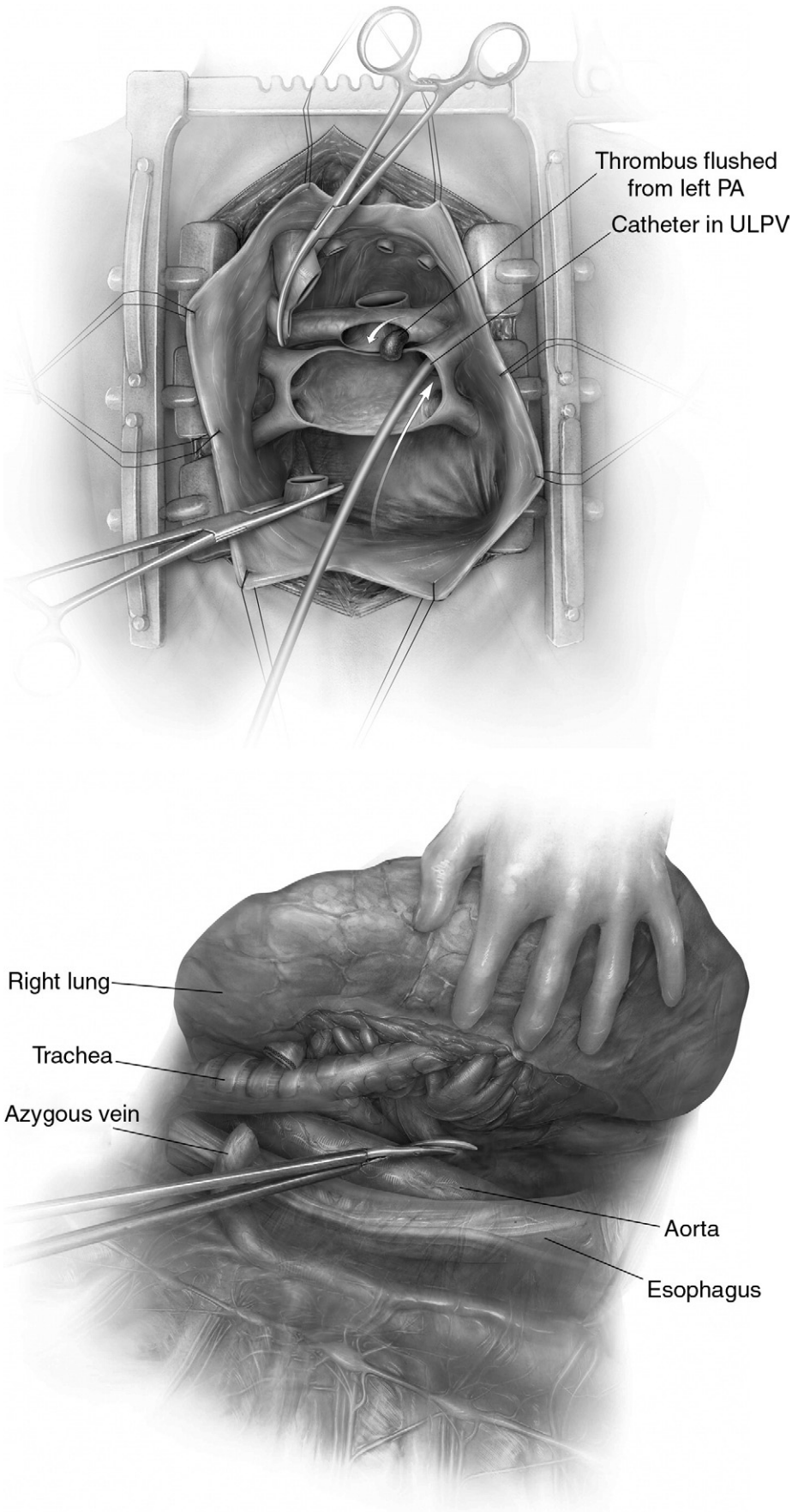


Figure 10 Once the heart is removed, the lungs receive 3 L of retrograde perfusion. Using either the previous pulmonary cannula or a catheter like a Foley with a soft balloon already inflated, the additional flushing is done by hand and flow is directed into each major venous orifice bilaterally. In our experience, over 50% of donors will demonstrate a previously unrecognized but significant pulmonary embolus that is demonstrated when it is flushed out. During this time, the lungs continue with low-rate, low-volume ventilation. Following perfusion, ventilation is transiently stopped. Both inferior pulmonary ligaments are divided and with them the pericardium is incised across the midline. The pericardium is taken with the lungs and creates the guide behind which the majority of the mediastinal dissection will occur. The right lung is moved across the midline into the left thorax. The exposed avascular plane behind the pericardium and anterior to the esophagus is mobilized all along the length of the mediastinum until above the level of the hilum. The same maneuver is repeated on the left. Often flipping back and forth several times makes this dissection easier. PA = pulmonary artery; ULPV = upper left pulmonary vein.

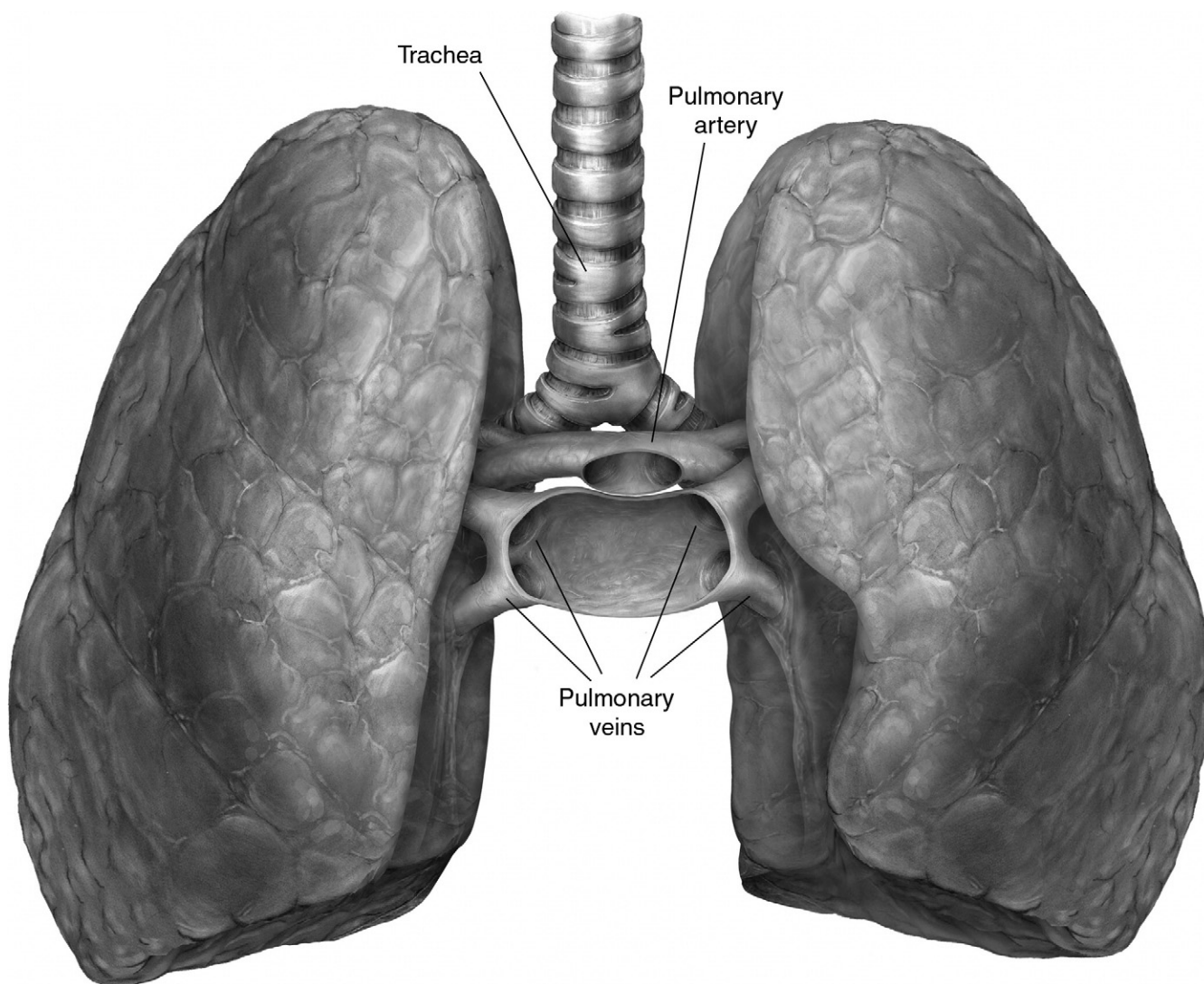


Figure 11 The lungs are returned to their anatomic location. The soft tissue between the tracheal umbilical tape and both the left and the right thoraces is above the hilum and contains no significant structures. This tissue is sharply divided, leaving only the trachea as a point of attachment. At that point the trachea is gently pulled forward while a stapler is positioned around the uppermost aspect that was previously mobilized. The anesthesia provider then hand-inflates the lungs to full and gently allows mild deflation to about 80% volume. The stapler is fired twice and the trachea is divided. The lungs are then removed to the back table, inspected, and packaged for transport back to the recipient hospital.