

Medical Parasitology for 1st year Medical students

Introduction to protozoa, Intestinal protozoa

Presented by

Dr. Amany M Kamal & Dr. Noha H Abdelgelil

Assistant Professor of Medical Parasitology

Assistant Professor of Medical Parasitology

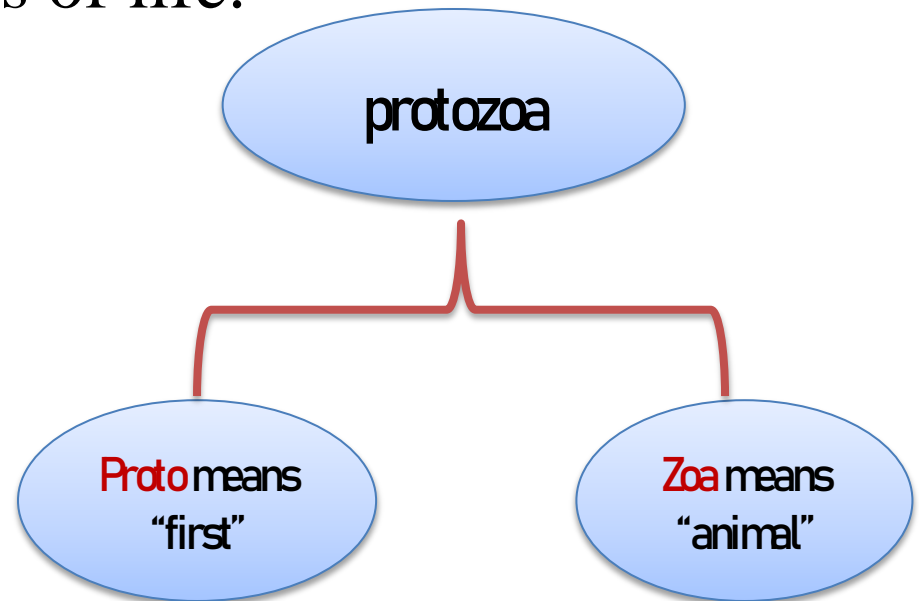
ILOs

By the end of the lecture the student will be able to:

1. Identify medically important protozoa.
2. Understand life cycle's needs for common protozoa.
3. Recall and differentiate the infective and diagnostic stages
4. Demonstrate different types of protozoal infection.
5. Explain host-parasite relationship in protozoa.
6. Memorize the intestinal protozoa.

What is protozoa?

- Smallest, simplest and most primitive of all organisms.
- Unicellular (formed of single cell), perform all functions of life.
- Life stages of protozoa:
Trophozoite, Cyst.



Protozoa cell structure

Cytoplasm

Nucleus

Ectoplasm

Endoplasm

Vesicular

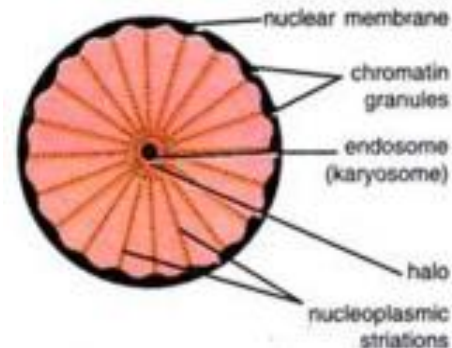
Compact

For:

- 1- Protection
- 2- Locomotion
- 3- Food ingestion
- 4- Respiration
- 5- Excretion
- 6- Cyst wall formation

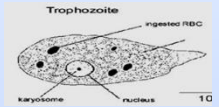
Contains:

- 1- food vacuoles
- 2- stored food granules
- 3- excretory vacuoles
- 4- nucleus (reproduction, regulation of cell activity)



***Locomotion:** Takes place through one of the following:

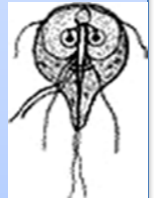
a. Pseudopodia: A pseudopodium is formed by throwing the ectoplasm in a certain direction followed by the endoplasm and thus the whole organism precedes (e.g. Amoebae).



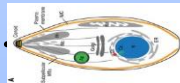
b. Cilia: Fine small ectoplasmic processes found in great numbers and arranged in rows (e.g. Ciliates).



c. Flagella: Thread-like cytoplasmic extensions; each one arising from an intra cytoplasmic granule termed blepharoplast (e.g. *Giardia*).



d. Gliding: The body glides smoothly along without change in shape (e.g. *Toxoplasma*).



***Respiration:** Aerobic (e.g. *Plasmodium* and *Leishmania*). Or anaerobic (e.g. most parasitic protozoa).

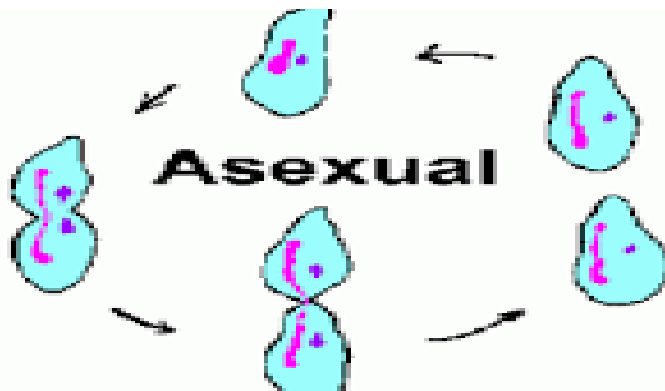
***Nutrition:** Is done by: Pseudopodia (e.g. Amoebae), Flagella (e.g. *Giardia lamblia*), cilia (e.g. *Balantidium coli*), Diffusion (e.g. Sporozoa).

***Excretion:** Waste products pass out through ectoplasm by diffusion or They accumulate in excretory (contractile) vacuoles which increase in size till they rupture to the surface.

***Reproduction:** Biological process by which new individual organism (offspring) are produced from their parents

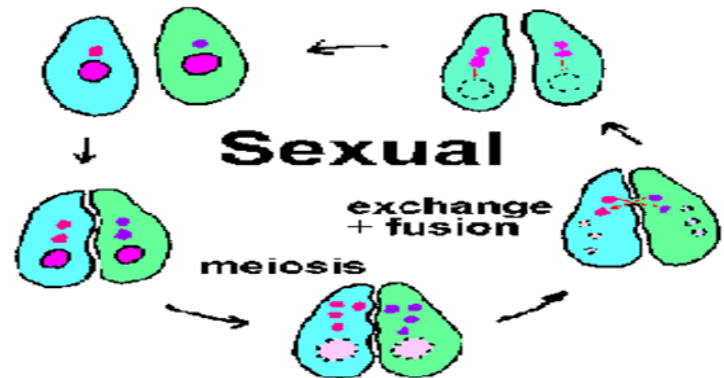
Asexual reproduction

- Binary fission
- Multiple fission (Schizogony)
- Internal budding Endodyogony)
- Reproduction by cyst formation



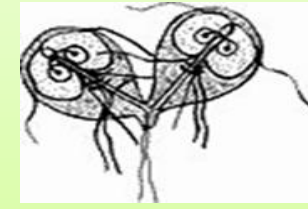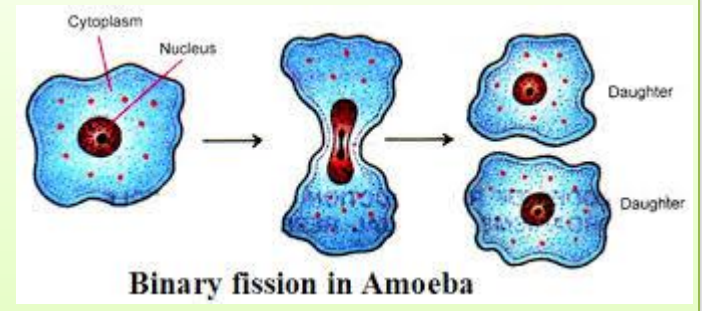
Sexual reproduction

- Conjugation
- Copulation (Syngamy or union of gametes)

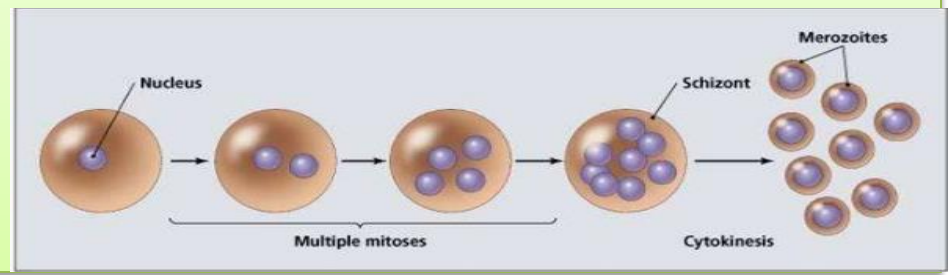


Binary fission: Is the commonest type, in which each individual divides into two. It starts by nuclear division followed by cytoplasmic division and then separation of the newly formed daughter cells.

The plane of division is **irregular** (at any point) In Amoeba, **longitudinal** in flagellates and **transverse** in ciliates.

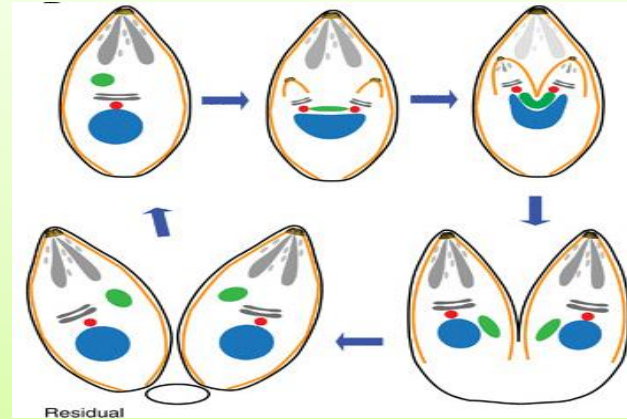


Multiple fission (Schizogony): The nucleus divides, several times before the division of cytoplasm; each is surrounded by a part of cytoplasm. The dividing cell is called schizont and the daughter cells are merozoites (e.g. malarial parasites).



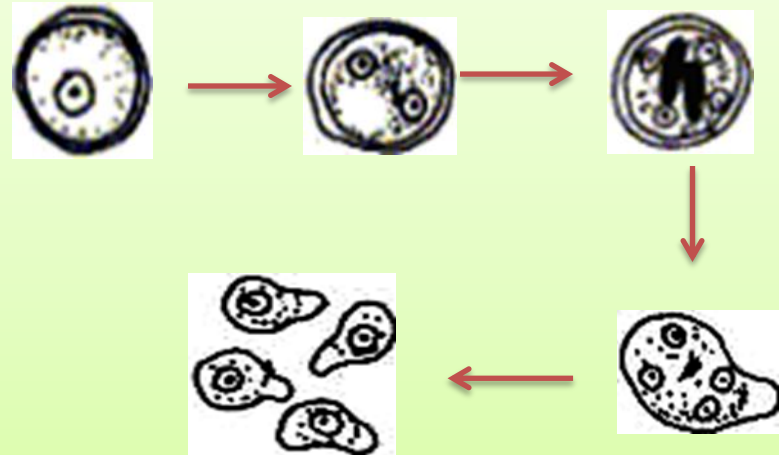
Internal budding (Endodyogony):

The daughter cells are formed within the mother; to be free individuals (e.g. *Toxoplasma* and *Sarcocystis*).



Reproduction by cyst formation:

Some protozoa form resistant cysts, by deposition of heavy wall around the whole organism. The nucleus divides to give a definite number of nuclei specific to each parasite, when the cyst ruptures; it gives the same number of parasites (e.g. Amoebae).



Conjugation: Two organisms

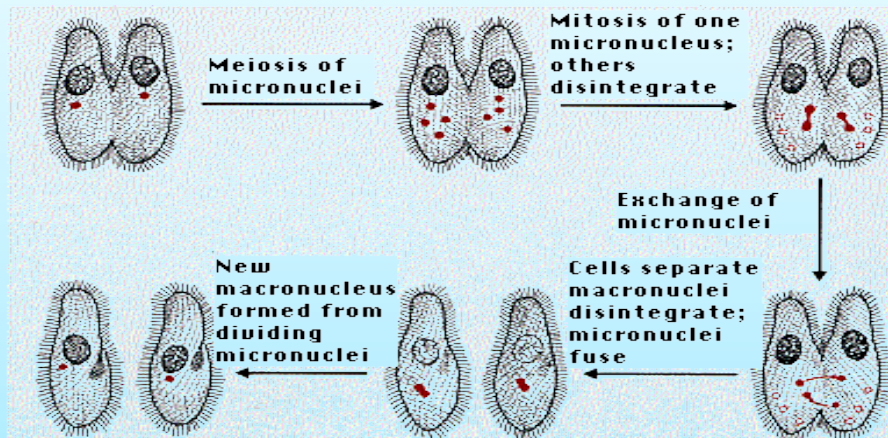
adhere to each other; their macronuclei degenerate.

Micronuclei divide into fragments which are exchanged.

The 2 organisms separate.

There is no increase in number of the parasite but a sort of

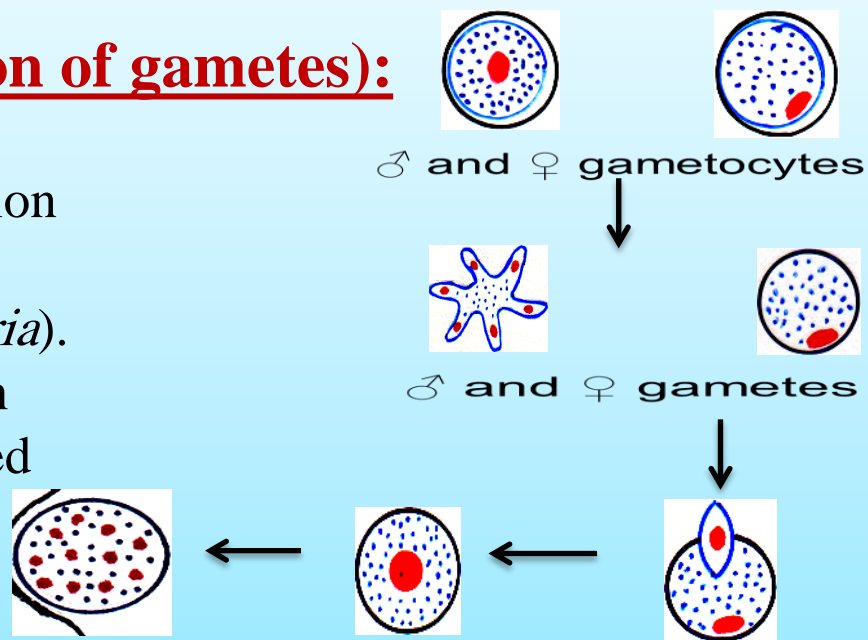
renewal of nuclear chromatin (e.g. Ciliates).

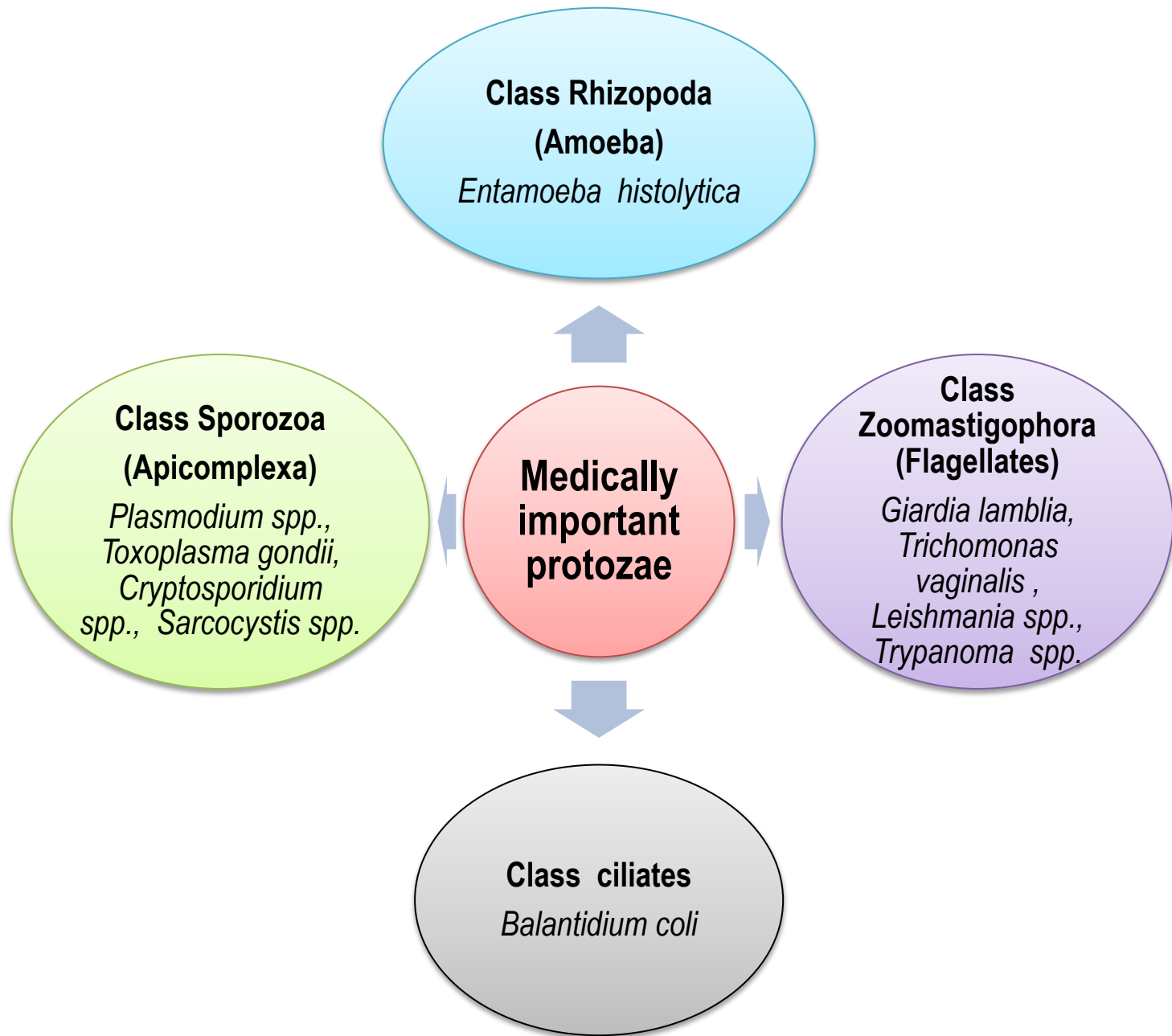


Copulation (Syngamy or union of gametes):

The formation of two cells (male and female gametes) by reduction division followed by their union and formation of a zygote (e.g. *Malaria*).

The zygote develops into an oocyst in which infective sporozoites are formed (sporogony) (e.g. Sporozoa).







Intestinal protozoa

Small intestine

Giardia lamblia
Cryptosporidium spp.

Diarrhea

Increase in frequency
/fluidity/volume of bowel
motions may be defined in
a clinical sense as change
in bowel habits

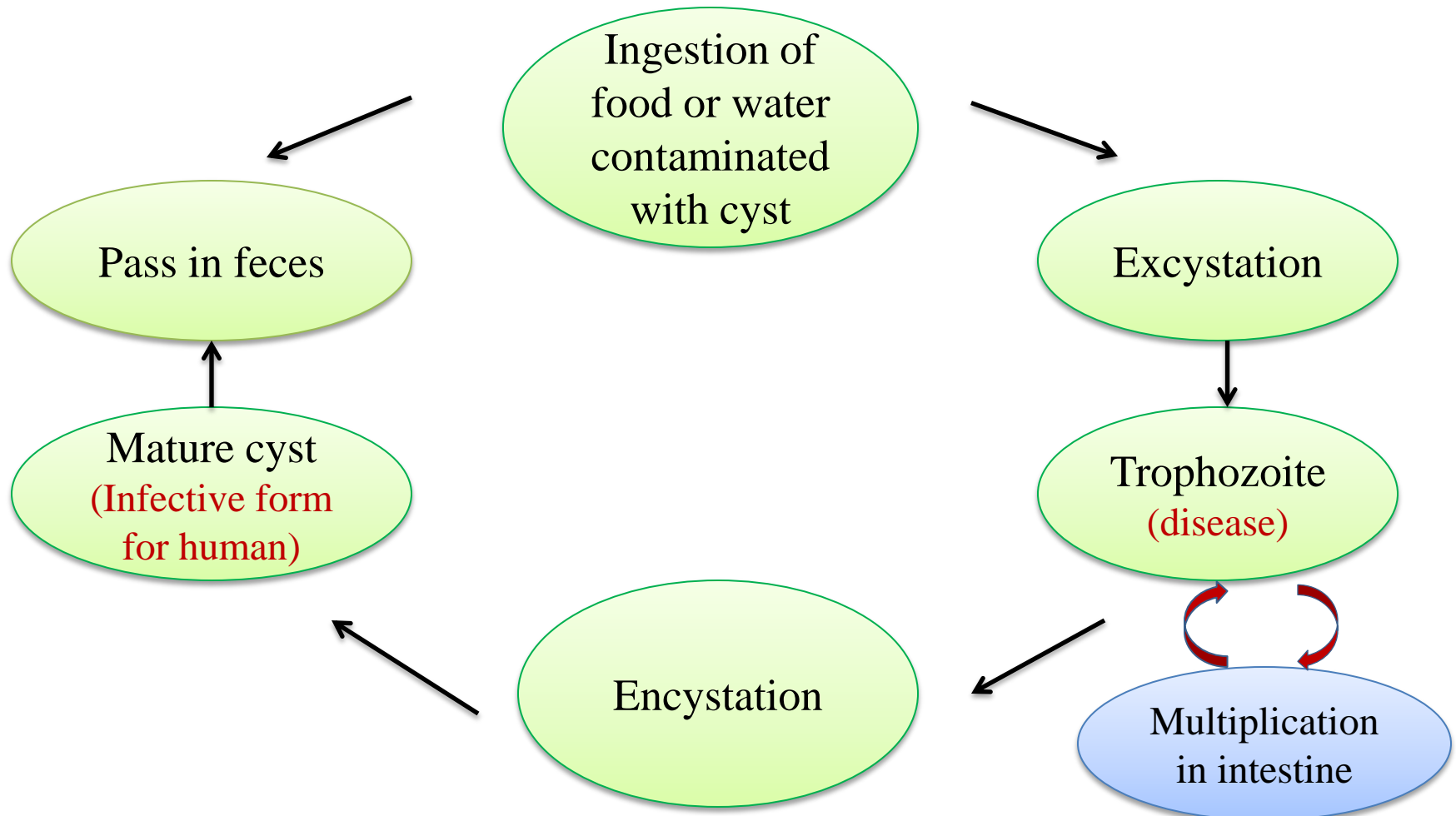
Large intestine

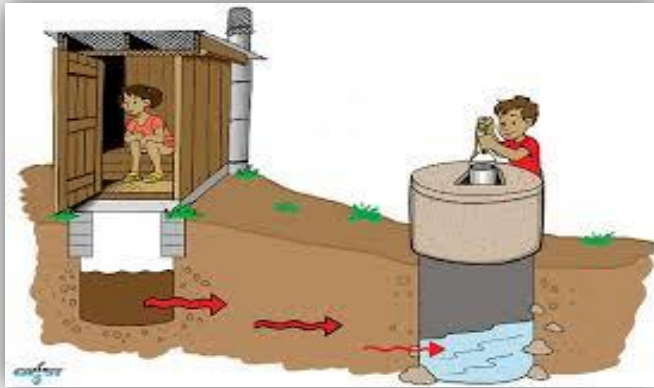
Entamoeba histolytica
Balantidium coli

Dysentery

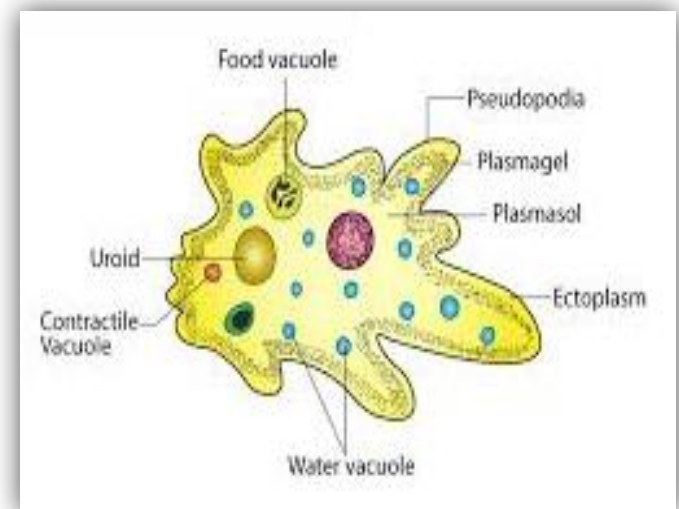
Painful-frequent
evacuation of small
quantities of stool largely
composed of blood
& mucus

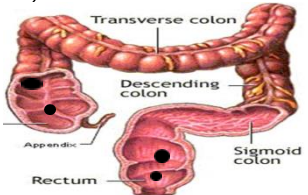
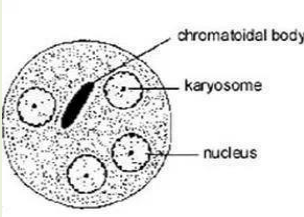
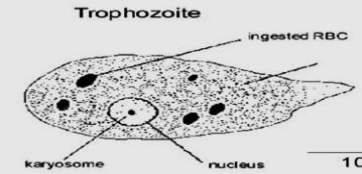
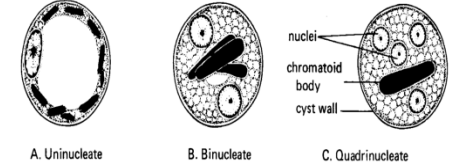
General life cycle of *Entamoeba histolytica*, *Balantidium coli* and *Giardia lamblia*





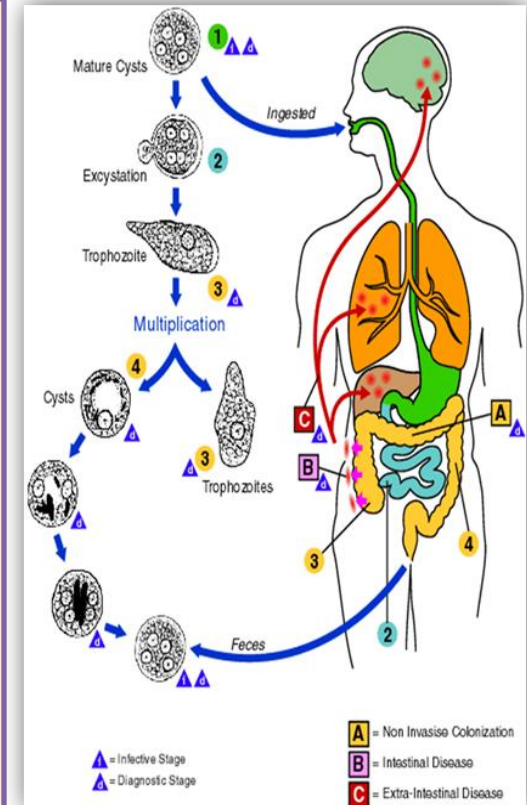
Entamoeba histolytica (Intestinal amoeba)



<p>Disease</p>	<p>Amoebiasis, Amoebic dysentery</p>
<p>Definitive host</p>	<p>Man</p>
<p>Habitat</p>	<p>Large intestine, mainly in the caecum, rectum and in the flexures.</p> 
<p>Infective stage</p>	<p>Quadrinucleated cyst (Small, spherical, 15µm, surrounded by thin cyst wall, contain 4 vesicular nuclei)</p> 
<p>Diagnostic stage</p>	<p>Trophozoite in diarrheic stool (20 µm, amoeboid, contains vesicular nucleus, food vacuoles, RBCs or WBCs)</p>  <p>Cysts in semiformed and formed stool (uni, bi, quadrinucleated cysts)</p> 

life cycle:

- Following ingestion of mature quadrinucleated cysts, excystation occurs in the lumen of the small intestine liberating metacyst with four nuclei that divide once followed by cytoplasmic division resulting in the formation of eight trophozoites.
- The trophozoites multiply, most of them remain in the lumen of the intestine feeding on starch and mucus.
- Some trophozoites (non pathogenic form) encyst in the lumen of the colon into precysts, then cysts which pass out with the feces.
- Under certain conditions, trophozoite (pathogenic form) may invade the intestinal mucosa by their proteolytic secretions forming ulcers.



Mode of infection:

1. Autoinfection: Feco-oral route (external autoinfection).

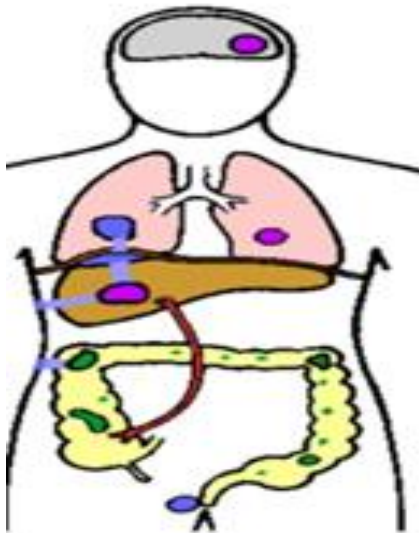
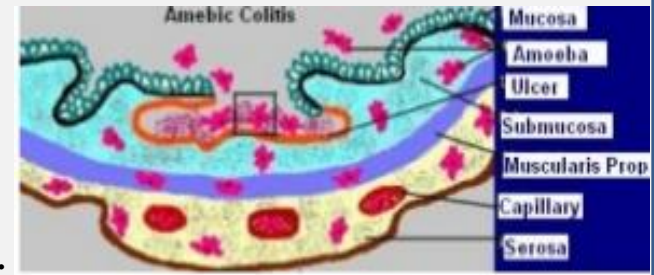
2. Heteroinfection:

- Food or drink contaminated with human feces.
- Direct contact of person to person (fecal-oral) (food handlers)
- Contamination of food stuffs by flies, and possibly cockroaches (mechanical transmission).

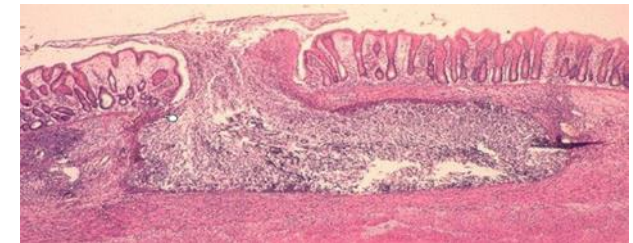
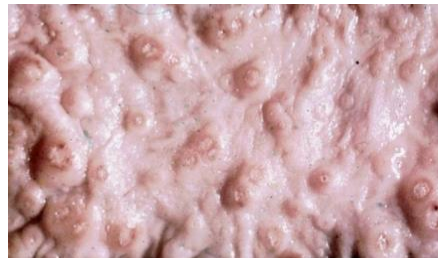Cyst passer

Pathogenesis:

- Depends on (Parasite virulence, Host resistance, Condition of the intestinal tract).
- Trophozoites may be either Non-pathogenic (in the lumen) or Pathogenic (invade intestinal mucosa).
- Trophozoites produce histolytic enzyme that produce necrosis of mucosa leading to the formation of flask-shaped ulcer.
- This is followed by:
 - *Proliferation of connective tissue.
 - *Intensive ulcerations.
 - *Extra-intestinal invasion to brain, liver, lung or skin.




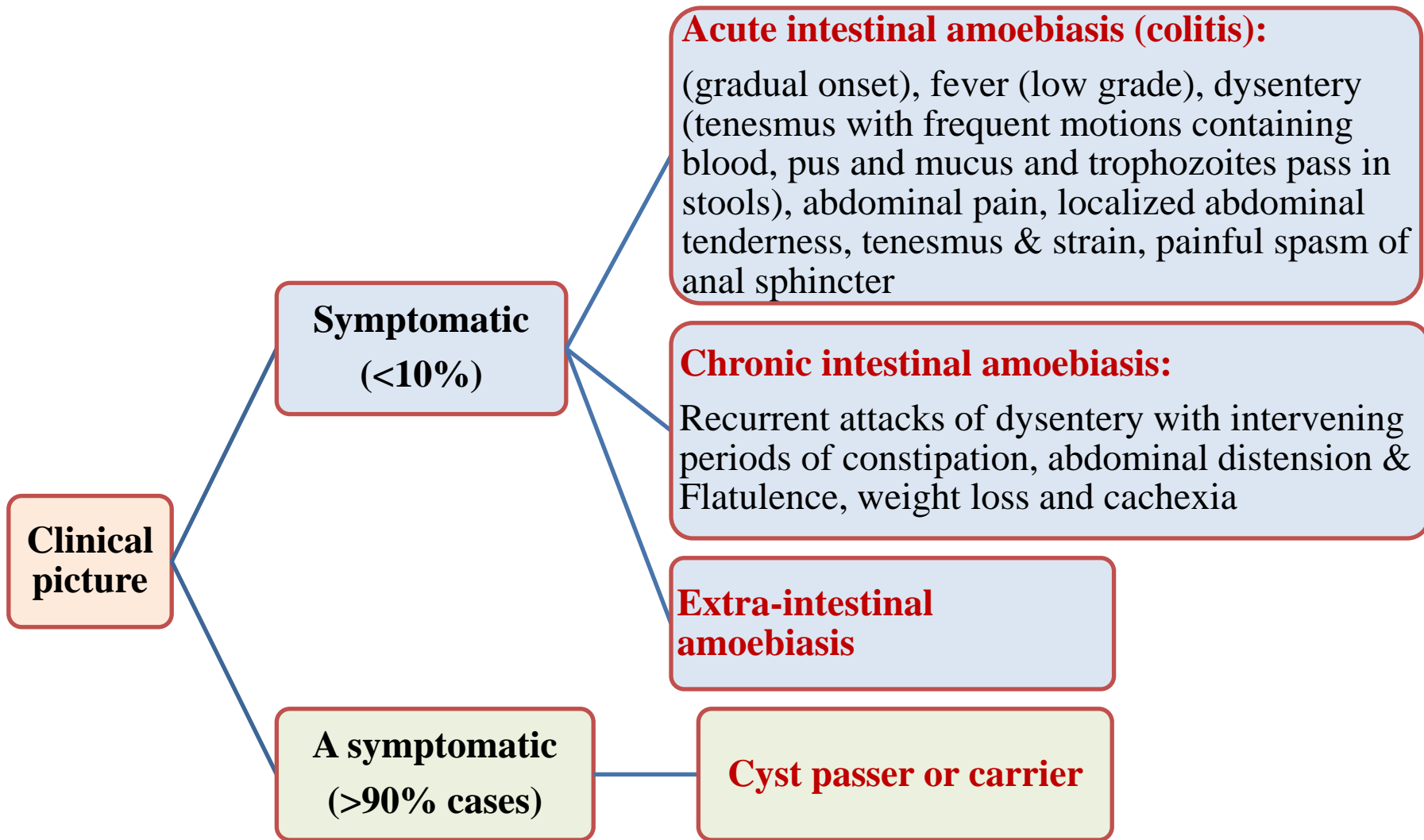
Extra-intestinal lesions



Flask shaped ulcer

Invasion of blood vessels, extension outside bowel





Diagnosis:

I. Intestinal amoebiasis:

1. **Clinically:** Dysentery: painful frequent evacuation of small quantities of stool containing mucus tinged with blood.

2. **Laboratory diagnosis:**

- **Direct stool examination:** Trophozoites are found in diarrhoeic stool. Cysts are found in formed stool.

- **Indirect diagnosis:**

*Serological tests in chronic amoebiasis.

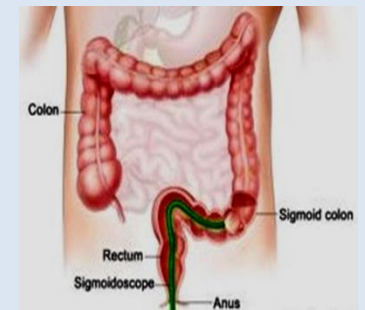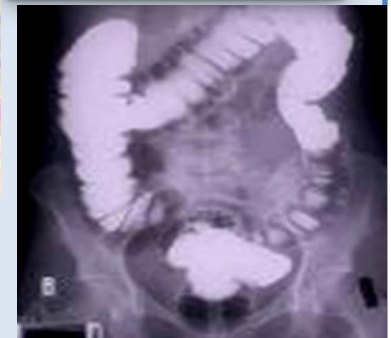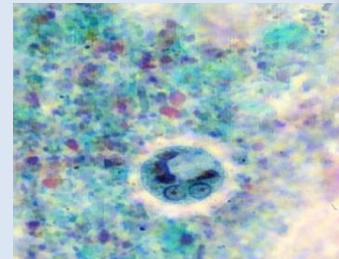
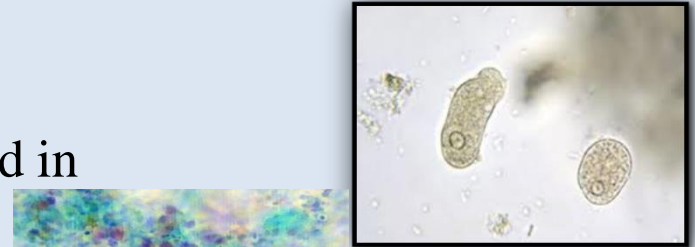
*Detection of copro-antigen using monoclonal antibodies.

- **Molecular techniques.**

3. **Radiological examination:** Using barium enema.

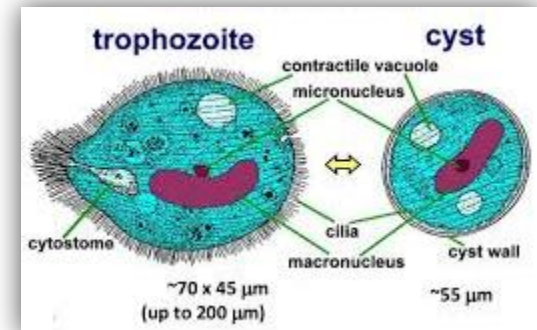
4. **Sigmoidoscopy:** to visualize the ulcer, scrap, aspirate or take biopsy to see the trophozoites.




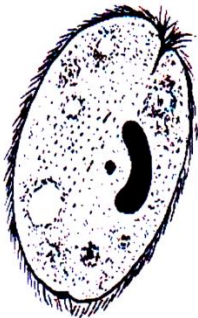

II. **Extraintestinal amoebiasis:** according to the organ affected.





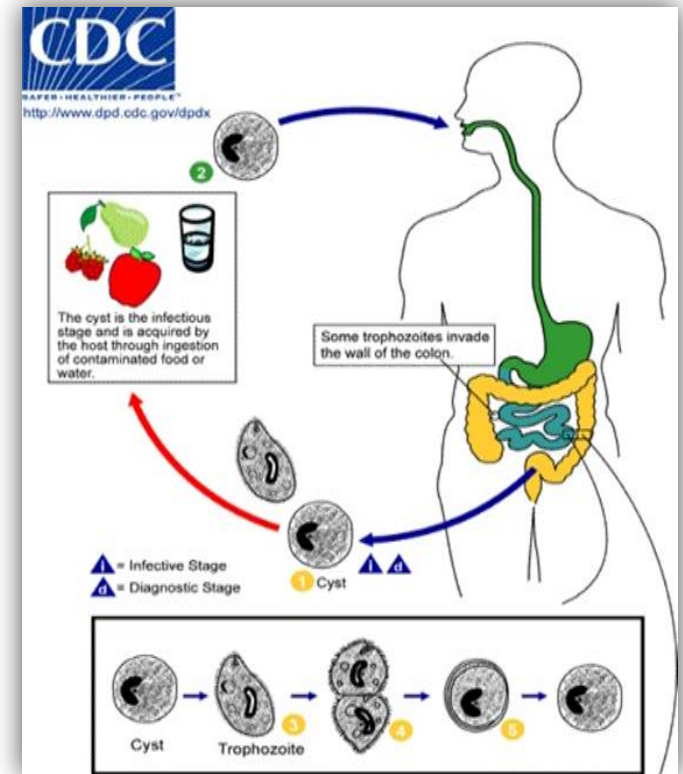
Balantidium coli (Intestinal ciliates)



Disease	Balantidiasis or Balantidial dysentery	
Definitive host	Man	
Reservoir host	Pig	
Habitat	large intestine especially the caecum	
Infective stage	Cyst (round, 40-60 μm , surrounded by a thick cyst wall. The cytoplasm is granular and contains micronucleus and macronucleus)	
Diagnostic stage	 <div data-bbox="852 905 1760 1096" style="border: 1px solid black; padding: 5px;"> <p>Trophozoite in diarrheic stool (oval, large, contains many food vacuoles, 2 nuclei; macronucleus and micronucleus)</p> </div> <div data-bbox="852 1143 1553 1253" style="border: 1px solid black; padding: 5px; margin-top: 10px;"> <p>Cyst in semiformed and formed stool</p> </div>	

Life cycle:

- Following ingestion of cysts, excystation occurs in the lumen of the small intestine and trophozoites pass to its habitat (large intestine).
- Trophozoites may live free in the lumen, multiply or invade submucosa of the large intestine producing ulcer.
- After a period of multiplication in the lumen of the large intestine, encystment takes place and cysts are passed in stool.



Mode of infection

1. Autoinfection: Feco-oral route (external autoinfection).

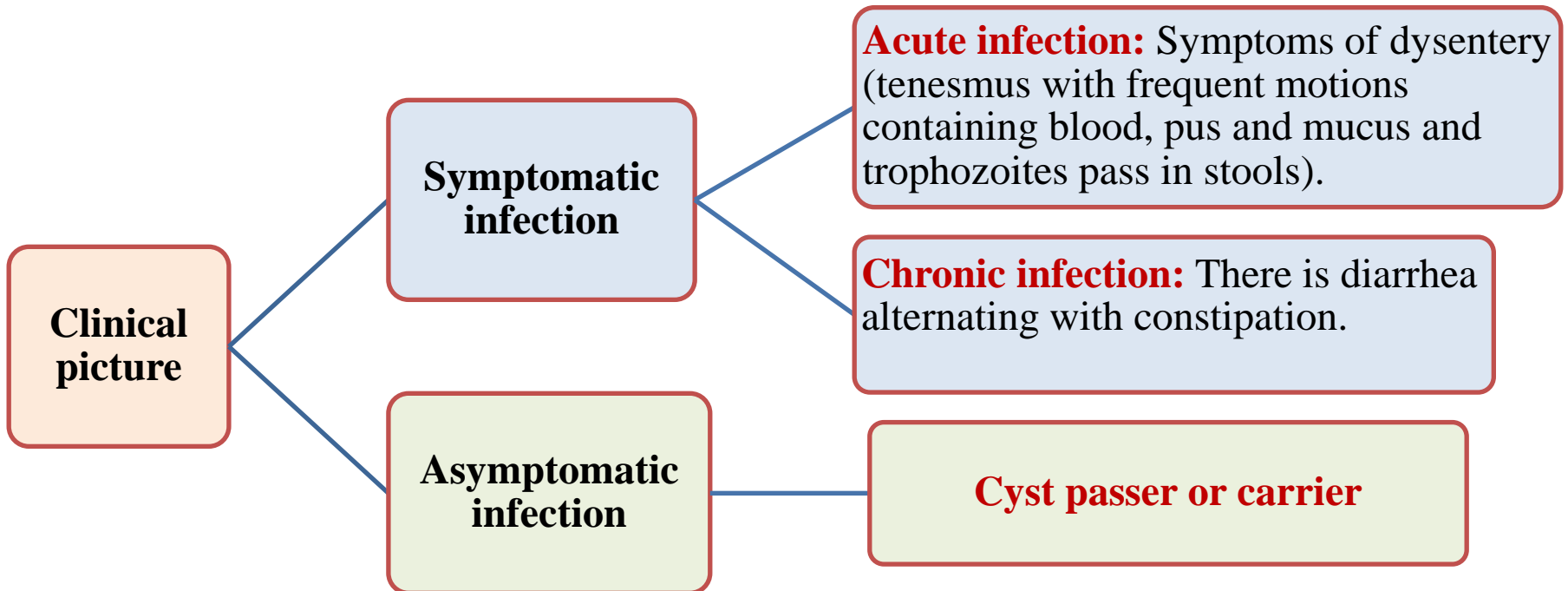
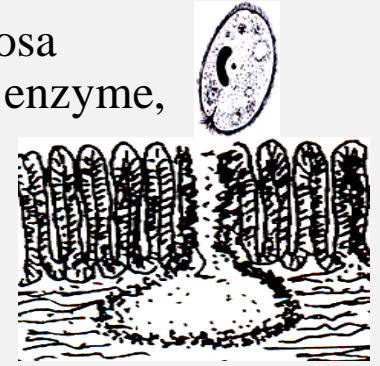2. Heteroinfection:

- Food or drink contaminated with human feces or pig feces
- Direct contact of person to person (fecal-oral) (food handlers).
- Contamination of food stuffs by flies, and possibly cockroaches (mechanical transmission).

Cyst passer

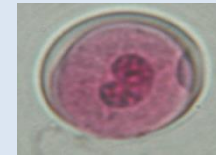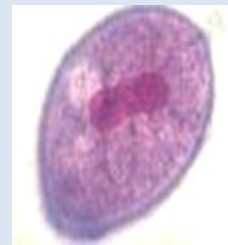
Pathogenesis:

- Trophozoites mainly live freely in the lumen of large intestine.
- Trophozoites may become pathogenic and invade the intestinal mucosa producing intestinal ulcers. **Invasion is facilitated by:** hyaluronidase enzyme, mechanical action of cilia.
- The *Balantidium* ulcer: Multiple, flask shaped with undermined edge, wide opening, large, Superficial.
- Secondary bacterial infection.
- Rarely extraintestinal invasion.



Diagnosis:

I. Clinical diagnosis: It is difficult to distinguish balantidial dysentery from amoebic or other dysentery but history of contact with pigs is useful.



II. Laboratory diagnosis:

1. Stool examination:

- Microscopic examination of direct saline wet mount: Trophozoite is found in diarrhoeic stool, cyst is found in formed stool.
- Permanent stain with iron haematoxylin or trichrome.

2. Serological tests are of value in tissue invasion and chronic infection.

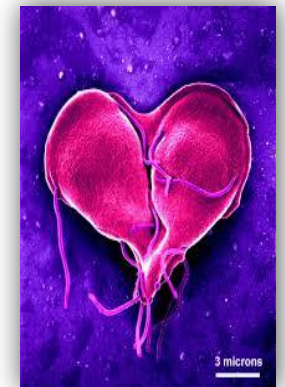III. Sigmoidoscopy: To obtain biopsy from large intestine and scraping of an ulcer for demonstrating the trophozoites stage.

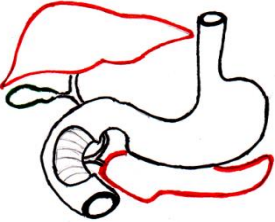


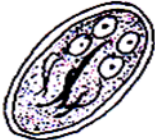


Giardia lamblia (Intestinal flagellates)



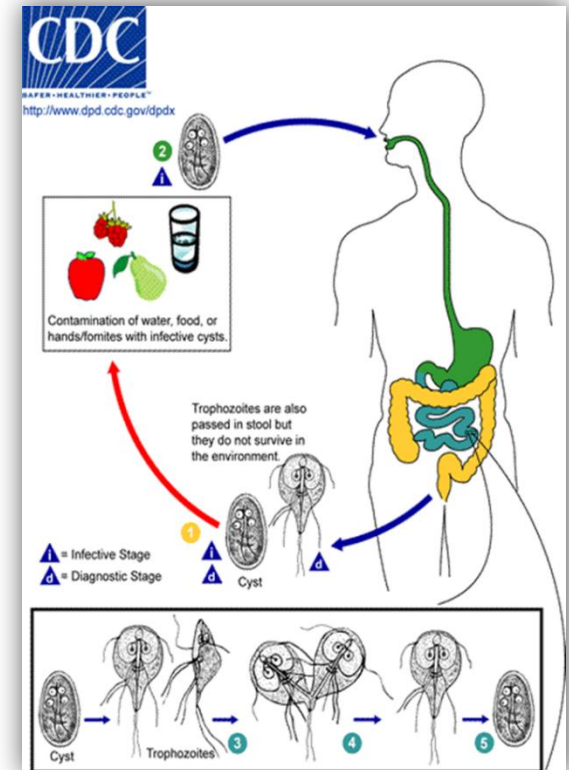
Shutterstock.com • 1499385557



<p>Disease</p>	<p>Giardiasis.</p>	
<p>Definitive host</p>	<p>Man.</p>	
<p>Habitat</p>	<p>Small intestine mainly the duodenum and the upper jejunum</p>	
<p>Infective stage</p>	<p>Cyst (9-12x7-9 um, Oval, Clear space, 4 nuclei in one pole)</p>	
<p>Diagnostic stage</p>	<p>Trophozoite in diarrheic stool (12-15x8 um, Pear shaped, Flat ventrally, Convex dorsally, Two sucking discs, 4 pairs of flagella)</p>  <p>Cyst in semiformed and formed stool</p> 	

Life cycle:

- After ingestion of mature quadrinucleate cysts, excystation occurs in the duodenum. Each cyst produces two trophozoites.
- Trophozoites multiply and get attached by sucking disks to the intestinal mucosa.
- Trophozoites may also reach the bile ducts and gall bladder through the ampulla of Vater.
- Encystation occurs and cysts are excreted in feces.



Mode of infection

1. Autoinfection: Feco-oral route (external autoinfection).

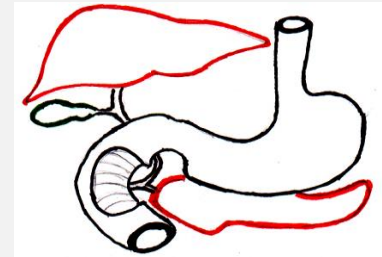
2. Heteroinfection:

- Food or drink contaminated with human feces or pig feces.
- Direct contact of person to person (fecal-oral) (food handlers).
- Contamination of food stuffs by flies, and possibly cockroaches (mechanical transmission).

Cyst passer

Pathogenesis:

1. Mechanical irritation by trophozoites together with toxic effects cause inflammation and hyperaemia in the wall of the duodenum (duodenitis). Epithelial damage, shortening of the villi leading to their dysfunction (diarrhea with malabsorption), hypertrophic crypts and extensive cellular infiltration of lamina propria.
2. The parasite may reach the biliary passage giving the picture of cholecystitis, cholangitis that leading to jaundice and biliary colic



Clinical picture:

1. **Asymptomatic cases:** Trophozoites feed on mucus (cyst passer or carrier).
2. **Symptomatic cases:** Due to duodenitis, the patient suffers from epigastric pain, abdominal discomfort, dyspepsia and diarrhea.
3. **Severe symptoms:** Occur in patients with impaired immunity (hypogammaglobulinaemia, diminished secretory IgA in small intestine, diminished gastric acidity or achlorohydrria). The symptoms are in the form of persistent diarrhea, steatorrhoea (fatty stool), Hypoproteinaemia and fat soluble vitamins deficiencies.

Diagnosis:

I. Clinical diagnosis: Clinical picture.

II. Laboratory diagnosis:

1. Stool examination:

a. Macroscopic examination: The stool is pale yellow, loose, frothy containing excessive mucus and fat.

b. Microscopic examination:

- Direct saline wet mount: Trophozoites appear in diarrhoeic stool, cysts in formed stool.

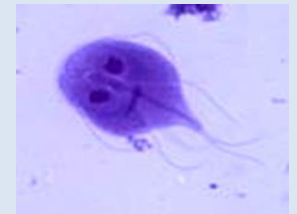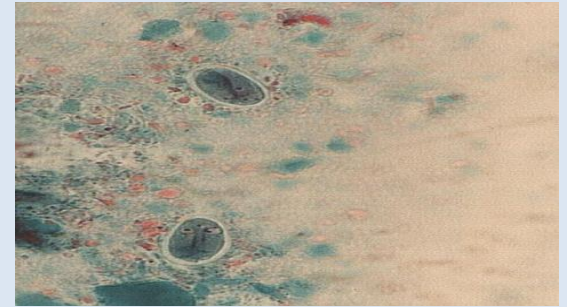
- Concentration methods (floatation): Increase chance of detection.

c. Detection of *Giardia* copro-antigen in stool: IFA assay , ELISA.

2. Duodenal contents or bile examination: Microscope examination of duodenal contents or bile is carried out, when the repeated stool examination is negative but giardiasis is still suspected.

3. Serological tests: ELISA, IFA tests.

4. Molecular diagnosis: PCR techniques may detect *Giardia* DNA in stool samples.

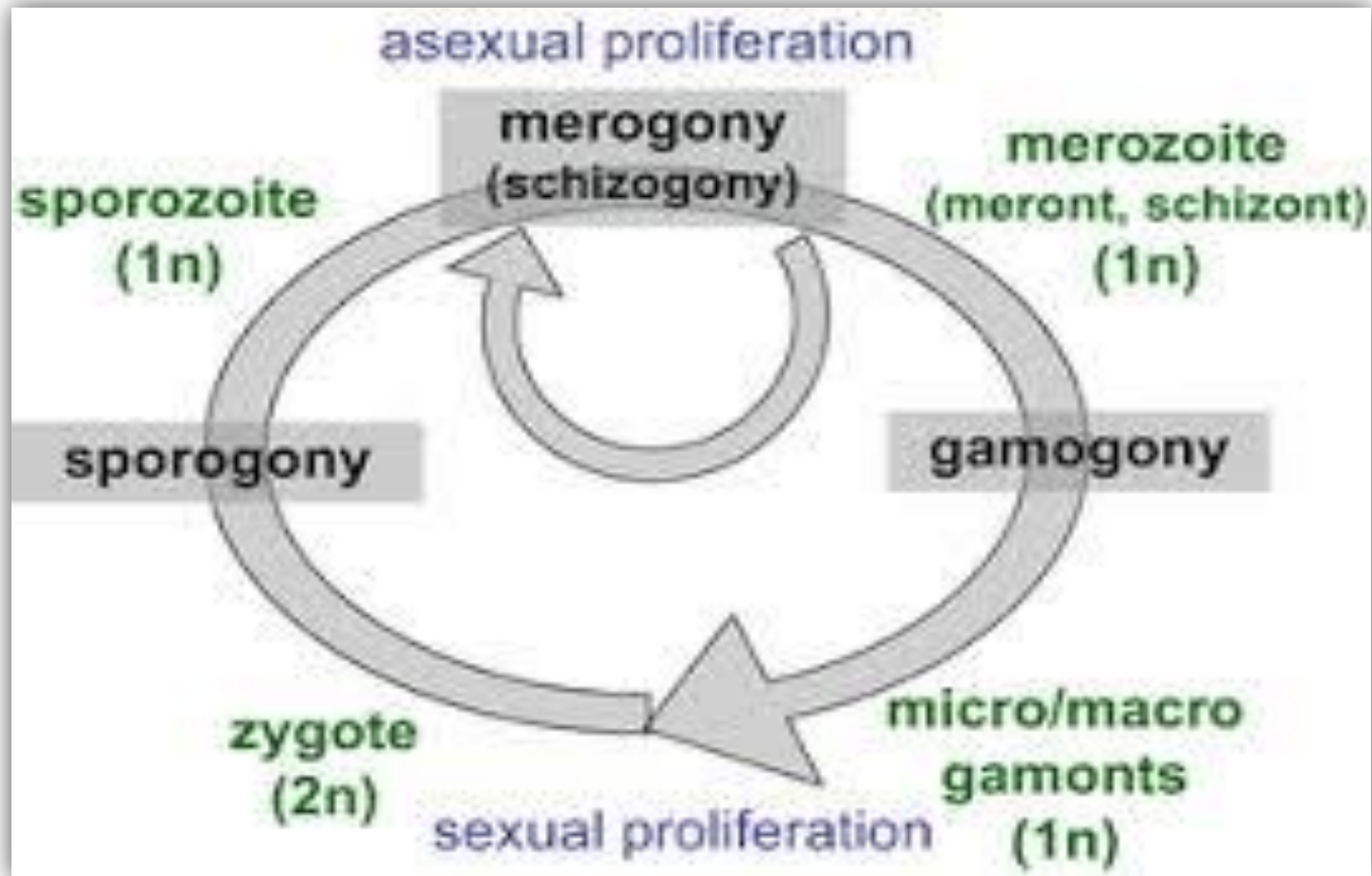


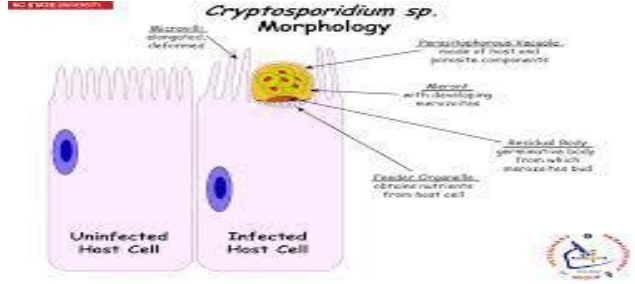





***Cryptosporidium* spp.** **(Intestinal apicomplexa)**



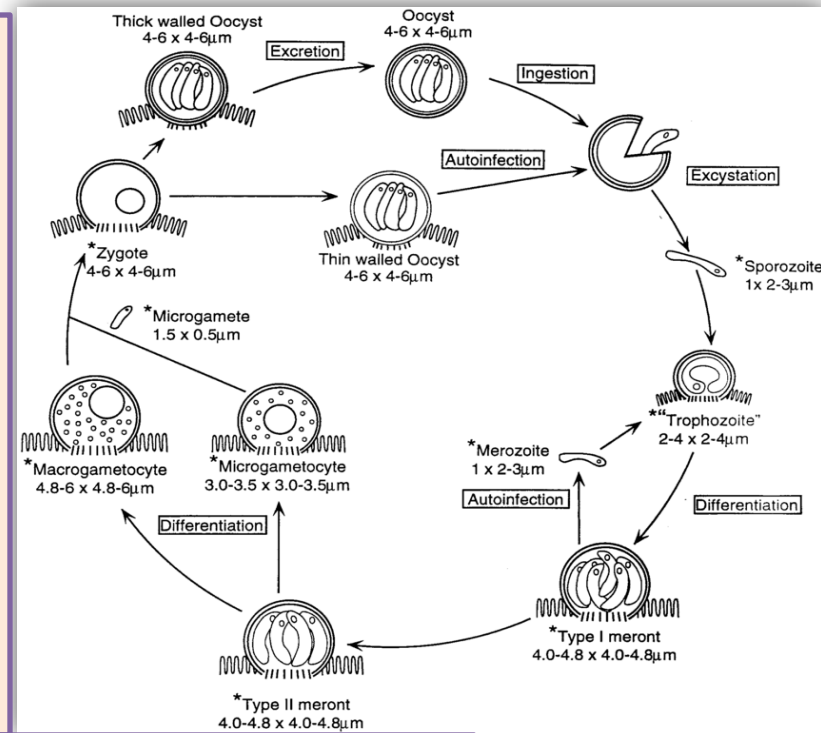
General life cycle of Apicomplexa



<p>Disease</p>	<p>Cryptosporidiosis</p>	
<p>Definitive host</p>	<p>Man</p>	
<p>Habitat</p>	<p>Small intestine (attached to the surface epithelial cells of villi or crypts)</p>	
<p>Infective stage</p>	<p>Thick wall oocyst</p>  <p>(4-6 μm in size, oval in shape, colourless and contain 4 sporozoites)</p>	<p>Thin wall oocyst</p> 
<p>Diagnostic stage</p>	<p>Thick wall oocyst</p>  <p>Dr.Amany M. Kamal& Dr. Noha H. Abdelgelil</p>	

Life cycle:

- The sporozoites are released from the oocyst.
- Merogony and gametogony occur within the brush border of the infected cells.
- Meronts released merozoites which invade adjacent cells and repeat the cycle.
- Gametogony (micro and macrogametes are formed by some merozoites.
- Zygote is formed by fusion of gametes.
- Thin wall oocyst is formed (autoinfection), thick wall oocyst are excreted in stool.



Mode of infection:

1. Heteroinfection:

Ingestion of thick wall oocyst in:

- Contaminated food and water.
- Open source water.
- Direct contact the feco-oral in food handlers.
- Indirect mechanical transmission by flies.



2. Autoinfection:

External autoinfection (Faco-oral) by thick wall cyst.

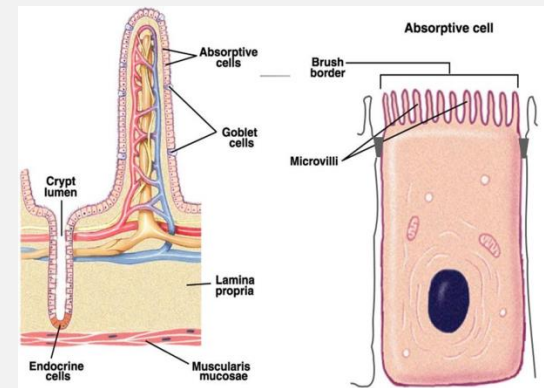
Internal autoinfection by thin wall oocyst.



Pathogenesis:

Intestinal villi show:

Blunting and loss of villi, lengthening of the crypts, infiltration of lamina propria by inflammatory cells. This results in decreased ability of the intestine to absorb proper amounts of water and nutrients leading to dehydration and anorexia.



Clinical picture:

Cryptosporidium is one of Opportunistic protozoa (weak protozoa that cause minimal effect to infected healthy man but has severe effect on infected immunocompromized man.

The clinical picture is depending upon the immune status of the host.

- **In immunocompetent patients:** Mild self-limited diarrhoea for 2 weeks
- **In children:** Abdominal discomfort, watery diarrhoea, anorexia, low grade fever, nausea, weight loss
- **In immunocompromised patients:** Severe life-threatening diarrhoea (Sever persistent watery diarrhea up to 20 L/day, dehydration, malabsorption, low grade fever, weight loss, dissemination of the parasite to other organs.

Diagnosis:

I. Clinical diagnosis: History and clinical pictures.

II. Laboratory diagnosis:

1. Stool examination:

a. Macroscopic examination: Stool is loose and may be watery.

b. Microscopic examination: For detection of thick oocyst.

- Direct wet mount smear.

- Concentration method using Shaether's sugar floatation technique.

- Staining with acid-fast staining (modified Ziehl Neelsen stain), the oocysts appear as bright red or pink, oval or round bodies against a green background.

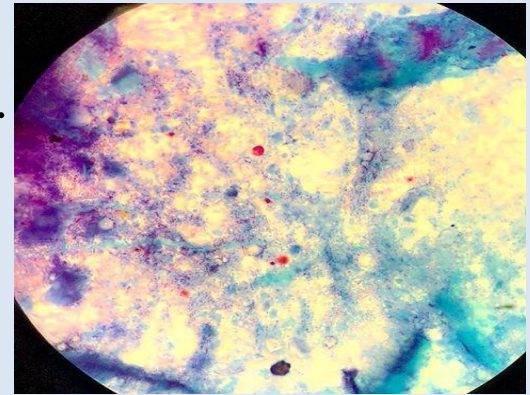
2. Immunodiagnosis:

- Immunofluorescence assay (Direct fluorescent antibody test) by which fluorescent oocysts can be easily detected.

- ELISA for detection of *Cryptosporidium* coproantigen in stool

3. Intestinal biopsy: To detect meronts and gamonts.

4. Molecular diagnosis: Detection parasite DNA in stool by PCR.



Thank
You!

wd
tags

Satisfaction.com

Satisfaction.com

Dr.Amany M. Kamal & Dr. Noha H. Abdelgelil