

Healing after Exposure of Periosteum on the Alveolar Process*

by

SIGURD F. RAMFJORD,** L.D.S., PH.D.
EMMETT R. COSTICH,*** D.D.S., PH.D.

SINCE HILMING¹ in 1942 introduced frenum severance and mucobuccal fold extension as periodontal surgery techniques, numerous articles have appeared recommending these procedures.²⁻⁵ The few histologic studies following periosteal exposure or supraperiosteal reposition of the gingiva⁶⁻⁸ which have been reported have indicated a relatively mild reaction and uneventful healing whenever the periosteum was undamaged by the surgery and remained covered by some connective tissue. However, it takes a long time for the regenerated gingival tissue to regain normal morphology.⁹⁻¹² Apparently on the basis of the earlier studies, clinicians have come to assume that as long as the periosteum is left intact on the bone, not much will happen to the bone; implying that this is a much kinder procedure than bone denudation.^{13, 14}

The purpose of the present investigation was to study clinically and histologically the healing following surgical exposure of the periosteum and the periodontal membrane in a small area at the alveolar crest and over the adjacent alveolar process in humans.

MATERIAL

Twelve immediate denture patients at The University of Michigan School of Dentistry participated in the study. The patients were in good health and their age varied from 25 to 45 years. Dental records, roentgenograms and clinical pictures of the patients were available. The periodontal status varied from normal gingiva to moderately severe periodontitis. All of the experimental teeth had antagonists.

A block section of the experimental tooth with adjacent buccal soft tissues and alveolar process to the middle of the root at least, was obtained from each of the

patients at the time of insertion of the immediate denture.¹⁵

METHOD

The experimental method and measurement procedures were the same as in the previous report on healing after denudation of bone.¹⁶ However, in the present investigation the periosteum was left on the bone. The gingival tissues were removed by sharp dissection on top of the periosteum as is commonly done in periosteal retention procedures or split flaps. The surgical wounds were the same size as those described in the previous paper on denudation. Surgical dressings were placed on the wounds also as in the previous investigation.¹⁶

RESULTS

A. Clinical and Histometric Findings

The healing took place without any pain or complications in a slightly shorter time than following denudation of the bone.¹⁶

All clinical and histometric measurements have been compiled in Table 1. The loss of attachment was approximately the same as after denudation of the bone, and the temporary loss of labial bone, 3 to 5 weeks after the surgery, was also about the same. This loss of labial bone seemed to be regained by regeneration 9 to 10 weeks after the surgery (see Table 1), while some loss of attachment persisted as seen in the second to the last column. There also was considerable lowering of the gingival margin shown by comparison of the presurgical and after healing measurement (see last column Table 1).

B. Histologic Findings

The 12 specimens represent 6 time intervals of healing (1 week, 2 to 2½ weeks, 3 weeks, 4½ weeks, 9 to 10 weeks, and 13 months, see Table 1). The characteristic histologic findings will be described for each of these time intervals.

One Week after Experimental Surgery (Cases 1 and 2, Table 1). One specimen shows regenerating epithelium over inflamed granulation tissue. The epithelium does not cover the entire wound (Fig. 1A). There is necrotic debris, coagulated blood and bacterial colonies on the wound toward the contact with the tooth. The labial surface of the bone with the exposed periosteum is in part necrotic, and there is some sequestration at the alveolar crest (Fig. 1B). There is active bone resorption from the labial and periodontal membrane side (Fig. 1C), as well as from the crest and the marrow spaces (Fig. 1D). The bone resorption extends to the apical limit of the specimen, which is beyond the area of intentionally performed experimental surgery.

*The University of Michigan School of Dentistry, Ann Arbor, Michigan.

**The University of Michigan School of Dentistry, Department of Periodontics, Ann Arbor, Michigan 48104.

***University of Kentucky, College of Dentistry, Department of Oral Surgery, Lexington, Kentucky 40506.

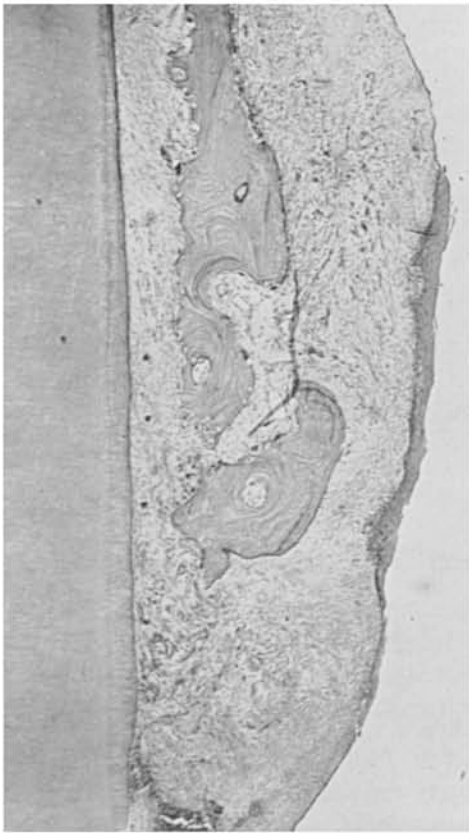

FIGURE 1A. Case 1. One week after surgery. Partial epithelialization. Granulation tissue extending both from residual periosteum and from periodontal membrane. Bone resorption from labial surface and from periodontal membrane side of alveolar bone. (Magnification X35).

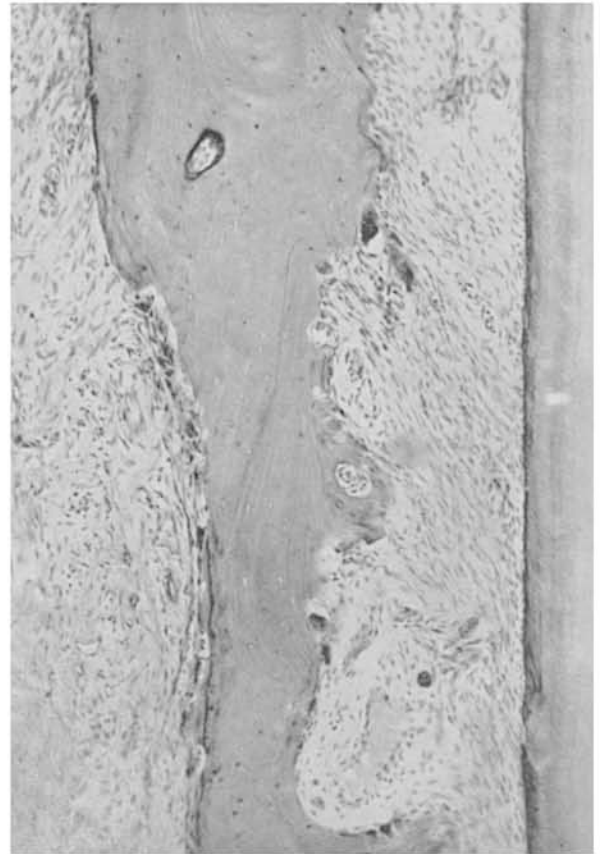

FIGURE 1C. High magnification from Figure 1A. Bone resorption both from labial and periodontal aspect of alveolar process. (Magnification X80).

The other specimen shows a small central area of thin necrotic remains of the periosteum which is heavily infiltrated with polymorphonuclear cells and covers the partially necrotic labial bone (Fig. 2A).

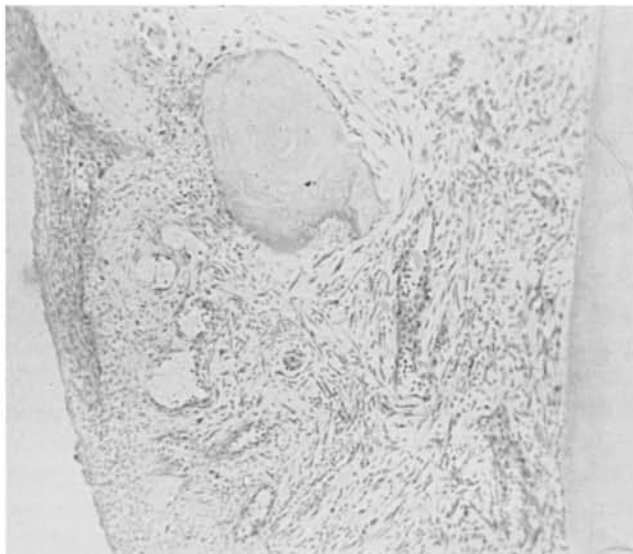


FIGURE 1B. High magnification from same specimen as Figure 1A. Sequestration of necrotic bone. (Magnification X96).

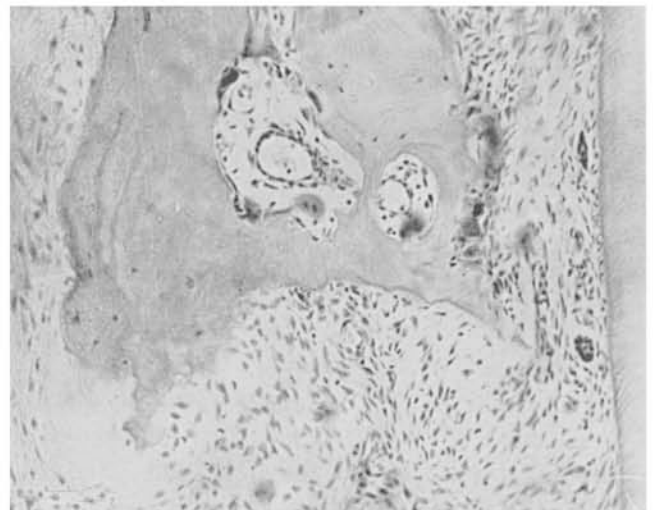


FIGURE 1D. From same specimen as Figure 1A. Bone resorption from marrow spaces. (Original magnification X173).

TABLE I
Clinical and Histometric Measurements in Millimeters

Case Number	Tooth Number	Age of Patient (yrs.)	Pre-surgical		Time of Surgery			Healing Time (days)	Posthealing					Results		
			Notch to Gingival Margin	Bottom of Crevice	Notch to Level of Surgery	Notch to Alveolar Crest	Notch to Apical Level of Periosteal Exposure		Clinical		Microscopic			Loss or Gain of Attachment	Loss or Gain of Bone	Lowering of Gingival Margin
									Notch to Gingival Margin	Notch to Bottom of Crevice	Notch to Gingival Margin	Notch to Bottom of Crevice	Notch to Alveolar Crest			
1	8	42	1.0	2.3	3.0	4.1	7.0	7	2.2	3.4	2.6	3.2	4.3	-1.1	-0.2	1.2
2	11	32	1.3	3.0	3.5	4.4	6.9	7	2.8	2.8	2.6	3.0	4.1	+0.2	+0.3	1.5
3	10	28	1.9	3.7	4.7	6.6	8.2	14	4.6	5.4	4.1	5.1	5.9	-1.7	+0.7	2.7
4	10	36	2.8	4.7	4.8	6.5	8.5	18	6.4	7.6	---	---	---	-2.9	---	3.6
5	7	45	2.0	3.4	4.0	4.8	6.3	20	3.5	4.7	3.1	3.6	4.8	-1.3	0.0	1.5
6	10	26	1.3	3.0	3.5	4.0	8.0	21	2.7	3.2	1.2	1.8	3.6	-0.2	+0.4	1.4
7	8	25	1.7	2.8	4.4	5.7	8.2	21	4.4	5.3	4.2	4.9	7.0	-2.5	-1.3	2.7
8	7	28	1.7	3.7	4.6	5.8	9.4	21	4.0	4.6	5.3	5.5	7.3	-0.9	-1.5	2.3
9	8	27	1.8	3.4	4.0	4.2	8.0	32	3.4	4.6	3.1	3.3	8.1	-1.2	-3.9	1.6
10	10	28	2.5	5.0	5.2	5.7	10.4	65	2.7	4.1	2.9	4.0	5.2	+0.9	+0.5	0.2
11	10	28	1.0	3.5	4.6	5.7	8.5	71	5.1	5.6	3.0	4.3	5.2	-2.1	+0.5	1.6
12	8	26	2.0	5.0	---	7.0	---	390	3.7	5.6	4.0	5.8	7.3	-0.6	-0.3	1.7

The epithelium does not cover the entire wound but it extends to the margin of the necrotic debris (Fig. 2B). There is rapid proliferation of granulation tissue at the coronal aspect of the wound. Bone is being resorbed from the fibrotic and inflamed marrow spaces (Fig. 2C), while bone deposition rather than resorption is taking place from the periodontal membrane side. The labial bone in this case was rather thick, with well developed marrow spaces. There is no inflammation in the periodontal membrane, but mild subacute inflammation in the granulation tissue that extends from the periodontal membrane coronally to the alveolar crest.

Two and Two and One-Half Weeks after Surgery (Cases 3 and 4, Table 1). In the 2 week specimen there is complete epithelial coverage of the area of the experimental surgery, and beginning formation of crevicular epithelium which extends to a mark on the root surface as a result of root planing during the surgery. The regenerated gingiva is made up of vascular granulation tissue with evidence of subacute inflammation.

The alveolar crest is undergoing resorption, both at the top of the crest and on the labial aspect of the alveolar process. There are also separate spicules of necrotic bone being resorbed and slight resorption of the alveolar bone from the periodontal membrane side. Mild subacute inflammation extends into the periodontal membrane.

The 2½ weeks specimen shows very similar findings, except that the bone resorption is more advanced with sequestration (Fig. 3).

Three Weeks after Surgery (Cases 5, 6, 7, 8, Table 1). The experimental areas are covered completely with squamous epithelium and there is beginning parakeratosis of the gingival surface (Fig. 4A). There is also epithelial covering of a shallow new gingival crevice which extends to a demarcation mark from root curettage at the time of the surgery (Fig. 4B). The connective tissue is arranged parallel to the root surface in the regenerated area. There is no evidence of attachment of the granula-



FIGURE 2A. Case 2. One week after surgery. Necrotic and fragmented periosteum over part of labial bone. Granulation tissue extending from periodontal membrane and from marrow spaces. (Magnification X15).

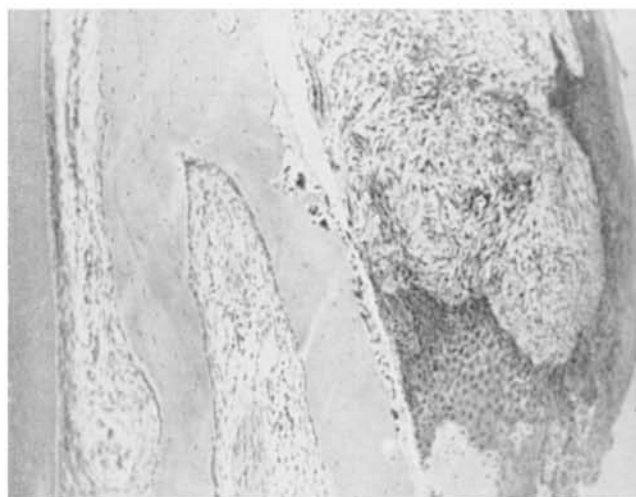


FIGURE 2B. High magnification from Figure 2A. Regenerating epithelium reaching alveolar process. Bone resorption and fibrosis of bone marrow. (Original magnification X80).

tion tissue coronally to the presurgical bone level. Apical to the new crevicular epithelium there appears to be a thin film of a fibrinoid material between the root surface and the granulation tissue for a short distance. Some sections show Malassez epithelial rests between the alveolar crest and the bottom of the new epithelialized crevice. The epithelial rests are residual and indicate old periodontal tissues rather than regenerated new connective tissue. The clinical and histometric measurements indicate a loss of about 1.5 mm of bone in two of the four cases (Table 1).

Some sections show active resorption of the alveolar crest; others show bone regeneration or both resorption and regeneration in alternating areas.

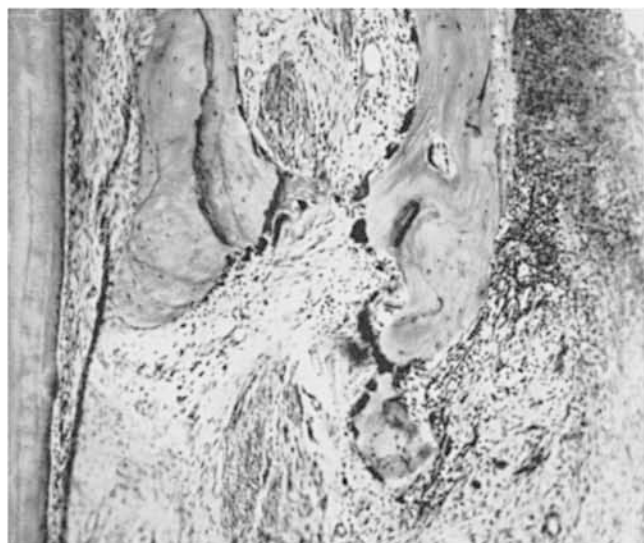

FIGURE 2C. High magnification of alveolar crest from Figure 2A. Bone resorption from fibrotic and inflamed marrow spaces. Granulation tissue extending over alveolar crest and into necrotic debris. (Original magnification X147).

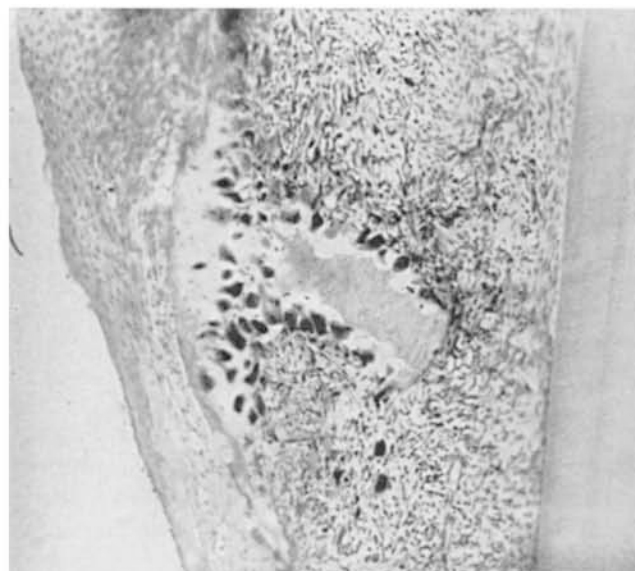


FIGURE 3. Case 4. Two and one-half weeks after surgery. Complete epithelial covering. Bone resorption and sequestration. (Magnification X41).

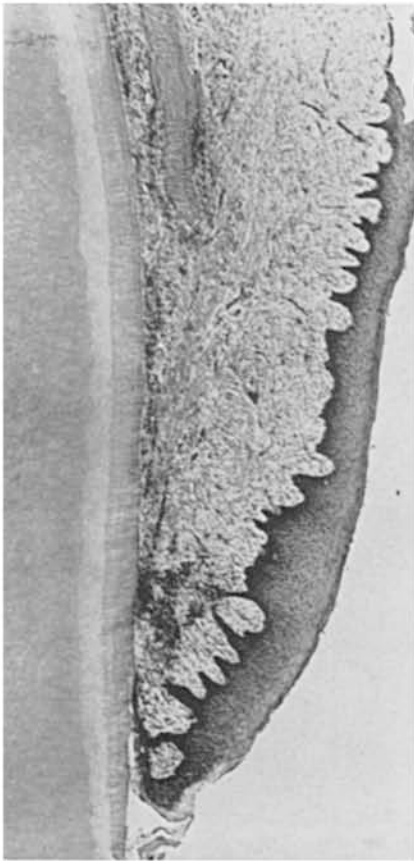


FIGURE 4A. Case 5. Three weeks after surgery. Complete epithelial coverage with new gingival crevice. (Magnification X33).

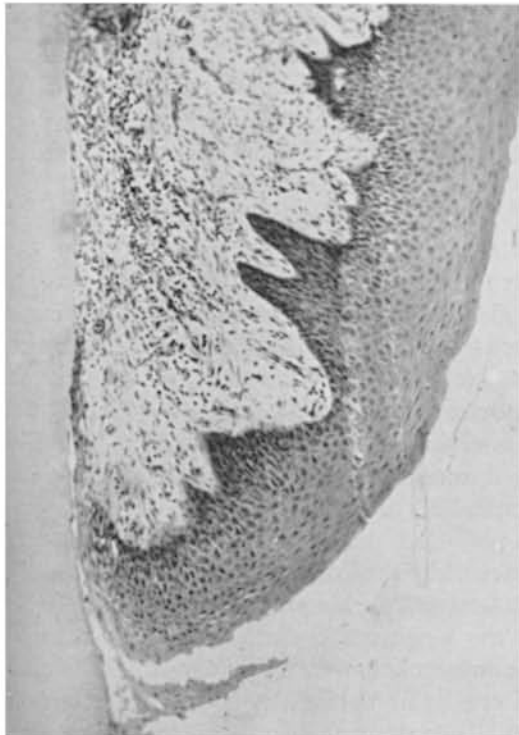


FIGURE 4B. High magnification from same specimen as Figure 4A. Beginning epithelial lining of shallow gingival crevice. Mild chronic inflammation. (Magnification X102).

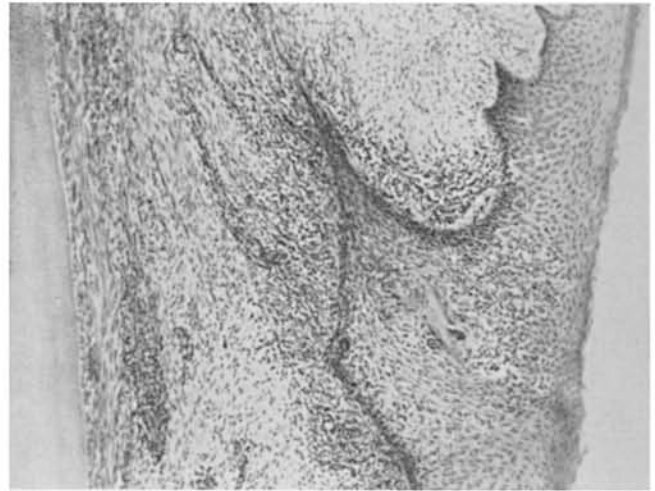


FIGURE 4C. Case 7. Three weeks after surgery. Sequestrum surrounded by epithelium. Chronic inflammation. (Original magnification X102).

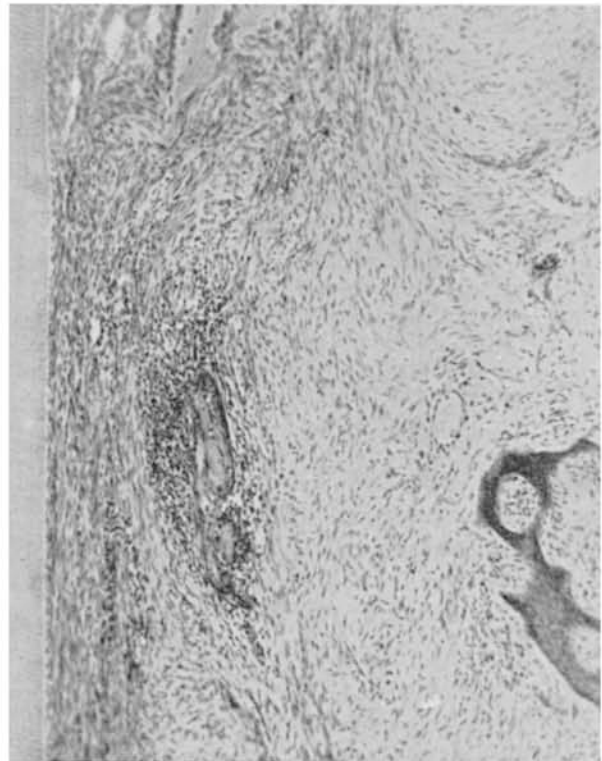


FIGURE 4D. From same specimen as Figure 4C. Sequestrum surrounded by chronic inflammation. Vital bone at alveolar crest. (Magnification X102).

Three of the specimens include small sequestra surrounded by foci of chronic inflammation or epithelial projections (Fig. 4C and 4D). Diffuse chronic inflammation is seen in the entire area of experimental surgery in all cases.

The inflammation is most severe at the bottom level of the new crevicular epithelium and associated with small sequestra. The gingival fibers have not regained a functional arrangement and the crevicular lining does not

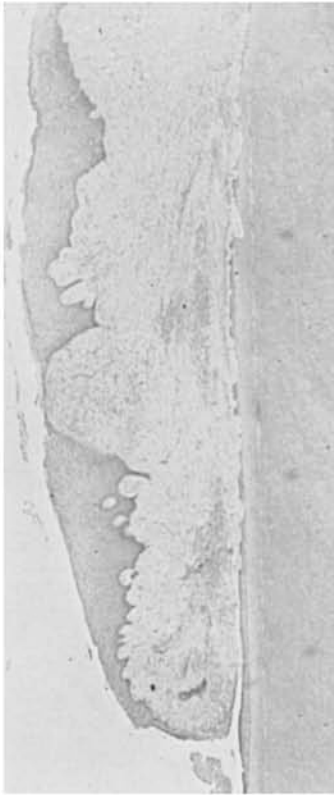


FIGURE 5A. Case 9. Four and one-half weeks after surgery. Irregular epithelial covering. Labial bone missing, 3.9 mm of bone have been lost, according to measurements in Table 1. Resorption lacunae on root surface. Chronic inflammation. (Magnification X22).

appear to serve as an epithelial seal or attachment since there is persistent severe inflammation at the bottom level of this epithelial lining. There is evidence of plaque and early calculus formation on the roots of two of the experimental teeth.

Four and One-Half Weeks after Surgery (Case 9, Table 1). The regenerated gingival tissues, except for a couple of microscopic ulcerations, are covered by squamous epithelium of irregular thickness. There is a shallow gingival crevice (about 0.5 mm) (Fig. 5A) with underlying severe inflammation. According to the combined clinical and histometric measurements, the alveolar crest is 3.9 mm apical to its position at the time of surgery (Table 1). There is reparative osteoblastic activity at the new alveolar crest. Numerous resorption lacunae are seen on the root surface; some of these extend into the dentin (Fig. 5B). There is severe chronic inflammation in the entire healing area. Plaque and early calculus formation is seen supragingivally on the root surface.

Nine to Ten Weeks after Surgery (Cases 10 and 11, Table 1). Almost normal appearing gingival epithelium

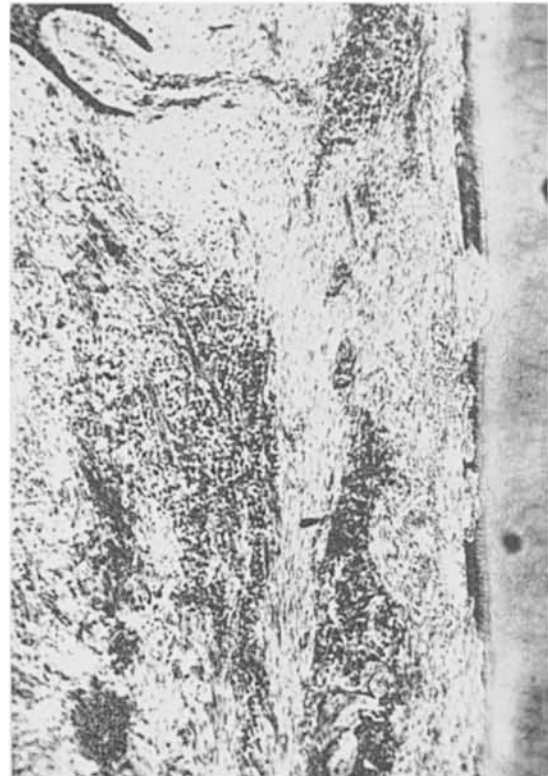

FIGURE 5B. High magnification from Figure 5A. Root resorption extending into dentin. Severe chronic inflammation. (Magnification X102).

with parakeratosis covers the experimental areas (Fig. 6A). The gingival crevice is 0.5 to 1 mm deep and includes a new epithelial attachment in one specimen (Fig. 6B). In the other specimen chronic inflammation extends to the bottom of the epithelialized crevice. A slight amount of new bone has been deposited on the alveolar crest in one specimen (Fig. 6C). There is diffuse mild chronic inflammation throughout the regenerated gingival tissues. A few consecutive slides of one specimen show a narrow tract filled with blood extending 0.5 mm apically to the bottom of the epithelial attachment (Fig. 6D). This is apparently from passing the measuring point too vigorously into the crevice and penetrating into the connective tissue attachment during the session of measurements prior to the removal of the specimen. There is slight roughness of the supragingival root surface and some bacterial plaque and calculus in both specimens.

Thirteen Months Follow-up (Case 12, Table 1). The free gingival margin is rounded and the epithelial covering of the gingiva is normal (Fig. 7). There is mild chronic inflammation corresponding to the middle part of the crevicular epithelium at the cementum-enamel junction. The total crevicular depth and epithelial attachment is 1.8 mm. No inflammation is seen at the bottom of the epithelial attachment. The labial bone is very thin.

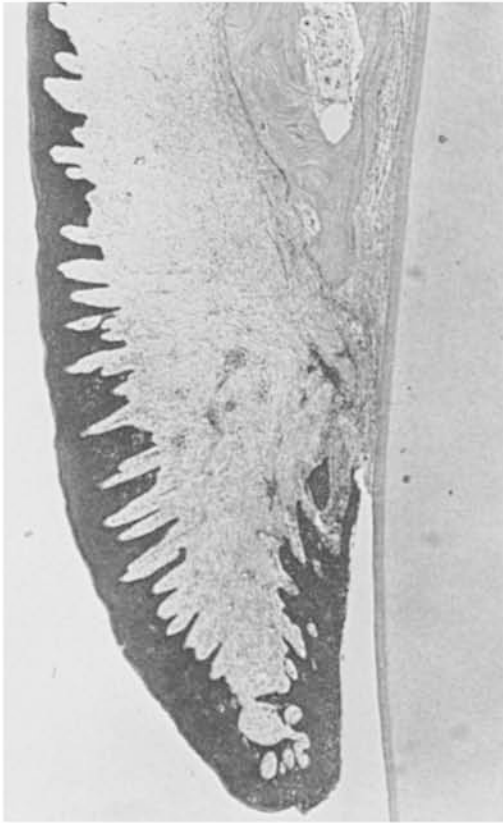


FIGURE 6A. Case 10. Nine weeks after surgery. Almost normal gingiva. Mild chronic gingivitis extending to the alveolar crest. (Magnification X26).

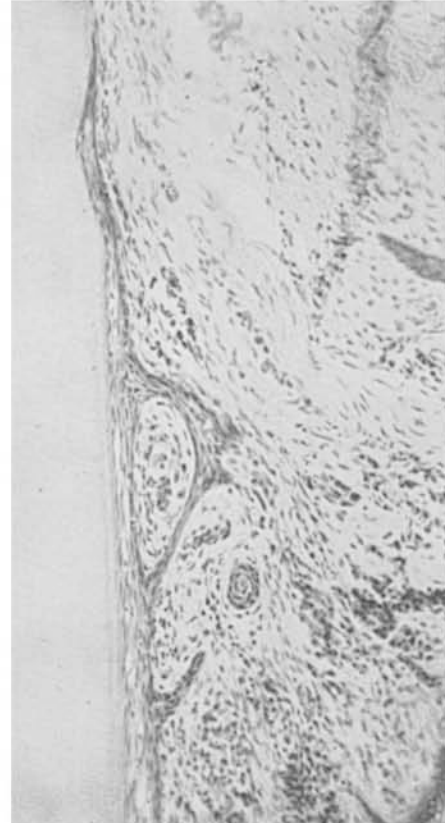


FIGURE 6B. Case 11. Ten weeks after surgery. Long thin epithelial attachment on cementum. No inflammation at apical end of epithelial attachment. (Magnification X173).

The periosteal fibers appear to be compressed and parallel to the tooth surface at the crestal level. There is slight resorption of cementum corresponding to the alveolar crest. This area is undergoing repair, and there is no histological evidence of trauma from occlusion, although clinically the tooth had slightly above average mobility.

DISCUSSION

The clinical, histometric and histologic findings all indicated a more severe reaction to periosteal retention surgery than was anticipated on the basis of previous reports.⁶⁻⁸ The reaction following periosteal retention was only slightly less severe than that which we reported following denudation. The difference most certainly was one of degree rather than a difference in kind of reaction. Unless a definite layer of connective tissue was left on top of the periosteum,⁶ the tendency was for the thin periosteum to undergo necrosis with subsequent healing as occurred after denudation.

Periosteum seemed to give only a limited degree of protection to the underlying bone after the removal of the epithelial covering. Other studies have shown a very mild reaction to split-flap procedures when the flap with

covering epithelium was replaced over the area of surgery.⁸

The continuation of bone resorption after the superficial regeneration of the gingival tissues was striking and lasted for at least 4 weeks after the surgery. This resorption was accompanied by severe inflammation and resembled the resorption which occurred after denudation.¹⁶ However, there seemed to be a tendency to regain most of the lost bone within 9 to 10 weeks after the surgery.

The resorption was not limited to the labial aspect of the alveolar process and the marrow spaces, but occurred also from the periodontal membrane side of the alveolar bone. Only one case showed cemental resorption associated with the bone loss (Fig. 5A). This may have been a case in which the periosteal covering was thin and became necrotic, since this complication occurred more often after denudation of the periosteum.¹⁶

Normal histologic appearance of the gingiva was not regained within 10 weeks after the surgery, and there appeared to be some loss of attachment after the surgery (Table 1).

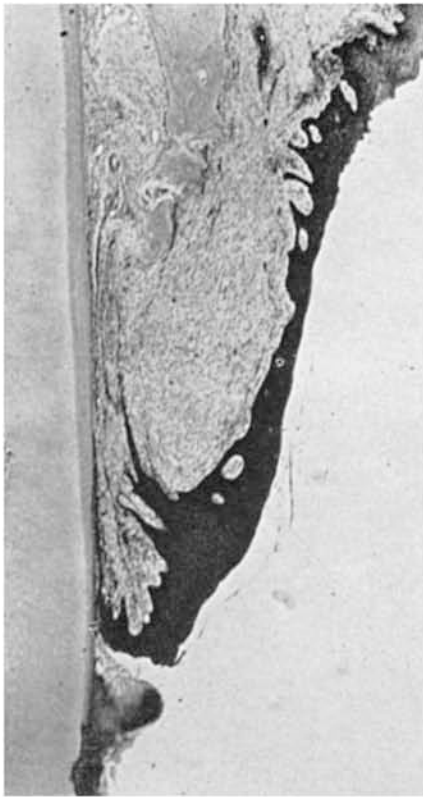


FIGURE 6C. From same specimen as Figure 6B. Irregular gingival epithelium. Mild chronic inflammation. New bone formation at alveolar crest. (Magnification X26).

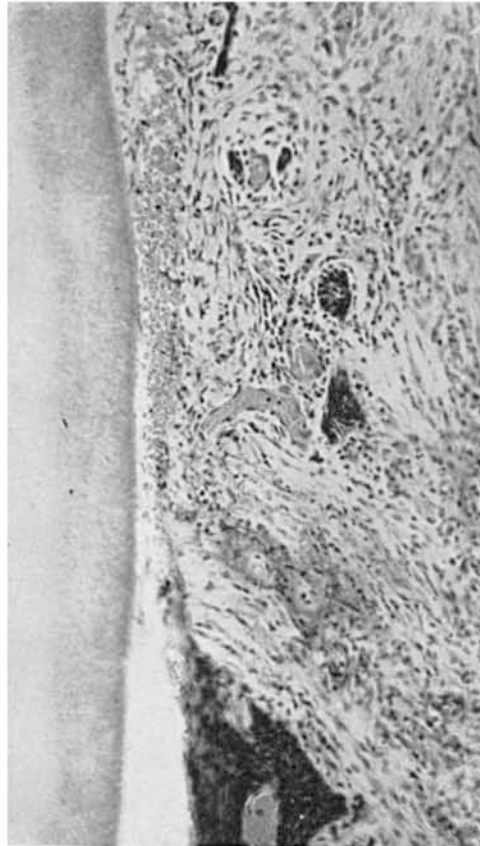

FIGURE 6D. Case 10. Nine weeks after surgery. Narrow tract filled with blood along tooth surface from traumatic probing of crevice depth prior to removal of the specimen. (Magnification X173).

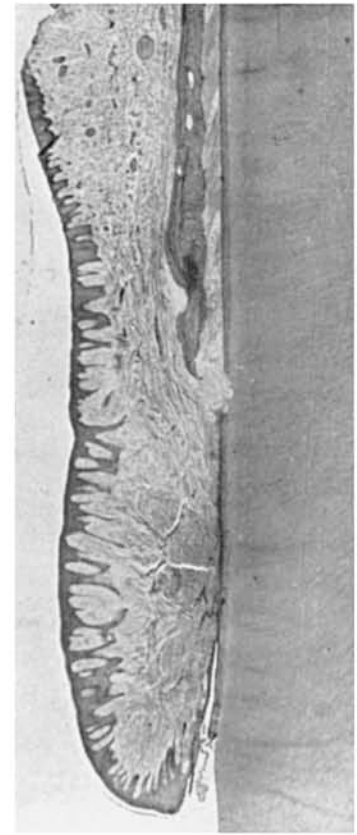


FIGURE 7. Case 12. Thirteen months after surgery. Normal epithelial lining. Mild chronic gingivitis. Slight root resorption at alveolar crest. (Magnification X14).

SUMMARY

The clinical and histologic results following exposure of the periosteum on the alveolar process was studied in 12 patients. Each provided a postsurgical block specimen of the experimental tooth and the surrounding tissues.

Periosteal retention surgery resulted in severe inflammation and resorption of the alveolar process for 3 to 4 weeks after the surgery. Repair approached the presurgical level of bone in 9 to 10 weeks, but the gingiva did not regain its normal histological appearance within this time interval.

CONCLUSIONS

1. Exposure of the periosteum on the alveolar process without subsequent flap coverage results in a severe inflammatory reaction with bone resorption.
2. The degree of bone resorption which occurs following periosteal retention is almost equal to the resorption which occurs following denudation.
3. As thick a layer of connective tissue as is possible should be left over the periosteum if the area of surgery is not going to be covered by an epithelialized flap.

REFERENCES

1. Hilming, F.: Om Betydningen av Höjt Inserterende Ligamenter I de Marginale. Parodontale Lidelsers Klinik. Odont. Tidsk., 50:602, 1942.
2. Goldman, H.: Periodontia, ed. 3. St. Louis, C. V. Mosby Co., 1953.
3. Gottsegen, R.: Frenum Position and Vestibular Depth in Relation to Gingival Health. Oral Surg., Oral Med. and Oral Path., 7:1069, 1954.
4. Robinson, R. E.: Mucogingival Junction Surgery. J. Calif. D. A. and Nevada D. Soc., 33:379, 1957.
5. Hileman, A. C.: Surgical Repositioning of Vestibule and Frenums in Periodontal Disease. J.A.D.A., 55:676, 1957.
6. Wilderman, M. N.: Repair after a Periosteal Retention Procedure. J. Periodont., 34:487, 1963.
7. Glickman, I., Smulow, J., O'Brien, T. and Tanner, R.: Healing of the Periodontium following Mucogingival Surgery. Oral Surg., Oral Med. and Oral Path., 16:530, 1963.
8. Pfeifer, J.: The Reaction of Alveolar Bone to Flap Procedures in Man. Periodontics, 3:135, 1965.
9. Ivancie, G. P.: Experimental and Histological Investigation of Gingival Regeneration in Vestibular Surgery. J. Periodont., 28:259, 1957.

10. Grant, J.: A Histological Study of Repositioning the Attached Gingiva in Periodontal Therapy. *Iowa D. J.*, 44: 62, 1958.

11. Bradley, R.: Histological Evaluation of Mucogingival Surgery. *Oral Surg., Oral Med. and Oral Path.*, 12:1184, 1959.

12. Pennel, B., et al.: Retention of Periosteum in Mucogingival Surgery. *J. Periodont.*, 36:39, 1965.

13. Bohannon, H. M.: Studies in the Alteration of Ves-

tibular Depth. II. Periosteum Retention. *J. Periodont.*, 33: 354, 1962.

14. Corn, H.: Periosteal Separation—Its Clinical Significance. *J. Periodont.*, 33:140, 1962.

15. Ramfjord, S. P. and Costich, E. R.: Healing after Simple Gingivectomy. *J. Periodont.*, 34:401, 1963.

16. Costich, E. R. and Ramfjord, S. P.: Healing after Partial Denudation of the Alveolar Process. *J. Periodont.*, 39:127, 1968.

Abstracts

THE GINGIVAL GIANT CELL GRANULOMA. HISTOCHEMICAL OBSERVATIONS

Shklar, G. and Cataldo, E.

J.A.S.P. 5:303-307, November-December, 1967

Ten gingival giant cell lesions were studied for the following histochemical observations: (1) RNA: moderate amounts of RNA were found in the lower layers of the stratified squamous epithelium and in the giant cells of the granuloma, (2) Metachromia: metachromasia was not observed in the giant cell lesions, (3) Tyrosine: the epithelium and the stratum corneum were lightly and moderately reactive whereas the giant cell lesion was irregularly reactive, (4) Tryptophan: epithelium and the giant cell lesion were non-reactive, (5) Sulfhydryl Groups: epithelium was non-reactive except for the stratum corneum and the giant cell lesion was lightly reactive, and (6) Acid Mucopolysaccharides: with alcian blue there was light reactivity within the giant cell lesion as well as in the lower layers of the epithelium, although most giant cells were non-reactive for acid mucopolysaccharides. Distinct differences were observed in different multinucleated giant cells in studies of tyrosine and sulfhydryl distribution. Some giant cells were essentially non-reactive, while others were moderately or even strongly reactive. *Department of Oral Pathology, Tufts University, School of Dental Medicine, Boston, Massachusetts.*

THE EFFECT OF HYPERVITAMINOSIS D ON THE PERIODONTAL MEMBRANE COLLAGEN IN LATHYRITIC RATS

Shoshan, S., Pisanti, S. and Sciaky, I.

J. Periodont. Res. 2:121-126, 1967

This study was conceived to investigate whether or not incompletely crosslinked collagen may serve as the site of predilection for calcification in hypervitaminosis D. Toxic doses of vitamin D₂ were administered to lathyritic rats which received amino-acetonitrile in drinking water for 15 days. The normal control group received neither the lathyrogen nor toxic doses of vitamin D₂. The periodontal ligament of the molars was studied both histologically and biochemically. The periodontal collagen of the lathyritic animals could be extracted with cold 0.15 M NaCl, while that of the normal controls, or of the animals which received either the vitamin alone or both the lathyrogen and the vitamin, was not extractable. Ossification of the periodontal connective tissue was apparent in the lathyritic group which received toxic doses of the vitamin but not in either lathyrisms or hypervitaminosis alone. It is concluded that whereas the release of calcium from bone or the increased absorption of the mineral from the intestine is affected by vitamin D₂ its deposition in the soft connective tissues may depend on the nature of the protein matrix. Incompletely crosslinked collagen, as in lathyrisms, apparently serves as a cation acceptor, thus contributing to the re-establishment of the calcium balance which

was disturbed during hypervitaminosis D. *Connective Tissue Research Laboratory, Department of Oral Diagnosis and Oral Medicine, Hebrew University, Faculty of Dental Medicine, Jerusalem, Israel.*

ACUTE INFECTIOUS ORAL NECROSIS AMONG YOUNG CHILDREN IN THE GAMBIA, WEST-AFRICA

Malberger, E.

J. Periodont. Res. 2:154-162, 1967

Fifty cases of acute necrotizing disease in children between the ages of 1 to 6 were observed during a 13 month period at the Royal Victoria Hospital, Bathurst, Gambia. The acute infection started as necrosis and ulceration of the interdental papillae and marginal gingiva, forming the characteristic punched-out areas. In the severe cases the attached gingiva became involved with subsequent denudation and sequestration of bone. The final stage was frequently a fulminating necrosis with oro-facial destruction causing a high incidence of death. The disease intensity was inversely related to the child's age. Local factors believed to be related to the acute infection were seen in 361 children in four neighboring Gambian villages. They were poor oral hygiene, gingivitis, food debris in various amounts and chronic periodontal disease. Bacterial smears showed a high incidence of Vincent's organisms. Systemic factors associated with the acute infection were improper nutrition, debilitation, and lowered resistance brought about by endemic infectious diseases. *The H. M. Seldin Center for Oral and Maxillo-Facial Surgery and Institute of Pathology, Rambam Government Hospital, Haifa, Israel.*

TISSUE REACTIONS IN THE ORAL MUCOSA TO CATGUT, SILK, AND MERSILENE SUTURES

Bergenholtz, A. and Isaksson, B.

Odont. Revy 18:237-250, #3, 1967

Tissue reactions to catgut, silk, and mersilene were studied clinically and histologically after suturing in the oral mucosa of three dogs, using atraumatic needles. Six sutures were placed in similar positions and depth in each quadrant at intervals for clinical and histologic examination after 1, 3, 5, and 10 days. The tissue around the sutures was excised, fixed, stained and examined histologically. After 10 weeks the procedure was repeated. In all, 144 sutures were placed, 43 were lost and 85 sections examined. Leukocytic infiltration around the sutures were graded 0-3. Results showed that a large proportion of catgut sutures were lost, and these were thus considered inferior to both other materials. There were no major differences between silk and mersilene, but the latter was considered slightly superior. *Departments of Oral Surgery and Parodontology, University of Umeå, Sweden.*