

# Pacing Swan-Ganz Catheter in Minimally Invasive Mitral Valve Surgery

## *Catéter de Swan Ganz con marcapasos en la cirugía mini-invasiva mitral*

RICARDO LEVIN<sup>1,2,3</sup>, CARLOS RUANO<sup>2</sup>, IGNACIO RÍOS<sup>2</sup>, EDMUND DONAHUE<sup>1</sup>, MICHAEL PITRACEK<sup>1</sup>

### ABSTRACT

**Background:** The use of a lateral mini-thoracotomy presents several advantages over the standard access, such as less surgical trauma, reduced morbidity and mortality, shorter recovery time and better cosmetic results, but presents difficulties if temporary pacing is required.

**Objective:** The aim of this study was to evaluate the therapeutic use of a Swan-Ganz catheter with pacing capabilities and analyze its complications.

**Methods:** Patients undergoing scheduled minimally invasive mitral valve surgery through lateral mini-thoracotomy were included in the study. Therapeutic use of the pacing catheter was defined as the need for pacing due to bradyarrhythmias or conduction disorders or need of increasing heart rate in case of hemodynamic instability. Patients undergoing urgent or emergency surgery were excluded from the study.

**Results:** A total of 517 patients were included in the study; mean age was  $68.3 \pm 10.4$  years and 289 (55.9%) were men; 115 patients (22.2%) underwent mitral valve replacement and 402 (77.7%) mitral valve repair. The following concomitant procedures were carried out: 294 (56.9%) Maze procedures, 182 (35.2%) left atrial appendage closures, 9 (1.7%) atrial septal defect closures and 14 (2.7%) tricuspid valve repair surgeries. In the postoperative period 162 (31.3%) patients required pacing due to bradyarrhythmias in 85 cases (52.47%), conduction disorders in 50 (30.86%), and need to increase heart rate in 27 (16.66%) patients with low cardiac output syndrome. Postoperative mortality was 2.32% (n=12). Fourteen (2.7%) patients presented loss of capture that was resolved with catheter repositioning, while 2 (0.6%) patients presented catheter entrapment requiring reintervention.

**Conclusion:** Almost one-third of the patients undergoing lateral mini-thoracotomy required therapeutic use of the pacing Swan-Ganz catheter. Two patients presented catheter entrapment and required surgical reintervention.

**Key words:** Cardiac pacing, artificial - Catheterization, Swan-Ganz - Minimally invasive surgical procedures - Mitral valve/surgery - Thoracotomy

### RESUMEN

**Introducción:** La cirugía mediante mini-toracotomía lateral presenta ventajas comparativas sobre el acceso convencional como menor trauma quirúrgico, reducida morbimortalidad y un resultado estético superior, pero plantea dificultades en caso de necesitar estimulación eléctrica temporal.

**Objetivo:** Valorar el empleo terapéutico del catéter de Swan-Ganz con marcapasos incorporado como solución a dicho problema y analizar sus complicaciones.

**Material y métodos:** Se incluyeron pacientes programados para cirugía mini-invasiva mitral mediante mini-toracotomía lateral. Se definió empleo terapéutico del catéter al uso debido a bradiarritmias o trastornos de conducción o necesidad de incrementar la frecuencia cardíaca con fines hemodinámicos. Pacientes intervenidos de urgencia o emergencia, fueron excluidos del estudio.

**Resultados:** Fueron incluidos 517 pacientes (289 de sexo masculino, con edad promedio de  $68,3 \pm 10,4$  años); se efectuaron 115 (22,2%) reemplazos y 402 (77,7%) plásticas mitrales. Simultáneamente, se realizaron 294 (56,9%) procedimientos de Maze, 182 (35,2%) cierres de orejuela izquierda, 9 (1,7%) cierres de defectos septales y 14 (2,7%) plásticas tricuspídeas. Ciento sesenta y dos (31,3%) pacientes necesitaron ser marcapaseados; debido a bradiarritmias, 85 (52,47%) pacientes; por trastornos de conducción, 50 (30,86%) pacientes; mientras que otros 27 (16,66%) requirieron incrementar su frecuencia debido a bajo volumen minuto. La mortalidad resultó de 12 (2,32%) casos. Catorce (2,7%) pacientes presentaron pérdida de captura y se resolvieron con el reposicionamiento del catéter, mientras que 2 (0,6%) pacientes presentaron atrapamiento y requirieron reintervención.

**Conclusiones:** Casi un tercio de los pacientes intervenidos mediante mini-toracotomía lateral requirieron del empleo terapéutico del catéter de Swan-Ganz con marcapasos. Dos pacientes presentaron atrapamiento y requirieron resolución quirúrgica.

**Palabras clave:** Estimulación cardíaca artificial - Cateterismo de Swan-Ganz - Procedimientos quirúrgicos mínimamente invasivos - Válvula mitral/cirugía - toracotomía

### Abbreviations

PSGC Pacing Swan-Ganz catheter

LCOS Low cardiac output syndrome

REV ARGENT CARDIOL 2019;87:357-362. <http://dx.doi.org/10.7775/rac.v87.i5.15807>

Received: 07/05/2019 – Accepted: 08/19/2019

Address for reprints: Dr. Ricardo Levin - Maure 1776 1 A CABA, Argentina. E-mail: rllewin@gmail.com

<sup>1</sup> Vanderbilt University Medical Center.

<sup>2</sup> Universidad Abierta Interamericana

<sup>3</sup> Hospital Universitario, Universidad Abierta Interamericana

## INTRODUCTION

The use of a right lateral mini-thoracotomy represents an alternative to conventional sternotomy for patients requiring mitral valve or tricupsid valve procedures. This is the standard procedure adopted by different surgical teams including ours since 2006 due to several advantages such as less surgical trauma, reduced morbidity and mortality, shorter recovery time and better cosmetic results (Figure 1). (1-3)

Because of the proximity to the conduction system and the increased risk of developing new conduction disorders, it is extremely important to have pacing capabilities in patients who undergo mitral or tricupsid valve surgery, especially when concomitant procedures such as the Maze procedure are performed. Epicardial pacing electrodes represent an option in traditional methods of cardiac surgery via median sternotomy; however, in procedures through lateral mini-thoracotomy, it is difficult to place a ventricular epicardial electrode. In this approach, pacing Swan-Ganz catheters (PSGC) (Swan-Ganz Pacing TD catheters model #D200HF7, Edwards Lifesciences) with three atrial and two ventricular electrodes are used (Figure 2 A and B). The aim of this study was to evaluate the therapeutic use of PSGC in minimally invasive surgery in case of bradyarrhythmias or severe conduction disorders, and to analyze the complications associated with its use.

## METHODS

**Population:** The study included patients admitted to a university-based hospital with high volume of cardiovascular surgery and routine use of mini-thoracotomies to treat non-ischemic mitral regurgitation between January 1, 2009 and January 1, 2014. All the patients were scheduled for elective surgery with or without concomitant procedures.

**Operative technique:** The specific details of the procedure have been previously described. Briefly, the chest was opened through a 5- cm right anterolateral submammary incision at the fourth intercostal space. The atrioventricular

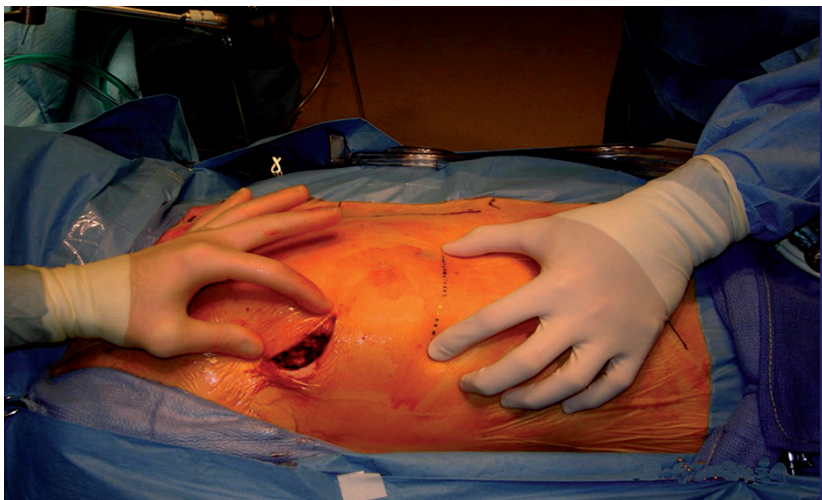
(AV) groove was incised and the left atrium was approached. Carbon dioxide was insufflated into the surgical field to reduce intracardiac air throughout the procedure, while suction was used to maintain a bloodless surgical field. A traditional Carpentier ring was used for mitral valve repair. (3-7)

Therapeutic use of PSGC was defined as the need for atrial, ventricular or atrioventricular pacing due to bradyarrhythmias (sinus bradycardia, nodal rhythm or atrial fibrillation with slow ventricular response) or severe atrioventricular disorders (second or third degree atrioventricular block). The need to increase heart rate due to low cardiac output syndrome (LCOS) in patients with inappropriately low heart rate for the condition was also considered a therapeutic use.

**Exclusion criteria:** Patients undergoing urgent or emergency surgery and those who refused to participate in the study or in whom the pacing PSGC could not be implanted were excluded from the study. In-hospital mortality was defined as mortality within 30 days after surgery or later but within the original hospitalization. Low cardiac output syndrome was considered when cardiac index was  $<2$  L/min/m<sup>2</sup> or in the presence of need for inotropic support or intra-aortic balloon pump to maintain an adequate cardiac index. Prolonged mechanical ventilation was defined as ventilatory support for  $>48$  hours. Perioperative infarction was defined as the association of the following factors: new symptoms (angina or dyspnea) or signs (complex ventricular arrhythmia, development of pathological Q waves in at least two contiguous leads, new persistent left bundle branch block or new regional wall motion abnormality by echocardiography) with troponin I level  $>15$  times the upper reference limit or CK-MB level  $>5$  times the upper reference limit within the first 72 hours. Stroke was defined as a new neurological dysfunction persisting  $>72$  hours, while transient ischemic attack was defined as a new neurological dysfunction persisting  $<72$  hours. Renal failure was considered in the presence of a twofold increase of creatinine levels compared with preoperative levels, or need for dialysis.

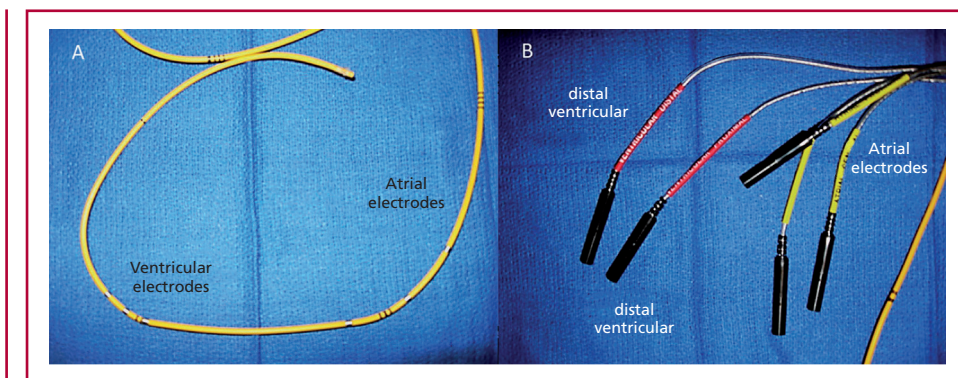
## Associated complications

The complications analyzed were related with PSGC placement (pneumothorax, vascular trauma and severe ventricular arrhythmias, such as ventricular tachycardia or fibrilla-



**Fig. 1.** Access through lateral mini-thoracotomy.

**Fig. 2. A.** The atrial and ventricular electrodes are observed in the catheter structure **r. B.** Atrial and ventricular connectors.



tion) or PSGC infections during the perioperative period, including permanent capture failure or complications during catheter withdrawal.

#### Statistical analysis

Descriptive statistics were used for the analysis. Discrete variables were expressed as numbers and percentages and continuous variables as mean and standard deviation, as applicable. All the statistical calculations were performed using SPSS 17.0 statistical package for Windows (IBM Corp., Armonk, NY, USA).

#### Ethical considerations

The protocol was authorized by the institutional Research Committee, it was approved by the institutional Ethics Committee, and was conducted following the recommendations of the Declaration of Helsinki. All patients gave their informed consent before participating in the study.

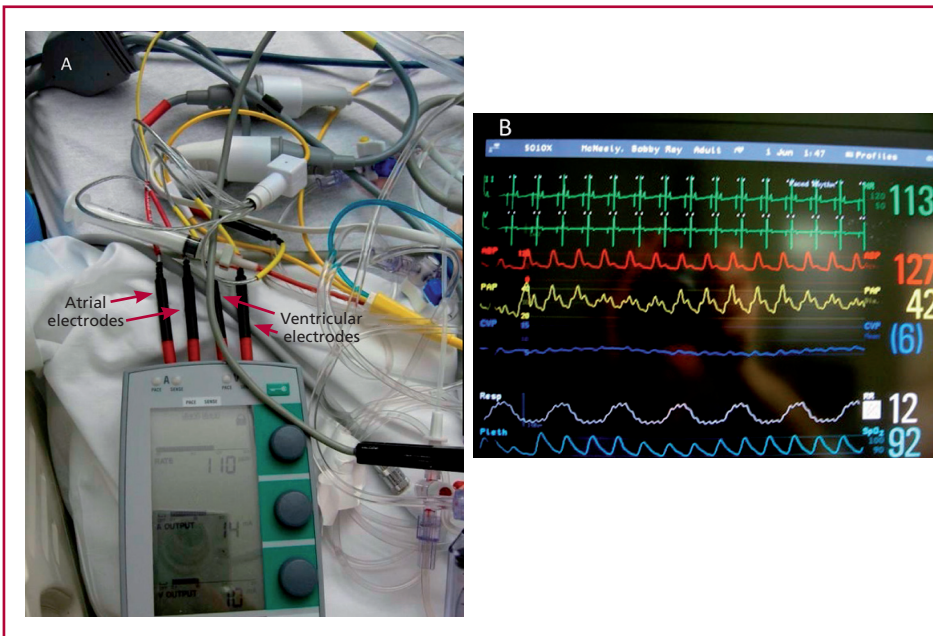
#### RESULTS

During the study period, 518 patients underwent mitral valve surgery through mini-thoracotomy. The PSGC could not be implanted in one (0.19%) patient; thus, the study population consisted of 517 patients. Mean age was  $68.3 \pm 10.4$  years and 289 (55.9%) were men; 115 (22.2%) patients underwent mitral valve replacement and 402 (77.7%) mitral valve repair. The following concomitant procedures were carried out: 294 (56.9%) Maze procedures, 182 (35.2%) left atrial appendage closures, 9 (1.7%) atrial septal defect closures and 14 (2.7%) tricuspid valve repair surgeries. Table 1 shows the baseline characteristics of the population.

The PSGC was placed in the operating room after orotracheal intubation, and effective ventricular capture was confirmed in all the patients. In those patients with sinus rhythm, both atrial and ventricular captures were confirmed (Figure 3). In 496 (95.9%) patients, the right internal jugular vein was accessed for the insertion of the PSGC, and no complications occurred during the procedure. A transesophageal echocardiogram was routinely performed. Then, the patients were positioned in a supine position with the chest slightly turned to the left and the femoral artery or axillary artery was cannulated. After systemic heparinization, patients were placed on cardiopulmonary

bypass and were cooled to  $28^{\circ}\text{C}$ . Ventricular fibrillation was induced through the PSGC by activating rapid atrial pacing at 800 beats/min and hypothermia was initiated. In case concomitant tricuspid valve surgery was performed, the right atrium was opened, a venous cannula was inserted into the superior vena cava and the PSGC was withdrawn during the procedure and reinserted thereafter. A postoperative transesophageal echocardiogram was performed in the operating room to confirm proper valve function. All the patients received a 10-g bolus of epsilon aminocaproic acid, followed by a continuous infusion at a rate of 2 g/h until arrival at the postoperative area. Table II shows the surgical data of the population. In the postoperative period, 162 (31.3%) patients required effective pacing. The indications for pacing were bradyarrhythmias in 85 (52.47%), severe AV block in 50 (30.86%), and a need to increase heart rate in 27 (16.66%) patients with LCOS.

Need for pacing was significantly higher in patients undergoing a concomitant Maze procedure (64.2% v. 35.8%,  $p=0.01$ ). The average time with pacing was  $23.3 \pm 1.5$  hours: 58 (35.8%) patients were paced less than 6 hours, 61 (37.6%) between 6 and 24 hours, 21 (12.9%) between 24 and 36 hours, and 22 (13.6%) more than 36 hours. Fourteen (2.7%) patients presented loss of capture that was resolved after rotating and repositioning the catheter. Among the 22 patients who were paced for more than 36 hours, 12 (2.3%) required a definite pacemaker. Nine (1.7%) patients suffered a postoperative stroke, 4 (0.8%) had a transient ischemic attack, 27 (5.2%) developed LCOS, 12 (2.32%) required re-exploration for bleeding, and 6 (1.1%) presented ventilatory failure requiring prolonged mechanical ventilation. Nine (1.8%) patients developed renal failure and 2 of them (0.4%) required dialysis. None of the patients presented surgical wound infections or perioperative myocardial infarction. Postoperative mortality was 2.32% ( $n=12$ ). The causes of death included multiorgan failure in 4 patients, stroke with extensive brain damage and persistent coma in 3 and irreversible respiratory failure in 4 patients, while one patient died suddenly after being discharged home but within the 30 postoperative days.



**Fig. 3.** A. Access through lateral mini-thoracotomy B. Postoperative result.

Characteristic	Number (N = 517)	%
Male gender (%)	289	55.9%
Age (years)	68.3 ± 10.4	
Body mass index (kg/m <sup>2</sup> )	28.1 ± 5.8	
Hypertension (%)	277	53.5%
Current smoker (%)	203	39.3%
Diabetes (%)	161	31.1%
Dyslipidemia (%)	78	15.1%
Chronic obstructive pulmonary disease (%)	29	5.6%
History of myocardial infarction (%)	32	6.2%
History of myocardial revascularization surgery (%)	27	5.2%
History of percutaneous coronary intervention (%)	31	5.9%
Creatinine level >1.5 mg/dL (%)	48	9.3%
Preoperative dialysis (%)	3	0.6%
Ejection fraction (%)	47.9±14.7	
Functional class	2.3±0.6	
Etiology of mitral valve disease		
Myxomatous degeneration	394	76.2%
Rheumatic fever	110	21.3%
Other	3	0.6%

**Table 1.** General population characteristics

Two (0.6%) patients who underwent concomitant tricuspid valve repair presented PSGC entrapment which required surgical removal.

**DISCUSSION**

The main finding in our series is that, besides its recognized usefulness as a diagnostic and monitoring tool, the Swan-Ganz catheter with pacing capabilities proved to be useful to treat a group of patients who underwent minimally invasive cardiac surgery for non-ischemic mitral valve regurgitation. This is one the largest series analyzing its use. Cardiac surgery

was the last area of surgery to become minimally invasive, a process that began in the mid-1990s with some regularity at the Cleveland Clinic and the Brigham and Women’s Hospital in Boston. The incision first used was a lower hemisternotomy and, more recently, a right thoracotomy. (4) Since the first procedures performed by Navia and Cosgrove, Carpentier et al. in 1996, and Cohn et al. in 1997, this technique has been adopted by several institutions, including ours, as the surgical standard for procedures on mitral and tricuspid valves, with many publications on this topic. (1, 4-10)The benefits of this type of access have been

**Table 2.** Surgical characteristics

Surgical characteristics	Patients (N = 517)	%
Mitral valve replacement (%)	115	22.2%
Mitral valve repair (%)	402	77.7%
Concomitant procedures		
Tricuspid valve repair (%)	14	2.7%
Left atrial appendage closure (%)	182	35.2%
Maze procedure (%)	294	56.9%
Atrial septal defect closure (%)	9	1.7%
Site of arterial cannulation		
Femoral artery (%)	471	91.1%
Axillary artery (%)	44	8.5%
Aorta (%)	2	0.4%
Site of venous cannulation		
Femoral vein (%)	508	98.2%
Femoral vein and vena cava (%)	9	1.7%
Cardiopulmonary bypass time (minutes)	115.7±36.5	
Fibrillatory arrest time (minutes)	85.7±28.4	
Total operative time (minutes)	276.7±68.4	

widely described in the literature and include less surgical trauma and less use of blood products, lower incidence of atrial fibrillation, shorter length of hospital stay, reduced surgical costs, and higher cosmetic outcome. In our study, we focused on the specific use of the PSGC in this type of intervention. (1, 3, 5, 7)

The limitations of the minimally invasive surgery via a right thoracotomy include a strict learning curve and the difficulty to implant a pacing catheter if needed, a common requirement in mitral surgery, especially when concomitant procedures such as tricuspid valve repair or Maze surgery are performed to treat associated arrhythmias. Thus, in 1998, Gordon et al. identified mitral valve surgery, tricuspid valve repair and ablative arrhythmia operations as independent predictors of requirement for permanent pacing, while Berdajs et al. reported an incidence of 23.5% new atrio-ventricular blocks in a series of 391 mitral valve surgeries. (11,12) Moreover, Jouan et al. reported a high incidence (41,2%) of postoperative atrio-ventricular conduction disorders in patients undergoing mitral valve surgery and concomitant tricuspid valve repair. (13)

Therapeutic use of the Swan Ganz catheter with pacing capability: The use of this type of catheter allowed inducing ventricular fibrillation in the operating room in all the cases as it provided transient pacing when bradyarrhythmias or conduction disorders develop, or increased heart rate in the presence of postoperative LCOS in almost one third of the patients operated on in this series. The therapeutic use of this device has been described in several populations of patients undergoing surgery through minimally invasive approaches, even valve surgeries or myocardial revascularization procedures.

The usefulness of this type of catheter in minimally invasive myocardial revascularization surgery was firstly proposed by Colardyn et al. in 1986 and Roth in

1992, followed by Wasnick et al. (in two series) in 1995 and 1997. In the last series, the authors used the device for therapeutic reasons in 31% of their patients (6/15), a percentage similar to our series. (14-17) The number of patients requiring pacing was high (n=162); when these patients were analyzed, need for pacing was higher among those undergoing the Maze procedure (104/162; 64.2%), versus those who did not undergo this type of intervention (58/162; 35.8%), which may in part explain the higher need for pacing.

Catheter-related complications: In our series, transient loss of capture was the most common catheter-related complication that was resolved after the catheter was repositioned. In two patients the catheter was entrapped and required surgery. In both cases, this complication was related to a combination procedure on the tricuspid valve, confirming the risk of using this catheter in case of tricuspid valve surgery.

In addition to the usual complications of the conventional PSGC catheter, other complications have been reported: diaphragmatic stimulation, generally due to the position of an atrial electrode or the inability to record pulmonary capillary wedge pressure because of the necessary location to obtain effective capture; in this case, a second pulmonary artery catheter may be required for hemodynamic monitoring. Pacing may produce some discomfort in conscious patients, and Nagata et al. reported a case of right ventricle rupture due to a PSGC. (18, 19)

#### Limitations

This a retrospective series from a single center and was not compared with a control group. Nevertheless, and beyond its descriptive nature, the study included a considerable number of patients undergoing mitral and tricuspid valve procedures through a minimally invasive approach performed by an experienced team.

## CONCLUSION

The use of the Swan-Ganz catheter with pacing capabilities was useful not only to induce ventricular fibrillation in the operating room but also allowed resolving the need for temporary pacing after minimally invasive surgeries via lateral thoracotomy, demonstrating the diagnostic and therapeutic use of the device. Although few severe complications occurred (two entrapped catheters), surgery was required to solve the problem, confirming the high risk associated with the use of this catheter in tricuspid valve surgeries.

## Conflicts of interest

None declared.

(See authors' conflicts of interest forms on the website/ Supplementary material).

## REFERENCES

- Cohn LH, Adams DH, Couper GS, Bichell DP, Rosborough DM, Sears SP, et al. Minimally invasive cardiac valve surgery improves patient satisfaction while reducing costs of cardiac valve replacement and repair. *Ann Surg* 1997;226:421-8. <http://doi.org/cn5bfn>
- McClure RS, Cohn LH, Wiegerinck E, Couper GS, Aranki SF, Bolman RM 3rd, et al. Early and late outcomes in minimally invasive mitral valve repair: An eleven-year experience in 707 patients. *J Thorac Cardiovasc Surg* 2009;137:70-5. <http://doi.org/fc7t66>
- Umakanthan R, Leacche M, Petracek MR, Kumar S, Solenkova NV, Kaiser CA, et al. Safety of minimally invasive mitral valve surgery without aortic cross-clamp. *Ann Thorac Surg* 2008;85:1544-50. <http://doi.org/fckrms>
- Cohn L, Byrne J. Minimally Invasive Mitral Valve Surgery. *Tex Heart Inst J* 2013;40:575-6.
- Greelish JP, Cohn LH, Leacche M, Mitchell M, Karavas A, Fox J, et al. Minimally invasive mitral valve repair suggests earlier operations for mitral valve disease. *J Thorac Cardiovasc Surg* 2003;126:365-73. <http://doi.org/bmbrws>
- Levin R, Leacche M, Petracek M, Deegan RJ, Eagle SS, Thompson A, et al. Extending the Use of the Pacing Pulmonary Artery Catheter for Safe Minimally Invasive Cardiac Surgery. *J Cardiothorac Vasc Anesth* 2010;24:568-73. <http://doi.org/djd7cn>
- Petracek M, Leacche M, Sollenkova N, Umakanthan R, Ahmad RM, Ball SK, et al. Minimally invasive mitral valve surgery expands the surgical options for high-risk patients. *Ann Surg* 2011;254:606-11. <http://doi.org/b2bbdb>
- Navia JL, Cosgrove DM. Minimally invasive mitral valve operations. *Thorac Surg* 1996;62:1542-4. <http://doi.org/d9wem3>
- Carpentier A, Loulmet D, Carpentier A, Kieffer JP, Tournay D, Guibourt P, et al. First open heart operation (mitral valvuloplasty) under videosurgery through a minithoracotomy. *Comptes Rendus de L Academie des Sciences III* 1998;321:437-42. <http://doi.org/dxjw7w>
- Brittain EL, Goyal SK, Sample MA, Leacche M, Absi TS, Papa F, et al. Minimally-Invasive Fibrillating Mitral Valve Replacement for Patients with Advanced Cardiomyopathy: a safe and Effective Approach to Treat a Complex Problem. *J Thorac Cardiovasc Surg* 2014;148:2045-51. <http://doi.org/f6pxcd>
- Gordon RS, Ivanov J, Cohen G, Ralph-Edwards AL. Permanent cardiac pacing after a cardiac operation: Predicting the use of permanent pacemakers. *Ann Thorac Surg* 1998; 66:1698-1704. <http://doi.org/czsmtd>
- Berdajs D, Schurr UP, Wagner A, Seifert B, Turina MI, Genoni M, et al. Incidence and pathophysiology of atrioventricular block following mitral valve replacement and ring annuloplasty. *Eur J Cardiothorac Surg* 2008;34:55-61. <http://doi.org/d42v44>
- Jouan J, Mele A, Forens E, Chatellier G, Carpentier A, Achouh P, et al. Conduction disorders after tricuspid annuloplasty with mitral valve surgery: Implications for earlier tricuspid intervention. *J Thorac Cardiovasc Surg* 2016;151:99-103. <http://doi.org/f74g3f>
- Colardyn F, Vandenbogaerde J, De Niel C, Jordaens L. Ventricular pacing via a Swan Ganz catheter: a new mode of pacemaker therapy. *Acta Cardiol* 1986;41:23-9.
- Roth JV. Temporary transmyocardial pacing using epicardial pacing wires and pacing pulmonary artery catheters. *J Cardiothorac Vasc Anesthesia* 1992;6:663-7. <http://doi.org/fhczq8>
- Wasnick JD, Hoffman WJ, Acuff T, Mack M et al. Anesthetic management of coronary artery bypass via minithoracotomy with video assistance. *J Cardiothorac Vasc Anesthesia* 1995; 9:731-3. <http://doi.org/dnw328>
- Wasnick J and Acuff T. Anesthesia and minimally invasive thoracoscopically assisted coronary artery bypass: A brief clinical report. *J Cardiothorac Vasc Anesthesia* 1997;11:552-5. <http://doi.org/b98wkx>
- Zaidan J and Freniere S. Use of a Pacing Pulmonary Artery Catheter during Cardiac Surgery. *Ann Thorac Surg* 1983; 35:633-6. <http://doi.org/bdzgzh>
- Lichtental P, Wade L, Collins JT. Multipurpose Pulmonary Artery Catheter. *Ann Thorac Surg* 1983; 36:493. <http://doi.org/dp5cw4>