



# Anatomy

Faculty of Medicine - JU2017

Number >>

9

Doctor

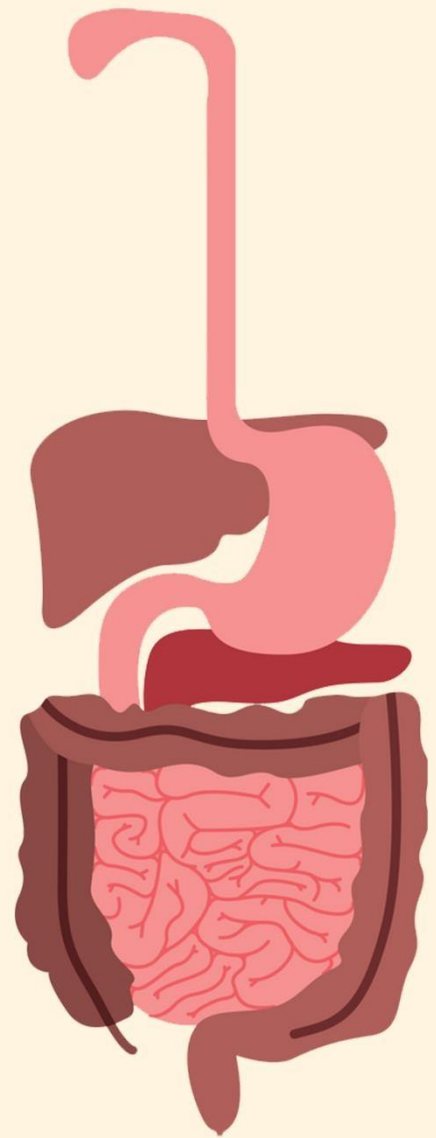
Al-Mohtaseb

Done By

Riham Abu Arrah

Corrected By

Rand Abu Anzeh

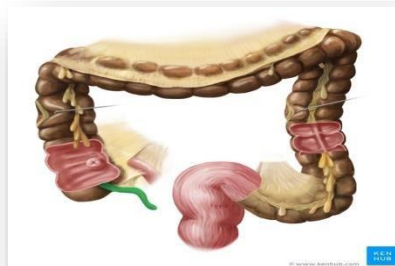

2<sup>nd</sup> system - GI



# Appendix

- Appendix is a lymphoid tissue that is involved in immunity (especially in children). If appendix is resected, other lymphoid tissues in the body can compensate.
- Although it is a part of GIT (mid gut), it has no role in absorption or digestion.
- It has a very narrow lumen.
- It has a muscular layer in its wall.
- It varies in length: from 3 to 5 inches, some books state that it is between 2 to 22 cm; it could be very short or very long.
- In case of inflammation: expansion of the appendix occurs resulting from edema and the engorgement of blood.
- Attached posteromedially to the cecum about 1 inch below the ileocecal junction.
- The remainder of the appendix is in the free edge of Mesoappendix (a short mesentery attached to the mesentery of the small intestine).
- The Mesoappendix contains the appendicular vessels and nerves.
- It has a complete peritoneal covering → intraperitoneal organ.
- Tenia coli of cecum reach the base of the appendix.
- Two folds of mucosa surrounding ileocecal opening are responsible for the closure of this opening.



**Position of the Appendix:** It lies in the right iliac fossa, and in relation to the anterior abdominal wall.

- 1) Retrocecal (in retrocecal recess behind cecum) in 74% of people: most common site.
- 2) pelvic: in pelvis related to Rt. Ovary and uterine tube in 21% of people.

→ If a woman is having a severe pain in the right iliac fossa, you have to determine whether it is appendicitis or menstrual cycle?

- 3) Subcecal: below cecum in 3.5% of people.
- 4) Preileal: in front of ileum in 1% of people.
- 5) Postileal: behind the ileum in 0.5% of people.

### Surface anatomy of appendix = McBurney's point

To determine the location of the base of appendix (regardless of its position: retrocecal, pelvic,...) from the anterior abdominal wall.

McBurney's incision → parallel to inguinal ligament and pass through McBurney's point.  
(Old technique)

#### Steps:

- A. Surgical cut of the skin, superficial fascia, muscles: external oblique- internal oblique-transversus abdominis, transversalis fascia and finally peritoneum).
  - B. Two ligations/stitches of the base will be done.
  - C. Cut of appendicular artery and vein.
- To reach the appendix during operation, follow the tenia coli which converge toward the appendix.
  - The patient needs to stay in hospital for 7-10 days.

Nowadays: endoscope is used instead, accompanied by surgical instruments passing through 3 openings around the umbilicus (6hs hospitalization).



### Blood supply of the appendix:

Appendicular artery (runs in the free margin of the mesoappendix); a branch of posterior cecal artery; from superior mesenteric artery.

### Venous drainage of the appendix:

Appendicular vein drains into posterior cecal vein to superior mesenteric vein, then into portal vein.

## Lymphatic drainage of the appendix:

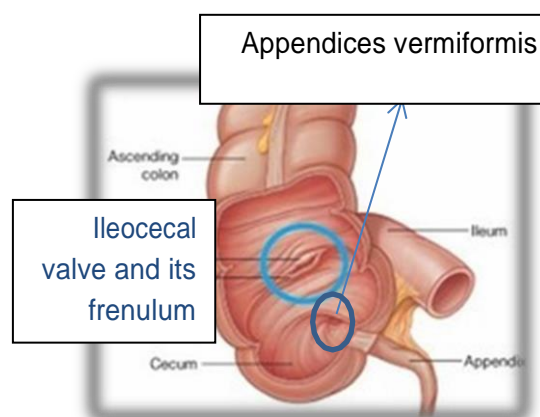
Lymph nodes in the mesoappendix to sup mesenteric lymph nodes around the origin of superior mesenteric artery.

## Nerve supply of the appendix:

The appendix is supplied by the sympathetic and parasympathetic (vagus) nerves from the superior mesenteric plexus.

Afferent nerve fibers concerned with the conduction of visceral pain from the appendix accompany the sympathetic nerves and enter the spinal cord at the level of the 10th thoracic segment.

T10 supplies the appendix, the peritoneum over, and has a dermatome (supplying skin around umbilicus). Therefore, appendicitis patients will suffer from umbilical pain first then localized pain in the right iliac fossa.



## Clinical notes

- Appendectomy is the only line of treatment for appendicitis; because of the narrow lumen, so any infection will obstruct the appendix causing edema, engorgement of blood, expansion, rupture and peritonitis, it may be fatal.
- You have to treat in suspicion.
- No sedation or antibiotics must be given.
- Appendix has only 1 arterial supply; any thrombosis will cause gangrene/degeneration of the tissue → perforation → left paracolic gutter.
- In contrast to acute cholecystitis (more than one artery supplying the gallbladder: cystic artery + arterial supply directly from the liver): no gangrene.

## Ascending Colon

- is about *5 inches* (13 cm) long.
- It extends upward from the cecum to the inferior surface of the right lobe of the liver, where it turns to the left forming the right colic flexure, then becomes continuous with the transverse colon.
- It lies in the right lower quadrant, considered as a part of the midgut.
- The peritoneum covers the front and both sides of the ascending colon, fixing it to the posterior abdominal wall: **Retroperitoneal organ**.
- Paracolic gutter presents on medial and lateral sides, that aids in the passage of fluid and infections.
- Taenia coli, sacculations & appendices epiploica are present.
- Left colic flexure (splenic flexure) is higher than the right colic flexure, and is attached to phrenicocolic ligament.
- Phrenicocolic ligament (between the diaphragm and splenic flexure) has three functions:
  - a. Fixation of the left colic flexure.
  - b. Support the spleen which lies above.
  - c. Prevent infection to pass under diaphragm.

→ Infection in the left side will spread down to the pelvis and won't spread up toward the diaphragm, while in the right side, it may reach subdiaphragmatic space.

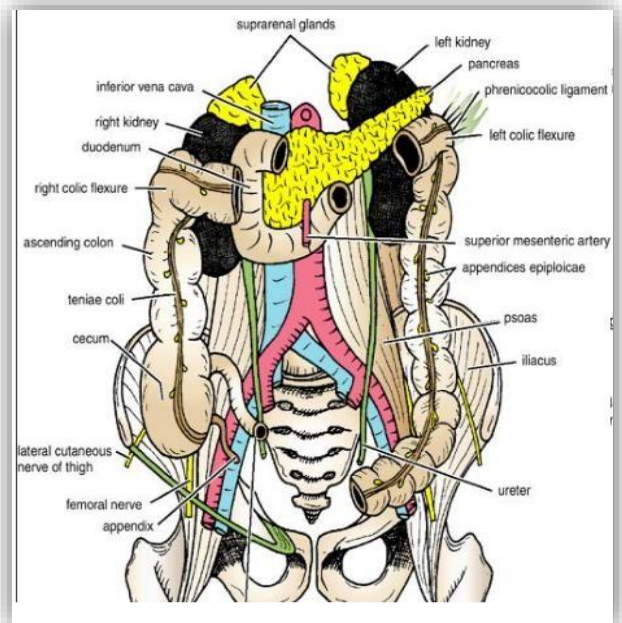
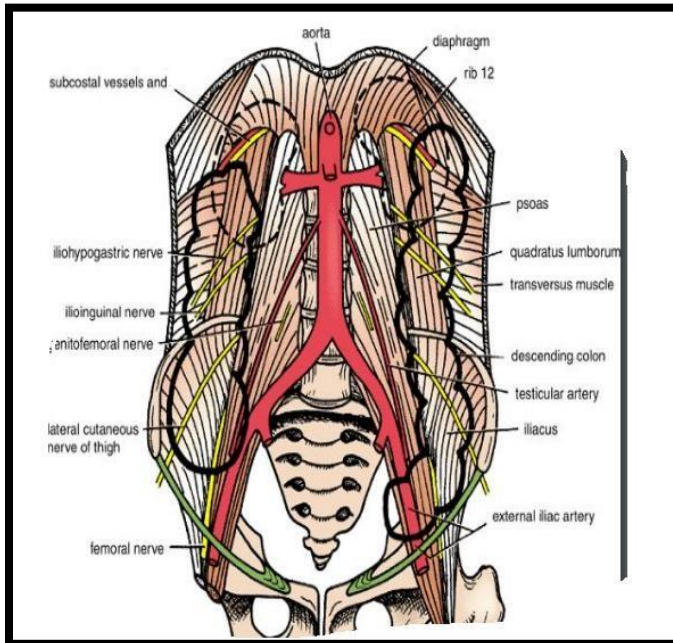
### Relations of ascending colon

- Anteriorly:

1. Anterior abdominal wall.
2. The greater omentum.
3. Coils of small intestine.

- Posteriorly:

1. The iliacus
2. The iliac crest
3. Quadratus lumborum
4. The origin of the transversus abdominis muscle.
5. The lower pole of the right kidney
6. The iliohypogastric nerve and the ilioinguinal nerves cross behind it.



### Blood Supply of Ascending colon

- Upper part of the ascending colon is supplied by right colic branches of the superior mesenteric artery
- Lower part of the ascending colon is supplied by the ileocolic artery which is a branch of the superior mesenteric artery

Ileocolic artery also supplies cecum and ileum.

### Venous drainage of Ascending colon

The veins correspond to the arteries and drain into the superior mesenteric vein.

### Lymphatic drainage of Ascending colon

The lymphatic vessels → lymph nodes lying along the course of the colic blood vessels → the superior mesenteric nodes.

### Nerve Supply of ascending colon

Sympathetic (from superior mesenteric ganglia) and parasympathetic (vagus) nerves from the superior mesenteric plexus.

## Transverse Colon

- is about 15 in. (38 cm) long.  
extends across the abdomen.
- It begins at the right colic flexure below the right lobe of the liver then ascends to the left colic flexure below the spleen.
- occupying the umbilical region.
- Hangs downward.
- Taenia coli, sacculations & appendices epiploicae are present.
- Intraperitoneal organ** (covered by transverse mesocolon)
- Transverse mesocolon is formed by the two layers of greater omentum (ant and post) descending from stomach covering superior and inferior surfaces of the **transverse colon**, respectively. Then, these two layers blend together and go to posterior abdominal wall, specifically the anterior border of pancreas.
- The position of the transverse colon is extremely variable and may sometimes reach down as far as the pelvis.
- Proximal two thirds: midgut.
- Distal third: hindgut.

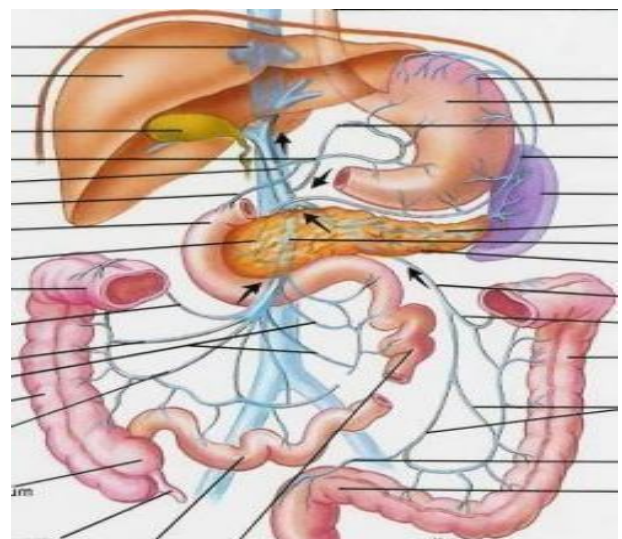
### Relations of Transverse colon

- Anteriorly:

- I. The anterior abdominal wall (umbilical and hypogastric regions).
- II. The greater omentum.
- III. Coils of small intestine may be found. This depends on the length of mesocolon: if it is long, coils of intestine are present. If it is short, no coils of small intestine will be present.

- Posteriorly:

- I. The second part of the duodenum.
- II. The head of the pancreas.
- III. The coils of the jejunum and ileum.



## Blood Supply of transverse colon

- The proximal two thirds are supplied by the middle colic artery, a branch of the superior mesenteric artery.
- The distal third is supplied by the left colic artery, a branch of the inferior mesenteric artery.

## Venous Drainage of transverse colon

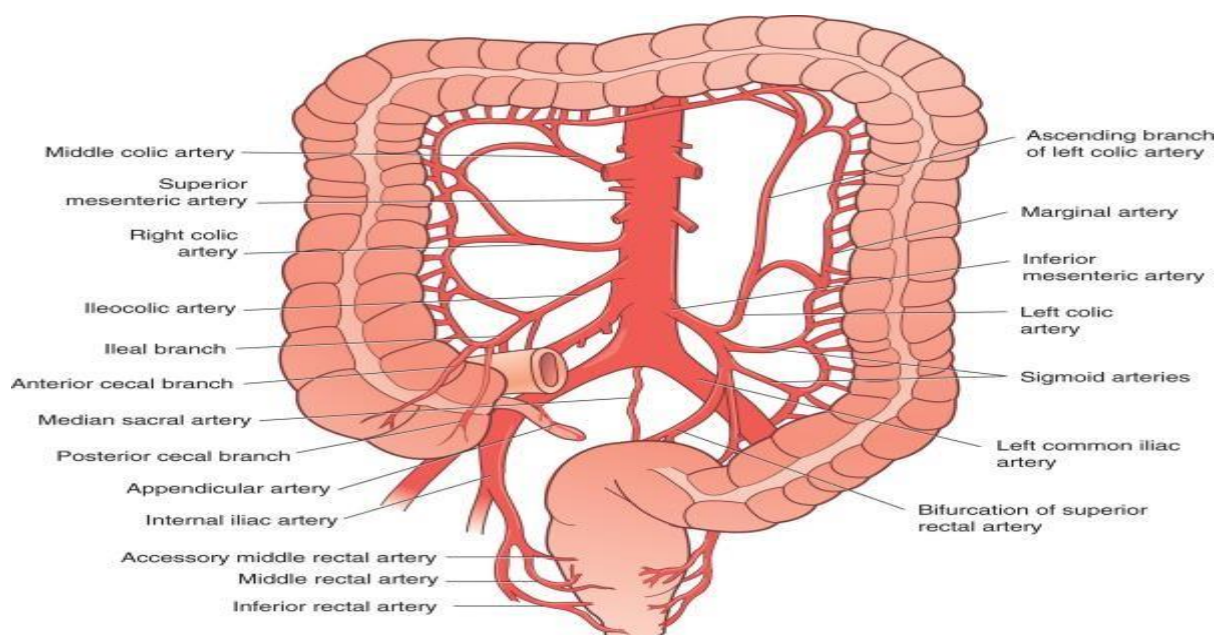
The veins correspond to the arteries and drain into the superior & inferior mesenteric veins.

## Lymphatic Drainage of transverse colon

- The proximal two thirds drain in the colic nodes and then into the superior mesenteric nodes
- The distal third drains in the colic nodes and then into the inferior mesenteric nodes.

## Nerve Supply of transverse colon

- The proximal two thirds are innervated by sympathetic (superior mesenteric ganglia) and parasympathetic (vagal nerves) through the superior mesenteric plexus around superior mesenteric artery.
- The distal third is innervated by sympathetic (inferior mesenteric ganglia) and parasympathetic pelvic splanchnic nerves (S2, S3, S4) through the inferior mesenteric plexus around inferior mesenteric artery.





## Descending Colon

- ✚ is about 10 inches (25 cm) long.
- ✚ It extends downward from the left colic flexure, to the pelvic brim (inlet of pelvis), where it becomes continuous with the sigmoid colon (pelvic colon).
- ✚ The peritoneum covers the front and both sides of descending colon → **retroperitoneal organ**.
- ✚ Paracolic gutter is present on medial and lateral borders of descending colon.
- ✚ Fixed in the posterior abdominal wall.
- ✚ Part of the hindgut.
- ✚ Taenia coli, sacculations & appendices epiploicae are present.

### Relations of Descending colon

- Anteriorly:
  1. The anterior abdominal wall.
  2. The greater omentum.
  3. Coils of small intestine.
- Posteriorly:
  1. The lateral border and inferior border of the left kidney.
  2. The origin of the transversus abdominis muscle.
  3. The quadratus lumborum.
  4. The iliac crest.
  5. The iliacus.
  6. The left psoas.
  7. The iliohypogastric and the ilioinguinal nerves.
  8. The lateral cutaneous nerve of the thigh.
  9. The femoral nerve.

### Blood Supply of Descending Colon

The left colic (mainly) and the sigmoid branches (mainly supplying sigmoid colon, but some branches supply the end of descending colon) → they are branches of the inferior mesenteric artery.

## Venous Drainage of Descending Colon

The veins correspond to the arteries: drain into the inferior mesenteric vein.

Imp. Note: inferior mesenteric vein drains into splenic vein. splenic vein and superior mesenteric vein form portal vein.

## Lymphatic Drainage of Descending Colon

The colic lymphatic nodes & the inferior mesenteric nodes around the origin of the inferior mesenteric artery.

## Nerve Supply of Descending Colon

The sympathetic (inferior mesenteric ganglia) and parasympathetic pelvic Splanchnic nerves (S2, S3, S4) through the inferior mesenteric plexus around inferior mesenteric artery.

----- End of Large Intestine -----

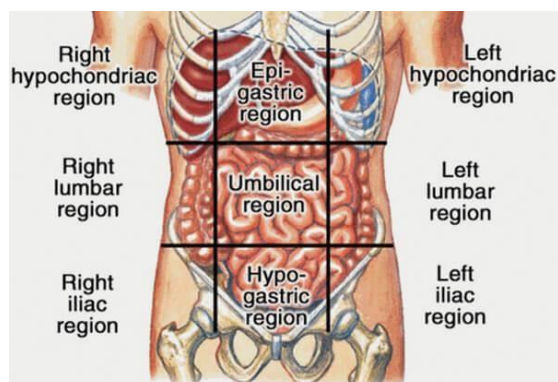
# Liver

- The largest gland in the body.
- Weight of the liver: 1/50 of body weight in adults (1 & 1/5 kg usually) & 1/20 of body weight in infants (more active).
- Any infection in the liver will rapidly spread causing fibrosis/cirrhosis, especially in alcoholic.
- It is an exocrine (secretes bile and bile salts for complete digestion of fat) & endocrine organ (Albumen, globulin, prothrombin, coagulative materials & fibrinogen).
- Formation of heparin & anticoagulant substances.
- Detoxication (of drugs for ex.).
- Detoxication occurs in liver or kidneys. So drugs detoxicated in the liver (ex: morphine) are contraindicated in patients having liver cancer. Instead, drugs detoxicated in kidneys are administered (ex: pethidine).
- Storage of glycogen and vitamins.
- Activation of vitamin D.
- ❖ Metabolism of carbohydrate, fat and protein → portal vein carries absorptive materials from GIT to the liver.

*Note: scientists are trying to plant stem cells nourished by certain protein (still unknown) to ensure their differentiation into hepatocytes.*

### Location of liver:

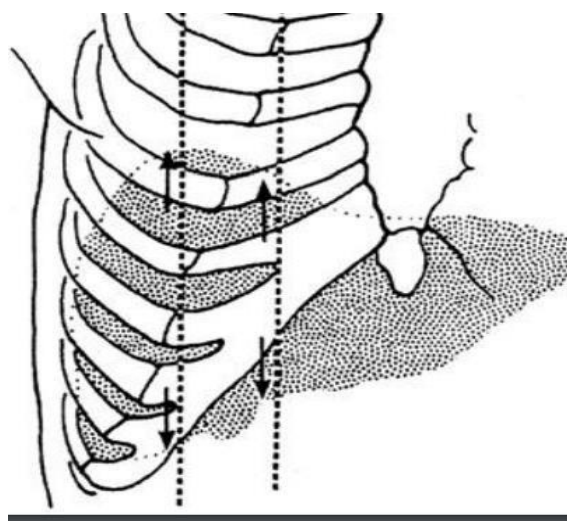
right hypochondrium + epigastrium regions/ the left lobe extends to left hypochondrium.



### Surface anatomy of the liver

It has 5 surfaces (anterior, right, superior, posterior and visceral).

- Visceral structures (IVC, stomach, esophagus, right kidney, duodenum, gallbladder and transverse colon) form **impressions** on visceral surface.
- Superior border pushes the diaphragm toward the chest on the right side reaching the level of 5<sup>th</sup> costal cartilage “The greater part of the liver is situated under cover of the right costal margin.”
- The diaphragm separates the liver from **right & left** pleura, lungs, pericardium and heart.



When examining the liver to detect hepatomegaly, examination must be on the right side of abdomen:

1. Place the index at the inferior border of the liver (on the right side).
2. Ask the patient to take deep breath then exhale (while supine).
3. if the patient is having the disease, you will easily feel the inferior border.

## Lobes of the liver

1. Right lobe.
2. Left lobe.
3. Caudate lobe (next to IVC).
4. Quadrate lobe (next to gallbladder).

Caudate & Quadrate lobes follow left lobe regarding physiology and function, meaning that the right hepatic artery supplies the right lobe, while left hepatic artery supplies left, caudate & quadrate lobes. Also, left hepatic duct comes from left, caudate & quadrate lobes.

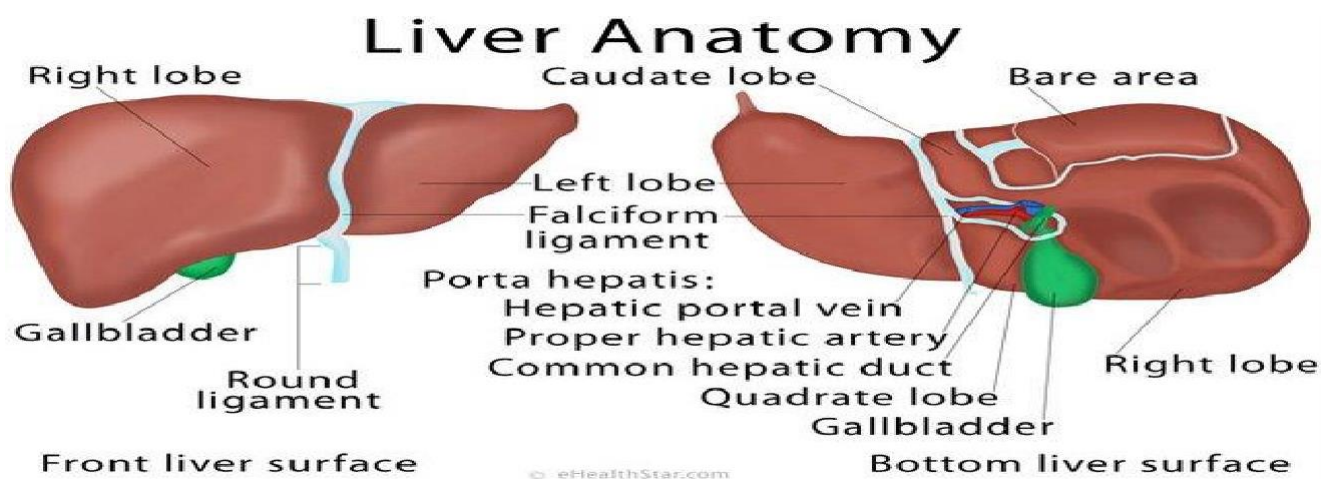
### Notes:

1- Coronary ligaments on the superior border surround Bare area by dividing into left triangular ligament and right triangular ligament.

2- Falciform ligament (thin fold of peritoneum) separates the right lobe from the left lobe & connects the liver to the anterior abdominal wall and diaphragm.

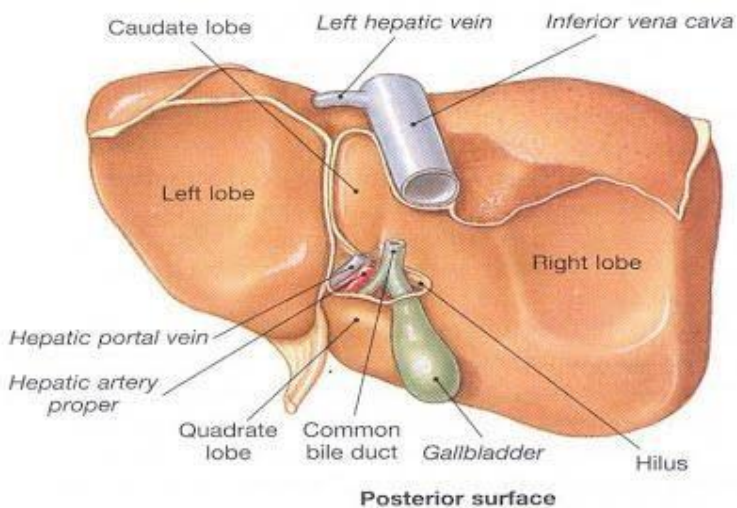
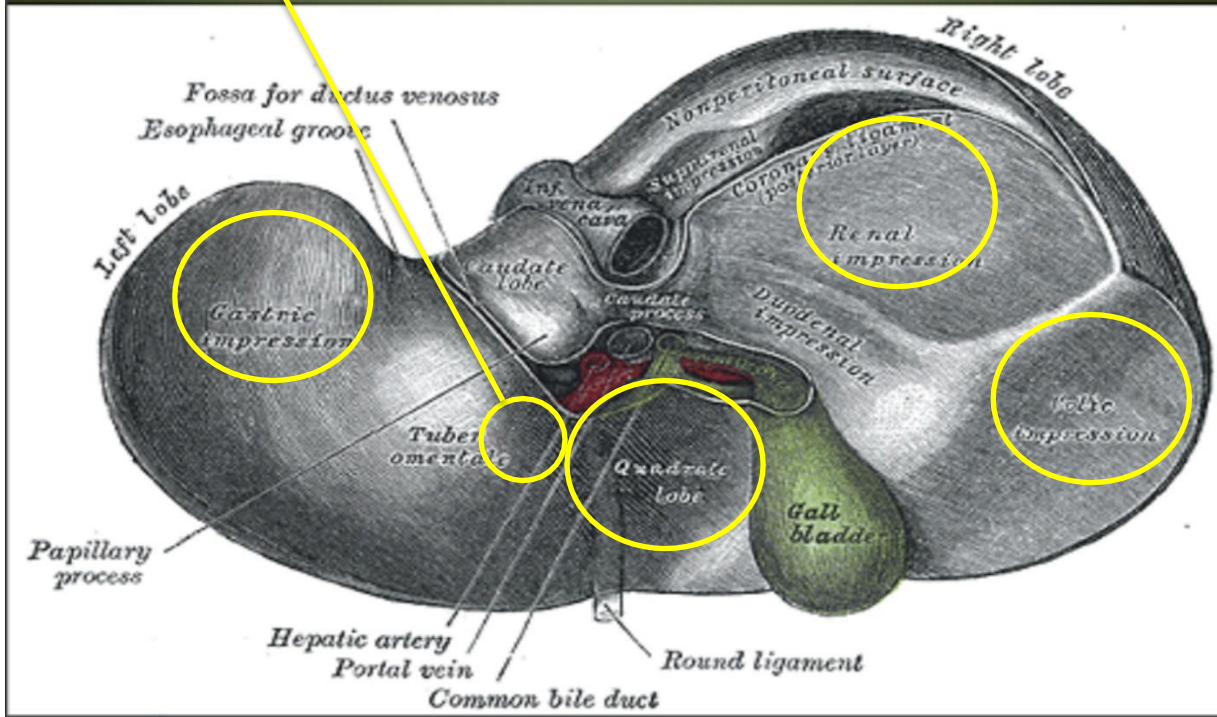
3- In the free edge of Falciform ligament: a round ligament (ligamentum teres) is present, which is an obliterated umbilical vein.

4- Ligamentum Venosum (remnant of the ductus venosum of fetal circulation).



Pyloric impression

## Postero-inferior surface of the liver



### Relations of visceral surface

- Porta hepatic (opening for bile duct, portal vein & hepatic artery) • IVC
- Esophagus
- Rt. Suprarenal gland
- Fissure for Lig. Venosum & lesser omentum
- Tubular omentum
- Right kidney
- Lig. teres
- Right colic flexure
- The stomach
- The duodenum
- The gallbladder

*Good Luck*