

Intrapartum Fetal Monitoring

Dr Amal Barakat
5th & 6th Year Medical Students
Jordan University

Intrapartum fetal surveillance

- **Fetal Heart Rate Monitoring (FHR)**
 - Intermittent auscultation
 - Continuous electronic fetal heart monitoring (EFM)
- **Fetal Scalp blood pH estimation**
- **Intrapartum fetal stimulation tests**
 - Fetal scalp stimulation tests
 - Fetal acoustic stimulation test (FAST)
- **Newer approaches**
 - Fetal ECG
 - Scalp blood lactate estimation
 - Continuous biochemical monitoring
(Pulse oximetry)

Fetal heart rate (FHR) monitoring

- **Fetal heart rate (FHR) monitoring can be done by:**
 - Structured Intermittent Auscultation
 - Continuous Electronic Fetal Monitoring (EFM)
 - 1) External
 - 2) Internal

Structured Intermittent Auscultation

- The FHR should be assessed at least every **30 minutes** in the first stage of labor and every **15 minutes** in the second stage .
- It ensures frequent contact between healthcare professionals and the laboring woman.
- If abnormal, continuous EFM is recommended

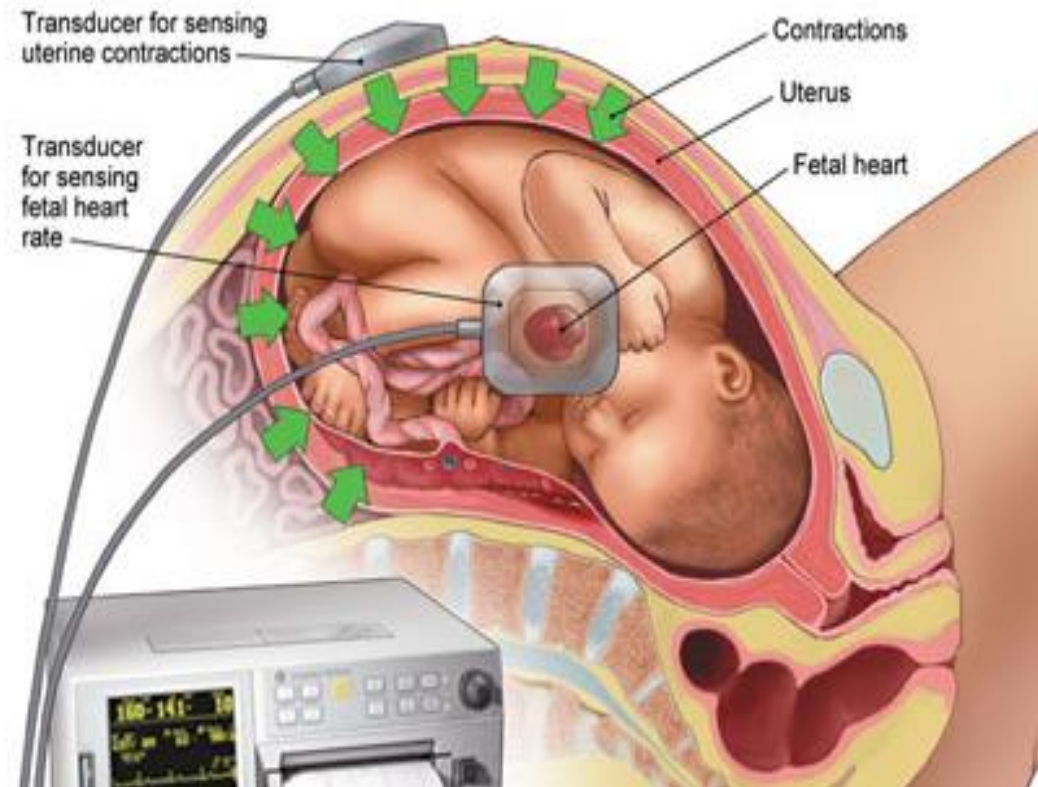
Continuous Electronic Fetal Monitoring (EFM)

- Continuous electronic fetal monitoring is the continuous monitoring of fluctuations of the fetal heart rate (FHR) in relation to maternal contractions and is considered standard practice during active labor.

External Electronic Continuous Fetal Monitoring

- An ultrasound transducer transmits the FHR in beats per minute.
- Non-invasive.
- Does not require cervical dilatation or rupture of membranes.
- Needs readjustment with maternal or fetal movements.
- Difficult to obtain a clear tracing in obese women or those with polyhydramnios.

External Electronic Continuous Fetal Monitoring



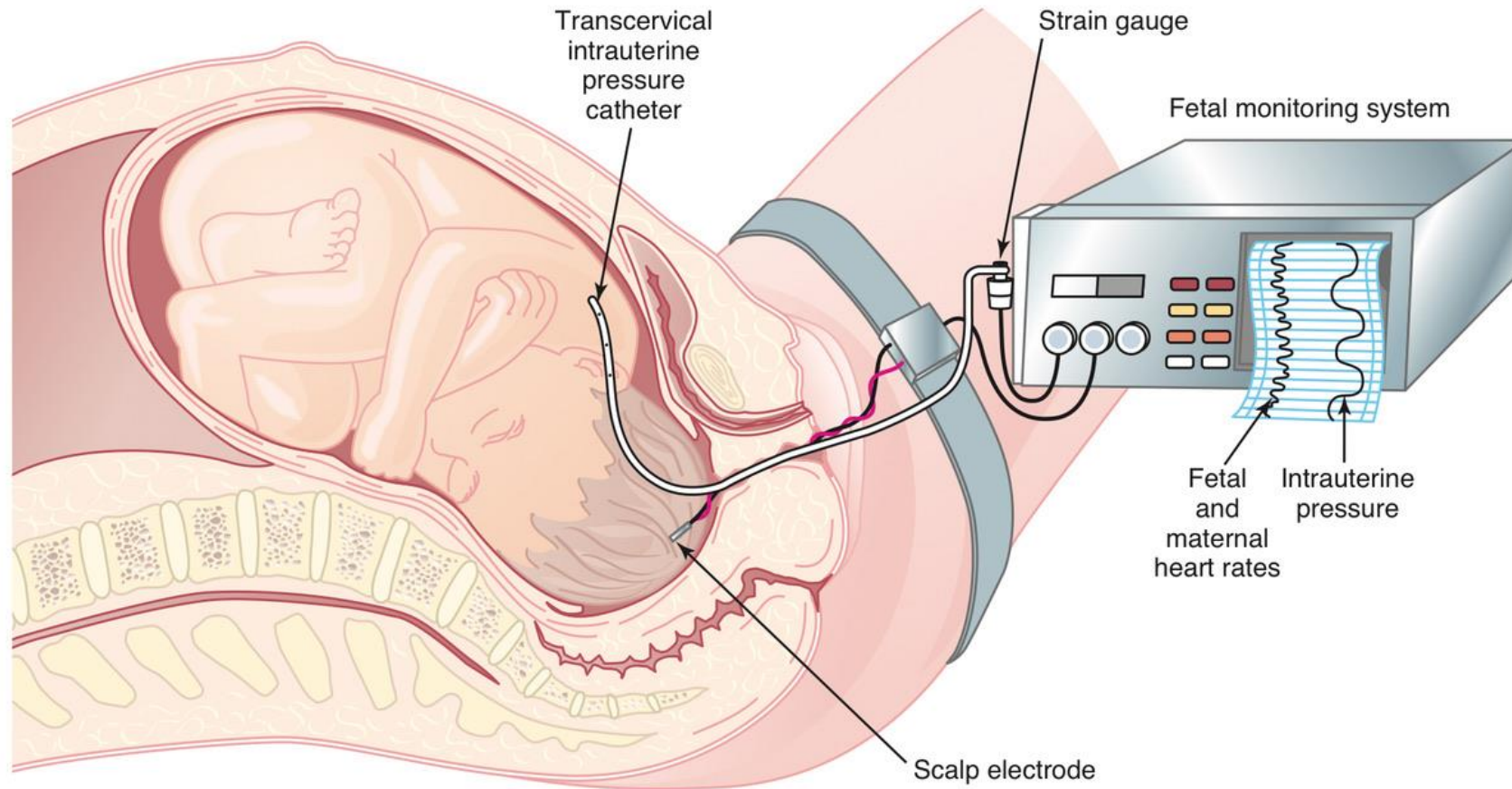
Internal Electronic Continuous Fetal Monitoring

- Performed with a spiral electrode inserted through vagina and cervix and attached to the fetal scalp.
- Indicated when the external tracing is inadequate for accurate interpretation.
- **Contraindications include:** placenta previa, face presentation, unknown presentation, HIV seropositivity, or active genital herpes.
- Internal uterine activity monitoring is done via an intrauterine pressure catheter (IUPC).

External Vs Internal

- External monitors measure only contraction frequency, but an intrauterine pressure catheter can also determine the strength of contractions.
- Placement of an intrauterine pressure catheter (IUPC) or fetal scalp electrode requires cervical dilation and amniotomy, which can increase the risk of **intrauterine infection, fetal injury, and the transmission of herpes simplex virus and hepatitis B or C.**

Internal Electronic Continuous Fetal Monitoring



How to read a CTG?

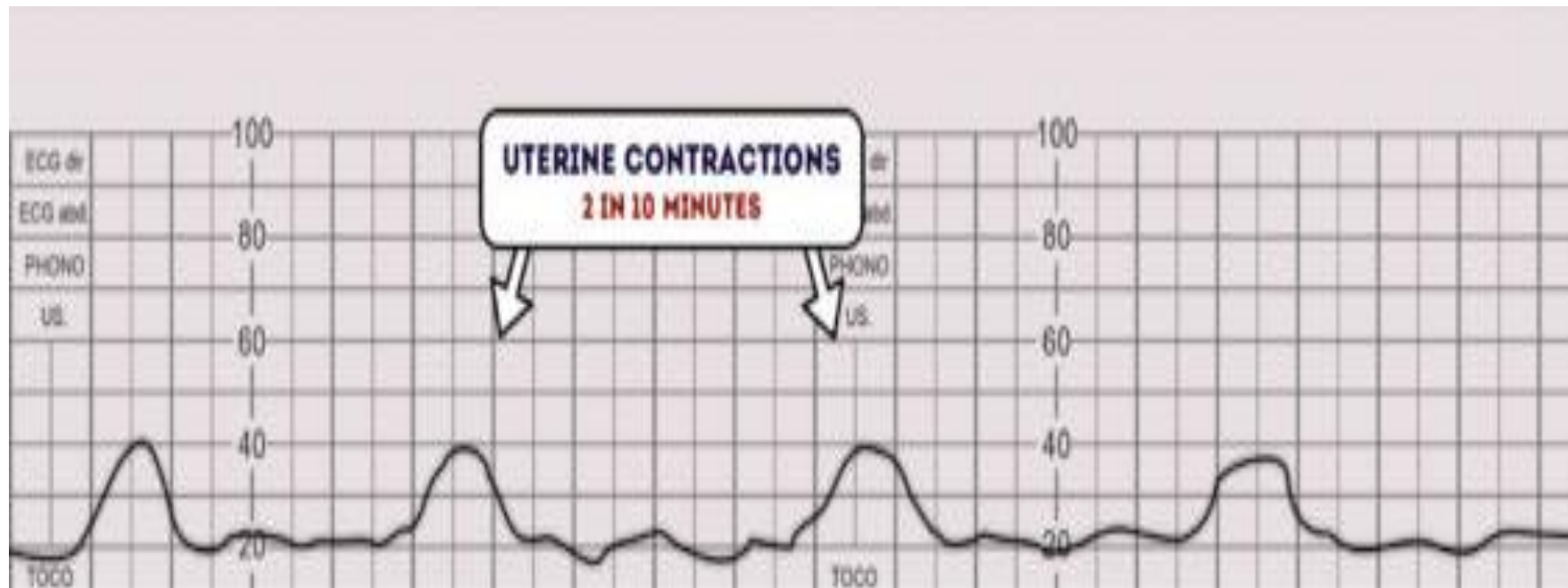
- Name of the patient & Date
- Define the risk
- Contractions (frequency & duration)
- Baseline FHR (normal 110 bpm – 160 bpm)
- FHR variability (beat to beat variation)
- Acceleration (present or absent)
- Deceleration (Early, Late & Variable)
- Assessment & plan of management
- The overall impression can be described as either **reassuring**, **suspicious** or **abnormal**.

Assessment of uterine contractions

- The lowest intrauterine pressure between contractions is called resting tone.
- Normal resting tone is 5-10 mmHg, but during labor it may rise to 10-15 mmHg.
- Pressure during contractions rises to ~25-100 mmHg (varies with stage).
- A resting pressure above 20 mmHg causes decreased uterine perfusion.

Contractions

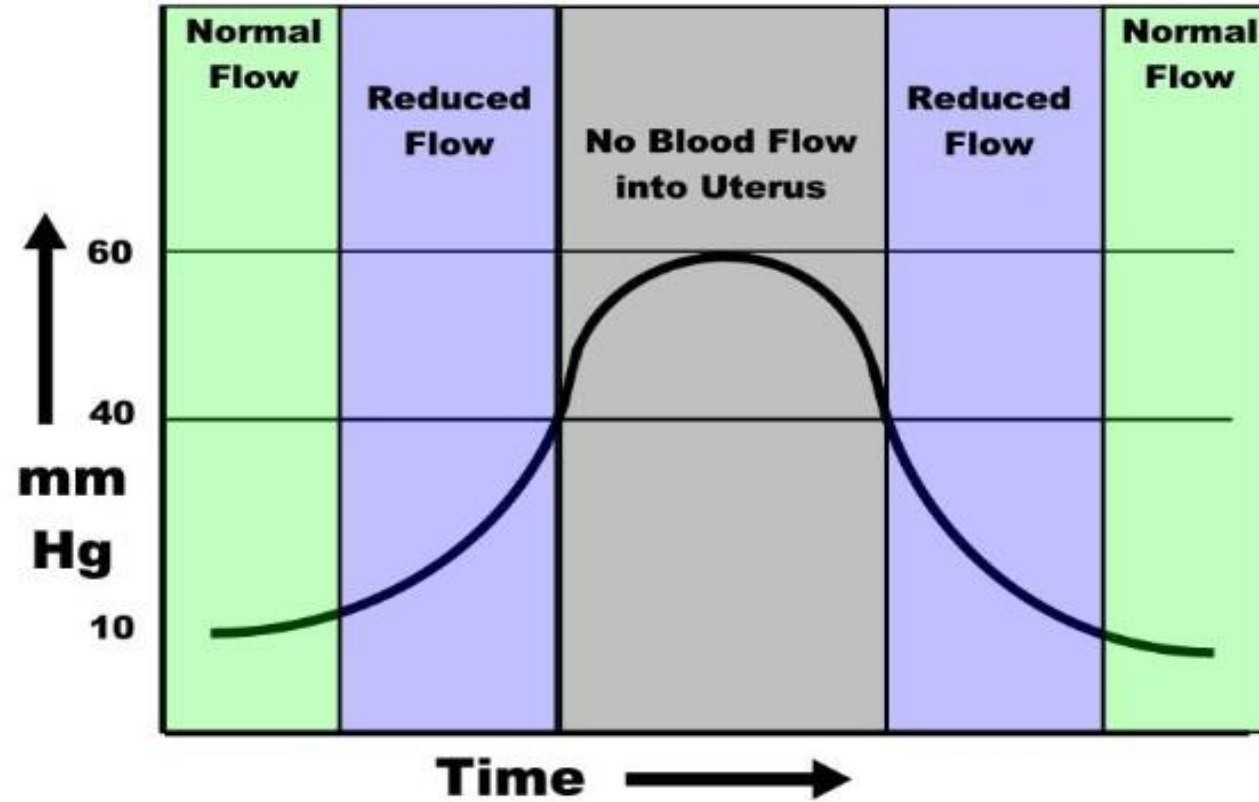
- The number of contractions in a 10 minute period is recorded.
- Hyperstimulation : More than 5 contractions in 10 minutes.
- Hyperstimulation can result in hypoxia, acidosis & abnormal fetal heart rate.



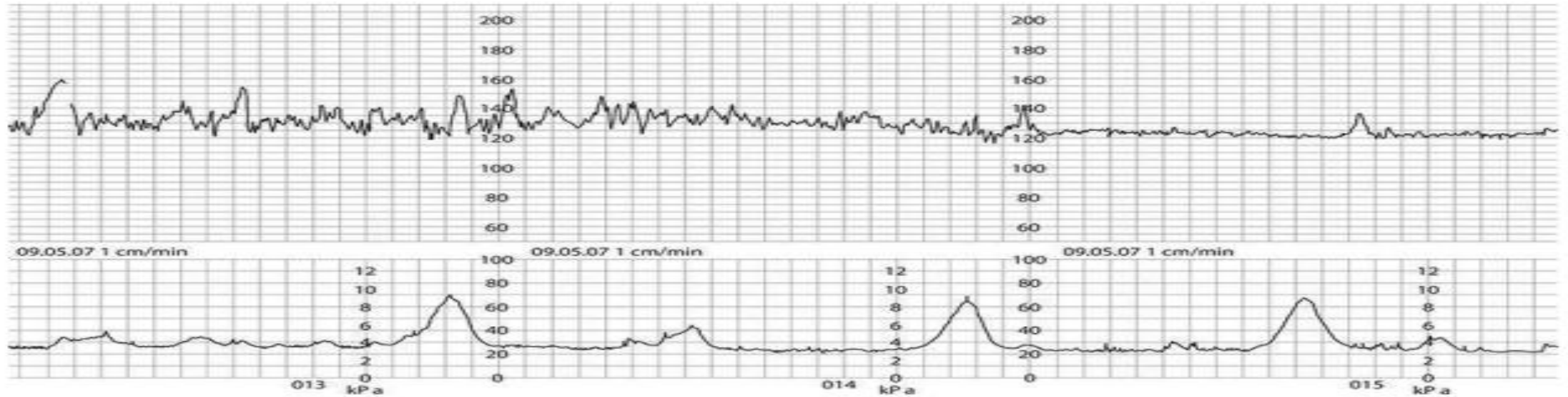
Change in Uterine Blood Flow with Contractions

- Normal human labor is characterized by regular uterine contractions, which cause repeated intermittent reductions of blood flow to the intervillous spaces resulting in repeated transient interruptions of fetal oxygenation. Contractions may also compress the umbilical cord and fetal head.
- Most fetuses tolerate this process well because of placental reserve and effective compensatory mechanisms, but some do not because of preexisting uteroplacental insufficiency and/or intrapartum factors.

Change in Uterine Blood Flow with Contractions



Change in Uterine Blood Flow with Contractions



- **A normal cardiotocograph (CTG), showing a baseline fetal heart rate of approximately 120 bpm, frequent accelerations, baseline variability of 10– 15 bpm and no decelerations.**
- **The uterus is contracting approximately once every 5 minutes**

BASELINE RATE

- **Normal fetal heart rate: Between 110-160 bpm**

Tachycardia: A baseline value above 160 bpm lasting more than 10 minutes.

- **Causes:**

- Maternal pyrexia (infection, chorioamnionitis)
- Fetal hypoxia.
- Medications (beta-agonist drugs used for tocolysis) .
- Fetal arrhythmias (SVT).
- Fetal anemia.

Bradycardia: A baseline value below 110 bpm lasting more than 10 minutes

- Values between 100 and 110 bpm may occur in normal fetuses, especially in postdate pregnancies.
- **Causes:**
- Maternal hypothermia, Hypotension, Hypoglycemia
- Administration of beta-blockers
- Fetal arrhythmias such as atrioventricular block
- (SSA/Ro positive pregnancies (systemic lupus erythematosus (SLE) and Sjögren's syndrome (SS)) associated with with heart block)
- Fetal metabolic acidosis

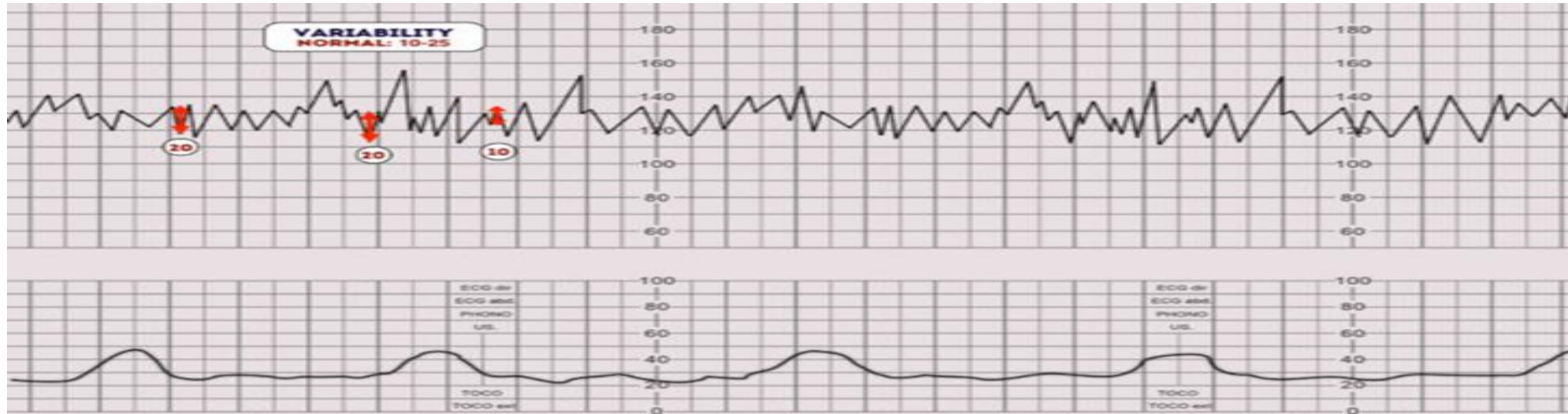
Variability

- It refers to the fluctuations in the baseline FHR
- **Variability** occurs as a result of the interaction between the nervous system, chemoreceptors, baroreceptors and cardiac responsiveness.
- Normal variability indicates an intact neurological system in the fetus
- **Normal variability is between 5-25 bpm.**
- Absent variability = Amplitude range undetectable
- Minimal = < 5 BPM
- Moderate = 6 to 25 BPM
- Marked = > 25 BPM

Variability

- Persistently minimal or absent FHR variability appears to be the most significant intrapartum sign of fetal compromise.
- On the other hand the presence of good FHR variability may not always be predictive of a good outcome.

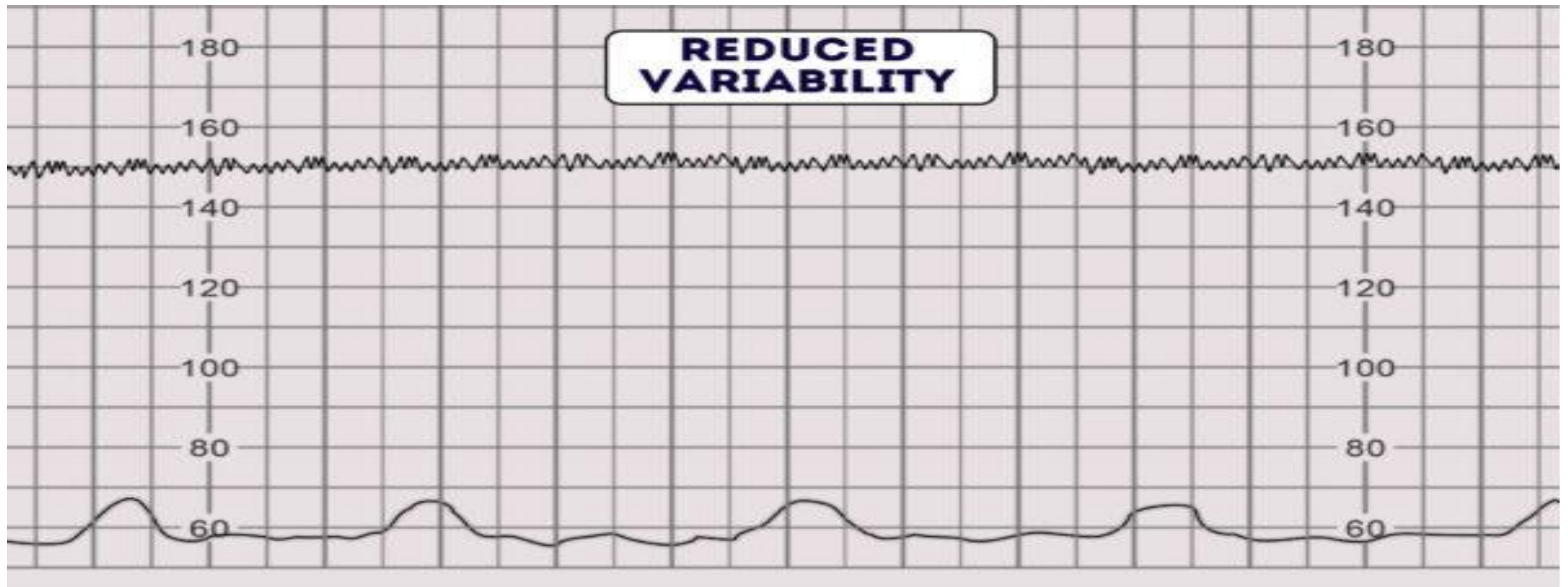
Normal Variability







Variability

- **Variability can be categorized as:**
- **Reassuring:** 5 – 25 bpm
- **Non-reassuring:**
 - less than 5 bpm for between 30-50 minutes
 - more than 25 bpm for 15-25 minutes
- **Abnormal:**
 - less than 5 bpm for more than 50 minutes
 - more than 25 bpm for more than 25 minutes
 - sinusoidal

Reduced Variability



Variability

| Overview of fetal heart rate variability | | |
|--|--|--|
| Type | Oscillation amplitude | Causes |
| Moderate variability  | <ul style="list-style-type: none">• 6–25 bpm | <ul style="list-style-type: none">• Physiological fluctuation of FHR• Normal finding |
| Absent variability | <ul style="list-style-type: none">• Undetectable amplitude | <ul style="list-style-type: none">• Severe fetal <u>acidemia</u> |
| Minimal variability  | <ul style="list-style-type: none">• < 6 bpm | <ul style="list-style-type: none">• Sleeping fetus• Effects of <u>opioids</u> or <u>magnesium</u>• Fetal <u>hypoxia</u> |
| Marked variability  | <ul style="list-style-type: none">• > 25 bpm | <ul style="list-style-type: none">• Fetal <u>hypoxia</u>• <u>Umbilical cord compression</u>• May precede a decrease in variability |
| Sinusoidal variability  | <ul style="list-style-type: none">• 5–15 bpm• FHR wave resembles a sinus wave | <ul style="list-style-type: none">• Severe fetal <u>anemia</u>• Severe fetal <u>hypoxia</u> |
| Pseudosinusoidal variability | <ul style="list-style-type: none">• Similar appearance to sinusoidal variability• Irregularly shape and amplitude of the FHR curves | <ul style="list-style-type: none">• Maternal <u>meperidine</u> use |

Causes of Reduced Variability

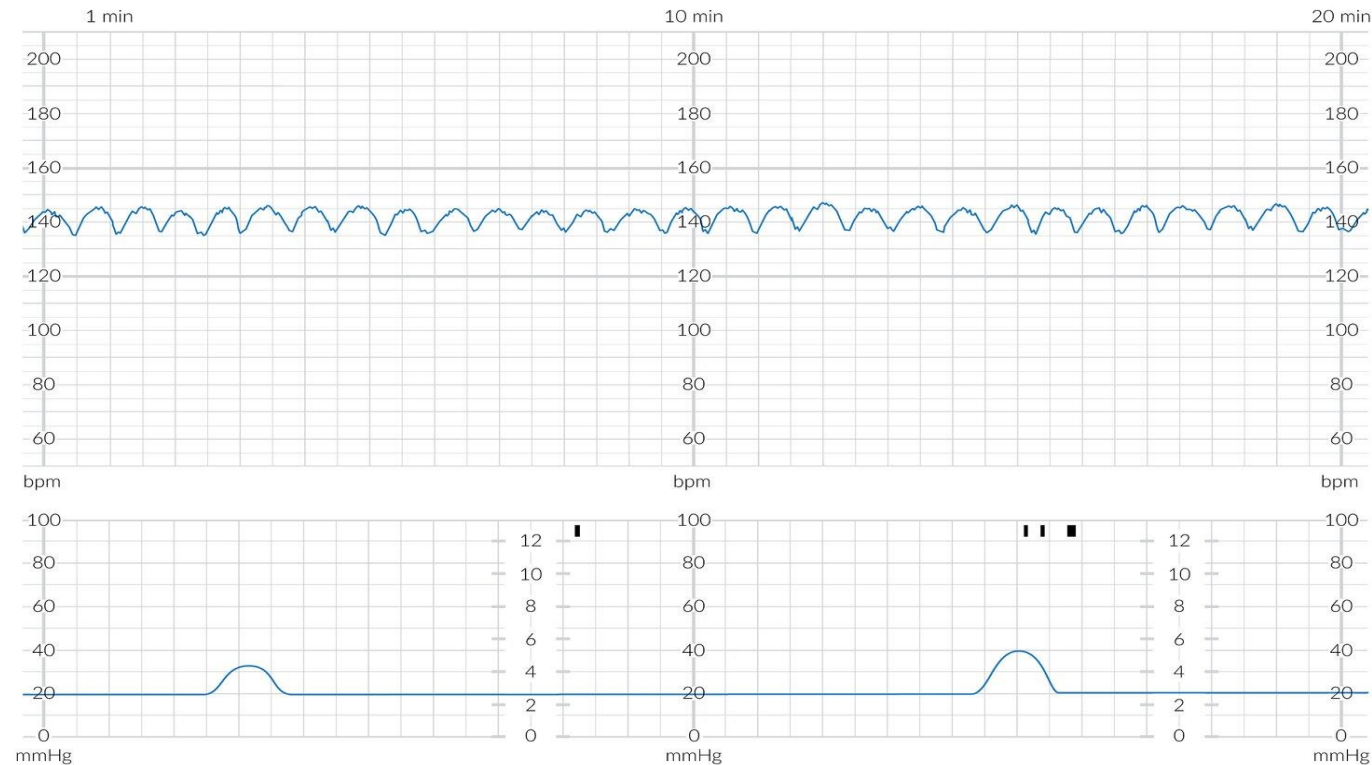
- **Reduced variability can be caused by any of the following:**
- **Fetal sleeping:** this should last no longer than 40 minutes (this is the most common cause)
- **Fetal Hypoxia & acidosis**, more likely if late decelerations are also present
- **Fetal tachycardia**
- **Drugs:** (opiates, benzodiazepines, methyldopa and magnesium sulphate, betamethasone)
- **Prematurity:** variability is reduced at earlier gestation (<28 weeks)
- **Congenital heart abnormalities**

Sinusoidal Pattern

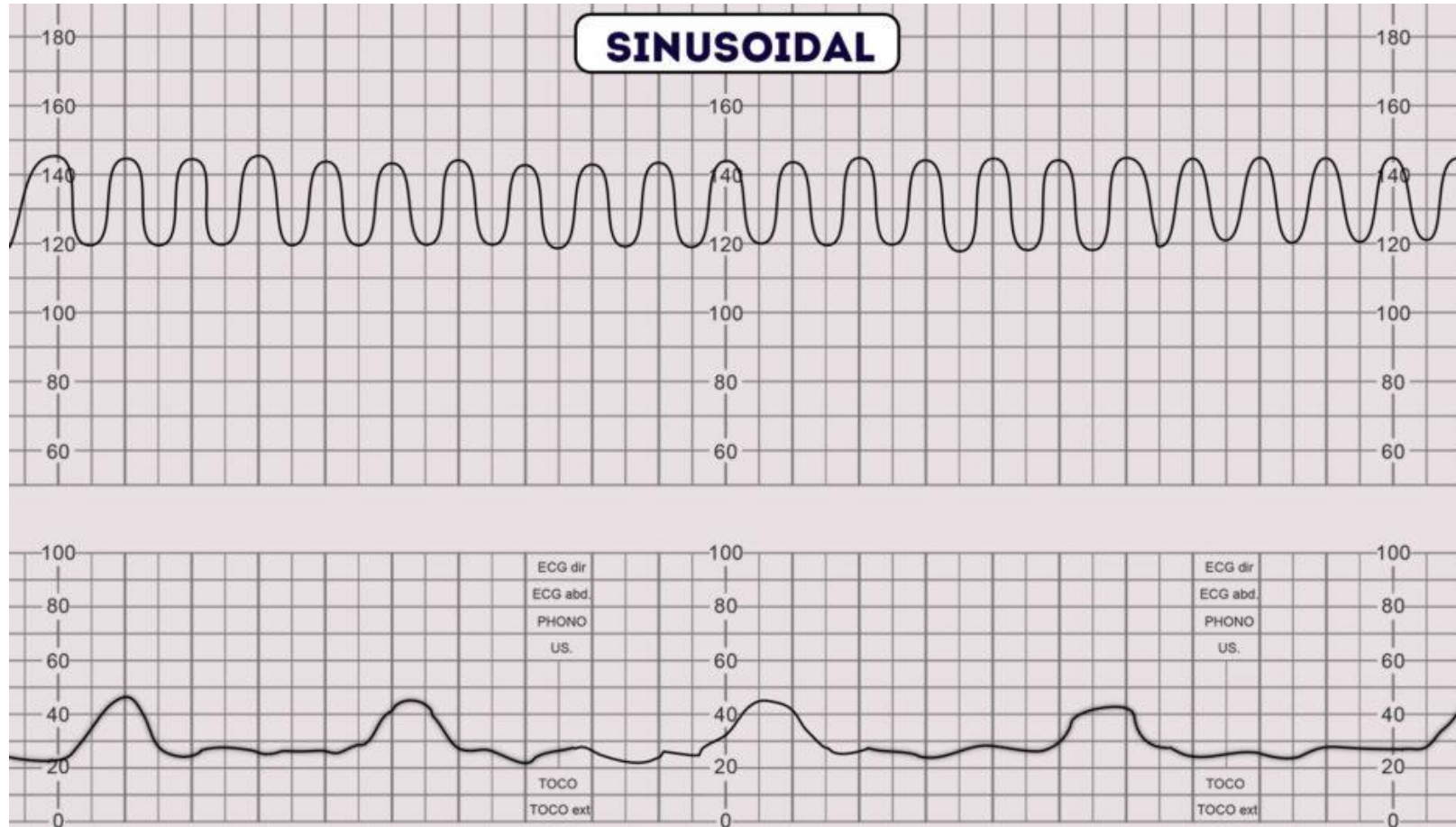
- Sinusoidal pattern is a regular, smooth, undulating pattern resembling a sinus wave, with amplitude 5-15 bpm at frequency 3-5 cycles/min, lasting for **>30 min** and coinciding with absent accelerations.
- **A sinusoidal CTG pattern has the following characteristics:**
 - A **smooth, regular, wave-like** pattern
 - Frequency of around **2-5 cycles a minute**
 - **Stable baseline rate** around 120-160 bpm
 - **No** beat to beat variability

Sinusoidal Pattern:

A regular, smooth, undulating signal, resembling a sine wave



Sinusoidal Pattern



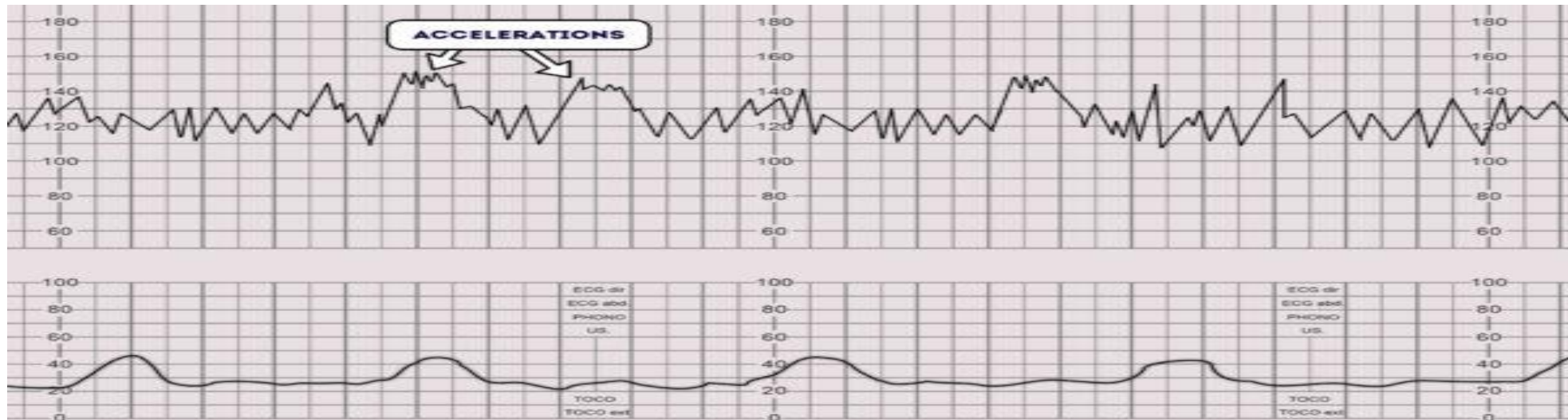
Causes of Sinusoidal Pattern

- Sinusoidal pattern is **very concerning** as it is associated with high rates of **fetal morbidity** and **mortality**
- **It occurs in association with:**
 - Severe fetal hypoxia
 - Severe fetal anemia
 - Fetal-maternal hemorrhage
 - Ruptured vasa previa

Accelerations

- **Accelerations** are an **abrupt increase** in the baseline fetal heart rate of greater than 15 bpm for greater than 15 seconds.
- The presence of accelerations is **reassuring**. It indicates a neurologically responsive fetus without hypoxia/acidosis.
- The **absence of accelerations** with an otherwise normal CTG is of uncertain significance.
- Adequate accelerations are defined as:
 - <32 weeks' : ≥ 10 BPM above baseline for ≥ 10 seconds
 - >32 weeks' : ≥ 15 BPM above baseline for ≥ 15 seconds

Accelerations



Decelerations

- Decelerations are an abrupt decrease in the baseline fetal heart rate of greater than 15 bpm for greater than 15 seconds.

➤ **Early**

➤ **Late**

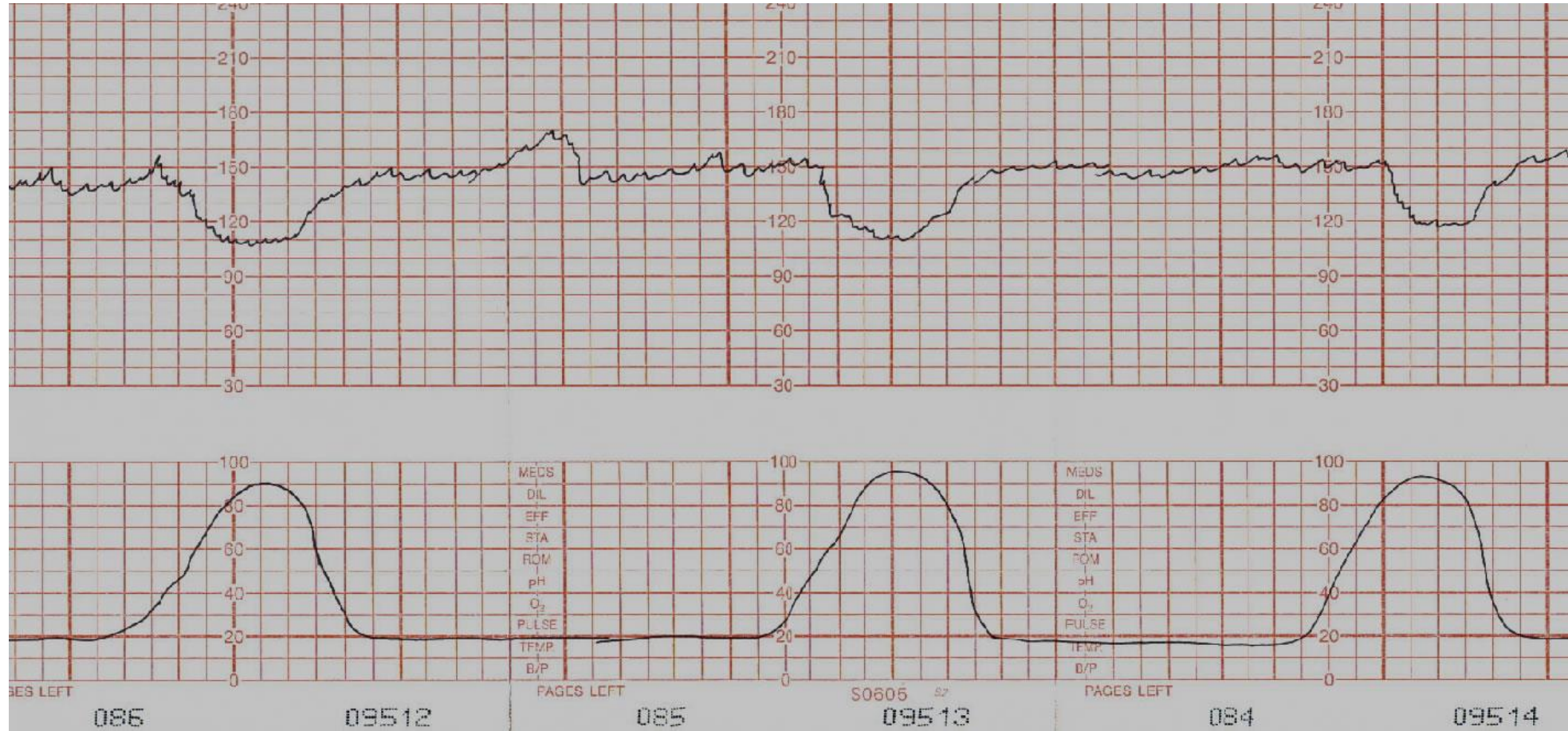
➤ **Variable**

Early decelerations

- **Cause: Head Compression**

- Gradual decrease in the FHR and return to baseline associated with uterine contraction.
- Early decelerations are shallow, short-lasting, have normal variability, and are coincident with uterine contraction.
- The onset, nadir, and recovery of the decelerations coincide with the beginning, peak, and ending of the contraction.
- This type of deceleration is not pathological and do not indicate fetal hypoxia/acidosis.

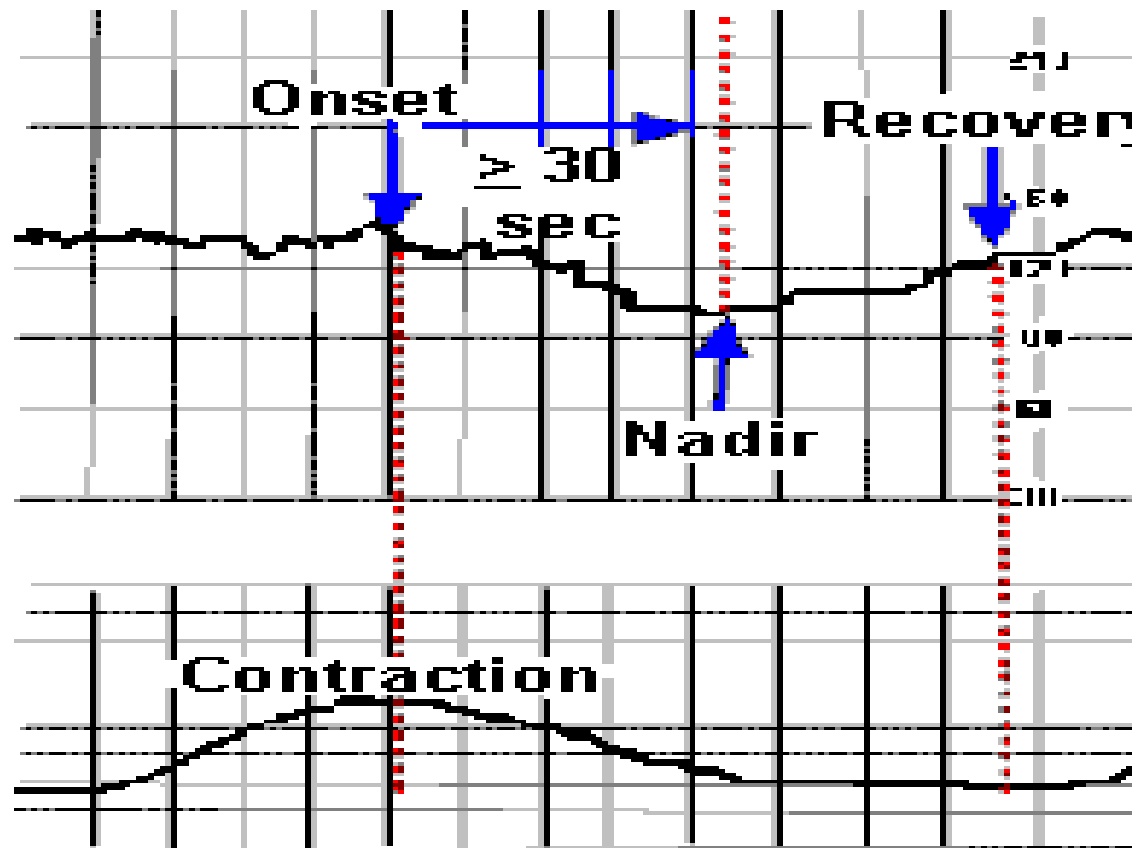
Early decelerations



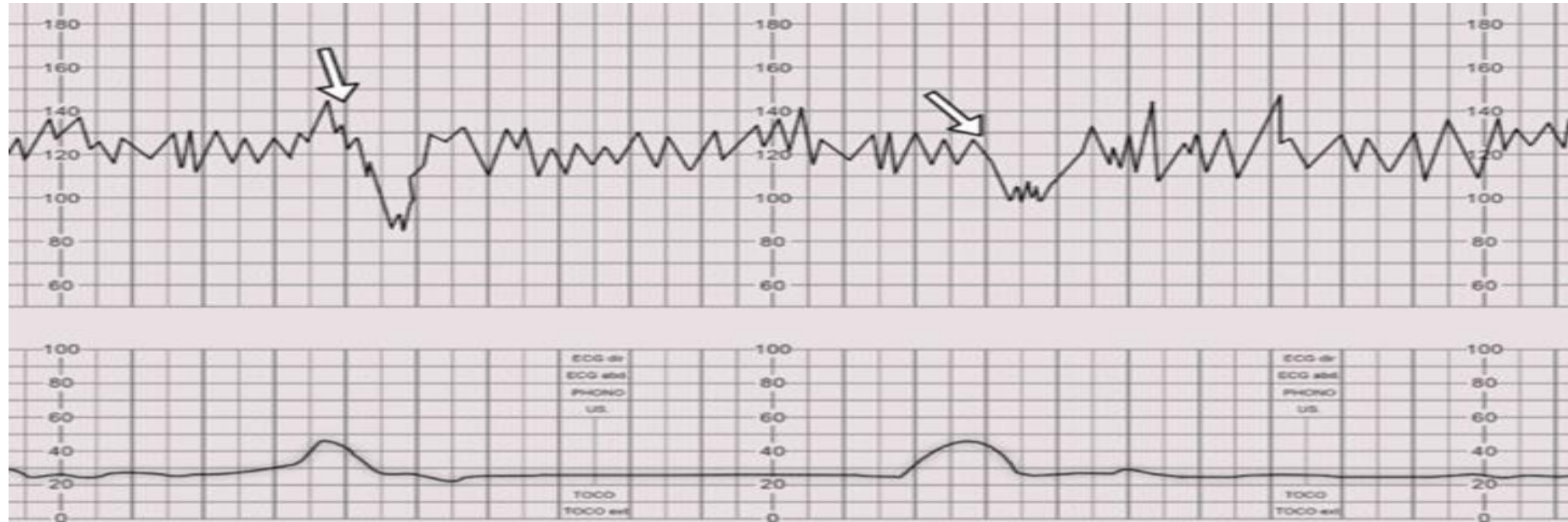
Late decelerations

- **Cause: Uteroplacental Insufficiency**
- Late decelerations are **U-shaped** with reduced variability, start more than 20 s after the onset of uterine contraction with a gradual onset with >30 s to nadir, have a nadir after the acme (the highest point) of contraction, and return to baseline gradually with >30 s from nadir to baseline
- Late decelerations begin at the peak of the uterine contraction and recover after the contraction ends.
- **Insufficiency is caused by uterine tachysystole (hyperstimulation), maternal hypotension, epidural or spinal anesthesia, IUGR, intraamniotic infection, or placental abruption.**
- Severe, repetitive late decelerations usually indicate fetal metabolic acidosis.

Late decelerations



Late decelerations



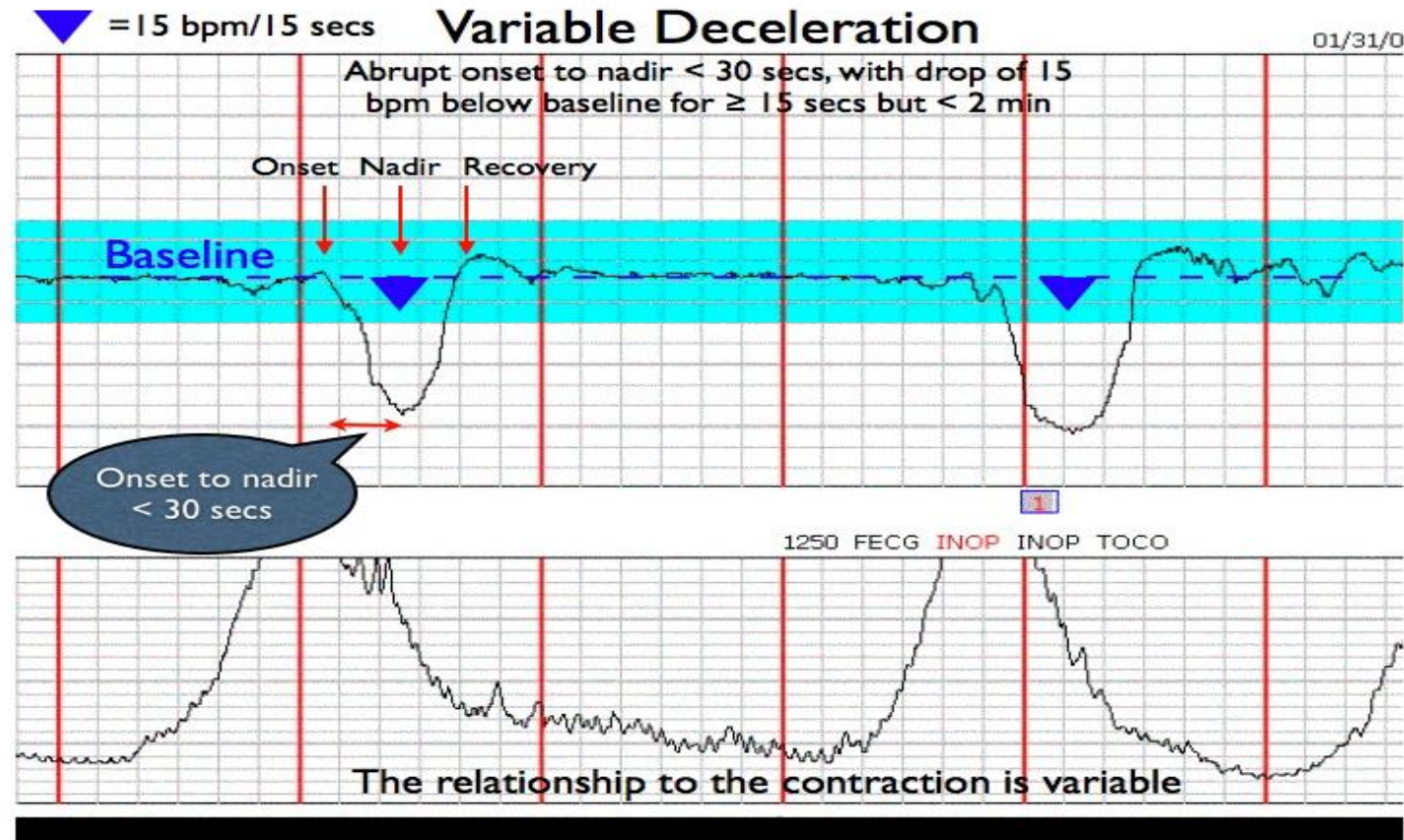
Management of Late decelerations

- Maternal left lateral position to improve uterine blood flow
- Correct maternal hypotension with IV fluids
- Administer O₂ by mask
- Stop oxytocin infusion
- Consider tocolytic drugs to slow down or stop contractions that are provoking the decelerations
- Vaginal examination
- If persistent perform fetal scalp PH

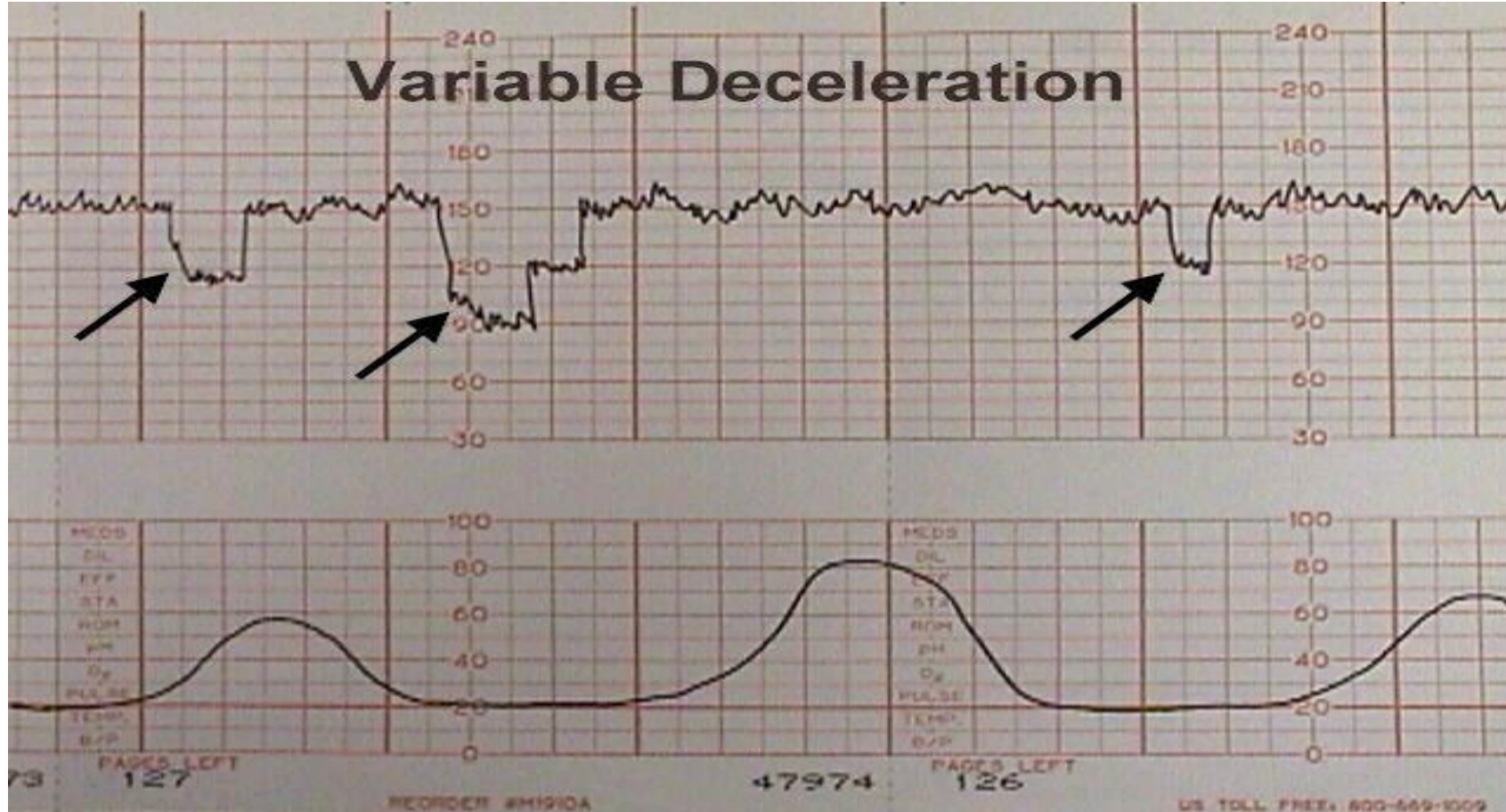
Variable decelerations

- **Cause: Cord compression**
- Variable decelerations are **V-shaped**. Variable in onset, duration and depth. They may occur with contractions or between contractions.
- Typically, they have an abrupt onset and rapid recovery (in contrast to other types of decelerations which gradually slow and gradually recover).

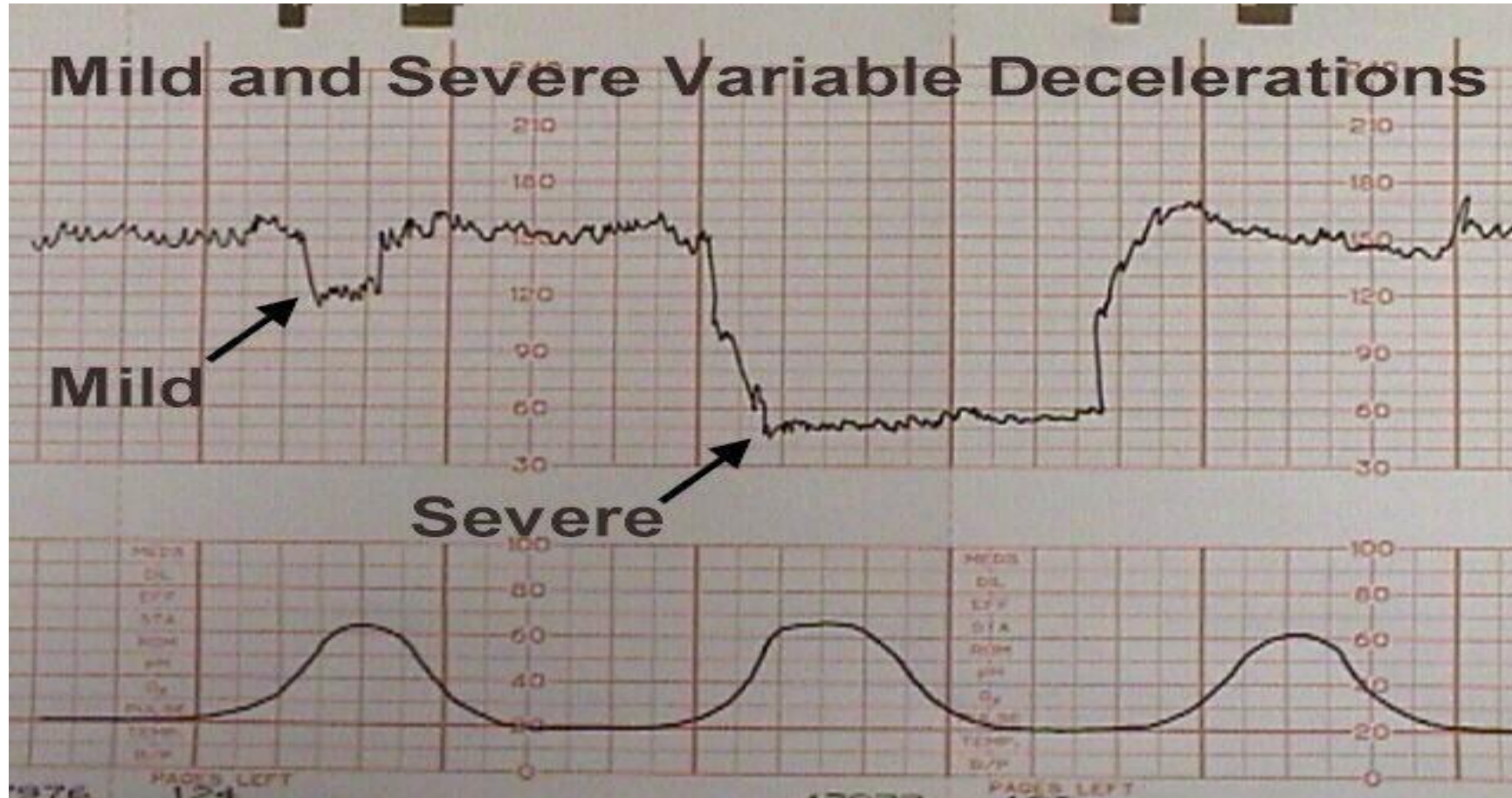
Variable decelerations

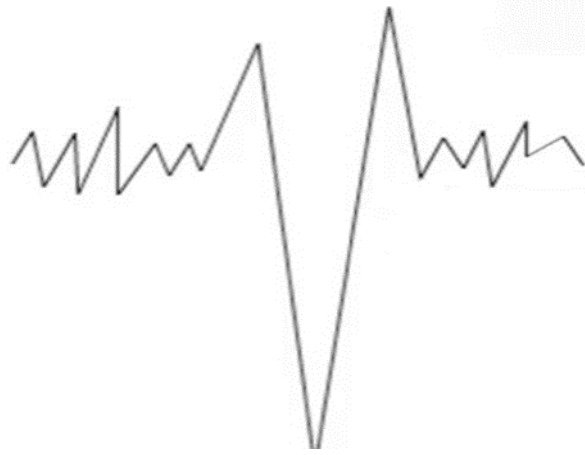


Variable Decelerations



Variable Decelerations





- **The accelerations before and after a variable deceleration are known as the shoulders.**
- Their presence indicates the fetus is not yet hypoxic and is adapting to the reduced blood flow.

Management of variable decelerations

- Changing maternal position to improve uterine blood flow
- IV hydration to increase maternal blood volume, presumably leading to increased uterine blood flow
- Administering oxygen to the mother to try to get some additional oxygen through to the fetus. (The least useful).
- Amnioinfusion to improve oligohydramnios
- Decreasing or discontinuing oxytocin infusion to slow down or stop contractions that are provoking the decelerations.
- Tocolytic drugs to slow down or stop contractions that are provoking the decelerations.
- Digital elevation of the fetal head out of the maternal pelvis to ease pressure on the umbilical cord

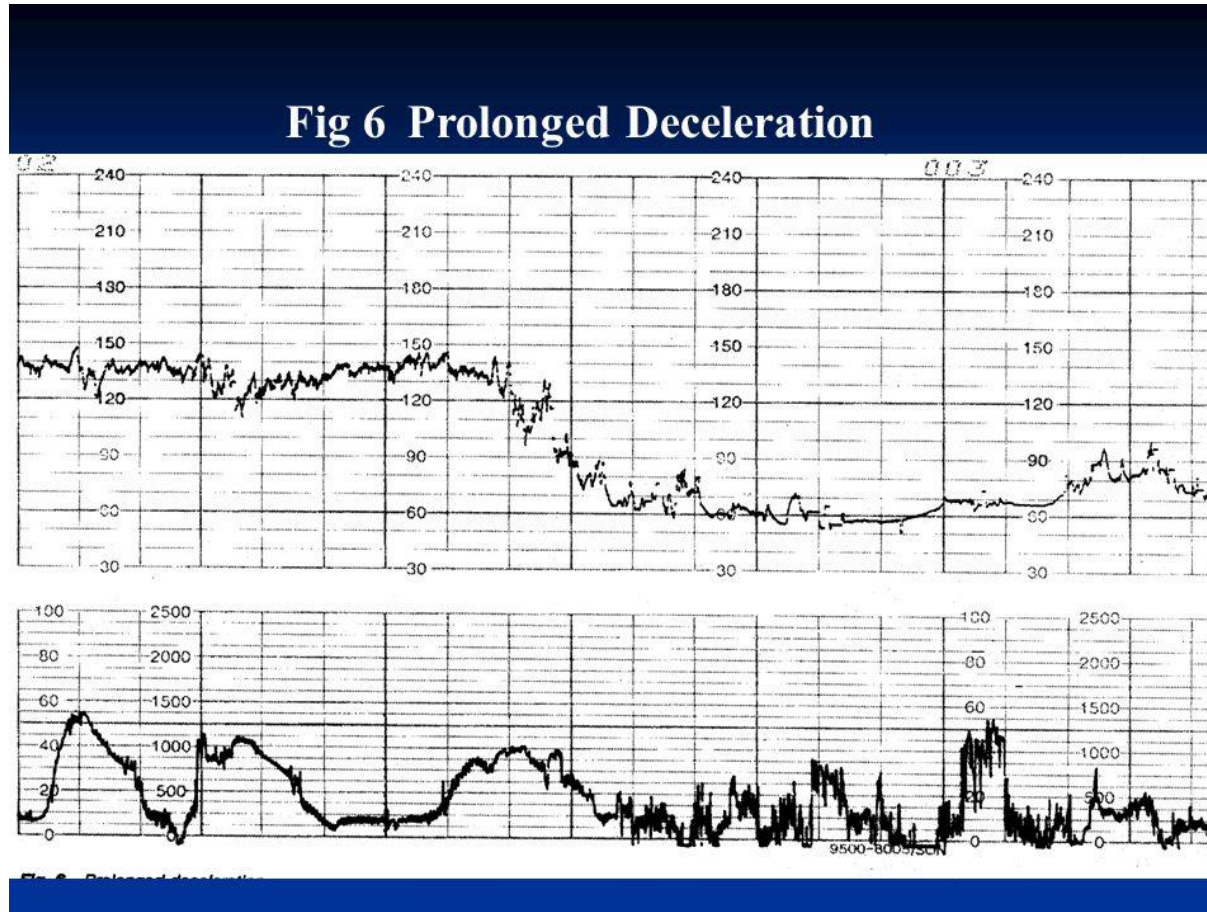
Management of variable decelerations

- Occasional mild or moderate variable decelerations are common and not considered threatening.
- Severe variable decelerations dip below 60 BPM for at least 60 seconds ("60 x 60").
- If persistent and not correctable by simple means, they can be threatening to fetal well-being.
-
- Like persistent, non-remediable late decelerations, fetuses demonstrating persistent, non-remediable severe variable decelerations should be delivered promptly.

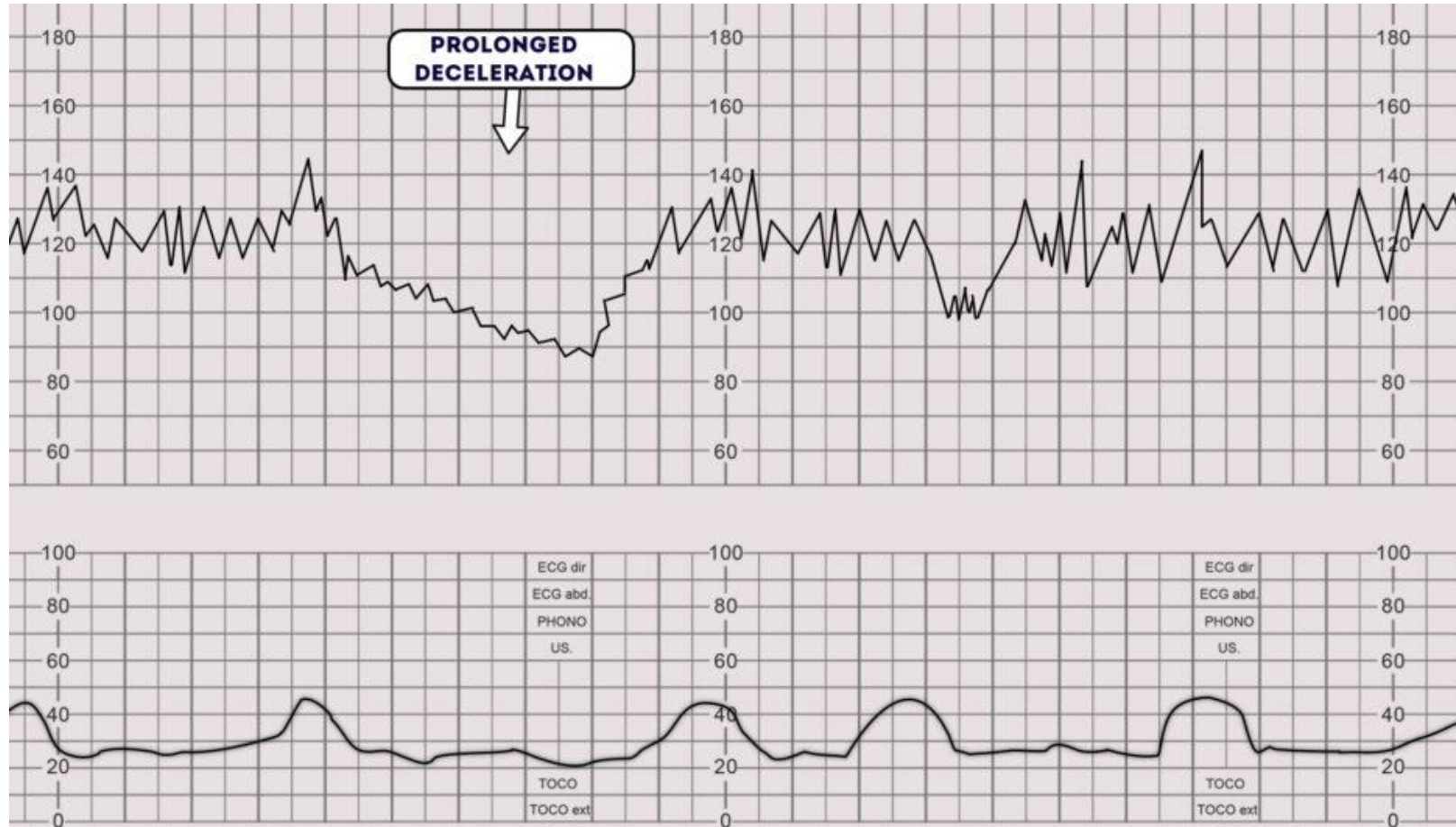
Prolonged decelerations

- Usually lasting more than 3 minutes.
- If associated with reduced variability, they indicate acute fetal hypoxia/acidosis and require emergent intervention.
- **Other Possible Causes:**
- placental abruption, uterine rupture, prolapsed umbilical cord and fetal hemorrhage (Vasa previa)

Prolonged Decelerations



Prolonged Decelerations



What causes sudden fetal bradycardia?

- **Cause of Acute fetal Bradycardia is acute fetal hypoxia due to:**
- Hyper stimulation of the uterus (with oxytocin or prostaglandin)
- Placental abruption
- Cord prolapse
- Uterine rupture
- Vasa previa
- Epidural & spinal analgesia
- Paracervical Block
- Maternal hypotension due to supine hypotension syndrome

Prolonged decelerations

- **There is a “rule of 3's” for fetal bradycardia when they are prolonged:**
 - 3 minutes – call for help.
 - 6 minutes – move to theatre
 - 9 minutes – prepare for delivery

Interpretation of FH tracings

| Interpretation | Baseline (bpm) | Variability (bpm) | Decelerations | Accelerations |
|-----------------------|------------------------|---------------------------------|--|----------------------|
| Reassuring | 110-160 | 5-25 | None | present |
| Non-reassuring | 161-180 | less than 5 30-90 minutes | <ul style="list-style-type: none"> - Variable decelerations with over 50% ,over 90min. - Late decelerations, up to 30 minutes over 50% of contractions. | |
| Abnormal | Above 180 Below 100 | Less than 5 for over 90 minutes | <ul style="list-style-type: none"> - Variable decelerations for more than 30 min despite conservative measure. - Late decelerations over 30 minutes, occurring with over 50% of contractions . - Single prolonged deceleration more than 3 min. | |

Interpretation of FHR

| Category | Definition | Management |
|--|--|---|
| CTG is normal/ reassuring | All 3 features are normal/ reassuring | Continue CTG and normal care. |
| CTG is non- reassuring | 1 non-reassuring feature, and 2 normal/ reassuring features | <ul style="list-style-type: none">- check temperature- left-lateral position- oral or intravenous fluids- stopping oxytocin- Inform coordinating midwife and obstetrician |
| CTG is abnormal and indicates further testing | 1 abnormal feature OR 2 non-reassuring features | <ul style="list-style-type: none">- Same as non reassuring- Take Fetal Blood Sample FBS |

The FIGO2015 intrapartum cardiotocography (CTG) classification system

| | Normal CTG^a | Suspicious CTG | Pathological CTG |
|------------------------------------|-------------------------------|---|--|
| Baseline ^b | 110-160 bpm | Lacking at least one of normal characteristics, but with no pathological features | <100 bpm |
| Variability ^{c,d,j} | 5-25 bpm | | Reduced/increased variability ^{c,d} ; sinusoidal pattern ⁱ |
| Decelerations ^{e,f,g,h,i} | No repetitive* decelerations | | Repetitive* late or prolonged decelerations for >30 min (or >20 min if reduced variability); one deceleration >5 min |
| Interpretation | No hypoxia/acidosis | Low probability of hypoxia/acidosis | High probability of hypoxia/acidosis |

Category 1: Strongly predictive of normal fetal acid-base status at the time of observation.

Requires no specific management.

Category I (Normal)

Category I FHR tracings include **all** of the following:

- Baseline rate: 110-160 beats/min
- Baseline FHR variability: moderate
- Late or variable decelerations: absent
- Early decelerations: present or absent
- Accelerations: present or absent

Category II FHR (Intermediate)

- The fetal heart rate tracing shows **ANY** of the following:
- Tachycardia, bradycardia without absent variability, minimal variability, absent variability without recurrent decelerations, marked variability, absence of accelerations after stimulation, recurrent variable decelerations with minimal or moderate variability, prolonged deceleration ≥ 2 minute but less than 10 minutes, recurrent late decelerations with moderate variability, variable decelerations with other characteristics such as slow return to baseline, and "overshoot".
- Not predictive of abnormal fetal acid-base status, but requires continued surveillance and reevaluation.

Category II FHR (Intermediate)

- Not predictive of abnormal fetal acid-base status, so management depends on clinical circumstances.
- Search for the underlying cause (ex: maternal hypotension) and correct it.
- Some interventions:
 - Change the mother's position to the left lateral recumbent.
 - Reduce the infusion rate of oxytocin
 - Increase intravenous fluids.

- **Category 3: Predictive of abnormal fetal acid-base status.**
In addition to measures in category II treatment, may consider:
Fetal scalp blood sampling
Ultrasound doppler velocimetry
Delivery

Category III (Abnormal)

Category III FHR tracings include either of the following:

- Absent baseline FHR variability and any of the following:
 - Recurrent late decelerations
 - Recurrent variable decelerations
 - Bradycardia
- Sinusoidal pattern

Secondary tests of Fetal wellbeing

- Fetal Scalp Sampling
- Scalp stimulation
- Acoustic stimulation
- Fetal pulse oximetry
- Fetal Electrocardiogram Analysis

Fetal Blood Sampling (Fetal Scalp PH)

- FBS may be used in cases of abnormal CTG.
- A vaginal examination needs to be performed prior to the procedure to assess the nature and position of the presenting part.
- Contraindications : maternal infection, women seropositive to hepatitis B, C, or to HIV, suspected fetal blood disorders, uncertainty about the presenting part, preterm fetus.
- CTG + FBS results in a reduction in cesarean deliveries when compared with CTG alone

Fetal Scalp PH

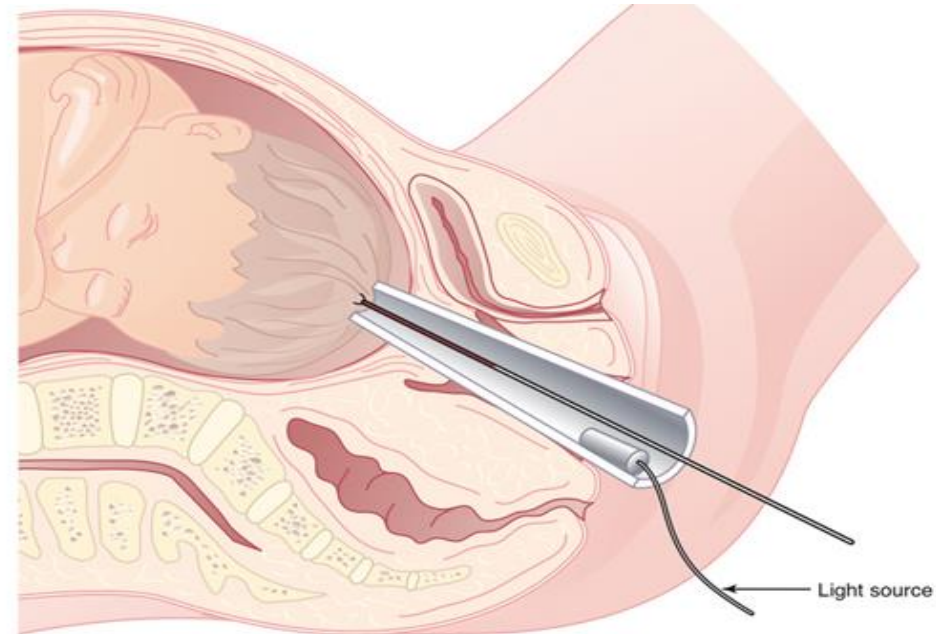


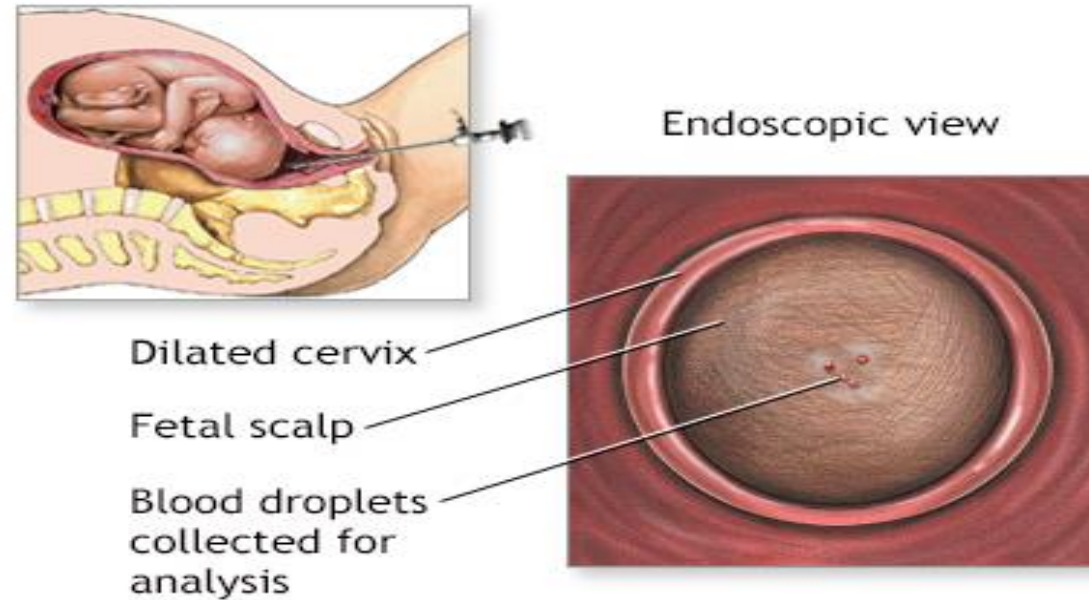
FIGURE 9-6 This technique of fetal scalp blood sampling via an amnioscope is still used in many centers. After making a small stab incision in the fetal scalp, the blood is drawn off through a long, heparinized capillary tube.

✓ **Risks:**

Continued bleeding from the puncture site (more likely if the fetus has a pH imbalance)

Infection

Bruising of the baby's scalp



Fetal Blood Sampling (Fetal Scalp PH)

| Interpretation | pH | Lactate (mmol/L) |
|-------------------|-------------|------------------|
| Normal | ≥ 7.25 | < 4.2 |
| Repeat in 30 mins | 7.21 – 7.24 | 4.2 – 4.8 |
| Birth expedited | ≤ 7.20 | > 4.8 |
| Urgent delivery | < 7.15 | > 5.0 |

Dr Amal Barakat

• Thank you

• The End of Intrapartum Fetal Monitoring