

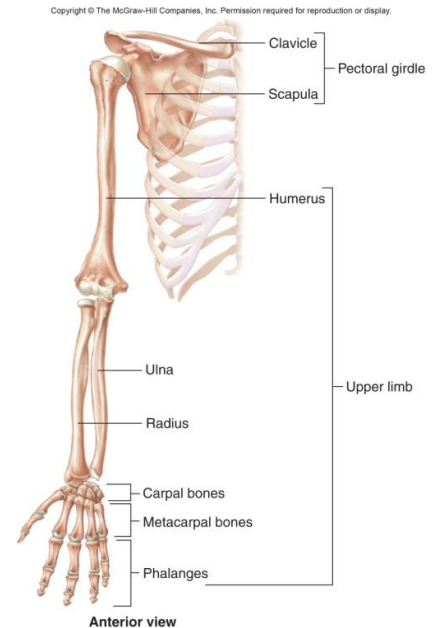
Unit 2 Lecture 6

THE APPENDICULAR SKELETON

The **APPENDICULAR SKELETON** consists of the pectoral and pelvic girdles and the upper and lower extremities.

The **PECTORAL (SHOULDER) GIRDLE** attaches the bones of the upper extremities to the axial skeleton and supports the shoulder. The Clavicle serves as a brace to keep the arm away from the thorax. It has two curves (one convex, one concave); juncture of these curves is where most fractures to the clavicle occur. The Scapula (shoulder blade) are broad triangular bones with spines, acromium processes (articulates with the clavicle), bodies, coracoid processes, glenoid cavities (fossa) receives the head of the humerus. They provide many points for muscle attachment.

The UPPER EXTREMITY consists of 60 bones (thirty per limb) that provide the framework for muscle attachment and functions in levers that move the limb and its parts. The **humerus** is the longest bone in the upper extremity. It has a head (proximal end), anatomical neck (former site of the epiphyseal plate), greater and lesser tubercle and intertubercular sulcus, deltoid tuberosity (point of attachment for deltoid muscle), a capitulum (articulates with the head of the radius) radial fossa (receives the head of the radius when forearm is bent), a trochlea: looks like a spool (articulates with the ulna), and a coronoid fossa (receives part of the ulna when forearm is bent), body (main shaft), olecranon fossa (receives olecranon when forearm is extended), medial ("funny bone") and lateral epicondyles (point of muscle attachment). The surgical neck is the site of most fractures.



The **ulna** and is longer than the **radius** and overlaps the humerus posteriorly. It has a trochlear notch (receives the trochlear and separates the olecranon and coronoid processes), olecranon, and radial notch (receives the head of the radius).

The bones of the hand consist of **carpals, metacarpals, and phalanges**. The carpals are eight bones called scaphoid, lunate, triquetrum, pisiform, trapezium, trapezoid, capitate, and hamate. The five bones called metacarpals form the palm of the hand. Each bone has a proximal base, shaft, and distal head. The fourteen bones of the fingers are called the phalanges. Each has a base, shaft, and head. There are three per finger (phalanx), two bones in the thumb (pollex).

PELVIC (HIP) GIRDLE

The pelvic girdle consists of two hipbones or coxal bones joined anteriorly at the pubic symphysis. At birth there are three separate bones (ilium, ischium and pubis)

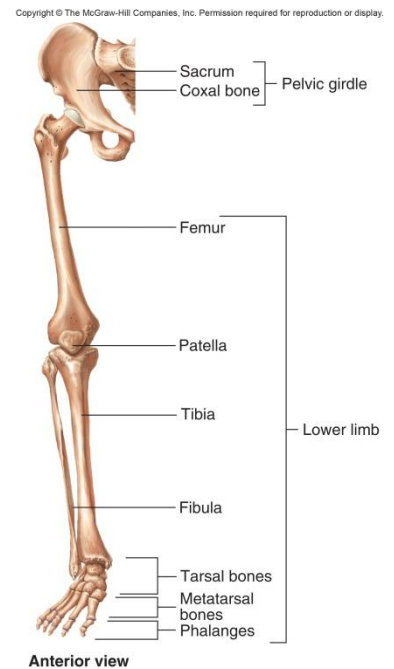
but they fuse to form one bone. The **ilium** is the superior bone, contains the iliac crest, anterior and posterior superior and inferior iliac spine, greater sciatic notch and iliac fossa. The auricular surface articulates with the sacrum to form the sacroiliac joint. The **ischium** is the middle bone. Prominent features include an ischial spine, lesser sciatic notch, ischial tuberosity, and an obturator foramen (largest foramen in the skeleton). The ramus joins with the pubis. The **pubis** is the anterior bone. It has a superior and inferior ramus, body, and a pubic crest (anterior border) and pubic tubercle (on lateral end). The acetabulum is a fossa formed by the ilium, ischium and pubis. It functions as a socket for the head of the femur. Together the hipbones, sacrum and coccyx form the pelvis. The pelvic brim is a plane marked by sacral promontory and the arcuate lines of the ilia. It also is the superior most margin of the true pelvis. The portion above pelvic brim is called the greater or (false) pelvis. The portion below pelvic brim is known as the lesser (true) pelvis. It surrounds the pelvic cavity. The superior opening of lesser pelvis is called the pelvic inlet and is the pelvic brim whereas the inferior opening is the pelvic outlet. In females the outlet is wide and oval shaped. In males it is narrower and heart shaped. The pelvis axis is the course taken by baby's head as it descends through the pelvis.

The LOWER EXTREMITY consists of sixty bones (again, thirty per limb).

The **femur** or thighbone is longest, heaviest, and strongest bone in the body. The proximal portion (head) articulates with the hip bone, distal end articulates with the tibia. The body is the shaft. It has a linea aspera (ridge that serves as attachment point for thigh muscles), a neck (most of the fractures in elderly patients occur here), greater and lesser trochanter (serve as points of attachment for muscles), distal end has medial and lateral condyles which articulate with tibia, medial and lateral epicondyles which lie above condyles, and a fovea capitis (a depression in the head of the femur to which is attached a ligament that joins to the acetabulum). The Patella is the kneecap.

The **tibia** (shinbone) bears most of the weight of the leg. It has lateral and medial condyle at proximal end articulate with the femur. The tibial tuberosity is a point of attachment for the patellar ligament. Its medial malleolus can be located as the inner bulge of ankle and the fibular notch articulates with end of fibula. The **fibula** is parallel and lateral to the tibia. It does not articulate with the knee and the lateral malleolus is outside bilge of ankle.

The **tarsus, metatarsals, and phalanges** make up the bones of the ankle and foot. The bones of the ankle are the talus (only bone that articulates with the fibula and tibia), calcaneus, cuboid, navicular, three cuneiforms and the calcaneus (heel bone which is largest and strongest tarsal bone). The metatarsals consist of five bones. The phalanges of the foot, like the metatarsals, have a base, shaft and



head. The hallux is the great toe. There is a longitudinal arch and transverse arch provide support and leverage to foot.

FEMALE AND MALE SKELETONS

Male bones are usually larger and heavier than female bones and have more prominent markings for muscle attachment. The [female pelvis](#) is adapted for pregnancy and childbirth and is wider, shallower, lighter, and rounder than the male pelvis.

DISORDERS OF THE SKELETAL SYSTEM

Genetic disorders include Achondroplasia (an autosomal dominant trait which is the most common inherited form of dwarfism), Osteopetrosis (nine rare inherited disorders causing abnormally dense bone), osteogenesis imperfecta (a connective tissue disease that affects the skeleton, child appears with many broken bones suggesting child abuse).

Developmental or metabolic disorders include Scoliosis and kyphosis (curvature of the spine usually seen in adolescent girls), osteochondroma (developmental defect where bone grows away from the joint), osteoporosis (metabolic loss of bone tissue usually seen in older females) and Osteomalacia or Rickets (inadequate mineralization due to decreased Vitamin D). Osteomyelitis is an infection in the bone. Tumors can be malignant (Osteosarcoma) or benign (Fibroma and osteoid osteoma). Metastatic tumors are those that originate in breast, prostate, lung, thyroid and kidney cancers and spread to the bone.

Why is this chapter important?

The bones of the appendicular skeleton contribute to homeostasis by providing attachment points for muscles (body movements), provide support and protection of internal organs (reproductive organs), and by storing and releasing calcium. We learned the identity and location of 120 of the body's 206 bones. We also learned how to differentiate male from female skeletons based on the pelvic bones.