

# Research Recherche

## A simple system for the assessment of trachoma and its complications

B. THYLEFORS,<sup>1</sup> C. R. DAWSON,<sup>2</sup> B. R. JONES,<sup>3</sup> S. K. WEST,<sup>4</sup> & H. R. TAYLOR<sup>5</sup>

*A simple grading system for trachoma, based on the presence or absence of five selected "key" signs, has been developed. The method was tested in the field and showed good observer agreement, the most critical point being the identification of severe cases of the disease. It is expected that the system will facilitate the assessment of trachoma and its complications by non-specialist health personnel working at the community level.*

Trachoma is still a widespread disease that causes blindness in many developing countries, particularly among rural populations. Considerable efforts have been made to control the disease, including large-scale antibiotic treatment schemes (1). The pattern of trachoma in a community may vary from severe hyperendemic "blinding trachoma" to less severe, but prevalent, non-blinding forms of the disease (2). This variation in severity may be brought about not only by treatment schemes but also by socioeconomic progress (3) and behavioural factors (4).

The natural history of trachoma usually includes an inflammatory stage during childhood, with the formation of lymphoid follicles and diffuse infiltration with papillae in the conjunctiva. Chronic inflammation eventually results in conjunctival scars, which, in turn, may lead to trichiasis and corneal complications in older children and adults.

In order to identify populations and individuals with the blinding form of the disease, and to assess changes in the pattern of trachoma over a period of time in a community, it is important to have a grading system that is both simple and reliable. Diagnostic criteria for trachoma and its intensity have previously been analysed (5) and revised for field use (6, 8). Although existing methods of scoring clinical signs are suitable for use by experienced eye specialists, they are too complex for general use by non-specialist health personnel. We therefore report here a complementary, simplified grading system for the easy but reliable assessment of trachoma at the community level, which focuses on the presence or absence of selected "key signs" of the disease. This system should enable non-specialists, after appropriate training, to make a reliable assessment of trachoma and its severity from a public health point of view.

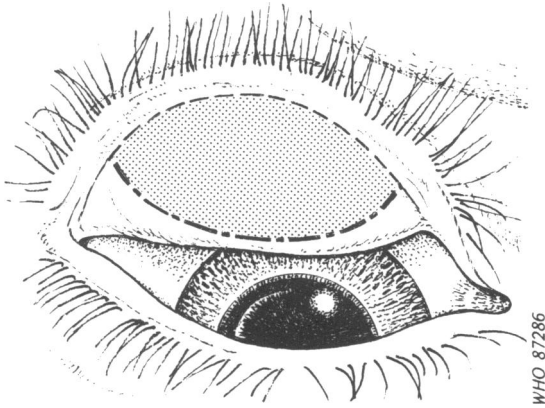
<sup>1</sup> Programme Manager, Programme for the Prevention of Blindness, World Health Organization, 1211 Geneva 27, Switzerland. Requests for reprints should be sent to this author.

<sup>2</sup> Director, Francis I. Proctor Foundation for Research in Ophthalmology, WHO Collaborating Centre for the Prevention of Blindness, University of California, San Francisco, CA, USA.

<sup>3</sup> Formerly, Director, International Centre for Eye Health, Institute of Ophthalmology, WHO Collaborating Centre for the Prevention of Blindness, London, England.

<sup>4</sup> Epidemiologist, International Center for Epidemiologic and Preventive Ophthalmology, The Wilmer Institute, WHO Collaborating Centre for the Prevention of Blindness, Johns Hopkins School of Medicine, Baltimore, MD, USA.

<sup>5</sup> Associate Director, International Center for Epidemiologic and Preventive Ophthalmology, Johns Hopkins School of Medicine, Baltimore, MD, USA.



WHO 87286

Fig. 1. Outline sketch of everted eyelid, showing the area of the tarsal conjunctiva to be examined (shaded area) for assessment of trachoma (the eye is shown at twice actual size).

#### THE GRADING SYSTEM AND ITS USE

##### *Normal conjunctiva (Plate 1A)*

In order to examine the eye for trachoma, the eyelids and cornea are observed first for inturned eyelashes and any corneal opacity. The upper eyelid is then turned over (everted) to examine the conjunctiva over the stiffer part of the upper lid (tarsal conjunctiva). The conjunctiva covering the rounded edge of the tarsal plate and corners of the everted eyelid (palpebral conjunctiva) should not be examined for this purpose (see Fig. 1).

The normal conjunctiva of the upper tarsal area is pink and is smooth, thin, and transparent. Over the whole area of the tarsal conjunctiva there are normally large deep-lying blood vessels that mainly run vertically from the upper and lower edges of the tarsal plate.

In trachoma, the inflammation produces thickening and diffuse opacification of the conjunctiva. There are two *types* of conjunctival reaction in trachomatous inflammation: follicles; and diffuse infiltration, sometimes with enlarged vascular tufts (papillary hypertrophy). Each type may vary in intensity. Follicles and diffuse infiltration usually occur together.

It is useful to define two *degrees* of trachomatous inflammation: medium, with predominantly follicular inflammation (TF) and no more than moderate degrees of diffuse infiltration; and intense inflammation (TI), with predominantly diffuse thickening. Cases with severe diffuse thickening have more

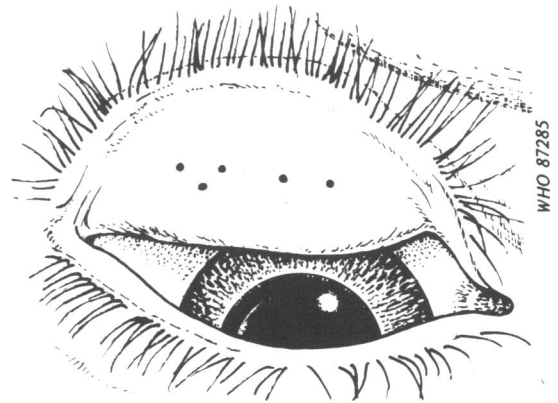
intense inflammation and are believed to be more infectious than those with less severe diffuse thickening of the conjunctiva, regardless of the number of follicles that are visible. Sometimes, follicles and severe diffuse thickening occur together, and the presence of both signs should then be recorded.

Trachomatous inflammation may lead to scarring of the tarsal conjunctiva (TS), corneal opacity (CO), and also distortion of the eyelids, leading to inturned eyelashes (trichiasis (TT)). The presence or absence of each of these signs should be recorded in every case.

*Trachomatous inflammation—follicular (TF): the presence of five or more follicles in the upper tarsal conjunctiva (Plate 1B)*

Follicles are round lumps or spots that are paler than the surrounding conjunctiva. In the grading system discussed here, follicles must be at least 0.5 mm in diameter, i.e., at least as large as those shown in Fig. 2.

Care should be taken to distinguish follicles from spots due to small scars and from degenerative deposits in the conjunctiva. Small scars are not round, but have angular borders with sharp corners, whereas follicles have rounded edges that are not sharply defined. Degenerative deposits include conjunctival concretions that are yellow or white opaque masses with clear-cut edges, as well as cysts that appear as clear bubbles in the conjunctiva.



WHO 87285

Fig. 2. Illustration of five follicles of 0.5 mm diameter on the tarsal conjunctiva (the eye and follicles are shown at twice actual size).

*Trachomatous inflammation—intense (TI): pronounced inflammatory thickening of the upper tarsal conjunctiva that obscures more than half of the normal deep tarsal vessels (Plate 1C)*

The key feature of this grade of trachoma is the pronounced inflammatory thickening, which is defined as being present when, in more than half the area of the tarsal conjunctiva, the large deep tarsal vessels are not visible because they are obscured by inflammatory infiltration or follicles. In severe trachomatous inflammation, the tarsal conjunctiva appears red, rough, and thickened. This is due to diffuse inflammatory infiltration, oedema, or enlargement of vascular tufts (papillary hypertrophy); also there are usually numerous follicles, which may be partially or totally covered by the thickened conjunctiva. Inflammatory thickening and opacification of the conjunctiva should not be confused with that caused by scarring, especially diffuse fibrosis or formation of a fibrovascular membrane.

*Trachomatous scarring (TS): the presence of scarring in the tarsal conjunctiva (Plate 1D)*

Scars are easily visible as white lines, bands, or sheets (fibrosis) in the tarsal conjunctiva. Characteristically, they are glistening and fibrous in appearance, with straight, angular or feathered edges. Scarring, especially diffuse fibrosis, may obscure the tarsal blood vessels, and so must not be confused with diffuse inflammatory thickening.

*Trachomatous trichiasis (TT): at least one eyelash rubs on the eyeball (Plate 1E)*

Evidence of recent removal of intumed eyelashes should also be graded as trichiasis.

*Corneal opacity (CO): easily visible corneal opacity over the pupil (Plate 1F)*

This sign refers to corneal scarring that is so dense that at least part of the pupil margin is blurred when viewed through the opacity. The definition is intended to detect corneal opacities that cause significant visual impairment (less than 6/18 or 0.3 vision), and in such cases the visual acuity should be measured if possible.

#### *Method of examination*

The examination should normally be performed with binocular loupes ( $\times 2.5$ ) and adequate lighting (either daylight or a torch). If appropriate, loupes of higher magnification or a slitlamp (biomicroscope) can be used, but the same optical aid and level of magnification should be used for all examinations. The grading obtained with a higher magnification may not necessarily be directly comparable to that with  $\times 2.5$ . Eyes should be examined first for intumed eyelashes (TT), and the cornea then scrutinized for opacities (CO). In order to check for intumed eyelashes, the upper lid should be pushed upwards slightly to expose the lid margins. The upper eyelid should then be examined for inflammation (TF and TI) and scarring (TS). Each eye must be examined and assessed separately. Clinical signs must be clearly seen in order to be considered present. If in doubt, a sign should be regarded as absent.

#### RESULTS

The system described has been tested in the field in Burma and Tunisia in order to assess grading variations for individual observers and inter-observer variations; the results, summarized in Tables 1 and 2,

Table 1. Inter-observer variation in the grading of trachoma using the simple system described in the text

Sign	Average $\kappa$ -statistic	
	First study <sup>a</sup>	Second study <sup>b</sup>
Trichiasis (TT)	0.87 (0.75–0.93) <sup>c</sup>	0.76 (0.68–0.81)
Corneal opacity (CO)	0.71 (0.59–0.79)	0.68 (0.48–0.71)
Trachoma – follicular (TF)	0.58 (0.53–0.63)	0.70 (0.66–0.74)
Trachoma – intense (TI)	0.30 (0.20–0.36)	0.45 (0.38–0.49)
Trachomatous scarring (TS)	0.73 (0.69–0.76)	0.75 (0.67–0.79)

<sup>a</sup> Six observers, each examining 152–155 cases.

<sup>b</sup> Four observers, each examining 179 cases.

<sup>c</sup> Figures in parentheses indicate the range.

Table 2. Intra-observer variation in the grading of trachoma using the simple system described in the text

Sign	Average $\kappa$ -statistic	
	First study <sup>a</sup>	Second study <sup>b</sup>
Trichiasis (TT)	0.91 (0.65-1.0) <sup>c</sup>	0.89 (0.79-1.0)
Corneal opacity (CO)	0.91 (0.64-1.0)	—
Trachoma — follicular (TF)	0.64 (0.37-0.93)	0.89 (0.79-1.0)
Trachoma — intense (TI)	0.78 (0.48-1.0)	0.79 (0.65-0.88)
Trachomatous scarring (TS)	0.85 (0.63-1.0)	0.68 (0.44-0.93)

<sup>a</sup> Four observers, each examining 45-47 cases.

<sup>b</sup> Four observers, each examining 44 cases.

<sup>c</sup> Figures in parentheses indicate the range.

respectively, are based on kappa ( $\kappa$ ) statistics. A  $\kappa$ -value of 0.7 or more was taken to indicate satisfactory observer agreement. It should be noted that after the first study the definition of TF was modified to include only follicles that were at least 0.5 mm in diameter. This resulted in considerably improved observer agreement in the second study. Similarly, the definition of TI was modified twice, since the inter-observer agreement was very low in the first study. The definition finally used has also been adopted in a recent field trial (7) with good results ( $\kappa$ -values of 0.78 and 0.77 among four observers for inter-observer agreement and agreement for individual observers, respectively).

#### DISCUSSION

The grading system described was developed for use by trained non-specialist personnel to obtain reliable information on trachoma in population-based surveys or for the simple assessment of the disease at the community level. Clearly, the system gives a less detailed picture of trachoma than more complex methods for use by specialists (8), but should prove more reliable for less experienced observers.

The interpretation of findings recorded using the simplified system generally corresponds to that of the more detailed grading method (Table 3). In the simplified system the coding of follicular trachoma (TF) ensures that trivial cases are ignored, but includes a wide range of mild or moderate cases. The grading code for intense trachoma (TI) corresponds to the key sign for severe intensity of trachoma in the detailed system. For the potentially disabling, irreversible lesions, trachomatous scarring (TS) may represent all levels of conjunctival scarring, whereas

the coding of trachomatous trichiasis (TT) corresponds to more severe cases, with eyelashes rubbing on the eyeball. Only the more severe cases of corneal scarring (CO) are covered by the simplified system, in order to ensure reliable recording and inclusion of significant visual disabilities.

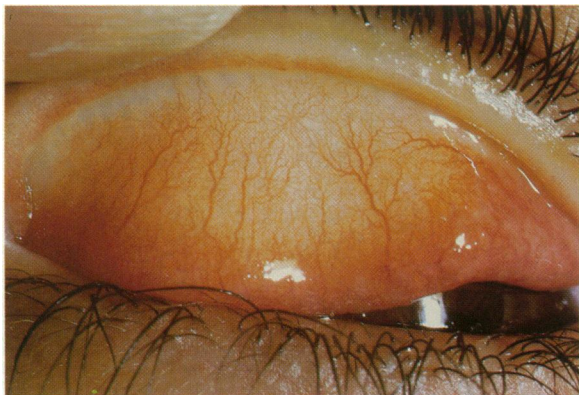
The system described permits an adequate epidemiological analysis of trachoma in a community, covering prevalence, severe intensity of inflammation, trichiasis, and disabling corneal lesions. The rate of TF should give an overall measure of the extent of transmission and of active trachoma in a population, and can be used to make comparisons over a period of time and with other geographical areas. Similarly, the rate of TS indicates the amount of cicatricial trachoma in a community. For a particular area, the rate of CO gives a measure of the possible contribution of trachoma to visual loss. The

Table 3. Comparison of the simple grading of trachoma with the grading used in a more detailed system

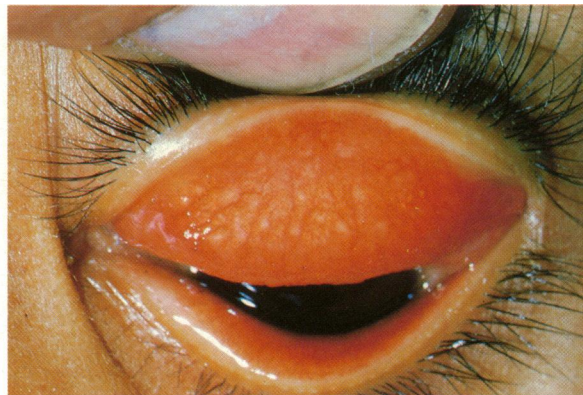Grading		Implication
Simple system	Detailed system <sup>a</sup>	
TI	P3	Severe intensity of inflammation
TF	F <sub>2</sub> or F <sub>3</sub>	Presence of inflammatory trachoma
TS	C <sub>1-3</sub>	Presence of cicatricial trachoma
TT	T/E 2,3	Potentially disabling lesion
CO	CC 2,3	Visually disabling lesion

<sup>a</sup> DAWSON, C. R. ET AL. *Guide to trachoma control in programmes for the prevention of blindness*. Geneva, World Health Organization, 1981.

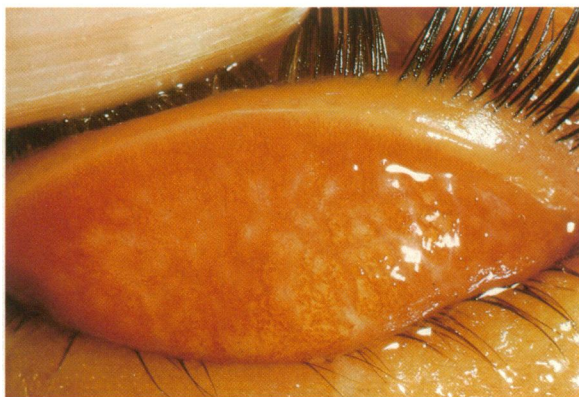
**Plate 1. Appearance of the normal tarsal conjunctiva and the five selected signs of trachoma and its complications (for further details, see text)**



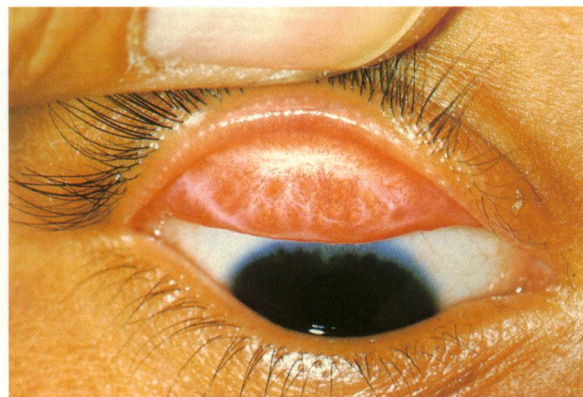**A. Normal tarsal conjunctiva**



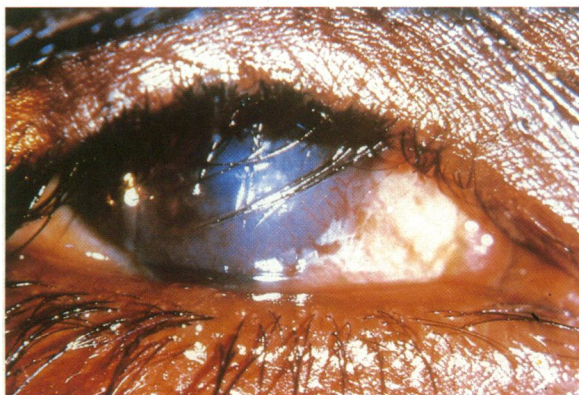
**B. Trachomatous inflammation – follicular (TF)**



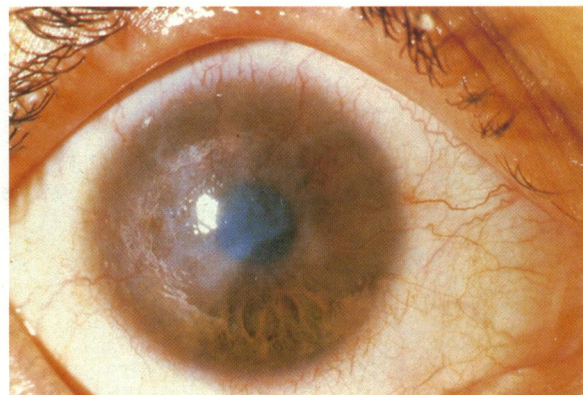**C. Trachomatous inflammation – intense (TI)**



**D. Trachomatous scarring (TS)**



**E. Trachomatous trichiasis (TT)**



**F. Corneal opacity (CO)**

simple scheme may also provide information about the relation between inflammatory and cicatricial trachoma in relation to age and sex.

The simple grading system should facilitate the assessment of trachoma in population-based surveys and the identification of communities at high risk of

blindness due to the disease. It should also be suitable for monitoring and evaluating large-scale control efforts at the community level and for the assessment of major changes in the pattern of trachoma over a period of time.

## ACKNOWLEDGEMENTS

We thank Professor M. T. Daghfous, Director, Institute of Ophthalmology, WHO Collaborating Centre for the Prevention of Blindness, Tunis, for his valuable support of the field work, as well as Dr S. Lwin, Ministry of Health, Burma, and Dr R. Pararajasegaram, Regional Adviser for the Prevention of Blindness, WHO Regional Office for South-East Asia, New Delhi. This study was made possible through funds provided by the Edna McConnell Clark Foundation.

## RÉSUMÉ

### UN SYSTÈME SIMPLE D'ÉVALUATION DU TRACHOME ET DE SES COMPLICATIONS

Le présent article décrit un système simple de cotation du trachome et de ses complications, basé sur la présence ou l'absence d'un certain nombre de signes de la maladie. Ces signes comprennent: la présence d'au moins cinq follicules, signifiant que l'on a affaire à un trachome "folliculaire"; un épaissement inflammatoire prononcé de la conjonctive tarsienne supérieure qui masque plus de la moitié des vaisseaux tarsiens profonds normaux, définissant ainsi le trachome "intense"; et des lésions cicatricielles de la conjonctive tarsienne. Ce système de cotation comprend les complications suivantes: trichiasis trachomateux, avec au moins un cil venant frotter sur la cornée, et opacité

cornéenne, aisément repérable au niveau de la pupille.

Ce système de cotation a été testé sur le terrain dans deux pays et a montré une uniformité acceptable des résultats entre observateurs, l'accord se faisant le moins bien sur le "trachome intense". Ce système vise à faciliter l'évaluation du trachome et de ses complications lors des enquêtes sur le terrain ou dans les programmes de lutte à grande échelle à base communautaire, où l'on ne dispose souvent que d'un personnel non spécialisé. Cette méthode a été mise au point pour que ce type de personnel puisse l'utiliser après une courte période de formation, et devrait permettre une évaluation plus facile et plus répandue du trachome.

## REFERENCES

1. THYLEFORS, B. Trachoma programme development and involvement of national resources. *Reviews of infectious diseases*, 7: 774-776 (1985).
2. JONES, B. R. Prevention of blindness from trachoma. *Transactions of the Ophthalmological Society of the United Kingdom*, 95: 16-33 (1975).
3. DAWSON, C. R. ET AL. Severe endemic trachoma in Tunisia. *British journal of ophthalmology*, 60: 245-252 (1976).
4. TAYLOR, H. R. ET AL. The ecology of trachoma: an epidemiological study in southern Mexico. *Bulletin of the World Health Organization*, 63: 559-567 (1985).
5. WHO Technical Report Series, No. 234, 1962 (*Trachoma: third report of an Expert Committee*).
6. DAWSON, C. R. ET AL. Blinding and non-blinding trachoma: assessment of intensity of upper tarsal inflammatory disease and disabling lesions. *Bulletin of the World Health Organization*, 52: 279-282 (1975).
7. TAYLOR, H. R. ET AL. Trachoma: evaluation of a new grading scheme in the United Republic of Tanzania. *Bulletin of the World Health Organization*, 65: 485-488 (1987).
8. DAWSON, C. R. ET AL. *Guide to trachoma control in programmes for the prevention of blindness*. Geneva, World Health Organization, 1981.