

PURULENT DISEASES OF FINGERS

Training program


general surgery
department





Felon is

- Furuncle version
- Purulent inflammation of hand fingers
- Purulent inflammation of any finger



Certainly not





Historically the term of "felon" is applied only to purulent diseases of hand fingers






Felon is an acute suppurative disease of fingers



Main cause of Felon development



- immunity deficiency
- Microinjury of a finger
- Gematogenes infection spreading




Theoretically probably, but it
is almost improbable






wrong





Correctly!



Felon

The superficial

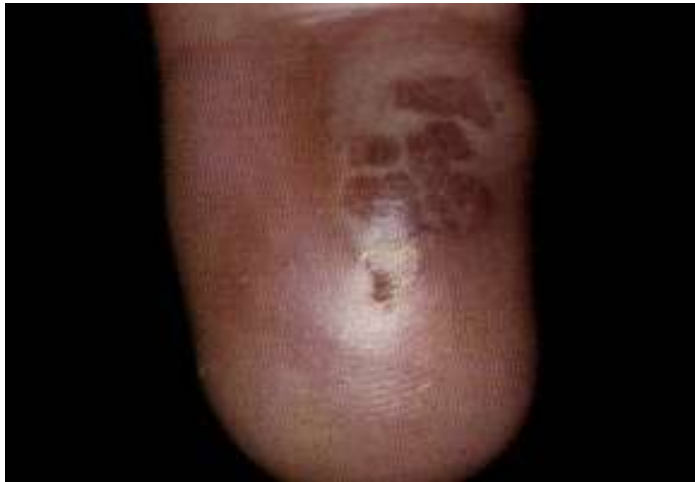- cutaneous
- paronychia
- hyponychia
- subcutaneous
- furuncle of the finger

The deep


- osteal
- tendinous
- articular
- panactylitis



The disease has begun after one has rubbed finger skin with a glove at a physical activity. There was a blister with muddy contents. Skin around a blister is hyperemic. Diagnosis?



- Bedsore of finger skin
- The infected callosity of a finger
- cutaneous felon




Bedsore appears at a long pressure of a motionless site of a body – a sacrum, a nape, interscapular area





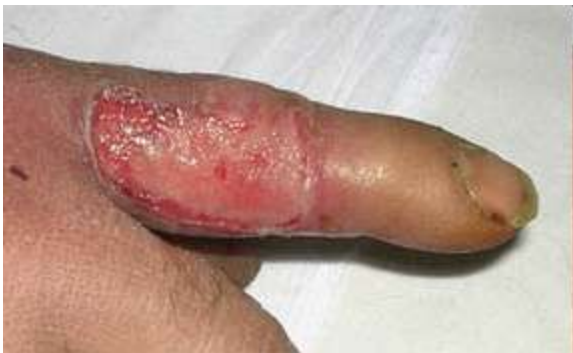The term «the infected callosity»
sometimes is applied, but mainly in
relation to diseases of feet



Correctly!



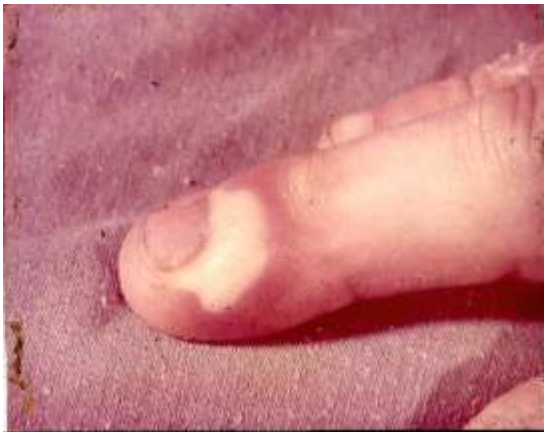- cutaneous felon- a local pus accumulation within skin (a site under epidermis). Often felon is accompanied with expressed lymphangitis and lymphadenitis.
- Treatment surgical - is made removal of epidermis, as a rule thus it is not required anaesthesia. Purulent exudate is evacuated, then it is necessary to examine carefully an surface not to pass felon in the form of "cuff link" (when purulent process by a narrow fistula extends in subcutaneous tissue). The inflammatory is stopped within 5-10 days depending on spreading of process.




Soon after performance of manicure there was a pain at the basis of a nail plate. Skin is red. Diagnosis?



- Abscess of the nail
- erysipelas
- Paronichial

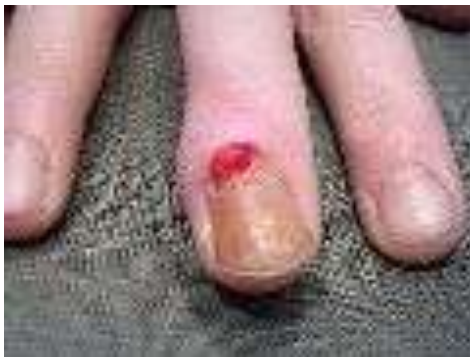
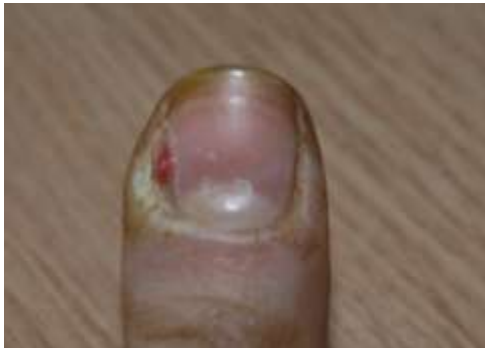



Erysipelas of a finger happens. Its feature is distinct margins and a bright redness of skin. Sometimes (after pork cutting) on a finger there is «a pork Erysipelas» - Erysipeloid. But on this photo is not an Erysipelas

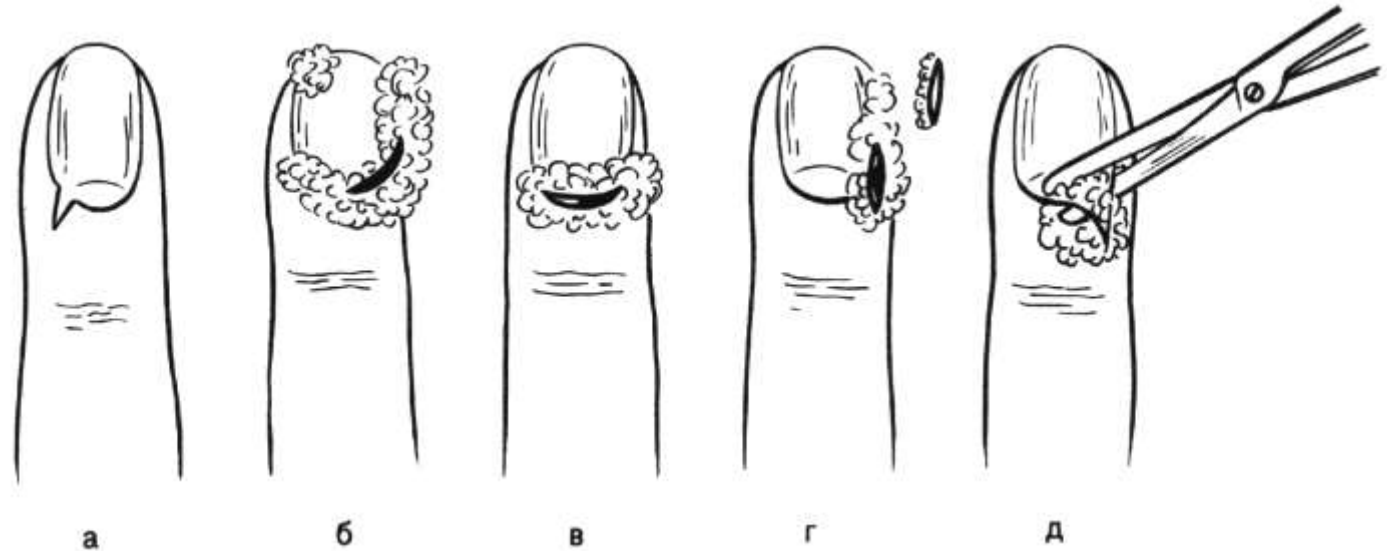


Correctly!



- paronychia- an inflammation of the nail fold.
- wrong treatment the paronychia can get a chronic current, delivering a great deal of trouble to the patient.
- reason, as a rule, is a nail injury, or wound of skin at manicure. There is an edema, redness of the nail fold, intensive pains. Pus can spread to beneath the nail plate dividing it from the sides

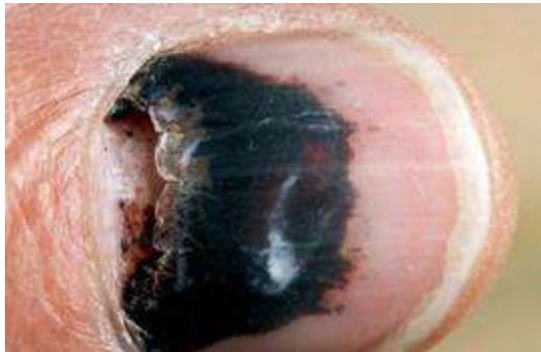



At a paronychia it is necessary cut epidermis and pathological granulations; to raise the nail fold and to wash the inflammation place. Usually the regional resection of a nail plate is required



After casual blow a hammer on a finger pain disturbed under a nail plate. Under a nail plate there was dark, almost black spot. Then pain has become stronger, the nail plate exfoliated – brown pus with a blood clot was discharged. Diagnosis?



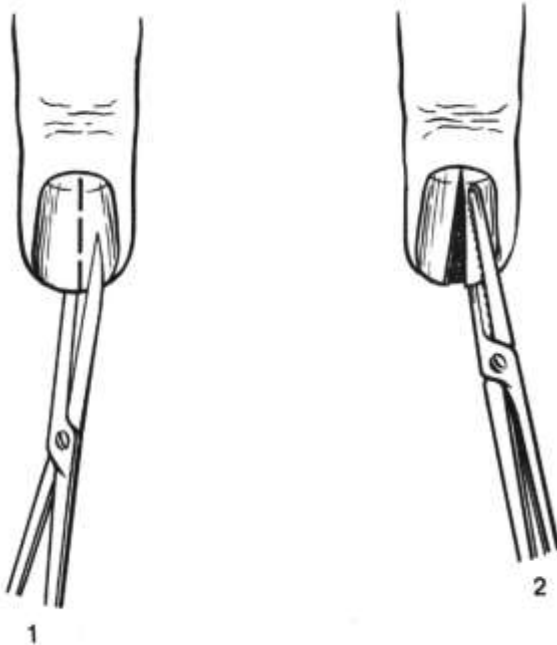
- Hemorrhagic gangrene of a nail phalanx
- Hyponychial
- Purulent hematoma



Such does not happen



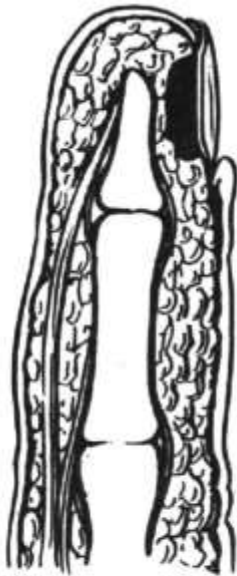
Correctly!



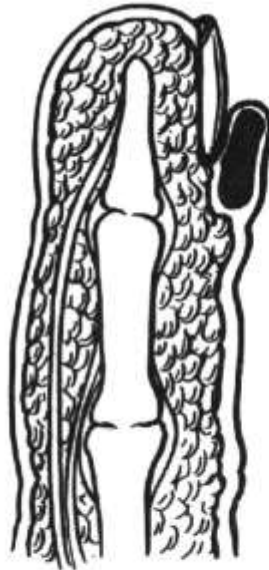

- Hyponychial- a purulent inflammation under a nail plate, thus the nail plate exfoliates from a nail bed on a bigger or smaller extent. The disease can be as a result of a paronychia; at direct introduction of an infection under a nail plate (a prick a needle, a nail); or is complication of a hematoma under nail (often after an injury of a finger by the door).
- Disease prevention - competent treatment of a paronychia and early evacuation of hematoma after a trauma.
- At the limited local exfoliation of a nail plate pus (less than 1/3 its total areas) is admissible to execute a nail resection only on the changed site. In case of more extensive lesion it is necessary to delete completely a nail plate, keeping a growth zone of a nail (if it is possible). Usually eroded surface of a nail bed is epithelized on the average in 10-15 days after operation.



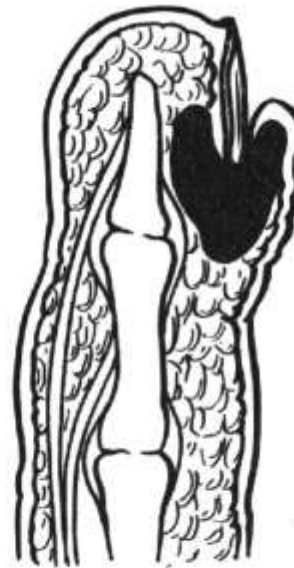Choose a combination of a paronychia with Hyponychial



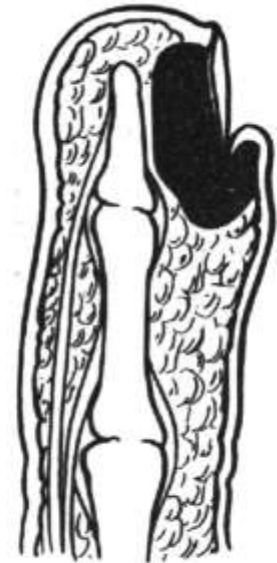1



2




3




4





NO

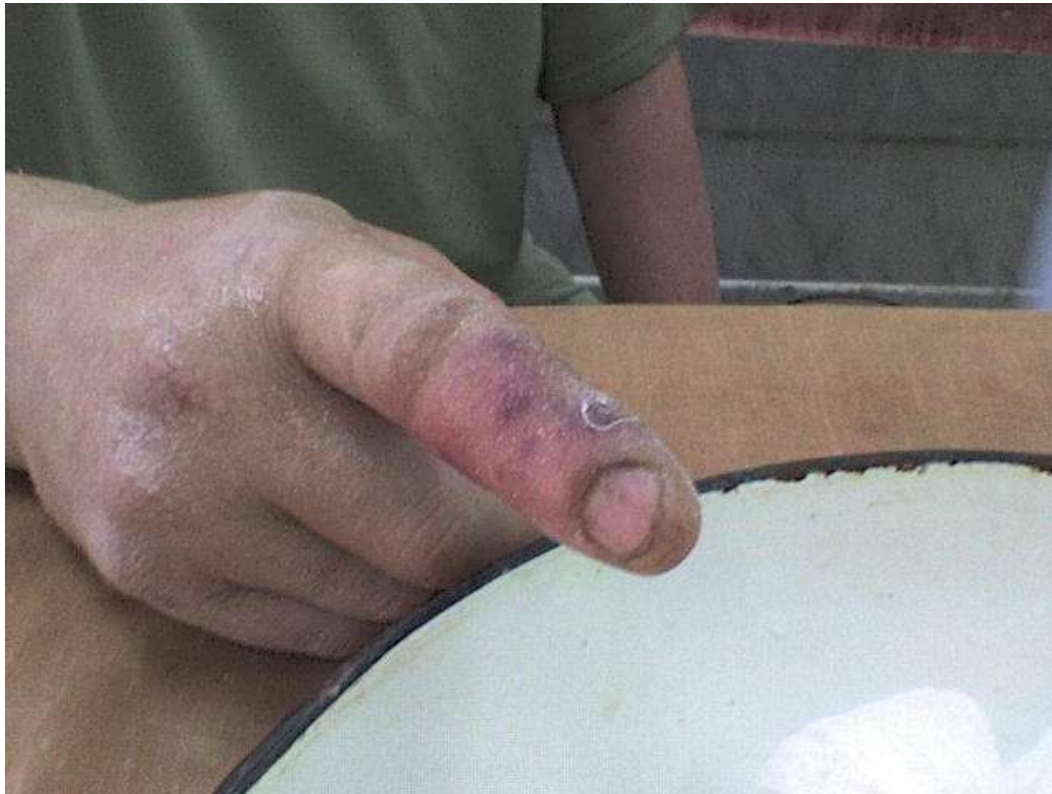



Correctly!




In the anamnesis microtrauma. On a surface of a finger there is a blister filled with muddy liquid. Around – a soft redness. Define the diagnosis



- Intracutaneous felon
- Paronychia
- erysipelas

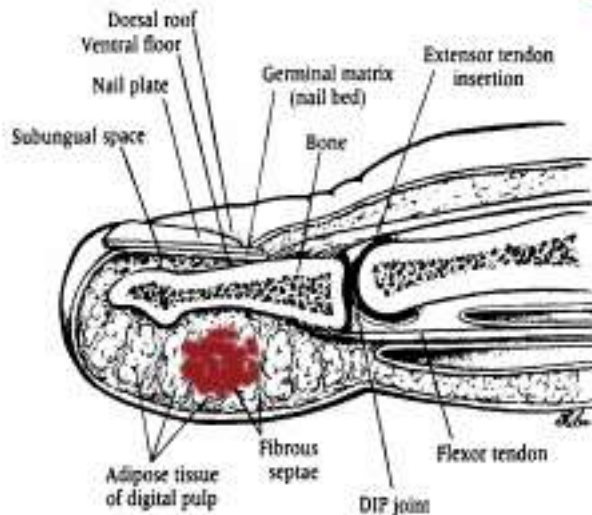
Correctly!



Subcutaneous felon– abscess of subcutaneous tissue of hand finger



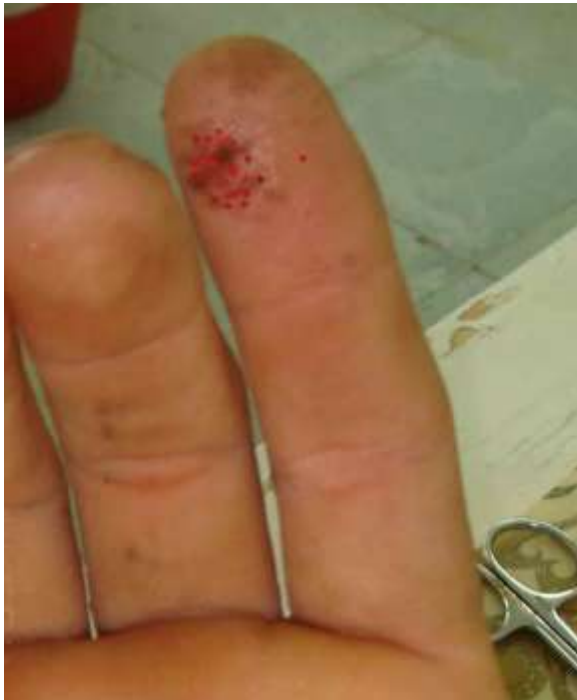Subcutaneous felon



- The disease develops at direct introduction of an infection in subcutaneous tissue of a finger with further development of a purulent inflammation. As a rule is a consequence of a microtrauma - a prick, a cut, a splinter etc. At first moderate edema and redness of skin of a finger, further the inflammatory process is noted progress, pains gain pulsing character, become very intensive. Treatment surgical.



Yesterday has pricked a finger when cutting fish. Constant moderate pain in a prick place disturbs. Round a prick place a morbidity zone with a soft redness without tension of soft tissues. Tactics:




- Immediately to operate
- To prescribe antibiotics
- To paint skin around a wound iodine tincture, to apply a local hypothermia



Term of development of a
purulent disease – 2-3 days.
Convincing signs of an abscess it
is not described





Antibiotics at anything. To create effective concentration of antibiotics in the inflammation place all the same it will not be possible



Correctly!



In a phase of a serous exudation anti-inflammatory therapy is applied.

If there is a trace of a stabwound, it is necessary to cut off hanging epidermis and to apply cold and rest. Cooling of a finger repeats 5-6 times. Then the sterile bandage and an immobilisation is applied. Krioterapiya not unique method, but available and effective method of treatment.

Surgical treatment is shown at development of a purulent inflammation. Thus pains are get pulsing character, there is a area of a redness and tension of tissues.

- On a nail phalanx of a finger the " hockey stick " cut is made, on middle and main phalanxes the cut on a lateral surface is made. Skin and hypodermic rags are parted and necrotic tissue is removed
- the formed cavity is carried out by a gauze strip with levomekol. Further, daily change of bandages is made.




Choose a type of anaesthesia for opening
Subcutaneous felon of an middle phalanx III finger of
the right hand

- Intravenous anaesthesia
- Terminal anaesthesia with chloretyl
- Conductive anaesthesia according to
Lukashevich-Oberst
- Conductive anaesthesia according to
Kullenkamp




It is absolutely impractical ...





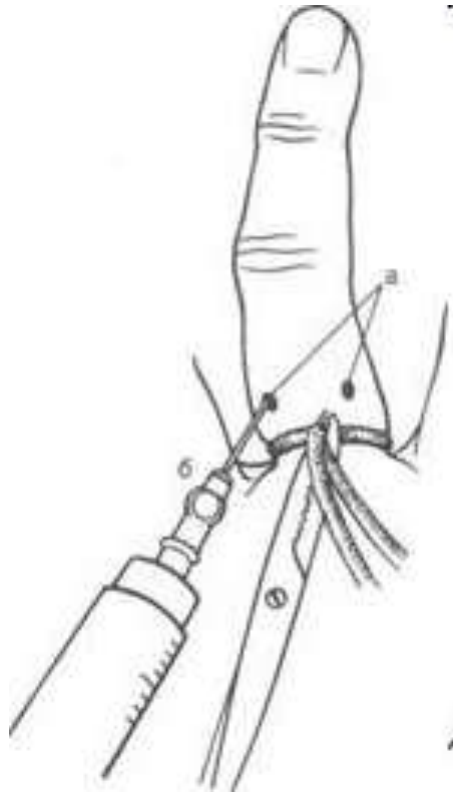
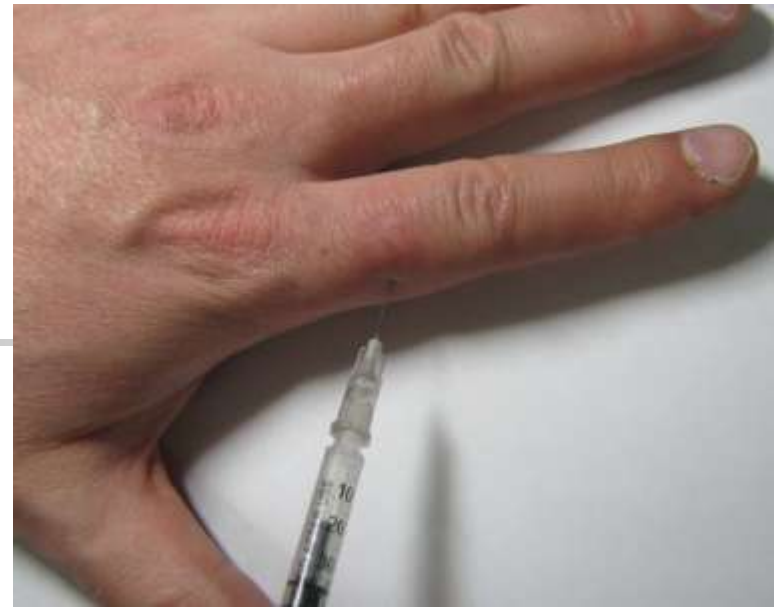It is painful!





Conductive anaesthesia according to Kullenkampf is an anaesthesia of a humeral plexus

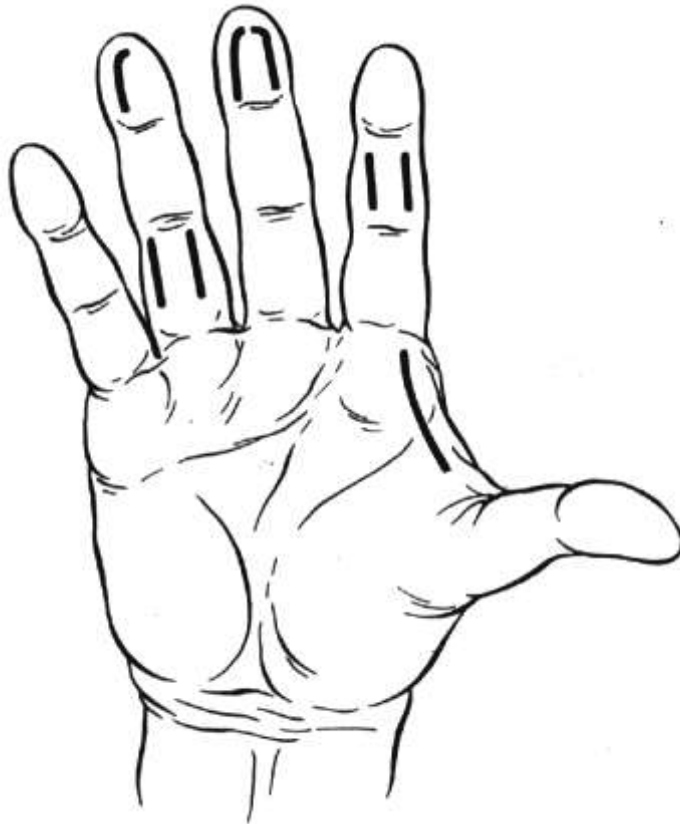



Operation is carried out under
Conductive anaesthesia according
to Lukashevich-Oberst



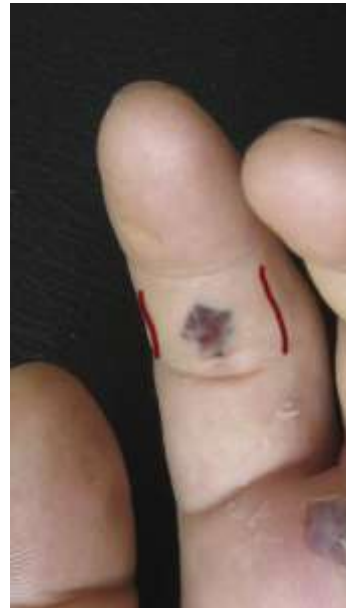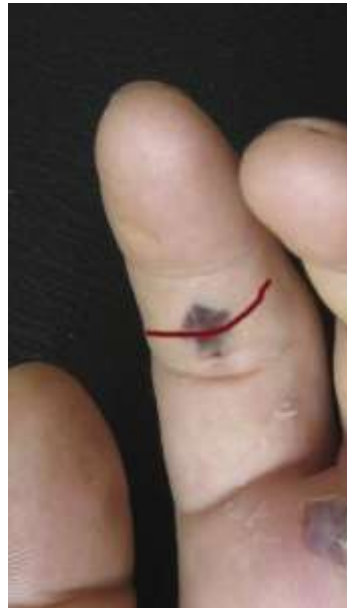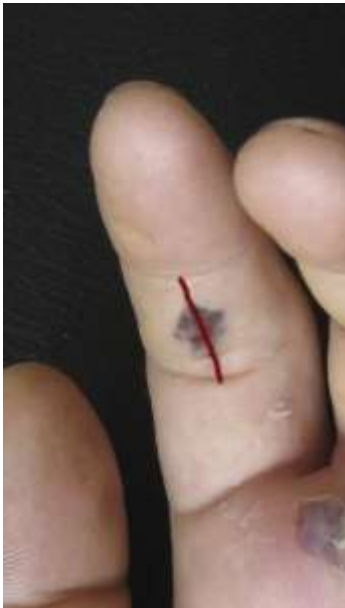Cuts in Subcutaneous felon



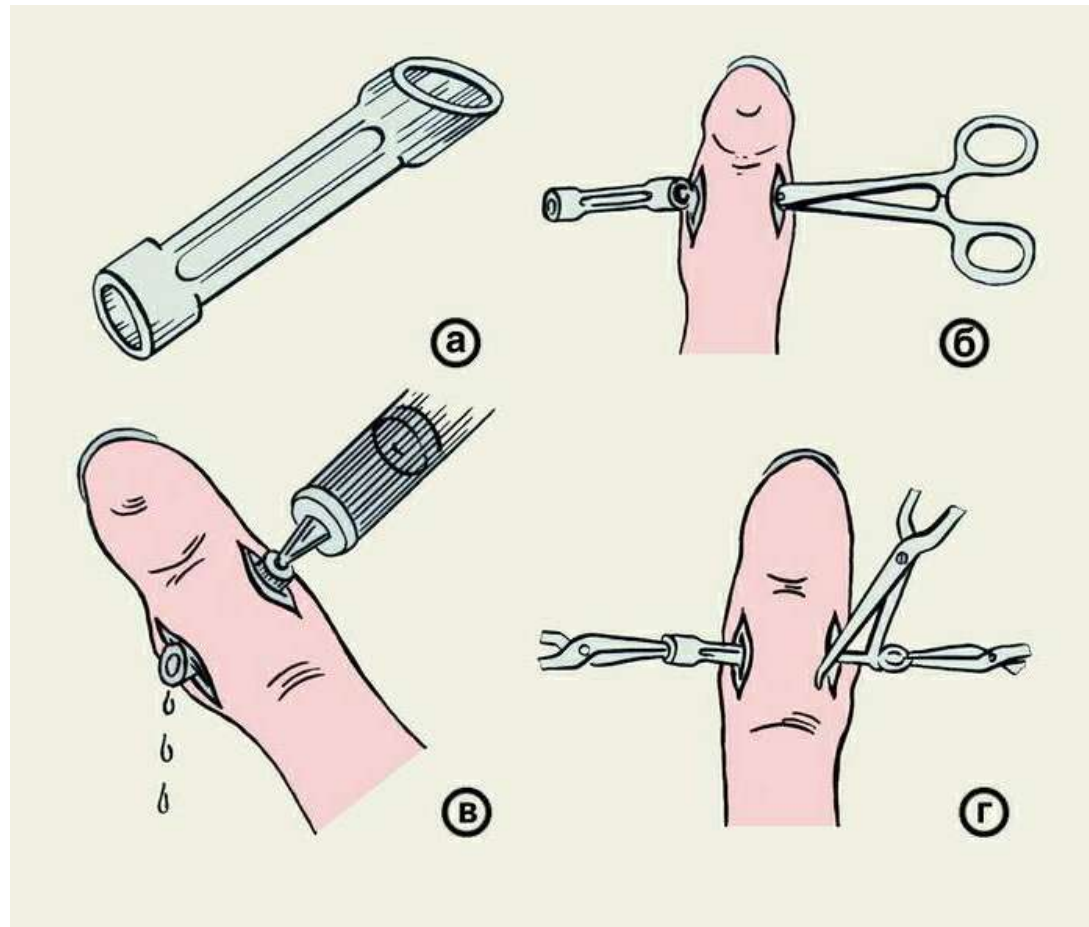
- Cuts on lateral surfaces of fingers
- " hockey stick " cuts on a distal phalanx



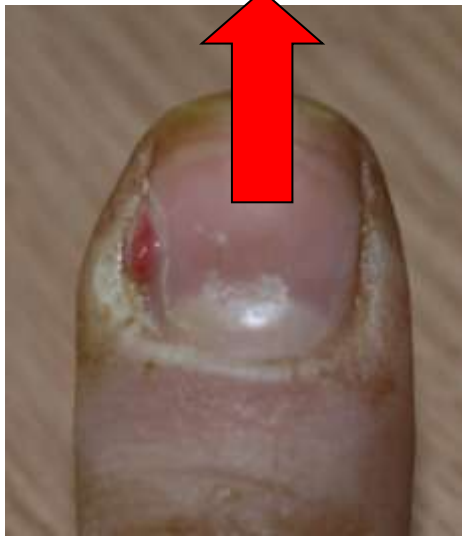Choose an optimum surgical cut at treatment of felon



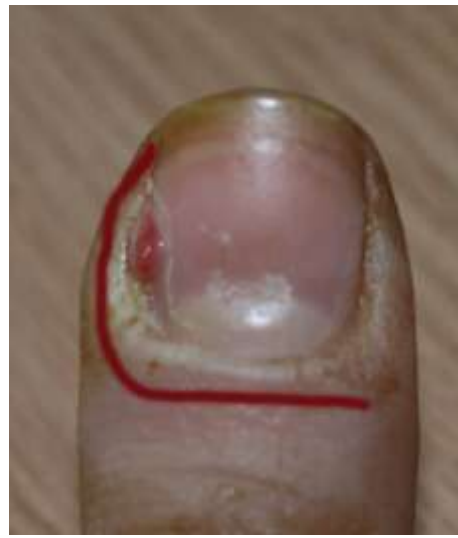Opening Subcutaneous felon



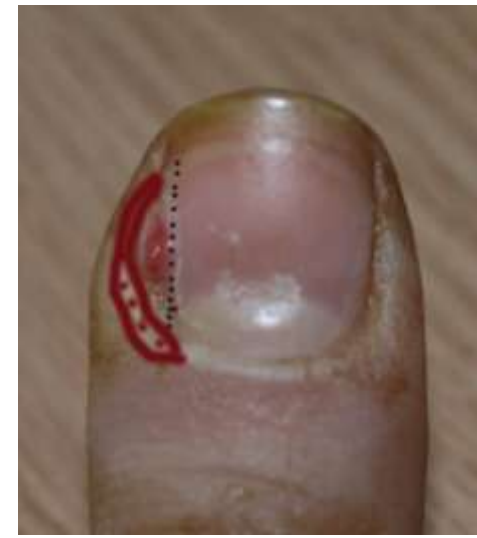Optimum surgical treatment of a paronychia



Removal of a nail plate



Cut along edge of the nail fold



excision of edge of the nail fold and regional resection of a nail plate

Correctly!



How to drain a wound after opening a felon?

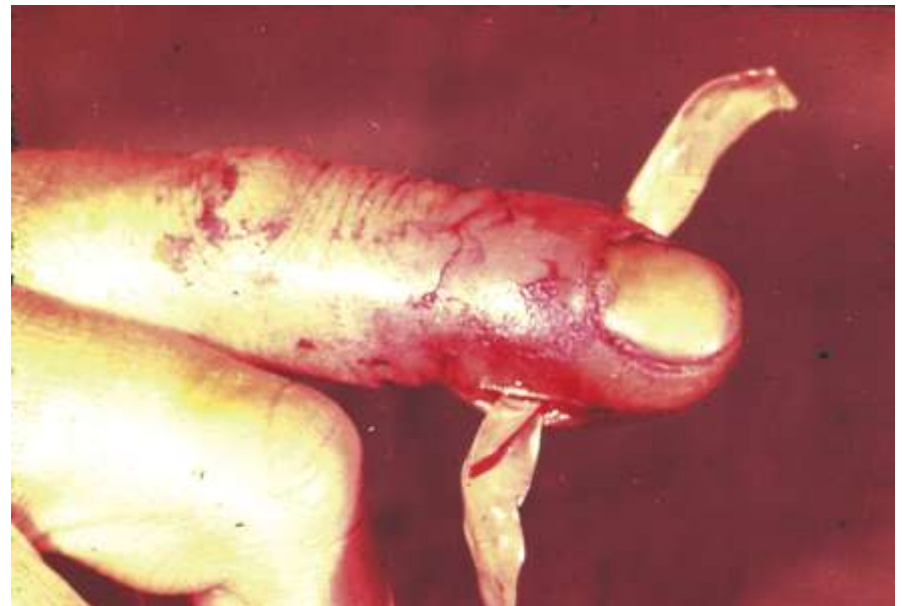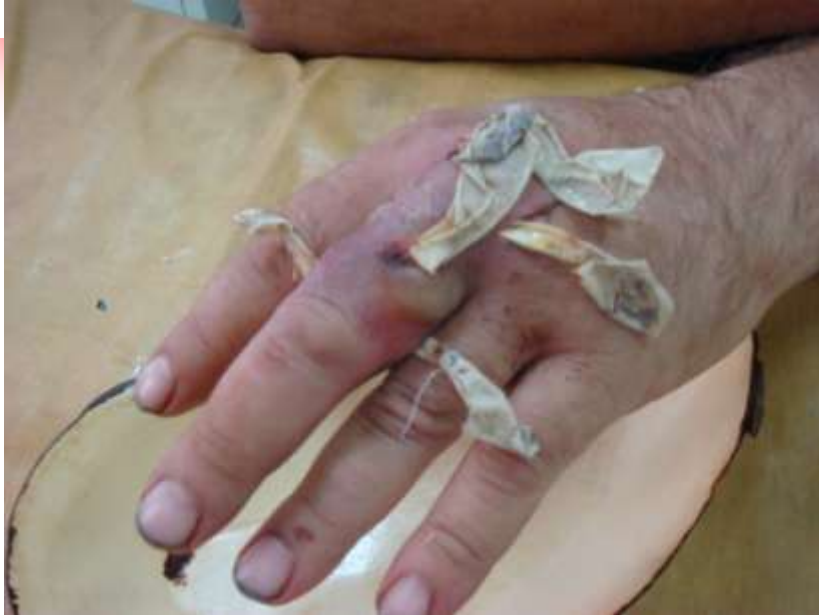- Gauze napkin with ointment Vishnevsky
- Rubber strip
- It is not necessary to drain. It is necessary to place suture



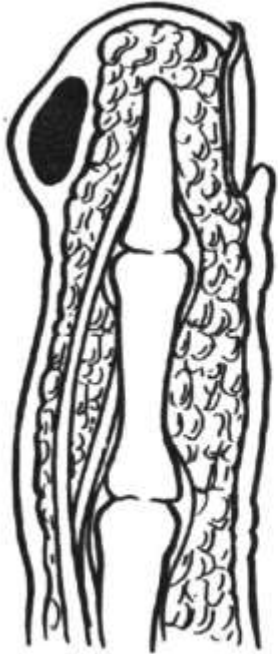
It is impossible so to act



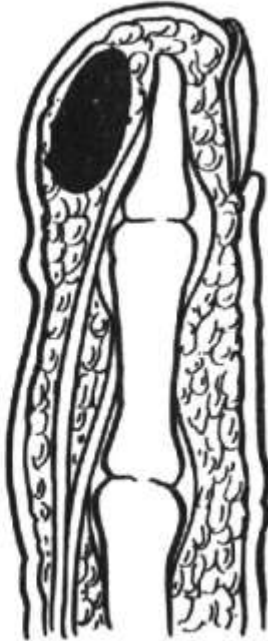

Opening felon



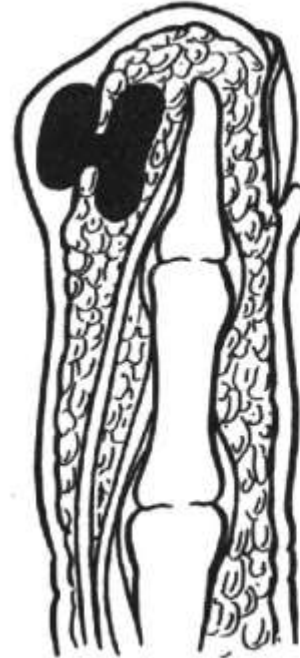Choose felon on the cuff link type



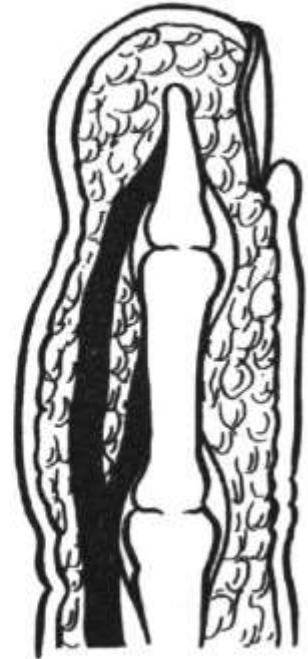

5




6




7



8

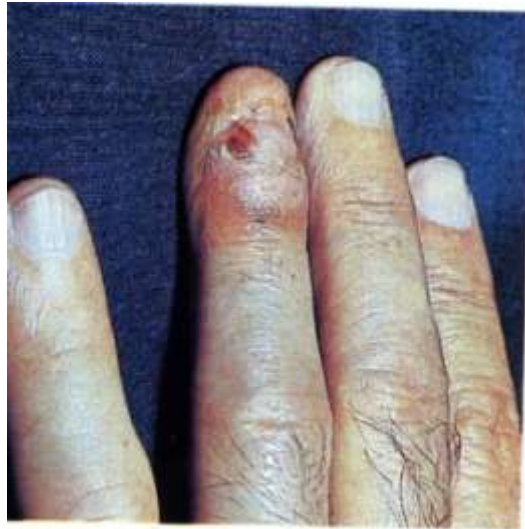



Correctly!

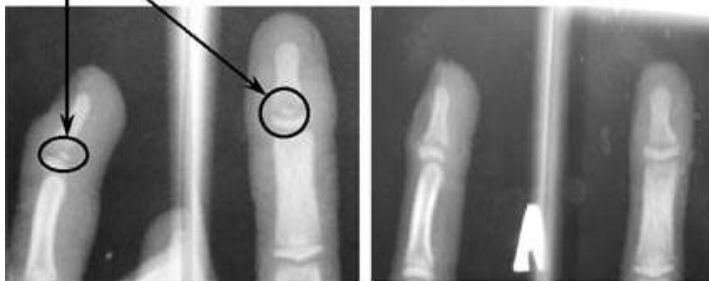

After a microinjury of a nail phalanx of a finger there was not healing wound with the purulent secretion. For medical care has addressed in two months from the disease beginning. In a hospital long treatment was carried out. Define character of a disease



- Purulent fistula of a finger
- It is long not healing felon
- Osteal panaritium (Bone felon)

sequestrum



Before
treatment

After
treatment

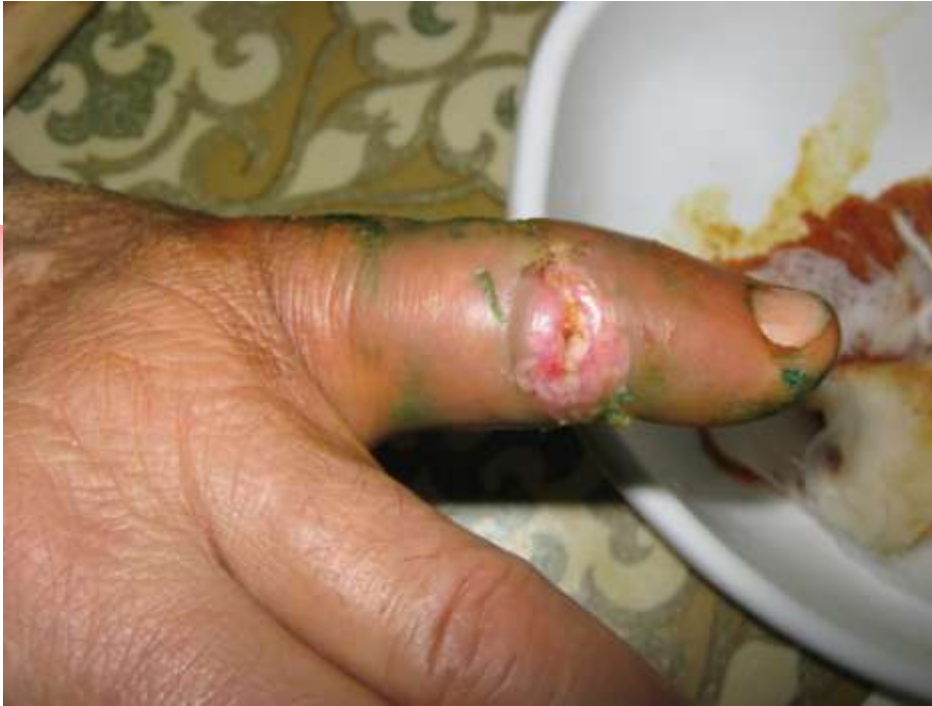

Bone felon is osteomyelitis of a bone phalanx of a finger.

Develops upon transition of pathological process from soft tissues of a finger to bone, i.e. process has secondary character.

Generally bone panaritium is the result of not appropriate treatment of.



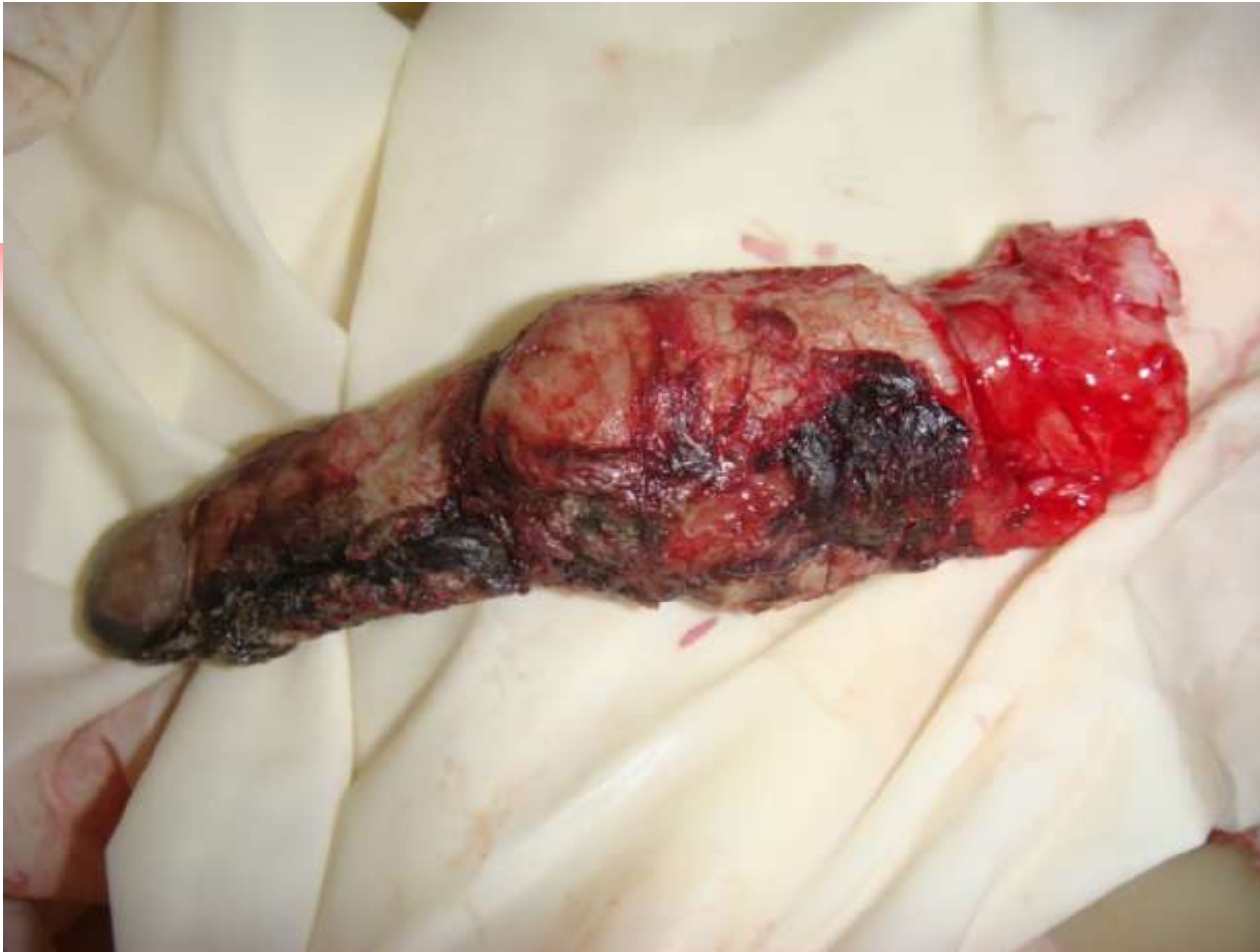

Microinjury of a finger a week ago – has pricked a finger with a wire.

In a x-ray picture rough pathology is not present.

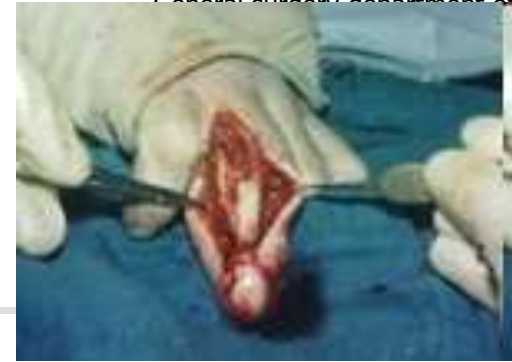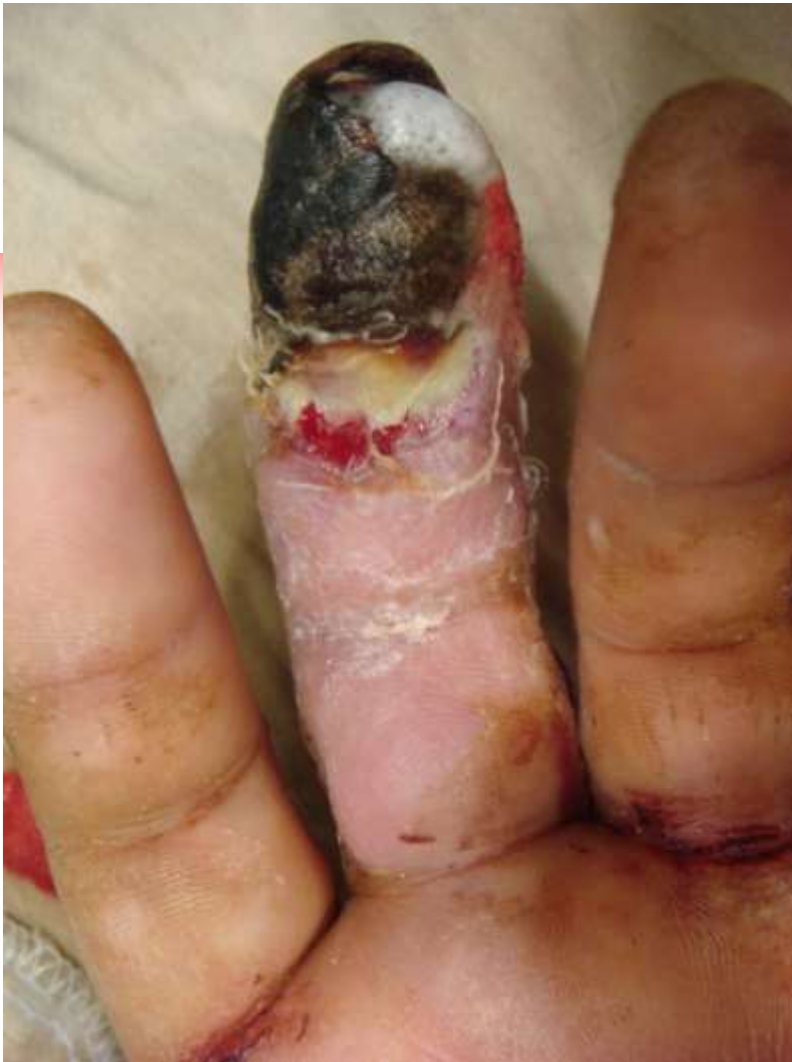Define treatment tactics

- Plaster immobilisation, cold, antibiotics
- Operation – an excision edges of a wound, opening a panaritium
- Thermal procedures, control of a x-ray picture



The result of your treatment will be such



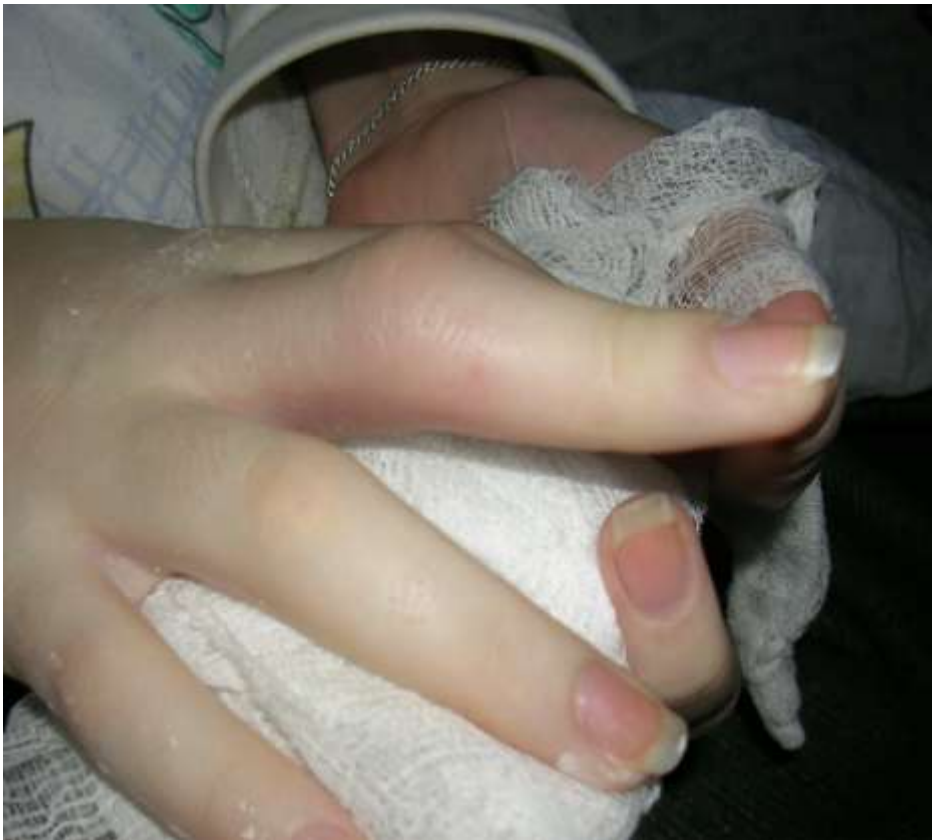

Operation should be carried out without waiting the obvious destructive changes defined radiological.

It is necessary to be guided by a clinical picture of a course of process. Diagnostic bone panaritium in 3-4 weeks in a phase of a sequestrum comes easy, but treatment will consist in finger amputation.



Has ached 2 weeks ago. The disease connects with a microtrauma. There was a redness in a joint. Disturbs pain at the straightened finger. Finger is bended. Diagnosis?

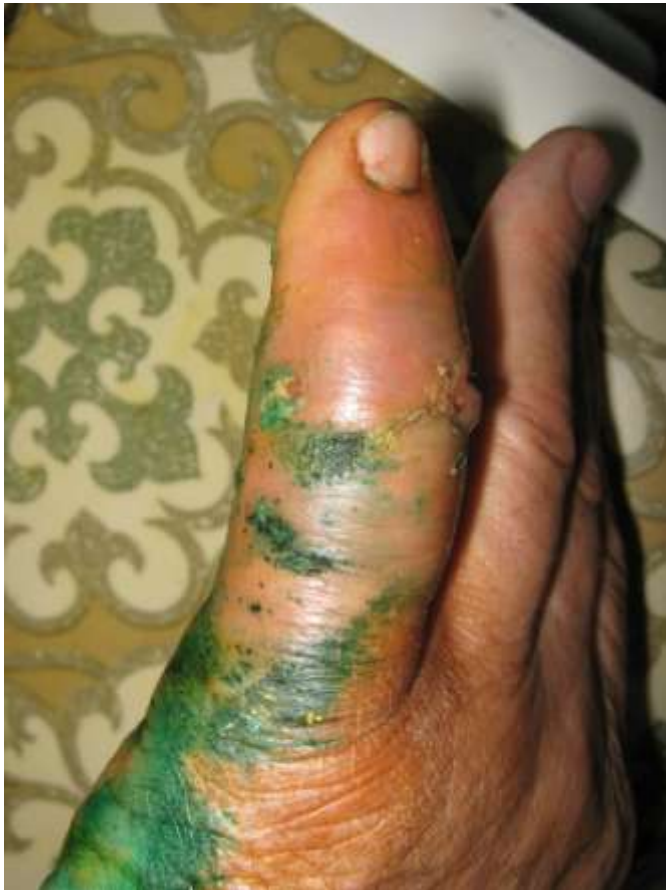

- Bursitis of interphalanx joint
- Erizepeloid
- Articular panaritium

- **serous -purulent inflammation of interphalanx and metacarpal-phalanx joints of fingers is called articular panaritium**
- **Primary articular panaritium– wounds getting into a joint, pricks**
- **The secondary – progressing bone, tendon, subcutaneous panaritium**



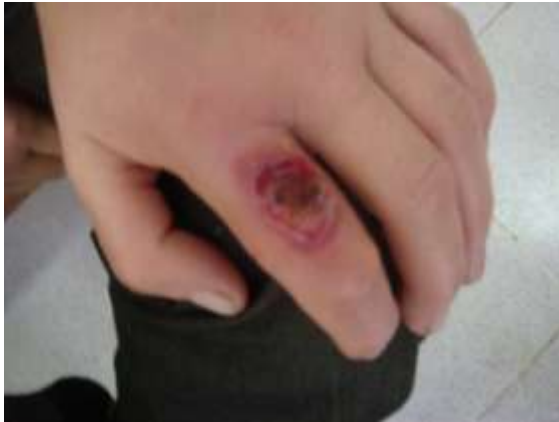Articular panaritium



- fusiform distension of a finger in projections of an interphalanx joint,
- sharp restriction of movements in a joint,
- tenderness at a palpation and at movements,
- appearance of pathological mobility and a krepitation in a joint.



Trauma 5 days ago. There is a purulent wound of the back of a finger. In polyclinic local treatment by bandagings with oil was carried out. Your tactics:



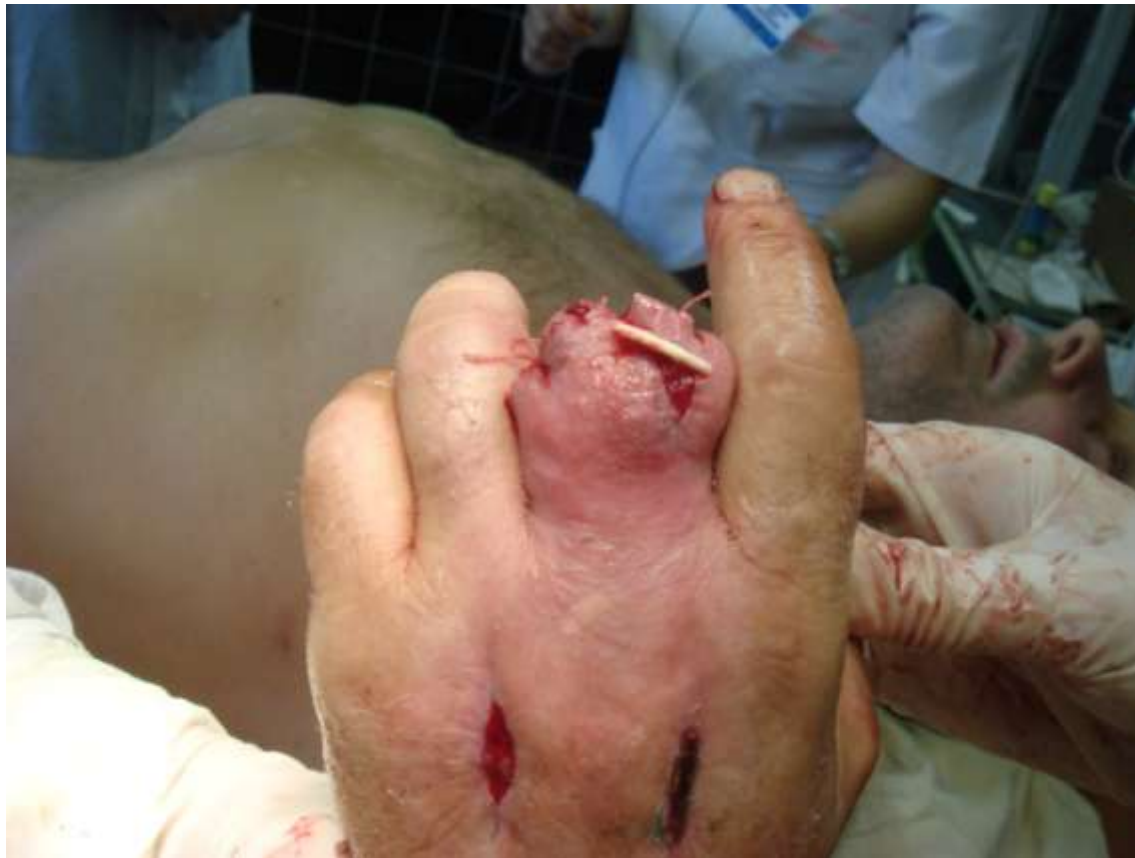- Hospitalisation in purulent department of a hospital
- Treatment in polyclinic to add with prescription of antibiotics
- Immediately to operate



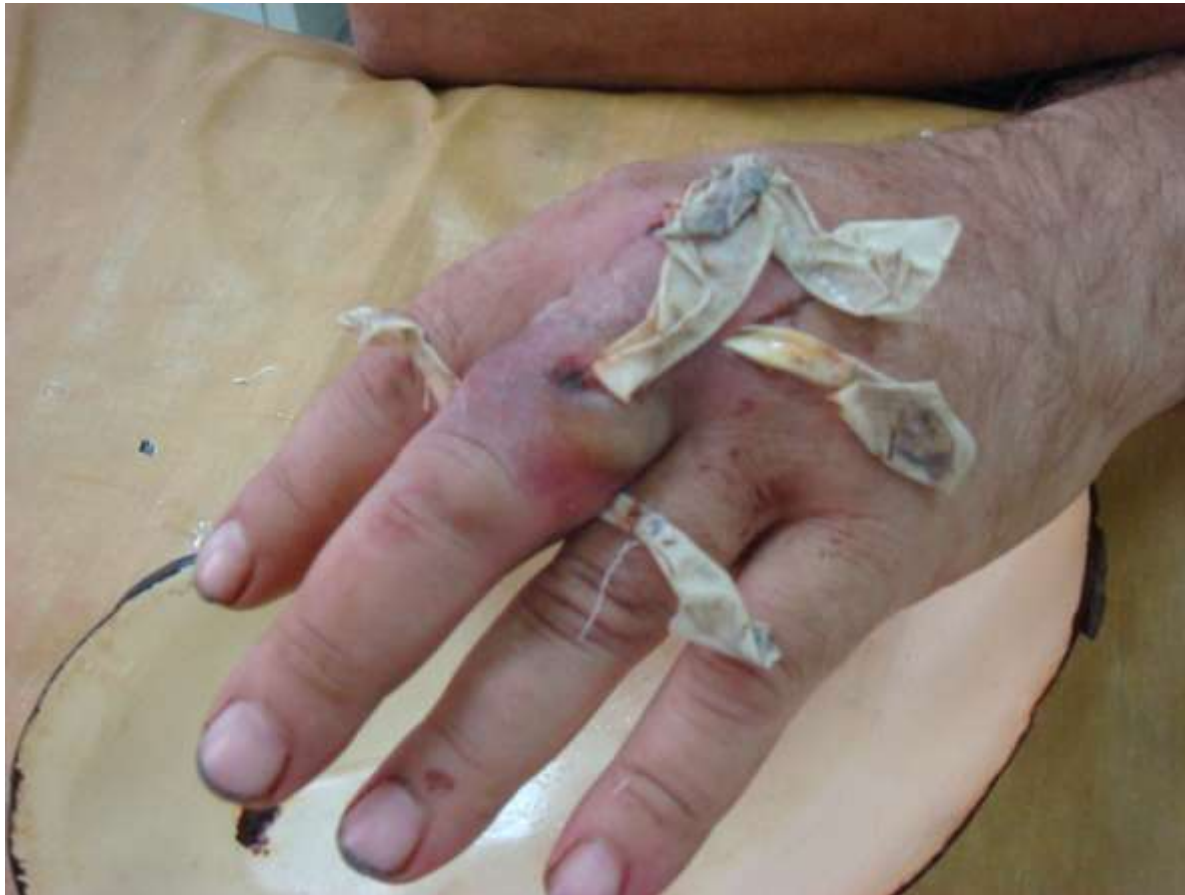What to operate?



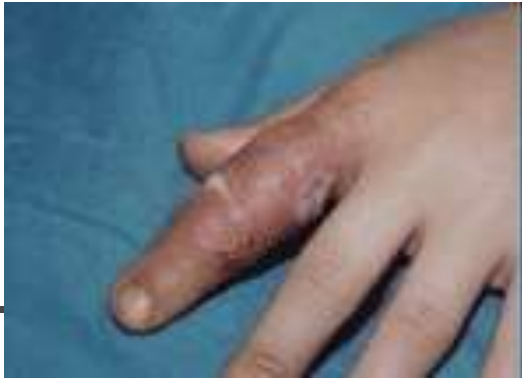Here result of such treatment



The patient will be dissatisfied. The insurance company can be dissatisfied. Operations can be demanded. But the patient will be under control of surgeons



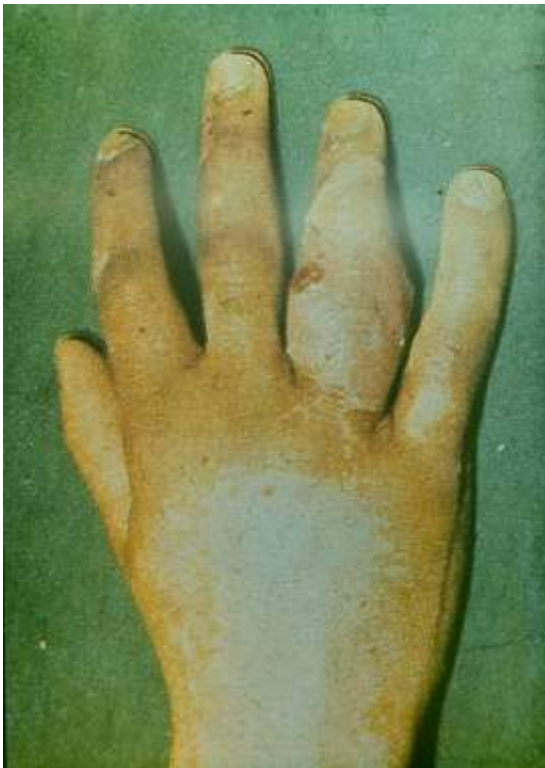Whether it is possible to keep a finger at this articular panaritium?




The finger should be amputated

It is necessary to apply a plaster immobilisation, to order antibiotics, a joint puncture with washing its by antiseptics

It is necessary to perform an arthrotomy with excision of articulate cartilages

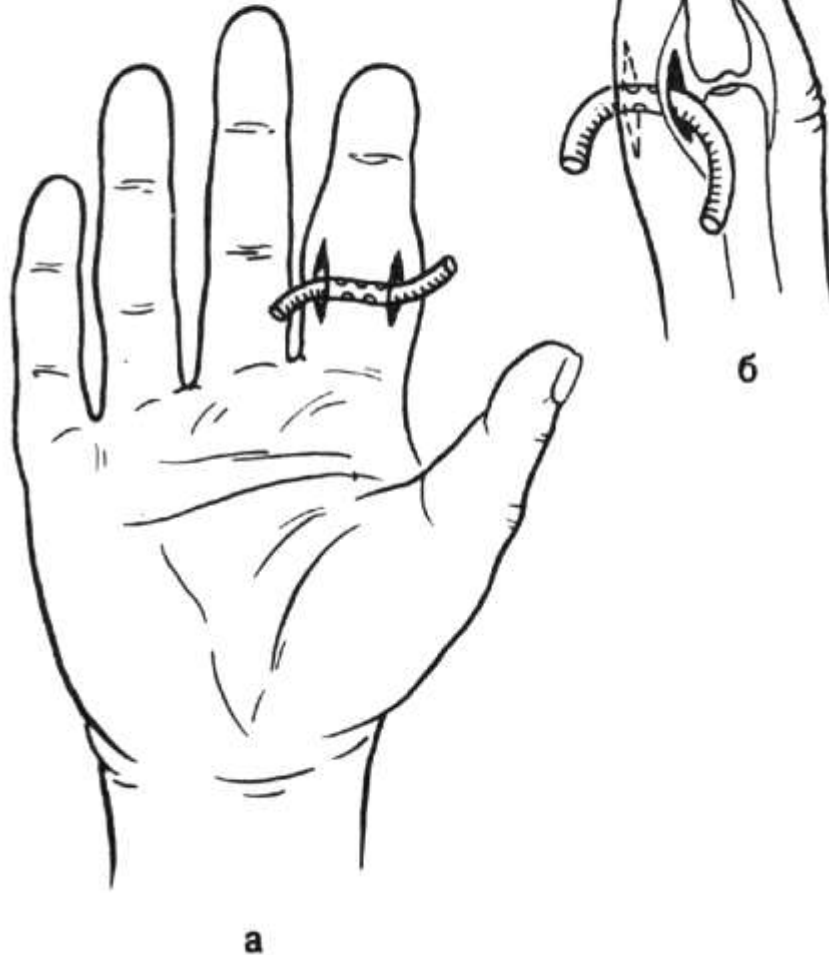




While early



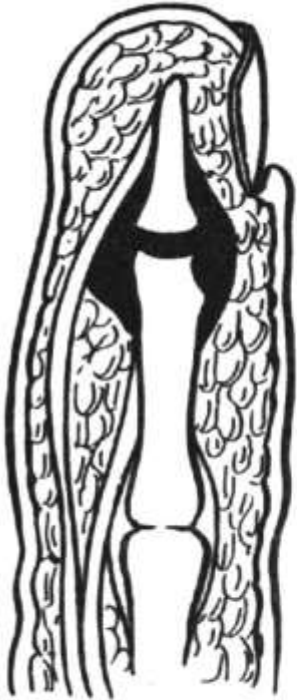Yes. It is necessary to try to keep a finger



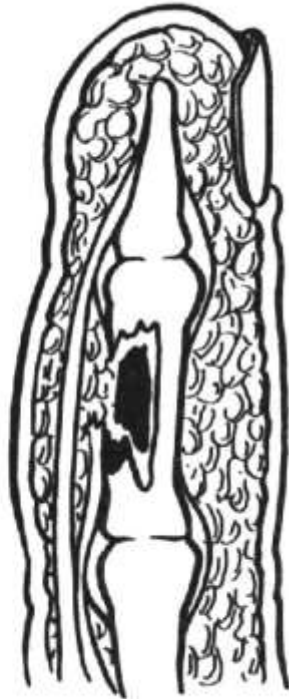
Treatment only surgical - is made an arthrotomy, careful sanitation of a cavity of a joint by antiseptics then the cavity of a joint is drained by the punched polymeric tube. It is necessary to close a wound over a joint cavity.



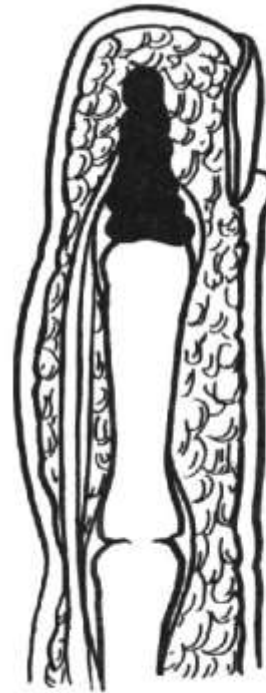

In what case finger amputation is shown?



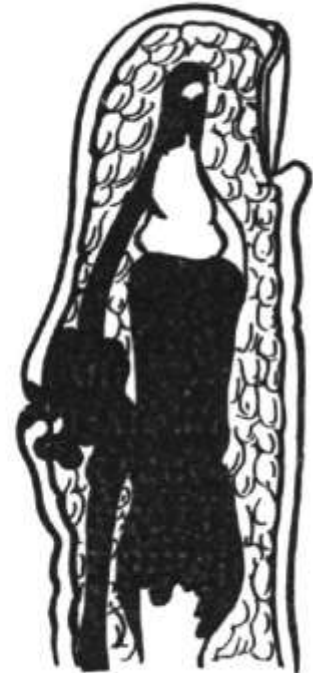9




10



11



12

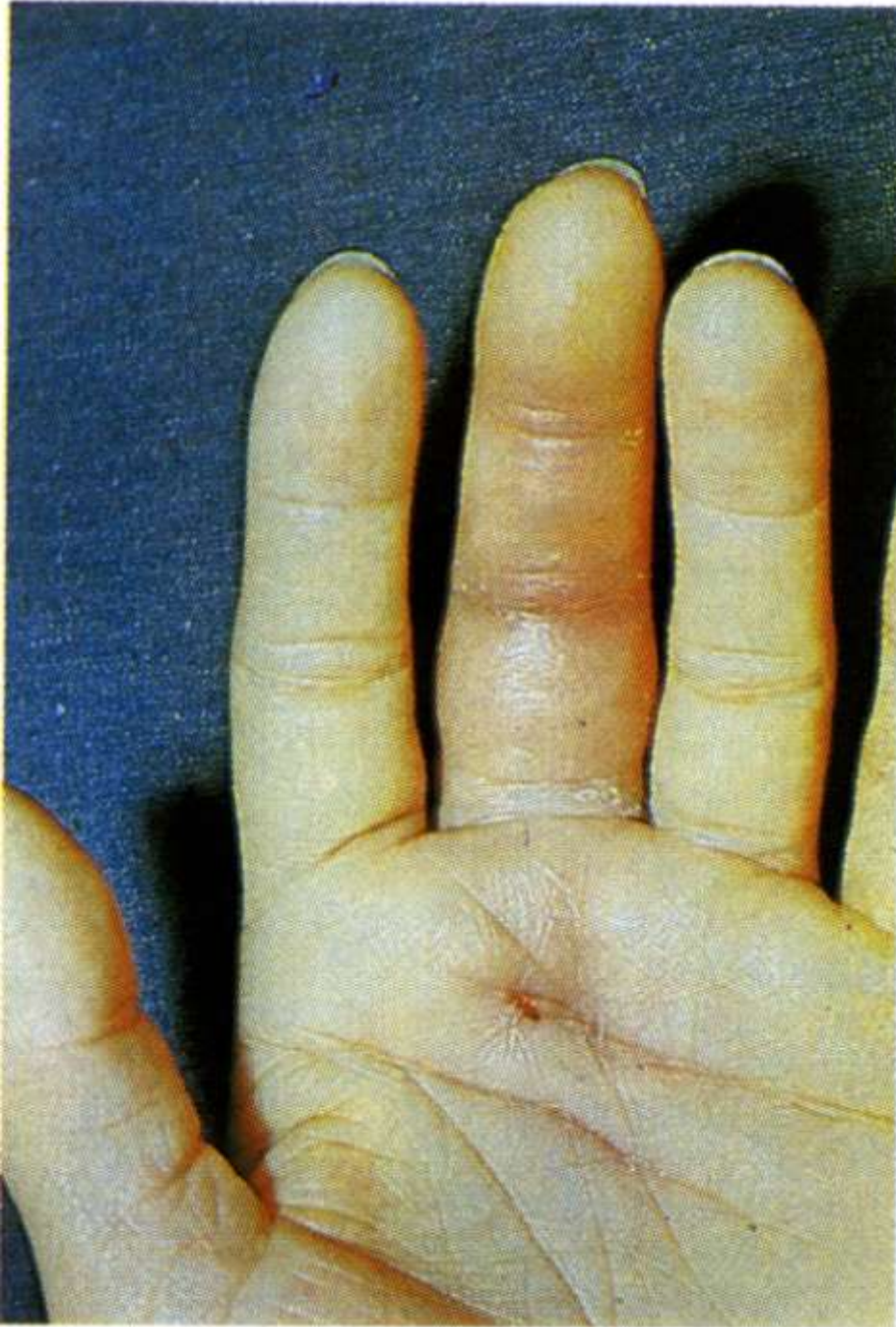



In two last cases amputation
is shown



Tendinous panaritium



one of the heaviest types panaritium. There is signs of purulent tendovaginitis. The disease develops due to primary entering of an infection into a tendon sheath of flexor(at a cut, a prick etc.), or as progressing of hypodermic process at inadequate treatment of the last. Development of a purulent infection in tendon sheath has bright clinical picture - the patient is disturbed by the expressed pains along the whole length of tendon, any movements are extremely painful. The surgical help should be performed as soon as possible as tendons quickly die in the conditions of surrounding purulent process.



Tendinous panaritium

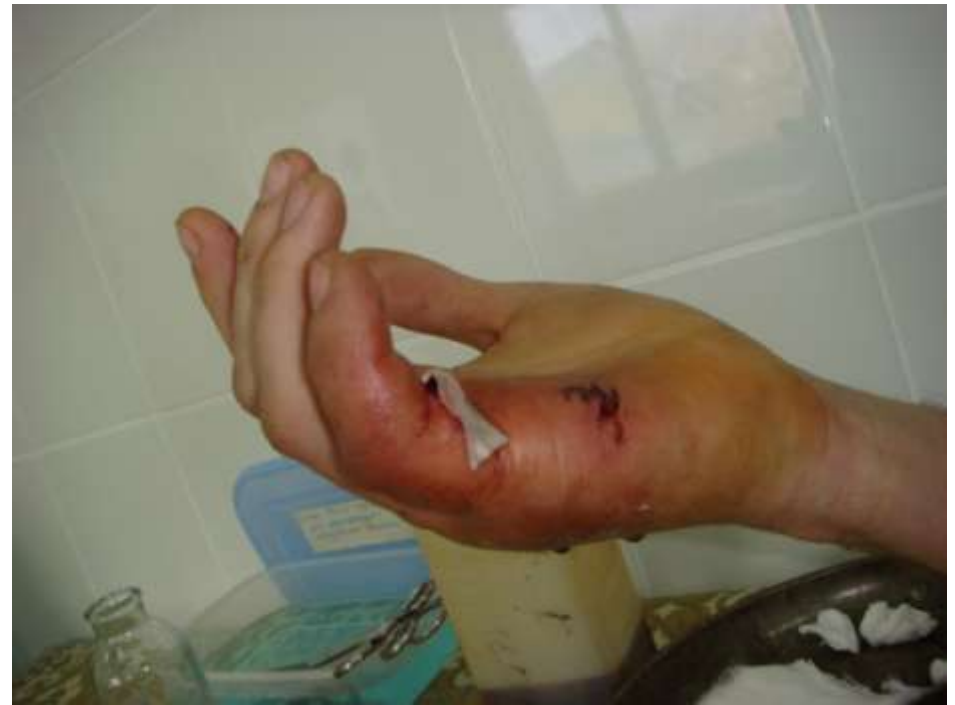- **Uniform swelling of all finger with edema on a back surface of a hand;**
- **tenderness at pressure by a probe along the whole length of tendon sheath , precisely limited by a zone of its location;**
- **Sharp pain at movements, especially at a straightening;**
- **Finger fixing in the position of easy bending.**



Tendinous panaritium

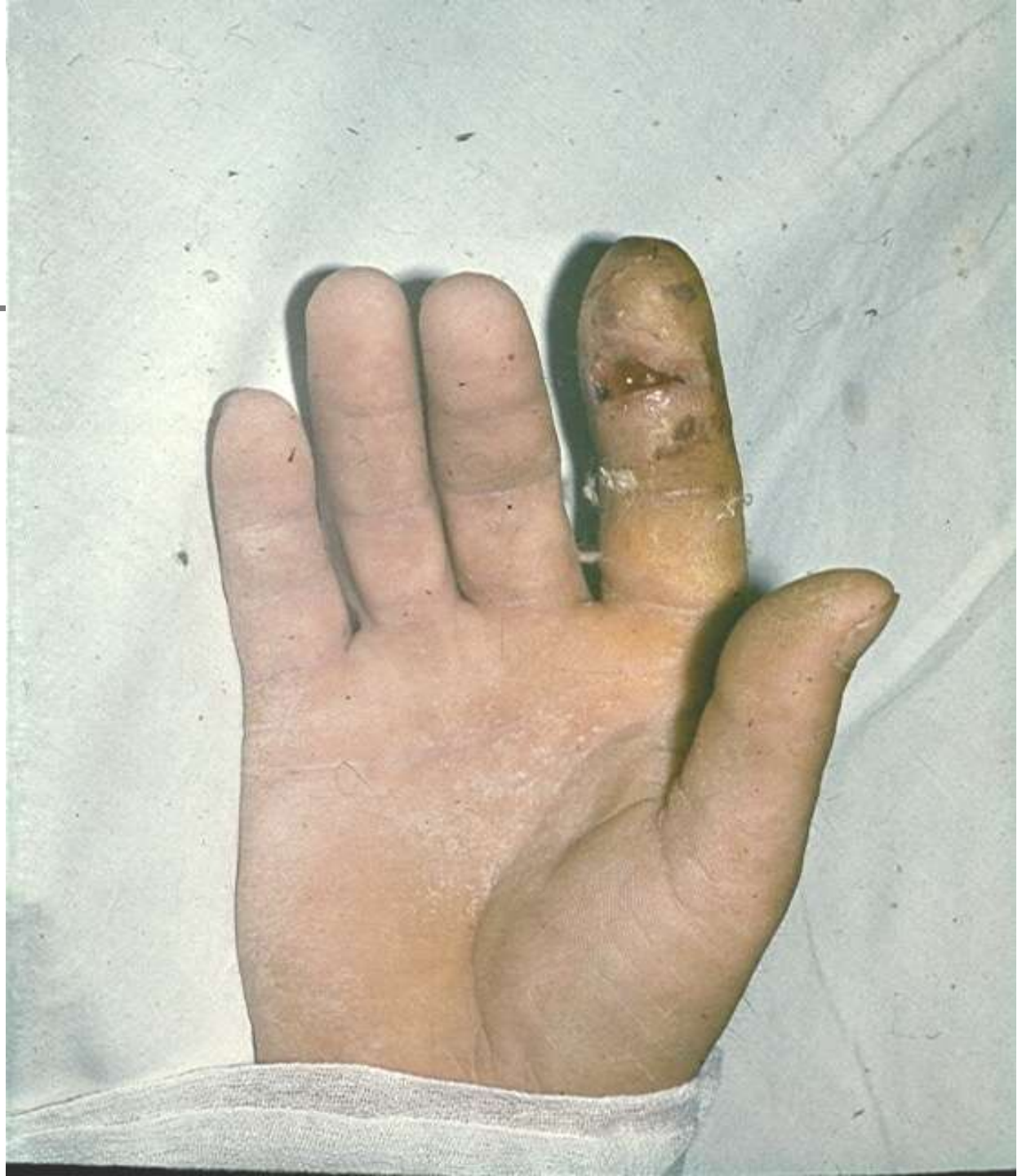General surgery department of SGMU
ass. Khilgiyaev R.H

At development of a purulent infection in a tendon sheath the expressed pain along the whole length of tendon sheath disturbs, any movements are extremely painful.



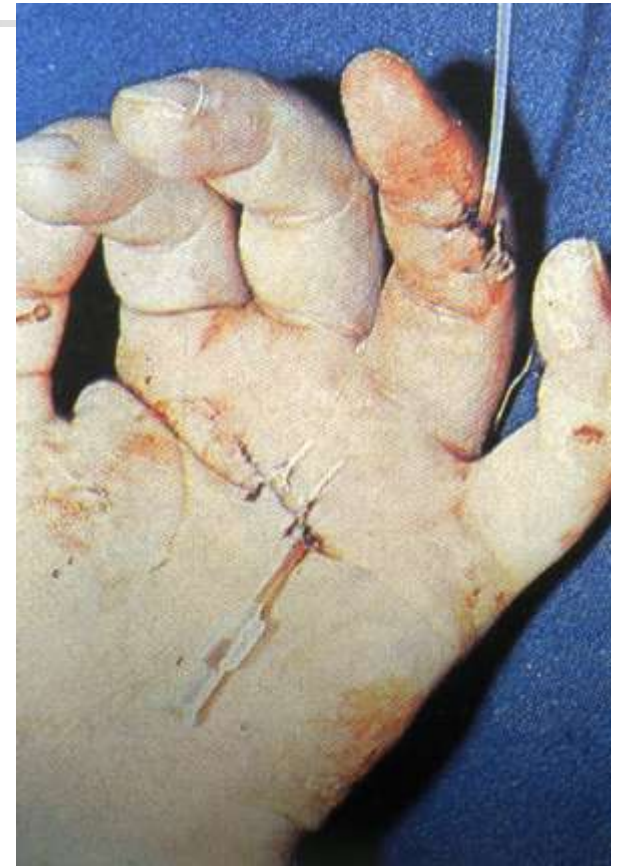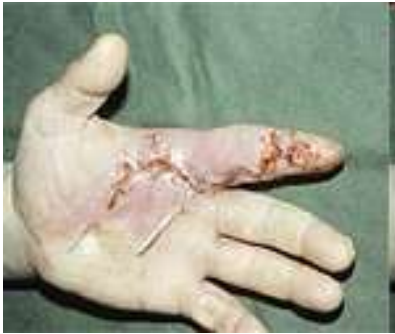Tendinous panaritium

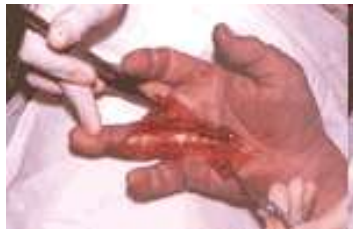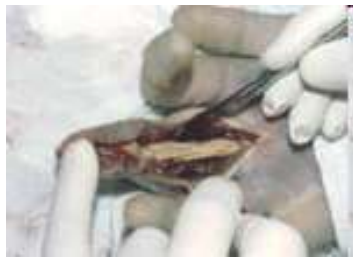The surgical help
should be performed
as soon as possible
as tendons quickly
die in the conditions
of surrounding
purulent process



Tendinous panaritium

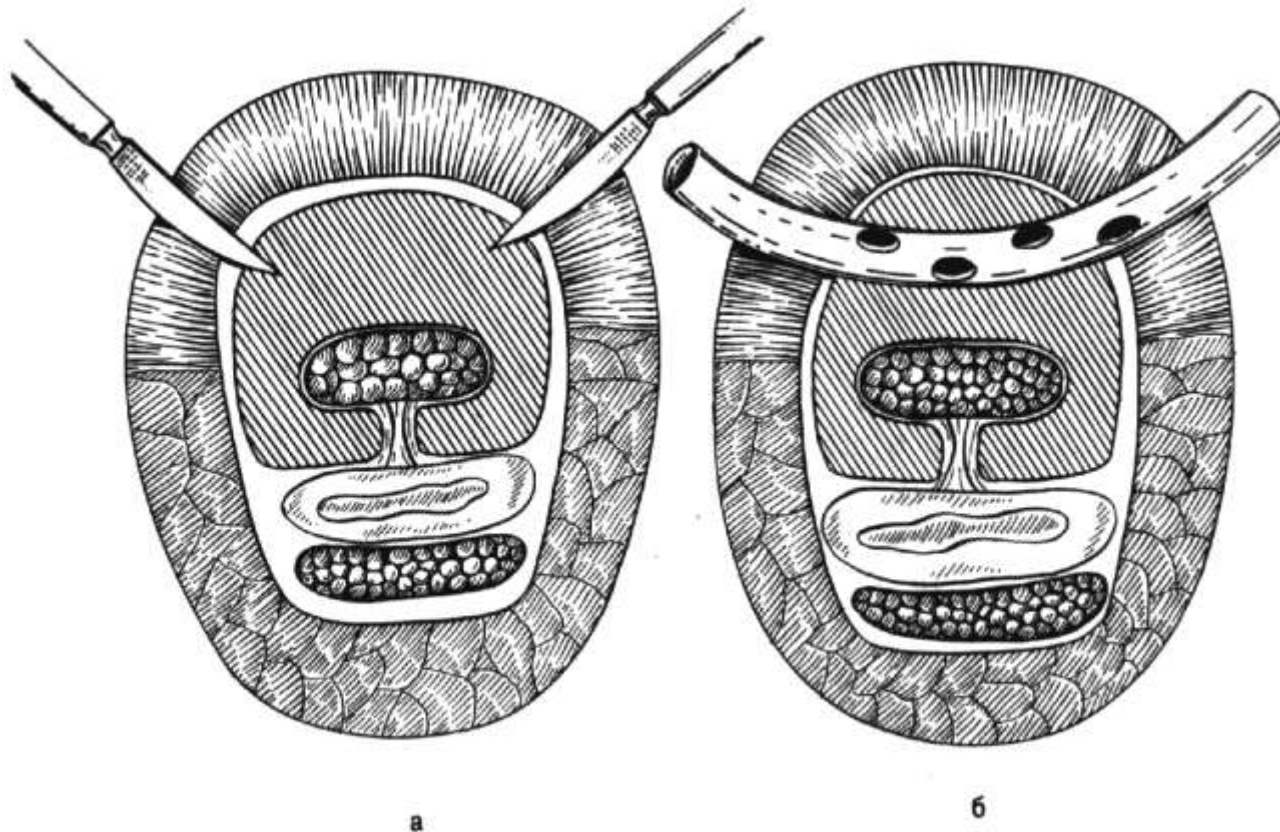
Operation is made under conductive anaesthesia or under narcosis. The main task of operation – to open a tendon sheath and to estimate viability of a tendon. If it is viable, the sheath is carefully washed out by antiseptics from two parties and is drains by the punched polymeric tubu.





- At identification of a necrosis of tendon the last is cut within healthy tissues. Operation is ended with wound filling by a gauze strip with levomekol. Further, secondary sutures are placed.

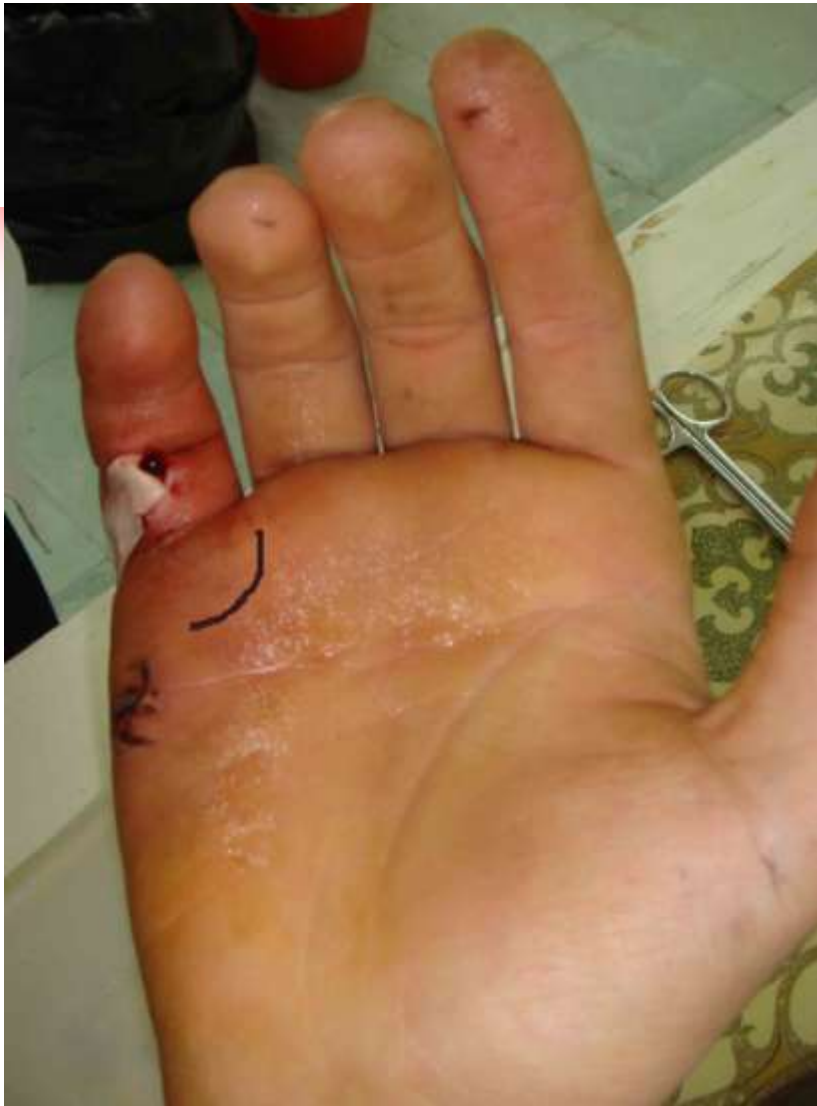



Opening of a sheath releases a finger tendon from pressure and prevent necrosis



Opening Tendinous panaritium



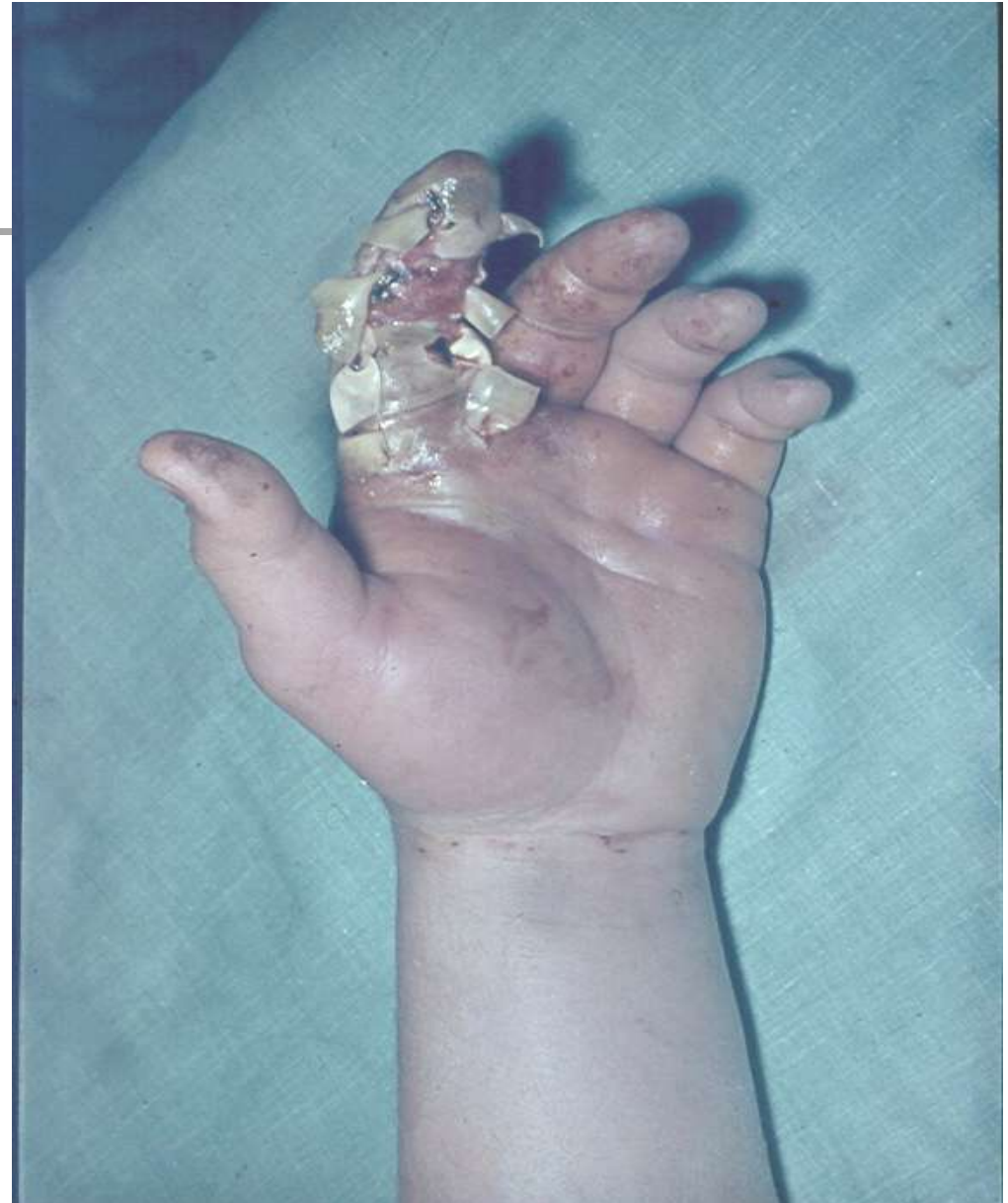it is important to open end of the sheath at level of a head of a metacarpal bone. For this purpose use a " hockey stick " cut below the finger basis



Whether it is
correctly opened
Tendinous
panaritium?

Yes. Some cuts are executed.
The abscess is adequately
drained.

No. Viability of a finger in
doubt

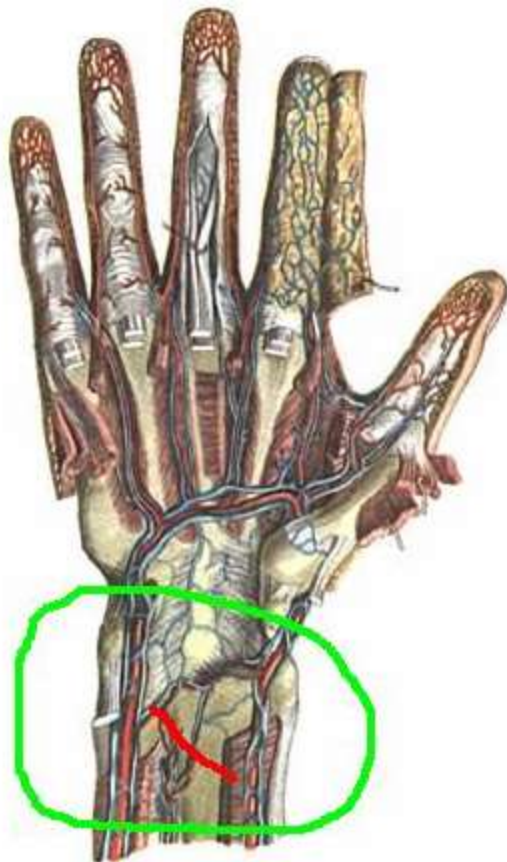




Part of surgeons open Tendinous panaritium exactly so. But ...

On a photo it is visible that soft tissues of a finger are inflamed on all its extent. It means that the necrosis of a tendon has taken place. It is impossible to remove a tendon from a set of small cuts. It will continue to support pyoinflammatory process before development pandactylitis.

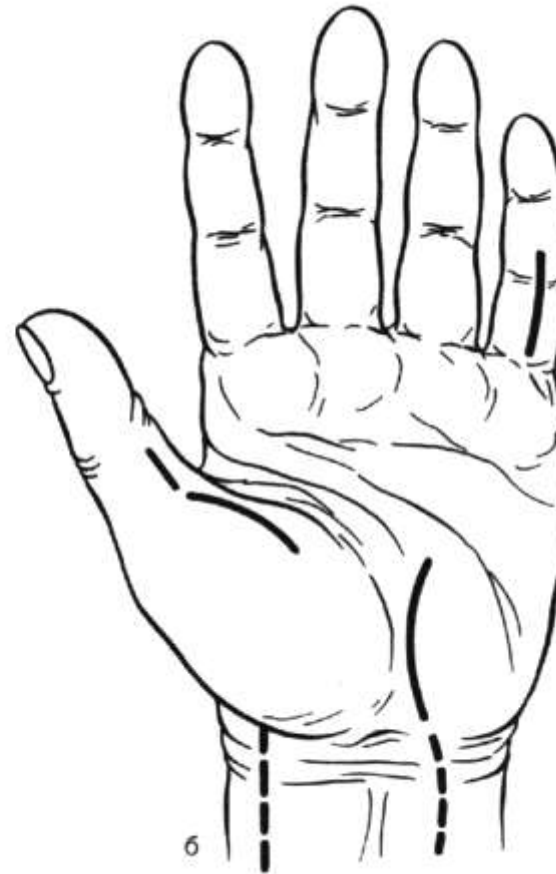
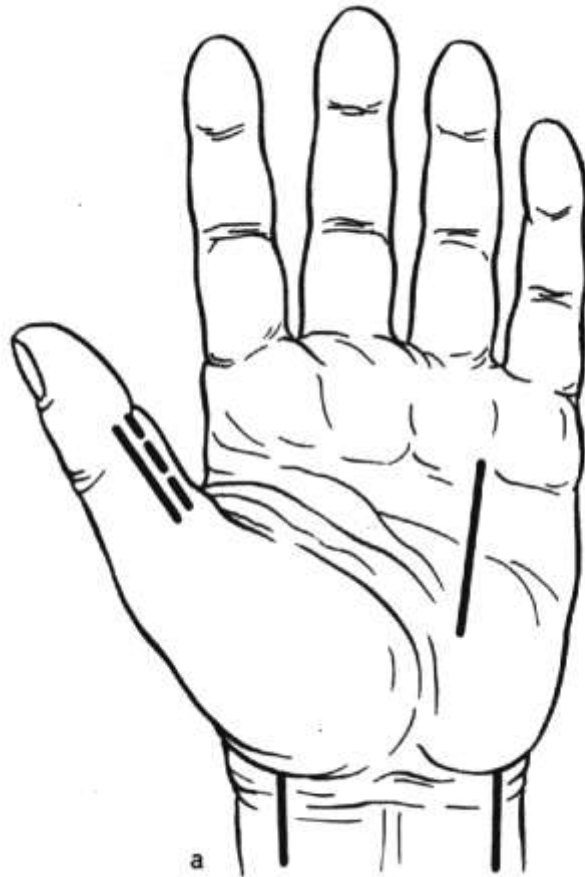


- tendon sheaths II-IV fingers end at level of heads of metacarpal bones.
- sheaths I and V fingers proceed on a forearm via the karpal channel
- Therefore progressing of purulent tendovaginitis I and V fingers leads to development of phlegmon of Pirogovsky space of a forearm




inTendinous panaritium I and V fingers opening deep space of a forearm is necessary





pandactilitis is

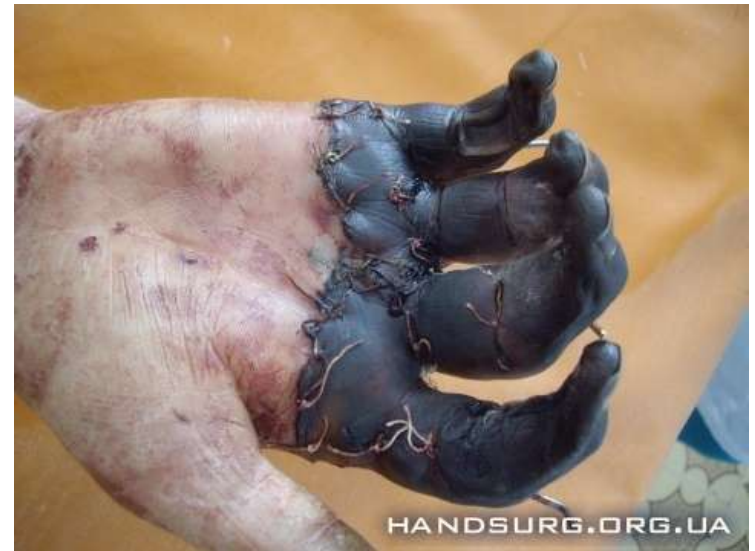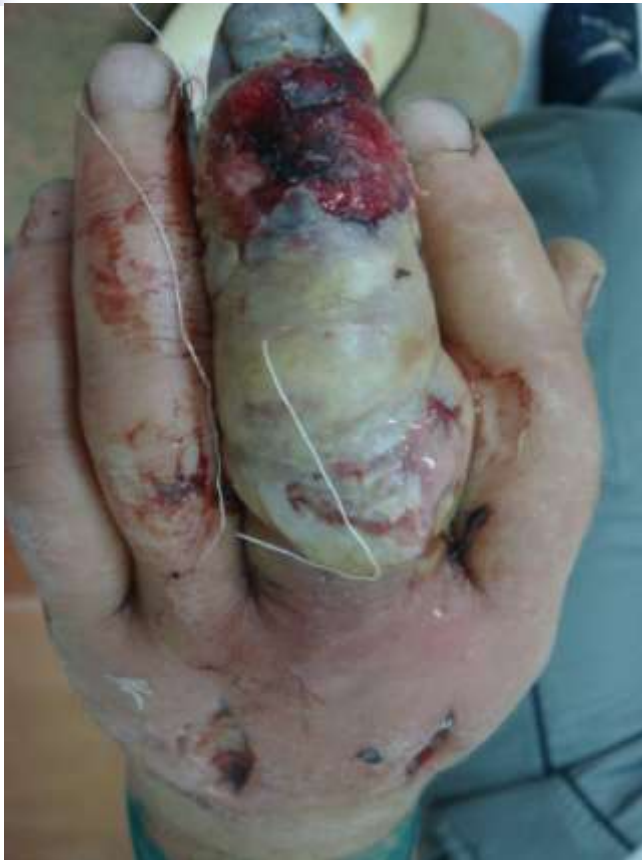- Inflammation of all fingers
- It is purulent - necrotic lesions of all structures of a finger
- Finger gangrene



pandactilitis is nonspecific purulent - necrotic lesions of a finger extending not less than on two phalanxes and affecting skin, subcutaneous tissue, tendon, a bone or at least one of joints. Pandactilitis is not gangrene.



In what photo it is represented Pandactilitis ?





No. It is a necrosis of fingers after
their unsuccessful transplantation



Correctly. Itself Pandactilitis yet is not the indication to finger amputation, but its probability is high

