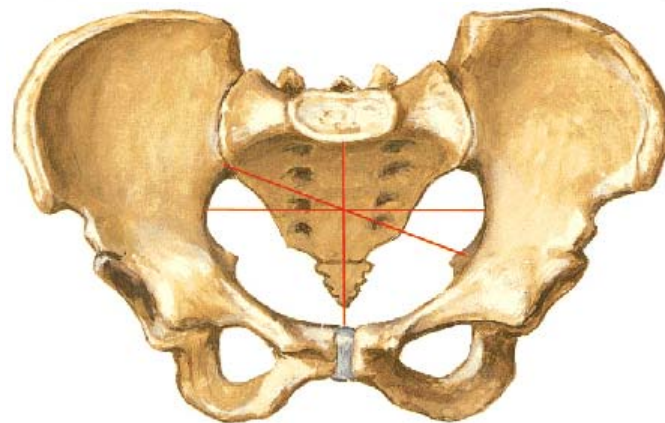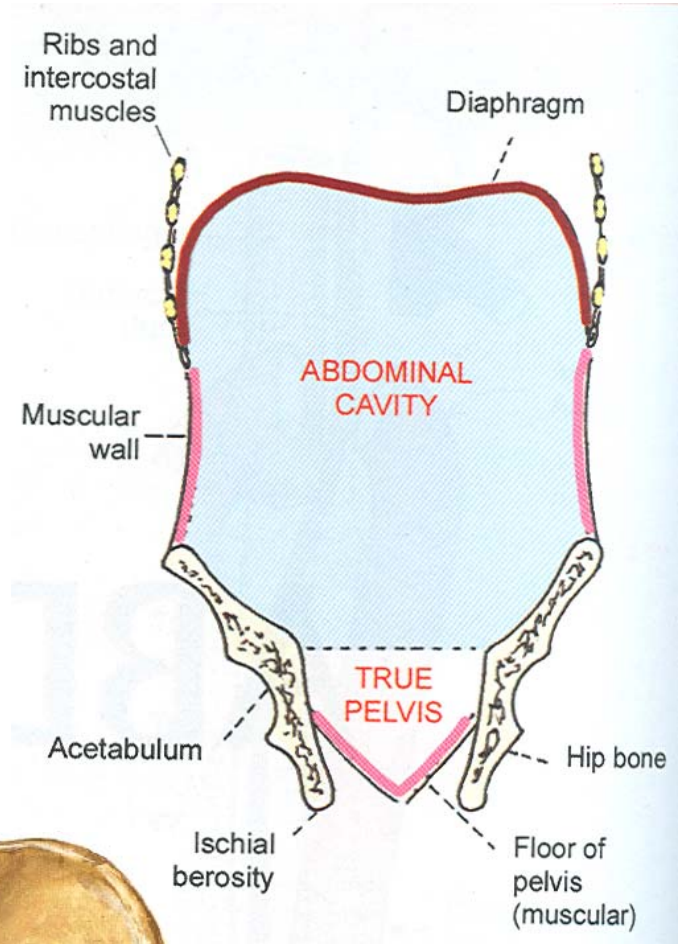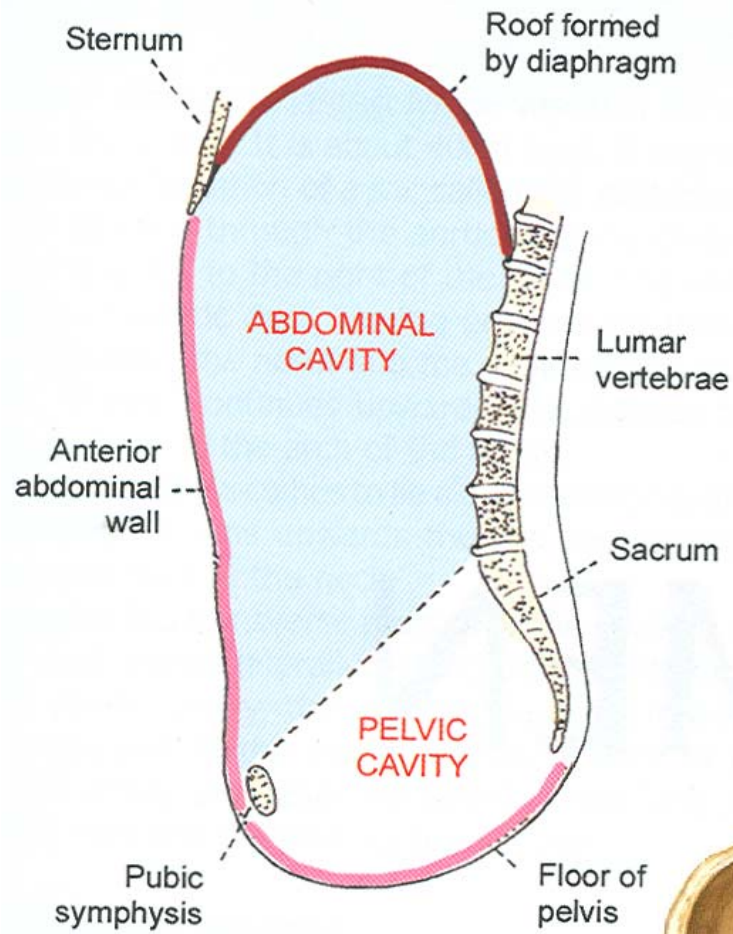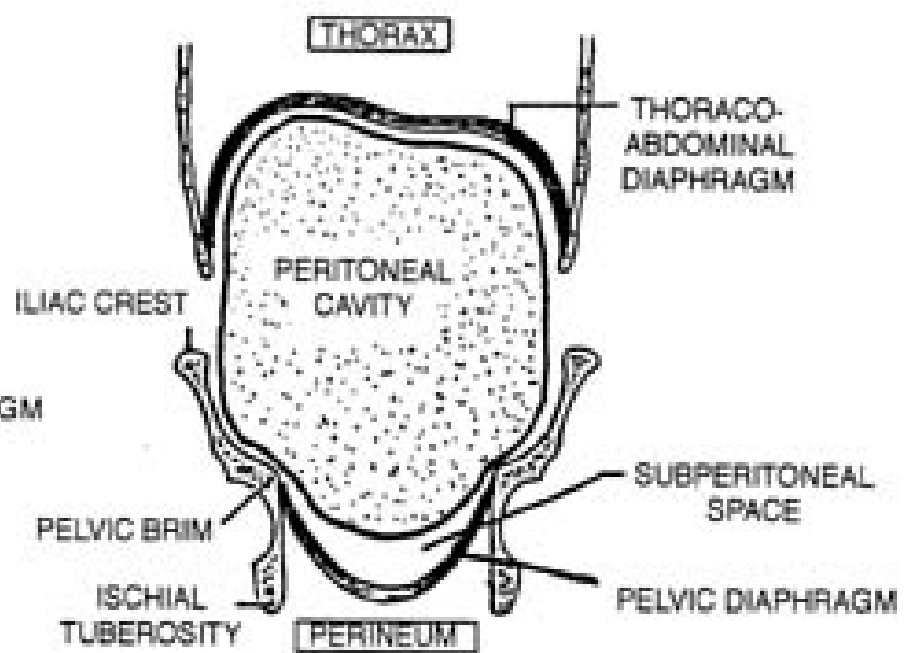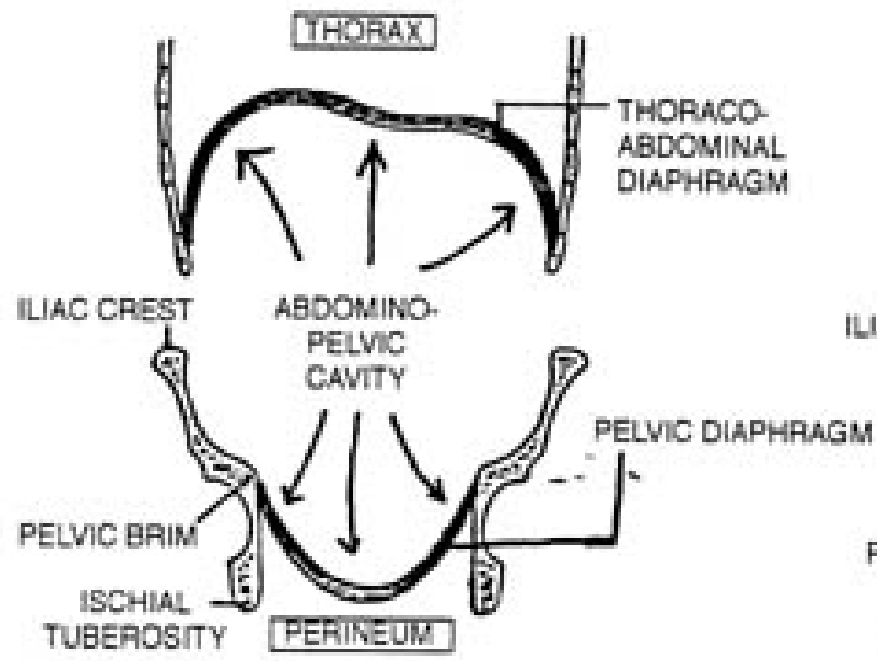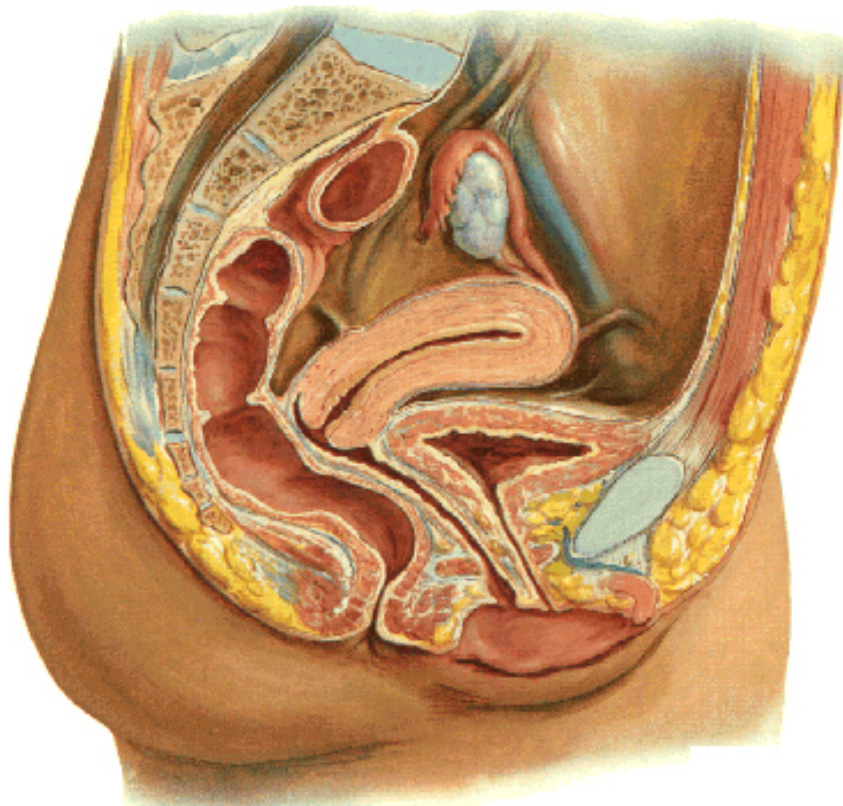
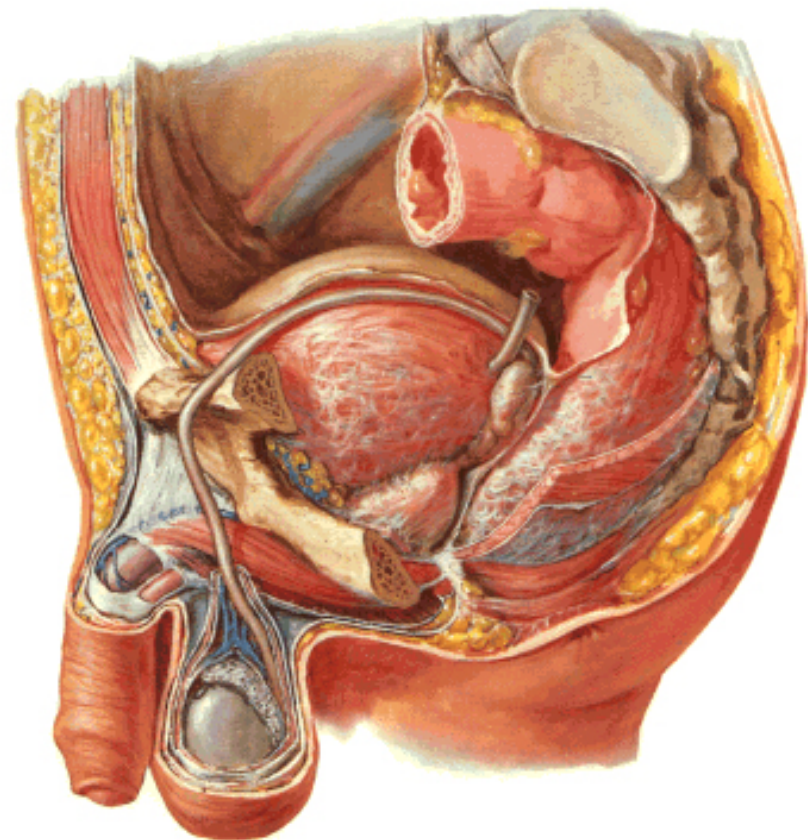


Pelvis

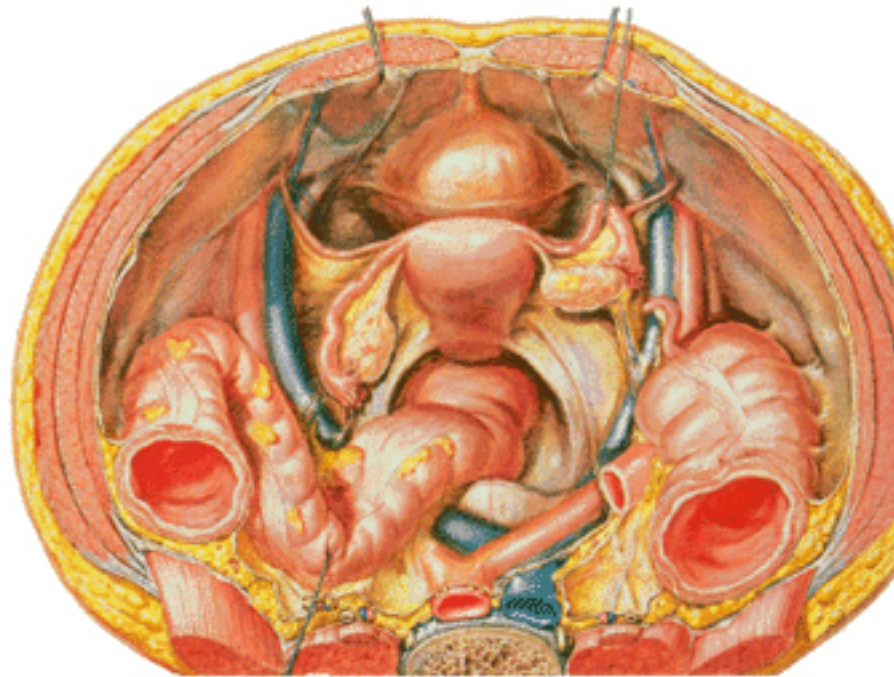
Pelvic Viscera and Perineum of Female
Midsagittal Section



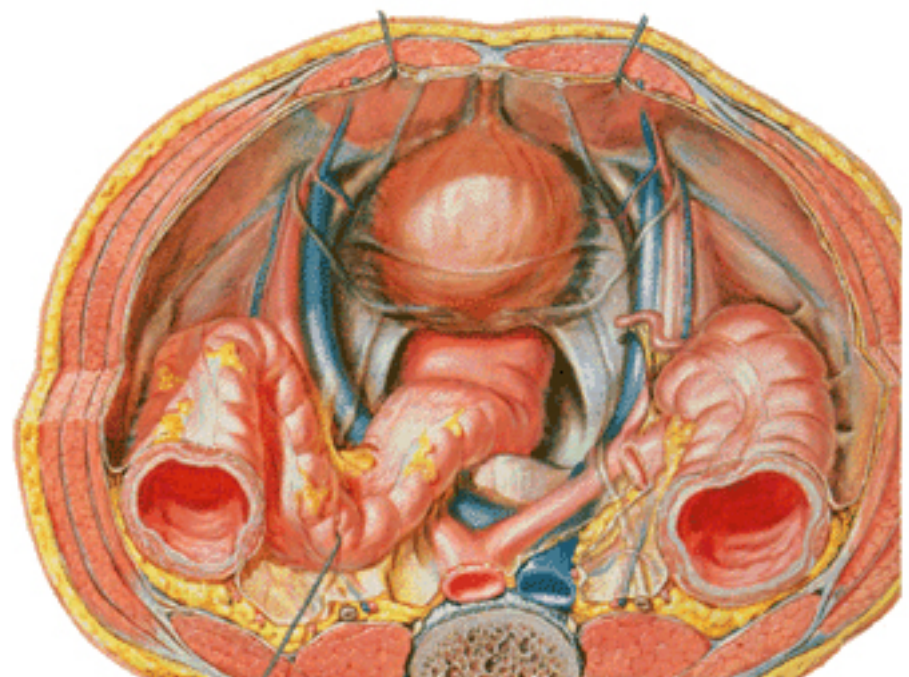
Pelvic Viscera and Perineum of Male
Paramedian Sagittal Section



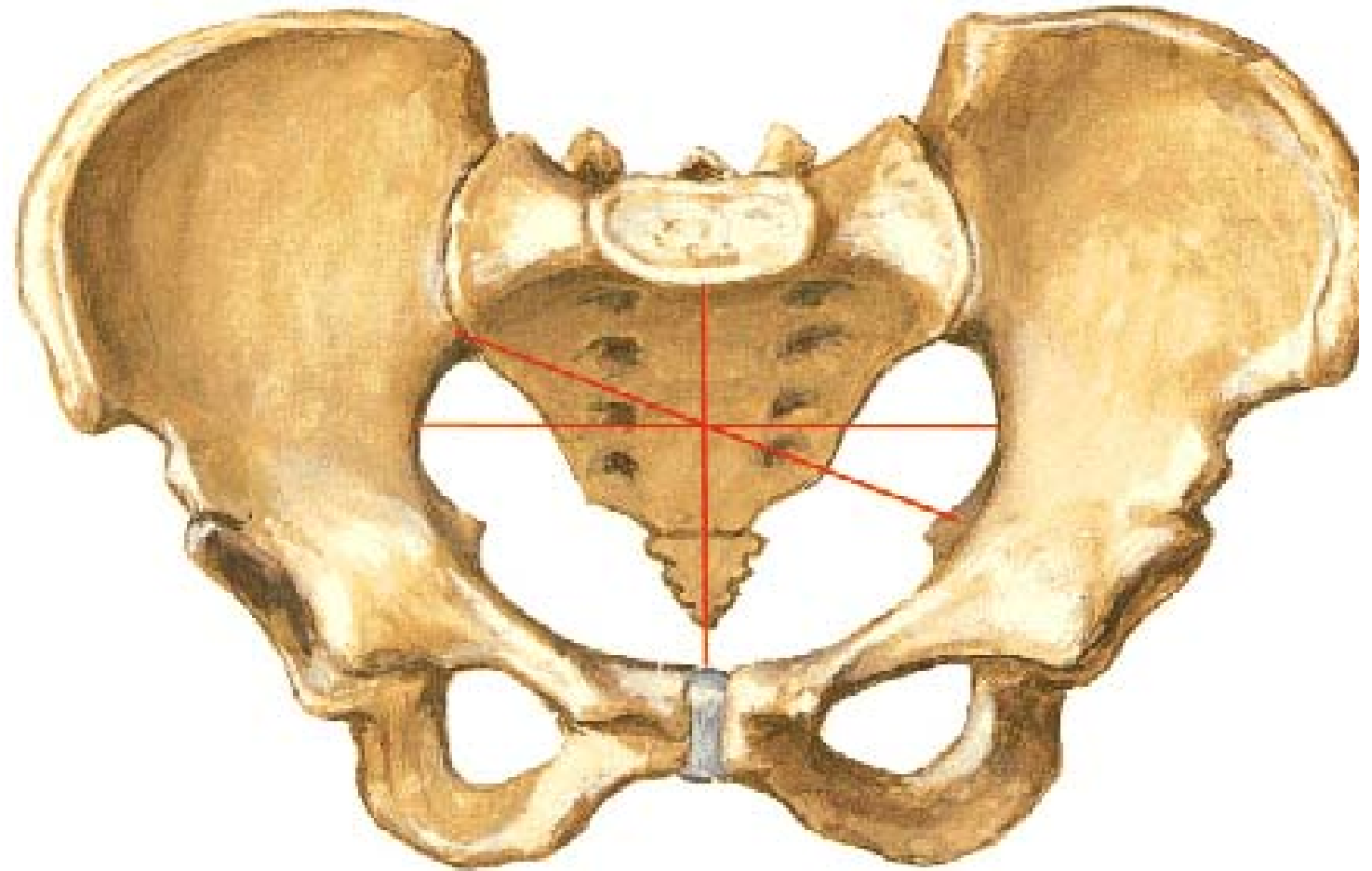
Pelvic Contents of Female
Superior View



Pelvic Contents of Male
Superior View



Pelvis



- Bones
- Ligaments
- Muscles

Bony Pelvis

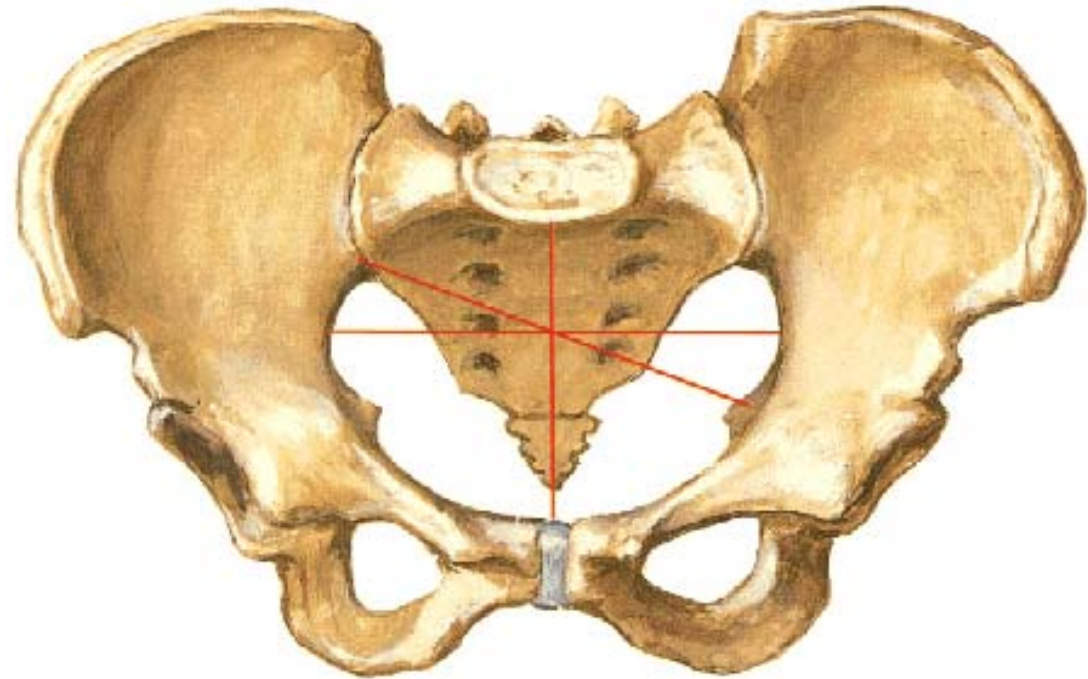
Components

4 bones

- 2 hip bone
- 1 sacrum
- 1 coccyx

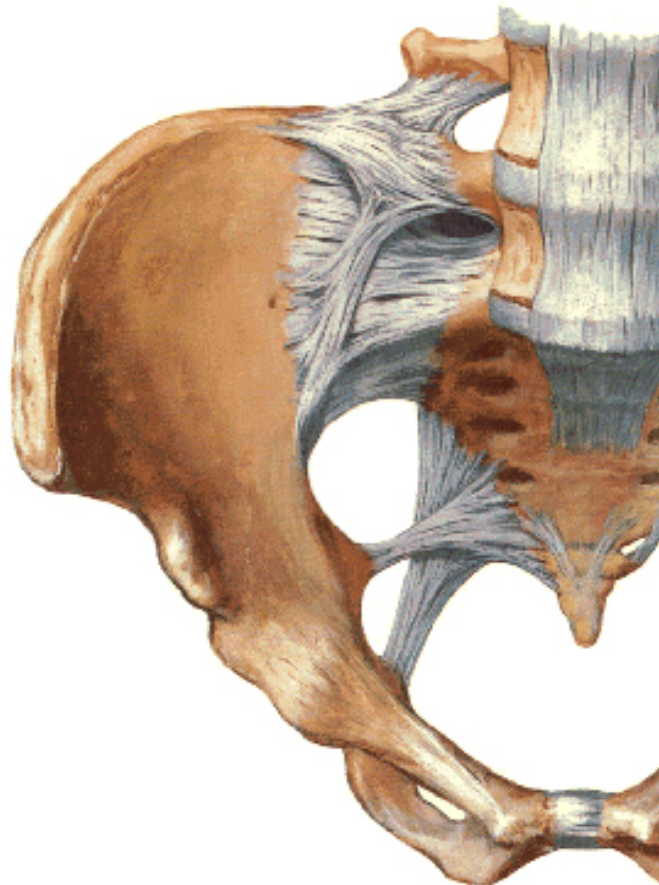
4 joints

- 2 sacro-iliac (Plane Synovial)
- Symphysis pubis (Sec. Cart.)
- Sacro-coccygeal (Sec. Cart.)

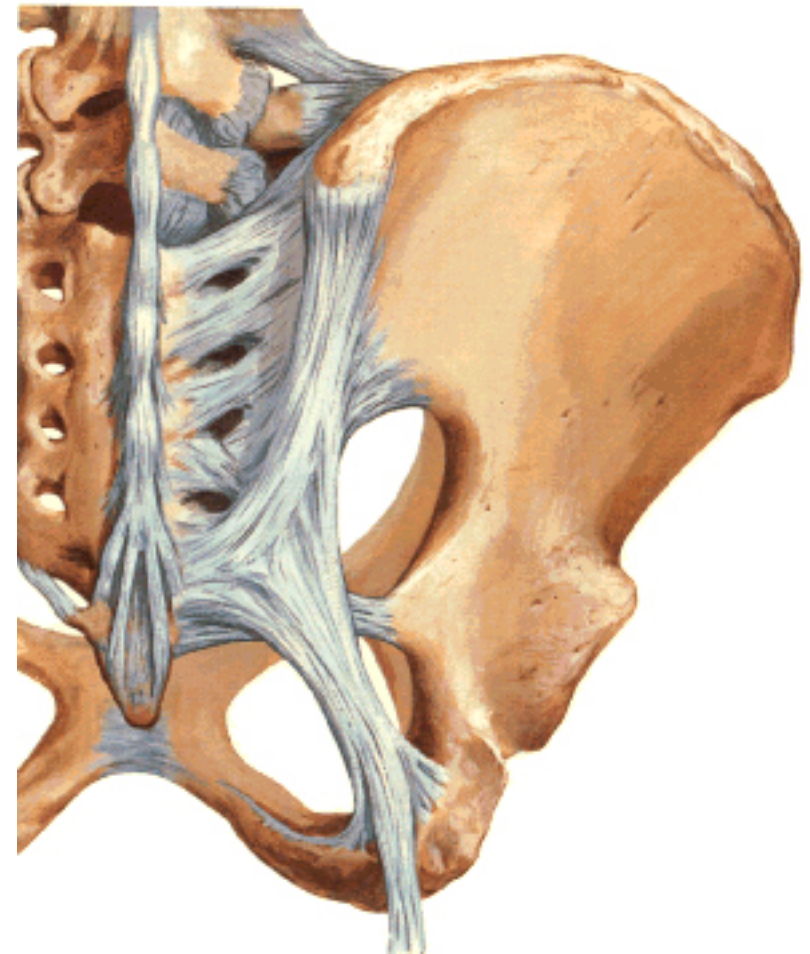


Walls of Pelvis

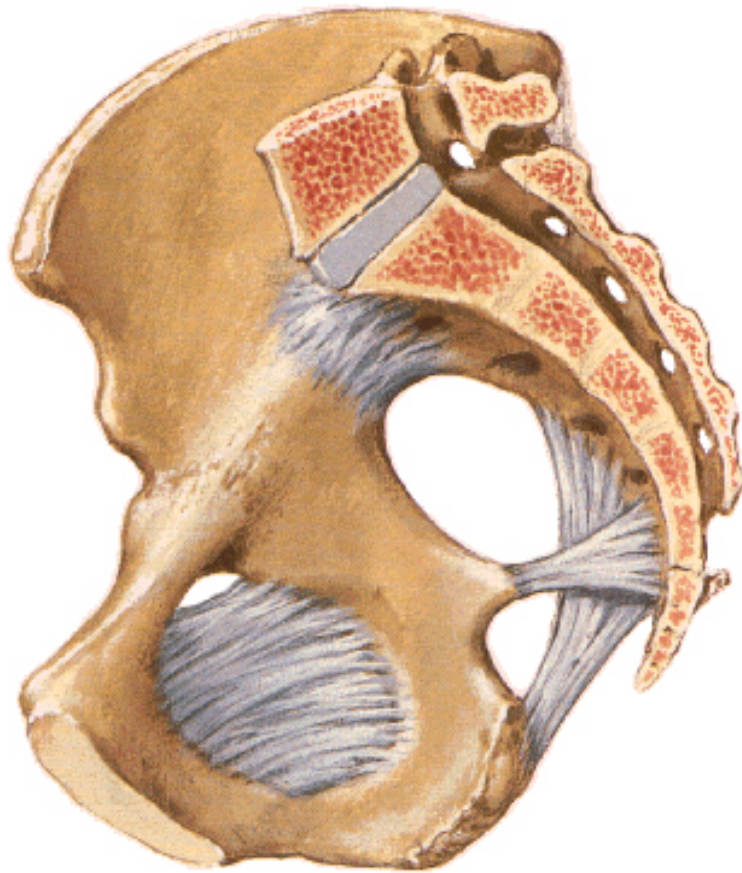Bones and Ligaments of Pelvis
Anterior View



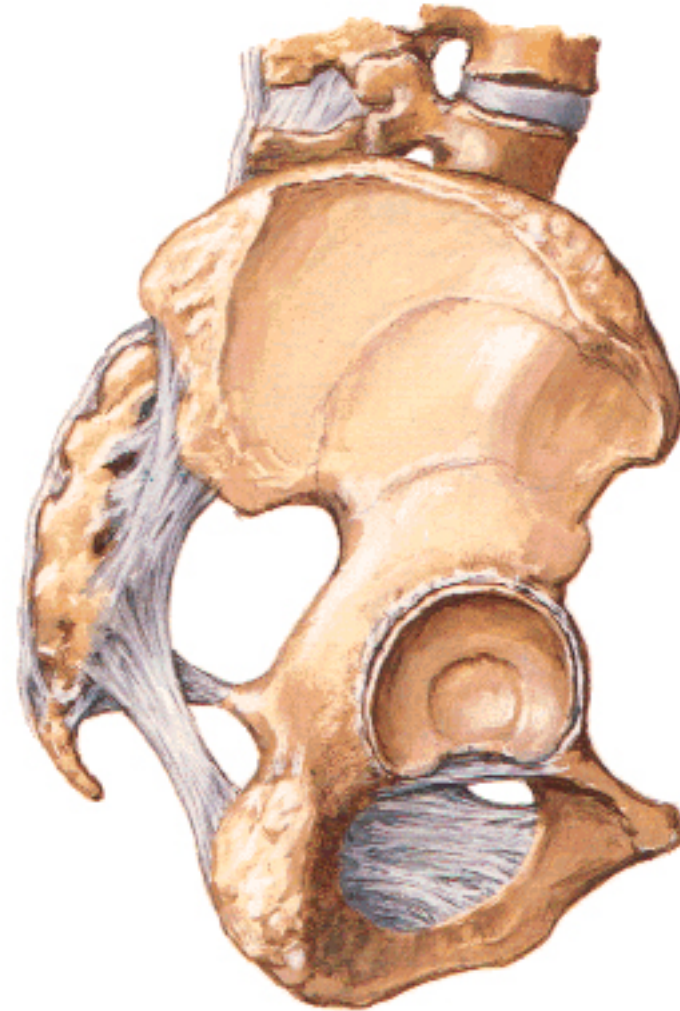Bones and Ligaments of Pelvis
Posterior View



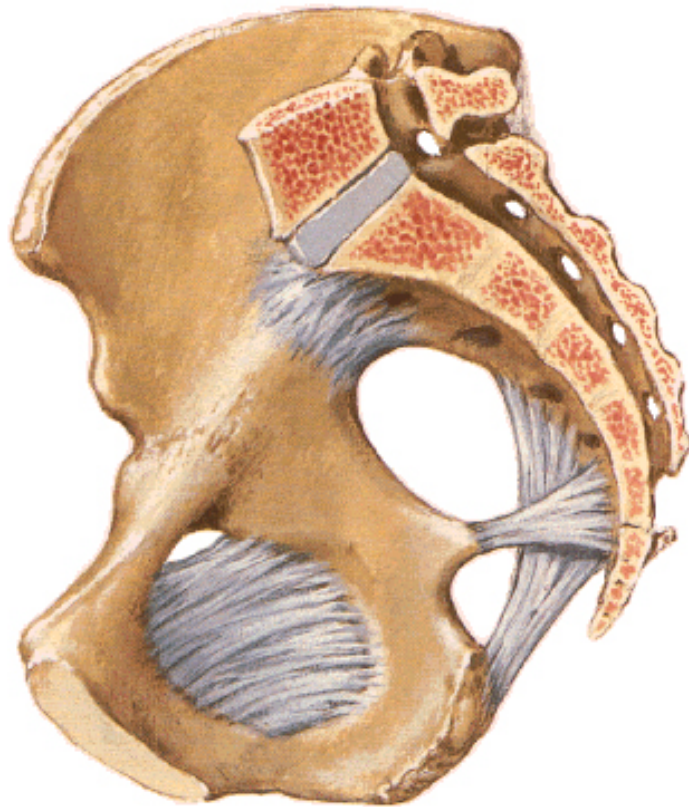Bones and Ligaments of Pelvis
Midsagittal Section



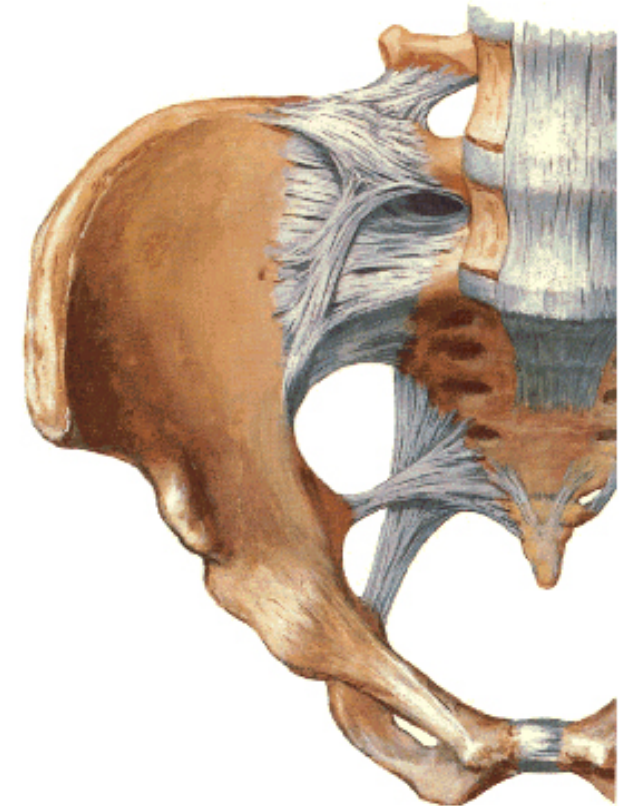
Bones and Ligaments of Pelvis
Lateral View



Bones and Ligaments of Pelvis
Midsagittal Section



Bones and Ligaments of Pelvis
Anterior View



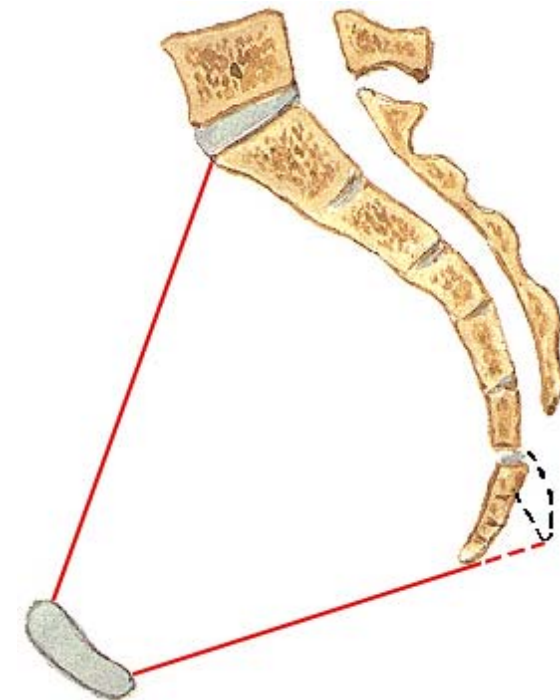
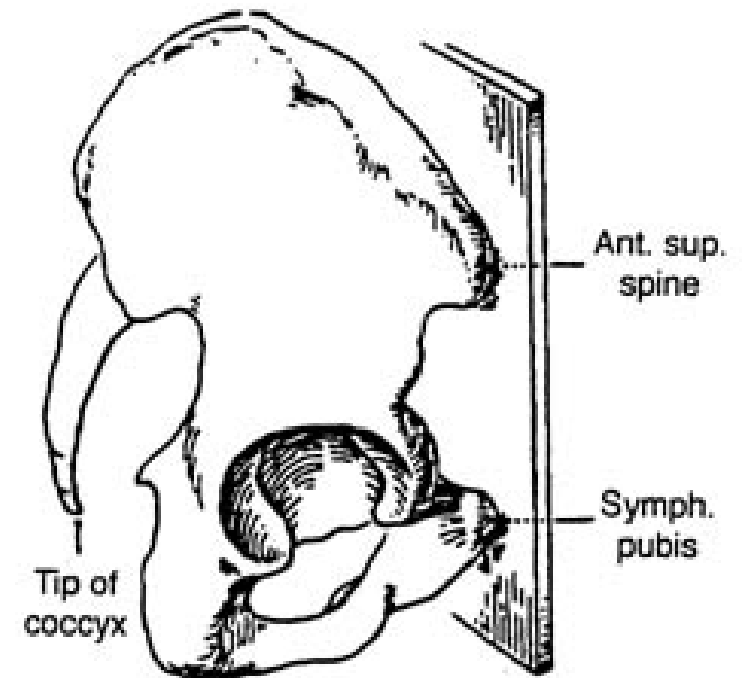
Gateway of Pelvis

4 gateways – besides pelvic outlet

1. Below Inguinal Ligament
2. Obturator foramen
3. Greater sciatic Foramen
4. Lesser sciatic foramen

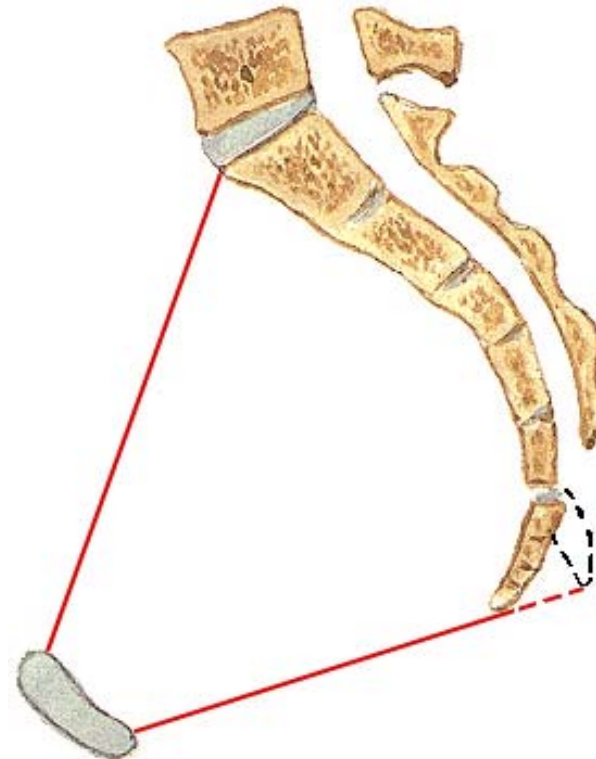
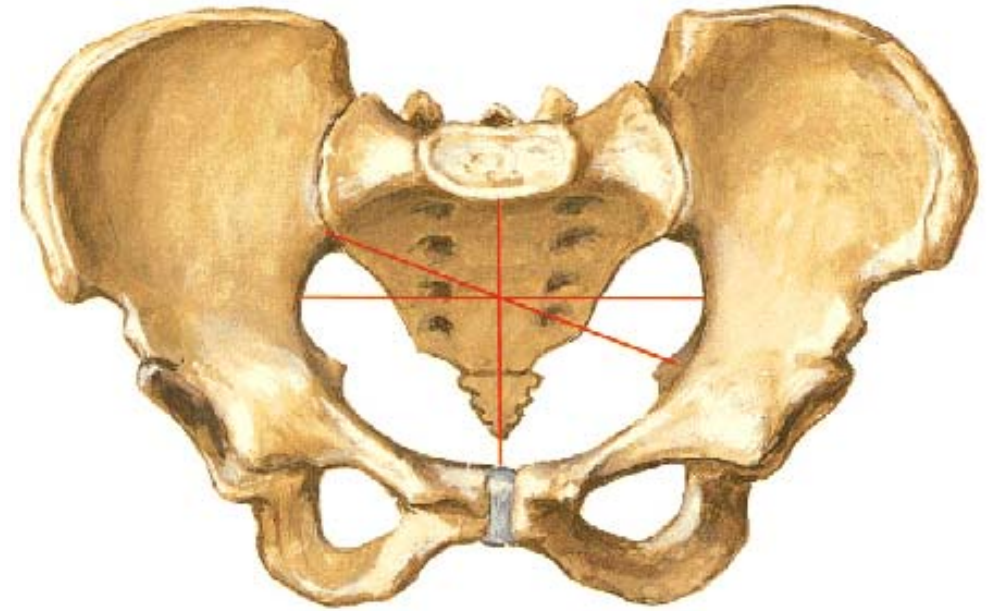
Anatomical Position

- Both **ASIS** & upper end of **symphysis pubis** should lie in same coronal plane
- Pelvic surface of **body of pubis** directed more upward than backward
- **Sacral canal** facing upward



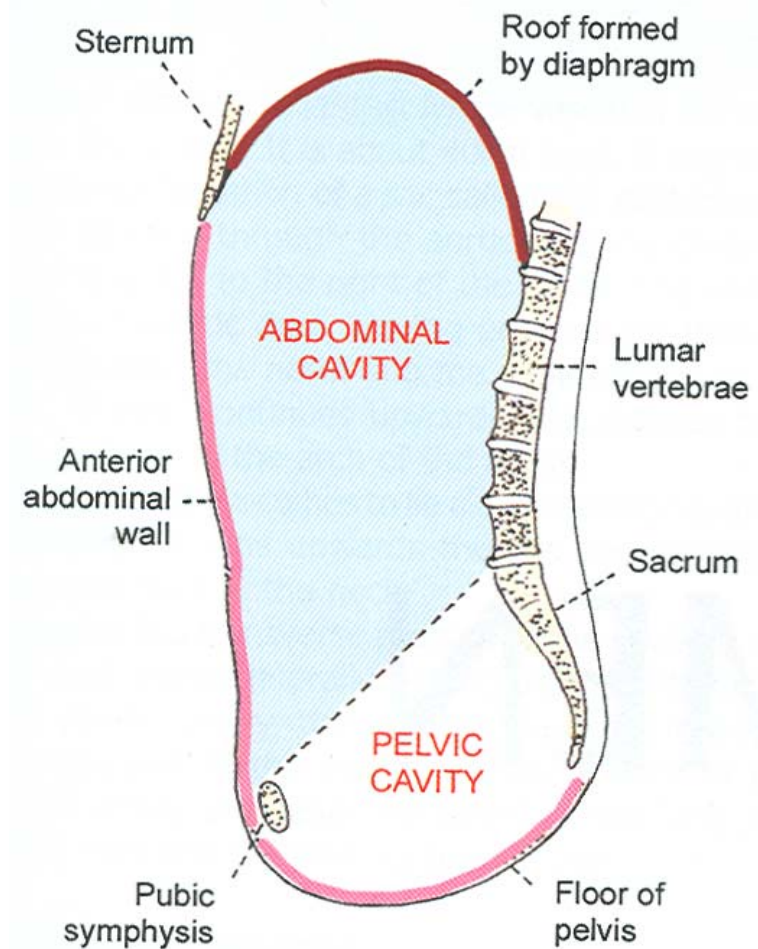
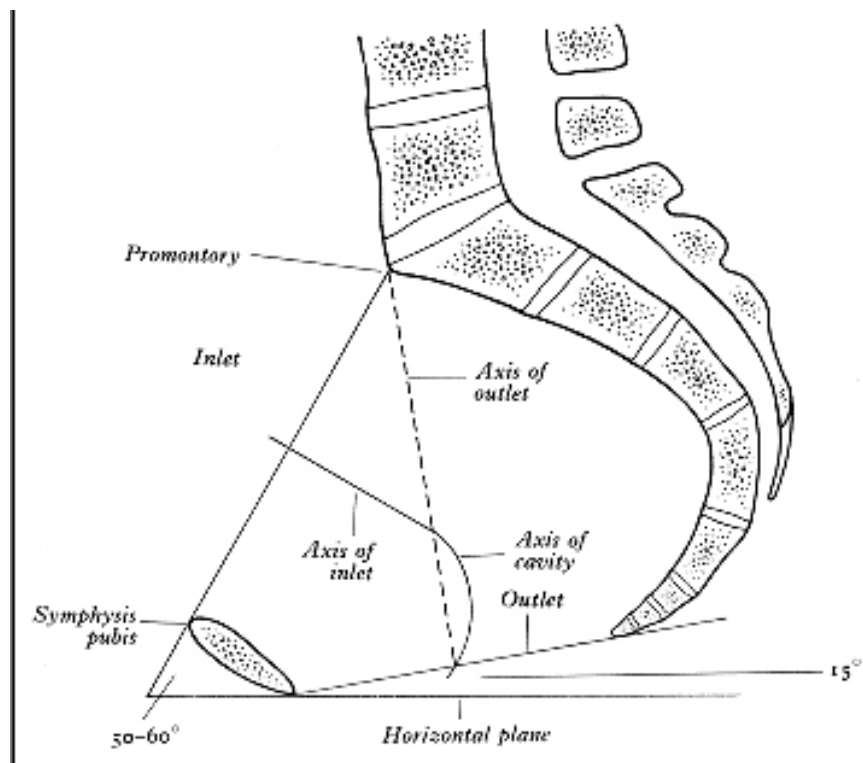
Anatomical Position

- Tip of coccyx should correspond with upper margin of symphysis pubis
- Pelvic surface of sacro-coccygeal curve faces more downward than backward



Anatomical Position

- Angle of pelvic inlet – 50 – 60° with horizontal
- Angle of pelvic outlet – 15° with horizontal



Pelvic inlet

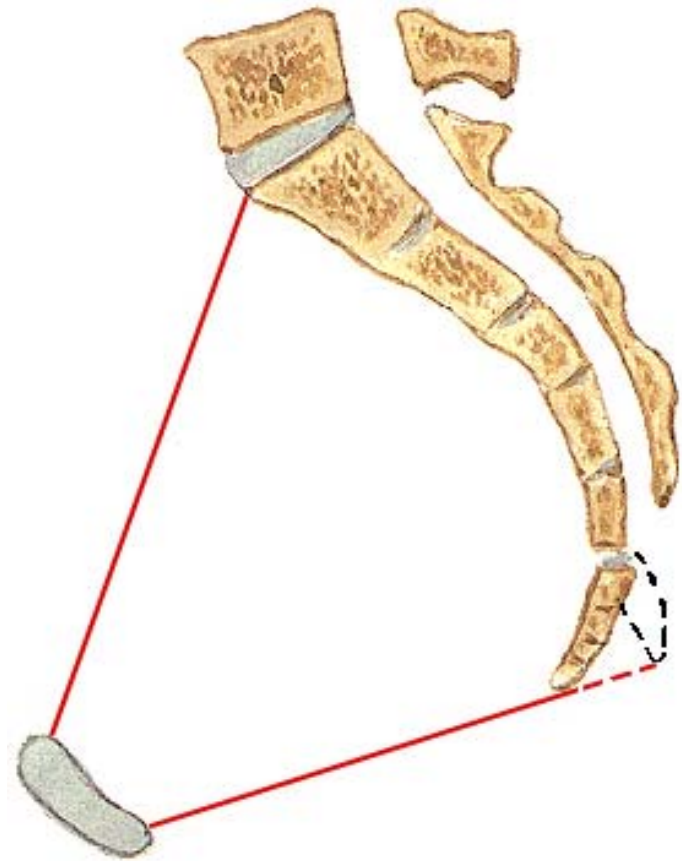
Plane of pelvic inlet

Pelvic Brim

Superior pelvic Aperture

Slopes obliquely
downward & forward

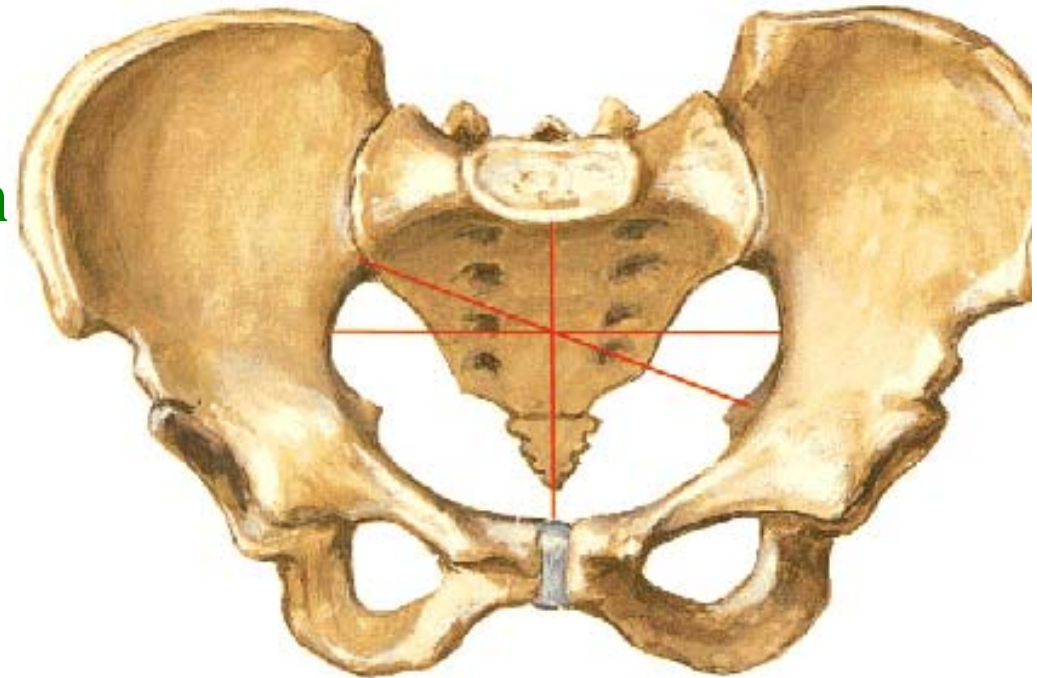
- Sacral promontory
- upper margin of symphysis pubis



Pelvic Brim

Components

- Sacral Promontory
- Ala of Sacrum(ant. Margin
- Lineae terminalis
 - Arcuate line(ilium)
 - Iliopubic eminence
 - Pecten pubis
 - Pubic crest

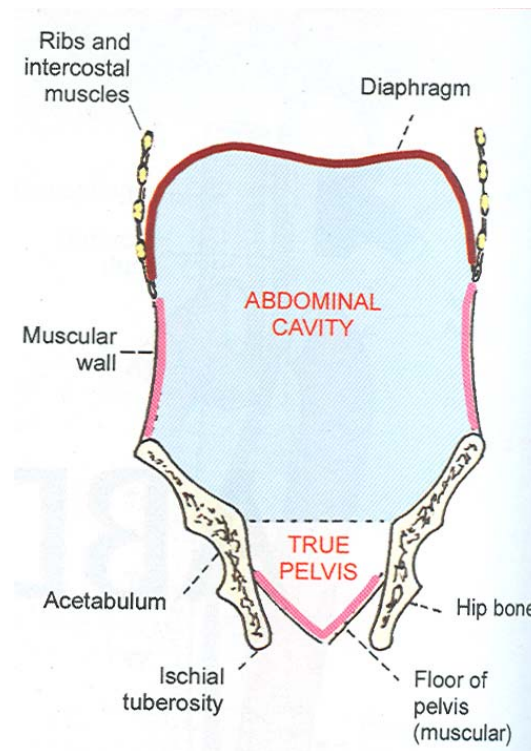
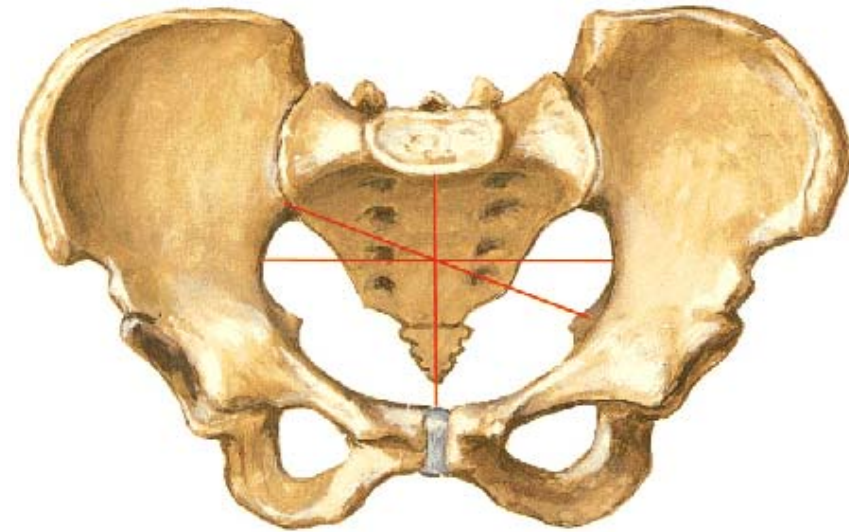


Bony Pelvis

Superior pelvic aperture

Divides into

- Upper wider greater part (false pelvis)
- Lower narrower part (Lesser or true pelvis)



Greater Pelvis

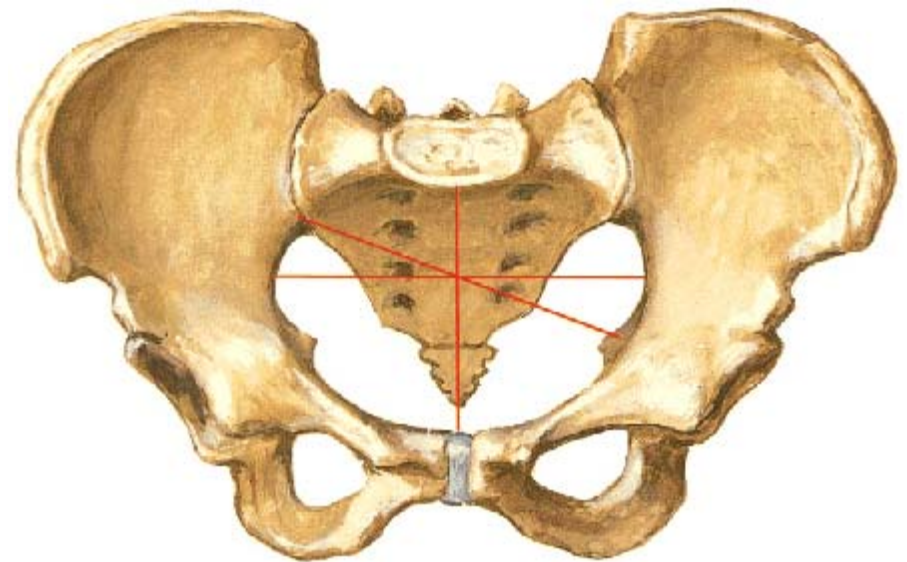
- Upper wider part (**false pelvis**)
- Lie above & in front of pelvic inlet
- No bony walls anteriorly
- (belong to abdomen proper)

Contribution

- ❖ Iliac fossa of hip bone
- ❖ Ala of sacrum

In females

- Iliac blades are more vertical
- Ant. Sup iliac spine are projected outward



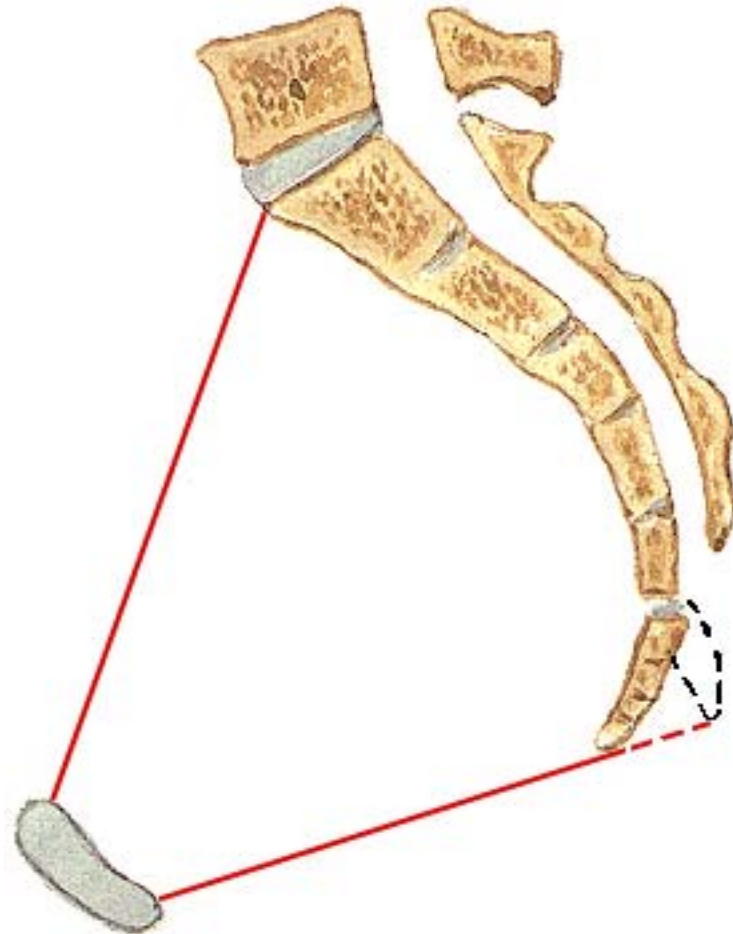
Lesser or true Pelvis

Features

- Pelvic Inlet
- Pelvic Cavity
- Pelvic Outlet

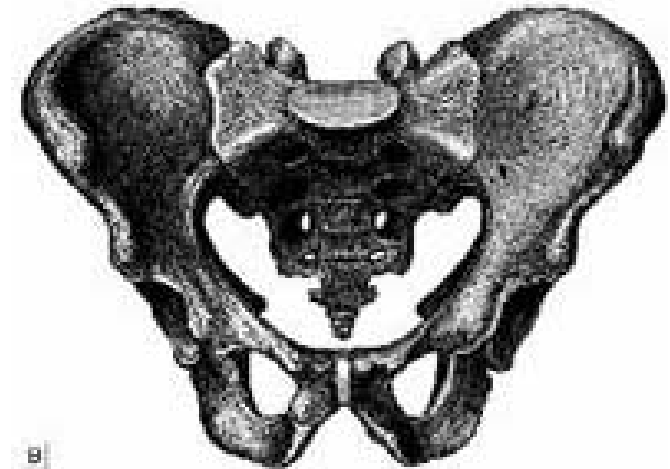
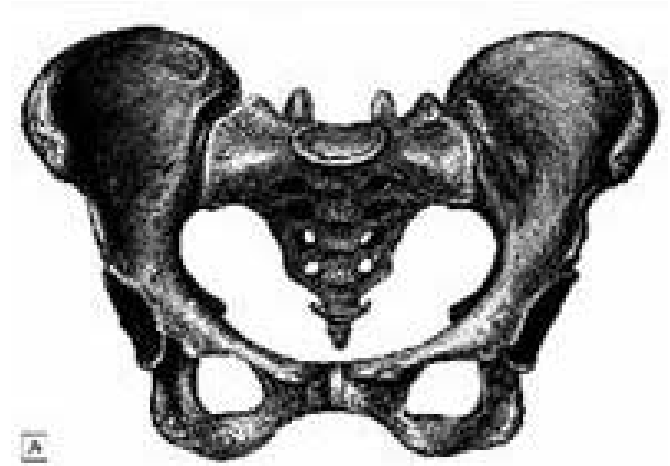
Each can be measured by three dimensions

- Antero - posterior
- Transverse diameter
- Oblique diameter



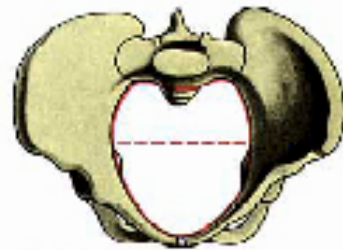
Shape - Inlet

- Heart shaped in males (widest towards back)
- Transversely oval in females
- At birth pelvis of both sexes is ovoid

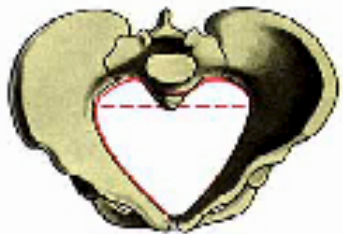
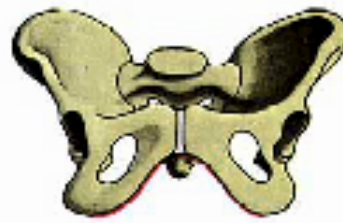
Classification of Pelvis

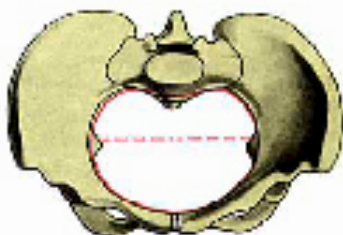
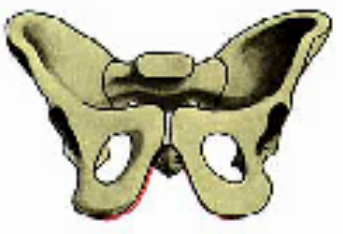- Acc. to shape of inlet –conventional method used by **Obstetrician**
- Acc. To measurements of inlet – method used by **Anthropologists**



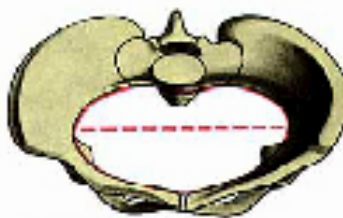
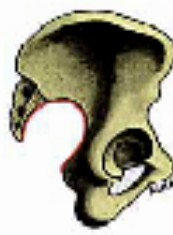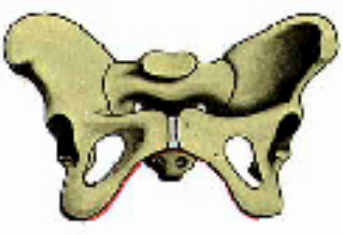
A Anthropoid.



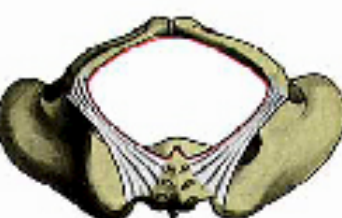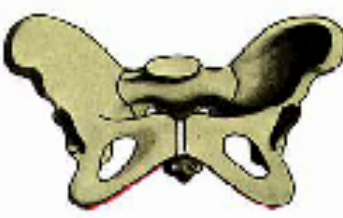B Android.



C Gynaeoid.



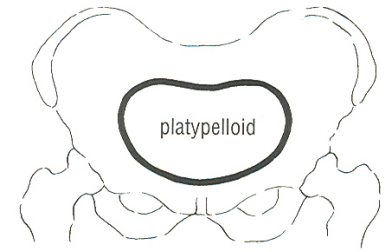
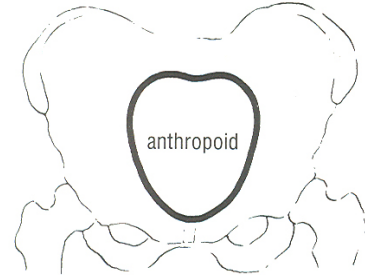
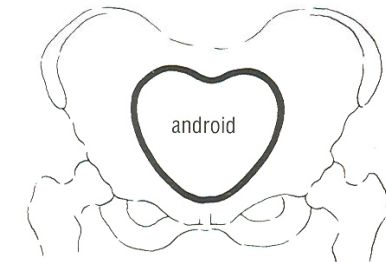
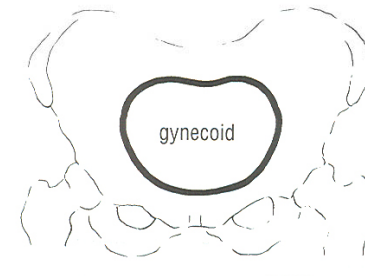
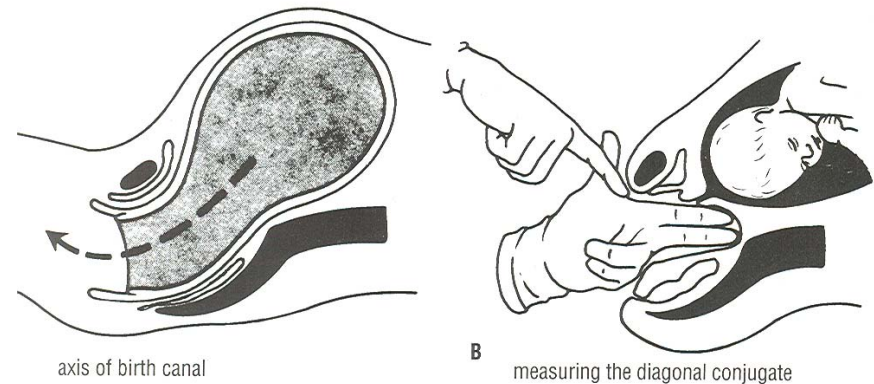
D Pyrbelloid.



Classification of Pelvis

Acc. to shape

- **Gynaecoid** - Rounded shape, Tr dia widest
- **Android** – heart shaped , inlet more wide in Post. segment
- **Anthropoid** – Oval , AP dia. More than Tr. Dia
- **Platypaloid** – Flat pelvis , Tr. Dia disproportionately wider than AP dia.



- Anthropoid & Android common in **males**
- Android & Gynaecoid common in **females**
- Platypelloid - **rare**

Classification of Pelvis

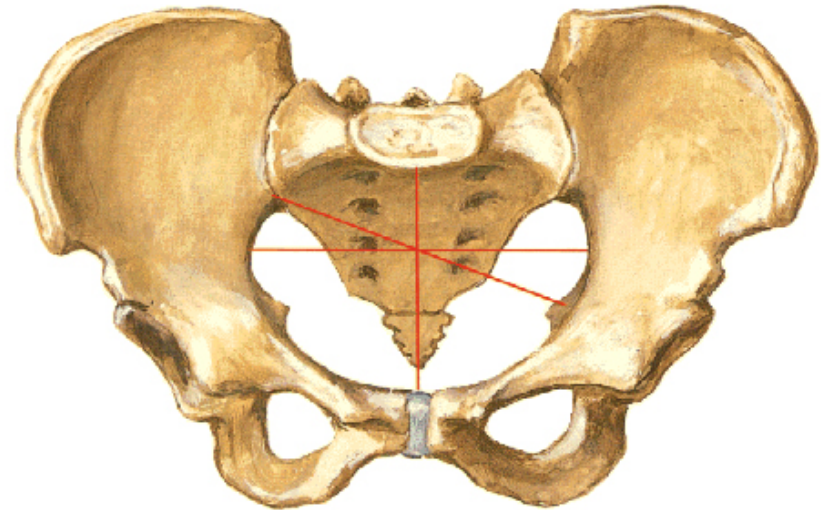
Anteropost. Dia / Tr. Dia. X 100

- Pletypellic (transversely flat) - pletypelloid
- Mesatipellic (intermediate) -Gynaecoid
- Dolichopellic (antero-posteriorly long) –Anthropoid
- Brachypellic –Android

Pelvic inlet

- Antero-post. Diameter
(Anatomical conjugate)
- Middle of sacral
promontary – upper
margin of symphysis pubis
- Males- 10 cm
- Females – 10.5 – 11 cms

Female Pelvis
Measurements - Anterior View

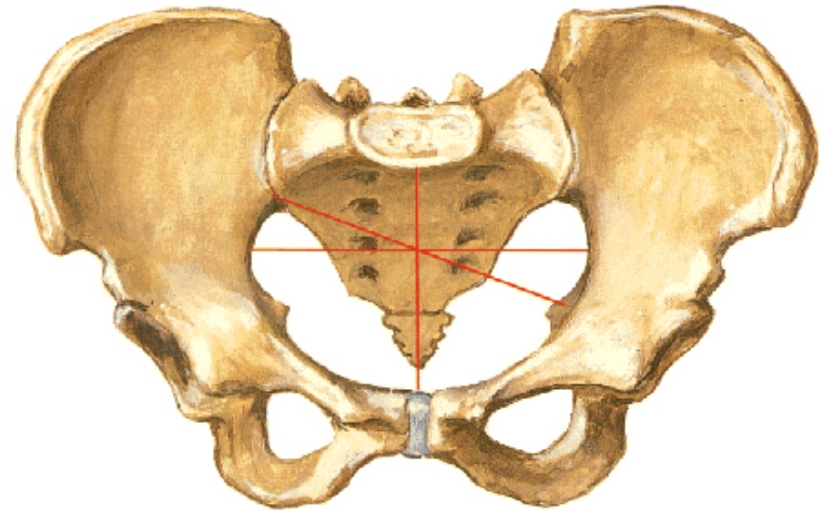


Pelvic inlet

Transverse diameter

- Widest measurement across inlet
- Males – 12.5 cms
- Females – 13 cms

Female Pelvis
Measurements - Anterior View

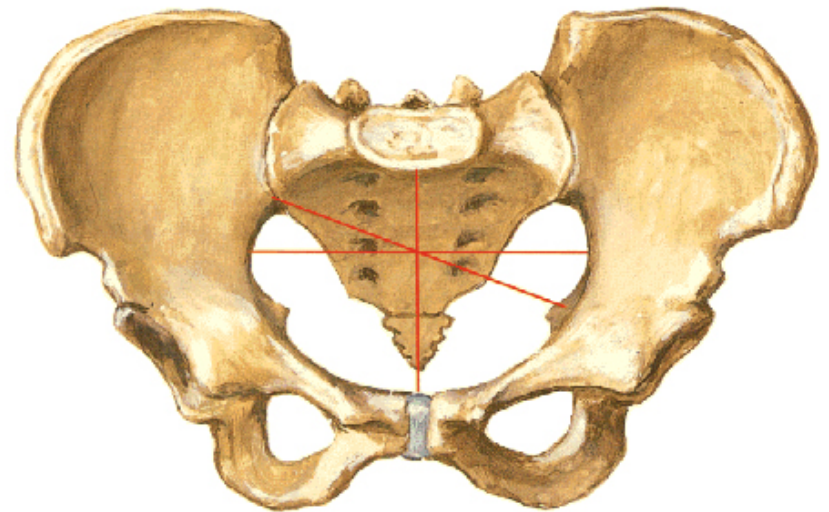


Pelvic inlet

Oblique diameter

- Sacro-iliac joint of one side to ilio-pubic eminence of other
- **Males** –11 cms
- **Females** –12.5 cms

Female Pelvis
Measurements - Anterior View



- True Conjugate
- Obstetrical conjugate
- Diagonal conjugate
- External conjugate

Pelvic cavity Dimensions

- **Antero-post.**- middle of back of symphysis pubis – centre of pelvic surface of S3
- Female – **13 cms**
- **Oblique diameter**- lower end of sacro-iliac joint to centre of obturator membrane – **13.1 cms**
- **Transverse diameter** – widest transverse distance – **12.5 cms**

Pelvic outlet

- Inferior pelvic aperture
- Diamond shaped

Boundaries

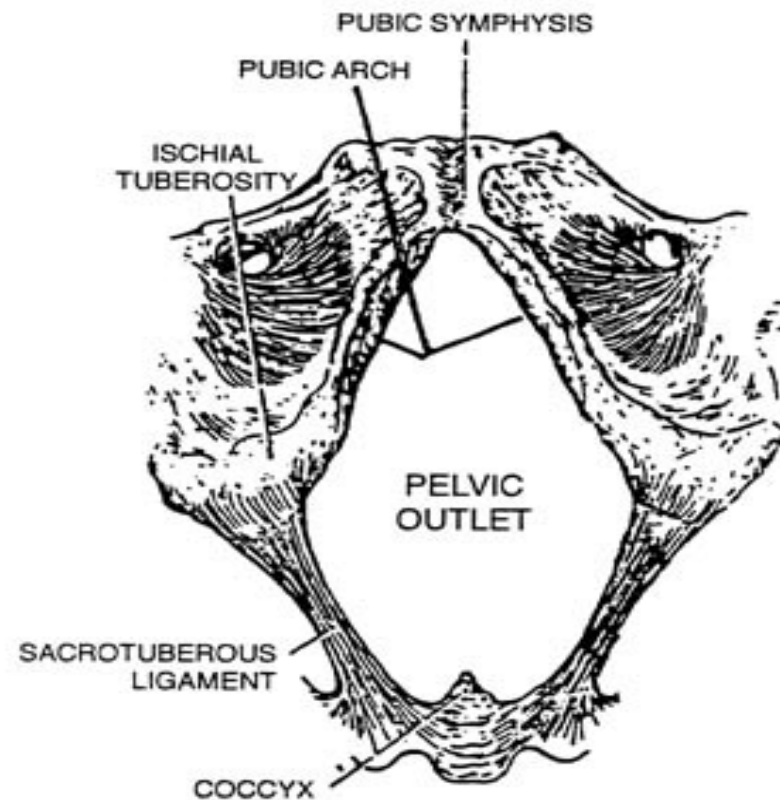
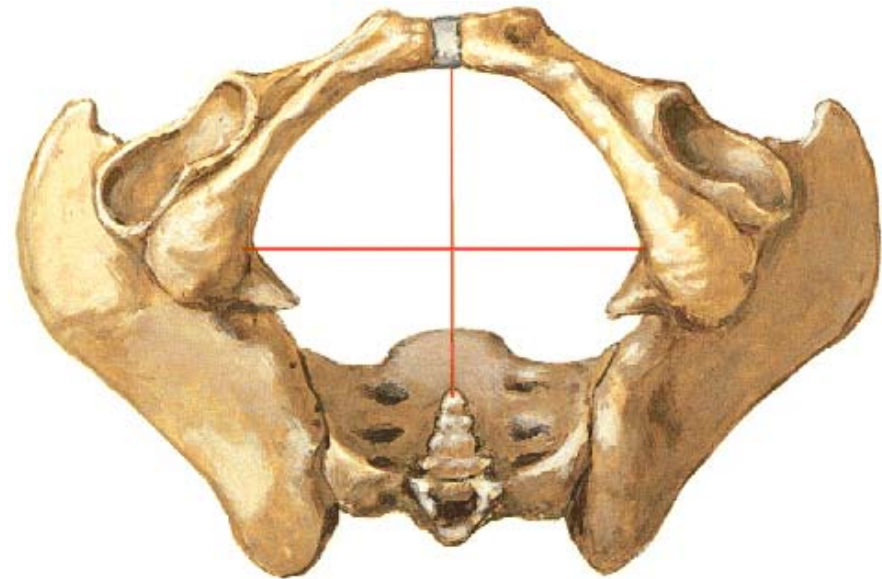
Front- lower margin of symphysis pubis

Behind – tip of coccyx

Antero-laterally- conjoint ischio-pubic rami

Laterally – ischial tuberosities

Postero- laterally – sacrotuberous ligament

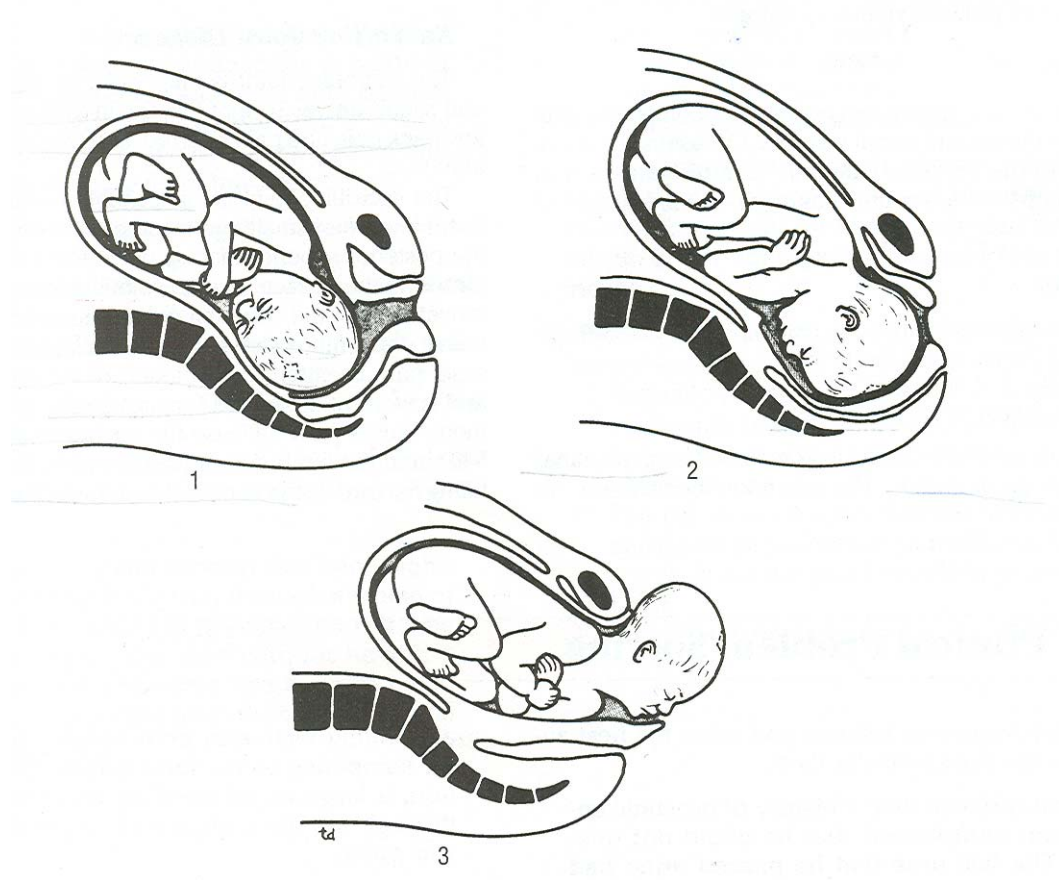


Pelvic outlet dimensions

- AP – lower border of symphysis pubis – tip of coccyx
- Male- 8 cms
- Females – 12.5 cms
- Oblique dia.- junction of ischio-pubic ramus of one side to middle of sacro-tuberous ligament
- Males – 10 cms
- Females – 11.8 cms
- Transverse Dia. – distance b/w medial surface of two ends of ischial tuberosities
- Males – 8.5 cms
- Female – 11.8 cms

Female Pelvis

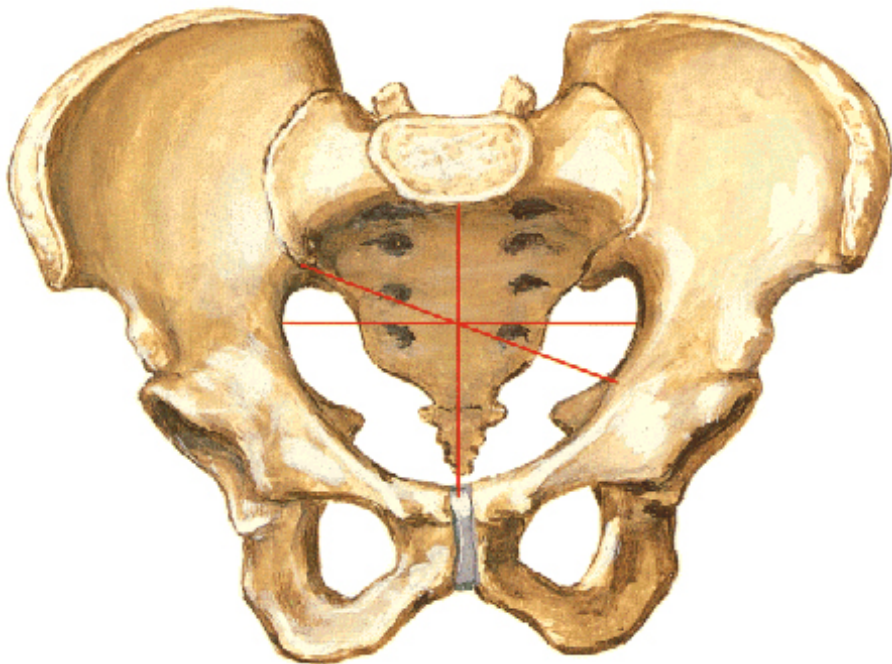
- Wider , Shorter , Shallower
- For accommodation of foetal head & parturation
- Tr. Dia of inlet , Oblique dia of cavity & Ap dia of outlet are maximum



Sexual Difference

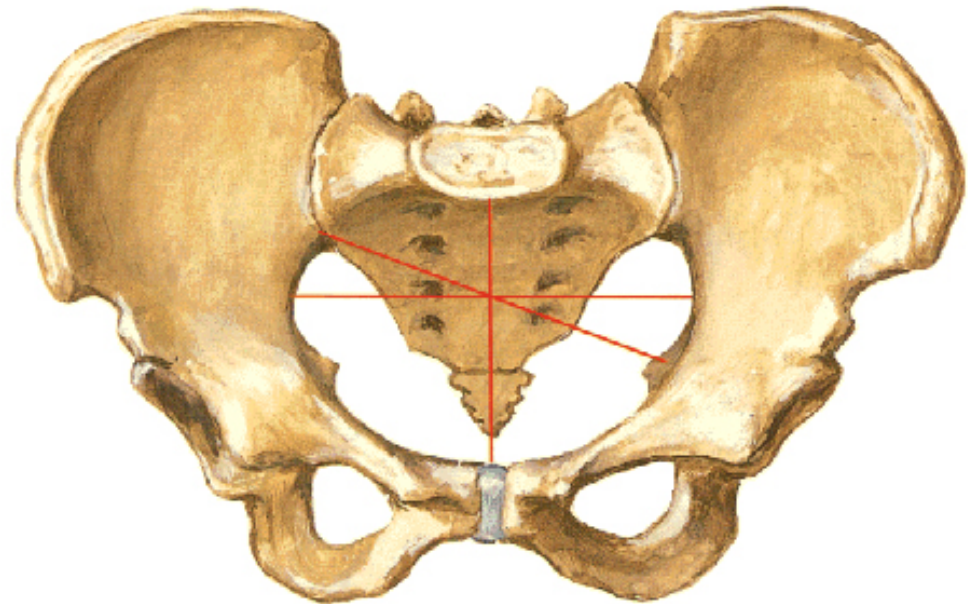
Male Pelvis

Measurements - Anterior View

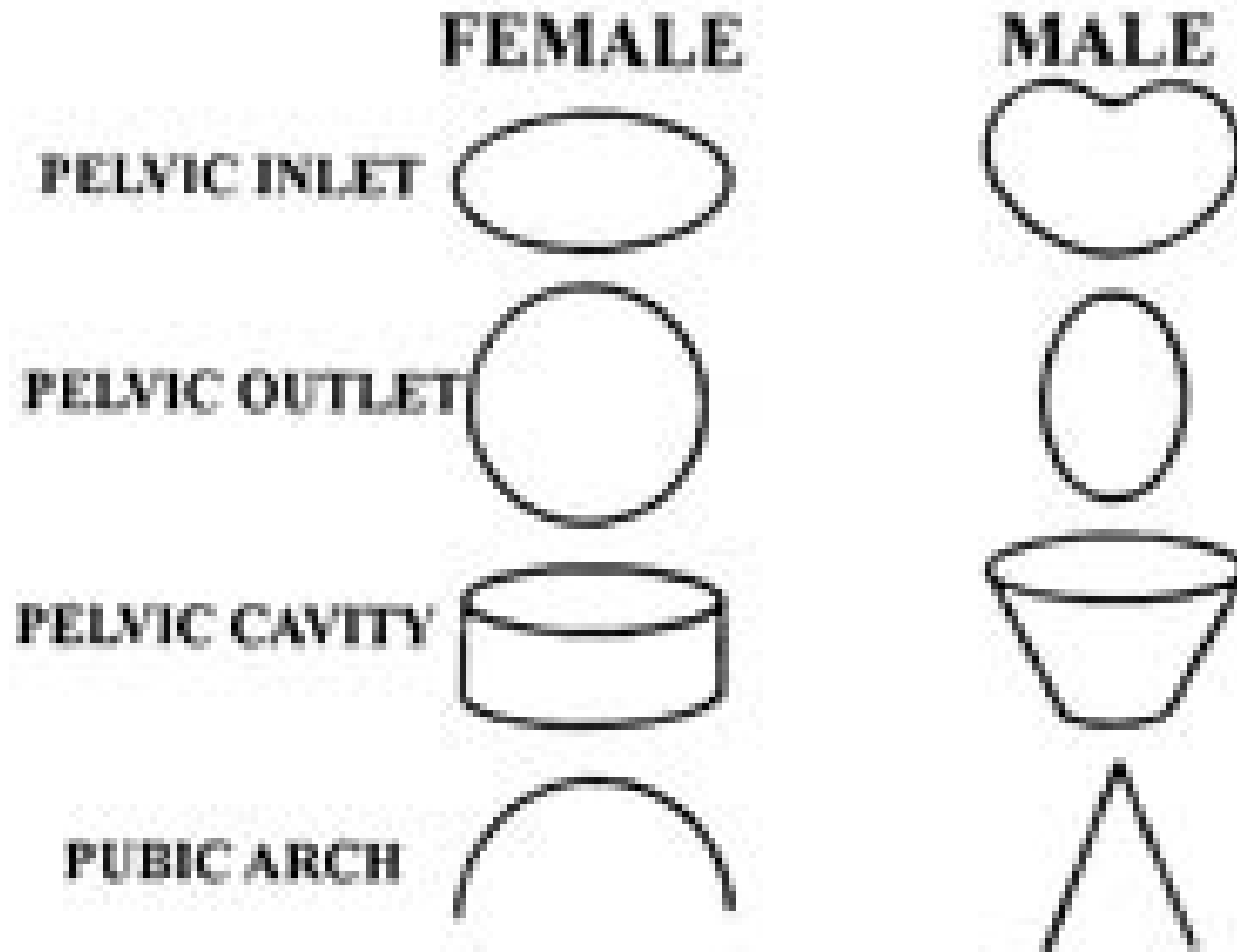


Female Pelvis

Measurements - Anterior View

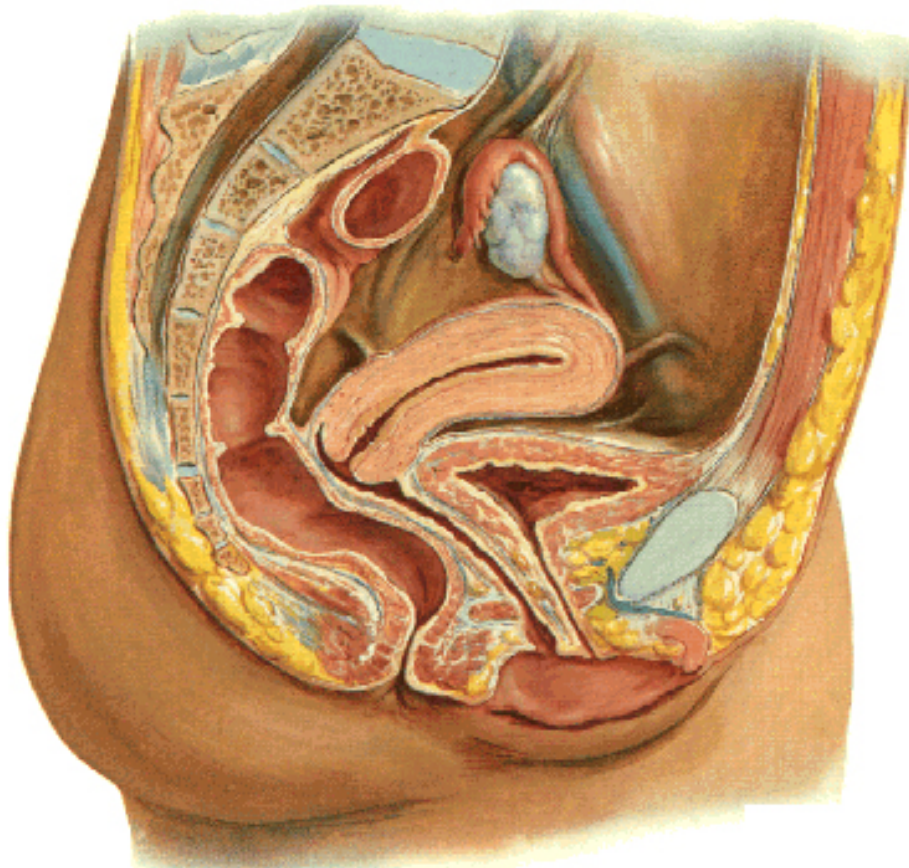


Sexual Differences

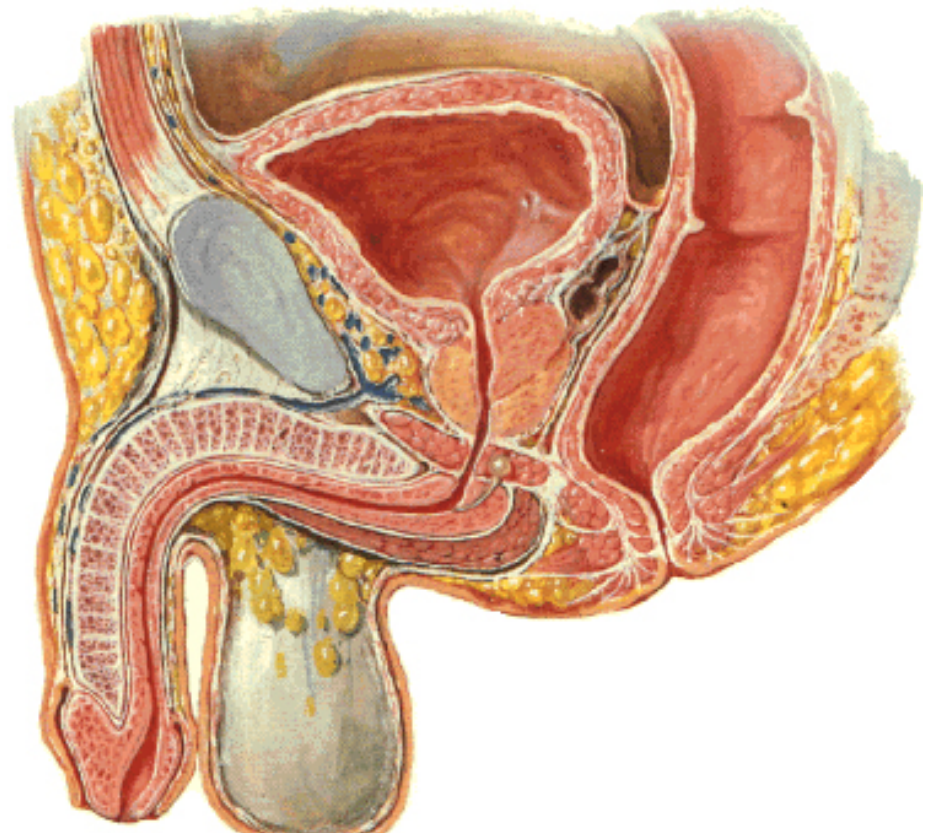


Contents of Pelvic Cavity

Pelvic Viscera and Perineum of Female
Midsagittal Section



Pelvic Viscera and Perineum of Male
Midsagittal Section



Axis of pelvic Cavity

