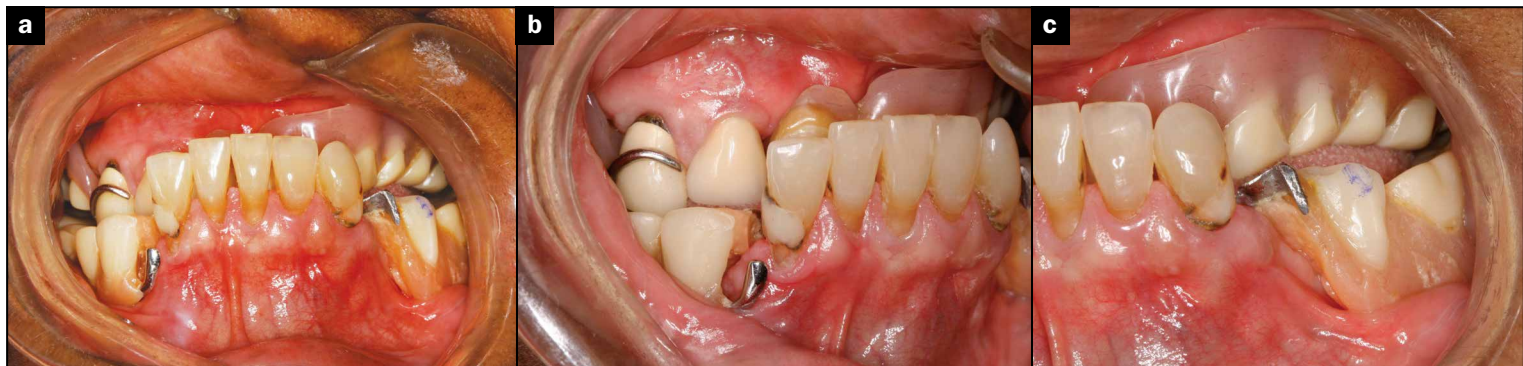

# Rehabilitation of Mandibular Atrophy

## *The Case of the Prolonged Partial*



Richard B.  
Winter, DDS



**Figure 1a.** Retracted preoperative photo, showing the decimated and ill-fitting partials.

**Figure 1b.** Right lateral retracted view, showing ill-fitting clasps.

**Figure 1c.** Left lateral view, showing broken clasps and loss of posterior occlusal support.

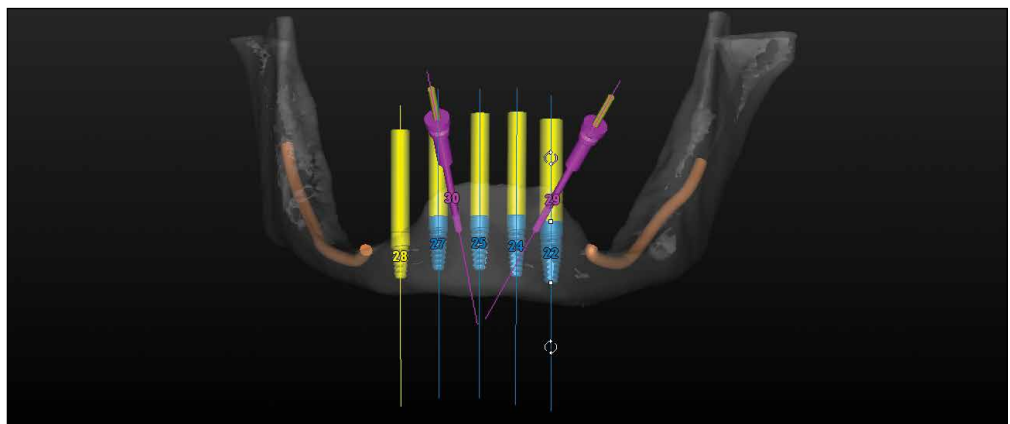
### “EGADS, WATSON, A MYSTERY IS AFOOT—OR SHOULD I SAY, AMOUTH?”

It is certainly not surprising that patients who wear prostheses often suffer as a direct result of these prostheses if they are not carefully monitored and maintained. Traditional dentistry and insurance constraints often perpetuate occlusal destruction by failing to address the long-term sequelae of removable prostheses. The foundations upon which our dentures and partial dentures rest will deteriorate from abrasion, erosion, caries, periodontal disease, and super eruption.<sup>1</sup>

When we treatment plan complex dental problems, discussion should include options for rehabilitative dentistry and not just conformative dentistry. Rehabilitative dentistry refers to preemptive bone and occlusal construct improvement, replacement of lost bone, tooth structure, and support while addressing force factors unique to that patient's needs.

Conformative dentistry refers to the placement of a prosthetic device, or the replacement of a prosthesis with yet another one, *without regard* for the destruction, super-eruption, or deterioration, which has occurred to the teeth/underlying bone caused by the previous prosthesis.<sup>2</sup>

Even if a patient can not afford ideal treatment, the dynamic treatment plan should engage the patient in the decision-making process so that interim steps may preserve bone and treatment options before the cost and time of rehabilitation may escape a patient's means.<sup>3</sup>



**Figure 2.** Implants planned in the A to E positions with the denture masque hidden.

*When we treatment plan complex dental problems, discussion should include rehabilitative dentistry and not just conformative dentistry.*

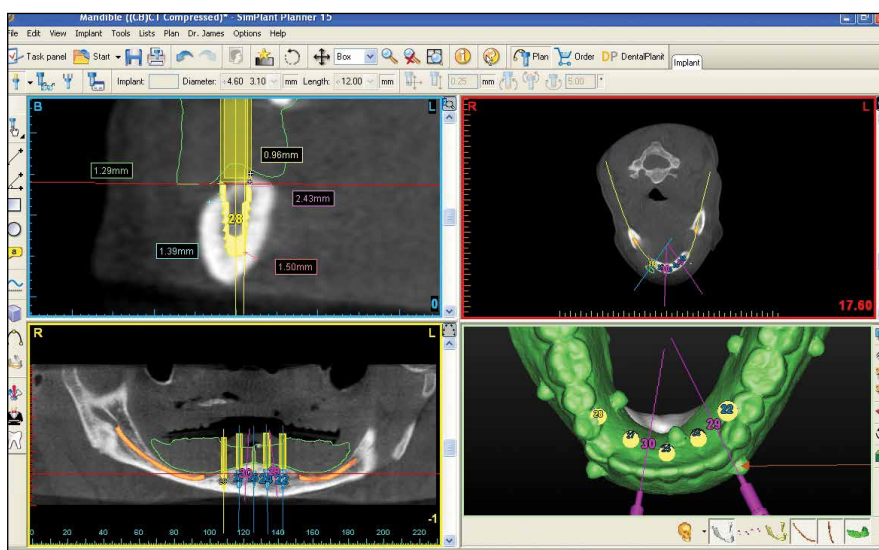
### TWO SHIPS THAT PASS IN THE NIGHT: MAXILLO-MANDIBULAR RELATIONSHIPS

In this case study, the patient had been suffering with chronic oral pain for years. She had faithfully worn her upper partial denture and lower partial denture and had been experiencing pain upon chewing. Not only did she have masticatory pain but also nerve pain associated with dehiscence of the mental nerve and pressure from her ill-fitting partials. A comprehensive examination was performed, which included study models mounted at her over-closed Class III acquired centric occlusion position with, and without, her

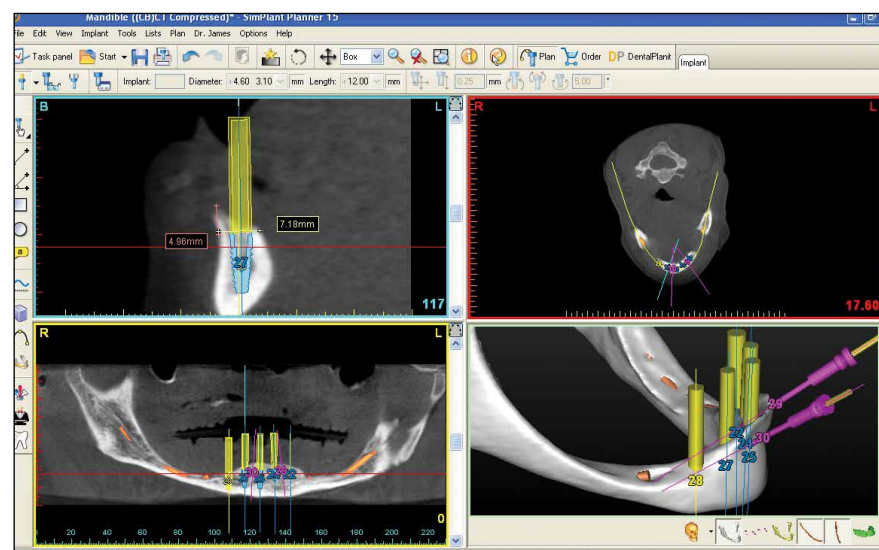
partials. Panorex and periapical radiographs were taken, along with a CBCT scan, to begin examining implant options to restore her maxilla and mandible. Her partial dentures were ill fitting and the teeth were worn out and without stable occlusal contacts. To complicate things further, she had broken clasps and severe super-eruption of the mandibular anterior teeth from combination syndrome (Figure 1).

The term *combination syndrome* (as first described by Ellsworth Kelly) is a condition that involves severe maxillary anterior

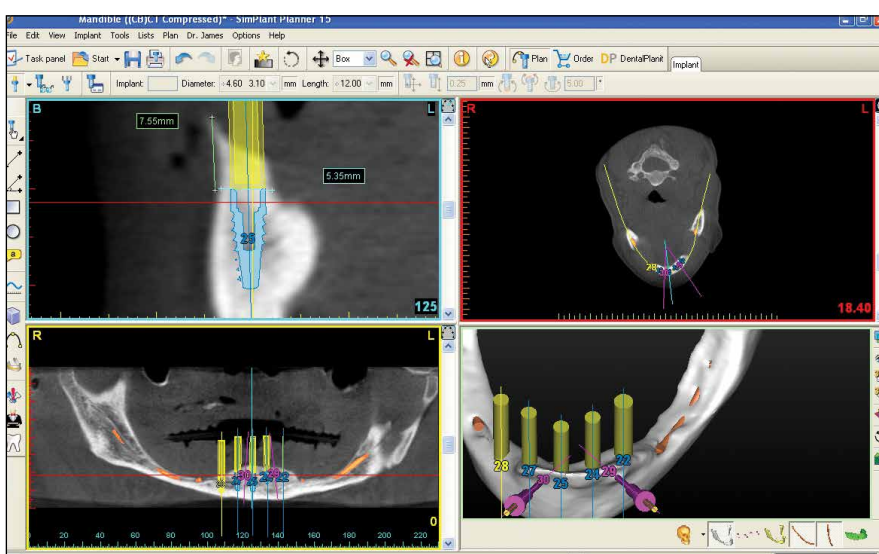
*continued on page 138*



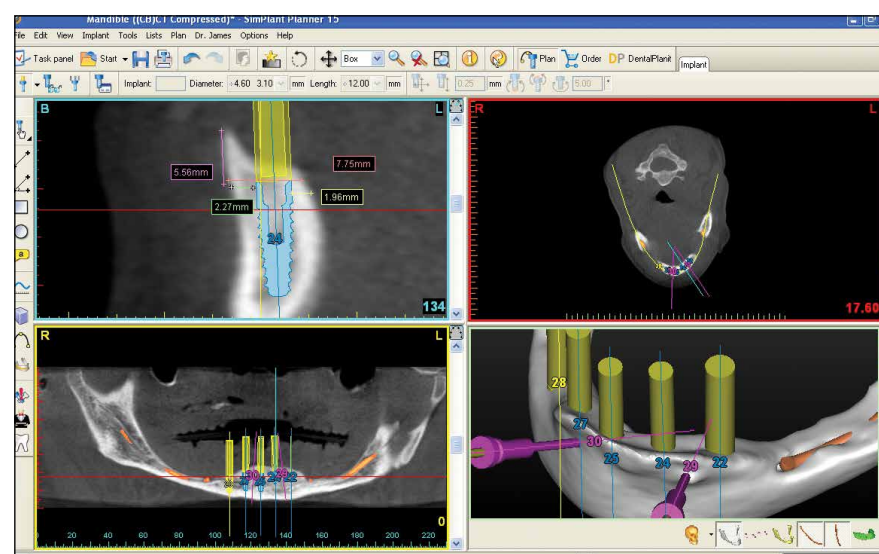
**Figure 3.** Implant No. 28 and all implants in DENTSPY/SIMPLANT software planning (DENTSPY Implants).



**Figure 4.** Implant No. 27 with relationship to nerve and lip of bone.



**Figure 5.** Implant No. 25 with amount of osteoplasty noted.



**Figure 6.** Implant No. 24 and dimensions required for implant placement.

### Rehabilitation of Mandibular Atrophy...

continued from page 136

wear under an upper complete denture opposing lower anterior teeth. The severe maxillary atrophy and the resultant super-eruption of remaining mandibular anterior teeth can make prosthetic management extremely challenging.<sup>4,5</sup> This condition often is accompanied by enlarged tuberosities, atrophy in the mandibular posterior quadrants, and tongue enlargement with the development of a Class III maxillo-mandibular relationship. Advanced treatment planning requires treatment of the mandibular super-eruption, arresting bone loss, and restoration of all foundations to affect a long-term stable rehabilitation.

In treating this patient, the lower jaw rehabilitation would be done first with a second phase of treatment to carry out maxillary foundational work and a prosthetic rehabilitation. The treatment plan that was agreed upon first required edentulation, socket preservation, and fabrication of

*Due to our patient's age and budget, the decision was made to do osteoplasty to create a broad enough base for 5 implants....*

dentures at the proper occlusal vertical dimension. The approved denture was then used to place fiduciary markers (barium sulfate balls) so a CBCT scan could be done using a dual-scan protocol to record the edentulous arches as well as the approved dentures. The DICOM images were converted by 3D Diagnostix (3DDX.com) and sent digitally so that implant planning could begin. DENTSPY/SIMPLANT software (DENTSPY Implants) was then used to assess the available bone and to plan the implants in 3-D.

#### WHO STOLE THE BONE? PROFESSOR MORIARTY, I PRESUME?

In classifying ridges according to volume and angle of bone present, Misch et al<sup>6</sup> identified ridge classifications of A to D ridges. A ridge labeled "A" has

sufficient height (> 12 mm) and width (> 6 mm) and angle of bone (< 25°) for implant placement. A "D" ridge has basal bone and cannot be used for placement of endosseous implants without significant onlay grafting or the use of subperiosteals or transosteal implants.

For patients with a "C" ridge, there is zero to 2.5 mm of bone width and < 12 mm of bone height. For these patients, if no treatment has been undertaken, the bone will devolve from a C ridge to a D ridge. This will first involve loss of width (C-W) and then become deficient in height (C-H).

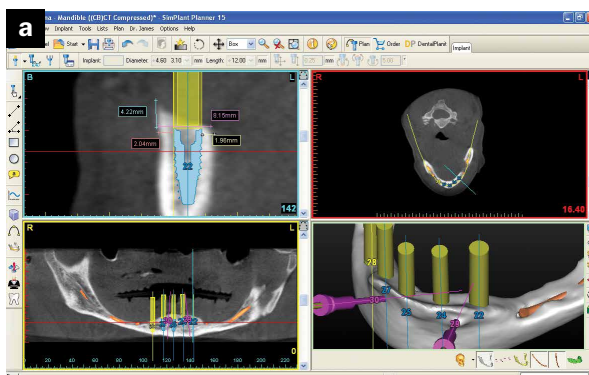
In patients who have C-W and C-H ridges, one option is augmentation where grafting material from the hip, tibia, or symphysis can be used to augment the anterior segment of bone to provide for wider diameter implants. Implants such as subperiosteals or

transosteals have also been used to treat C ridges with success. Additionally, bone morphogenic proteins in the form of biologics have been used off label to build bone volume. The last option for patients with a C ridge is to create a broader base of bone by performing osteoplasty.

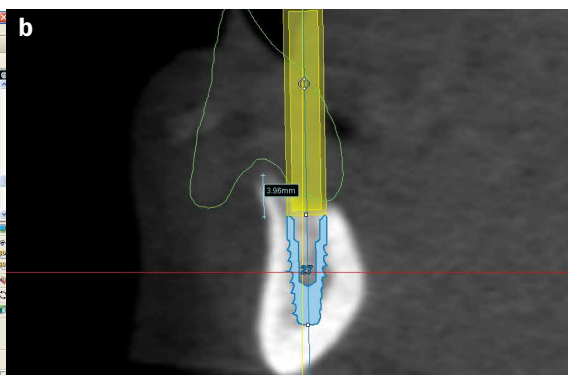
Due to our patient's age and budget, the decision was made to do osteoplasty to create a broad enough base for 5 implants in the A, B, C, D, and E positions between the mental foramina. Because the mental nerve exited the superior aspect of the ridge, a bone reduction surgical guide could not be utilized. This type of guide required more reflection of the soft tissue to seat the guide, with injury to the mental nerve being a real possibility due to the size of the flap required (Figure 2).

The denture with its fiduciary markers can be seen in Figure 3 in the lower right corner. The use of 2 implants with attachments or 4 implants with a bar were both discussed with the patient, but she wished to have "fixed" teeth that

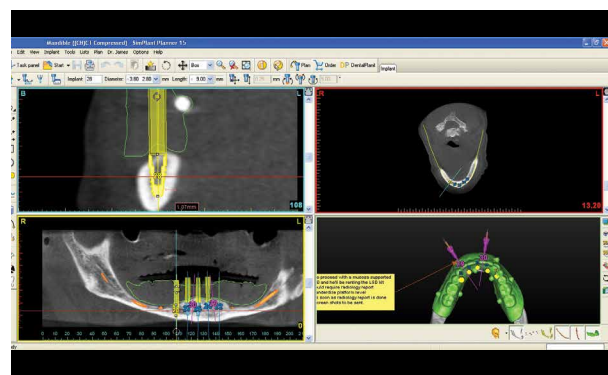
continued on page 140



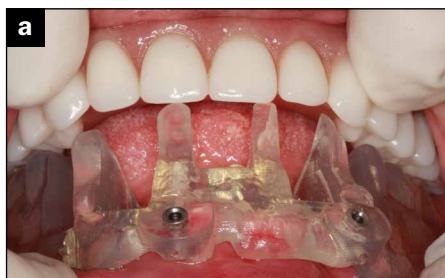**Figure 7a.** Implant No. 22 and measurements for placement.



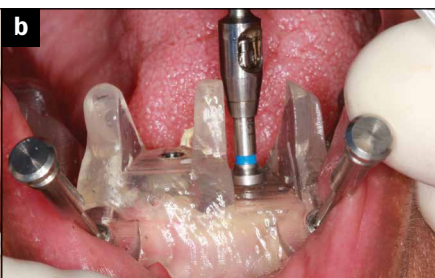**Figure 7b.** Closeup of axial view for implant No. 27.



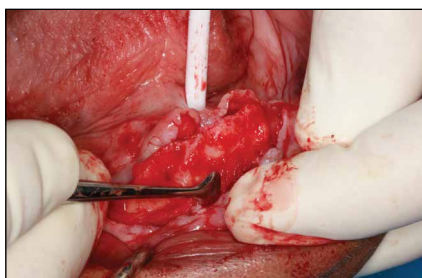
**Figure 8.** Implant No. 28 with planned exposure of buccal lip Laser-Lok threads [BioHorizons].



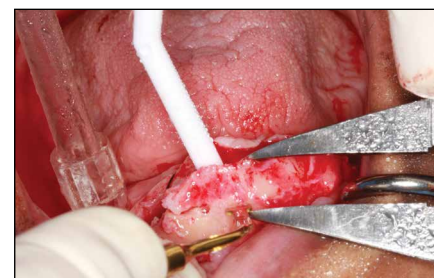
**Figure 9a.** Seated Pilot surgical guide (3D Diagnostix) with approved tooth placement.



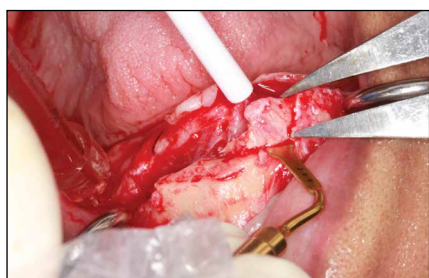
**Figure 9b.** Pilot guide osteotomy with stabilization pins placed.



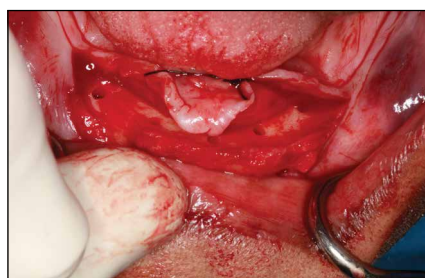
**Figure 10.** Degloving the mandible prior to osteoplasty.



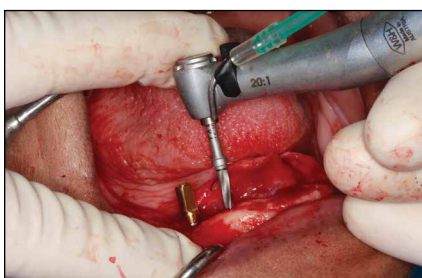
**Figure 11.** Measurement and Piezo (Piezosurgery, Inc) reduction of bone by design.



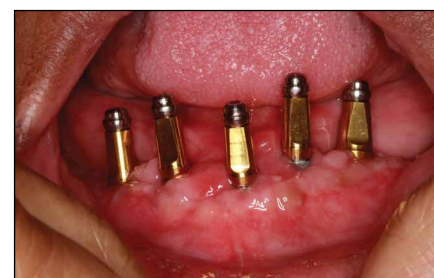**Figure 12.** Piezosurgery tip and removal of bone blocks with microvibration technology.



**Figure 13.** Finished osteoplasty of mandibular anterior.



**Figure 14.** Completion of osteotomies for BioHorizons Implant placement.



**Figure 15.** Frontal view of implants prior to initial impressions.

**Rehabilitation of Mandibular Atrophy...**  
*continued from page 138*

she would not have to remove at night. A solid zirconia bridge was planned.

At each implant site, the bone

was evaluated to see if it required osteoplasty and, if so, how much was needed. For implant No. 28, the facial of the implant would remain equigingival, as the Laser-Lok surface (BioHorizons) could be used to hold onto


uneven bone levels as well as to support soft-tissue contours by allowing the hemidesmosomal attachments to stay at the laser-etched, microgroove levels while inhibiting bacterial down-growth.<sup>7</sup> So, 1.29 mm of implant No. 29

were to be in soft tissue and not fully buried in the osteotomy (Figure 3).

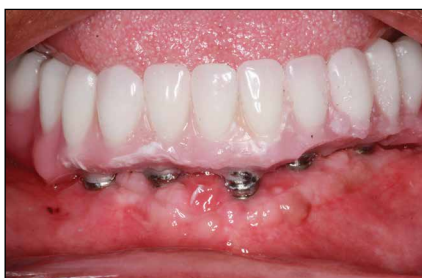Relevant measurements were made to ensure complete bony support. Furthermore, each implant was taken through implant-centric review to check the bone contours while rotating 360° around each implant (DENTSPLY/SIMPLANT) Careful attention was made to allow for a 5.0 mm safety zone anterior to the mental foramen in case of any anterior loop that might be present.<sup>8,9</sup> The implants were planned to create the widest anterior to posterior (A-P) distance where adequate bone could be appreciated after osteoplasty. Placement of implant at site No. 27 revealed a lip of bone that was 4.96



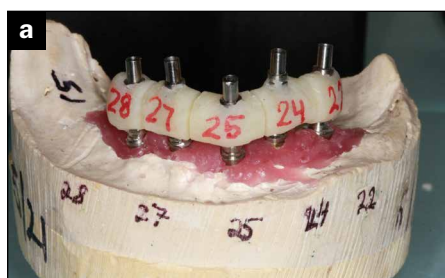
**Figure 16a.** Vinyl polysiloxane (VPS) impression (Aquasil Ultra Extra [DENTSPLY Caulk]) of ball top screws.



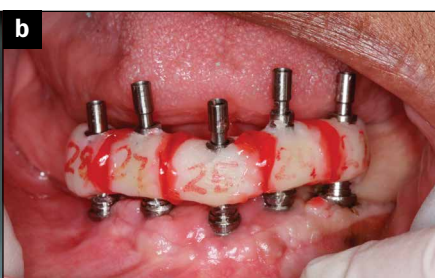**Figure 16b.** Seating the abutment ball top screw prior to analog placement.



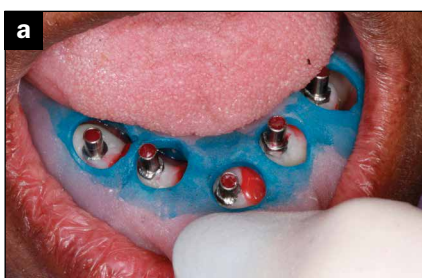
**Figure 17.** Full try-in of teeth at proper occlusal vertical dimension with windows to view component seating.



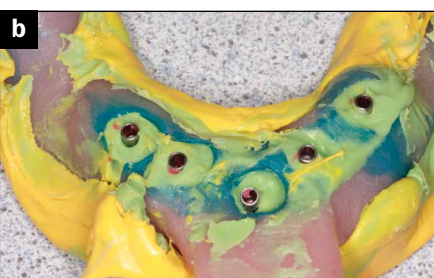
**Figure 18a.** Verification jig on cast.



**Figure 18b.** Verification jig intraorally, after luting and performing Sheffield test.



**Figure 19a.** Open-tray pickup of jig.



**Figure 19b.** VPS body and wash was used to pick-up verification jig.

mm higher than the flat plane level of the other implants. So this would be the amount of osteoplasty at this site. In the 3-D rendering view (lower righthand portion of Figure 4), the presence of the mental foramen on the crestal ridge could be viewed as well as the safety zone of the implants placed, with respect to the nerve (Figure 4).

The implant at site No. 25 revealed the need for 7.55 mm of osteoplasty to allow for a 1.5 mm amount of bone for the facial and palatal walls after implant placement and osteoplasty.

Viewing the lower righthand corner of the DENTSPLY/SIMPLANT screen reveals the actual lip of bone that would be removed in order to find a flat platform for implant placement (Figure 5). The implant at site No. 24 shows the 5.56 mm lip that required removal and the 2.0 mm of bone that would be present facially and lingually post-osteoplasty (Figure 6).

For the implant at site No. 22, the DENTSPLY/SIMPLANT views show the full-screen window and the closeup of the axial

---

*Use of a pilot surgical guide would indicate the amount of soft-tissue reflection that would safely protect the mental nerve.*

---

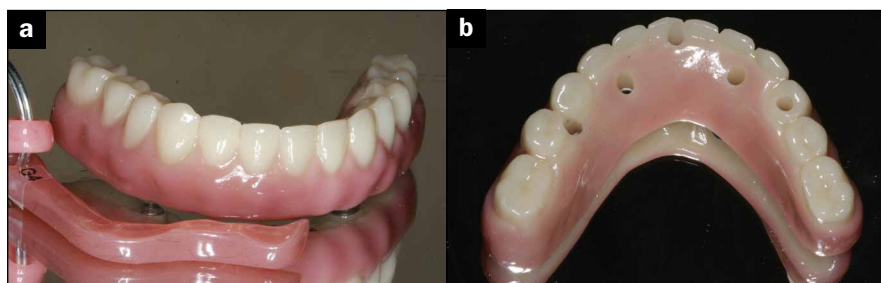
view showing that measurements can vary if careful attention is not paid to where the measurements were taken (Figure 7). The planned implants, and where they are oriented with respect to the approved denture, can help plan the prosthesis design (Figure 8). Since the cantilever of a fixed prosthesis can be no more than 1.5 times the A-P distance from the anterior to posterior implant, the prosthesis may need to be removable as well as soft-tissue and implant-supported, if the number of teeth allowed due to A-P spread constraints is too small.<sup>10</sup>

In this case, a bone reduction guide would have been desirable, as osteoplasty could have been accomplished quickly; however, to reflect the tissue enough to seat the surgical guide may have encroached on the safety zone, making the dissection a riskier procedure. Therefore, the measurements of the CBCT on the reformatted images and the use of a pilot surgical guide would dictate the angulation, location, depth of the osteotomies, and would indicate the amount of soft-tissue reflection that would safely protect the mental nerve as it exited the summit of the ridge. The Seated Pilot surgical guide (3D Diagnostix), as fabricated and ordered from 3DDX.com, shows where the teeth of the denture are located during osteotomy placement (Figure 9).

A mid-crestal incision was made connecting the pilot osteotomies, the tissue was reflected carefully and a 3-0 Silk suture (Salvin Dental Specialties) was used to hold lingual tissues back during osteoplasty (Figure 10). At each implant site, the amount of osseous reduction was marked with a round bur, and piezosurgery (Piezosurgery, Inc) was used to remove the bone atraumatically at each implant site. The micrometric cutting action caused by microvibrations of the piezosurgery device will cut the bone while minimizing soft-tissue trauma.<sup>11</sup> The pulsating hydrodynamic cooling of the device keeps the bone cool while aiding in maintaining decreased bleeding in the surgical view.

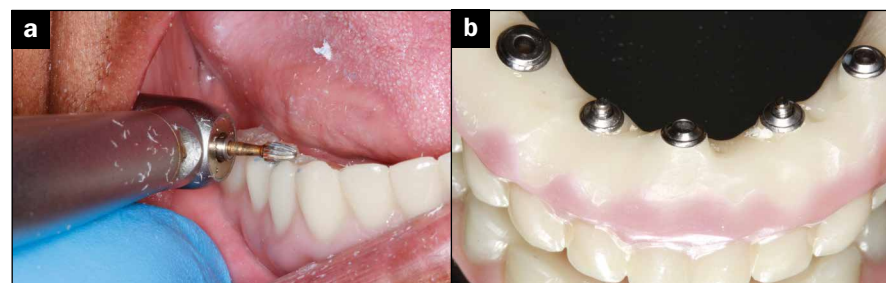
The bone removal and amount of reduction are carefully controlled at each site (Figure 11). Removal of the bone in segments ensures a flat plane and allows for autogenous bone that can be further morselized for grafting any defects appreciated during the surgery (Figure 12). The completed osteoplasties with the pilot surgical osteotomies are accomplished according to pre-planning (Figure 13). Sequentially enlarging the osteotomies and placement of the implants were then performed (Figure 14).

After 5 months of healing, the 3-in-one abutments and ball top screws were used to make a vinyl polysiloxane (VPS)



**Figure 20a.** Prototype polymethyl methacrylate (PMMA) restoration ready to deliver.

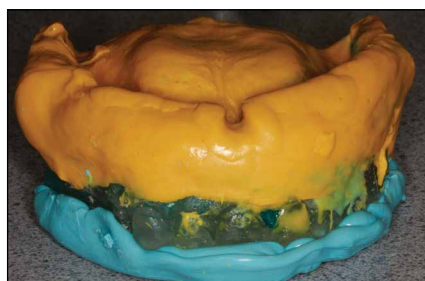**Figure 20b.** Lingual view of PMMA showing screw access problem.



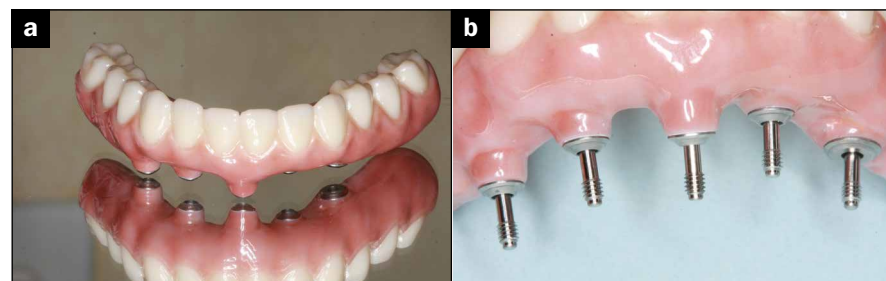
**Figure 21a.** Adjustment of right working interferences.

**Figure 21b.** Intaglio of adjusted provisional PMMA.

(Aquasil Ultra Extra [DENTSPLY Caulk]) impression of the implants (Figure 15). This VPS impression material allowed for extra working time and captured the soft tissues and the implant positions definitively, providing an accurate master cast and soft-tissue masque that gave the dental laboratory team the information required to properly design and fabricate the zirconia prosthesis (BruxZir Solid Zirconia Bridge [Glidewell Laboratories]) (Figure 16).



**Figure 22.** VPS impression in Lang Duplicate for fabrication of new upper complete denture.



**Figure 23a.** Zirconia (BruxZir Solid Zirconia Bridge [Glidewell Laboratories]) bridge.

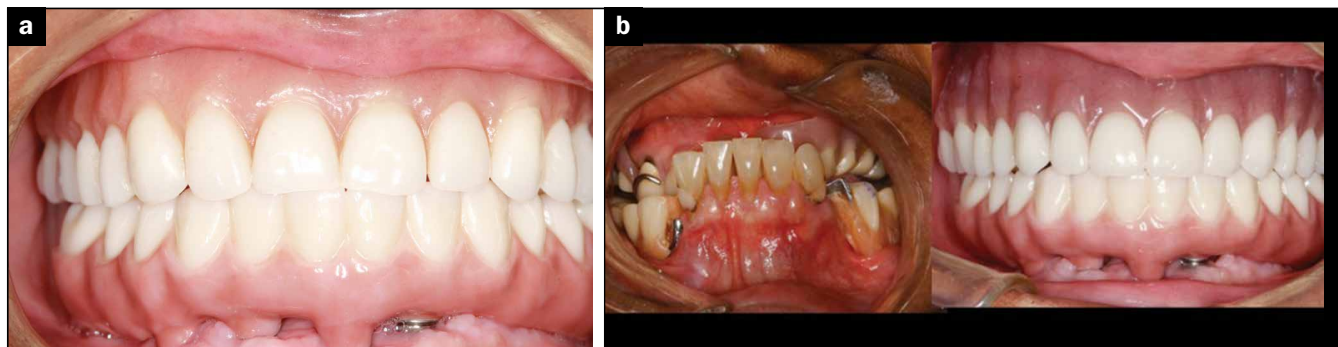
**Figure 23b.** Apical design of bridge and hygienic access.

After the baseplate and wax-rim try-in visit was done, a full wax-up of the anticipated prosthesis was tried in. The anterior portion of the baseplate had been removed (per prescription instructions) so that the fit of the wax-up could be verified and a one-screw test (Sheffield) performed on the try-in as well as the verification jig (Figure 17).<sup>12-14</sup>

The verification jig consists of blocks of acrylic that are tried in intra-orally and luted together with a light-cured pattern resin (Primopattern LC Gel [Primattec]) that provides excellent dimensional stability and low polymerization shrinkage. Once the jig was seated and luted together, radiographs were taken to ensure complete seating (before unscrewing the jig and trying it on with each screw independently) and, in addition, to ensure the accuracy of the master impression and stone cast (Figure 18).

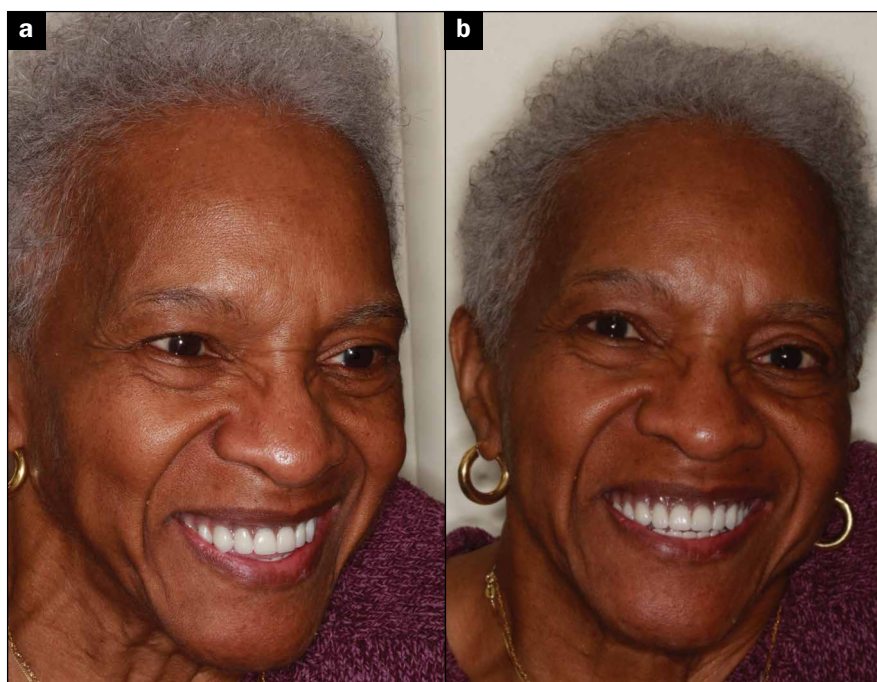
You can see from Figure 18b that using one screw, 2 screws, and alternating screws can show whether the jig is passive. If it rises with one screw, the verification jig must be sectioned, reluted, re-verified with a radiograph, and then the Sheffield test must be redone (Figure 18).<sup>12-14</sup>

Picking up the verification jig with an open-tray impression was done as a tertiary check to ensure the accuracy of the BruxZir prosthesis (Figure 19). Aquasil Ultra fast-set medium-body and light-viscosity wash material was used to pick up the verification jig. Red rope wax was used to seal the long coping screw, and a gloved finger was used to swipe off the occlusal portion of the impression material until the red wax was visible (Figure 19b).



**Figure 24a.** Delivery of final prosthesis.

**Figure 24b.** Before and after views.



**Figures 25a and 25b.** Our very happy patient, smiling with her completed maxillary and mandibular prostheses.

The polymethyl methacrylate (PMMA) prototype was milled and returned with the properly shaded gingiva to evaluate aesthetics, phonetics, and function prior to milling the final zirconia prosthesis. Any changes to the

PMMA would necessitate a new bite registration and return of the approved PMMA for rescanning, prior to fabrication of the final bridge (Figure 20a).

The occlusal view of the prosthesis shows the A-P spread, the requisite 1.5

times A-P spread required ending the prosthesis at first molar occlusion. The thinness of the tooth at site No. 25 was disconcerting, so a new upper denture was made to labialize the maxillary anterior teeth and to also allow for movement of the mandibular anteriors labially to improve tooth contours and strength (Figure 20b). The occlusion of the PMMA was adjusted to allow for lingualized and bilateral balanced occlusion. The intaglio of the restoration was also adjusted to make it convex and easily cleansable (Figure 21). A Lang Duplicate of the upper denture was fabricated at the operator chair. The intaglio was reduced and a wash accomplished with Aquasil Ultra medium- and light-viscosity materials. A bite registration was taken (Blu-Mousse [Parkell]) and the laboratory team now had the incisal edge position, occlusal vertical dimension, tooth shape, shade, and mold, and (by prescription) could accomplish a full try-in with all teeth set at the next PMMA try-in visit (Figure 22).

#### THE MYSTERY SOLVED

Approval of the prototypic restoration and final milling of the zirconia

---

*Our patient underwent a real transformation, with the emotional and psychological aspects of implant rehabilitation being very apparent.*

---

prosthesis ensured that the final delivery would go smoothly. The zirconia prosthesis was well festooned, accurately tinted, and the intaglio was smooth and cleansable (Figure 23). The completed restoration was delivered and verified using radiographs before torquing the abutment screws to 35 Ncm twice and sealing the orifices of the prosthesis with composite resin (Temposil II and TPH [DENTSPLY Caulk]) (Figure 24).

The before and after photos are a startling reminder of the steps required to initiate rehabilitation of occlusal form and aesthetic concerns for the first phase of the treatment. The need to educate our patients *before* they reach this point may help our patients choose comprehensive implant reconstruction *prior to reaching this level of occlusal destruction*.

Our patient underwent a real transformation, with the emotional and psychological aspects of implant rehabilitation being very apparent (Figure 25).

#### IN SUMMARY

Treatment planning of advanced dental problem sets can be a bit like solving a complex mystery case. It can involve financial, anatomic, medical, and psychogenic factors. As clinicians, it is easy to perpetuate occlusal disharmony and exacerbate foundation eradication by viewing difficult patients through narrow lenses. Challenging cases, as alluded to by the title of this case study, are abundant in our practices. How we present the facts, as well as the options for dynamic treatment, can lead to rewarding dental care. ♦

#### References

1. Ozan O, Orhan K, Aksoy S, et al. The effect of removable partial dentures on alveolar bone resorption: a retrospective study with cone-beam computed tomography. *J Prosthodont*. 2013;22:42-48.
2. Shavell HM. Bioesthetics of complete porcelain occlusal rehabilitation using the Sunrise ceramic system: a case report. *Int J Periodontics Restorative Dent*. 1990;10:256-279.
3. Winter R. Compromised foundations require confident conversation. *Dent Today*. 2011;30:110-115.
4. Tolstunov L. Combination syndrome: classification and case report. *J Oral Implantol*. 2007;33:139-151.
5. Kelly E. Changes caused by a mandibular removable partial denture opposing a maxillary complete denture. *J Prosthet Dent*. 1972;27:140-150.
6. Misch CE, Qu Z, Bidez MW. Mechanical properties of trabecular bone in the human mandible: implications for dental implant treatment planning and surgical placement. *J Oral Maxillofac Surg*. 1999;57(6):700-708.
7. Guarnieri R, Serra M, Bava L, et al. The impact of laser-microtexturing collar on crestal bone level, and clinical parameters under various placement and loading protocols. *Int J Oral Maxillofac Implants*. 2014;29(2):354-363. DOI: 10.11607/jomi.3250.
8. Mardinger O, Chaushu G, Arensburg B, et al. Anatomic and radiologic course of the mandibular incisive canal. *Surg Radiol Anat*. 2000;22:157-161.
9. Kuzmanovic DV, Payne AG, Kieser JA, et al. Anterior loop of the mental nerve: a morphological and radiographic study. *Clin Oral Implants Res*. 2003;14:464-471.
10. English CE. Critical A-P spread. *Implant Soc*. 1990;1:2-3.
11. Chiriac G, Herten M, Schwarz F, et al. Autogenous bone chips: influence of a new piezoelectric device (Piezosurgery) on chip morphology, cell viability and differentiation. *J Clin Periodontol*. 2005;32:994-999.
12. Abduo J, Bennani V, Waddell N, et al. Assessing the fit of implant fixed prostheses: a critical review. *Int J Oral Maxillofac Implants*. 2010;25:506-515.
13. JOMI Current Issues Forum: "How do you test a cast framework fit for a full-arch fixed implant-supported prosthesis?" *Int J Oral Maxillofac Implants*. 1994;9:469-474.
14. Hollweg H, Jacques LB, da Silva Moura M, et al. Deformation of implant abutments after framework connection using strain gauges. *J Oral Implantol*. 2012;38(2):125-132.

**Dr. Winter** graduated from the University of Minnesota School of Dentistry in 1988. He is a Master in the AGD and a Diplomate in the American Board of Oral Implantologists/Implant Dentists and the International Congress of Oral Implantologists. He holds Fellowships in the International College of Dentists, the Academy of Dentistry International, and the American Academy of Implant Dentistry. He has published numerous articles on implant and reconstructive dentistry as well as advanced treatment planning and general dentistry as a specialty. He can be reached for lecture and hands-on course information via email at rick@winterdental.com.

*Disclosures:* Dr. Winter discloses that honoraria has been provided from DENTSPLY Caulk, BioHorizons, Piezosurgery Inc, 3D Diagnostix, and Glidewell.