

# EVALUATION OF THE POSTOPERATIVE BREAST

Ellen B. Mendelson, MD

The large number of surgical procedures involving the breast can be extrapolated from the expected number of cancers.<sup>12</sup> About 175,000 new breast carcinomas will be diagnosed during the current year in the United States. If this number represents approximately 15% to 35% of surgical breast biopsies, the total number of surgical procedures would be at least 500,000. Because postsurgical changes may overlap with radiographic features of malignancy, mammographic evaluation in these patients may be difficult. Alterations in breast tissue also may change in time, further complicating interpretation.

For analysis to be accurate, the mammograms must be placed in temporal context and correlated with the physical findings and procedures that have been performed. A favorable outcome for a breast cancer patient requires the combined efforts of the radiologist, pathologist, surgeon, radiation oncologist, medical oncologist, and the patient herself. Particularly when the carcinoma is nonpalpable, the radiologist plays a central role in the team effort.

This article focuses on imaging and follow-up management of the conservatively treated breast. Also reviewed are the radiographic findings associated with benign breast biopsy and cosmetic procedures including reconstruction, augmentation, and reduction mammoplasty.

## LUMPECTOMY/BENIGN BIOPSY

### Background, Eligibility, and Role of Mammography in Patient Selection

In the last two decades, breast cancer therapy has changed dramatically. For eligible women, equivalent survival rates have been demonstrated for breast conservation therapy (wide tumor excision and radiation therapy) and mastectomy.<sup>29</sup> Tumor recurrence varies from 6% to 10%, at rates reported as 1% to 2% or more per year after treatment.<sup>5, 25, 29, 36, 83, 86</sup> In the first 7 years, the tumor generally recurs near the lumpectomy site, with mean time to recurrence being 3 years. After that, tumor is found increasingly in other quadrants. The conservatively treated breast cancer patient with recurrent local tumor does not have the same poor prognosis as a patient with a mastectomy who has a chest wall recurrence. Salvage mastectomy to treat recurrence after lumpectomy and radiation therapy does not jeopardize a patient's survival expectations. In some cases, the recurrent carcinoma has been reexcised without sacrificing the breast.

Careful selection and staging of patients for breast conservation therapy are important for optimal outcomes.<sup>29, 68, 88</sup> Although eligibility criteria may vary somewhat, candidates

From the Department of Radiology, The Western Pennsylvania Hospital and the University of Pittsburgh School of Medicine, Pittsburgh, Pennsylvania

for lumpectomy and irradiation will have tumors less than 5 cm (T1 or T2), although most tumors have been smaller than 4 to 4.5 cm.<sup>20, 62</sup> Positive axillary lymph nodes are not a contraindication. An important selection criterion is that the tumor be removed with satisfactory cosmesis. Excision of a large tumor from a small breast may result in breast deformity and a poor cosmetic effect. No location in the breast is absolutely contraindicated for breast conservation therapy. Retroareolar lesions involve removal of the nipple areolar complex, and for some patients, mastectomy may be preferable. Women with multicentric masses or diffuse, widespread malignant appearing microcalcifications are not good candidates for lumpectomy and radiation therapy.<sup>62, 79, 80</sup>

Breast conservation therapy that requires irradiation is not an option for patients who are in the first and second trimesters of pregnancy.<sup>38</sup> If lumpectomy is performed in the third trimester, the breast carcinoma can be irradiated after delivery. Women who have collagen vascular disease are at risk of breast fibrosis after radiation therapy.<sup>36, 38, 71</sup> In patients who have had radiation therapy previously to an area that has included the breast, such as for Hodgkin's disease, irradiation for breast carcinoma results in an unacceptably high cumulative dose. Breast conservation therapy is not a good choice for debilitated patients for whom the long commitment to therapy would be a hardship. Those women who do not wish to undergo lumpectomy and radiation therapy should be offered other treatments.

### **Preoperative and Perioperative Assessment: The Role of Mammography**

When tumor is demonstrable radiographically, mammography can establish appropriateness of lumpectomy and radiation therapy by defining extent of a patient's disease, suggesting multicentricity, and evaluating the contralateral breast.<sup>74</sup> Mammographic analysis can further help to guide patient selection by suggesting presence of certain prognostic indicators for tumor recurrence such as invasive carcinoma with an extensive intraductal component as manifested by microcalcifications seen on the mammogram.<sup>40, 61</sup> Magnification radiography should be performed in two projections to characterize

microcalcifications better and exclude benign calcifications such as milk of calcium in small cysts (90-degree lateral view). Clusters of dermal calcifications can be identified with magnification views that might show their radiolucent centers and tangential views for localization in the skin. Magnification radiography is also useful to bring out other faintly seen foci of involvement and to evaluate the retroareolar area. Many more microcalcifications may be present than seen on standard projections.<sup>73</sup>

A factor that may affect risk of recurrence is size of the tumor, a good prognosis for tumors smaller than 1 cm.<sup>32, 72</sup> If the tumor can be outlined on a mammogram or seen on a sonogram, three dimensions can be measured. Spot compression, with or without magnification, can be used to spread apart overlapping areas of breast tissue, exclude a pseudomass caused by superimposed parenchyma, and image marginal detail of a true mass. Spot compression should be used to define the margins of discrete, rounded soft-tissue densities that might represent tumor satellites near the tumor or multicentric foci in distant quadrants.

Presurgical localization should be precise, usually no more than 0.5 to 1.0 cm away from the mass or calcifications.<sup>33, 74, 86</sup> Whether the level of suspicion of malignancy is high or low, all presurgically localized nonpalpable and some palpable abnormalities require specimen radiography to confirm removal. If dense fibroglandular tissue obscures the mass or microcalcifications in the specimen, a different projection may shift tissue relationships and permit the abnormality to be perceived.<sup>17</sup> Full compression and magnification also increase visibility of the abnormality. If the mass is present at one or more margins or microcalcifications extend to the edge of the specimen, the surgeon, before closure, should be advised to remove more tissue. Additional excised material should also be radiographed. Each specimen should be numbered, correlated with the mammogram, and described, with findings conveyed by the radiologist immediately to the surgeon in the operating room and then later in the written report.

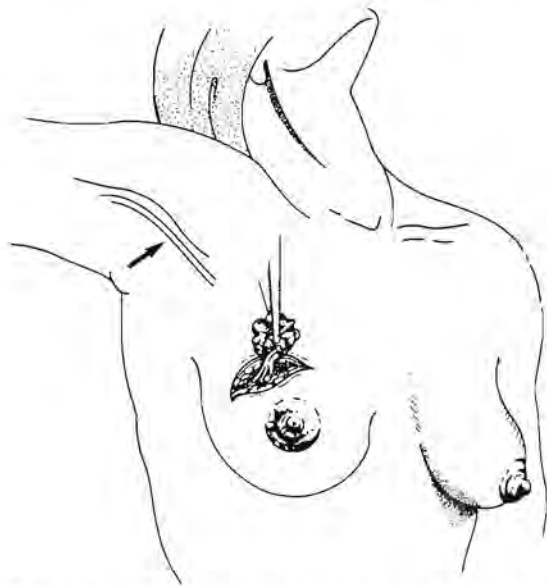Perioperative radiographic assessment of the adequacy of resection is one of the radiologist's major responsibilities. If removal of the abnormality remains uncertain after specimen radiography and additional tissue sampling, intraoperative mammography has

been suggested if local anesthesia has been given.<sup>84</sup> After loose suturing of the incision, a mammogram is performed. If the lesion is confirmed in the breast, the abnormality is then relocalized and the patient returned to surgery. Merits of the procedure have occasioned some debate, calling attention to the radiologist's central role in patient management.<sup>35</sup>

## BREAST CONSERVATION IN CARCINOMA

### Surgical Approach

In the United States, the surgical approach for excisional biopsies is the same as that for lumpectomy for carcinoma.<sup>82</sup> Through a curvilinear incision made directly over it, the lesion is removed, surrounded by a rim of grossly normal breast tissue (Fig. 1).<sup>29, 30, 79, 92</sup> Ordinarily, no skin is taken with the lesion; if any skin is excised, it should be only a small ellipse. Unless the tumor is adherent to the pectoralis fascia, the fascia deep to the tumor is spared. In a young patient in whom an abnormality is thought to be benign, such as a fibroadenoma, some tunneling through



**Figure 1.** Breast conservation therapy: surgical technique. Through an incision made directly over the tumor, the tumor is removed with a surrounding area of grossly normal parenchyma. A separate incision is made for the axillary dissection (arrow), which may be performed later. (Adapted from Isaacs JH: Breast biopsy and the surgical treatment of early carcinoma of the breast. *Obstet Gynecol Clin North Am* 14:711-732, 1987.)

the breast tissue to reach the lesion from a circumareolar incision is acceptable for a better cosmetic result.<sup>16</sup> Tunneling is avoided otherwise in the breast cancer patient because of difficulties in radiation treatment planning and follow-up care where the skin incision site and the deeper tumor bed do not correlate.

Cosmesis is one of the requirements of successful breast conservation therapy, and the surgical technique should aspire to a good cosmetic result as well as control of disease.<sup>29, 38</sup> Ordinarily, in a lumpectomy only the subcutaneous fat and subcuticular layers are sutured. The deeper tissues of the surgical bed fill in gradually. Meticulous hemostasis decreases the likelihood that large hematomas or seromas will form in the biopsy site. Use of a drain is discouraged.<sup>10, 29</sup> Theoretically, using this surgical technique, the normal breast contour might be preserved better than where apposition of breast parenchyma and the placement of a drain could create a craterlike concavity.

Terms for the surgical procedures of breast conservation therapy are not defined consistently.<sup>2</sup> For Kinne and Kopans, lumpectomy and excisional biopsy signify tumor removal without regard to marginal status.<sup>4</sup> They distinguish these synonyms from wide excisional biopsy or removal of the tumor with a surrounding area that is free of malignancy grossly or histologically. In the literature, the terms *excisional biopsy*, *wide excision*, *tumorectomy*, *lumpectomy*, *segmental mastectomy*, and *tylectomy* are often interchanged. A description of the procedure is ordinarily provided in each reference.

The wide excisional biopsy (partial mastectomy, limited resection) is the definitive surgical procedure for conservative treatment of breast carcinoma in the United States.<sup>18</sup> Other surgical techniques, such as a quadrantectomy, are advocated in Europe for tumor removal, with removal of the quadrant of breast tissue containing the tumor along with the skin and superficial pectoralis fascia.<sup>90, 91</sup> Except where confirmation of carcinoma has been provided by fine-needle aspiration or core biopsy in advance of surgery, additional surgical procedures await histologic interpretation. Thus, axillary dissection or mastectomy may be performed as the second of a two-stage procedure.<sup>16</sup> Other theories of tumor spread may lead to different approaches to resection such as excision of a discharging ductal segment mapped preoperatively with galactography.

## Radiation Therapy

The affected breast is ordinarily irradiated as soon as the surgical site has healed adequately, 2 to 5 weeks after lumpectomy and axillary dissection. Forty-five to 50 Gy is given to the breast in five daily doses per week over a 5-week period.<sup>36-61</sup> For many patients, an electron beam or iridium implant boost to the lumpectomy site will be used, increasing the total dose to the breast to approximately 60 to 66 Gy. After lymph node dissection, the axilla is not irradiated.<sup>62</sup>

## IMAGING AFTER BENIGN BIOPSY AND LUMPECTOMY AND RADIATION THERAPY

The purposes of breast imaging after surgical biopsy are to confirm removal of the abnormality, to assess postprocedural complications, to detect recurrent tumor at the operative site, and to demonstrate other ipsilateral or contralateral interval changes that might signify carcinoma. Expected postoperative changes include masses, scarring, edema, skin thickening, and calcifications.\* These postoperative findings, which may mask the signs of malignancy, occur both after benign biopsy and excision of carcinoma and are accentuated and prolonged by radiation therapy.

### General Approach

Diagnostic accuracy increases with the awareness (1) of how the procedures are performed, (2) that there may be drastic or little temporal change, and (3) that interpretation is even more difficult in the densely fibroglandular breast.<sup>34</sup>

The potential of mammography to characterize physical and mammographic findings should be fully utilized. Additional views, such as spot compression, magnification, tangential, and various obliquities will be useful in most cases. To identify the fluid component of a postoperative mass, sonography is indicated,<sup>1-6</sup> and other techniques such as computed tomography (CT) or magnetic resonance (MR) imaging will be helpful occasionally.<sup>42, 43, 36</sup>

\*References 6, 7, 10, 22, 23, 34, 39, 40, 51, 52, 55, 56, 59, 65-67, 73, 74, 76, 86, 89.

Accurate interpretation depends as much on the chronology of alterations as it does on mammographic depiction of masses and calcifications on each single examination.<sup>15, 40</sup> Many errors will be avoided if mammograms are evaluated in sequence, always comparing with the earliest not just the most recent study. If evaluated in this manner, the possibility of recurrent carcinoma can be suggested with greater confidence. Misinterpretation of surgical and radiation changes also will be less likely, which is important in avoiding unnecessary biopsy of radiated tissues, which may heal less readily than in the untreated breast.

### Patient Data

For the appropriate examination to be performed, the radiologist and technologist must be aware of pertinent aspects of the patient's history. A diagram and checklist of signs and symptoms can be printed on the referring physician's prescription pad used to request a mammogram. In many practices, including our own, the patient is given a data sheet to complete. In addition to questions related to family history and other possible risk factors for breast carcinoma, the patient is asked if and when she has had surgical or other treatment for breast cancer, biopsies, aspirations of fluid-filled or solid lesions, or cosmetic alterations. The patient is requested to indicate locations of masses, pain, and prior surgery on a diagram. On subsequent visits, the patient will fill out an abbreviated form to update her history of surgical procedures and medications, including postmenopausal hormonal replacement therapy. These informational forms and copies of all pathology and cytology reports are kept in the patient's folder where they are easily accessible for patient management decisions and case review conferences.

### Marking Scars

Technologists take a brief history from the patient. They mark the location of palpable masses, dermal lesions, and scars on a diagram and then on the patient. Small radiopaque BBs are placed on the site of dermal lesions or palpable masses. For correlation with possible mammographic findings such as architectural distortion and new dystrophic calcifications, scars are marked with

lengths of thin wire that are taped to the skin. Wires that are used for presurgical localization of nonpalpable lesions are of the appropriate caliber, and they can be made easily to conform to the length and shape of the scar. Fine-gauge radiopaque metallic wires are also obtainable inexpensively from jewelry and craft shops. A piece of wire the size of the scar is affixed to the adherent surface of hypoallergenic paper tape, which is then placed on the scar before the mammogram is performed.

Although the breast may show no radiographic evidence of prior surgical activity, particularly with benign biopsies after several years have passed (Fig. 2),<sup>76</sup> application of a skin marker to the patient adds little to the time required for the examination. Marking all scars will ensure that the maneuver will not be forgotten in the conservatively treated breast cancer patient in whom mammographic changes may be more profound, persistent, and ambiguous. An exception is made for extensive surgical procedures, such as reduction mammoplasty, that involve much of the breast, which are shown diagrammatically only. In demarcating the scar, the marker reminds the technologist to position the patient carefully so that the entire area is included on at least one view. The marker also can be used to direct patient positioning for tangential views that will define the relationships of a mass or calcifications to the skin. Mammographic visualization of the breast tissue is not compromised by the wires.

### Identifying the Surgical Bed

It is important to evaluate the tumor bed because more than 65% of recurrences are in or within a few centimeters of the site of excision.<sup>32, 37, 38, 87</sup> The skin marker on the scar may not always correlate with the site of surgical excision lying deeper in the breast. A mammographic view tangential to the skin incision site will permit differentiation of an external scar from the spiculated intramammary scar.

Ultrasonography can be used similarly to distinguish the skin from the lumpectomy scar within the breast. On posttreatment sonograms, the surgical bed can be identified beneath the subcutaneous fat as a distinct hypoechoic oval area with posterior acoustic enhancement if fluid remains or as a linear

hypoechoic area with posterior acoustic shadowing (Fig. 3) seen when scarring has developed.<sup>56</sup> Not infrequently, a tract between the surgical bed and the skin incision site can be demonstrated.

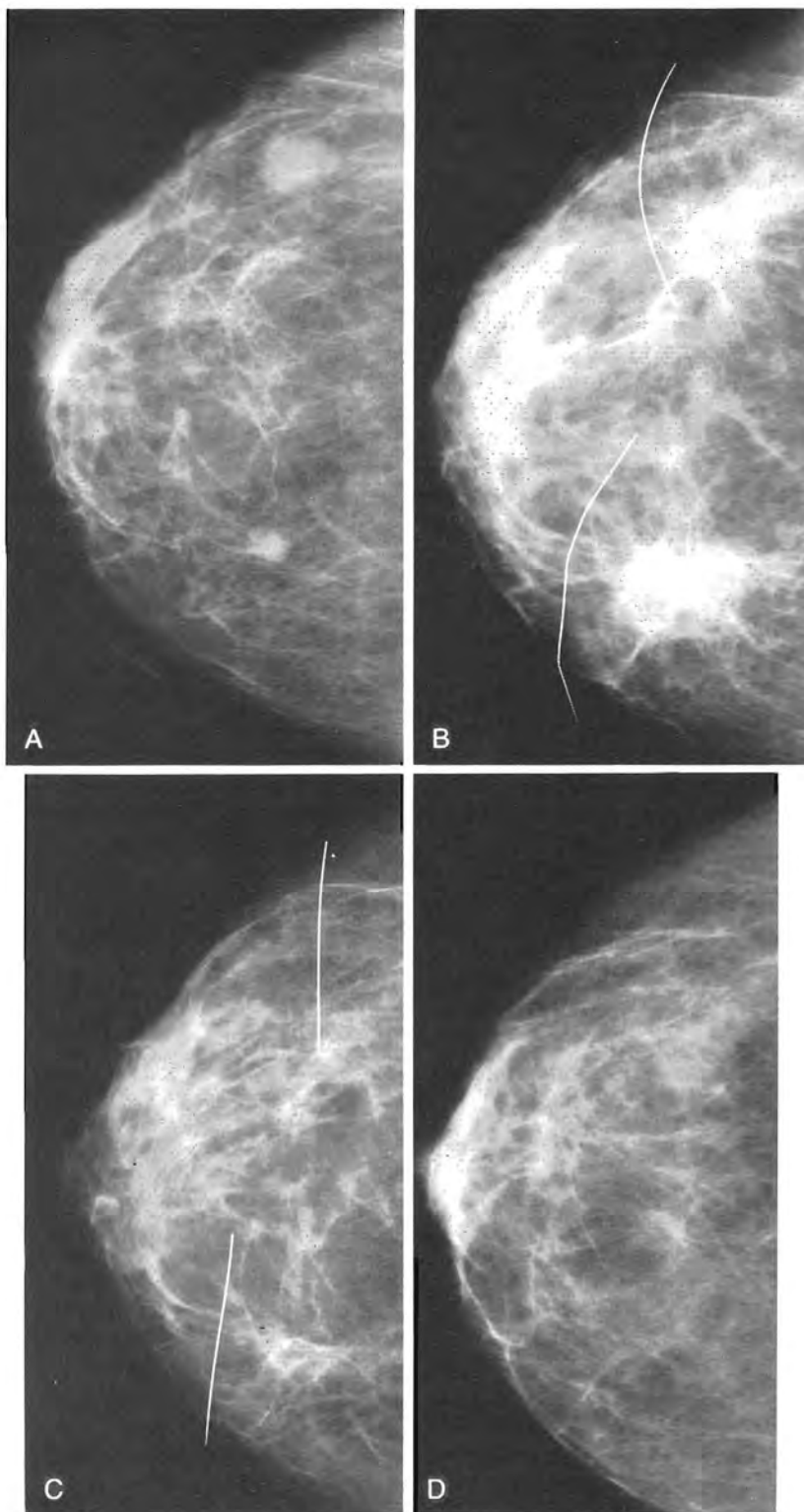
Some surgeons deploy clips within the breast at the margins of the lumpectomy site to focus mammographic follow-up and for radiation therapy planning (Fig. 4). The interclip distance provides a measurable reference for the surrounding soft-tissue density, which represents postsurgical fibrosis and fat necrosis. On follow-up studies, there will be contraction of the scar tissue. Stability is defined as lack of interval change on two successive studies. After that, a new nodule, microcalcifications, or an increased area of soft-tissue density surrounding the clips or even separating them will suggest recurrent tumor.

Neither the surgical clips nor the skin wires will interfere with imaging. Except to cause a small signal void artifact, the clips should not interfere with MR imaging, a technique being studied for its potential to allow differentiation of mature postsurgical scarring from recurrent tumor at the lumpectomy site.<sup>43, 44</sup>

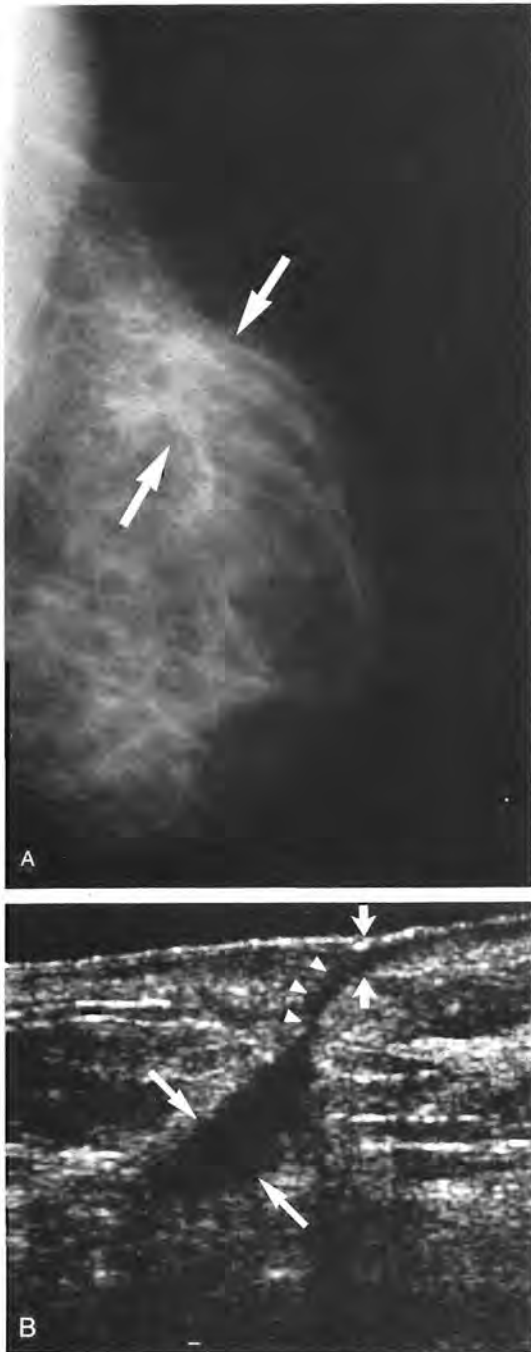
## FINDINGS AFTER BENIGN BIOPSY AND LUMPECTOMY AND RADIATION THERAPY

### Masses and Fluid Collections

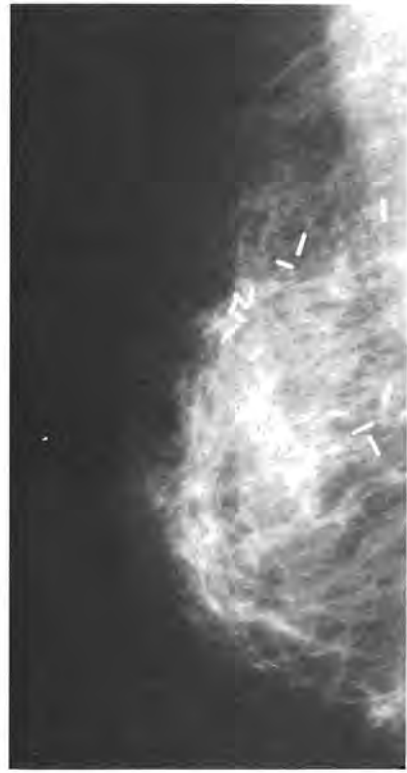
Asymmetric soft-tissue densities are expected at postoperative sites.<sup>85</sup> They may represent fluid collections, fibrosis, or fat necrosis at the site of surgical activity. Parenchymal asymmetry may also come to attention as a possible contralateral abnormality, ultimately explained by absence of equivalent tissue on the operative side (Fig. 5). The appearance of the surgical site depends upon the interval that has elapsed between the procedure and the imaging studies. During the first year after breast conservation therapy, in the area of lumpectomy, the mammogram often shows an oval mass that is fairly dense and well marginated but usually with a few spiculations or irregularities. On a 90-degree lateral view, fluid elements within these hematomas or seromas may show layering.<sup>23</sup> The mammographic appearance and timing are suggestive; tumor re-



**Figure 2.** Resolution of postsurgical change after benign biopsy. *A*, In a patient who already had been biopsied in the inner half of the breast (note wire on skin), the two soft-tissue densities were localized and excised. The smaller, medial mass was a fibroadenoma and the larger, a focal area of chronic cystic disease. No specimens were submitted for radiography at the time of biopsy. *B*, The diagnosis of the larger mass was questioned, and a postoperative mammogram was requested. Two months following biopsy, there are large spiculated masses and mild edema. Detection of residual mass is not possible with this study, and follow-up was suggested. *C*, Six months later, 8 months after the biopsy, the biopsy site in the outer half of the breast has healed nearly to completion, and there is considerable resolution at the medial site. Postsurgical architectural distortion remains and edema has cleared. *D*, Two years after the biopsy, little evidence of surgical activity is seen.



**Figure 3.** Postoperative scarring. *A*, Postoperative pre-radiation mammogram shows asymmetric area of soft-tissue density and architectural distortion (*arrows*) at the site of excision of an infiltrating ductal carcinoma 4 weeks earlier. *B*, Correlative sonogram demonstrates the shape, depth, and size of the parenchymal scar (*arrows*) in the breast, with a tract (*thin arrow*) connecting it to the thickened skin (*short arrows*) at the incision. A small amount of residual fluid manifested by posterior acoustic enhancement is present in the surgical bed with fibrosis developing in the deeper, irregularly marginated, shadowing portion.

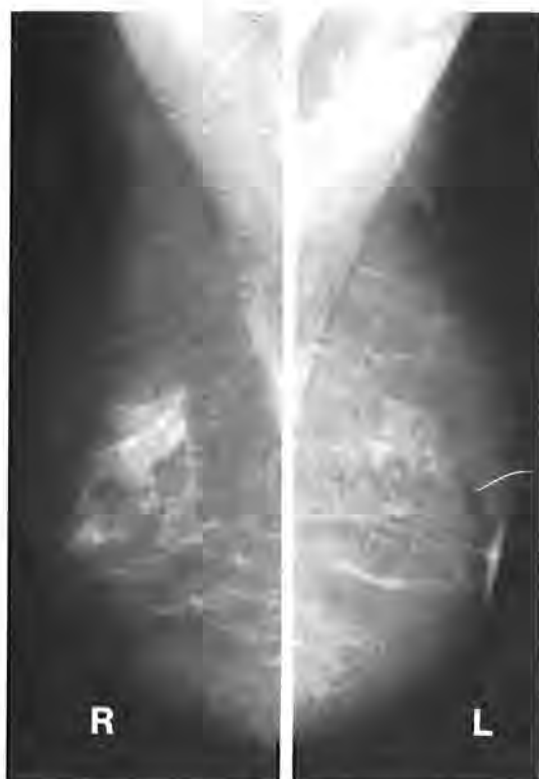

**Figure 4.** Surgical clips demarcating lumpectomy site. Surgical clips outlining the site of tumor removal are useful markers for radiation therapy planning and mammographic followup studies. (Courtesy of David M. Van Hook, MD.)

growth to larger than preoperative dimensions is unlikely within the first year. If there is doubt, sonography is indicated to identify the fluid-filled nature of the mass. Some hematomas have echoes within them initially,<sup>1</sup> but most soon become anechoic. Post-lumpectomy collections show posterior acoustic enhancement. The location, shape, and some marginal irregularity correlate with the surgical excision. Septa may be present and do not signify complications.<sup>56</sup>

Management of a complex mass requires knowledge of the clinical context. Clumps of echogenic material may represent thrombus and abscess formation is uncommon. If the fluid-filled region is not tense or painful and if abscess is not suspected, observation may be preferred to either aspiration or incision and drainage of tissue in which healing mechanisms may be somewhat compromised by radiation therapy.

Postsurgical fluid collections are also seen following benign biopsies. If the specimen radiograph has confirmed removal of the



**Figure 5.** Asymmetric density after benign biopsy. Mediolateral oblique projections of the breasts show an area of soft-tissue density in the right upper breast. After exclusion of a mass with other radiographic projections, the asymmetry is ascribed to removal of similar tissue from the left upper breast during a previous biopsy. For correlation with changes, the biopsy incision is marked by a thin wire taped to the skin. No scarring or architectural distortion remains in the left upper breast after this patient's biopsy.

abnormality and the pathology report does not suggest the need for urgent imaging, the patient will be placed in a routine follow-up category. At 1 year, architectural distortion or a spiculated soft-tissue density representing an evolving scar may be seen. Few post-surgical collections remain 1 year after benign biopsy.<sup>56, 76</sup>

Approximately half of 110 breast cancer patients we studied 4 weeks after lumpectomy and prior to radiation therapy had fluid collections at the surgical site. Most often, their size was 3 to 5 cm in longest dimension, but occasionally collections were larger. In our experience, the sonographic characteristics of cystic lesions are retained much longer than the 2 to 3 weeks reported by Peters<sup>66</sup> and 2 to 8 weeks by Sadowsky.<sup>74</sup> Paulus<sup>51</sup> noted persistence of these fluid accumulations for months and, in some cases, years. Fifty percent of fluid collections we identified

initially were still present at 6 months, with 20% demonstrated at 9 months. Ninety-six percent of fluid collections had lost the ultrasonographic features of cysts by 1 year, and nearly 100% by 18 months.

The percentage of patients with postsurgical fluid collections will undoubtedly reflect the surgical technique. In the group of patients we studied, tumor excision was performed as advocated by Fisher,<sup>29</sup> that is with only subcuticular and skin closures and without drainage of the site. Theoretically, gradual fluid resorption will result in a more normal breast contour, but a few surgeons prefer to aspirate or drain these fluid accumulations briefly. Advantages of evacuation of the fluid would be to accelerate scar formation and minimize the already low incidence of abscess formation at the surgical site. For the radiologist, a hematoma or seroma obscures the surgical bed, and aspiration allows better breast compression and penetration of the lumpectomy site for the mammogram.

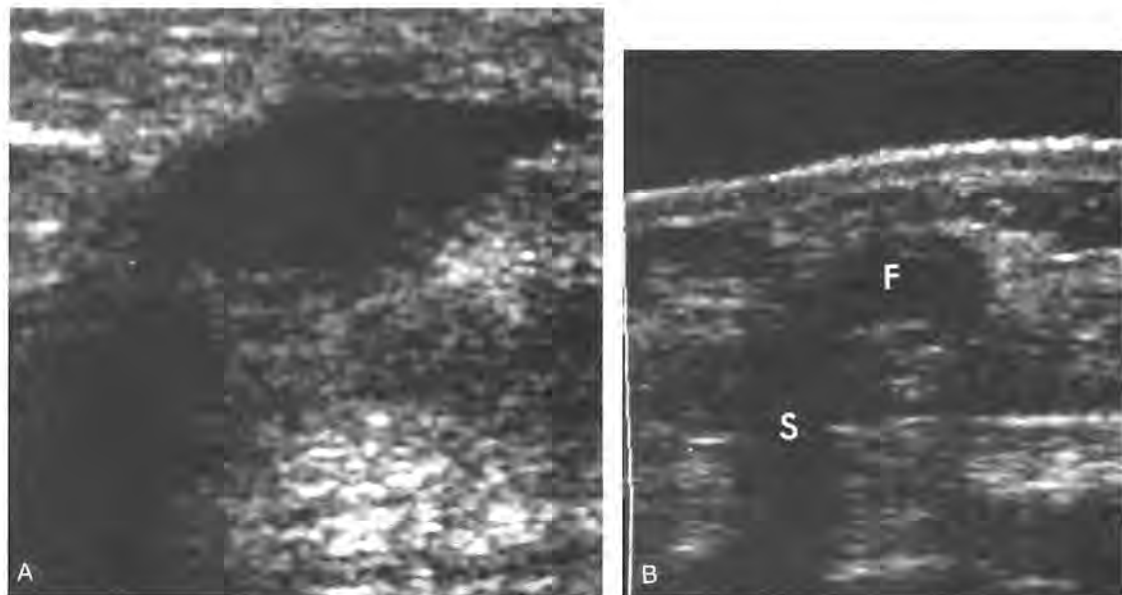
As the lumpectomy site is imaged on follow-up mammograms during the next 6 to 18 months, the discrete, dense, fairly well-margined mass that represents the fluid collection will begin to diminish. As scar formation progresses, areas of radiolucency are seen interspersed with the soft-tissue density. The radiolucencies represent fat entrapped by the developing scar. As fluid is resorbed, the lesion may elongate and become poorly margined and spiculated.

Sonography performed between 6 and 12 months may show a complex mass containing a well-margined residual cystic portion and a component with posterior acoustic shadowing suggesting formation of fibrosis (Fig. 6). When scar evolution is complete, by 12 to 18 months, the cystic areas will no longer be seen.

#### **Asymmetric Soft-Tissue Density with Architectural Distortion or Spiculation**

Thickened skin at the incision should be distinguished from the parenchymal scar of tumor removal. Prominent scarring in the breast develops in more than 95% of patients by the end of the first year after lumpectomy and radiation therapy. Benign biopsy changes often resolve more quickly and completely.<sup>76</sup> Because both scarring and carci-





**Figure 6.** Resolving fluid collection after lumpectomy and radiation therapy. *A*, Small oval fluid collection 6 months after breast conservation therapy. *B*, At 1 year, the skin is still thick. A small residual fluid collection (*F*) is present centrally, and scarring is developing at the periphery where posterior acoustic shadowing (*S*) is seen. Ultimately, an irregular hypoechoic shadowing area will be present.

noma are spiculated, poorly marginated soft-tissue densities, the clinical history, physical examination, and comparison with previous studies are necessary for appropriate management. On physical examination, scarring uncomplicated by fat necrosis is perceived as induration rather than a mass.

Radiolucencies within the central area of soft-tissue density suggest scarring (Fig. 7). This mammographic feature is one of the few found to be helpful by Mitnick.<sup>60</sup> The radiolucencies represent fat trapped by fibrous stranding in the parenchymal scar. Other authors have noted a similar appearance with lack of a central mass in postsurgical scarring, fat necrosis, and in nonencapsulated sclerosing lesions (radial scars) as opposed to most breast carcinomas. Some carcinomas, notably infiltrating lobular, may contain radiolucencies and may not have a central tumor focus.<sup>57, 58</sup>

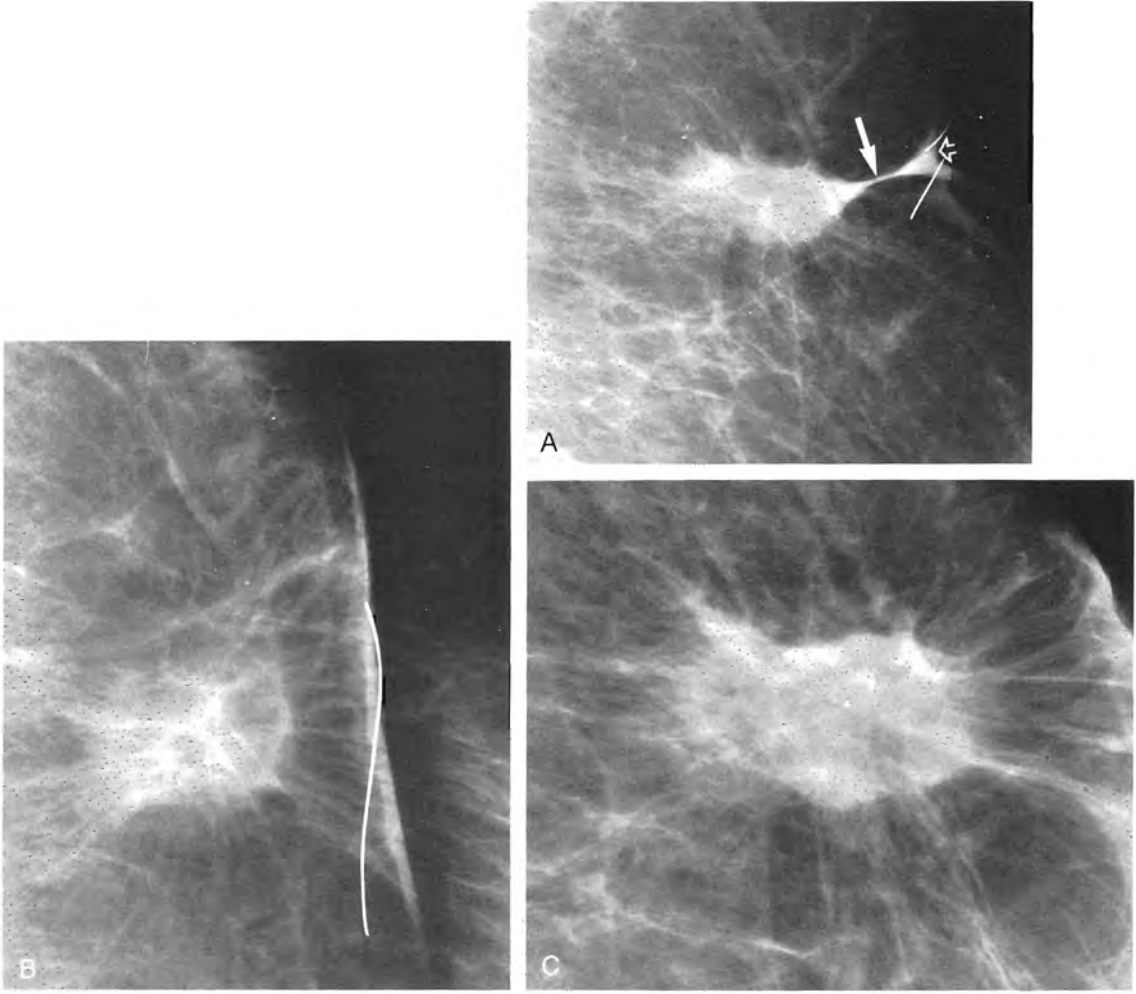
Another finding observed in intramammary scars is a changing appearance in different projections. In one view, the spiculated soft-tissue densities are masslike, but they elongate in other projections. More difficult discriminators to apply, in our experience, are the length, thickness, density, and communication of spicules with the overlying skin (Fig. 8). Wolfe describes spicules of scarring as curvilinear and thicker than the

fine, very straight spiculations of a breast carcinoma that extend directly to the skin and cause retraction.<sup>94</sup>

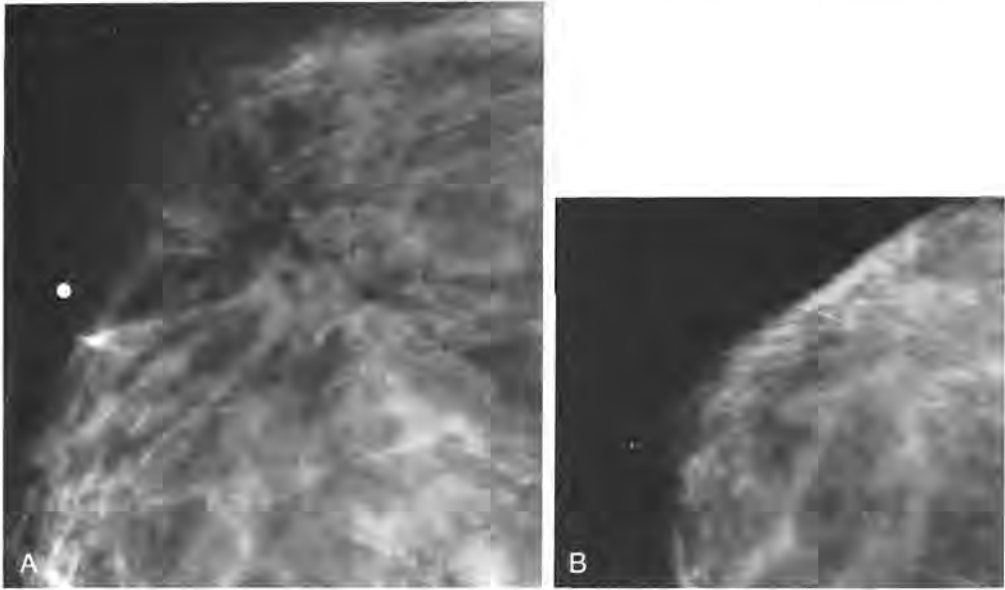
The evolving scar in the breast contracts and shrinks as it matures in the first year or two. The period of change for an individual patient is variable and does not depend on the breast parenchymal type. The size of resection, volume of postsurgical fluid collection, and whether it was drained postsurgically may affect the rate of scar formation. A scar may have formed within 6 months or as late as a year or more after tumor excision and breast irradiation.<sup>56</sup> On sequential studies, decrease in scar size may be barely perceptible or seen in only one projection. After two successive studies have shown no change, recurrent tumor should be suspected if there is increasing size or nodularity at or near the scar. Fine-needle aspiration cytology, core biopsy, or surgical excision may confirm recurrent tumor as the cause of increasing soft-tissue density. A diagnosis of fibrosis, fat necrosis, or granuloma may be more certain with surgical biopsy.

#### *Mammographic Evaluation of the Scar*

Because breast density and architectural distortion cause interpretive uncertainty, the



**Figure 7.** Mature scar 4 years after breast conservation therapy. *A*, Tangential view shows a fibrous bridge connecting the parenchymal scar (*large arrow*) with incision site (*short arrow*) marked by thin wire taped to the skin. *B*, Another projection showing the amorphous scar with thin spiculations and benign calcification. *C*, A third projection showing still another shape of the scar and demonstrating radiolucencies of fat trapped by fibrous tissue with lack of a central mass. Spot compression and magnification are essential in demonstrating features of scarring and excluding recurrent tumor.



**Figure 8.** Scarring versus carcinoma: Nonspecificity of spicule length. *A*, Magnification view of a tubular carcinoma shows central radiolucencies and microcalcifications. Radial scar was also considered preoperatively. Long, thin spicules extend toward the skin, of normal thickness. Radiopaque marker corresponds to a thickening felt by the patient. *B*, Postoperative preradiation study shows patch of soft-tissue density at excision site with thickened skin and very long spicules extending toward the incision. Length, curvature, and thickness of the spicules represent only scarring here but are difficult features to apply in differentiating malignancy from scarring.

standard mediolateral oblique and craniocaudal views require supplementation by additional mammographic projections that demonstrate characteristics of scars. The area of excision should be imaged fully in two projections. Depending upon the location of the tumor, various obliquities can provide this visualization. If the surgical site is near the posterior edge of the compression plate, a small spot compression device will be useful both in fixing the area and in spreading apart the tissue elements (Fig. 9). Magnification radiography of the surgical site should be performed in the projection in which it is seen most completely.

The thickened skin at the incision may be superimposed upon the surgical bed causing masslike increased density, particularly when a keloid has formed. Using a wire taped to the scar as a focus for positioning the patient, a view tangential to the scar permits separation of the skin and parenchymal elements.<sup>45</sup> As discussed, the distinction between scarring of the skin and the surgical bed can be made sonographically as well. At the incision, a band of thickened skin will be seen.

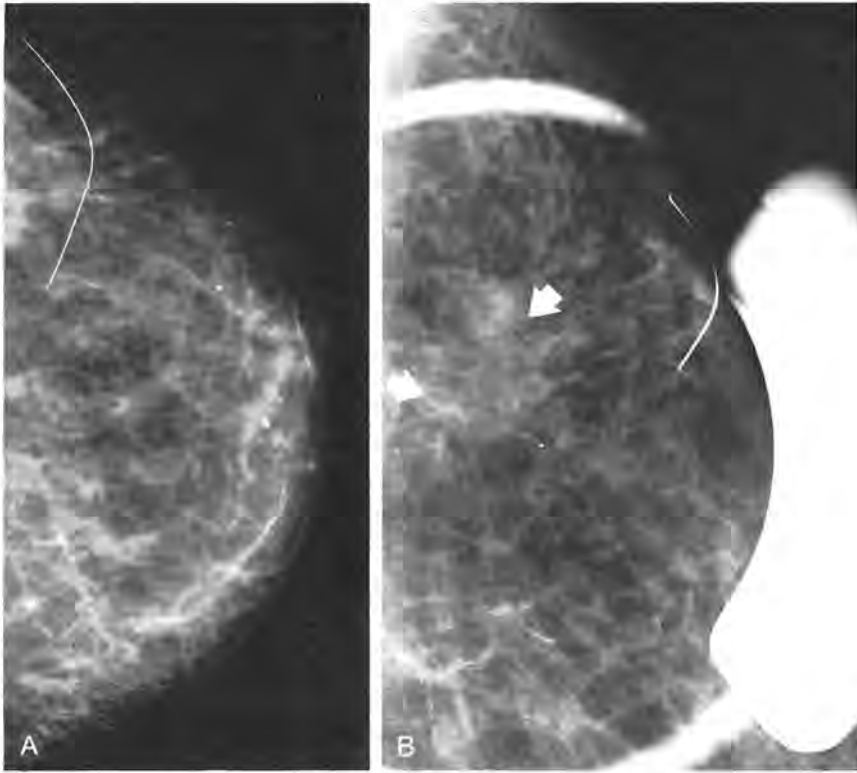
### Increased Breast Density: Breast Edema and Skin Thickening

Increased breast density caused by edema and skin thickening is one of the most striking changes in the mammographic appearance after lumpectomy and breast irradiation.

#### *Breast Edema*

A benign biopsy will cause breast edema in the first month or two, but the mammographic changes are less marked and resolve more rapidly than when the breast has been irradiated. After benign biopsies and lumpectomies for carcinoma prior to radiation therapy, edema is often mild.

Nearly all patients who have had axillary dissection or radiation therapy have breast edema.<sup>8, 37</sup> Moderately severe or marked breast edema may be present on the mammogram requested for the 6-month follow-up evaluation after radiation therapy has commenced. Thickened, stringy linear parenchymal trabeculations are seen when edema is moderately severe. The breast enlarges and mammographic compression is more difficult as edema involves the parenchyma, subcutaneous tissues, and skin. In marked edema,



**Figure 9.** Use of spot compression in postoperative mammography. *A*, Craniocaudal view shows portion of a spiculated nodular soft-tissue density in outer posterior breast where tumor excision (wire taped to skin) had been performed 3 years earlier. It is impossible to exclude recurrent tumor. *B*, Spot compression film separates the parenchymal elements more completely, is able to engage the posterior tissue better than the larger plates, and demonstrates radiolucencies within the scar (arrows). Recurrent tumor was excluded with confidence.

the breast is homogeneously dense and white (Fig. 10). Outlined by subcutaneous fat, linear densities representing engorged lymphatics and interstitial fluid collections extend toward the skin, which is thickened. These changes are most evident in the periareolar and dependent areas of the breast.<sup>13</sup>

Breast edema gradually diminishes and resolves for many patients within 2 years. Mild edema persists in a small percentage of patients and is seen radiographically as coarsened linear interstitial elements.<sup>15, 52</sup> In one study, 20% of women had edema lasting more than 3 years, slowly resolving between 4 and 8 years after irradiation.<sup>37</sup> The breast's lymphatic drainage is toward and through the axilla, and a cause of prolonged edema may be the interruption of lymphatic drainage in the axilla after extensive axillary dissection.

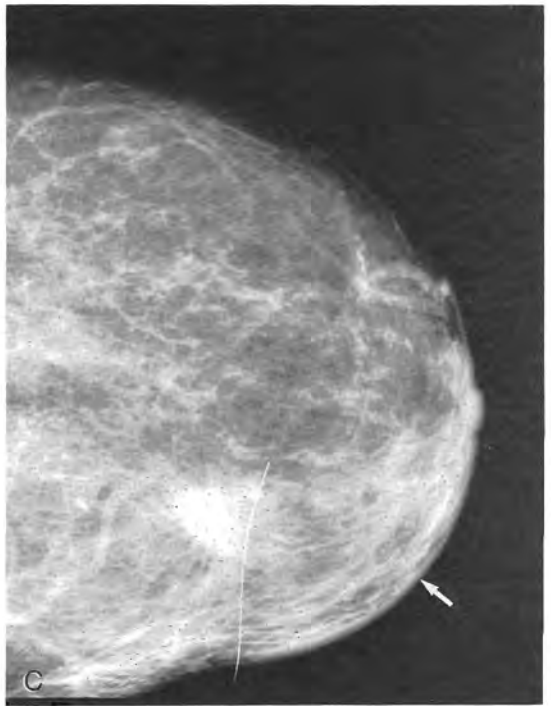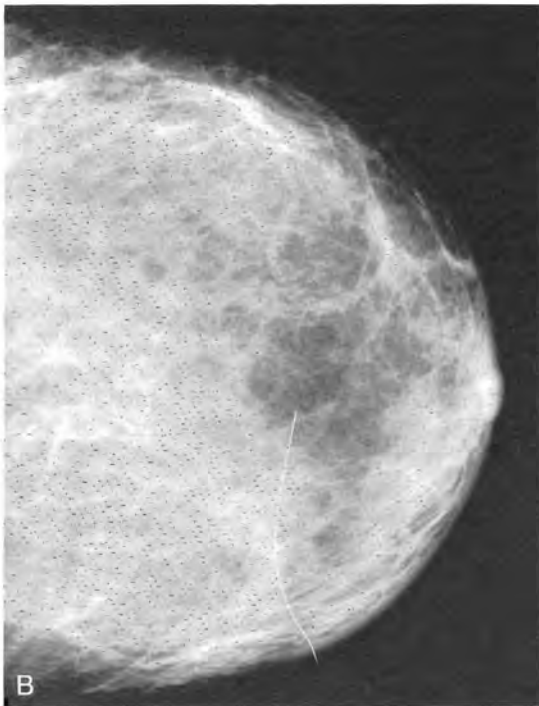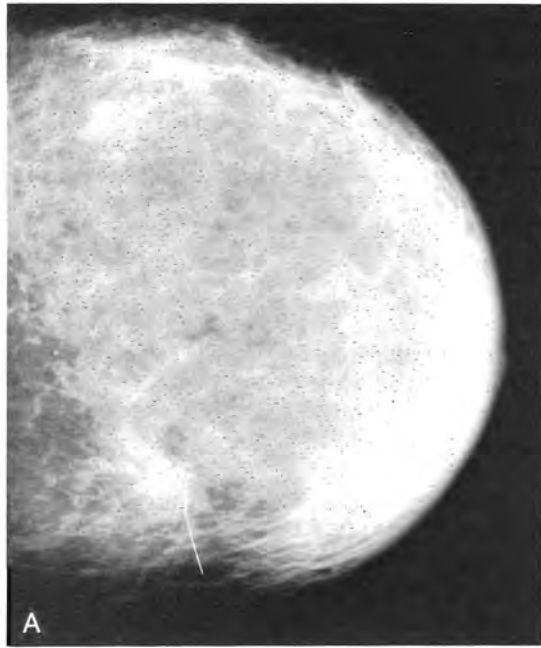
After breast density has stabilized, recurrent edema is cause for concern. A small percentage of patients will develop infection postoperatively and after radiation therapy.

Congestive heart failure and recurrent carcinoma require exclusion. Although a new mass or microcalcifications are more common presentations of recurrent tumor, the reappearance of breast edema can represent lymphatic dissemination of breast carcinoma, which requires a different therapeutic management.

As edema recedes, the breast size also normalizes. After several years, the irradiated breast may become progressively smaller and somewhat denser because of radiation fibrosis.<sup>61</sup>

#### *Skin Thickening*

Skin thickening and breast edema are companion findings that have similar time courses for maximal change and resolution after lumpectomy and breast irradiation. The skin of the breast is ordinarily less than 0.2 cm thick, but it is slightly thicker in the lower breast near the inframammary fold and around the nipple. After radiation therapy,



**Figure 10.** Breast edema and skin thickening. *A*, Six months after lumpectomy and radiation therapy, craniocaudal view shows marked edema of the breast parenchyma and skin, particularly in the anterior half and periareolar region. Tumor excision site in the medial breast is marked by a wire taped to the skin. *B*, One year after breast conservation therapy, moderate edema remains with stringy interstitial densities and periareolar skin thickening. Although edema still obscures visualization of the fibroglandular tissue in this predominantly fatty breast, the lumpectomy site is better visualized. *C*, Craniocaudal view of the same patient 1 year later (2 years after initial treatment) shows progressive contraction and spiculation of the scar and continued resolution of edema. Mild-to-moderate edema persists, and the periareolar and medial skin thickening is unchanged or minimally diminished (arrow).

the skin's thickness may reach 1 cm or even greater (Fig. 10A) in the periareolar region.<sup>56</sup> As in parenchymal edema, skin edema clears last in the periareolar area and dependent portion of the breast. By 2 to 3 years after breast conservation therapy, the skin has returned to near-normal thickness, although mild thickening persists in approximately 30% of the patients.<sup>52</sup>

### Imaging Evaluation of Increased Breast Density

Increased breast density, a reticular pattern, and measurable thickness of the skin are easily recognized mammographic signs of skin thickening and edema, particularly if only one breast is affected. Using a bright light to illuminate the skin line on high contrast film-screen studies will ensure that a focal area of skin thickening or subcutaneous abnormality will be noticed. Breast edema and skin thickening also can be assessed with ultrasonography (Fig. 11). An offset pad or built-in standoff should be used to bring the skin and superficial tissues into the transducer's focal zone.

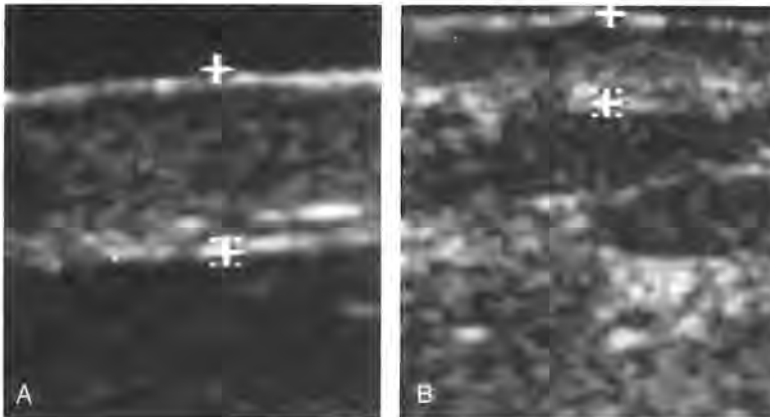
The 0.2-cm-thick skin complex is comprised of two thin echogenic lines with a hypoechoic dermis between them.<sup>56</sup> As interstitial fluid seeps through the tissues during the first year after radiation therapy, the deeper of the two lines becomes interrupted. Curved arcs are seen extending through the subcutaneous fat to the thickened skin on the mammogram, and interstitial fluid is imaged sonographically as linear collections in nonductal distribution extending toward the skin.<sup>56</sup> As edema diminishes, the deeper line resumes continuity. After radiation therapy or with any process that causes edema, the

dermis will be more echogenic, which reflects fluid accumulation and fibrosis. Because sonography is recommended for evaluation of postoperative masses and fluid collections, it is important that the sonographic appearance of the entire region including the skin and tracts from the surgical bed to the skin's scar be recognized as well.

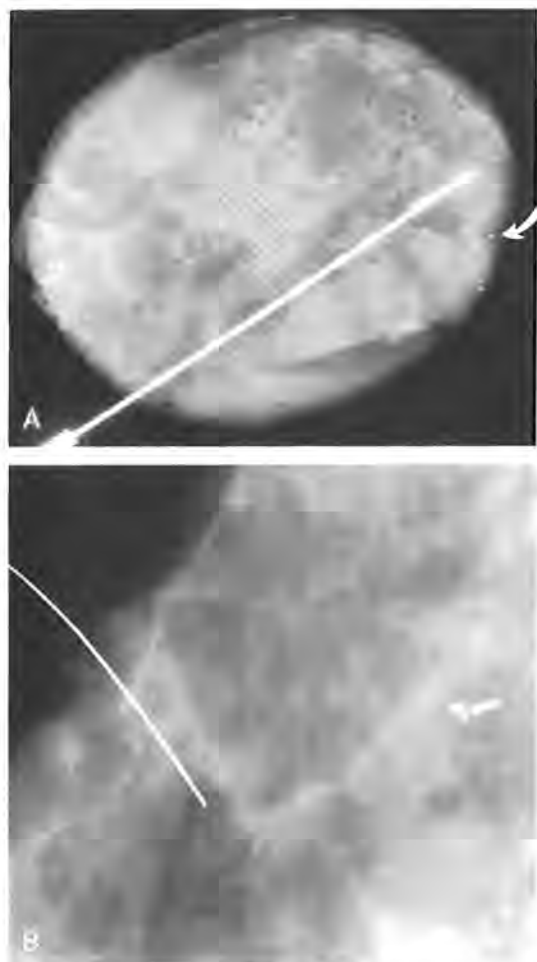
### Calcifications

Calcifications are a most important marker of new or recurrent breast carcinoma. Forty-three percent of mammographically detected recurrences were manifested by calcifications.<sup>87</sup> In evaluating calcifications at the lumpectomy site, radiologists should apply the same morphologic and distributional features used preoperatively to rate the probability of malignancy. Postoperative preradiation magnification radiography should be performed to detect residual calcifications at the tumor excision site (Fig. 12).<sup>73</sup> The surgical bed ordinarily will be reexcised if microcalcifications remain.<sup>41, 80</sup> Mammographic localization may be necessary, and the specimen should be radiographed. The surgical procedure is easier to accomplish, with fewer sequelae, if it is performed before breast irradiation.

It is common for new calcifications to occur at the site of tumor excision in conservatively treated breast cancer patients. New calcifications were found within 6 to 12 months in 28% of 110 patients treated with breast conservation therapy whom we studied.<sup>56</sup> Although some calcifications appeared within 6 months, in many patients additional calcifications were seen over a period of 3 to 4 years. In unpublished data, Paulus found that 20% to 25% of 450 irradiated breasts



**Figure 11.** Skin thickening: sonography. *A*, Six months after tumor excision and irradiation, magnified sonogram (7.5 MHz with offset pad) demonstrates skin thickening to 1 cm. *B*, Follow-up sonogram 6 months later shows decrease in skin thickening. Skin measures 0.5 cm thick. Cursors denote the superficial and deep echogenic lines of the skin complex. Between them is the dermis, more echogenic than seen normally, suggestive of edema or fibrosis.



**Figure 12.** Residual carcinoma. *A*, Compressed, magnified view of specimen. Near the tip of the localization hookwire is a stiffening cannula placed over it at surgery to facilitate its palpation intraoperatively. Microcalcifications are at the margin (*arrow*) of the resected tissue. After comparing the specimen radiograph with the mammogram, the surgeon, still in the operating room, was advised to remove additional tissue, but no further specimens were received for radiography. *B*, Postoperative preradiation magnification view of the scar in mediolateral oblique projection shows wire taped to the linear scar. More posteriorly, an area of vague soft-tissue density with microcalcifications (*arrow*) represented residual comedo-carcinoma in the surgical bed. The microcalcifications were relocalized and removed.

developed benign appearing calcifications.<sup>65</sup> Libshitz, studying a smaller group of patients undergoing tumor excision and radiation therapy, noted that 14% of 81 patients developed benign calcifications during a wide-ranging period of 2 to 44 months.<sup>31</sup>

Several types of benign calcifications are found at the lumpectomy site. Although they will coarsen later, calcifications may be quite

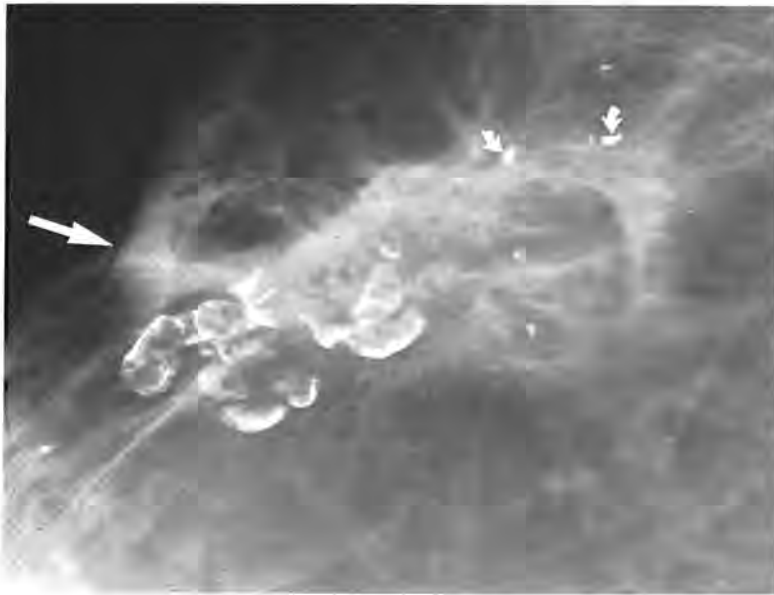fine, faint, and difficult to characterize as they begin to precipitate in scars, necrotic tissue, or areas of fat necrosis. Most studies assign a low probability of malignancy to calcifications that occur soon (6–18 months) after the surgery and radiation therapy.<sup>40</sup> In Rebner's small patient group, there was considerable overlap, and new malignant microcalcifications antedated benign calcifications at the lumpectomy site.<sup>67</sup> Although the time course may not always be reliable, it serves as a reasonable guide to interpretation of alterations in mammographic appearance, with early changes often being benign.

Fat necrosis is associated with all types of surgical procedures in the breast. In vague, patchy soft-tissue densities, calcifications may be needlelike, of varied shapes, bizarre, disorganized appearing, and alarming. These dystrophic calcifications will become thick, calcified plaques. Common expressions of fat necrosis are thin arcs of calcification, which may form complete circles to define the rims of rounded, radiolucent oil cysts.<sup>6</sup> Oil cysts, fibrous tissue, and calcifications may form calcifying conglomerations of tissue presenting as palpable masses on physical examination. Radiographically, the radiolucent centers of these heterogeneous masses will suggest their benign postoperative etiologies (Fig. 13) thus leading to a recommendation for follow-up evaluation rather than biopsy. The physical findings, however, may be worrisome enough to prompt rebiopsy.

Developing unilaterally after tumor excision and radiation therapy, small, round, and smooth dystrophic calcifications are common at the lumpectomy site. They resemble the calcifications of secretory disease or ductal ectasia and may have a similar pathogenesis, forming in areas of necrotic tissue, sloughed cells, and cellular detritus.<sup>37</sup> Paulus found calcifications of this type in 20% to 25% of mammograms of conservatively treated breast cancer patients that he reviewed.<sup>65</sup> As new unilateral calcifications in the treated breast, a causal relationship is inferred between the procedures and the occurrence of the calcifications.

Also benign appearing and somewhat less common are more coarse, plaquelike, angular calcifications. These larger calcifications are also dystrophic, developing in scars and in the disturbed subcutaneous tissue beneath the incision. Views tangential to the skin can demonstrate their superficial locations.

Calcified remnants of suture material at




**Figure 13.** Calcifications at the tumor excision site: fat necrosis. Three years after tumor excision and irradiation, the parenchymal scar contains radiolucencies, and curved spicules extend to the thickened skin of the incision (arrow). A cluster of calcifying oil cysts indicative of fat necrosis is present. Other benign calcifications, dystrophic, are seen at the site (short arrows).

the lumpectomy site have distinctive shapes (Fig. 14). Knots, branching linear calcifications, and double tracking may suggest malignancy, but these linear calcifications can be several millimeters long and quite wide. They resemble the thick linear calcifications of ductal ectasia or secretory disease.<sup>45, 71, 95</sup> Davis suggests that magnification radiography of the lumpectomy site will remove any hesitancy in calling them benign.<sup>19</sup> They do not require biopsy. Although sutural calcifications are relatively rare, encountered in the mammograms of 3 of 110 patients we studied, once having been recognized, they will subsequently be an "Aunt Minnie."

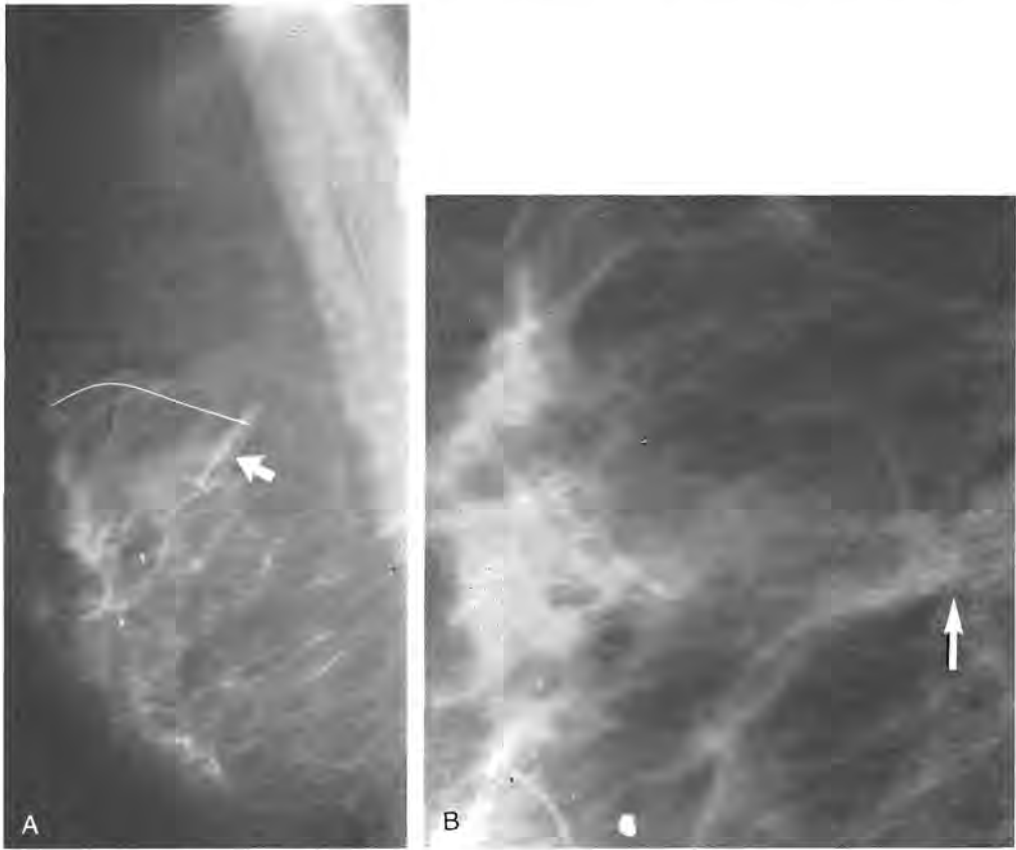
Microcalcifications are the most common radiographic sign of recurrent tumor, with 43% of mammographically detected recurrences presenting in this fashion in Stomper's

series.<sup>87</sup> Mammographic analysis is made more difficult by the increased soft-tissue density and architectural distortion of the parenchymal scar and possible confusion with benign calcifications at the excision site. At the outset, benign forms of calcification should be excluded and an active search, with magnification radiography, made for new indeterminate or malignant-appearing calcifications (Fig. 15). Rebner cautions that there is overlap in appearances and recommends that unless the calcifications are unequivocally benign, they be biopsied.<sup>67</sup> Twenty-seven (18%) of 152 patients developed calcifications. Of those, 10 patients had malignant or indeterminate calcifications and had biopsies (7%). Four biopsies of microcalcifications were positive for malignancy in a period of 6 to 32 months. In 75%, tumor had



**Figure 14.** Sutural calcifications. Magnification view of lumpectomy site 4 years after tumor excision and radiation therapy for infiltrating ductal carcinoma shows coarse calcifications, unchanged from their appearance 1 year earlier. Wishbone-shaped strands joined by a knot (arrow) are seen at one end of the thin wire marking the scar. Another linear calcification (curved arrow) with a knot in its midportion also suggests clipped suture material. Additional benign calcifications may represent suture material, other dystrophic calcification, or fat necrosis.





**Figure 15.** Tumor recurrence: microcalcifications. *A*, Five years after lumpectomy and radiation therapy for infiltrating ductal carcinoma, no mass is identified at the lumpectomy site. On this unmagnified view, faint new microcalcifications were seen at the posterior aspect of the scar (arrow). *B*, Lateral spot compression magnification view of the tumor excision site shows architectural distortion and a linear soft-tissue density containing numerous, pleomorphic microcalcifications (arrow) that represent a new focus of ductal carcinoma in situ.

presented initially with microcalcifications. Although Rebner's numbers are small, they emphasize the need for a high degree of vigilance in follow-up studies of the lumpectomy site, particularly when the tumor has presented as microcalcifications.

Another study makes a similar point.<sup>81</sup> With an overall positive biopsy rate of 52% for recurrent tumor (in the location of the primary or in other quadrants), 21% of 145 biopsies were performed for microcalcifications seen on the mammogram without associated physical findings. Of this group, 66% were positive, a much higher percentage after breast conservation than for patients recommended for biopsy of microcalcifications after routine screening mammography.

In summary, most newly occurring calcifications in the treated breast are benign. Residual microcalcifications should be excluded prior to radiation therapy. Unexcised calcifications may or may not disappear after ra-

diation therapy, and their persistence does not necessarily indicate viable tumor.<sup>51</sup> The expectation of recurrence will be higher after excision of invasive carcinoma with extensive intraductal carcinoma or with large areas of comedocarcinoma.<sup>37</sup> Accuracy of interpretation will be furthered by familiarity with the clinical background, careful review of sequential studies, and magnification radiography of the lumpectomy site and other areas where calcifications are suspected.<sup>73</sup>

#### **RECURRENT TUMOR: EFFECTIVENESS OF IMAGING**

Berenberg states that edema, fibrosis, and architectural changes may make mammography less conclusive after breast conservation therapy, but he notes that in six local recurrences found in 126 cases (4.8%), the mammogram alone was positive in four of

the six.<sup>7</sup> The other two recurrences were detected through physical findings, not mammography. The data of Stomper are similar: 35% of 45 recurrent carcinomas after lumpectomy and radiation therapy were detected only by mammography and 61% of tumor recurrences were identified through mammography with the addition of clinical findings.<sup>87</sup> Berenberg's, Stomper's, and other studies<sup>34, 40</sup> support the conclusion that mammography is an effective technique for follow-up evaluation of these patients but that mammography requires complementation with physical examination to maximize detection of recurrent tumor. Similar results and conclusions are offered by Fowble, whose group reported on 66 tumor recurrences after breast conservation therapy in which there was mammographic detection exclusively in 29% (13/19 presenting with microcalcifications without a mass) and physical examination alone in 50% (11/65 did not have mammography, however, at the time the recurrent tumor was diagnosed) and with both in 21%.<sup>32</sup> In all of these studies, microcalcifications were found to be a major sign of recurrent tumor that cannot be identified by physical examination and requires mammography.

Of the imaging techniques, mammography has been studied the longest, and its limitations in the densely fibroglandular, early postoperative, edematous breast are accepted. Second in frequency of use, with specific applications to the management of breast disease, is ultrasonography. Microcalcifications are the most frequent indicator of recurrent tumor, and ultrasonography demonstrates microcalcifications poorly.<sup>20, 28, 47</sup> Sonography cannot be substituted for primary evaluation of the breast before or after surgery.

In our practice, ultrasonography has been useful in the follow-up evaluation of the conservatively treated breast cancer patient. In serial mammographic 6-month follow-up studies of 110 patients for at least 3 years, postoperative masses in the first year were identified unequivocally as fluid collections in 40.5% of patients.<sup>56</sup> Recurrent tumor at or within 2 cm of the lumpectomy site was subsequently detected in 6% of these treated breasts, the earliest at 30 months. Three masses without calcifications and one with calcifications were detected with mammography, with the masses also being demonstrable sonographically and distinct from the scars (Fig. 16). New microcalcifications iden-

tified 48 months after lumpectomy and radiation therapy were not imaged, even with knowledge of their precise location, by ultrasonography. One suspicious palpable mass not detected mammographically was seen with ultrasonography. Several palpable masses with a sonographic appearance consistent with either fat necrosis and scarring or recurrent tumor and no mammographic change represented fat necrosis on biopsy.

Without specifying the presentation of tumor recurrences, Balu-Maestro and her group in France found that mammography and sonography allowed high detection rates of tumor recurrences.<sup>4</sup> Ninety-five and one half percent of tumor recurrences were identified mammographically and 90.9% by ultrasonography. Only 45.5% were detected by physical examination.<sup>4</sup> In no instance did sonography alter the management plan for biopsy or follow-up study that was determined by physical or mammographic findings.

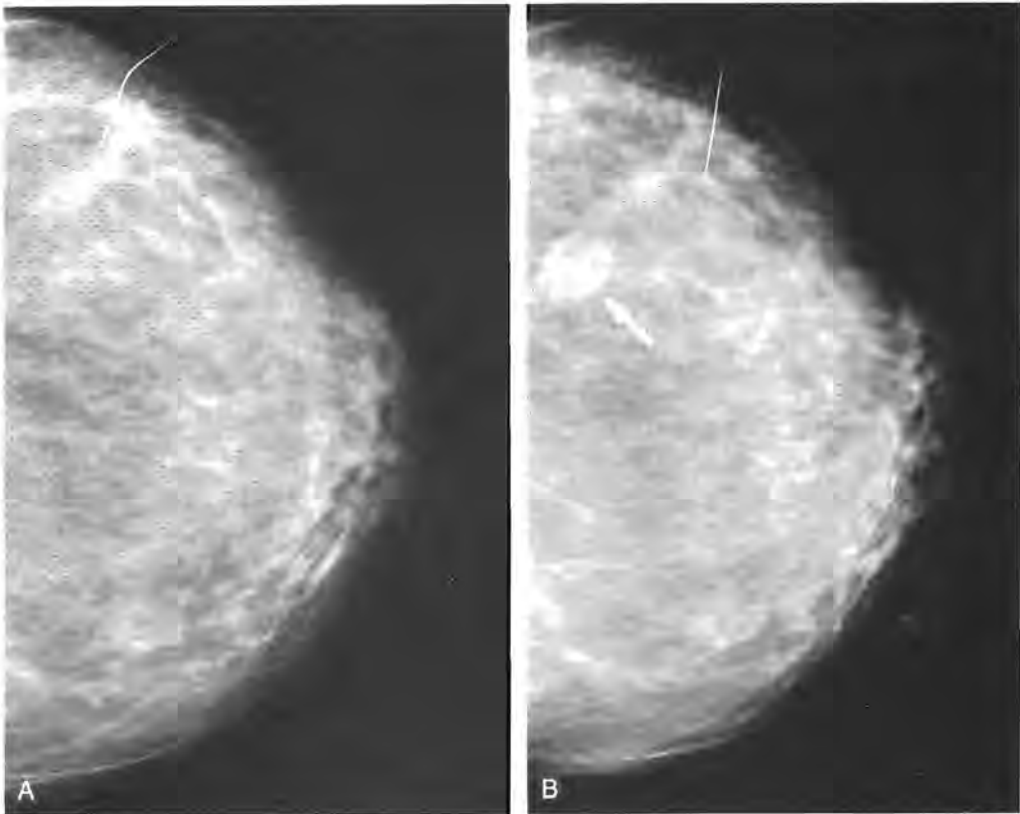
Nevertheless, sonography is an excellent supplemental technique, and familiarity with the sonographic appearances of findings after tumor excision and radiation therapy is necessary to avoid misinterpretation. In the postoperative breast, sonography can be used to characterize a mammographic or palpable mass as fluid-filled or solid, to guide interventional procedures, and as an alternate method of imaging sequential changes such as skin thickening.

Gadolinium-enhanced MR imaging is under investigation for distinguishing mature scarring from recurrent tumor at the lumpectomy site.<sup>43-44</sup> Theoretically, a seasoned area of postsurgical change would not show gadolinium uptake, but an active area of tumor growth might. Sensitivity, specificity, and possible indications for this technique have not yet been established.

For postprocedural findings at the lumpectomy site, pulsed Doppler and the more sensitive color flow imaging have proved disappointing, adding no useful diagnostic information apart from that provided by mammography and standard sonography.<sup>11</sup> Cosgrove, investigating usefulness of color flow Doppler in breast masses, found no abnormal vascularity in five of seven locally recurrent breast malignancies.<sup>18</sup>

#### PROTOCOLS FOR FOLLOW-UP IMAGING AFTER BREAST CONSERVATION THERAPY

There is considerable geographic variation within the United States in the treatment of



**Figure 16.** Recurrent tumor: mass. *A*, Two years after breast conservation therapy, minimal breast edema is present. The lumpectomy site in the outer aspect of the breast on this craniocaudal projection appears linear and spiculated. *B*, One year later, a new mass (arrow) is present posteromedial to the scar, representing recurrent infiltrating ductal carcinoma.

breast cancer. Tumors of the same stage and size may be treated altogether differently depending on the philosophy in a given locale. On the two coasts, the majority of breast cancer patients may be treated with wide excision and irradiation, but in some areas up to two thirds of women eligible for breast conservation are not being offered this option.<sup>72</sup> Somewhat dependent on the prevailing surgical practices, there is also wide variation in experience with the radiologic follow-up evaluation of these patients. Currently, beyond the first year after therapy, no guidelines have been adopted for intervals between follow-up studies, although many recommendations have appeared in the literature.<sup>40, 64, 65, 75</sup>

To determine an appropriate schedule of studies, the purposes of imaging the conservatively treated breast must be clearly stated. Two major objectives are (1) early diagnosis of recurrence, prior to development of metastases,<sup>81</sup> and (2) minimizing misinterpretations of postprocedural change as tumor

recurrence (high positive predictive value when rebiopsy is suggested). Achievement of these objectives will be facilitated by familiarity with timing of tumor recurrence and the sequential postoperative and irradiation changes that are anticipated: masses and fluid collections, scarring and architectural distortion, edema and skin thickening, and calcifications. In Table 1, results of our ongoing study of these findings are summarized.

The treated breast is a rapidly changing organ, with changes as dramatic as those seen at puberty. Following lumpectomy and radiation therapy, the mammogram will portray the magnitude of the assault required to control the disease process. Later, the mammogram will depict the resilience of mammary tissue as the breast returns to a more normal appearance. On the basis of radiographic evolution (progression) or resolution of changes, several periods are defined (Fig. 17).

The period of greatest change occupies the

first 18 months, with the most marked changes occurring around 6 months.<sup>40</sup> If the margins of resection have been free of tumor and the breast has been irradiated, recurrent tumor is unlikely to explain a large masslike density on the mammogram (Fig. 18).

Perhaps the most important period is stabilization of the breast, which we have defined as lack of change on two successive mammograms. Subsequently, a change counter to the direction of resolution would suggest recurrent tumor. In an individual patient, selection of the appropriate follow-up interval for mammography depends on determination of stability. Many proposals for the time of stabilization have been offered. For Berenberg,<sup>7</sup> the conservatively treated breast is stable at 4 months, for Stomper<sup>86</sup> at 3 to 6 months, and for Paulus,<sup>65</sup> 6 to 8 months. The term *stable* is not defined, and no criteria for establishing this milestone are specified. Differences might be explained by variations in surgical procedures such as size of resection or drainage of the lumpectomy site, the radiation dose, and in the definition stability.

There is agreement that mammography at 6 and 12 months after tumor excision will record the greatest changes in the postprocedural breast. Beyond the 1-year study, various schedules have been proposed for follow-up mammograms. Most authors have supported studies every 6 months after the first year for some period of time.<sup>40, 56, 73, 74</sup> Sickles comments that he reevaluates his lumpectomy and radiation therapy patients every 6 months for a "few years."<sup>77</sup> Cady advocates 6-month follow-up studies for 2 years.<sup>16</sup> Rebner calls for mammography at 6-month intervals for the first 2 years, then annually for the treated breast and the contralateral breast, which is also at increased risk of carcinoma.<sup>15, 54, 67</sup> The recommendations of Paulus are for mammograms to be performed after the initial 6-month study either annually or at 6- to 9-month intervals for several years.<sup>64, 65</sup> Hassell, reporting on rebiopsies of 48 conservatively treated breast cancer patients, suggests that more frequent follow-up evaluation in the first several years might help reduce false-positive interpretations of recurrent tumor at the lumpectomy site, particularly during the early period when biopsies of this area are most often benign.<sup>40</sup> Although she states that the number of recurrences in her continuing study is too small to suggest general guidelines, she

notes that patients whose recurrences were diagnosed mammographically fared better than those who presented clinically, and she argues for close interval follow-up evaluation. Her Vancouver group advocates mammography at intervals of 6 months for 3 years, then annually.

Our recommendations for imaging after breast conservation therapy are similar to Hassell's and are shown in Table 2. Until 1988, when we extended to 5 years the period in which we performed mammography at 6-month intervals, we requested mammograms at 6-month intervals for 2 years with annual examinations after that. We currently propose studies every 6 months for 3 years to cover the 1 to 3 year period of stabilization as much to avoid unnecessary biopsies of postprocedural benign changes as to diagnose recurrent tumor.

The achievement of stability coincides with the time that recurrences begin to appear, which is 2 to 3 years after conservation therapy. A new mass, microcalcifications, or architectural distortion at the lumpectomy site may be more easily recognized as an interval change when the breast is stable, and after 3 years, an annual study may be sufficient for most patients. Women treated with tumor

**Table 1. FOLLOW-UP AFTER BREAST CONSERVATION THERAPY: MAMMOGRAPHIC FINDINGS IN 110 PATIENTS**

Findings	% of Total Patients	Time Period
Calcifications	52	75% by 18 mo.
Mass or scarring	100	by 2-3 y
Postoperative fluid collections (US confirmation)	40	at 6 mo
Spiculated densities and architectural distortion	60	at 6 mo
Breast edema (mild, moderate, marked)	100	6-12 mo
moderate to marked	72	6-12 mo
moderate to mild	gradual decrease	12-18 mo
resolution	60	2 y
Skin thickening		
range: 0.4-1.0 cm (average)	100	6-12 mo
50% reduction	50	18-24 mo
Recurrent tumor	5.5	30-48 mo
Masses detected	3	
mammographically		
New calcifications	1	
Calcifications and mass	1	
Palpable mass	1	

## CHANGING APPEARANCE OF THE CONSERVATIVELY-TREATED BREAST

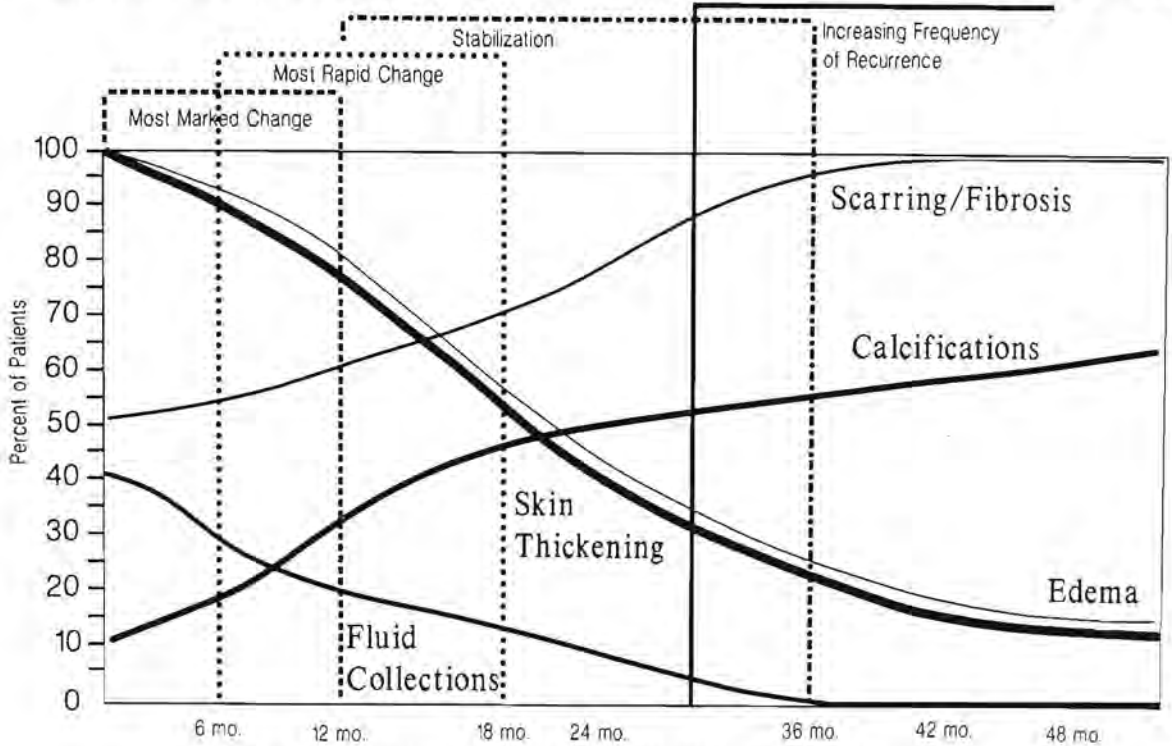


Figure 17. Changing appearance of the conservatively treated breast.

excision and irradiation who have a known increased risk of recurrence, as in infiltrating carcinoma with an extensive intraductal component,<sup>37</sup> might benefit from increased mammographic vigilance through continuation of the studies every 6 months of the treated breast.

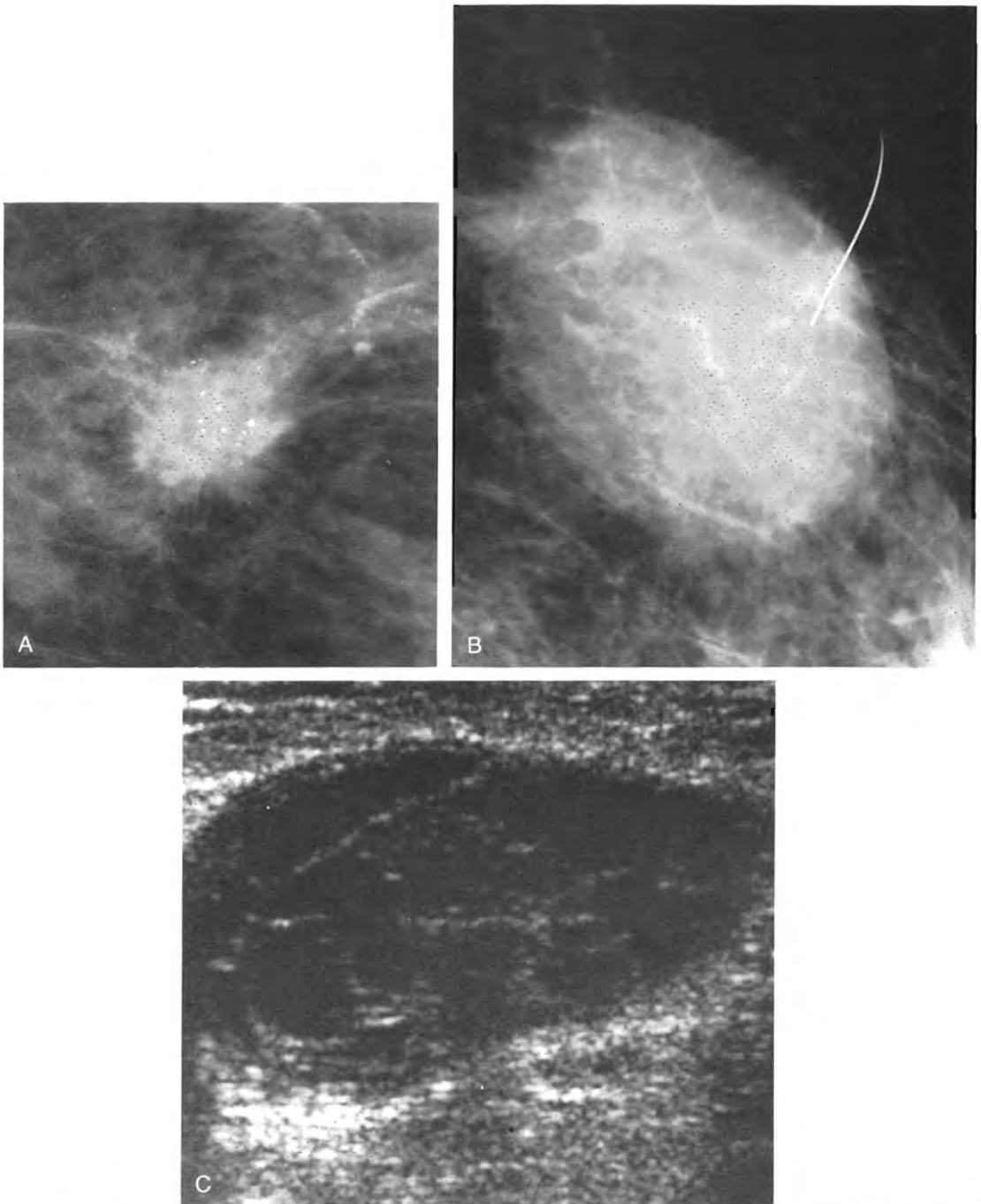
### IMAGING AFTER MASTECTOMY

Until the 1970s, the radical mastectomy was the surgical procedure of choice for treatment of breast cancer in the United States. Removed en bloc are the breast, skin over the tumor, both the pectoralis major and minor muscles, and the axillary contents.<sup>19, 49</sup> Although the radical mastectomy remains an option for patients with bulky tumors involving the pectoralis major muscle or fascia, the modified radical mastectomy has become the more common surgical procedure.<sup>13, 49</sup> Patients with Stage I to III tumors not fixed to the pectoralis major muscle by axillary lymph nodes are candidates for modified radical mastectomy, which has a number of variants.

In general, the breast tissue and pectoralis major muscle are removed with a generous ellipse of skin overlying the tumor. The area of incision extends to the axilla, which is completely or partially dissected. Modified radical mastectomy offers disease-free survival equivalent to that of radical mastectomy with better cosmetic result. In addition, reconstruction is easier to accomplish if the pectoralis major muscle is preserved.

Mastectomy should leave no breast tissue for mammographic evaluation, and ipsilateral axillary dissection removes nodal sites of potential spread. Recurrent local breast carcinoma in more than 50% of cases involves the chest wall or overlying skin.<sup>70</sup> Recurrent tumor is frequently detected in physical examination, and CT can be used to evaluate its extent.

Should the axilla on the side of mastectomy be imaged? No studies in the literature support its use in the patient who has had an axillary dissection. Wolfe suggests a lateral view of the axilla for breast cancer patients who have not undergone axillary lymphadenectomy or for patients with complaints referable to the axilla.<sup>93</sup>



**Figure 18.** Mass at the site of tumor excision. *A*, Preoperative magnification view shows a spiculated mass with microcalcifications. *B*, The infiltrating ductal carcinoma was resected and radiation therapy performed. The site of excision is marked with a wire taped to the skin. One year later, a large oval soft-tissue density is seen with some stranding in its posterosuperior margin. Recurrent tumor of this size is unlikely, especially in the first year after treatment. *C*, Sonogram shows a well-defined hypoechoic mass with septa and locules, a solidified postoperative hematoma that will be very slow to resolve. Mass was firm, and there were no signs of infection.

**Table 2. IMAGING AFTER BREAST CONSERVATION THERAPY**

Timing of the Study Treated Breast	Rationale
Postoperative preradiation (2-5 w after lumpectomy)	Detection of residual carcinoma
6 mo	Baseline study Peak of postprocedural changes: masses, skin thickening, edema. Early calcifications form.
12 mo	Assess changes listed above; begin to look for mammographic stability (no change on 2 successive studies)
18 mo	End of time of most rapid change; confirm stability
24 mo	Expect stabilization for most patients. More confident recognition of benign postprocedural changes.
30 mo	Mammogram should be stable for nearly all patients.
36 mo	Stable mammogram. Suspect recurrence if direction of change is unexpected.
Annually	Detect recurrence. For patients at increased risk of recurrence (EIC and young patients), consider intervals of 6 months.
Contralateral breast Annually	Screening; increased risk of breast carcinoma

The lateral view of the axilla is obtained without compression, with the molybdenum filter of the mammographic unit replaced by one of aluminum, using a higher kilovoltage and milliamperage than are used to image the breast.

In our practice, for the last 3 years, we have not imaged the axilla routinely on the side of mastectomy and axillary dissection. Prior to that, between 1985 and 1988, the only abnormality seen was bone metastases already identified in a symptomatic patient. In personal communications with colleagues, many agree that the lateral axillary view is noncontributory and have eliminated it from their routine imaging of patients with mastectomies who are asymptomatic or have unchanged arm edema. For women who

have masses, pain, or other complaints referable to the axilla, the view can be retained. In some instances, a mammogram will be reassuring to the patient in showing that asymmetric lumpiness at the operative site is fatty redundant tissue.

Mammographic study of the contralateral breast can be performed according to screening guidelines or as indicated by clinical and radiographic considerations. In assessing the remaining breast, the radiologist should be aware of the histology of the carcinoma, its incidence of bilaterality, and presence of additional indicators of risk for breast carcinoma such as lobular carcinoma in situ (lobular neoplasia) that may increase the likelihood of malignancy.

## IMAGING AFTER COSMETIC SURGERY

### Breast Reconstruction

The diagnosis of breast cancer inflicts psychological trauma. Breast reconstruction may provide some restoration of body self-image after mastectomy. Pros and cons of breast reconstruction and several methods of accomplishing it are presented to the patient as therapy is discussed. Breast reconstruction should meet reasonable cosmetic expectations without compromising oncologic control and management.<sup>14</sup>

Reconstructive surgery can be performed immediately, months, or years after the mastectomy. There are two types of breast reconstruction procedures: implants or autogenous tissue transfer (myocutaneous flaps or free flaps attached with microvascular technique). At times a combination of both may be used with reduction, augmentation, or mastopexy of the contralateral breast to achieve symmetry.

Silicone implant reconstruction can be performed at the time of mastectomy or later. Submuscular placement is preferred to minimize complications such as fibrous contracture, which commonly occur after placement of silicone prostheses, particularly if the implant is anterior to the pectoralis major muscle. Retropectoral location also compromises mammographic and physical examination of the reconstructed breast less than a subglandular installation.

The mastectomy incision is frequently used, and the implant is inserted into a pocket located behind the pectoralis major. When the space is too small to accommodate

the implant, a saline-filled tissue expander is used to enlarge the space. Creation of a pocket large enough for a prosthesis may require multiple outpatient visits for injection of increasing amounts of saline. Two or three surgical procedures also will be required to complete the prosthetic reconstruction.

Autogenous tissue transfer is more complicated technically than placement of a prosthesis. It involves more extensive surgery but offers more natural-looking breast simulation. Myocutaneous flaps and microvascular free flaps transport distant tissues to the mastectomy site for creation of a replacement breast mound. The latissimus dorsi flap swings anteriorly on its vascular pedicle to the mastectomy site. With this flap, an implant is often necessary to achieve the appropriate bulk of tissue.

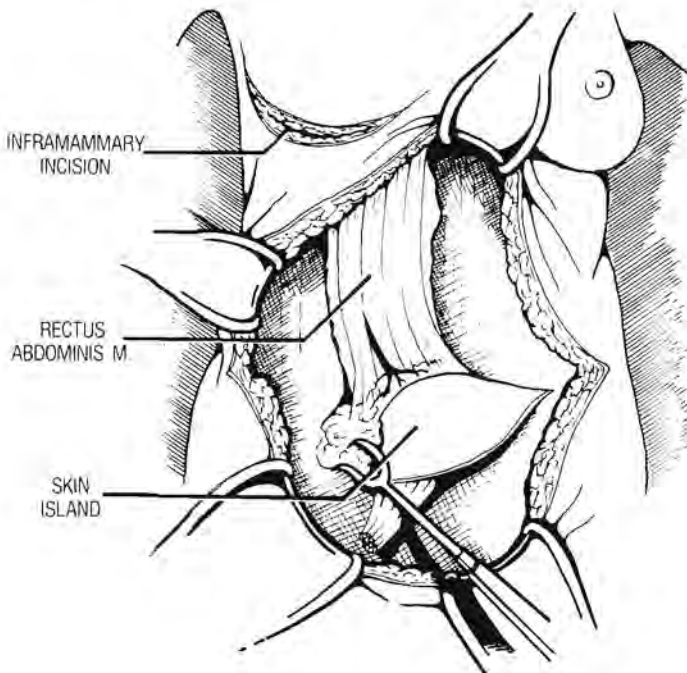
The transverse rectus abdominis myocutaneous (TRAM) flap may achieve the best cosmetic result and does not require a prosthesis. TRAM flap reconstruction is major surgery, doubling the time of mastectomy if reconstruction follows immediately.<sup>14, 92</sup> In this procedure, transverse abdominal incisions are made, forming a large ellipse of subcutaneous abdominal tissue and skin (Fig. 19). On a vascularized pedicle, this flap, attached to the rectus abdominis muscle, is tunneled into the mastectomy site where it is shaped and sewn into place. The abdomi-

nal wound is then closed. Hernias involving the donor site are not uncommon.

Because tumor frequently involves the nipple and areolar tissue, the nipple-areolar complex is not preserved at the time of mastectomy for use in reconstruction. Donor sites for the areola include postauricular skin and that of the upper inner thigh. Tattooing can be used to match the skin color to that of the contralateral areola. A nipple can be created by a variety of flap techniques or transplantation of a portion of the contralateral nipple.

The necessity to image the reconstructed breast has not been established. The mastectomy patient with and without a simulated breast shares the same risk of tumor recurrence. Although film-screen compression mammography can be performed on a reconstructed breast either with an implant or with a myocutaneous flap, in asymptomatic patients with myocutaneous flap reconstruction as with the unreconstructed mastectomy patient, because of the low yield of significant radiographic findings, we no longer perform routine follow-up studies. If findings on physical examination or breast self-examination suggest an abnormality, however, mammography will be performed.

With mammography, no radial ductal organization is seen. Behind the created nipple, no ducts are present. The simulated breast is fatty with vascular and connective tissue ele-



**Figure 19.** Transverses rectus abdominis myocutaneous (TRAM) flap reconstruction. An elliptic incision is made isolating a tissue flap including skin and subcutaneous fat. Maintaining its communication with the rectus abdominis muscle, the flap is brought through the mastectomy incision into the site of breast removal, and the breast mound is fashioned. The abdominal incision is repaired, and the umbilicus restored. (Adapted from Krizek TJ: Breast reconstruction after mastectomy. In Harris JR, Helman S, Henderson et al: *Breast Disease*, ed 2. Philadelphia, JB Lippincott, 1991, p 496; with permission.)



ments scattered randomly (Fig. 20). Clips may be seen near the muscular pedicle. The skin at the sites of suturing may be thickened.

Most often, in myocutaneous breast reconstructions, a palpable mass may be explained by fat necrosis.<sup>14</sup> Patchy areas of soft-tissue density are seen initially. Fine, faint calcifications may develop, which become thicker and heavier in time. Conglomerations of oil cysts, calcified and uncalcified, may occur. Despite a confident radiologic diagnosis of fat necrosis, worrisome physical findings may result in biopsy.

Nodules of recurrent tumor at incision sites will be evident clinically and chest wall recurrences may be studied with CT.

### Augmentation Mammoplasty

Indications for augmentation mammoplasty are for breast reconstruction after mastectomy, for achievement of breast symmetry, for correction of congenital deformities, and for improvement of self-image. More than 1.5 million women have undergone breast augmentation since the early 1960s when silicone gel implants were developed<sup>50, 78</sup>; 150,000

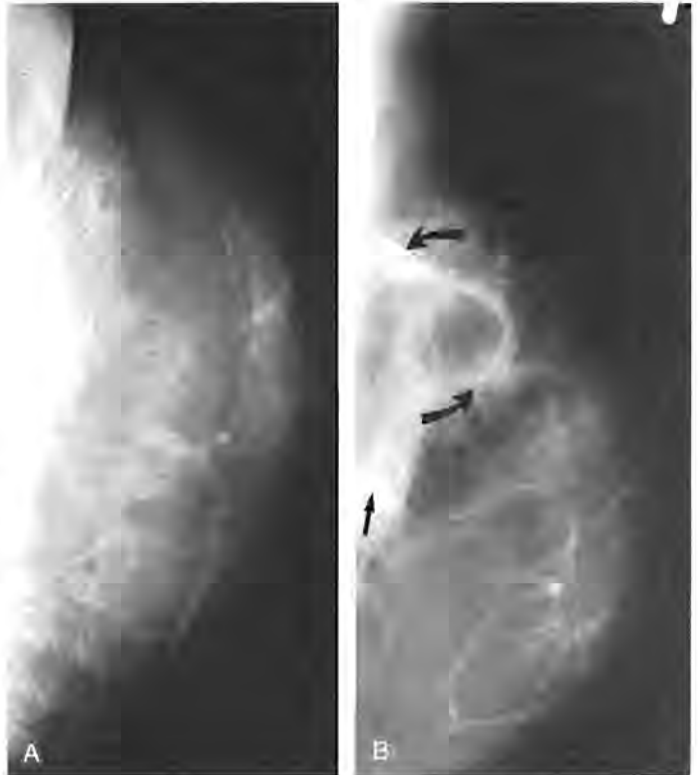women elect the procedure annually,<sup>26</sup> nearly the number expected to receive the diagnosis of breast cancer each year.

Injections of liquid silicone into the breast, which are now illegal in the United States, have caused formation of calcified silicone granulomas, masses, chronic sinus tracts, and drainage.<sup>13</sup> Elastomer-enclosed single lumen silicone implants and the saline injectable double lumen (outer lumen contains saline and innerlumen silicone gel) prostheses are common among the presently used prostheses.<sup>13, 42</sup>

Associated complications include fibrous and calcific contracture; postoperative infection in rash; implant rupture with escape of free silicone into the parenchyma, axillary lymph nodes and ducts; deflation of saline prostheses; and possible association with scleroderma and other connective tissue disorders.<sup>13, 26, 27</sup>

The silicone prosthesis can be positioned via periareolar, axillary, or inframammary incisions either anterior to or behind the pectoralis muscle. The incidence of capsular contractures is higher with subglandular silicone implants, occurring in up to 74% of patients in one study.<sup>13</sup> It is speculated that the overlying muscular thickness compresses

**Figure 20.** TRAM flap with painful mass 5 years after reconstruction. *A*, Craniocaudal view shows rounded, spiculated soft-tissue mass. *B*, Exaggerated craniocaudal projection allows the mass to be seen completely. Central radiolucency suggests a large oil cyst, and the surrounding calcifications (*curved arrows*) are compatible with fat necrosis as well. Surgical clips (*arrow*) are noted in the muscular portion of the flap. Most of the flap is fatty, and no ductal structures are present. Patient had felt a new mass, presumably fat necrosis, that was aspirated by the surgeon and became infected.

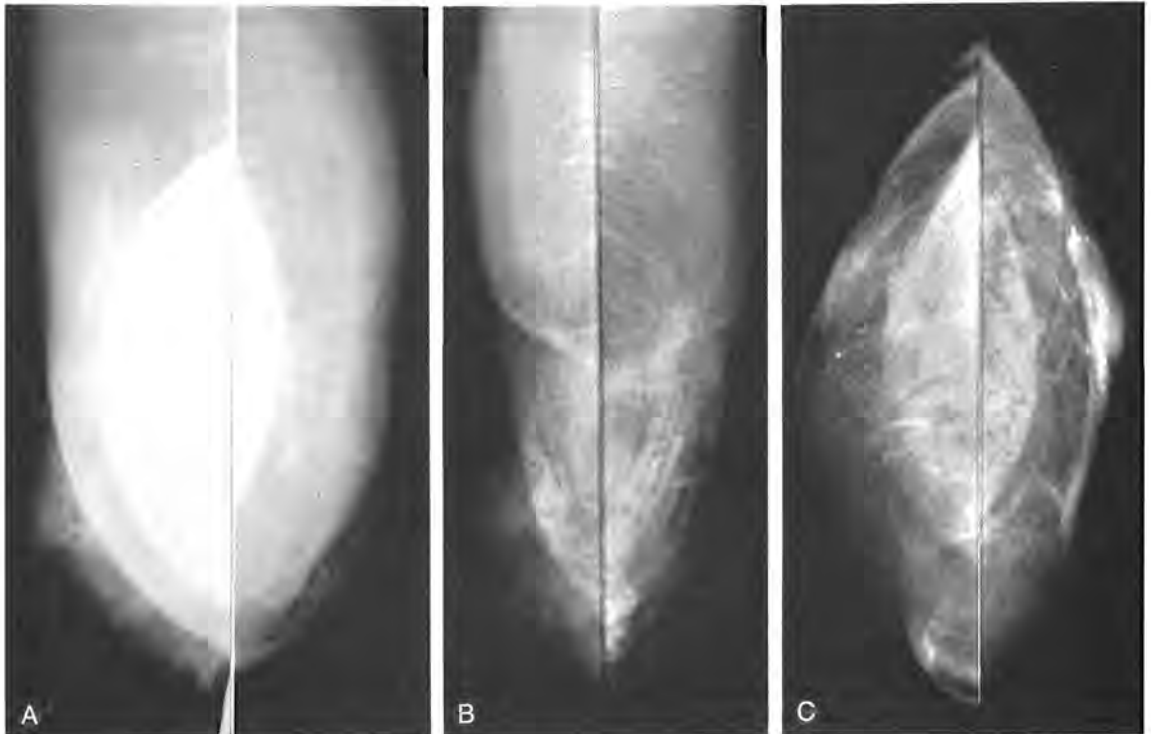

and massages the implant between the muscle fibers and the chest wall, thereby inhibiting development of spherical capsular contracture and minimizing the unnatural firmness of the prosthesis.<sup>13</sup>

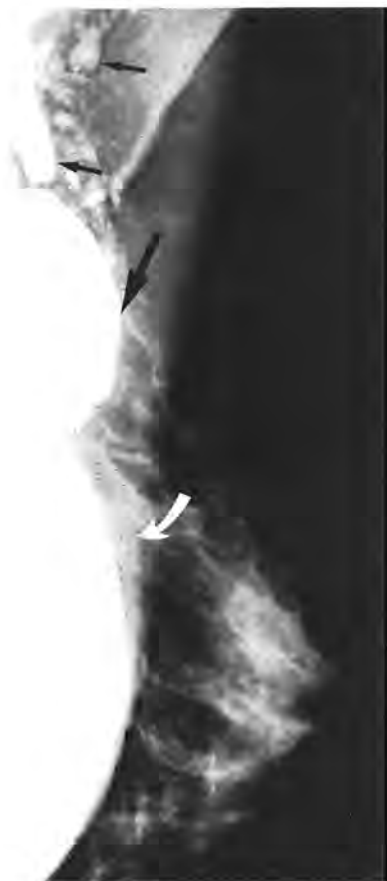Imaging and physical examination of the breast augmented with a retropectoral implant is less compromised than with a subglandular prosthesis.<sup>21</sup> The position of the implant is more secure with the retropectoral location, but submuscular placement is more difficult in the tight, hypertrophic pectoralis muscles of athletic women (Fig. 21). The submusculofascial placement is preferred by most plastic surgeons to the subglandular wherever possible.<sup>13</sup>

The possible reduction in detectability of breast carcinoma is of chief concern with cosmetic augmentation. Silverstein concluded in a study of 20 women with implants and breast carcinoma, 65% of whom were node positive at the time of diagnosis, that the prosthesis might have caused delay in diagnosis.<sup>78</sup>

Eklund reported on modified compression views with which he supplemented the standard mammographic technique in over 250 patients.<sup>26</sup> For the additional views, in craniocaudal and mediolateral projections, the implant is displaced posteriorly against the chest wall while the breast tissue is pulled over and in front of the implant and compressed fully for the image (see Fig. 21). The compression paddle keeps the implant from reentering the field. This technique allowed 2 to 5 cm of additional breast compression, and no ruptures were reported. Eklund notes that for 15% to 20% of patients with fibrous encapsulation of the implants, the technique was more difficult to accomplish. For all patients with implants, the standard views are supplemented by the modified views, and for patients with fibrous encapsulation, he has added a 90-degree lateral view to the standard views for depicting the tissue above and below the implant. The standard views are used to image the posterior breasts. These four views, two standard and two with mod-



**Figure 21.** Modified views for implants. A, Mediolateral oblique projections (MLO) of each breast obtained with routine positioning show hypertrophic pectoralis muscles surrounding the silicone implants. Only a minimal amount of fibroglandular tissue is seen. B, MLO projections of each breast after the implant has been displaced posteriorly and the anterior breast tissue pulled into the compression plates demonstrate only a little more parenchyma. C, Craniocaudal views with the implants displaced posteriorly demonstrate periareolar dermal calcifications that were not seen on the routine projections. Use of the modified views for the anterior tissue along with standard projections for the posterior breasts has partially compensated for limitations on mammography imposed by the radiopaque implants. The positioning techniques are more effective in the retropectoral implant location than the subglandular.



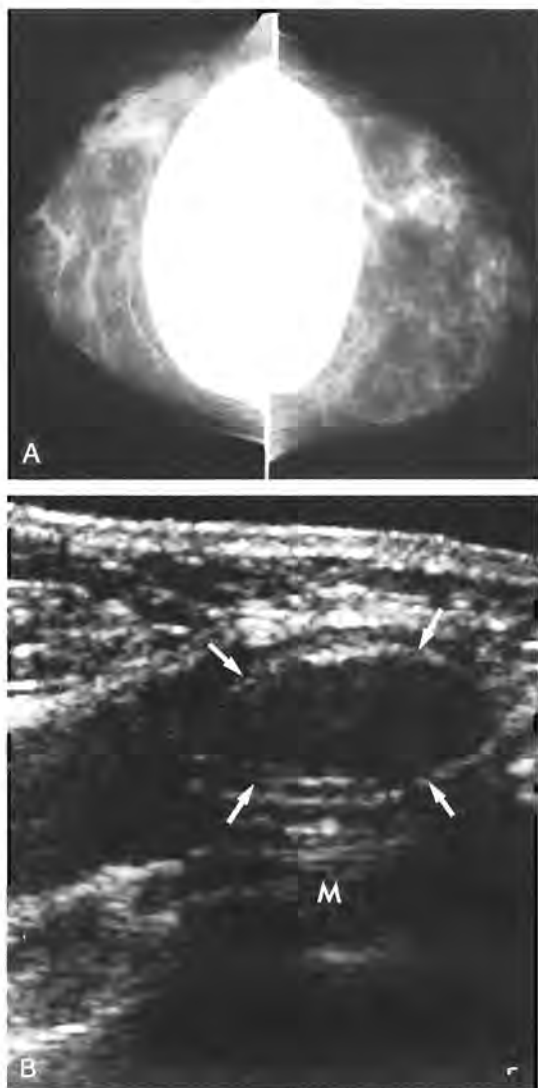
**Figure 22.** Ruptured implant. Silicone globules are seen in the axilla (*small arrows*) to be taken up by lymph nodes and possibly to form calcified granulomas. The patient had presented with a large mass, a diverticulum-like outpouching or contained rupture of the implant (*large arrow*). The implant is seen posterior to the pectoralis muscle (*curved arrow*).

ified positioning, have been adopted in many practices as the protocol for mammography of the augmented breast.

Leibman and Kruse reviewed 11 cases of breast cancer in patients with implants.<sup>50</sup> Sixty percent of the patients were node negative, and 10 of the 11 patients presented with an abnormal mammogram or sonogram. With use of special mammographic techniques including modified compression views and sonography, these authors suggest that early detection of carcinoma should not be an unattainable goal after breast augmentation.

A mass palpated in the augmented breast may represent an abnormality of the breast tissue itself or the implant.<sup>23</sup> The implant's contour may change, becoming spherical with fibrous encapsulation.<sup>21</sup> The implant

may rupture with escape of free silicone into the breast (Fig. 22). Focal herniations or diverticula of the envelope may occur.<sup>23</sup> Particularly with special views, mammography can often identify the cause of an implanted-related palpable mass.<sup>23</sup> Sonography also can frequently delineate a locule within the implant that has simulated a parenchymal breast mass (Fig. 23).<sup>56</sup> Although in one case we were accurate in determining the site of rupture in an implant with sonography, capsular wrinkles and folds often mimic breaks.<sup>56</sup>



**Figure 23.** Palpable mass in augmented patient. *A*, Subglandular silicone implants in routine projections show no contour abnormality of the implants and no mass in the parenchyma of the right breast. *B*, Sonography excludes parenchymal abnormality and shows that mass is a locule (*arrows*) within the implant. On this scan, the pectoral muscle (*M*) can be seen posterior to the implant.

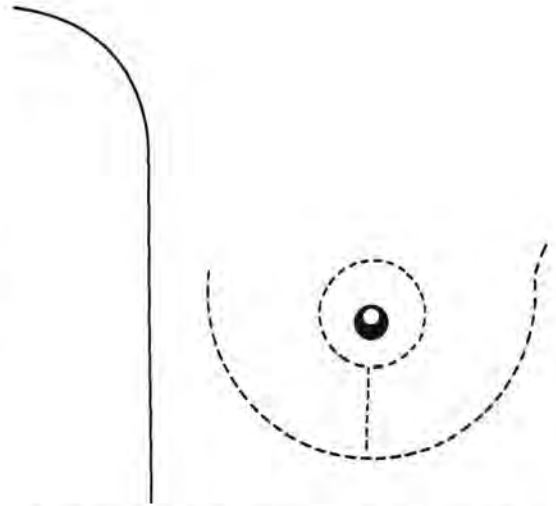
Calcifications develop in the breasts after augmentation and all other surgical procedures. Thin plaques of calcification or bulkier accumulations can form on the capsules. The radiolucent centered coarse eggshell calcifications of silicone granulomas can be seen after implant rupture or with the injection of free silicone. Dystrophic calcifications and those of fat necrosis may form. Indeterminate microcalcifications near the capsule may represent postoperative fibrosis but will require biopsy.

Because a variety of calcifications can be expected to develop after augmentation mammoplasty, we support Leibman and Kruse's suggestion that presurgical and post-surgical mammograms be performed for these patients to ease the task of distinguishing benign postoperative findings from more worrisome parenchymal changes. The four-view study has improved the quality of mammographic examination of these patients, and the modified techniques of positioning also can be applied to procedures such as presurgical needle hookwire localizations. Use of the modified views minimizes chances of implant puncture or poor visualization of the abnormality because of inadequate compression. Sonography should be used for all masses not definitively imaged mammographically and for palpable masses or thickenings not seen on the mammogram. Ultrasound-directed procedures such as cyst aspirations also can reduce the chance of implant puncture.

### Reduction Mammoplasty

Reduction mammoplasty is a common surgical procedure. Indications for breast reduction are to bring the breasts into symmetry after contralateral breast conservation therapy or mastectomy and reconstruction; for treatment of gigantomastia, with its attendant back pain and strap marks; and to address problems of self-image.<sup>13</sup>

Although there are many variations, the surgical procedure involves a circumareolar incision, an inframammary incision, and a vertical incision between the two, with removal of breast tissue, fat, and skin from a combination of these vertical and horizontal incisions (Fig. 24). Breast tissue is removed predominantly from the lower breast, and the nipple-areolar complex is brought upwards.<sup>13, 58</sup>



**Figure 24.** Reduction mammoplasty. A circumareolar incision is made with a vertical incision connecting it to an inframammary incision. Keyhole flaps permit removal of excess breast tissue. At the conclusion of the procedure, the nipple, which has remained attached to a vascular pedicle, is sewn into place in a higher location.

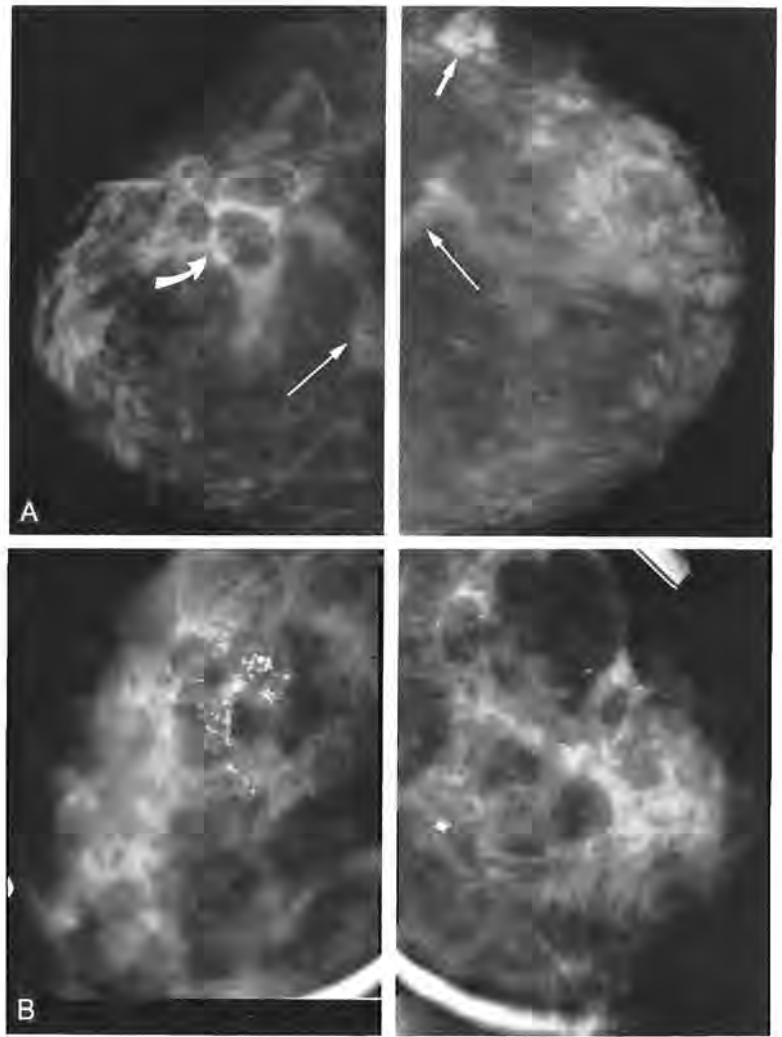
Radiographic features of reduction mammoplasty include redistribution of tissue into the lower breast, with nonanatomic distribution, linear strands, parenchymal bands, and calcifications.<sup>38</sup> The skin is thickened around the incision sites in the periareolar area and inframammary fold. The retroareolar ducts may be interrupted depending upon the type of nipple transplantation procedure. Fat necrosis is common after breast reduction, as in other surgical procedures.<sup>3</sup> Sometimes presenting as a suspicious palpable mass, fat necrosis has many radiographic appearances (Fig. 25). Often beginning as vague, patchy areas of mottled architectural distortion, oil cysts may form and calcify, and fibrosis manifested by spiculation may be seen.<sup>39</sup> Calcification is more worrisome when it first appears, but ultimately coarse, benign plaques will develop. Oil cysts may form large conglomerate masses that may cause clinical concern as palpable findings.

Diagnosis of asymmetric areas of soft-tissue density and developing foci of fat necrosis can be difficult. After reduction mammoplasty has been performed, the symmetry of the mammographic findings and clinical history can suggest a postsurgical cause.

### SUMMARY

With widespread use of mammography for breast cancer screening, the number of sur-

**Figure 25.** Reduction mammaplasty: fat necrosis. *A*, Craniocaudal views show some architectural disorder after excision of breast tissue. A soft-tissue density (*short arrow*) in the outer aspect of the left breast most likely represents fat necrosis, and a grouping of oil cysts is seen in the outer half of the right breast (*curved arrow*). Linear densities (*thin arrows*) near the central posterior breasts suggest scarring related to the inframammary and vertical incisions. Typical findings in breast reduction include fat necrosis, parenchymal bands, retroareolar ductal disruption, and alteration of parenchymal architecture. *B*, More advanced fat necrosis in another patient. Thin arcs of calcification at the rim of oil cysts and heavier deposition of dystrophic calcification are seen bilaterally on these magnified spot compression craniocaudal views.



gical procedures has also increased. Overlapping with radiographic signs of malignancy, including masses, areas of asymmetric density and architectural distortion, microcalcifications, and skin thickening, postsurgical changes may make mammographic evaluation difficult. After tumor excision and irradiation where breast alterations are more profound and prolonged, the task of distinguishing recurrent tumor from scarring or fat necrosis is even more challenging. Mammograms after breast conservation therapy for carcinoma or after cosmetic surgery require correlation with physical findings and the surgical procedures that were performed.

Responses of tissue to lumpectomy and radiation, such as breast edema and skin thickening, are most pronounced 6 to 12 months after treatment, gradually resolving within 1 to 3 years. Carefully tailored mam-

mographic studies will promote the dual goal of early detection of local tumor recurrence and avoidance of misinterpreting postoperative and irradiation changes as malignancy. Sequential examinations should begin with a postoperative preradiation mammogram for residual carcinoma, particularly when microcalcifications have been present, followed by the baseline postradiation examination at 6 months with the next study 6 months later (1 year after initial treatment). Mammograms of the treated breast may be performed at intervals of 6 months until radiographic stability has been recognized. Annual studies thereafter are suggested. The contralateral, unaffected breast should be evaluated mammographically according to screening guidelines or clinical concerns.

Mammograms performed after cosmetic and reconstructive procedures should be cor-

related with the surgical techniques and clinical history. Modified views for silicone implants can maximize visualization of breast parenchyma. Ultrasonography is a useful complement to mammography in demonstrating the origin of a palpable mass either within the implant or the breast parenchyma. In reduction mammoplasty, distorted architecture, parenchymal bands, tissue redistribution, and fat necrosis should be recognized. After mastectomy, myocutaneous reconstruction may be performed. Masses that develop within flap reconstructions most frequently represent fat necrosis, which, when calcifying oil cysts are seen, may have a characteristic radiographic appearance.

## References

- Adler DD: Ultrasound of benign breast conditions. *Seminars in Ultrasound, CT and MR* 10:106-118, 1989
- Aspegren K, Holmberg L, Adami HO: Standardization of the surgical technique in breast-conserving treatment of mammary cancer. *Br J Surg* 75:807-809, 1988
- Baber CE, Libshitz H: Bilateral fat necrosis of the breast following reduction mammoplasties. *AJR Am J Roentgenol* 128:508-509, 1977
- Balu-Maestro C, Bruneton J-N, Geoffray A, et al: Ultrasonographic posttreatment follow-up of breast cancer patients. *J Ultrasound Med* 10:1, 1991
- Barr LC, Brunt AM, Goodman AG, et al: Uncontrolled local recurrence after treatment of breast cancer with breast conservation. *Cancer* 64:1203-1207, 1989
- Bassett LW, Gold RH, Mirra JM: Nonneoplastic breast calcifications in lipid cysts: Development after excision and primary irradiation. *AJR Am J Roentgenol* 138:335-338, 1982
- Berenberg AL, Levene MB, Tonnesen GL: Mammographic evaluation of the postirradiated breast. *In* Harris JR, Hellman S (eds): *Conservative Management of Breast Cancer*. Philadelphia, JB Lippincott, 1983, p 265
- Bland KI, Copeland EM III: General principles of mastectomy. *In* Bland KI, Copeland EM III (eds): *The Breast*. Philadelphia, WB Saunders, 1991, p 570
- Bland KI, Copeland EM III: Halsted radical mastectomy. *In* Bland KI, Copeland EM III (eds): *The Breast*. Philadelphia, WB Saunders, 1991, p 594
- Bloomer WD, Berenberg AL, Weissman BN: Mammography of the definitively irradiated breast. *Radiology* 118:425-428, 1976
- Bohm-Velez M, Mendelson EB: Computed tomography duplex Doppler ultrasound, and magnetic resonance imaging in evaluating the breast. *Seminars in US, CT, and MR* 10:171-176, 1989
- Boring CC, Squires TS, Tong T: *Cancer statistics 1991*. Atlanta, American Cancer Society, Professional Education Publication, 1991, p 10
- Bostwick J III: Aesthetic breast surgery. *In* *Plastic and Reconstructive Breast Surgery*, vol 1. St. Louis, Quality Medical Publications, 1990, pp 195-408
- Bostwick J III: Reduction mammoplasty. *In* *Plastic and Reconstructive Breast Surgery*, vol 2. St. Louis, Quality Medical Publications, 1990, pp 555-1182
- Buckley JH, Roebuck EJ: Mammographic changes following radiotherapy. *Br J Radiol* 59:337, 1986
- Cady B: Choice of operation for breast cancer: Conservative therapy versus radical procedures. *In* Bland KI, Copeland EM III (eds): *The Breast*. Philadelphia, WB Saunders, 1991, pp 753-769
- Cardenosa G, Eklund GW: Paraffin block radiography following breast biopsies: Use of orthogonal views. *Radiology* 180:873-874, 1991
- Cosgrove DO, Bamber JC, Davey J, et al: Color Doppler signals from breast tumors. *Radiology* 176:175-180, 1990
- Davis SP, Stomper PC, Weidner N, et al: Suture calcification mimicking recurrence in the irradiated breast: A potential pitfall in mammographic evaluation. *Radiology* 172:247-248, 1989
- Dempsey PH: Breast sonography: Historical perspective, clinical applications and image interpretation. *US Quarterly* 6:69-90, 1988
- Dershaw DD, Chalagssian TA: Mammography after prosthesis placement for augmentation or reconstructive mammoplasty. *Radiology* 170:69-74, 1989
- Dershaw DD, McCormick B, Cox L, et al: Differentiation of benign and malignant local tumor recurrence after lumpectomy. *AJR Am J Roentgenol* 155:35-38, 1990
- Destouet JM: Mammography of the altered breast. *Syllabus for the Categorical Course on Breast Imaging*. ACR, Nashville, TN, 1990, p 78
- Dinner MI, ARTZ JS: Carcinoma of the breast occurring in routine reduction mammoplasty. *Plastic and Reconstructive Surgery* 83:1042-1044, 1989
- Dubois JB, Saumon-Reme M, Gary-Bobo J, et al: Tumorectomy and radiation therapy in early breast cancer: A report on 392 patients. *Radiology* 175:867-871, 1990
- Eklund GW, Busby RC, Miller SH: Improved imaging of the augmented breast. *AJR Am J Roentgenol* 151:4690473, 1988
- Endo LP, Edwards NL, Longley S, et al: Silicone and rheumatic diseases. *Semin Arthritis Rheum* 17:112-118, 1987
- Feig SA: The role of ultrasound in a breast imaging center. *Seminars in US, CT, and MR*, 10:90-105, 1989
- Fisher B, Bauer M, Margolese R, et al: Five year results of a transabdominal clinical trial comparing total mastectomy and segmental mastectomy with and without radiation in the treatment of breast cancer. *N Engl J Med* 312:665-673, 1985
- Fisher B: Lumpectomy (Segmental Mastectomy) and Axillary Dissection. *In* Bland KI, Copeland EM III (eds): *The Breast*. Philadelphia, WB Saunders Company, 1991, p 634
- Fleck RS, McNeese, Silverbroek NA, et al: Consequences of breast irradiation in patients with preexisting collagen vascular diseases. *Int J Rad Oncol Bio Phys* 17:829-833, 1989
- Fowble B, Solin LJ, Schultz DJ, et al: Breast recurrence following conservative surgery and radiation: Patterns of failure, prognosis, and pathologic findings from mastectomy specimens with implications for treatment. *Int J Rad Oncol Biol Phys* 19:833-841, 1990
- Gallagher WJ, Cardenosa G, Rubens JR, et al: Minimal-volume excision of nonpalpable breast lesions. *AJR Am J Roentgenol* 153:957-961, 1989

34. Geftter WB, Friedman AK, Goodman RL: The role of mammography in evaluating patients with early carcinoma of the breast for tylectomy and radiation therapy. *Radiology* 142:77-80, 1982
35. Hall FM: Immediate postoperative mammogram for failed surgical excision of breast lesions. *Radiology* 180:19-20, 1991
36. Haffty BG, Goldberg NB, Rose M, et al: Conservative surgery with radiation therapy in clinical stage I and II breast cancer. *Arch Surg* 124:1266-1270, 1989
37. Harris JR, Recht A: Conservative surgery and radiotherapy. In Harris JR, Hellina S, Henderson IC, et al (eds): *Breast Disease*, ed 2. Philadelphia, JB Lippincott, 1991, p 395
38. Harris JR, Schnitt SJ, Connolly JL: Conservative surgery and radiation therapy for early breast cancer. *Arch Surg* 122:754-755, 1987
39. Harris KM, Costa-Greco MA, Baratz AB, et al: The mammographic features of the postlumpectomy, postirradiation breast. *Radiographics* 9:253-268, 1989
40. Hassell PR, Olivetto IA, Mueller HA, et al: Early breast cancer: Detection of recurrence after conservative surgery and radiation therapy. *Radiology* 176:731-735, 1990
41. Hellman S, Harris JR: Breast Cancer: Considerations in local and regional treatment. *Radiology* 164:593-598, 1986
42. Hester TR, Bostwick J III: Implants and expanders. In Bostwick J III: *Plastic and Reconstructive Breast Surgery*. St. Louis, Quality Medical Publishing, 1990, pp 131-192
43. Heywang SH, Hilbertz T, Beck: Gd-DTPA enhances MR imaging of the breast in patients with postoperative scarring in silicon implants. *J Comput Assist Tomogr* 14:348, 1990
44. Heywang SH, Wolf A, Pruss E, et al: MR imaging of the breast with Gd DTPA: Use and limitations. *Radiology* 171:95, 1989
45. Hoeffken W, Lanyi M: The breast following surgery and radiation therapy. In *Mammography*. Philadelphia, WB Saunders, 1977, pp 240-256
46. Holland R, Hendriks JHCL, Verbeek ALM: Extent, distribution, and mammographic/histological correlations of breast ductal carcinoma in situ. *Lancet* 335:519-522, 1990
47. Jackson VP: Sonography of malignant breast disease. *Seminars in US, CT, and MR*, 10:119-131, 1989
48. Kinne DW, Kopans DB: Physical Examination and Mammography in the Diagnosis of Breast Disease. In Harris Jr, Hellman S, Henderson IC, et al (eds): *Breast Diseases*, ed 2. Philadelphia, JB Lippincott, 1991, p 83
49. Kinne DW: Primary Treatment of Breast Cancer: Surgery. In Harris JR, Hellman S, Henderson IC, et al (eds): *Breast Diseases*, ed 2. Philadelphia, JB Lippincott, 1991, pp 347-373
50. Leibman AJ, Kruse B: Breast Cancer: Mammographic and sonographic findings after augmentation mammoplasty. *Radiology* 174:195-198, 1990
51. Libshitz HI, Montague ED, Paulus DD: Calcifications and the therapeutically irradiated breast. *AJR Am J Roentgenol* 128:1021-1025, 1977
52. Libshitz HI, Montague ED, Paulus DD: Skin thickness in the therapeutically irradiated breast. *AJR Am J Roentgenol* 130:345-347, 1978
53. McCraw JB, Cramer AR, Horton CE: Breast Reconstruction Following Mastectomy. In Bland KI, Copeland EM III (eds): *The Breast*. Philadelphia, WB Saunders, 1991, pp 656-693
54. Mellink WAM, Hendriks JHCL, Rutgers EJT: The contribution of routine follow-up mammography to an early detection of asynchronous contralateral breast cancer. *Cancer* 7:1844-1848, 1991
55. Mendelson EB, Bhagwanani DG, Bohm-Velez M: Imaging the breast treated by segmental mastectomy and irradiation. *Recent Results in Cancer Research*. New York Springer-Verlag, 1990, pp 175-192
56. Mendelson EB: Imaging the post-surgical breast. *Seminars in US, CT and MR* 10:154-170, 1989
57. Mendelson EB, Harris KM, Doshi N, Tobon H: Infiltrating lobular carcinoma: Mammographic patterns with pathologic correlation. *AJR Am J Roentgenol* 153:265-271, 1989
58. Miller CL, Feig SA, Fox JW: Mammographic changes after reduction mammoplasty. *AJR Am J Roentgenol* 149:35-38, 1987
59. Mitnick JS, Roses DF, Harris MN, et al: Calcifications of the breast after reduction mammoplasty. *Surg Gynecol Obstet* 171:409-412, 1990
60. Mitnick J, Roses DF, Harris MN: Differentiation of postsurgical changes from carcinoma of the breast. *Surg Gynecol Obstet* 166:549-550, 1988
61. Moffat FL, Ketcham AS, Robinson DS, et al: Segmental mastectomy without radiotherapy for T1 and small T2 breast carcinomas. *Arch Surg* 125:364-369, 1990
62. NIH Consensus Conference: Treatment of early stage breast cancer. *JAMA* 265:391-395, 1991
63. Osteen RT, Connolly JL, Recht A, et al: Identification of patients at high risk for local recurrence after conservative surgery and radiation therapy for stage I or II breast cancer. *Arch Surg* 122:1248-1252, 1987
64. Paulus D: Conservative treatment of breast cancer: Mammography in patient selection and follow-up. *AJR Am J Roentgenol* 143:483-487, 1984
65. Paulus D: Mammography of the treated breast. In Feig SA (ed): *Breast imaging - American Roentgen Ray Society categorical course syllabus*. Proceedings of the 88th Annual Meeting of the American Roentgen Ray Society, San Francisco, pp 56-57, 1988
66. Peters ME, Fagerholm MJ, Scanlan KA, et al: Mammographic evaluation of the postsurgical and irradiated breast. *Radiographics* 8:873-899, 1988
67. Rebner M, Pennes DR, Adler DD, et al: Breast microcalcifications after lumpectomy and radiation therapy. *Radiology* 170:691-693, 1989
68. Recht A, Connolly JL, Schnitt SJ, et al: Therapy of in situ cancer. *Hematol Oncol Clin North Am* 3:691-708, 1989
69. Recht A, Eberlein TJ, Sadowsky NL: Local recurrence following breast conservation. In Harris JR, Hellman S, Henderson IC, et al (eds): *Breast Diseases*, ed 2. Philadelphia, JB Lippincott, 1991, pp 541-546
70. Recht A, Hayes DF: Local recurrence following mastectomy. In Harris JR, Hellman S, Henderson IC, et al (eds): *Breast Diseases*, ed 2. Philadelphia, JB Lippincott, 1991, p 529
71. Robertson JM, Clarke DH, Pavzner MM, et al: Breast conservation therapy—severe breast fibrosis after radiation therapy in patients with collagen vascular disease. *Cancer* 68:502-508, 1991
72. Rosenthal E: Many with breast cancer have limited surgery. *New York Times* July 21, 1991, pp A1, A18
73. Sadowsky NL, Semine A, Harris JR: Breast imaging: A critical aspect of breast conserving treatment. *Cancer* 65:2113-2118, 1990
74. Sadowsky NL, Semine A: Good mammography

- finds postop cancer recurrence. *Diagnostic Imaging* October:100-106, 1990
75. Schapira DV, Urban N: A minimalist policy for breast cancer surveillance. *JAMA* 265:380-382, 1991
  76. Sickles EA, Herzog KA: Mammography of the post-surgical breast. *AJR Am J Roentgenol* 136:585-588, 1981
  77. Sickles EA: Periodic mammographic followup of probably benign lesions: Results in 3,184 consecutive cases. *Radiology* 179:463-468, 1991
  78. Silverstein MJ, Gierson ED, Gamagami P, et al: Breast cancer diagnosis and prognosis in women augmented with silicone-gel filled implants. *Cancer* 66:97-101, 1990
  79. Singletary SE, McNeese M: Segmental mastectomy and irradiation in the treatment of breast cancer. *Am J Clin Oncol* 11:679-683, 1988
  80. Solin LJ, Fowble BL, Schultz DJ, et al: Definitive irradiation for intraductal carcinoma of the breast. *Int J Rad Oncol Bio Phys* 19:843-850, 1990
  81. Solin LJ, Fowble BL, Schultz DJ, et al: The detection of local recurrence after definitive irradiation for early stage carcinoma of the breast: An analysis of the results of breast biopsies performed in previously irradiated breasts. *Cancer* 2497-2502, 1990
  82. Souba WW, Bland KI: Indications and techniques for biopsy. In Bland KI, Copeland EM III (eds): *The Breast*. Philadelphia, WB Saunders, 1991, pp 534-550
  83. Stehlin JS, delpolvi PD, Greeff PJ, et al: A ten year study of partial mastectomy for carcinoma of the breast. *Surg Gynecol Obstet* 165:191-198, 1987
  84. Stein MA, Karlan MS: Immediate postoperative mammogram for failed surgical excision of breast lesions. *Radiology* 178:159-162, 1991
  85. Stigers KB, King JG, Davey DD, et al: Abnormalities of the breast caused by biopsy: Spectrum of mammographic findings. *AJR Am J Roentgenol* 156:287-291, 1991
  86. Stomper PC, Gelman RS: Mammography in symptomatic and asymptomatic patients. *Hematol Oncol Clin North Am* 3:611-640, 1989
  87. Stomper PC, Recht A, Berenberg AL, et al: Mammographic detection of recurrent cancer in the irradiated breast. *AJR Am J Roentgenol* 148:39-43, 1987
  88. Sunderland MC, McGuire WL: Prognostic indicators in invasive breast cancer. *Surg Clin North Am* 70:989-1003, 1990
  89. Tábár L, Dean PB: *Teaching Atlas of Mammography*. Stuttgart, Georg Thieme Verlag, 1983, pp 88-90, 134-5
  90. Veronesi U, Banfi A, Salvadori B, et al: Breast conservation is the treatment of choice in small breast cancers: Long-term results of a randomized trial. *Eur J Cancer* 16:668-670, 1990
  91. Veronesi U: Quadrantectomy. In Bland KI, Copeland EM III (eds): *The Breast*. Philadelphia, WB Saunders, 1991, p 631
  92. Wickerham DL, Fisher B: Surgical treatment of primary breast cancer. *Semin Surg Oncol* 4:226-233, 1988
  93. Wolfe J: *Xeroradiography of the Breast*, ed 2. Springfield, Charles C Thomas, 1983, p 20
  94. Wolfe J: *Xeroradiography of the Breast*, ed 2. Springfield, Charles C Thomas, 1983, p 405
  95. Wolfe J: *Xeroradiography of the Breast*, ed 2. Springfield, Charles C Thomas, 1983, p 419

*Address reprint requests to*

Ellen B. Mendelson, MD  
 Department of Radiology  
 The Western Pennsylvania Hospital  
 4800 Friendship Avenue  
 Pittsburgh, PA 15224